Prof. RAMESHWAR SHARMA

Principal & Controller

N. K. MAT

Librarian

G. C. BHAR

Asstt. Li

ORTHOPÆDIC SURGERY

BY

SIR WALTER MERCER

M.B., Ch.B. (Edin.), M.D.(Hon.) (Liv.) (Hon.), F.R.C.S. (Edin.), F.A.C.S. (Hon.), F.P.C.S. (Ire.) (Hon.), F.C.S.S.Af. (Hon.), F.R.S.E. (Hon.), F.R.S. (Edin.)

Professor Emeritus Orthopædic Surgery, University of Edinburgh; Chairman, Editorial Board, Journal of Bone and Joint Surgery; Chairman Editorial Board Journal of the Royal College of Surgeons, Edinburgh; Chairman Standing Advisory Committee on Artificial Limbs, Ministry of Health; Honorary Fellow Royal Medical Society, Edinburgh; Corresponding Member of American Orthopædic Society; Honorary Member of Alberta Orthopædic Society; Member, International Orthopædic Society; Fellow, Association of Surgeons of Great Britain and Ireland; Member, International Society of Surgery; Fellow Emeritus, British Orthopædic Association; Fellow, Société Internationale d'Orthopédie et de Traumatologie

FIFTH EDITION

LONDON

EDWARD ARNOLD (PUBLISHERS) LTD.

© Copyright
First published 1932
Second Edition 1936
Reprinted 1937, 1938
Third Edition 1941
Reprinted 1945, 1947
Fourth Edition 1950
Fifth Edition 1959

Printed in Great Britain by
Butler & Tanner Ltd, Frome and London

PREFACE TO FIFTH EDITION

The response to the fourth edition of this book has necessitated the pleasant but arduous task of writing a further edition. It is, unfortunately, true that before the manuscript is published much of the content is not only not up to date but is actually out of date. Developments take place rapidly in orthopaedic surgery and every month new and important advances occur. All this necessitates a careful search of much literature, and a careful consideration of one's own experience In writing a book that is to be of real value to the younger surgeon a great amount of debunking has to be done, and in particular one should, from one's own experience, show a preference for only what is good and of proved value. This I have tried to do.

Because of this I have made an extensive revision of the previous edition. A considerable amount of new material and many illustrations have been added in order that this book may contain the latest recognized facts in addition to reflecting present-day concepts of aetiology, diagnosis and treatment. The many helpful criticisms and suggestions made by other orthopaedic teachers, colleagues and others have been carefully considered, appreciated, and in many cases incorporated.

Many of the subjects have been re-written, notably congenital dislocation of the hip and other congenital affections, scoliosis, the paralyses, malignant disease and other tumours of bone, and general affections of the skeleton. All other subjects have been carefully revised and, it is hoped, brought up to date

The work could not have been undertaken without much help, and I have particularly to thank Robert Duthie (much revision), George Mitchell (Congenital Dislocation of the Hip and Poliomyelitis), Douglas Savill (Scoliosis), Eric Mekie (Bone Tumours), John Bruce (Hand Infections), and George Pollock (Spastic Paralysis). I appreciate more than I can say the valuable assistance of these friends. I have also to thank William Milne for many excellent line drawings, my secretary, Miss Jane Oliver, who undertook the onerous task of proof-reading, indexing and typing and re-typing and without whose help, indeed, there would have been no book, and many authors from whose writings much valuable material has been taken

W M.

PREFACE TO FIRST EDITION

This volume is a response to many requests that permanent form should be given to the series of lectures and clinique on orthopædic subjects which I have given under the direction of Professor Fraser during the last few years These requests have come from post-graduates reading for the Fellowship in Surgery, and from undergraduates. Their needs, therefore, have received special consideration

Father Stanton remarked once that he did not want to publish his sermons, as people would then recognize how much he owed to Spurgeon. How much I owe to the Spurgeons of my profession will not be difficult to gauge from this work. It would be a hard task for me to redeem these obligations to the goodly company who have been, and are, my surgical guides, and towards whom, through their writings and from personal contact, I cherish that peculiar affection which men feel for their own particular surgical Gamaliels.

It may occasion surprise that a general surgeon should have the temerity to write a book on a special subject, but the Edinburgh Medical School maintains the tradition that a surgical specialty is only a branch of general surgery, and that to become a good specialist one must first be a good general surgeon. In the compilation of a book such as this it has seemed to me to be a considerable advantage to look upon the subject from the point of view of a general surgeon and I hope that that view-point is reflected in these pages

The reader may be surprised also at the appearance of yet another book on this subject. The time, however, appears to be ripe for a volume of moderate size containing the essentials of the old and a summary of the new. An attempt has, therefore, been made to give a comprehensive survey of each subject, including the latest work, and, on occasion, the expression of personal opinion. In a book of limited size it is impossible to consider the details of conflicting theories. Where there is considerable divergence of opinion, the aim has been to give prominence to the theory which appears at the moment to be the most generally accepted, and to deal more briefly with others which are still in the realms of controversy.

Again, owing to the limits of space, no attempt has been made to give a comprehensive bibliography, but where a more detailed study of the literature seemed desirable references have been given to authoritative articles on the various subjects. An endeavour has been made to describe the technique of operations with sufficient detail to enable the young surgeon to perform them with some confidence.

The pleasantest portion of my task is to acknowledge the kindness and help which I have received from so many friends. My first debt is due to my old chief, John Wheeler Dowden, who, seventeen years

ago, imbued me with an enthusiasm for orthopædic surgery that has never left me, and who ever since has been my valued friend and counsellor.

I owe a particular debt of gratitude to Professor John Fraser, who, from the outset, has given me most useful help, inspiring suggestions and a wealth of advice He has been not only a most kindly monitor, but also a most sympathetic friend, and I value more than I can say the encouragement he has given me. Much of the work on which the book is based has been carried out in the Department of Clinical Surgery of the University of Edinburgh under his charge

Most of the proof-reading has been done by my good friend, John Bruce, who has, in addition, supplied the cold and reasoned criticism that is so helpful in the editing of a book. Much of the ease in reading and methods of tabulation are due to him

There are many others to whom I am very grateful I would specially refer to Dr H Torrance Thomson and to Colonel F R Hill, C B E, for assistance in proof-reading, to Dr J C Tainsh, Mr. Allan Armstrong, and the successive Radiologists to the Royal Infirmary of Edinburgh for X-rays, to Mr D B Smith, Assistant in the Laboratory of the University Department of Clinical Surgery, for his great assistance in the photographic work, and to Dr E B Jamieson, for hints on editorial arrangement To Dr Charles Cameron, of East Fortune Sanatorium, I owe a great debt for his valuable suggestions for the chapters on Tuberculosis, and for many of the excellent illustrations in these chapters My secretary, Miss Oliver, has been most helpful and enthusiastic in carrying out the clerical work, and has been untiring in generally supervising the important proof stages

The line drawings have been done by my wife She knows how much her work and her encouragement mean to me

In the bibliography I have, I trust, acknowledged the various sources of information to which I am indebted If, through inadvertence, any have been omitted, I apologize and hope that I may have in the future an opportunity of making due acknowledgement

I wish to acknowledge my indebtedness to Professor John Fraser for permission to reproduce certain diagrams from his book, *Surgery of Childhood*, and to Mr A J Walton, Mr H A T Fairbank, Mr Robert Milne and Mr E Rock-Carling for permission to reproduce diagrams from *Surgical Diagnosis*, edited by Mr A J Walton

Lastly, I have to express my grateful appreciation of the courtesy of the publishers, and the care and attention given to the work by them

W. M

CONTENTS

CHAP.		PAGE
	PREFACE TO FIFTH EDITION	v
	PREFACE TO FIRST EDITION	vii
I	INTRODUCTION	1
	History—Definition—The Scope of Orthopædic Surgery—Examination of a Case—Physical Facts of Importance	
II	CONGENITAL DEFORMITIES	18
	Definition—Congenital Dislocation of the Hip—Congenital Dislocation of the Knee—Congenital Angulation of the Tibia—Congenital Pseudarthrosis of the Tibia—Congenital Talipes—Equino-Varus—Arthrogryposis Multiplex Congenita—Congenital High Scapula—Congenital Short Neck—Cleido-Cranial Dysostosis—Congenital Dislocation of the Shoulder—Cervical Rib—The Scalenus Syndrome—Congenital Wry Neck—Other Forms of Wry Neck—Congenital Ulnar Synostosis—Congenital Absence of the Radius—Madelung's Deformity—Syndactylism—Dystrophy of the Fifth Finger	
III	GENERAL AFFECTIONS OF THE SKELETON	98
	The Organic Structure of Bone—The Development of Bone—Osteoporosis—The Healing of Fractures—Developmental Diseases of Bone—Achondroplasia—Chondro-Osteo-Dystrophy—Multiple Osteochondritis—Dyschondroplasia—Multiple Enchondromata—Metaphysial Aclasis—Polyostotic Fibrous Dysplasia—Monostotic Fibrous Dysplasia—Osteogenesis Imperfecta—Osteopetrosis—Osteopoikilosis—Engelman's Disease—Rickets—Genu Varum—Genu Valgum—Scurvy and Scurvy Rickets—Coeliac Rickets—Renal Osteo-Dystrophy—Osteomalacia—Parathyroid Osteodystrophy—Thyrotoxic Osteoporosis—The Pituitary—Disturbances—Dwarfisms—The Hyperpituitary Syndromes—Gigantism—Acromegaly—Congenital Hypothyroidism—Post-Traumatic Osteodystrophy at Joints—Myositis Ossificans Progressiva—Osteitis Deformans—Infantile Cortical Hyperostosis—The Reticulo-Endothelial Disturbances of Bone—Hodgkin's Disease—Histiocytic Granulomatosis—Lipoid Granulomatosis—Eosinophilic Granulomatosis—Letterer-Siwe Disease—Gargoylism	
IV	AFFECTIONS OF BONES	208
	Osteomyelitis—Tumours of Bone—True Bone Tumours—Non-Osteogenic Tumours of Bone—Tumours arising from Included Tissues—Metastatic Bone Tumours—Syphilitic Disease of Bone	
V	TUBERCULOSIS OF BONE	272
	General Considerations—Tuberculosis of the Spine—The Short Long-Bones of the Hands and Feet.	
VI	TUBERCULOSIS OF JOINTS	335
	General Considerations—Tuberculosis of the Hip Joint—Tuberculosis of the Knee Joint—Tuberculosis of the Ankle—Disease of the Tarsus—Disease of the Sacro-Iliac Joint—Disease of the Shoulder Joint—Disease of the Elbow Joint—Disease of the Wrist Joint.	
VII	NON-TUBERCULOUS AFFECTIONS OF JOINTS	392
	Pyogenic Arthritis—Acute Infective Arthritis of Infants—Aspiration of Joint Effusions—Pneumococcal Arthritis—Gonococcal Arthritis—Syphilis of Joints—Hæmophilic Arthritis—Hysterical Joints—Hypertrophic Pulmonary Arthropathy—Arthritis of Brucellosis	

CHAP PAGE

VIII CHRONIC ARTHRITIS . . . 421
Introduction—Rheumatoid Arthritis—Still's Disease—Reiter's Disease—Felty's Syndrome—Chronic Villous Arthritis—Osteo-arthritis—Arthritis in the Individual Joints—Tuberculous Rheumatism—Intrapelvic Protrusion of the Acetabulum—The Neuropathic Joint—Alkaptonuric Arthritis—Gout

IX AFFECTIONS OF THE EPIPHYSES 479
Osteochondritis, or Epiphysitis—Osteochondritis Deformans Coxæ Juvenilis—Osgood-Schlatter Disease—Osteochondritis of the Upper End of the Tibia—Osteochondritis of the Lower End of the Tibia and Fibula—Kohler's Disease of the Tarsal Navicular—Epiphysitis of the Calcaneus—Coxa Vara—Avulsion of the Lesser Trochanter of the Femur—Osteoporosis of the Carpal Bones

X PARALYSIS . 514
The Muscular Dystrophies—The Myopathies—Friedreich's Ataxia—Progressive Muscular Atrophy—Peroneal Muscular Atrophy—Syringomyelia—Poliomyelitis—Cerebral Palsy

XI AFFECTIONS OF NERVES 588
Lesions of the Peripheral Nerves—The Median Nerve—The Carpal Tunnel Syndrome—The Ulnar Nerve—Traumatic Ulnar Neuritis—The Radial Nerve—The Circumflex Nerve—Lesions of the Brachial Plexus—The Cervical Sympathetic—Obstetrical Paralysis—The Sciatic Nerve—The Lateral Popliteal Nerve—Anterior Tibial Syndrome—Medial Popliteal Nerve—Causalgia

XII CIRCULATORY DISTURBANCES OF THE EXTREMITIES 629
Circulation of the Extremities—Classification of Vascular Disturbances—Primary Vaso-Motor Lesions—Raynaud's Disease—Acrocyanosis—Erythromelalgia—Immersion Foot and Immersion Hand—The Primary Obliterative Disturbances—Embolism and Thrombosis—Thrombo-angiitis Obliterans—Arteriosclerosis—Leriche Syndrome—Diagnosis of Vascular Disease—Treatment of Peripheral Vascular Disease

XIII AFFECTIONS OF THE SPINE 659
Low Back Pain a consideration of the various causes and their treatment—Congenital Errors—The Neural Arch—Spondylolisthesis—Kissing Spines—Sprung Back—Sacralization of the Transverse Processes of the Fifth Lumbar Vertebra—Low Back Pain following Trauma—Strains—Injuries of Intervertebral Joints, Ligaments and Muscles—Low Back Pain associated with Pathological Changes—Spondylosis Deformans—Fibrositis—Pyogenic Osteomyelitis—Brucella Spondylitis—Low Back Pain associated with Static or Postural Errors—Low Back Pain referred from Other Regions—Low Back Pain from a Combination of Causes—Sciatica—Prolapsed Intervertebral Disc—Kummel's Disease—Vertebra Plana—Scoliosis—Antero-Posterior Curvature of the Spine—Kyphosis in Adolescence—Kyphosis in Adults and the Aged—Spina Bifida

XIV AFFECTIONS OF THE SHOULDER JOINT 763
A Consideration of the Various Lesions—Sprains—Muscular Strains—Acute Synovitis—Bursitis—Lesions of the Supraspinatus Tendon—Tendinitis — Calcification — Rupture — Peri-articular Adhesions — Recurrent Dislocation of the Shoulder Joint—Recurrent Dislocation of the Acromio Clavicular Joint—Dislocations of the Medial End of the Clavicle—Dislocation of the Biceps Brachii—Snapping Shoulder—Snapping Scapula—Winged Scapula—Neuralgic Amyotrophy—Protrusion of the Cervical Intervertebral Disc—Osteo-arthritis of the Cervical Spine—Spontaneous Axillary Thrombosis

CHAP. PAGE

XV AFFECTIONS OF THE KNEE JOINT 802
A Consideration of the Anatomy—Injuries and Displacements of the Semilunar Cartilages—Displaced Lateral Cartilage—Cysts of the Semilunar Cartilages—Rupture of the Cruciate Ligaments—Rupture of the Lateral Ligaments—Old Injuries of the Medial Collateral Ligament—Genu Valgum—Fractures of the Tibial Spine—Affections of the Infra Patellar Pad—Bipartite Patella—Chondromalacia of the Patella—Habitual or Recurrent Dislocation of the Patella—Loose Bodies—Pellegrini Stieda—Osgood

XVI AFFECTIONS OF THE FOOT 851
Static Disturbances of the Foot—The Arch of the Foot—The Unstable Foot—Congenital Flat Foot—Acquired Flat Foot—Peroneal or Spasmodic Flat Foot—Affections of the Bones and Joints of the Metatarsus—Hallux Valgus—Hallux Rigidus—Metatarsalgia—March Foot—Kohler's Disease of the Metatarsal Head—Freiberg's Infraction—Painful Conditions of the Heel—Painful Conditions of the Ankle—Club Foot—Shortening of the Tendo Calcaneus—Hammer Toe—Ingrowing Toe Nail—Subungual Hematoma—Onychogryphosis—Subungual Exostosis—Hyperidrosis—Athlete's Foot—Chronic Chilblains—Fracture of the Sesamoid Bones of the Great Toe—Overlapping of the Fifth Toe

XVII SOME COMPLICATIONS OF TRAUMA 906
Volkmann's Ischemic Contracture—Myositis Ossificans Circumscripta—Fracture—Delayed Union—Non-Union—Ununited Fracture of the Neck of the Femur—Malunion of Fractures of the Calcaneus—Mal-Union of a Pott's Fracture—The Problem of the Short Leg—The Problem of the Stiff Knee—Flexion Contracture of the Knee

XVIII MANIPULATIVE SURGERY 949
Adhesions—The Choice of Cases for Manipulation—Prevention of Adhesions—Treatment of Adhesions by Manipulation—The Treatment of Individual Joints—The Foot—The Knee—The Hip—The Spine—The Shoulder—The Elbow—The Wrist

XIX ARTHRODESIS AND ARTHROPLASTY 963
Arthrodesis—Arthrodesis in the Various Types of Arthritis—Arthrodesis for the Sequelæ of Trauma—Arthrodesis in Paralysis—Arthrodesis in the various Joints—The Hip—The Knee—The Ankle—The Shoulder—The Elbow—The Spine—The Wrist.
Arthroplasty—Indications for Arthroplasty—Technical Considerations in Performing any Arthroplasty—Arthroplasty of Individual Joints—Arthroplasty of the Elbow—Carpo-Metacarpal Arthroplasty—Arthroplasty of the Hip—Arthroplasty of the Knee

XX AFFECTIONS OF SOFT TISSUES 982
Ganglion—Affections of Bursæ—Traumatic Bursitis—Infectious Bursitis—Syphilitic Bursitis—Gouty Bursitis—Diseases of Individual Bursæ—Dupuytren's Contraction—Injuries of Muscles—Injuries of Tendons—Dislocations of Tendons—Trigger Finger—Stenosing Tendo-Vaginitis at the Radial Styloid—Acute Infections of the Hand—Superficial Whitlows—Deep Whitlows—Tenosynovitis—Abscesses of the Hand—Infection of the Palmar Cellular Spaces—Snapping Hip

BIBLIOGRAPHY 1041

INDEX 1057

ORTHOPÆDIC SURGERY

CHAPTER I

INTRODUCTION

Sir Arthur Keith has aptly defined the scope of orthopædic surgery: "To effect the repair of the mechanical framework of the human body by all operations and appliances which may have that aim in view."

The term "orthopædy," adapted from the two Greek words, ὀρθός, meaning straight, upright, or free from deformity, and παῖς, παιδός, a child, was originally used by Nicholas Andry, whose work, *L'Orthopédie, ou l'Art de prévenir et de corriger dans les enfants les difformités du corps*, was published in 1757; and though orthopædic surgery has long since outgrown its original definition, no more descriptive or more accurate term has been invented for it so far.

Modern orthopædics is concerned with the study of the form and function of the human frame; its attack is directed against those affections that deform the architecture or arrest the balanced mechanism of man's body, and injuries of bones, muscles, nerves and soft structures which result in loss of form or function, are thus its legitimate objective.

Andry originally taught orthopædics as a branch of preventive medicine, rather than as an off-shoot of surgery and the various methods he described of preventing and correcting bodily deformities in children were, in his own words, within the reach of "fathers, mothers, nurses, and others entrusted with the bringing up of children." Andry's words need not be passed over lightly, for they have a moral even for our enlightened days: prevention is always better than cure, and if the principles and practice of preventive orthopædics were more liberally applied to-day, many of the severer degrees of flat foot, scoliosis, and similar deformities would disappear. But the timely institution of preventive measures demands the early recognition of incipient loss of form or function—an ideal to be attained only by periodical inspection of the young by one trained in orthopædic surgery.

The solution of the problems of an orthopædic case depends on a clear understanding of the pathological nature of each lesion, and success in treatment on a scrupulous attention to minute detail. Orthopædic work is thus exacting, for the surgeon must supervise personally each detail of treatment, and consequently devote more time to

each individual patient than in any other branch of clinical work The stimulus of success, however, will prove an ample reward, and the lightening of the burden of cripples and the deformed—not only the physical and visible burden, but the subtler and less evident mental one—may well be considered the pinnacle of surgical achievement. Those who escape contact with the deformed do not appreciate the keen mental anguish which they suffer—a mental anguish that led Gloucester, when bewailing his fate in his sad monologue in *Richard III*, to exclaim .

> "Cheated of feature by dissembling nature,
> Deformed, unfinished, sent before my time
> Into this breathing world, scarce half made up,
> And that so lamely and unfashionable,
> That dogs bark at me as I halt by them"

Even if no other word is uttered, it is worth while to hear your patient say, "You have made me walk."

The Scope of Orthopædic Surgery. Orthopædics as a specialized branch of surgery, though it has been growing progressively since the days of its great pioneers, has achieved its present prominence largely as a result of two closely related factors ; the casualties of the two wars, and the accidents incidental to the present mechanical age have, together, shown the need of better treatment for the injured, and aroused surgeons everywhere to greater effort.

Orthopædic affections fall into one or other of six groups :

1. Congenital anomalies
2. Affections of joints
3. Affections of bones
4. Affections of muscles, tendons, and other soft tissues.
5. Affections of the nervous system
6. Static deformities

While many of the lesions have a definite pathological basis, it is being realized more and more that a large number of orthopædic disorders are the end results of postural or static anomalies induced by habit, rather than by definite pathological change In this connection Goldthwaite has pointed out that only by using the body correctly can the best be got out of it, and that should the elaborate mechanism which controls and maintains the body in its upright position fail, the body processes are upset and the stage is set for many obscure and distressing maladies The rôle of the orthopædic surgeon in such a case is to correct body posture He became convinced, furthermore, that to treat any of the sequelæ of faulty posture was futile without first correcting the posture itself by ensuring the correct use of the body and by modifying faulty mechanics Many of the following pages are occupied with this aspect of the orthopædic problem , its intrinsic importance is great, and, further, it has an important lesson

to teach—that, from the orthopædic standpoint, the body must be viewed as a whole, even though the actual complaint is a local one.

The Examination of an Orthopædic Case

No part of orthopædic training is more important than the acquisition of a systematized method of examination. It cannot be too strongly urged that a true knowledge of disease, which forms the basis of successful diagnosis and treatment, can be formed only on the careful and accurate study of individual cases. Scientific and orderly investigation is as essential in orthopædic conditions as in any obscure internal malady.

I. The History.

At the first consultation, it is necessary to elicit a complete and accurate history of the patient's complaint, the mode of its onset, and the order in which the symptoms were first observed.

(*a*) *The Complaint.* The chief complaint may suggest to some extent the nature of the affection, while it always focuses attention on some definite part of the body.

(*b*) *The Manner of Onset.* The illness may begin suddenly, or it may be gradual and insidious in its development. Apart from trauma, the most likely cause of sudden derangement is acute infection. When the onset is insidious, it may be due to a low-grade inflammation, granuloma or tumour, a slow degenerative process, or a postural anomaly.

(*c*) *Pain.* The type, character, and distribution of the pain are important, since they all assist in reaching a diagnosis.

(*d*) *The Question of Preceding Injury.* There is a distinct tendency to ascribe all orthopædic symptoms and errors to some injury, often sustained at a date considerably remote. An attempt should always be made to ascertain the exact details of any alleged trauma, and to establish its exact relation to the actual lesion as this may have important medico-legal bearings. Such an inquiry should be directed towards discovering whether the symptoms arose at the time of the injury, existed previously, or only appeared subsequently. An example will make the importance of such an investigation obvious. The author was recently consulted by a lady who suffered from a dislocation of the hip which she ascribed to a recent railway accident. After careful clinical and radiological examination, it was evident that the condition was a congenital dislocation. A good practical rule is to ascertain whether the patient was able to leave the scene of the accident unaided, or whether he required immediate assistance.

II. Clinical Features; Symptoms and Signs.

The clinical features may be objective or subjective. The objective features, or signs, are those—such as deformity, errors in attitude or gait, and limitations of movement—which are obvious to the examiner. The subjective symptoms are those of which the patient complains, but of which the surgeon has no definite positive evidence. Considerable tact

and discrimination are often required to disentangle the truth from the complaints of patients who are neurotic, hysterical, or malingering.

III. The Examination of the Case.

The examination of an orthopædic case must include not only the physical condition of the patient, but any laboratory tests, and special investigations suggested by the clinical findings. Unless the complaint is a minor one, limited to one extremity, it is wise to make the examination with the patient stripped of all clothing, save, perhaps, bathing drawers, and, in the case of a female patient, some covering for the breasts The examination may be conveniently considered in two parts

1 The examination of the body as a whole

2. The examination of the affected member or part.

(*a*) *The Examination of the Body as a Whole* The attitude and carriage of the body are observed when the patient stands and walks and the manner in which the weight is borne on the soles of the feet, and the relation of the feet to the legs, should be noted The relation of the hips to the pelvis, and of the shoulders to the chest, is observed, and the contour of the spine, chest, and abdomen investigated. The inspection of the body is carried out from behind as well as from the front and laterally. Particular attention is paid to the spinal column and the situation of the spinous processes may be marked with a skin pencil, and also the lower angles of the scapulæ The position of the pelvis in the erect posture is often important, and differs in the two sexes. The female pelvis is lighter in construction than the male , its height and the expansion of its iliac crests are less The position of the pelvis depends upon the iliofemoral ligaments , when these are short, it lies more obliquely, as the pelvis is pulled forwards , when they are long, a greater degree of extension is possible at the hip joints, and the pelvis is tilted backwards and loses a good deal of its obliquity In men, the pelvis obliquity is less than in women, and the anterior superior spine lies on a plane slightly posterior to that of the symphysis pubis , the curvature of the lumbar spine is thus less than in the female, in whom lumbar lordosis is often marked

(*b*) *The Examination of the Affected Member or Part.* The thorough examination of the affected part demands a considerable knowledge of the anatomy of its joints, nerves, and muscles It should also follow a routine plan and must never be haphazard or unsystematic. The various details observed and elicited should be carefully recorded.

Method of Examination

(a) Inspection. The attitude in which the part is held, its general appearance and colour, and the presence of deformity, are noted. In the case of a limb, a comparison should always be made between the affected and the presumably healthy side

(b) Palpation. Handling of the affected part will elicit such objective phenomena as tenderness, fluctuation, elevation of local tem-

perature, induration, or gross alteration in shape. Friction within a joint may be discovered by combining palpation with passive movement.

(c) Passive Motion. Valuable information may be obtained by carrying out the movements of which the part is normally capable, and by comparing this range with that on the normal side. The amount and quality of the movements are assessed, and the presence or absence of pain determined.

Limited joint movement may be due to some bony block, to adhesions between the joint surfaces, or to reflex spasm of the related muscles, as in early cases of tuberculosis. During movement there may be a grating or crackling sensation, comparable to that produced between the ends of a broken bone. Such crepitation is characteristic of osteoarthritis.

Abnormal joint movement may take the form either of excessive mobility, or of false mobility. In the former, the normal range of movement is exaggerated in every direction; in the latter, the joint moves in a new or abnormal direction.

(d) Active Motion.—This represents the degree to which the patient can, without assistance, move the affected part. It is usually considerably less than the amount of passive motion, the limitation being due to a similar cause, aggravated by a greater degree of spasm or weakness or paralysis of the associated muscle groups.

In certain cases it may be advisable to record accurate observations of the range of active mobility: this is usually done by employing an apparatus such as an arthrometer. It is often instructive to compare the readings on subsequent occasions, as in this way an index of improvement is provided. The instrument is a simple one, consisting essentially of two metal strips, joined by a hinge. Opposite the joint there is a protractor, graduated in degrees. The joint is controlled by a thumb screw, so that after the angle or arc of movement has been estimated, the arthrometer can be fixed until the reading is made. Other methods may be employed, but it is important always to adopt the same technique to eliminate possible sources of error.

In making the record, the degree of passive and active movement at any joint may be conveniently denoted by symbols; e.g N 4 may be used to represent the normal, N 3 for 75 per cent. of normal, N 2 for 50 per cent. of normal, and so on.

(e) Measurement. Careful comparison of the measurements of the affected part with those of the opposite healthy side will often demonstrate atrophy or hypertrophy.

The length of the limbs is measured in order to assess any inequality that may be present. In the leg, the measurement is taken from the anterior superior spine to the level of the knee joint, or to the medial malleolus Certain lines may be drawn in the neighbourhood of the hip joint which are of value in discovering the site of any shortening in that region.

Nelaton's line extends from the anterior superior spine to the

tuberosity of the ischium Normally it passes through the tip of the greater trochanter, but in pathological conditions of the head or neck of the femur the trochanter is displaced upwards and lies above Nelaton's line.

Bryant's triangle is formed by the perpendicular dropped from the anterior superior spine when the patient is lying on his back. The base is the line extending from the tip of the trochanter to this perpendicular, while the hypotenuse is represented by the line joining the trochanter and the anterior superior spine. Here again, in pathological conditions of the femoral neck or head, the base of the triangle is shortened, whereas in fractures of the shaft, or shortening situated in parts other than in the base and neck, the normal relations are maintained.

Schoemaker's line is valuable in that its demonstration requires no movement of the patient It is drawn from the tip of the great trochanter through the anterior superior spine and prolonged towards the mid-line. Where the trochanter is displaced upwards, the continuation of the line meets the middle line of the body below the umbilicus, whereas in the normal case the mid-line is reached above the umbilicus.

(f) Auscultation. This may be of value, particularly in the neighbourhood of joints, for locating crepitation, snaps, and friction-rubs. As a rule, however, these can be detected without the aid of the stethoscope

(g) Neurological Examination. Routine neurological examination is unnecessary, but sometimes, when lesions of the nervous system are suspected in adult patients, it may be of value to test the reflexes, and the cutaneous sensation. If necessary, a systematic neurological investigation can then be carried out, including the withdrawal and the examination of the cerebro-spinal fluid Lesions of the peripheral nerves form an important class of orthopædic error, examination in such cases must follow a systematic plan, consideration of which is discussed later

(h) Aspiration. In cases of joint effusion, and in cystic swellings in other areas, aspiration and examination of the joint- or cyst-contents may yield valuable information A 10 c.c syringe should be used, with a fairly long needle of wide gauge The needle is inserted through the skin some way from the swelling, in order that the skin puncture be situated as far as possible from the breach in the cyst or joint capsule; in this way risk of subsequent infection is diminished.

The contents should be submitted to microscopic and chemical examination, and an attempt made to culture any organism present. A Wassermann test is carried out when necessary.

In some cases—particularly in tuberculosis—it may be advisable or even essential for diagnostic purposes to inoculate a guinea-pig with the aspirated material.

(i) Radiological Examination. Examination by X-rays is necessary to complete the diagnosis in the majority of orthopædic conditions. When the affection is unilateral, it is usually advantageous to secure at

the same time a radiograph of the normal side, as by this means the slightest and earliest evidences of disease may be recognized. Care must be taken, however, to ensure that the two sides are in a strictly similar position at the time of exposure. In parts such as the pelvis, hip joint, shoulder, and skull, a stereoscopic view is invaluable.

In a proportion of cases, the radiogram will be negative. Even after definite bone inflammation a considerable time—even up to six weeks—may elapse before reliable X-ray evidence of change appears. In the case of bone diseases, therefore, it is often necessary to make repeated exposures of the affected part before a conclusion can be reached regarding the presence or absence of a real pathological process.

The X-ray film may not only establish the diagnosis; it may assist the surgeon to formulate a prognosis, while examination at repeated intervals, especially in tuberculous bone or joint lesions, enables him to assess the progress. It seems unnecessary to point out that the quality of the film must be high if important decisions are to be made on its evidence. A radiogram of bones, to be of any value, must show up clearly the internal architecture.

The pathological changes revealed by radiograms of bone are of three types:

(a) *Atrophy*, or wasting, of the osseous structure, demonstrated by a decrease in density and loss of trabeculation. It is due to loss of lime salts, and may be local or general.

(b) *Hypertrophy*, or increased density of bone structure. This also may be widespread throughout the bone, or localized to a small area.

(c) True *destruction* of bone. The area destroyed may be an entire segment of bone, or a localized superficial erosion and occasionally a small area of destruction is found in the interior of the bone. The various findings have all a definite significance which will be referred to later. In many cases, too, all these conditions co-exist within the same bone.

The radiographic examination of joints should always include two views at different angles, particularly if the joint is fixed in an abnormal position. It has been shown by Campbell that when the knee joint is fixed in flexion and the routine antero-posterior view of the joint is impracticable, a satisfactory anterior view may often be secured by fixing the film to a cylinder which is placed in the popliteal space when the exposure is made.

(j) **Pathological Examination.** The last method which may have to be resorted to is biopsy, in which a portion of tissue is removed for microscopic and pathological examination. This method is particularly applicable to cases of tumours, both of bone and other tissues, and joint infections of doubtful origin. When tuberculosis is suspected, the tissue removed may be emulsified and injected into a guinea-pig. Such injections are usually made into the peritoneal cavity of the animal, and six weeks later the lymphatic glands are examined for the bacillus of tuberculosis, or for evidence of its presence.

Plaster-of-Paris Technique

An orthopædic surgeon must know how to apply a plaster case; this knowledge is as essential for an orthopædist as is a knowledge of asepsis for any general surgeon. Calot has said very truly that you can judge of the skill of the orthopædic surgeon by the apparatus he uses. "Show me your plaster apparatus and I will tell you what kind of orthopædist you are."

Plaster of Paris is more frequently used than any other material for retentive apparatus in orthopædics, and by its use the different parts of the body may be secured in any position desired. Its popularity is based on two considerations; firstly, it is necessary to maintain a limb in the desired position only for the few minutes required for setting, and then the position is secured permanently; secondly, because of its adaptability it gives results superior to those of all the splints of metal or of wood that have ever been evolved.

The equipment necessary for the application of plaster is as follows:

(*i*) *Crinoline*, a gauze stiffened with starch. A special crinoline, or book muslin, is used which has a mesh of 32 threads to the inch each way. It is cut in the desired widths—4, 6, and 8 inches being the most useful

(*ii*) *Plaster of Paris* or calcium sulphate—a white powder made from gypsum and known as "superfine plaster." The stone is crushed and pulverized, after which it is subjected to intense heat so that the water of crystallization is driven off. When mixed with water, it undergoes a re-crystallizing process which is commonly called "setting."

(*iii*) *Stockinet*, or underwear material, bought in various widths.

(*iv*) *Wool bandages.*

(*v*) *White felt*, preferably of the piano-makers' type. Saddlers' felt, though much cheaper, is coarser and not so comfortable for the patient. The thickness of the felt varies to about three-quarters of an inch. It can easily be split into thinner pieces

The felt, wool bandages and stockinet are sterilized in the autoclave to eliminate risk of tetanus spores infecting a plaster sore.

(*vi*) *White adhesive felt*, a quarter of an inch thick, backed with zinc oxide.

(*vii*) *Aluminum strips.* These should be about 2 feet long, roughened, perforated, and flexible

(*viii*) *Cramer wire*, $3\frac{3}{4}$ inches by 24 inches.

(*ix*) Some *wood lathes*, one inch square, of various lengths, for reinforcing plaster and for buttresses

(*x*) An *orthopædic* or *fracture table* of the "Shropshire Horse" type.

(*xi*) An *Abbott frame.*

(*xii*) An upright *suspension frame*, with spare apparatus attached

The instruments required are Stille's plaster cutters of various sizes, a saw, a hacksaw, a plaster opener of the glove stretcher type, plaster

benders, Bohler scissors, strong scalpels, plaster knives, wire cutters, indelible pencils, tape measure, pails, bowls, troughs, and pillows or sandbags of various sizes.

It is much more economical and satisfactory to use Gypsoma or other commercial bandages. They are of a standard weight and composition, and set easily and quickly, and are lighter than the home-made variety.

The Application of the Plaster. When the limb is in the desired position preliminary padding of wool, bandage or stockinet may be applied. The padding should be applied in a thin layer, otherwise it tends, in time, to become compressed, with the result that the plaster loosens, and friction sores may develop. It should be remembered that sores met with in patients with plaster cases are much more commonly caused by friction than by actual pressure. Over the bony prominences, however, it is wise to apply a little extra padding in the shape of felt. To adapt the felt to such prominences as the anterior superior spine, patella, and heel, the following procedure is useful: a square of felt having been grasped with both hands, its centre is forcibly opposed to the corner of a table or the end of a pole, so that a cup-shaped depression is formed at this point When the limb is properly clothed in this protective material, the plaster is applied.

The sister in charge of the theatre will have everything ready for the surgeon, including the probable requirements in bandages picked out of their tins and set out on a table, since if they are picked out of their tins by a wet hand the drops of water spoil them

The large bucket full of water should have a jaconet lining to catch the surplus plaster of Paris. Unless this precaution is taken, the plaster sinks and sets, and considerable difficulty may be experienced in removing it.

The plaster is spoken of as "slow" or "quick" setting, according to the time it takes to harden. A handful of salt added to 2 gallons of the water in use will hasten the setting, while gelatin or glue will retard it. The speed of setting can be varied according to the temperature of the water into which the dry bandage is placed: the higher the temperature, the quicker the setting. Most surgeons prefer a fast setting bandage (2 to 5 minutes).

When using Gypsoma bandages the surgeon is handed the dry bandage and soaks it himself as this procedure is a matter of a few seconds. The bandage, with 2 inches of it unrolled, is lowered into the water vertically, resting on the palm of one hand and supported by the other, but without any pressure. It is left at the bottom till all bubbling has ceased. When lifted clear of the water the bandage is squeezed and twisted, with a hand at each end to prevent escape of plaster. This simply drives out excess of water and the bandage is still very wet. The more thoroughly the bandage is squeezed the less water remains and so the bandage sets more quickly and is a stronger plaster.

As the bandage is applied every layer is smoothed or "worked" by the palm of the hand. This ensures better adherence of the successive layer and eliminates air pockets The ordinary bandage sets in 2 to 3 minutes but is not dry—devoid of water—for some 48 hours, at which time the plaster has reached its greatest strength.

The strength or durability of a plaster of Paris case is its most important property. Of prime importance is the rate of attainment of this case strength, as most case failures result from damage in the first 24 hours. A high case strength is therefore desirable during this period. Removal of excess water by squeezing the bandage results in a more rapid attainment of strength and should lead to fewer case breakdowns, provided there is no large plaster loss

Once the bandage is applied to a part it neither stretches nor contracts but is rigid, but before it is dry it is pliable Between these two states the limb is maintained carefully in the required position. The slightest movement during the setting is apt to form ridges inside and interfere seriously with the later comfort of the patient. Should it be found necessary, therefore, to alter the position of the patient during the setting the plaster has to be removed and a new one applied.

Two methods are described for the application of the roller plaster bandage to ensure that it lies evenly and also to permit change of direction—the "loop" by which a one- to two-inch loop of bandage is thrown back and the run of the bandage re-directed, and the "draw" where one edge of the bandage is drawn back a little with the free hand while the run is directed These methods, of course, are of most importance in the inner layers to prevent ridges or unevenness. Where a prominence like the anterior superior spine is being clothed, a loop is applied as each turn covers the spine and at the same time the plaster is well rubbed in and moulded to exaggerate if anything the hollows round the bone Pressure on the bone is usually thus prevented.

After the primary thin tube of plaster is on and fitting like a glove the outer structure is put on with the sole purpose of adding strength where it is needed. Many parts may be left unstrengthened—e.g. dorsum of the foot, front of the elbow, and the axilla. This second stage, as it may be called, may be done by bandage or added to by plaques or slabs of plaster of Paris

Plaster Slabs The usual slab is made from a Cellona bandage by holding the end in the left hand and allowing the bandage, supported by the right hand, to unroll downwards by its own weight until twice the requisite length is got. This length is then folded up on itself and the left hand holding the end now has added to it a fold of bandage, usually about 5 feet from the end, so producing a length of $2\frac{1}{2}$ feet, the size of slab ordinarily in use Small slabs are used for the forearm and hand as in a Colles's fracture, while larger sizes are used for reinforcing weak spots in big cases, as in the "groin" of a hip spica, and is then often gathered into a round rope to form a buttress. A similar strengthening effect is got by the incorporation of aluminium or other metal

strips in the plaster over the weak parts. These strips should be thin, fairly wide and made of rough metal with perforations so that they do not come adrift in the plaster. When slabs are used on a flat surface they are more easily applied by two workers each taking an end and pulling so as to flatten out creases, and thereafter applying flat to the desired area.

Polishing. Before the plaster is dry a nice even polish should be applied. A layer of well-soaked bandage is evenly applied all round in an even direction and, where there is apparently not a surplus of plaster in the bandage, some plaster cream is put on with a wet hand. The polish is put on simply with the freshly wet hand which is frequently dipped alternately in water and plaster cream.

Occasionally, in a body case, a piece of bandage material called a "scratcher" is inserted. It projects from both ends of the case and is inserted under the protective stockinet. By using a see-saw pull-through motion the skin can be kept clean or scratched as the case may be. The "scratcher" can be changed by tying a new one to one end of the old one and pulling it through.

After the plaster bandages have been applied and partially set, the edges are trimmed in order to prevent any chafing of the skin and any undue pressure on parts by flexion of joints, such as the lower part of the front of a plaster jacket on which the groins may impinge in sitting. Frequently a portion of a plaster jacket about the size of a dinner plate is removed from the epigastric region, the object of which is to facilitate respiration and permit of abdominal expansion. After trimming, the case is finished by the application of plaster cream, made by mixing plaster powder with lukewarm water until a creamy consistence is obtained. This is rubbed in all over the plaster and, when partially dry, is polished with a little water.

Drying. Though the plaster case is hard and set in a few minutes drying may take as long as two days. During this period the plaster should be covered with a cage, preferably a radiant heat cage. If it is covered with bedclothes the plaster will be softened and spoiled.

In children, when there is a likelihood of the case being soiled, it is helpful to paint the case with either shellac or varnish.

The toes or the fingers should always be left exposed, in order to judge of the circulation in the limb. An exception may be made, however, in the case of the fifth toe which is liable to pressure if the plaster is trimmed to its base

The edges of the case may be protected against soiling by means of oil silk, oil cloth, or gutta-percha A permanent binding on the edges of the case may be made with an Ajax shoe-stapler.

A good plaster case should be as light in weight as possible; the inside should be smooth, and it should fit snugly without constriction so that there is no friction on the skin The toes and fingers should be visible. Where there is any question of circulatory interference as evidenced by swelling, or discoloration, the case should be split,

and the edges of the split spread Where there are dressings below it these also should be cut and the underlying skin made visible. The nurse should observe the skin temperature of the fingers and toes frequently, to ensure that they are not getting cold from compression or constriction.

In carrying a patient to whom plaster has recently been applied care must be taken to hold the limbs in such a manner as to obviate movement, especially such as tends to call into play the articulations fixed by the apparatus. If the plastered leg of a hip plaster is lifted off the table, it will be seen how the edge of the spica presses into the ribs, since the leg is forced out of alignment with the chest.

The Nursing of Patients in Plaster of Paris. On return to bed a cage, preferably a radiant heat one, is put over the case to quicken the complete dehydration of the plaster, for though the setting only takes 8 minutes or so the drying requires the best part of two days, and during that time movement must be prevented as the plaster is liable to break so long as the least moisture remains. The nurse is warned that the case must never be lifted by the leg since it may easily be broken at the groin. One of the most important points in nursing the case lies in the careful arrangement of pillows to support the plaster. If the shoulder and head rest on pillows the upper anterior edge of the case cuts into the chest The obvious cure is to remove the head pillows and so straighten out the thoracic spine. The heel, if resting on a pillow, presses up and gives the patient heel pressure, and so as a rule a few pillows under the limb with nothing under the heel is all that is required.

Where it is necessary to strengthen a crack, the debris of the plaster bordering on the crack is removed. The surface is then roughened with a knife, moistened, and smeared with thin plaster cream. Squares of crinoline impregnated with plaster are then quickly applied before the cream has had time to set. Care should be taken to avoid too much reinforcement, as this may preclude incorporation with the old plaster.

Cellona is now made in large sheets so that various shapes and sizes of slabs can be made for various parts of the body. The sheets of plaster are accompanied by "shapes," so that all parts of the body may be easily clothed in plaster with a high degree of accuracy and with a good comfortable fit

Skin-Tight Plasters. On the whole skin-fitting, or unpadded, plasters are the most satisfactory and effective, with perhaps the addition of padding at selected points. The intimate and accurate fitting supports and immobilizes all parts to a higher degree than does a padded case. All bony prominences, such as the sacrum, iliac spines, and internal epicondyles of the humerus, are carefully padded with felt. Skin-tight plasters certainly require greater care in application and must be watched for some time afterwards in case œdema supervenes and produces circulatory obstruction. It is doubtful whether such a plaster is wise after an operation on the part since the inevitable

œdema may make the plaster case very tight. A wise precaution is to split the plaster, and any underlying dressing, in its whole length after its application and bind on with a wet cotton bandage. Should much œdema be produced the cotton bandage is cut and the plaster gives enough to relieve any circulatory obstruction that may be present.

Bridged Plasters. It is often necessary to leave areas of a limb uncovered and free from plaster so that wounds may be dressed, and yet have the limb adequately immobilized. In such cases proximal and distal plaster sections may be connected by bridges or ropes of plaster either alone or reinforced with aluminium or other metal inside the plaster. Where the uncovered areas are smaller it is enough to cover with a thin layer of plaster, mark out a window on it, and then reinforce the edges of the future window with buttresses of plaster before cutting out the window. The windows are cut out with a sharp scalpel or plaster knife right down to the dressing underneath, for in a window area the skin is always protected.

Special Plasters.

(*1*) *Sectional Method of Application.* A valuable method of applying a plaster case where a limb or other part has to be held in position during its application is the sectional method. It may be used after bone-grafts to the humerus, after reduction of a compression fracture of the spine, or in leg fractures, particularly when changing the first plaster. When the trunk to be encased is suitably dressed and padded, the whole of the front and lateral aspects are plastered, usually by slabs, but it may be by roller bandages taken across the body, reversed and back to the same side The case extends far enough round the lateral aspect to get a grip of the part so that when the plaster is dry the patient may be turned round on to his face and yet the part be kept adequately immobilized. The back is then carefully padded and the edges of the plaster trimmed, and the gap between the plaster edges filled in with further slabs. When the two-thirds front and the one-third back pieces are firmly joined a few turns of a roller plaster bandage are applied. This is not absolutely necessary, and in any case is usually delayed till the plaster is dry and the patient out of any anæsthetic that may have been used. It is obvious that this is a useful method where the condition of the patient, or his position, will not permit of the easy application of round-and-round bandages, and also where a plaster table is not available.

(*2*) *Arm abduction plasters* are put up with the shoulder in the position of optimum function (see p. 382). It is questionable whether the plaster should extend down to the iliac crests. It is often more comfortable and equally efficient if it stops short an inch or two above the crest The brachio-thoracic angle may be reinforced with a metal strut in the plaster or a buttress from the elbow region to the body plaster. The hand should be maintained in the dorsi-flexed position by a short extension of the plaster into the palm, stopping short of the

metacarpal heads and so allowing free movement at the metacarpo-phalangeal joints. This plaster may be conveniently applied by the sectional method. On turning, the arm piece hangs on the edge of the table

(3) *Hip Spica.* This plaster is usually applied on a fracture table —Hawley or Shropshire Horse. Care must be taken to protect the bony prominences—sacrum, iliac spines and lower ribs. When complete on the table the patient in his case is turned on his face on to a trolley, the back carefully examined, and an area cut out over the sacral region to ensure clean nursing. The felt covering round the lower ribs and the sacral area is folded back over the outside of the plaster case and held in position with a further plaster bandage or slab. This ensures a smooth felt-covered edge to the case.

(4) *Lower Limb.* The fitment of the plaster to the foot is most important The ankle is held out at a right angle and a felt shoe is fitted to protect the heel and malleoli. The plaster is carried beyond the ends of the toes to protect them from the weight of the bedclothes, and so act as a bed cage. The plaster sole should be moulded so that there is no undue upward pressure on the first and fifth metatarsals, tending to undo the normal anterior arch, or at any rate, the normal downward concavity of this region The toes should not be prevented from flexion by too much " cock-up " of the terminal part of the plaster since this tends to produce an atrophy of the small muscles of the forefoot.

(5) *The " Tobruk " Plaster* This is an excellent method of immobilizing a fractured femur for transfer, for first aid, and especially for compound fractures. It was used in the Middle East in the war and got its name from the besieged town of Tobruk. A Thomas splint that fits the limb is got ready and bent at the knee level. After attending to the wounds the leg is shaved and orthopædic strapping is applied to the lateral aspects of the limb from the mid-thigh to the lower leg, padding being put between the malleoli and the strapping. The limb is now encased in a wool bandage, a felt pad is placed under the heel, and, with the knee slightly bent, a plaster of Paris case is applied from groin to toes, the foot being supported at a right angle but the plaster allows the toes to flex and supports at the same time the anterior arch of the foot. When the plaster is set the Thomas splint is applied. This is pushed well up to the ischium. Care is taken that the flexion of the splint corresponds to that of the knee. Pads of gauze are placed between the ring anteriorly and Scarpa's triangle and between the outer aspect of the thigh and the ring. The ends of the traction plaster are now tied over the end of the Thomas splint by cord and a Spanish windlass inserted and twisted tight. The leg, encased in plaster, is now fixed to the Thomas splint by several plaster bandages—one at the ankle, one at the knee, and one at the ring The cast has then cut from it a longitudinal piece, 1 to 2 inches broad, from the front to allow expansion should any swelling take place. This produces the best

traction and immobilization possible and allows transport with the greatest degree of comfort.

The Difficulties of Plaster Treatment. The chief sources of trouble are—

(*a*) Constriction from too tight application of the case

(*b*) Pressure from the edges.

(*c*) Moisture from the patient's excretions.

Circulatory Troubles. A plaster produces pressure troubles more from swelling of the indwelling limb than from its own intrinsic constrictive effect Pressure sores are more commonly produced by friction than simple pressure. The most serious danger of compression of the limb is the effect on the circulation. Complete abolition of this, of course, produces gangrene. Incomplete compression may cause ischæmic contracture or disturb the sympathetic control. It is therefore of vital importance that undue compression should never occur, and if it does be immediately relieved. When a plaster is applied after an operation, the case should usually be split vertically from end to end and then bandaged with a wet cotton bandage. The limb in every case should be elevated as this obviates undue œdema. A careful watch is kept on the limb during the first day or two, and any signs of constriction noted in swelling of the toes, inability to move them, loss of circulation as noted in the peripheral vessels, loss of sensation or heat, and/or undue pain. Unless the digits are rosy warm and sensitive and can be moved voluntarily, the patient cannot be left alone with safety. The compression should be relieved by easing the plaster—either cutting the cotton bandage and easing the plaster, or splitting the plaster end to end if this has not already been done. Where circular dressings or bandages have been applied underneath the plaster it is, of course, essential to divide these also down to the skin as they are equally potential factors in producing compression.

Plaster Sores. Some may be due to pressure as described above, but they are more often due to friction in a loose plaster case Where the plaster is a big one and the condition permits it is a good thing to turn the patient for an hour or so night and morning on to his face. Besides relieving him of pressure on his back it allows the latter to be cleaned and treated with boracic powder and spirit. It is also of benefit in helping urinary drainage from the kidney pelves where otherwise the urine tends to stagnate and become infected and, it may be, produce calculi.

Sores often give little warning, and that for a brief period at the beginning since they so easily pass into the stage of skin necrosis when the sensitive nerve endings are deadened. The early signs are local pain and general restlessness, and these should be looked for, noted and reported to the surgeon by the nurse in charge. When the necrosis deepens to the underlying tissues pain comes on again, and by this time the characteristic musty odour of pus may be detected. Such symptoms

and signs necessitate further and closer investigation by removal of the plaster and its re-application.

Frequently the patient may complain of pressure of the edges of the cast. When pain is complained of in either the great or the small toes, a longitudinal cut should be made on the dorsal and plantar aspects of the plaster over the affected toe 2 to 3 centimetres in length, and the section of plaster thereafter eased outwards, so giving the toe more room It is unwise to split the plaster transversely since this merely produces an area of pressure a little higher up.

An edging of oiled silk or rubber mackintosh protects against soiling. The bed-pan should be carefully adjusted so that the flesh of the buttocks will press on the edge of the pan If the edge of the case rests on the pan, moisture will follow the buttocks up under the cast.

Pressure from the edges of a case is often caused, or increased, by the patient's position. When the front of a hip spica presses on the epigastrium or costal margin, the insertion of a pillow under the lumbar curve frequently gives the patient great comfort. Complaint of pressure on the heel is treated immediately by removal of a section of plaster over the affected area The plaster frequently becomes twisted and pain is referred from above. Where pressure is to be relieved splitting the case is always preferable to making a window. When a hole is cut in a case the tissues may bulge through the opening and produce pressure or deformity.

It is a good practice to smell the case occasionally with a view to the detection of any odour, a musty smell frequently indicates pus or necrosis

The Removal of a Plaster Case. Many instruments have been devised for the removal of plaster cases, but the best, in the author's opinion, is the Stille plaster scissors with a straight cutting blade. Occasionally there is a sharp angulation at the front of the blade, which makes it difficult to run it under the plaster, and which is, moreover, unnecessary This should be removed The oscillating Stryker cast cutter worked by electricity is a valuable precision instrument for the cutting of windows, bivalving, etc

As a rule, it is wiser to make two lateral incisions, in order that a posterior shell may be left in which the affected part can rest until a satisfactory examination has been made and, if necessary, X-ray photographs taken.

The Toilet of the Skin after Removal. The skin is washed with warm water and soap, after which it is moistened with Eau de Cologne or ether. If desquamation is troublesome, Vaseline may be rubbed in gently for a few minutes This has the effect of softening the scales and the skin can then be washed with cotton-wool moistened with a little ether If there are signs of irritation of the skin—eczema or vesicles—applications of oxide of zinc or talc may be made for a few days

The Making of a Plaster Mould or Cast. For the manufacture

of certain braces, foot supports, and other apparatus, it is necessary to have a plaster-of-Paris model of the affected part. A covering of stockinet or simply a thick coating of Vaseline is applied, and fillets of metal laid over it along the lines of proposed section. A thin plaster case is then applied, and immediately bivalved Before actually removing the two halves, a series of transverse pencil markings should be made at intervals across the lines of section to facilitate accurate co-aptation later. When thoroughly set, the plaster segments are removed, bandaged together, and allowed to dry. The model is now sent to a bracemaker, who fills the shell with plaster of Paris after lining the inner side with talcum powder, or a thin coating of soap. Sufficient plaster-of-Paris cream to fill the cavity is then poured into it. During the setting a strip or bar of metal may be placed longitudinally, so that when the cast sets this bar will be in place. Several inches of the metal project at either end so that the model can be handled easily. After removal of the case the mould is put in the oven until thoroughly dry. The bracemaker has now a positive impression of the deformed part. If the brace that is to be made from the mould is to be corrective in function, then the mould may be corrected by filling up concavities with plaster-of-Paris cream suitably coloured with mercurochrome or some dye. Abnormal convexities or bulges may be shaved off by means of a large knife, until the mould is corrected to the desired degree.

CHAPTER II

CONGENITAL DEFORMITIES

Congenital deformities are inherited according to Mendelian laws, some being recessive and some dominant The dominant deformities are rare and some are sex-linked

Mall divided congenital deformities into two classes—primary, or idiopathic, and secondary

The *primary deformities* result from some inherent defect of the

Fig 1.—Bifid Thumb

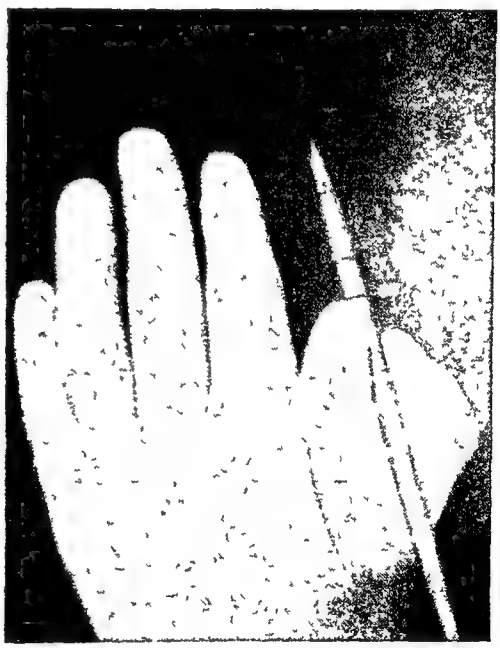

Fig 2 —Bifid Thumb

fertilized ovum which spontaneously influences the development of the embryo These errors may arise from an inherent peculiarity, weakness, or disorganization of the germ cells, as is proved by their transmission through several generations The belief that maternal impressions can bring about these developmental anomalies has no scientific justification.

In the *secondary congenital deformities*, it is assumed that the fœtus is at first normally formed , but that later, deformity is produced by the action of some extraneous cause—trauma to the pregnant mother, intra-uterine pressure, arrest or retardation of tissue-development as a result of nutritional disturbances in the growing embryo The opinion has

shifted in recent years towards the endogenous theory, namely that the primary cause of deformities is an inherent quality of the embryo itself.

CONGENITAL DISLOCATION OF THE HIP

(By George P. Mitchell)

Congenital dislocation of the hip consists of a partial or complete displacement of the femoral head from the acetabulum. It is one of the commonest of the congenital deformities and is particularly prevalent in certain areas such as Northern Italy and the Southern parts of France and Germany. Congenital dislocation of the hip occurs in sufficient numbers in this country to justify a greater interest in its early detection. There is a tendency to hereditary transmission and the female sex is involved almost six times as frequently as the male. The left hip is more commonly affected than the right and unilateral dislocation is more common than bilateral dislocation.

Etiology

The acetabulum appears as a condensation of mesoderm about the end of the fourth week of intra-uterine life, but at first it constitutes only a shallow socket on the outer aspect of the developing innominate bone. Later the socket is deepened by the progressive development of the original depression and in particular that part of the socket which lies in the axis of the transference of weight (the postero-superior rim or buttress. The constant defect in congenital dislocation of the hip is an aplastic development of this osseous buttress and it is of interest to note that this characteristic is apparent in the acetabulum of the lower forms where the hind limb has no postural function and is not concerned with the transference of weight, e.g., reptilia.

The primary defect is manifest radiologically in the earliest stages as a hypoplasia of the osseous formation of the acetabular roof. Ossific hypoplasia of the capital femoral epiphysis may also be apparent at an early stage and is a constant feature of the later stage.

Two main groups of congenital dislocation of the hip are recognized. Hass (1951) classified those as typical and atypical groups which can usually be distinguished from each other by two principal features—the typical by its post-natal appearance, the atypical by its pre-natal development and its combination with other congenital anomalies such as arthrogryphosis.

This classification is acceptable provided it is recognized that the early stage of a typical dislocation may be present at birth in a pre-dislocation stage.

Atypical dislocations account for only a small number of cases and their treatment is complicated by associated abnormalities. It is usually considered to be a sequel to intra-uterine muscular dystrophy. Autopsy findings in new-born infants in this atypical group reveal

complete dislocation of the hip and gross pathological obstacles to reduction. The socket is extremely small and filled with fibro fatty masses or flattened by accumulations of cartilaginous connective tissue.

Complete dislocation of the hip in the typical group is seldom found in the immediate post-natal period. Post-mortem reports on new-born

Fig 3 —Multiple Congenital Deformities

Both forearms are absent and both patellæ, one foot shows calcaneo-varus, the other calcaneo-valgus deformity

Fig 4 —The same patient some twenty years later, working and earning in John Groom's Crippleage

infants in the predislocation stage are naturally rare Hass found that the socket was only slightly reduced in circumference but corresponded in shape and depth to normal The soft parts showed no abnormal change except for slight laxity of the capsule and ilio-femoral ligament

The primary condition in the common or typical group of congenital dislocation of the hip is believed to be a congenital dysplasia of the hip from which different degrees of deformity may develop

Pathology of the Fully Established Case

1. Changes in the Bones.

(*a*) *The Acetabulum* is shallower than normal, and at birth the only other error apparent is a gap or groove at its postero-superior part. Later, its rounded shape disappears, the cavity being usually converted into a triangular depression, with its base in front and below, and its apex above and behind. X-ray examination shows that the outer surface of the ilium and the floor of the acetabulum lie practically in a straight line, owing to the absence of the usual projecting rim at the upper part of the cavity. Instead of containing the head of the femur, the acetabulum becomes occupied by an over-growth of fibro-cartilage, the remains of the ligamentum teres, and the Haversian gland, and is covered over by the anterior portion of the capsule which is usually to some extent adherent to the floor. Above the acetabulum there is a

(*a*) (*b*)

Fig 5.—(*a*) Predislocation aged 2 months (*b*) Same patient treated by Simple Abduction for 6 months

N.B. Mother and sister suffered from congenital dislocated hip. Infant presented with alteration of buttock creases and limitation of hip movement

depression on the dorsum ilii, lined with periosteum, in which the head of the femur rests insecurely, a fold of the capsule intervening between the ilium and the head.

(*b*) *The Head of the Femur* is at first normal, but later it becomes small, atrophied, and flattened on its medial and posterior aspects. In some cases the atrophy is so extreme that there is practically no head present. If the head rests on the dorsum ilii it becomes buffer-shaped, otherwise it is conical. It is usually large in comparison with the acetabulum.

(c) *The Neck of the Femur*. There is marked shortening of the neck of the femur, which increases the shortening of the limb. The neck is also depressed and sometimes anteverted, so that the normal anteversion of 12 degrees is increased until, in late cases, it may be almost 90 degrees, i.e., the neck appears to project straight forward from the shaft. As a

result of this, when the dislocation is reduced, the limb is rotated medially and the patella looks directly medially.

(*d*) *The Pelvis.* When there is a bilateral dislocation, the pelvis is tilted forwards and the normal lumbo-sacral lordosis increased. The whole innominate bone is small and atrophied, and lies more vertically than normal, so that the iliac crests are approximated and the ischia more widely separated.

In unilateral dislocation, the corresponding pelvic bone is imperfectly developed, and the whole pelvis has a lateral inclination, while the shape of the inlet is obliquely ovoid.

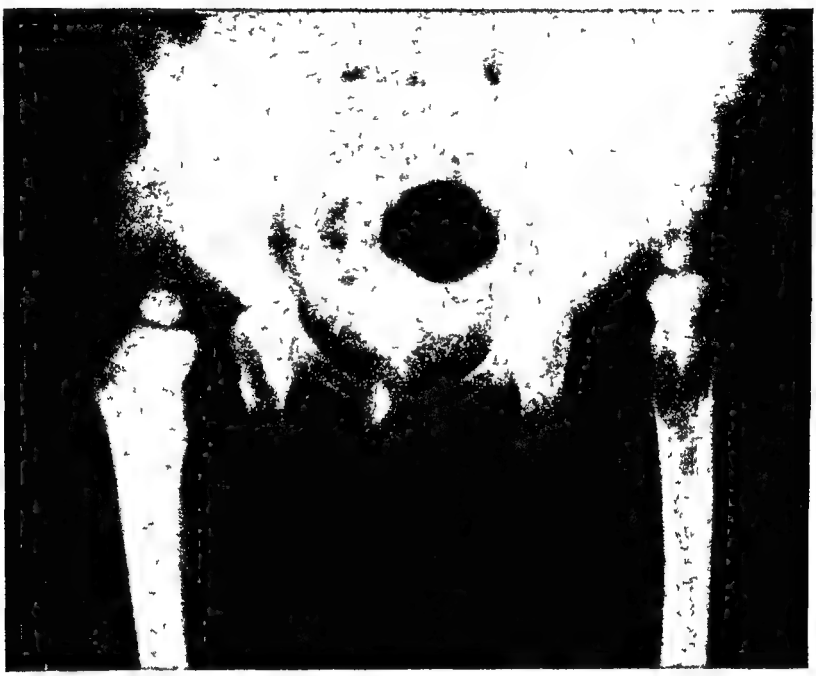

FIG 6 —Subluxation Right Hip and Dislocation Left Hip.

2. Changes in the Soft Parts.

(*a*) *The Capsule* Though not always evident, the capsule is said to assume an hour-glass shape, one cavity containing the head, the other covering the acetabulum, the constriction between them being produced by the ilio-psoas tendon which crosses the capsule at this level. Through this narrow isthmus, the ligamentum teres passes. The lower part of the capsule is stretched across the entrance to the acetabulum, and, in some cases, is adherent to its contents It will thus be seen that the capsule becomes a suspensory ligament for the pelvis, and, indeed, supports most of the weight of the body. It accordingly undergoes hypertrophy, particularly at its anterior and lower portions The ligamentum teres is usually attenuated, and may be altogether absent

(*b*) *The Muscles* There is considerable alteration in the muscles, indeed, this is one of the causes of failure to reduce the head into the

acetabulum during treatment. Bruce divides the muscles into three groups—the pelvifemoral, the pelvitrochanteric, and the gluteal groups.

(i) THE PELVIFEMORAL GROUP. This group runs in the same axis as the femur. As the head of the femur migrates upwards, they shorten, and thus form the most formidable obstacle to reduction. These shortened muscles are the adductors, the hamstrings, gracilis, sartorius, tensor fasciæ latæ, pectineus and the rectus femoris.

(ii) THE PELVITROCHANTERIC GROUP. This consists of the obturators, quadratus femoris, and the psoas tendon. These become functionally incompetent, since they are stretched and elongated. The psoas tendon, in addition, is displaced outwards, winds round the capsule, and acts as a suspensory ligament which supports the body-weight. Through its lateral displacement, an opening may be left beneath Poupart's ligament through which a crural hernia may occur. This constitutes a Narath's hernia.

(iii) THE GLUTEAL GROUP. These show little organic change but since they are without their fulcrum their power is considerably diminished, while the displacement of the head leads to an alteration in their axis of movement

Development of Congenital Dislocation of the Hip

In the typical group primary dysplasia may be evident at birth before significant displacement has occurred. This predislocation stage may be diagnosed radiologically in young infants with a family history of congenital dislocation of the hip and is frequently noticed on the "sound side" at X-ray examination for suspected dislocation.

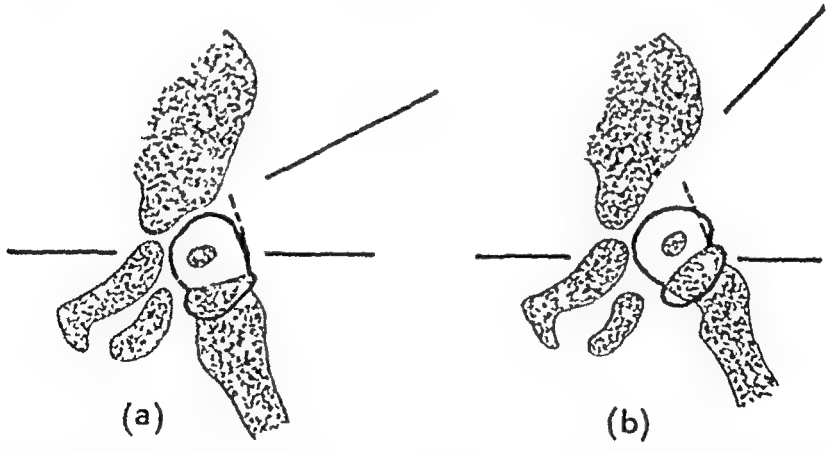

FIG. 7.—Arthrogram tracing of (*a*) Normal Hip and (*b*) Pre-dislocation Stage.
In the early stages of dysplasia the osseus roof is deficient but the cartilaginous roof as indicated by the dotted line approximates normal.

The significant feature on X-ray is the osseous hypoplasia of the acetabular roof. Arthrography confirms that while the osseous roof of the acetabulum is oblique and shallow, the cartilaginous roof is comparatively intact

This predislocation stage in young infants responds readily to simple

abduction and the rapid ossification of the cartilaginous roof which follows suggests that the ossific hypoplasia is potentially capable of responding to concentric pressure stimulus of the head.

Spontaneous correction may possibly occur in such cases without treatment but in the majority the hypoplasia persists and eventually the cartilaginous roof is unable to contain the head which migrates outwards to the subluxation or dislocation position

(a) (b) (c)

FIG 8 —(a) Subluxation of Right Hip (b) Arthrogram before reduction Diagram shows flattening of limbus. (c) Arthrogram after frame reduction Diagram shows normal outline of limbus.

SUBLUXATION STAGE

Subluxation is regarded as an intermediate stage in the development from primary dysplasia to complete dislocation and is frequently associated with either predislocation or dislocation of the other hip. Subluxation, however, does not always proceed to dislocation and may be observed in adults who have had no previous treatment.

The exact features responsible for migration of the femoral head from the predislocation stage to subluxation and dislocation are not known. The degree of primary hypoplasia affecting the cartilaginous roof of the acetabulum is probably the most important etiological factor. Its ability to contain the head and to ossify in response to a correctly reduced head will determine the final result

All structures affected by the primary dysplasia are probably involved in the displacement of the femoral head The capsule, ilio-femoral ligament and fibro-cartilaginous limbus (acetabular labrum) may be unduly lax and unable to withstand increasing hip movement.

Le Damany in 1908 suggested that congenital dislocation of the hip was directly attributable to increased anteversion of the femoral

neck. In support of his views Badgely (1949) considers that the primary dysplasia is produced by increased anteversion with an anterior primary position of the head and subsequent development of a flat socket.

Anteversion normally increases in fœtal life to approximately 35 degrees at birth and decreases during growth to 10-12 degrees. Marked increase in the anteversion angle, although present in a high proportion of cases, is not found in all cases of congenital dislocation. Anteversion cannot therefore be considered as the primary defect

Significant increase in the anteversion of the neck must, however, decrease the concentric pressure stimulus of the head in the acetabulum and should be regarded as a contributory factor in the persistence of ossific hypoplasia and migration of the head.

In the early subluxated position the anteverted head can be palpated anteriorly when the legs are extended. The extension thrusts of the limb from the flexed position which are a feature in the normal development of the growing infant, augment the pressure effect of the anteverted head. In the dysplastic hip, increased anteversion may stretch the capsule and fibro-cartilaginous limbus and precipitate displacement.

In the initial stage of subluxation where only the fibro-cartilaginous limbus has been subject to pressure by the migrating head, a normal anatomical outline can be restored by concentric reduction of the head which will then provide the necessary stimulus to ossification.

In more advanced stages of subluxation, the head flattens the limbus and exerts a deforming pressure on the cartilaginous roof, causing further inhibition of ossification and actual flattening of the socket. The response to reduction at this stage cannot be predicted and will depend on the extent to which these changes are reversible.

Transition from subluxation to dislocation may occur either before or after ambulation, depending on the degree of primary dysplasia, but weight-bearing is the precipitating factor in many cases.

Dislocation occurs when the femoral head loses contact with the original acetabulum and rides up over the fibro-cartilaginous rim. Arthrography demonstrates that in complete dislocation the fibro-cartilaginous lip or limbus is inverted compared with the eversion which accompanies subluxation.

Levenf (1948) considered that subluxation and dislocation represented two distinctive morphological types. In dislocation the limbus was inverted between the head and the acetabulum While Levenf's views on embryonic development are not accepted, the importance of the relative position of the limbus in the different stages of congenital dislocation is recognized

If dislocation is preceded by subluxation, inversion of the limbus must take place after the head leaves the socket. At operation it is usually the posterior and superior quadrants which are found to be inverted. Haas attributes the inversion to increased elasticity as the head slips out of the elastic loop of the limbus. Somerville (1953)

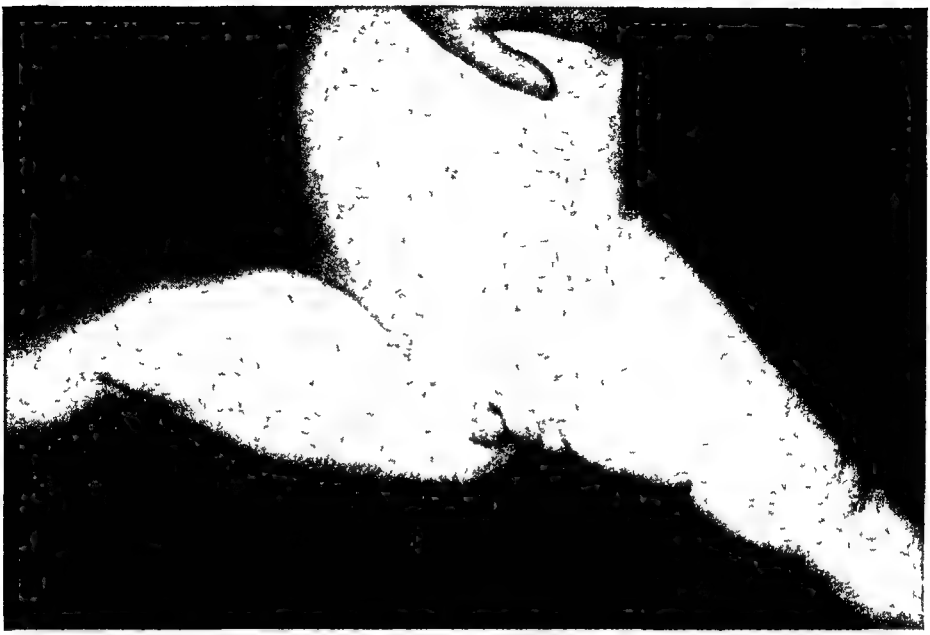

(a)

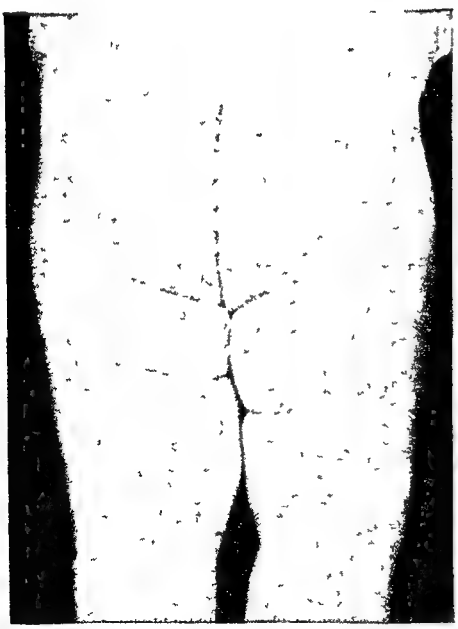

(b)

(c)

FIG 9 —Clinical Signs of Congenital Dislocated Hip (a) Limitation of Hip Abduction (b) Alteration of Skin Creases (c) Shortening of Thigh.

head which normally supports the femoral artery. Posteriorly, the head can be felt in its abnormal situation. In some cases a Narath's hernia may be evident.

Movements. Movements can be carried out painlessly and freely, except for some limitation of abduction and lateral rotation. In early cases, a distinct telescoping can be elicited when the femur is moved up and down in its long axis, as this produces upward and downward movement of the head on the dorsum ilii.

Measurements. In unilateral cases, the affected leg will be found to be shorter than the other, and even in bilateral dislocations there is usually some difference in length. The actual discrepancy varies with the amount of telescoping of the femur that takes place. On closer examination it will be seen that the shortening is above the level of the trochanter.

Trendelenburg's Sign. This is elicited by asking the child to stand first on one foot and then on the other. In unilateral cases, when she stands on the sound side, the buttock of the opposite side rises slightly, for the gluteus medius contracts in order to raise the pelvis and bring the trunk more directly above the limb which is sustaining the body weight. When she stands on the dislocated side, the opposite buttock now drops, for the gluteus medius is relatively inefficient and the pelvis cannot therefore be raised or even be kept horizontal. The amount of drop depends on the degree of displacement, and continues until the femur and the side wall of the pelvis of the side on which she is standing are brought into contact. Stability is then attained. In bilateral cases, the phenomenon is present on both sides

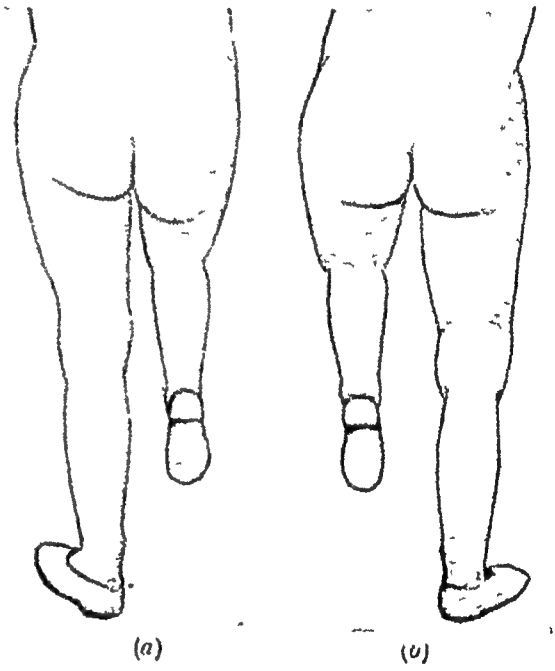

FIG 10.—Trendelenburg's Sign.

Congenital dislocation left hip (a) on lifting sound leg, buttock on that side drops; (b) on lifting dislocated leg, buttock rises slightly

The Trendelenburg test is not pathognomonic of congenital dislocation of the hip, but occurs whenever the action of the gluteus medius is interfered with—as for example in infantile paralysis, and in coxa vara. In congenital dislocation the inefficiency of the gluteus medius is due to two factors.

(1) Its axis—normally vertical—is now altered to a more nearly horizontal direction.

Clinical Features

Clinically, the condition is frequently not observed till the child begins to walk, when the observant mother usually notices a slight limp. It should, however, be the duty of the accoucheur, the nurse, or midwife, to examine all children, particularly when the labour has been difficult, for abnormality of the hip joint. The condition might then be suspected from the marked broadening of the perineum, or the swelling in the gluteal region due to displacement of the head of the femur. The mother may bring the child to the doctor because of an unduly prominent thigh. This is the appearance in a unilateral case where the femur on the dislocated side drops backwards, making the normal side appear more prominent.

If the child continues to walk, the gait becomes more abnormal. The limp is peculiarly unstable, the trochanter ascending whenever the body weight is transmitted through the leg of the affected side.

In the early stages there is neither pain nor tenderness, but passive and active movements of abduction and lateral rotation are limited.

The Gait. In a bilateral dislocation the gait has been described as a "duck-like waddle" or a "sailor's gait," and consists of an inclination to the side on which the weight is borne.

In a unilateral case, the child lurches towards the affected side. The gait is the result of the inefficiency of the gluteal muscles, the shortening of the neck of the femur, and the displacement of the head, combined with the lordosis and the abnormal lateral mobility of the lumbar spine.

The Lordosis. This is particularly noticeable in bilateral cases, but is present in lesser degree in unilateral cases, and is accompanied by a corresponding protrusion of the abdomen.

The Deformity. (*a*) *Unilateral Cases.* There is marked shortening of the leg, which, on measurement, is found to be in the region above the great trochanter. The great trochanter lies above Nelaton's line and is unduly prominent.

(*b*) *Bilateral Cases.* The legs appear too short for the body, the perineal space is broadened, the trochanters are unduly prominent, and the buttocks broad and flat.

Examination of the Patient

The waddling, lurching gait is at once noted. On inspection after stripping, the alteration in the figure is apparent. In the unilateral case there is a marked prominence of the great trochanter, increase of the lumbar lordosis, lack of development of the limb on the affected side, and asymmetry of the groove between the labia and the thigh. In the bilateral case, all these signs are present with the exception of the asymmetrical labio-femoral groove and in addition there is an obvious broadening of the perineum.

Palpation. On palpating the groins, it will be noticed that on the affected side the pulsation of the femoral vessels is difficult to feel ("vascular sign"). This is due to the displacement of the femoral

of upward displacement of the femur in relation to the acetabulum is of importance in the prognosis

Diagnosis

Early Diagnosis is the most important single factor in determining the end result Every effort must be made to detect dysplasia in the early stages before the acetabular roof is deformed by the migrating head and while the ossific hypoplasia is still capable of responding to the concentric pressure stimulus of the head. All those responsible for the post-natal care of infants should be conversant with the importance of diagnosis at this stage.

All infants with a family history of congenital dislocation of the hip should be X-rayed shortly after birth and kept under observation if diagnosis is in doubt.

The most important early signs of dysplasia are the limitation of hip abduction, however slight, and any alteration of thigh or buttock creases All such cases should be X-rayed. It should be recognized, however, that alterations of skin creases are found in infants with no suggestion of dysplasia, but this should not detract from the importance of an early X-ray examination.

Any abnormality of gait noticed by the mother warrants full examination of the hip If the child is irritable and difficult to examine at the initial visit to the clinic, a further appointment should be arranged before a negative finding can be established.

Definite displacement is characterized by prominence of the femoral head on rotation of the hip, telescoping of the head, shortening and outward rotation of the limb. Widening of the perineum will be found in bilateral cases

When the child commences to walk, the Trendelenburg sign will be positive, and the lumbar lordosis increased particularly in bilateral dislocation.

After a careful clinical and radiographic examination, there should be little difficulty in reaching a diagnosis, but occasionally there are early or slight cases which leave a slight element of doubt In such cases Hilgenreiner uses a helpful device to dispel the doubt.

A horizontal line is drawn on the radiogram through the clear areas which represent the triradiate cartilage, and a vertical line through the edges of the acetabular roof.

If the condition is unilateral, the vertical line is drawn on the sound side and on the other a parallel is inserted at an equal distance from the mid-line Normally the capital epiphysis lies below the horizontal line and medial to the vertical. In potential dislocation of the hip, it lies below the horizontal but lateral to the vertical, while in the fully established dislocation it lies above the horizontal and lateral to the vertical

(2) Its fulcrum—the head of the femur—is now unstable.

The X-ray Appearance

X-ray examination is essential to establish the diagnosis, but in the young infant it must be realized that the cartilaginous structures involved are not visible on straight X-ray.

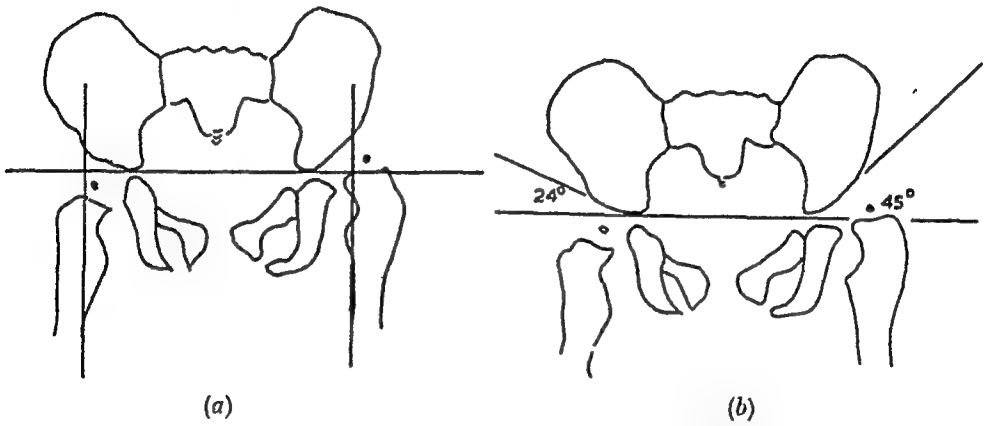

FIG. 11 —X-ray Signs of Congenital Dislocated Hip (a) Hilgenreiner's lines Epiphysis in superior outer quadrant (b) Acetabular angle Note shallow osseous roof.

The relation of the head to the acetabulum can be established by Hilgenreiner's lines, the epiphyseal nucleus should be inside a vertical line drawn from the acetabular margin and below the horizontal line drawn through the "Y" cartilages

The development of the osseous roof may be measured from the acetabular angle and this is of some value in prognosis and in recording the degree of primary dysplasia The normal inclination of the osseous roof to the horizontal plane is approximately 22 degrees but in congenital dislocation it is increased to 30 or 40 degrees

In taking X-ray photographs of this condition, it is important to obtain a stereoscopic view as well as the ordinary antero-posterior one It is not difficult to demonstrate, in this way, the dislocation of the head on to the dorsum ilii, but certain other points should be investigated The outline of the femoral head should be noted, and it will be seen that the femur is displaced outwards and upwards The epiphyseal shadow is usually smaller than normal, and displaced outwards in relation to the neck. The neck is fore-shortened and may be anteverted Anteversion is investigated by taking two plates, one with the patella pointing straight forwards, the other with the leg in full medial rotation. Any anteversion is noted by the superimposition of the head on the trochanter in the first plate, while the second shows the outline of the head quite distinct from the trochanter. The acetabulum appears less excavated than normal, and, where its floor is on the same plane as the dorsum ilii, it is flat, shallow and shelves upwards. The amount

Treatment

The treatment of congenital hip provides a grave orthopædic problem, and opinion is by no means unanimous as to the most efficacious solution. There is a variety of methods to choose from, and the critical problems may be said to concern the vexed questions of operative and manipulative reduction, and the advisability of supplementing such reduction by some reconstructive or retentive procedure

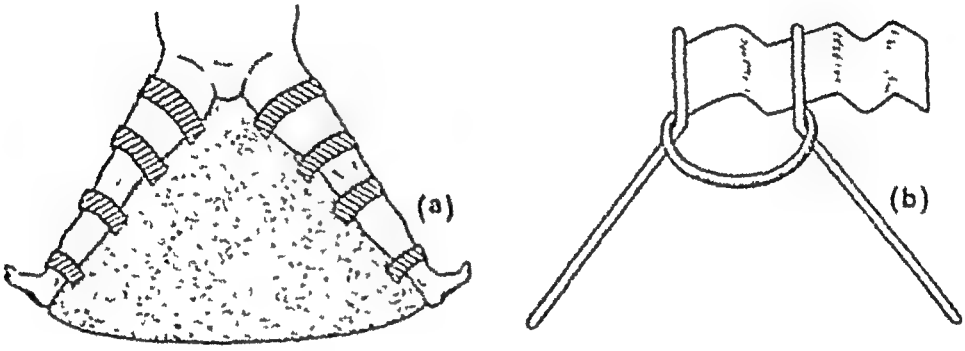

Fig 12.—(a) Putti's Mackintosh covered Wedge Splint (b) Forrester-Brown Abduction Splint for young infants

It is of supreme importance to commence the treatment with a well-established conception of the aim and scope of surgical treatment.

The treatment of congenital dislocation of the hip depends on the degree of dislocation and the interpretation of the underlying pathology. The pathogenesis of congenital dysplasia is not yet fully understood and the treatment and prognosis in certain cases are therefore difficult.

The preliminary consideration in treatment is the accurate replacement of the femoral head in the acetabulum. Radiographic evidence of reduction, however, does not necessarily imply that development of the joint will proceed satisfactorily to form a normal articulation. The results of accepted forms of treatment warrant a constant review of present methods.

Fig. 13.—Infant with Early Subluxation diagnosed at two months and treated as an out-patient on Forrester-Brown Splint

Predislocation Infants in the predislocation or initial subluxation stages diagnosed in the early months of life are treated by simple abduction on a Putti's mackintosh-covered wedge or Forrester-Brown

Differential Diagnosis

1. *Coxa Vara.* Here the limp is less severe, the head is not palpable in an abnormal position, nor is there any "telescoping." The shortening is constant, and the X-ray appearance is quite characteristic.

2. *Pathological Dislocation.* In these cases there is usually a history of some previous hip-joint trouble developing after birth. There is general limitation of hip movements. The X-ray examination shows greater deformity and absorption of the head, while the acetabulum is usually well developed.

3 *The Paralytic Dislocation of Poliomyelitis.* This condition simulates congenital dislocation in its waddling gait and the shortness of the limb, but the hip joints are normal and there is usually a history of febrile illness. There is obvious muscular paralysis. Any doubt should be removed by an X-ray photograph.

Prognosis

Although the condition is not a fatal one, and in some cases, in its early stages, not even a seriously disabling one, symptoms increase during the adolescent period and, with increase of age and weight, painful spasm and rigidity occur, and, at a still later date, arthritis in the false joint. Platt reports on forty hip joints treated by manipulation at various ages from 1 year 7 months to 11 years. Fifteen were excellent, thirteen good, ten fair, and two poor. The poor results were in children over 5.

The late results of closed reduction will vary according to the age when treatment is started, the degree of dysplasia and the criteria by which results are judged. Muller and Seddon (1953) reported 57 per cent of excellent late results following closed reduction in children under 3 years of age The assessment was made on combined clinical and radiographic criteria. Platou (1953) in a similar under-3 age-group reported good short-term results in 80 per cent and good anatomical results in 68 per cent After 14 years 68 per cent of patients still had good functional results and 58 per cent good anatomical results.

Results based purely on strict radiographic criteria of concentric reduction and anatomical restoration of the acetabulum are less favourable Gill (1943) reported only 11·9 per cent of normal hips in the ninth year, compared with 71 5 per cent of good reductions in the first year. Ponseti (1944) found that only 12 per cent. of his treated congenital hips could be classified as anatomically perfect, but in 38 per cent only slight deformity of the head or acetabulum was present in an otherwise well-developed joint.

It is evident from reported series that good clinical function in young adult life may be expected in approximately half the cases treated by closed reduction Restoration of normal anatomy is, however, extremely difficult to achieve These results can only be improved by earlier diagnosis and a better understanding of the factors which complicate reduction and subsequent joint development.

abduction is commenced by advancing each leg one opening of the abduction bar on alternate days.

Abduction is increased, depending on relaxation of the adductors and the descent of the head as observed on X-ray. If the head remains high despite increasing abduction, a cross pull is applied over the upper thigh with 1-2 lb. pulley traction to bring the head down to the level of the acetabulum. When the head arrives opposite to the acetabulum, the leg traction is reduced to allow the head to sink into the socket.

When the reduction is confirmed by X-ray, the child should remain on the frame for a further week before the application of Batchelor's plasters. It is emphasized that the frame is used to relax tight structures

Fig. 15.—Batchelor type plaster. Note freedom of movement and exposure of perineum.

and bring the head down to the acetabulum. Failure of concentric reduction of the head in a correctly treated case usually indicates an obstruction to reduction which will not be affected by continued use of the frame. Prolonged use of the frame is unnecessary in the treatment of congenital dislocation of the hip and is harmful to the child.

Children under 6 years of age may be treated on the abduction frame but reduction becomes increasingly difficult after the age of 4. The indication for operative measures will depend on the degree of reduction achieved

Batchelor's Plaster. Following successful reduction on the frame the hips must be protected until ossification of the acetabular roof provides a more stable socket. The Batchelor plaster position corrects anteversion by internal rotation and allows mobility of the concentrically reduced head which theoretically should encourage development of the socket.

The plaster is applied under general anaesthesia and the legs are internally rotated to compensate for the estimated anteversion angle. The degree of abduction should be sufficient to place the head centrally in the acetabulum. The cross bar is attached and the position of the

Splint The Forrester-Brown Splint is ideally suited for home nursing of small infants, the child is easily carried and the perineum is exposed Abduction of the hips is gradually increased to any desired angle by bending the side bars, adjustment for internal rotation is also possible

The response to treatment at this early stage is usually rapid and regular free exercise periods may be permitted as ossification of the roof increases.

Frame Reduction of Displacement. Migration of the head to any extent is usually associated with definite tightness of the adductor muscles which must be overcome before reduction is possible. Reduction by traction on a modified abduction frame followed by retention in a Batchelor type plaster is preferred to manipulation under anæsthesia and immobilization in the frog-position plaster spica



Fig 14 —" Wingfield pattern " Abduction Frame with Cross Pull on Left Thigh

Osteochondritis of the femoral head is more liable to follow manipulation than frame reduction—Scott (1953) This may be due to the force necessary to overcome the tight adductors or to torsion of capsular vessels in the extreme frog position Osteochondritis is a serious complication which may prejudice a good long-term result and should therefore be avoided where possible.

Frame reduction is a gradual process, the duration of treatment depends on the stretching of tight structures by traction and abduction In the average case the head can be brought down and opposite to the acetabulum in under six weeks, in resistant cases a longer period will be necessary.

The child is placed on the frame and skin traction applied to the legs in slight abduction with the foot of the bed elevated Fixed traction is sufficient in young children but pulley traction may be necessary in the older child After one week of preliminary traction,

femoral head verified by X-rays. The plaster requires renewal approximately every three months and as the acetabulum develops, the degree of abduction is gradually reduced to produce more stimulus to the roof of the socket.

The duration of treatment depends on the development of the acetabulum but is usually less than one year. When the plaster is removed the child should be admitted to hospital for mobilization and supervision of the initial weight bearing.

Arthrography of the Hip. Arthrography of the hip is of considerable value in the treatment of congenital dislocation. Arthrograms contribute to the understanding of the underlying pathology in the different types of dislocation and are frequently of value in deciding the appropriate treatment.

The technique is easily acquired but experience is necessary in the interpretation which proves difficult in some cases. Arthrography is of most value in centres where congenital dislocations of the hip are regularly treated.

Under general anæsthesia 1-3 c.c. of 35 per cent. Diodone are injected either by the anterior or superior approach. The spread of the radio opaque medium is visualized on the screen and radiographs are taken in the neutral and internally rotated positions. The arthrogram reveals the extent of the cartilaginous roof in subluxation and in dislocations confirms the interposition of the limbus between the head and socket In doubtful cases, the arthrogram should be repeated after reduction to verify the relationship between the femoral head and the cartilaginous roof of the acetabulum.

Subluxation. Subluxation implies incomplete dislocation. The femoral head remains in partial contact with the cartilaginous acetabulum and there is therefore no interposition of soft tissue. Arthrography may reveal eversion of the fibro-cartilaginous limbus but after reduction, in the early case, the limbus descends to provide good cover for the head.

Subluxation presents no problem at initial reduction provided treatment is commenced before the development of irreversible secondary changes in the joint. In children who have borne weight for several years, the head may be enlarged and the cartilaginous roof of the acetabulum permanently deformed

In younger children the subluxation is reduced on the frame and the reduction maintained by Batchelor's plaster until ossification of the cartilaginous roof increases. Mobilization is then permitted unless a marked degree of anteversion persists, in which case correction by derotation osteotomy of the femur should be carried out in order to maintain reduction and provide concentric stimulus to development of the osseous roof.

Dislocation. Dislocation implies complete displacement of the head and loss of contact with the articular surface of the original cartilaginous acetabulum

(a)

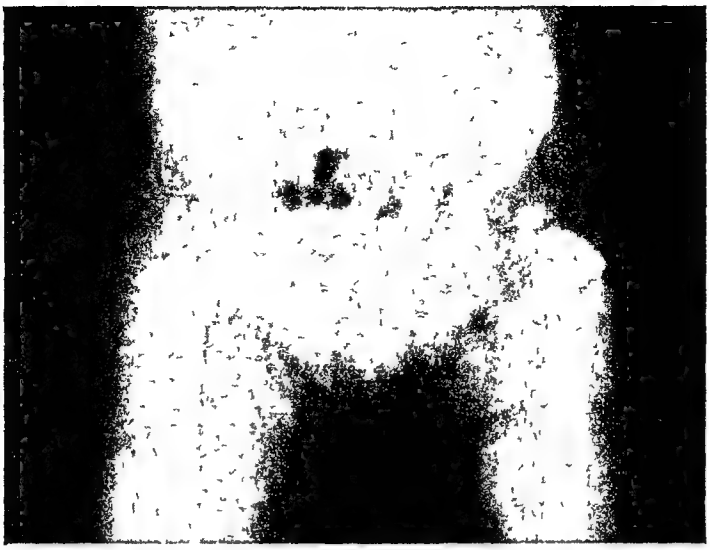

(b)

(c)

FIG 16 —(a) Subluxation of Left Hip. (b) Correction of Anteversion in Batchelor's Plaster Note improved ossification of roof after 9 months (c) Hip remains stable after 18 months of freedom



(d)

(c)

FIG 17 —(d) Arthrogram shows Inversion of Limbus Specimen removed from posterior superior aspect of acetabulum (c) Reduction remaining stable 2 years after excision of limbus and derotation osteotomy

Treatment even in the young child is difficult because in complete dislocation interposition of soft tissue may complicate reduction and subsequent joint development Opinions differ both as regards the exact nature of the obstruction and the ability of conservative treatment to accommodate the interposed tissue successfully in the joint

FIG 17 —(*a*) Predislocation of right hip Dislocation of left hip

(*b*)

(*c*)

FIG 17 —(*b*) Apparent Reduction after 1 year's conservative treatment (*c*) Displacement of Left Hip on weight-bearing.

exposed. The rectus and reflected head are defined and separated from the capsule. A transverse incision is made in the capsule close to the acetabular lip and carried forwards deep to the rectus and backwards to the posterior superior limit of the joint.

The leg is pulled downwards to expose the joint but the infolded limbus is seldom apparent at this stage. A blunt hook is introduced and the tip slipped over the edge of the fold and forced through its base. The anterior part of the limbus is freed from its peripheral attachment, grasped by a Kocher forceps and drawn out of the joint. The extent

(a)

(b)

FIG 18.—(a) Dislocation of Left Hip (b) Arthrogram shows Inverted Limbus.

Arthrographic study of complete dislocation in young children reveals the presence of an obstructing limbus which at the end of the frame reduction period is compressed into the joint. The presence of this obstruction will complicate accurate reduction and subsequent joint development, depending on its size and the duration of the dislocation.

If the inverted limbus is small it may be so compressed during reduction and application of abduction plaster that the head appears to be accurately reduced on straight X-ray. Under these circumstances the limbus may in some cases be successfully accommodated in the joint but in others the interposed limbus will lead to redisplacement of the head or faulty development of the joint.

The importance of inversion of the limbus as a stage in the development of the dislocation and as a barrier to complete reduction has been emphasized by Somerville (1953) and Scott (1956). They report the discovery and removal of an inverted limbus in over 70 patients The interim results in these cases appear promising

Adherents of the closed reduction method maintain that inversion of the limbus is not the obstacle to reduction in all cases, and that an adequate period of immobilization in the frog position following manipulation will bed the head down in the acetabulum and overcome the obstruction in a reasonable proportion of cases The disadvantage of this method is the danger of osteochondritis, the possibility of redislocation, and the fact that the ossific stimulus to the roof may be reduced by the interposed soft tissue.

Differentiation between subluxation and dislocation may prove difficult in some cases without the aid of arthrography. Unless the surgeon is experienced in the interpretation of arthrograms and in the operation for excision of limbus, dislocation should be treated by conservative methods, provided the head appears accurately centred following frame reduction and application of Batchelor's plaster. Any tendency for the head to stand out from the acetabulum after reduction or when freedom is permitted indicates the probable presence of an obstruction

The author's practice in the treatment of congenital dislocation is to confirm the presence of an obstructing limbus by arthrography both before and after frame reduction The inverted limbus is excised when interposition and imperfect reduction are confirmed by the arthrograms The operation should not be undertaken until the femoral head has been brought down and opposite to the acetabulum by frame reduction The surgical excision of an obstructing limbus should be carried out by surgeons familiar with the operative technique

Excision of Limbus. The operation for excision of limbus through a limited approach has been described in detail by Somerville. The frame is removed immediately before operation. A sandbag is placed beneath the affected hip and the legs are allowed to adduct. A straight incision is made above the anterior half of the iliac crest. The abductor muscles are reflected subperiosteally until the capsule of the joint is

and derotation osteotomy of the femur is carried out. The limb is then immobilized in a plaster spica until union at the osteotomy site has occurred. The plaster is then removed and the child is allowed to mobilize This regime has the great merit of shortening the treatment period without increasing the danger of early re-dislocation, provided the derotation osteomy has been adequate. Early weight-bearing is considered to stimulate the development of the acetabular roof.

Derotation Osteotomy of the Femur. Opinions differ on the significance of anteversion of the femoral neck and the necessity for surgical correction. Muller and Seddon reviewing the late results of congenital dislocation of the hip found that 83 per cent. of hips which showed a notable degree of anteversion were associated with subluxation or dislocation of the head. They concluded that anteversion is a factor in causing subluxation after reduction.

Anteversion is nullified while in the Batchelor position and may correct spontaneously during treatment. The exact indications for derotation osteotomy of the femur vary from case to case but as a rule only anteversion exceeding 60 degrees need be considered. It may be stated that the earlier the mobilization the greater the need for surgical correction.

Weight bearing may be permitted despite residual anteversion in cases where the original displacement has been minimal and the subsequent development of the osseous roof satisfactory.

Surgical correction of persistent, marked anteversion is advisable before weight bearing when displacement has been more advanced and development of the osseous roof less satisfactory.

In the young child anteversion of 45 degrees is taken as the upper limit of normal variation Accurate measurement of the anteversion angle is difficult but not essential as only anteversion exceeding 60 degrees need be considered for surgical correction.

X-rays taken at 15 degrees and 65 degrees of internal hip rotation are of value and the impression gained while screening for arthrography is reliable Clinical estimation of anteversion is regarded as a useful method. With the child supine and the knees flexed over the end of a table, the prominence of the greater trochanter is palpated and the hips internally rotated until the prominence is maximal. The angle of deviation of the tibia from the mid line equals the anteversion angle

The most suitable site for osteotomy is the subtrochanteric region. The bone is exposed with the hip in the internally rotated position. Two Steinman pins are inserted as markers and the femur divided between them by a gigli saw. The lower fragment is externally rotated to the required angle as judged by the markers and rotation maintained by a four-hole vitallium plate and screws The femur is immobilized in a hip spica for approximately six weeks

Derotation osteotomy is also indicated if displacement occurs following closed reduction provided there is no inversion of the limbus In the presence of an inverted limbus, derotation osteotomy should be

(c)

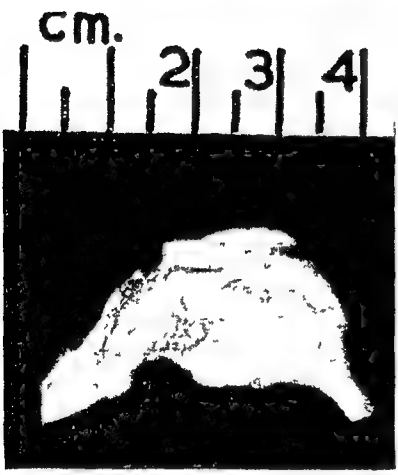

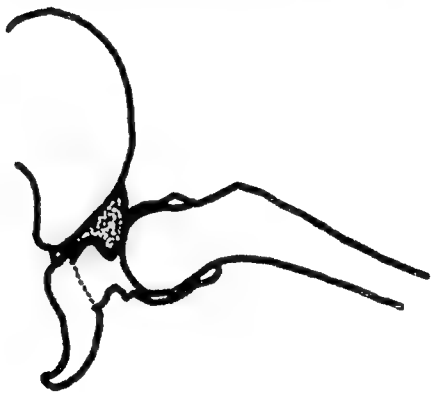

(d)

FIG 18 —(c) After three months on Abduction Frame the Head lies opposite the joint but the Limbus is obstructing complete Reduction (d) Arthrogram tracing showing position of Limbus in relation to the Head Photograph of large limbus removed at operation

of the true roof of the acetabulum is now apparent and the fold is seen extending to the bottom of the acetabulum, attached to its periphery all the way The remaining portion of the fold is removed by curved scissors and the whole of the acetabulum can be inspected without damage to the ligamentum teres or dislocation of the joint.

When the limb is fully rotated medially and abducted to 30 degrees the head sinks deeply into the acetabulum. This position is maintained during closure of the wound and application of a hip spica

Following excision of limbus the period of protection can be shortened by derotation osteotomy of the femur in order to allow early weight bearing and stimulus to development of the acetabulum.

One month after the limbus has been excised the plaster is removed

graft is then inserted between the cut margin of the ilium and the upper edge of the acetabulum. The graft is secured by two ivory pegs passed through it to the ilium. After operation a plaster spica is applied with the hip abducted and internally rotated to avoid any undue pressure on the newly formed roof.

Capsular Arthroplasty. Colonna states that the preferable age is over 3 and under 8, that the bony architecture of the head approaches normal, and that it should be done in arthrogriphotic or spastic cases or those with other congenital anomalies. Free telescoping of the head is helpful but previous surgery is not The chief indication is in congenital dislocation of the hip but it is sometimes done in pathological dislocation following infection and in carefully selected cases following poliomyelitis if the hip is not flail. The technique is carried out in two stages. In the first stage the head is brought down to the acetabulum

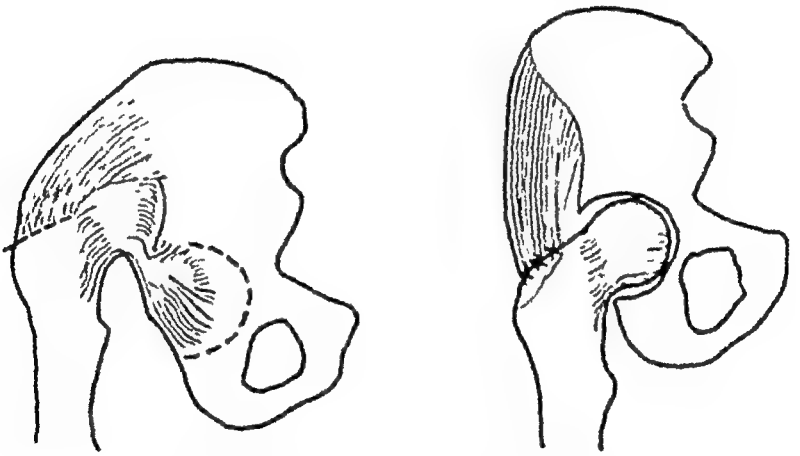

Fig 20—Colonna Capsular Arthroplasty.

by skin or skeletal traction with tenotomy of the adductors if necessary During the downward traction Colonna immobilizes the pelvis by a well-padded plaster spica applied to the opposite side. Traction is continued until the head of the femur is opposite the original acetabulum.

The second stage is carried out several weeks later The joint is exposed by a lateral approach and the greater trochanter is removed at its base and reflected upwards with the gluteal muscles. The capsule is dissected free, divided and sutured over the femoral head. The acetabulum is cleared of fibro-cartilaginous tissue and deepened with a reamer. The head is reduced and the trochanter reattached. If an internal rotational osteotomy is required this may be done two weeks later.

After operation a plaster spica is applied for four weeks. The limb is then suspended with light traction and active movement is commenced. A sandbag is placed between the legs to prevent adduction. Weight bearing is not allowed for three months and then only for short intervals in a walker and not until a good range of active and passive movement is regained.

regarded as only a supplementary procedure to surgical excision of the obstruction

Reduction of Late Cases. Successful reduction and development of a reasonable acetabulum becomes increasingly difficult in dislocation of the hip after the age of 4 Frame reduction with strong pulley traction should be attempted as treatment is governed by the extent to which the head descends.

If the head can be replaced within the acetabulum, the defective roof cover can be improved by the shelf reconstruction operation.

If reduction of the head is possible almost to the level of the acetabulum, the capsular arthroplasty of Colonna offers a good prospect of a stable hip This operation is particularly useful in unilateral dislocation because subsequent arthritis in a stable hip can be adequately treated by arthrodesis.

Shelf Reconstruction of Roof. The joint is approached by a Smith-Petersen incision, the capsule is opened to define the upper limit of the true acetabulum and to remove any interposed tissue. An osteotome is driven into the ilium above the capsular attachment and an incision is made in crescentic fashion to correspond with the upper outline of the socket.

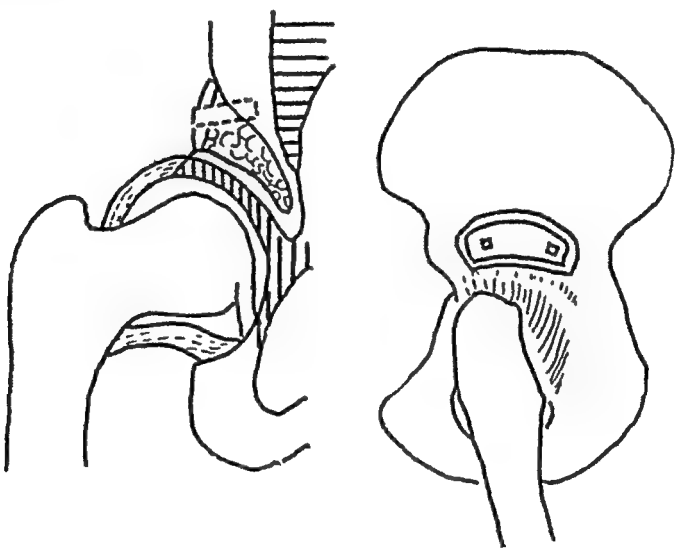

Fig 19 —Shelf Operation for Reconstruction of Shallow Acetabular Roof.

The upper half of the acetabulum is then dug out of the ilium and levered down over the head of the femur to form a hood This step is the most important one in the whole operation , it is essential that no gross projecting ledge is formed over the head Rather the normal shape of the acetabular roof is restored by digging the upward sloping superior half of the socket out of the ilium

A cortical graft from the bone bank is cut to form a crescentic plate which will maintain the position of the restored acetabular margin. The defect in the ilium is packed with bone chips and the crescentic

has the relative disadvantage of increased shortening, less mobility and a greater likelihood of arthritic pain.

Schanz Osteotomy. Schanz pointed out that in congenital dislocation of the hip the pelvis tilts on weight bearing until the femur on the dislocated side impinges on the lower border of the pelvis. If the femur is angled to align the upper fragment with the side wall of the pelvis and the lower fragment parallel with the axis of weight bearing, the lurching gait will be diminished since the stable position is reached earlier. The depression of the trochanter also improves the leverage of the gluteı.



Fig 22 —Improved Posture following Bilateral Abduction and Extension Osteotomies in girl of 16 years

The lower femoral fragment should also be extended backwards at the osteotomy site to decrease the pelvic tilt and diminish the lumbar lordosis

Prior to operation an X-ray is taken with the femur in full adduction and from the point of bone section a line is drawn vertically to correspond with the normal position of a femur. The correct abduction angle is ascertained by measurement. A strong vitallium plate is angled laterally to this degree and to compensate for the posterior

Palliative Operations

These operations are reserved for cases in which reduction is no longer possible either by closed or open methods They are designed to improve stability, decrease lordosis and control pain arising from the hip or lower back The advisability of palliative procedures in the young patient with symptomless displacement of the hip is doubtful and should not be lightly undertaken.

Palliative procedures fall into three categories (*a*) Shelf operation ; (*b*) arthrodesis , (*c*) osteotomy.

(a) **Shelf Operation.** The shelf is constructed at the level of the head without previous reduction. Some authorities believe that it increases stability but the lordosis produced by backward displacement of the head is not improved unless the head can be transposed to the correct frontal plane This shelf operation predisposes to early arthritic pain which, in bilateral cases, complicates subsequent treatment

(b) **Arthrodesis.** Hip fusion is a satisfactory procedure for relief of arthritic pain in the older patient with unilateral displacement. Arthritic pain occurs more commonly in subluxation than dislocation unless there is a well formed acetabulum

(c) **Osteotomy.** The primary object of osteotomy is deflection of weight bearing by leg angulation of the femur to bring the axis of the femoral shaft more in line with the direction of weight transmission

Angulation osteotomy of the Schanz type is preferred to the bifurcation osteotomy of Lorenz in which the upper end of the lower fragment is abducted and inserted into the acetabulum. The Lorenz procedure

Fig 21 —Schanz Osteotomy Right Femur Pelvis balanced by shortening and angulation of Left Femur

2. A primary embryonic defect. This type is usually accompanied by other defects, such as hare lip, cardiac defects, spina bifida. It is fortunate that this type is uncommon since it is much more difficult to treat and usually requires operation.

3. The third theory is that of contracture of the quadriceps extensor muscle dragging the knee into a deformed position It is suggested that this contracture is similar to that found in arthrogryphosis

Fig 23 —An Extreme and Untreated Case of Genu Recurvatum

Clinical Features

The knee is fixed in hyperextension, and the skin over the anterior aspect of the joint shows several transverse creases. The patella is small or absent. On the posterior aspect of the joint, the hamstring muscles are palpable as tense cords, and the femoral condyles are felt projecting in the popliteal fossa. The joint is relatively fixed. When attempts are made to flex it, an elastic resistance is appreciated—this is the quadriceps tendon.

Treatment

If begun shortly after birth, it may be possible to stretch the shortened quadriceps and replace the tibia in mild cases If this method is adopted, care must be taken not to attempt too much flexion at the start

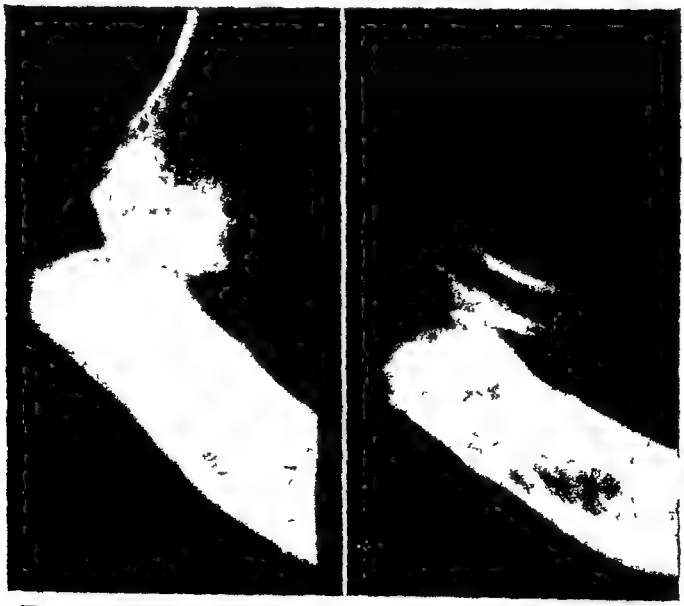

Fig 24 —X-ray of the Knees of the preceding figure

displacement of the head the plate is angled in extension to approximately 30–40 degrees

The femur is exposed by a lateral incision and the level of bone section decided by measurement from the X-ray. The angled vitallium plate is screwed to the upper femur and the bone divided by drill and osteotome The lower fragment is aligned with the lower angle of the plate and secured by screws A plaster spica is applied for three or four months

If the operation is carefully carried out, complications are few. Plate fixation ensures correct angulation but in growing children this may be altered by muscle pull Pain at the site of contact with the lower border of the pelvis occurs in some cases many years later but is seldom severe. The Schanz osteotomy is a useful palliative procedure in the irreducible case where pain or severe deformity warrant surgical correction.

Complications.

Certain complications may follow the treatment of congenital dislocation of the hip Some of these are the result of the operation itself, while it is doubtful if some of the others are due to the operation or are merely coincident. As a direct result of the manipulative treatment, fracture of the femur sometimes occurs, and occasionally the sciatic nerve may be bruised. The hæmatoma which sometimes occurs after damage to muscles may suppurate Fairbank describes two such cases.

Osteochondritis deformans juvenilis may occur after reduction of a dislocated hip, but cases have also been recorded of the condition occurring in the normal hip in unilateral cases

Arthritis. Pain and stiffness of the hip due to arthritis not uncommonly follow manipulative reduction, particularly where the manipulation has been carried out with considerable force A further degree of arthritis may result in complete ankylosis.

Displacement of the Epiphysis. It is a curious fact that so few cases of displacement of the epiphysis of the femoral head are recorded. The author is unable to find any statistics of the incidence of this complication This strongly supports the pathological theory of the etiology of slipped upper femoral epiphysis.

CONGENITAL DISLOCATION OF THE KNEE

(Congenital Genu Recurvatum)

The condition, known since the time of its first description by Chatelain as congenital dislocation of the knee, is also known as congenital genu recurvatum. There are three types

1 The traumatic developmental type This is the most common and is considered to be due to malposition in utero . thus the legs may be caught by the chin or axilla with the knees extended and uterine compression may prevent them from assuming the usual flexed position.

Pathology

The pseud-arthrosis is situated usually at the junction of the middle and lower thirds of the tibia. The ends of the bone are sclerosed, and there is a considerable gap between the fragments occupied by fibrous tissue. The leg is therefore much shorter than its neighbour. As in

Fig. 25.—The Clinical Appearance of an Untreated Congenital Pseud-arthrosis of the Tibia

Fig. 26.—The X-rays of the preceding case

ordinary transverse traumatic fractures of this region, there may be considerable overlapping which may mask the extensive loss of substance which the tibia shows.

Etiology

The essential nature of the error is the aplasia of a portion of the tibial shaft, which most likely arises as a sequel to a nutritional disturbance. It has also been suggested that it results from intra-uterine pressure or from constriction by amniotic bands (Codivilla). Watson Jones thinks it may be an ununited fracture, though it differs from all other congenital fractures in that it is so reluctant to unite.

Treatment

This is usually unsatisfactory

Short of amputation, there are two possible methods of treatment: (1) by shortening the leg sufficiently to get good approximation and

—the amount should be increased from day to day, and the correction maintained by adhesive plaster bands applied from thigh to foot.

There is, as in other muscular deformities, a strong tendency to relapse, while in the more severe cases manipulation will be insufficient to overcome the contracture. In these cases, operative division or lengthening of the quadriceps and its lateral expansion—and occasionally of the ilio-tibial tract—will permit of replacement. After this procedure there is apparently no tendency to relapse

After operation, the corrected position is maintained by a splint or light plaster case, and when the child begins to walk care should be taken to avoid, by appropriate splinting, the subsequent development of a knock-knee This is particularly prone to occur because of the imperfect nature of the ligaments of the knee joint.

CONGENITAL ANGULATION OF TIBIA

(Congenital Tibial Kyphosis)

In this condition, the tibial diaphysis on one or both sides shows marked anterior angulation Middleton has drawn attention to other concomitant anomalies, viz , a persistent pes equinus, and some apparent atrophy of the affected limb or limbs.

The error is often associated with other congenital derangements, such as absence of the fibula or congenital hip

Etiology

It is believed to be a result of failure in growth in length of the calf muscles, which remain short, pull on the heel, and produce a rigid equinus deformity When the ankle joint is plantar flexed to its farthest limit, the strain falls on the cartilaginous tibial diaphysis, which becomes angled at its weakest point, i e., the junction of its lower and middle thirds As soon as the tibia becomes ossified, the angulation ceases

Congenital angulation of the tibia has also been attributed to intra-uterine pressure, constriction by amniotic bands, and to the healing of an intra-uterine fracture It has even been thought to be related to the condition of congenital pseud-arthrosis of the tibia, but the errors have nothing in common save their site.

Treatment

Since the condition is fully established and maximal at birth, it should be treated at once The tendo-calcaneus may be tenotomized or lengthened to relieve the equinus displacement, and if necessary the tibia straightened later by osteoclasis or osteotomy.

CONGENITAL PSEUD-ARTHROSIS OF THE TIBIA

This is a fairly common congenital error which is notable for its resistance to all treatment. The child is born with what appears to be a fracture of the tibia which fails to unite.

at birth there is a slight calcanean deformity since pressure is exerted on the sole of the foot in the folded-leg position of the fœtus. This is quickly corrected because of the relative power of the calf muscles. If abnormal pressure is brought to bear on the foot in the normal position, however, the outer border of the foot takes the major part of the pressure and longitudinal bending of the foot occurs, that is, an adduction of the forefoot. As the pressure increases, the force exerted on its outer border causes the whole foot to be swung into varus and, owing to the inclination of the joint surfaces, into equinus as well; or, in rare cases, into the most severe degree of the deformity which Browne recognizes, in which the great toe is pointing directly upwards along the tibia and there is gross varus but no equinus deformity. In support of this view, Browne attaches importance to the dimples over the bony prominences which are an invariable feature and have their normal counterparts in the dimples over the elbows, the knuckles and the posterior superior iliac spines. He stresses the importance of the fact that treatment based on this conception of the error is more uniformly successful than any other.

2. Hereditary Defect. In support of this theory it is quoted that the condition appears to have a definite familial and hereditary incidence. Thus Adams records a case of a man with club-foot who had five children, one nephew, and one grandchild, all similarly affected. Brockman, its main advocate, has stressed the fact that the deformity in the main consists of a dislocation of the head of the talus out of the socket formed for it by the navicular, sustentaculum tali, and the plantar calcaneo-navicular (spring ligament). He contrasts the deformity with congenital dislocation of the hip, and believes that in congenital talipes equino-varus there is an aplasia of the socket.

Pathological Anatomy

The typical congenital club-foot is at first a deformity of soft tissue only. The essential features are plantar flexion of the talus, inversion of the calcaneus (and with it the other tarsal bones) and adduction of the forefoot. At birth the bones of the foot are normal in shape but altered in position. Browne has pointed out that three degrees of the error may be distinguished: in the first, adduction of the forefoot is the only error; in the second degree inversion and equinus are present as well as the adduction; while in the third degree, when the toes are pointing directly upwards and the sole is in contact with the medial surface of the tibia, there is inversion and adduction of the forefoot, but no equinus element in the deformity. Over the skin on the outer part of the foot there are usually dimples which may be so marked as to resemble scars. The lateral malleolus is prominent; the medial appears flattened and poorly developed.

The Muscles and Tendons. The muscles are poorly developed and the tendons delicate. The tendo-calcaneus passes downwards and

side-to-side apposition of the fragments; and (2) by some method of bone grafting The methods in use are:

(*a*) The massive inlay method of Albee.

(*b*) The McFarland method of grafting.

(1) Socur believes that the intact fibula is the obstacle which prevents the consolidation of the tibia after the bone-graft The tibia is useless physiologically as the axial pressure is transmitted by the fibula only and therefore no callus is formed after the grafting A simple osteotomy does not help as it heals too quickly. Socur performs a resection of the greater part of the fibular shaft and uses this as a graft on the tibia.

(2) McFarland suggests ignoring the zone of absorption of the pseud-arthrosis and placing a strong bone-graft behind the tibia, implanting the graft into the back of the bone well above and below the site of non-union It is a sort of "bony bypass" and carries the weight directly from the upper part of the bone to the lower. Good results are reported.

CONGENITAL TALIPES EQUINO-VARUS
(Club-foot)

Congenital talipes equino-varus is a deformity in which the foot is turned inwards to a varying degree. In its most characteristic form there are usually said to be four elements of deformity—flexion of the ankle, inversion of the foot, adduction of the forefoot, and medial rotation of the tibia. Slighter degrees of deformity are met with, however, and to these the name of congenital club-foot is equally applicable

Etiology

Club-foot may result from an osseous, a muscular or a neuropathic error, or may be termed idiopathic Of these the last is by far the most frequent and will be discussed first

The Idiopathic Type.

As a rule it occurs in otherwise normal infants, but occasionally other congenital deformities are present, indicating the developmental origin of the condition It is more frequently bilateral than unilateral. The following theories have been advanced to explain the actual cause of the deformity

1. Increased Intra-uterine Pressure. This is the oldest theory and according to it the deformity begins as a malposition in utero, this is made permanent by undue pressure on the foot by the uterine wall, probably as a result of a deficiency in the amniotic fluid

Objections are usually raised against it on the grounds that the uterus is not a rigid chamber, but one which accommodates itself to its contents and twins are rarely affected Further, the fœtus is supposed to be constantly changing its position and moving its limbs, so that continuous pressure on any one part is hardly possible.

Denis Browne, a supporter of this theory, points out that normally

suggests a primary myodysplasia. This type is difficult to correct and to maintain in correction.

In unilateral cases the deformity is never very severe, but the leg is obviously smaller and less well developed than on the healthy side. The skin of the foot may be normal, though stretched and thin on the dorsum and thrown into creases along the medial border and on the sole. In addition, there may be signs of external pressure on the dorsum in the shape of scars. The head of the talus can be felt on the dorsum of the foot. The lateral border of the foot is convex and the medial concave. The forefoot is plantar-flexed upon the hind foot. The heel is rotated medially and may be drawn upwards, throwing the whole foot into equinus. In many cases a well-marked genu-valgum is present. The patient walks with a stumbling gait, which lacks elasticity. Bursæ and callosities develop over the weight-bearing areas. When bilateral the deformity is rarely equal since, according to Browne, the foot on the outer side of the cross-legged position is always 10 per cent. worse than the sheltered one. He points out that the primary and constant deformity is the curving inwards of the sole and heel round a perpendicular axis, and that the equinus and varus elements are secondary and inconstant.

Diagnosis

The diagnosis is usually easy, but it is well to remember that an inverted position of the feet is frequently assumed by young infants. If this can be easily over-corrected by gentle manipulation the existence of club-foot can be excluded.

In all cases search should be made for spina bifida, and for evidence of poliomyelitis.

Prognosis

Without treatment, the deformity increases, the gait becomes more unsightly, and the foot more troublesome on account of callosities and ulceration.

With early, effective, and continued treatment, all cases of club-foot should be cured, and a useful and properly shaped foot obtained. In older children the condition should be greatly improved.

Treatment

The objects of successful treatment are two in number: the deformity must be corrected, and the muscular power of the limb developed to a sufficient extent to maintain the correction. This implies constant supervision until the period of growth is over, as there is a distinct tendency to retrogression. The mode of treatment varies with the age and the extent of the deformity. The important point is to get the forefoot deformity corrected so that it points outwards 20 degrees as in the military position of boxing. If the forefoot is treated correctly it

inwards to its insertion into the calcaneus, while the plantar muscles, especially on the medial side, are tensely contracted The anterior muscles of the leg are elongated

The Ligaments. The ligaments on the medial and inferior surfaces of the talo-calcaneo-navicular joints are contracted, the plantar calcaneo-navicular ligament being very small and short The deltoid ligament of the ankle joint is similarly affected.

The Bones. Bony changes appear as a result of the long-continued contraction of the soft parts. They are at first confined to the talus, but subsequently the calcaneus, the navicular and the cuboid become appreciably altered

Fig. 27.—Bilateral Congenital Talipes Equino-Varus.
Baby 3 months

(i) The Talus The head of this bone in normal alignment with the leg can be felt as a prominence on the dorsum of the foot Later a large portion of the upper surface of the talus escapes from between the malleoli and becomes prominent on the dorsum of the foot. This portion, now free from pressure, becomes broadened, and, in severe cases, is an obstacle to passive dorsiflexion of the foot even after the soft structures have been stretched or divided The head and neck of the talus are deflected downwards and medially, carrying the navicular and the forefoot with them

(ii) The Calcaneus. The calcaneus becomes tilted so that its medial tuberosity approaches the medial malleolus. Its vertical height is less on the medial side, and the anterior part of the bone is deflected medially, following the direction of the neck of the talus.

(iii) The navicular and the cuboid are displaced inwards The phalanges are plantar-flexed

It has been the usual convention to suppose that the tibia was medially rotated This, however, is not an obvious feature in the majority of cases and Denis Browne states that in his experience it never occurs.

Clinical Features

In a small proportion of cases structural bone changes are present at birth. This type is distinguished by the presence of a small inverted heel and hard stringy shrunken calf muscles, the condition of which

After the age of two the foot is too rigid and Browne advises a woodworker's vice, with a notched block of wood on one side of it and a wedge on the other. The foot is placed between the two blocks and the deformity reversed by forcing the foot into the notch so that it has a longitudinal bend convex inwards instead of outwards.

The foot is then forced into a calcaneo-valgus position by the full force of the hands. In the case of the right foot, the surgeon's right thenar eminence is placed below the great toe and the four fingers curled round the heel, with the palm of the hand over the external malleolus and the tips of the fingers on the tendo-calcaneus.

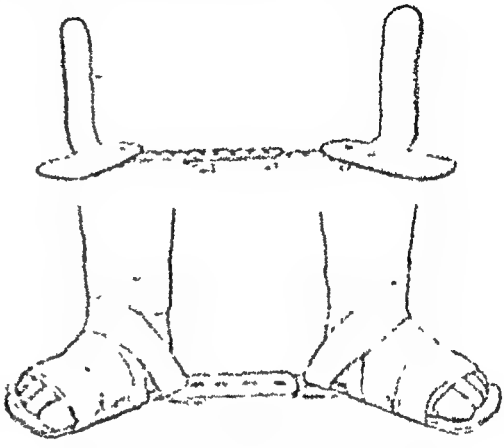

Fig. 29.—Denis Browne's Splint.

The Method of Splintage. After manipulation some form of splint must be used. A light lateral splint of aluminium covered with lint is sometimes applied to the outer side of the leg and foot. Attempts to maintain the correction by zinc oxide plaster have also been made.

Denis Browne points out that fixation in these types of appliance tends generally to produce immobilization of the foot and therefore the muscular recovery is inhibited rather than assisted. He has designed a splint (Fig. 29) which allows of full correction of the deformity and at the same time encourages the activity which is so important from the point of view of the muscular development. He maintains that the important element of the deformity is the longitudinal bending of the forefoot. If this is completely corrected the calcanean deformity is automatically improved and the equinus also tends to disappear. The essential of the method is that the feet are connected horizontally at any desired angle to the sagittal plane of the body. To hold the feet an L-shaped piece of aluminium is cut and bent up one side. This is put on so that the bent part is applied to the outer side of the leg, while the remaining limb of the L lies against the sole of the foot. After the manipulation the splint is applied and kept in place by a few turns of sticking plaster, while each foot splint is fixed by a friction-joint at a satisfactory angle to an aluminium crossbar. If the club-foot is unilateral the normal foot should be fixed to the cross-bar so that it is turned outwards at an angle of 20°, that is at its natural inclination. In the case of the club-foot the splint is fixed so that the toes are directed outwards at an angle of 90° from the sagittal plane. The splints should be removed once a fortnight and an opportunity taken then to manipulate the foot. In Browne's opinion treatment by this splint should be continued for about nine months. The child is encouraged to kick and to stand up as much as possible in the splint.

will grow from its inward bending to perfect straightness and normal size. (Correction of this part of the deformity with support and rest is the secret.)

FIG 28.—Congenital Talipes Equino-Varus
Associated with polydactylism and bowed tibiæ

1. Treatment in an Early Case.

The treatment should be begun as early as possible. Brockman points out that the ideal time to start treatment is when the child has adapted himself to an independent existence, i e, a week to ten days after birth.

The Method. Manipulation, frequently repeated, is the method of treating the deformity in an infant. The adduction of the foot is corrected by the hands of the operator up to the age of two. The infant lies supine on its mother's lap, while she protects the knee, and prevents any strain from falling on the ligaments, by grasping the upper end of the tibia. While one hand fixes the heel, the other reduces the adduction of the forefoot. To do this, the thumb of one hand rests on the talus and acts as a fulcrum, while the other hand presses the forefoot into abduction. The maximum result is maintained for a few seconds at each sitting.

but in older patients it is seldom possible to rectify the deformity completely by manipulation alone; in these tenotomy of the plantar fascia and the muscles, and elongation of the tendo-calcaneus may be necessary.

Once the deformity is corrected, physiotherapeutic treatment is instituted to mobilize the joints and to develop the muscles. In the intervals, the foot is kept in the corrected position by means of a Browne's splint. When the child is allowed to walk, the lateral side of the sole of the shoe is raised to keep the foot in good position. The use of the splint is continued during the night for many months.

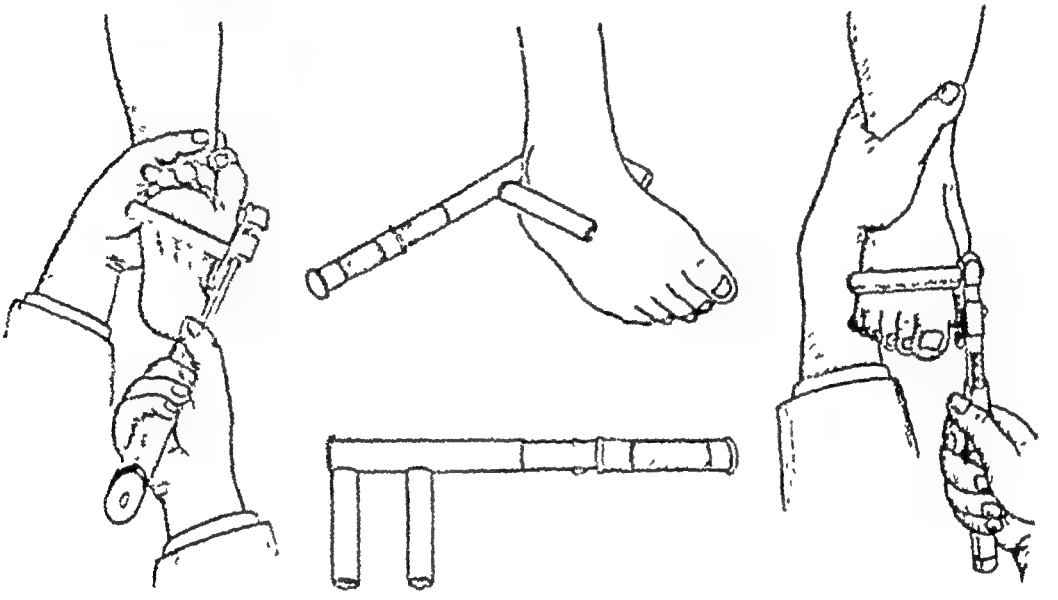

Fig. 30.—The Thomas's Wrench.
Used in the treatment of Club foot. Stages in its application. (Whitman.)

3. The Treatment of Old and Relapsed Cases.

However early and however thoroughly congenital club-foot is treated, in a certain percentage of cases, because of rigidity or a constant tendency to relapse, manipulative treatment will not suffice.

Although a plantigrade foot may still be obtained by manipulation, the heel will remain inverted and the navicular will still be in close contact with the medial malleolus. Any correction that takes place is between the cuneiform and the navicular, instead of between the navicular and the sustentaculum tali. To ensure a good result in this type of case, an operation is necessary.

The Open Operation of Brockman. A tourniquet having been applied to the limb, an incision is made on the lateral side of the foot, along the calcaneus. Through it, the plantar muscles and fascia are detached from their origins as far backwards and medially as possible, but they are not divided as in Steindler's operation. A second incision is then made on the medial side of the foot and the remaining attachment of the muscles completely erased. The tendon of the tibialis posterior is identified. It may be necessary to detach it from

When he is capable of holding the feet naturally in the corrected position and the feet have the full range of movement, the sticking plaster and the aluminium splint are discarded and replaced by a pair of boots riveted to the aluminium cross-piece to hold the feet in the same position as they occupied in the splint. These boots have open toes and unlace completely from one end to the other. In consequence there is no need for complicated fittings and one pair will last the child for the complete period of treatment, the toes simply sticking out of the open ends as the feet grow. It is often helpful in retaining the correction to reverse the boots, wearing the right boot on the left foot.

If it becomes apparent after a period of some months that the equinus deformity has not been completely overcome it is occasionally necessary to divide the tendo-calcaneus by subcutaneous tenotomy Occasionally the plantar fascia may also require to be divided. After such operations the foot and leg are encased in plaster of Paris with the foot in the over-corrected position, the knee flexed, and the leg laterally rotated. The plaster is carried up to the middle of the thigh, and is worn for three or four weeks

Denis Browne points out that plaster, by completely immobilizing the limb, retards or inhibits the recovery of the muscles and he is also averse to tenotomizing operations as these do still further damage to the muscular tissues. He recommends that forcible correction be obtained in these cases by means of a vice and that thereafter plaster may be employed for a few days until the effects of the operative or manipulative trauma have passed off, following which the child should straightaway be placed in his form of splint or in the special form of boot which he recommends

The deformity may be considered as cured when there is no adduction or inversion deformity, when there is a hollow on the dorsum of the foot in the position previously occupied by the head of the talus, passive movement to the full calcaneo-valgus position, and when the child is able to evert and dorsiflex the foot voluntarily to about a right angle.

2. The Treatment of Older Patients, hitherto untreated.

The older the child, the more resistant is the deformity. Treatment by manipulation, therefore, requires to be carried out under general anæsthesia The foot is manipulated with a Thomas's wrench or by Browne's instruments, but the various movements are the same as those effected manually in a younger child.

The correction is complete when the soft parts are completely lax and the whole foot lies quite limp. It may not be possible to mobilize the foot adequately at one sitting, in which case it will be necessary to repeat the manipulation. After the operation, the foot is fixed in the position of the greatest correction that can be obtained by means of plaster of Paris. The plaster is carried from the toes to well above the knee joint, which is flexed.

In some cases complete correction will be obtained by this method,

Middleton believes that the pathology of the muscular derangement may be of three types.

1. There may be an arrest of development at the myoblastic stage.

2. The muscles may develop normally but fail to elongate.

3 The muscles, fully formed, may be the site of intra-uterine degeneration, with progressive conversion into scar tissue (Myodystrophia fœtalis).

Middleton attributes these changes to a process of intra-uterine muscular degeneration—myodystrophia—allied, at least in its pathological effects, to the muscular dystrophies of a later age period.

The characteristics of the individual lesions which arise in myodystrophia fœtalis have been recounted previously. (*See* congenital dislocation of the hip, congenital genu recurvatum, congenital club-foot, etc.)

CONGENITAL HIGH SCAPULA

Congenital high scapula, eponymically called Sprengel's shoulder, is a deformity that has aroused much interest since the first description of it in 1863 by Eulenberg. It consists of an abnormally high and permanent elevation of the shoulder, and is frequently associated with other deformities, such as congenital scoliosis, absence of vertebræ, fusion of ribs, or cervical rib, i.e., errors in segmentation or position of the cervical spine. There is often also a midline cleft between the two occipital bones

Etiology

This deformity is the result of imperfect descent of the shoulder girdle, which first appears as a cervical appendage, but which should descend by the end of the third month to the level of the upper part of the thorax. The proper designation, therefore, should be undescended, or high, scapula.

Various explanations of this permanent arrest in the descent of the shoulder girdle have been suggested, but hitherto none has accounted satisfactorily for the gross abnormalities of vertebræ and ribs, nor for the development of a bridge of bone anchoring the scapula to the spine, all of which frequently co-exist.

Middleton found in one of his cases a band of muscle passing from the skull to the scapula which apparently had failed to grow and had anchored the scapula in an unduly high position. This muscle consisted of masses of undeveloped muscle cells which had remained in the myoblastic stage—a stage normally terminating at the third month

The muscles which suffer in their normal development will not fulfil their later function In this respect the complete or partial defect of the muscles, their fibrous appearance, and the interruption of the normal differentiation of muscle fibres at the myoblastic stage, as manifested

[illegible] They [illegible] and [illegible] for [illegible] rotation

[illegible]

[illegible] of normal shape, or may be [illegible] at the expense of [illegible] length. It lies at an unusually high level, and may be [illegible] to the vertebral column or the occipital bone [illegible] of inspiratory muscles [illegible] or by fibrous tissue, or even by a bar of cartilage. [illegible] to articulate with the upper scapular bone of the first vertebrate between the fourth cervical and the third [illegible] of vertebrae. Among the [illegible] in common [illegible] of the cervical spine are [illegible] transverse and [illegible] of the vertebrae, both of which produce [illegible] [illegible] The latter may be [illegible] one or both of which may be fused to the [illegible]

The Muscles. Constant alterations in the musculature of the shoulder girdle are [illegible] The [illegible] may be [illegible] [illegible] [illegible]

[illegible]

move laterally, nor does its lower angle rotate when the arm is raised above the horizontal.

The deformity of the shoulders rather than any functional disability of the arm attracts the notice of parents, and only occasionally is there weakness of, or disinclination to use, the limb. All movements of the arm are complete except abduction and elevation to the vertical position. The neck is frequently short in appearance, though the shortness is often more apparent than real, being caused or accentuated by the high position of the shoulder girdle. Torticollis is present in about 10 per cent. of cases. Cranium bifidum and spina bifida are often present. The skull may show the type of cranium bifidum which is caused by an unclosed tectal plate and consequent prolongation of the foramen magnum backwards between the two halves of the squamous occiput. Congenital kyphosis affecting the thoracic region is an almost invariable accompaniment of the deformity, whilst scoliosis is quite frequently present as well. This deformity causes cosmetic disturbance, functional impairment, and it can cause pain.

Diagnosis

The X-ray appearances are characteristic, the films showing the unduly high situation of the scapula. Other congenital defects in the neighbourhood may also be apparent.

Prognosis

Even if operation is undertaken, prognosis is not very favourable. Published results indicate that while the mobility of the shoulder may be improved, asymmetry almost always persists.

Treatment

Many operations have been performed—the omo-vertebral bone has been removed, the band of fascia has been tenotomized or excised, and a portion of the scapula has been excised—but usually without great improvement. McFarland suggests that nothing less than the removal of the whole of the scapula, with the exception of the portion of the glenoid and coracoid processes, should be carried out. Whatever modification of this is carried out it is obviously essential that the coracoid process should be freed from the scapula or from the clavicle by dividing the conoid and trapezoid ligaments. The author doubts, however, the advisability of suggesting operation in this deformity, especially if the functional and cosmetic defect is slight and as the results are disappointing

CONGENITAL SHORT NECK
(Klippel-Feil Syndrome: Brevicollis)

Our knowledge of this condition dates from a paper by Klippel and Feil who, in 1912, described a case which has formed the basis

of all subsequent work on this subject. It would appear to be an advanced stage of high scapula The prominent features which are emphasized as being the essentials of this syndrome are:

(*a*) Short neck or absence of neck.
(*b*) Absence, or limitation, of movement of the head.
(*c*) Lowered hair line.
(*d*) Often there is an expressionless mongoloid type of face.

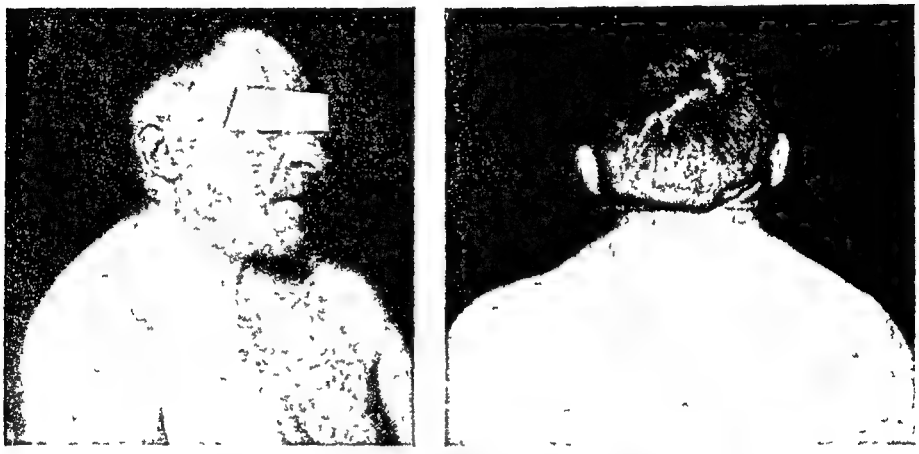

(*a*)

(*b*)

FIG 33 —(*a*) Klippel-Feil Syndrome (*b*) X-ray of case of Klippel-Feil Syndrome showing Abnormality of Vertebræ

The neck is frog-like and so short that the individual may appear to have no neck at all—the type called by the French *les hommes sans cou*. Movement of the head is very slight or is practically absent, and movement of the facial muscles is sometimes limited as well. The trapezii are tense and produce a wing-like appearance which has given rise to the name "congenital webbed neck." There may be an added torticollis of muscular or bony origin. The posterior hair line of the scalp is so low that it reaches the upper part of the thoracic wall Scoliosis elevation of the scapula, and other congenital anomalies may be present.

Varying degrees of the deformity occur. In the slighter cases the cervical shortening is not marked to any great extent. The conditions found on X-ray examination vary in an extraordinary way. In the typical extreme case there is a fusion of the lower cervical vertebræ and usually the thoracic vertebræ, into a solid mass. Less extreme cases vary from simple atlanto-occipital fusion to all possible combinations of fusions of different vertebræ. There is thus evident a considerable deformity of the cervical spine and usually numerical reduction of its component elements. Cervical spina bifida is usually present. As in other congenital defects, there are frequently associated defects in other parts of the body. Thus one case showed a supernumerary lobe of the lung, while in another there was a patent foramen ovale, and in another a cleft palate. Occasionally mental retardation is present. A few have shown functional impairment of the upper extremities suggestive of a common neurogenic origin.

This is the result of morbid conditions in the parent interfering with the normal fœtal development.

The importance of recognizing the condition lies, not in any hope of remedying the deformity, but in its differentiation from other conditions which present a somewhat similar appearance and are to some extent amenable to surgical treatment, namely, congenital torticollis and Pott's disease. The simpler congenital deformity of elevation of the scapula has also to be considered.

It would also appear desirable to investigate the cervical spine in all patients presenting Sprengel's deformity, since it is invariably one of the elements of the grosser Klippel-Feil syndrome.

Treatment

Treatment as a general rule is not indicated, but in cases where there is an extensive fold of skin a plastic operation may produce marked improvement. Gillies has described such a case.

CLEIDO-CRANIAL DYSOSTOSIS

The syndrome known as Cleido-Cranial Dysostosis and described by Marie and Fenton in 1897, is a relatively rare condition, of which the leading features are: (1) aplasia of the clavicles; (2) exaggerated development of the transverse diameter of the cranium; (3) delay in

closure of the fontanelles. Hereditary transmission is the rule. The condition affects both sexes equally, and may be transmitted by either father or mother, to either sons or daughters. Several cases are reported, however, in which neither a familial nor a hereditary history was discoverable

Heineke distinguishes between the following varieties of congenital defect of the clavicle:

1. Where the ends of the bone are normal, but a pseudo-arthrotic gap filled with connective tissue exists between them

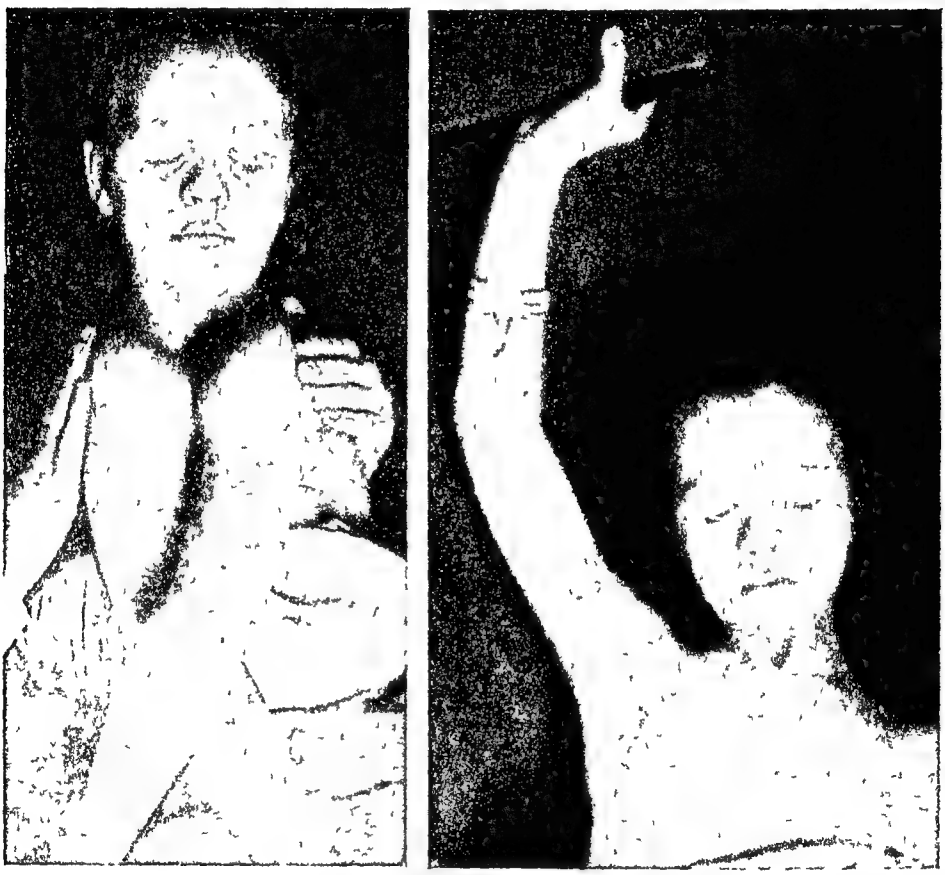

Fig. 34 —Cleido-cranial Dysostosis
Note the approximation of the shoulders, and the excellent functions of the limb

2 Where there is a partial defect of one end, usually the acromial, its place being taken by fibrous tissue.

3 Where the whole clavicle is absent.

Where the scapula is absent in addition, the deformity must be regarded as an aplasia of the whole shoulder girdle rather than a dysostosis

The deformities of the clavicles are always accompanied by variations in the muscles The clavicular portion of the trapezius may be absent, there may be mal-development of the pectoralis major, the

clavicular portion of the deltoid may be deficient; or there may be a wide variation in the form of the sternomastoid.

Many other malformations have been reported in association with defective clavicles. Some of these are: brachiocephaly and dolicocephaly; malformations of the various sutures, fontanelles, and bones of the skull and face; disturbances of dentition; achondroplasia; variations in the small bones of the hands and feet; deformities of the thorax, spine, and pelvis; prolapse of the virginal uterus; inguinal hernia; and spina bifida.

Etiology

Little or nothing is known of the etiology of this condition. Steindler thinks it belongs to the class of intrinsic systemic deformities, arising during the first week of embryonic life. The condition affects the bones which are formed in membrane. Thus the vault of the skull may show membranous areas which persist throughout life. The clavicle itself is mainly formed in membrane. Its ends, however, are ossified from cartilage, and in this deformity the ossification of the ends usually proceeds as in the normal condition, so that the clavicle is represented as a flexible membranous rod with a portion of bone at either end. In Hemeke's other types, the error is evidently more extensive, and the normal ossification of the parts derived from cartilage is also interfered with.

Clinical Features

The patient is usually brought to the surgeon on account of some accidentally discovered trouble with the shoulder. Sometimes an indefinite injury precedes, but more frequently no such history is obtained. Examination usually shows an apparently ununited fracture, or complete absence, of the clavicle, and the patient can usually approximate the tips of his shoulders to each other below the chin.

Treatment

If pain is present from the pressure of one or other of the ends, then removal of the part is indicated. As a rule there is little or no disability or discomfort and the abnormal mobility is not usually a hindrance

CONGENITAL DISLOCATION OF THE SHOULDER

True congenital dislocation of the shoulder is very rare, but the term is, wrongly, applied to acquired dislocations occurring at or shortly after birth, which are not so uncommon. The commonest forms of acquired dislocation are those arising from trauma at birth, or developing as a sequel to birth palsy. The true congenital form is not associated with difficult labour, and there is therefore no evidence of bruising at birth. It is often not discovered for some time.

The dislocation is invariably posterior, and subspinous Greig, reviewing this condition, draws attention to Studder's observations on two cases in one family in which the deformity occurred. In each case the labour had been easy; the accoucheur had failed to recognize the deformity, but it had been noticed by the mother soon afterwards The deformity was the same in both cases, viz abduction at the shoulder, medial rotation of the arm, and slight flexion of the arm and forearm. Movement was limited, and the head of the humerus was palpable below the spine and behind the acromion. The glenoid could not be felt, the scapula was small and the acromion and coracoid were closely approximated The electrical reaction of the muscles was normal

Congenital dislocation of the shoulder has been described in association with congenital dislocation of the hip In cases operated upon, the head of the humerus has been found to be small and atrophied, and resting on a facet on the posterior aspect of the glenoid fossa. Greig states "that muscular action alone hardly seems a likely possibility. Uterine pressure alone seems equally unlikely, but the two together, accompanied or not by some spasmodic contraction of a muscle or group of muscles, seems to give a possible explanation." It seems not unlikely, however, that, as in congenital dislocation of the hip an aplasia of the glenoid fossa may be the most potent factor in producing such a lesion Those who have operated on the condition appear to have found no great difficulty in reducing the dislocation. Some cases have been reduced by manipulation alone If this is successful, then the arm must be splinted for a few weeks to keep it in position

CERVICAL RIB

It is an old observation that numerical variations are common in the rib series of man; there may be an extra rib either in the cervical or in the lumbar region, on one or both sides.

Galen and Vesalius were the first to describe a cervical rib in detail. It is a supernumerary rib which springs from one of the cervical vertebræ, usually from the seventh, rarely from the sixth, and very rarely from the fifth.

Embryology

Wood Jones attributes the formation of supernumerary ribs to a conflict between the developing nerve plexuses and ribs. In the higher forms of animal life, the limb buds when they appear are in relation to several vertebral segments, the nerves from which innervate the bud. As the growth of the limb buds does not keep pace with the longitudinal growth of the vertebral column, the course of the segmental nerves to the buds becomes more and more oblique There then ensues a conflict between the obliquely running nerves and the developing costal processes of the cervical vertebræ. The nerves, much larger in proportion to the vertebræ and ribs of the embryo than to those

of the fully developed animal, impede the growth of the costal processes. The extent of growth of any cervical process is therefore determined by the extent of the resistance of the nerve in its path. Jones believes that when there is an accessory cervical rib—i.e. a hypertrophied cervical costal process, there has been a preceding anomaly in the nerve plexus. He points out that many so-called cervical ribs are really rudimentary first ribs. It is now well established that in addition to the normal arrangement, two well-marked variations may occur in the grouping of the brachial plexus These are:

1. The pre-fixed plexus which receives a considerable part of the fourth cervical root, and only a small contribution from the first thoracic.

2. The post-fixed plexus, which receives no fibres from the fourth cervical, but has a large first thoracic contribution, and a reinforcement from the second thoracic.

In association with the first type of plexus, the costal process of the seventh cervical vertebra does not encounter its wonted resistance and therefore tends to be unusually well developed. With the post-fixed plexus, the costal process of the first thoracic vertebra is met by abnormal resistance, and may remain rudimentary. Todd, on the other hand, is of opinion that the blood-vessels are of equal importance in producing anomalies of the upper end of the thorax.

Anatomy

In 1869, Gruber of St. Petersburg classified cervical ribs by dividing them into four groups:

1. A rudimentary rib in which the costal process does not reach beyond the transverse process

2. A more pronounced type, in which the cervical rib reaches beyond the transverse process and either has a free end or touches the first rib.

3 An almost complete rib, joined to the cartilage of the first rib by a distinct band of fibrous tissue, or by the tip of its long body.

4. A complete rib, which possesses a true costal cartilage uniting with the cartilage of the first rib or with the sternum.

A complete rib extends laterally from the seventh transverse process, then turns forwards and downwards between the scalenus anterior and scalenus medius muscles to join the costal cartilage of the first rib. As it turns downwards, the brachial plexus passes over it; and, on its downward course, the subclavian artery arches backward and laterally across it Usually the scalenus anterior acquires some attachment to the cervical rib, and separates it from the subclavian vein. Above the vein, and close to the rib, the transverse scapular and transverse cervical branches of the thyreo-cervical trunk pass across the root of the neck Above, and almost parallel to them, is the posterior belly of the omo-hyoid muscle.

When the rib is incomplete, the scalenus anterior is less likely to

be attached to it Murphy states that, if the rib is long enough, the space between the cervical and the first thoracic rib is occupied by intercostal muscles and by an intercostal vein and artery, in exactly the same manner as in the thoracic intercostal spaces

Not everyone with a cervical rib suffers from pressure on the nerve cords; indeed, it is well known that some persons with well-developed cervical ribs have no symptoms It has been laid down as a rule by Lewis Jones that where a bony prominence can be felt with ease, the brachial plexus is usually free from pressure. In these cases it is to be presumed that the pre-fixation is considerable and that the plexus

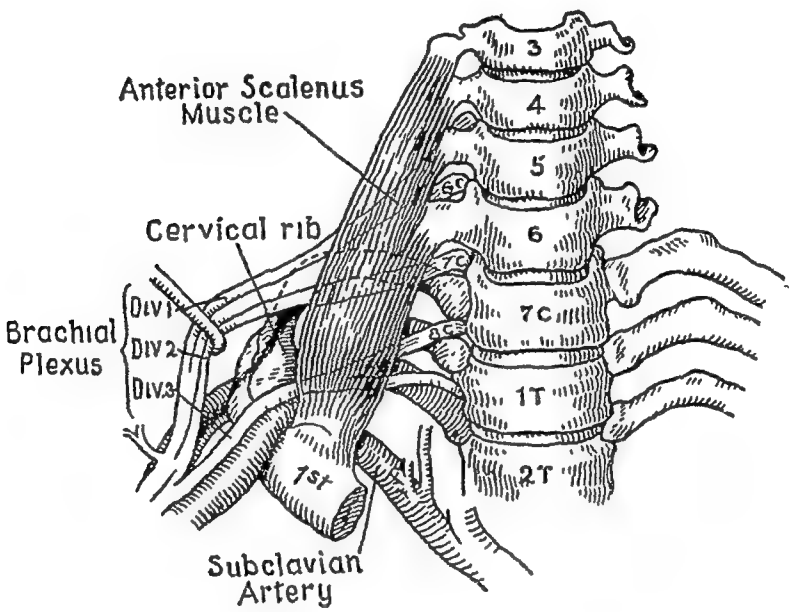

Fig 35 —The Effect of the Scalenus Anterior Muscle on the Lower Cords (After Adson)

and the bony outgrowth have readjusted themselves at a higher level than normal

The normal dropping back of the shoulder girdle and the upper extremity which occurs in adolescence is another important anatomical feature In women the shoulder drops back farther than in men, and it is obvious that the greater the drop of the arm relative to the highest rib, the greater will be the tension on the lowest trunk of the plexus as it arches over that rib It is also obvious that when drooping of the shoulder girdle has produced sufficient tension to cause the development of symptoms, these would probably be relieved by elevation of the shoulder.

Incidence. In reviewing 80,000 routine examinations at the Mayo Clinic for the five years ending in 1914, Henderson found 31 cases of cervical rib The condition is bilateral in 67 to 80 per cent. of all cases. Two cervical ribs on the same side are extremely rare, but have been reported.

Cervical rib is found more often on the left side, but, according to Murphy, symptoms are more common on the right, because of the greater use made of the right arm, because the right brachial plexus is in closer connection with the corresponding rib than the left, and because there is a greater drooping of the right shoulder in right-handed persons. Sargent reports that in his series of cases symptoms were usually present on the side of the smaller rib.

Authorities are agreed that the condition is more common in women than men. Childbirth, the greater susceptibility of women to the conditions which precipitate symptoms—rapid loss of weight, chronic nervous exhaustion, and general ptosis—are important factors, as also is the greater drooping of the shoulder girdle in women.

Symptoms and Signs

Aetiology. Symptoms may occur at any age, the earliest being recorded by Stiles in a patient of 18 months. The average age is about 30 years. During childhood and adolescence there is a progressive descent of the shoulder girdle, which normally attains its final position in adult life. In many individuals, a further droop may result from acquired deformity, and, if a cervical rib is present, the persistence of this deformity places the lowest plexus-trunk under conditions of abnormal tension. The elasticity of the nerve trunk permits slight repeated friction without damage, but the margin of safety is small, and friction neuritis is easily initiated.

Adson and Coffey have pointed out the importance of the scalenus anterior muscle in the causation of symptoms. They were able to demonstrate the pressure on the nerve trunks by this muscle by making the patient elevate the chin, extend the neck, or rotate the head to the affected side, while taking a deep inspiration. This produced paræsthesia over the distribution of the brachial plexus, and, frequently, obliteration of the radial pulse on the affected side. There is evidence that in some cases the scalenus medius, or a fascial band in the same plane may cause the symptoms, and in such cases these tight structures will also be divided. Adson attributes the pathological changes in the distal vessels, and particularly the cyanosis produced, to a disturbance of sympathetic innervation.

Symptoms of cervical rib may be grouped as sensory, motor, vasomotor and local.

1. The Sensory Symptoms. (*a*) *Subjective.* In many cases the patient complains of tingling in the hands and fingers, particularly in the finger-tips As a rule, these symptoms are unilateral, a point of importance in diagnosis. They are more frequently referred to either the ulnar or the radial side than to the whole hand

Pain is also experienced, and is constant in its distribution. It is usually felt only in the forearm, hand, or fingers, and radiates chiefly in a downward direction. The pain may be sharp and lancinating,

and may be brought on by sudden rotation of the head or by a forceful, downward pull of the shoulder Sometimes it is dull, aching, burning or boring in character, and frequently occurs late in the day after the patient has been working for a time. Especially is this so in the case of housewives, when it often begins after sweeping, washing, or dusting

(*b*) *Objective.* In some cases there is no alteration in cutaneous sensibility, but as a rule sensibility is diminished or lost This anæsthesia does not always strictly correspond in its distribution to the areas supplied by the radial or ulnar nerves, nor does it entirely coincide with a root supply.

2. The Motor Symptoms. In the early stages there is steadily increasing weakness of the hand, and inability to carry out finer movements

Wilson describes two types of muscular involvement The first of these, called the median type, is very frequent. There is early wasting of certain muscles of the thenar eminence, viz the abductor pollicis and the opponens pollicis, all the other thenar muscles, including the flexor pollicis brevis, being intact. The wasting may be slight, or profound enough to render apparent the outline of the metacarpal bone of the thumb The fact that only two of the three thenar muscles supplied by the median nerve are affected indicates that the nerve supply of the thenar muscles is derived from two sources—the eighth cervical and first thoracic segments

The second type of muscular involvement is that corresponding to the ulnar distribution Wasting of the interossei is present and in appearance the hand approximates to the main-en-griffe, indicative of a lesion of the eighth cervical root Occasionally only muscular cramp in the hands and fingers is complained of, muscular atrophy being absent

3. Vasomotor Symptoms. Circulatory changes may produce a dusky coloration of the affected arm and hand, associated with mild trophic changes in the tips of the fingers Several cases have been reported where gangrene of one or more fingers has followed obliteration of either the radial or the ulnar artery, or both Diminution in the volume of the radial pulse is common The pulse can be decreased or obliterated by making the patient elevate the chin or flex the head to the affected side during inspiration Occasionally the subclavian artery may be seen pulsating above the clavicle, and even aneurism of the subclavian artery has been noted The presence of Horner's syndrome has been recorded, due, possibly, to pressure or traction on the inferior cervical ganglion

Todd has suggested that the vascular symptoms are due to the pressure of the rib upon that portion of the sympathetic which enters the arm by the lowest trunk of the plexus Telford and Stopford have shown that the arrangement of the sympathetic fibres in the lowest trunk is not constant but that they occasionally form a separate bundle

on the inferior aspect of the trunk. They are then in apposition with the rib and they may be exposed to friction or pressure. This bundle of sympathetic fibres is distributed along with the branches of the plexus to the peripheral vessels at varying levels, and friction induces irritation, with consequent spasm of the arterial wall. The persistent spasm must embarrass the vasa vasorum and lead to changes in the health of the vessel wall. Thrombosis and gangrene are secondary to those changes. That portion of the main arterial trunk (subclavian and axillary) which lies above the pectoralis major tendon is innervated by a peri-arterial plexus, and not by branches from the cerebrospinal nerves, so that it is not affected by cervical rib and remains open, healthy and pulsating.

Lewis and Pickering criticize the above theory. They believe that obliterative lesions of the distal limb arteries are due to injury of the subclavian artery between the articulation of the cervical and first thoracic ribs and the clavicle, which space may often be so narrow as to nip the artery. They suggest that this injury may be followed by thrombus formation and subsequent detachment of the thrombus, so obstructing the distal arteries. Aneurysm of the artery has been described, and Eden has tabulated forty-five published cases forming an impressive body of evidence in favour of the view that the vascular disturbances result from injury to the subclavian artery. It is probable that there is no one cause for the vascular syndrome.

4. Local Symptoms. Not infrequently the patient complains of a dull ache or a dragging pain, at the root of the neck.

Diagnosis

An abnormal transverse process of the seventh cervical vertebra can usually be demonstrated in an X-ray film. It is only by counting the number of vertebræ which lie inferior to the suspected supernumerary rib that the real nature of the case can be determined with certainty, as it is known that by no means all rudimentary ribs are derived from the seventh cervical vertebra, although clinically they are commonly classed as cervical ribs. Many of them are rudimentary first ribs

The severity of the symptoms does not depend on the size of the bony projection. A small bony rib which might reasonably be considered little more than a large transverse process, may be so anchored down to the first rib by a firm fibrous band that the nerve is subjected to continuous and severe stretching. On the other hand, a large or even complete accessory bony rib may be present without causing inconvenience.

As similar symptoms are often present in patients who show little radiological evidence of an accessory rib, certain spinal diseases, such as syringomyelia, and progressive muscular atrophy, and also lesions of the ulnar nerve, must be considered in diagnosis.

In syringomyelia the thenar eminence may remain unaffected for some time.

In progressive muscular atrophy the thenar muscles are usually the first to be affected but the whole group is involved, whereas, in the case of cervical rib, selection is apparent This dissociated palsy of certain of the thenar muscles is of considerable importance in diagnosis.

Treatment

Surgical treatment of the condition is indicated when the symptoms are sufficient to incapacitate the patient; and when there is evidence of circulatory disturbance, such as obliteration or reduction of the radial pulse on extending the neck or rotating the head Where there is marked paræsthesia, and the patient is of a neurotic type, the advisability of operation should be discussed, the decision being left to the patient.

If a cervical rib is discovered accidentally and is causing no symptoms, surgical treatment is not indicated. In these cases it is well, for psychological reasons, to refrain from informing the patient of the condition

In many cases where the symptoms are slight, improvement results from the development of the trapezius and the levator scapulæ muscles Bracing up the shoulders relieves the constant strain on the nerve trunk as it crosses the abnormal rib This improvement is particularly seen in cases where there has been a recent illness, with loss of muscular power In some cases it may be advisable to change the occupation to one in which less strain is thrown on the affected arm.

In cases with severe symptoms, operation should be recommended, as the condition can be cured by removal of the rib and the fibrous band which is causing the abnormal pressure. Pain and circulatory disturbance are the principal indications for operation, and when the condition has gone as far as muscular atrophy operation is unlikely to be of benefit

The Operation. The operation may be performed through an anterior or a posterior incision, the former being preferable

A sandbag is placed under the shoulders, and the head turned well to the opposite side A long, straight, oblique incision is made from just above the sterno-clavicular joint outwards and upwards at an angle of 30 degrees with the clavicle for about 5 inches. The trapezius and the spinal accessory nerve are retracted backwards after cutting the descending superficial cervical nerve The omohyoid muscle may be cut The external jugular vein and the posterior border of the sternomastoid are freed and retracted inward The transverse cervical artery is ligated and divided as it crosses the brachial plexus. The plexus is exposed along the anterior surface of the scalenus medius muscle, between the lateral border of the scalenus anterior and the clavicle The lower part of the scalenus medius muscle is reached by mobilizing the plexus and retracting it downward and inward The

supra-scapular nerve is found arising from the lateral border of the upper trunk of the plexus. The long thoracic nerve is carefully protected from injury in freeing the plexus from the scalenus medius. It lies behind the lateral portion of the plexus, between it and the muscle. The two upper roots pierce the muscle. The lowest crosses in front of it, and the trunk of the nerve, after crossing the first digitation of the serratus anterior, descends behind the clavicle to reach the axilla. The serratus anterior, which occupies the floor of the outer angle of the wound, is recognized by the transverse direction of its fibres. Should the rib be not well developed, it will be found by dividing

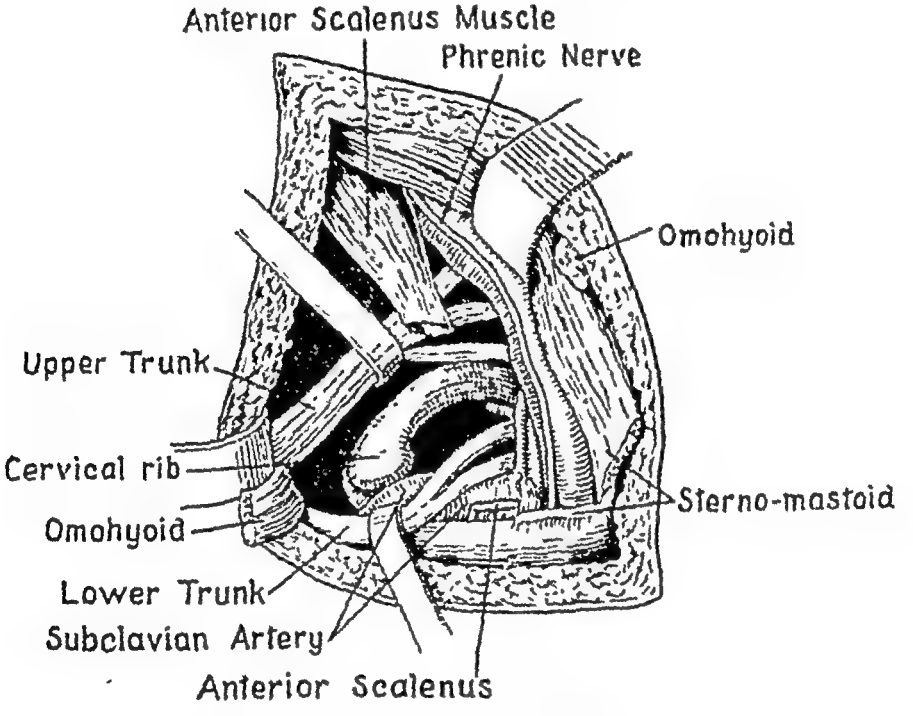

FIG. 36.—Adson's Operation

The scalenus anterior is divided near its insertion and the pressure on the plexus removed (After Adson)

the fibres of the scalenus medius above the first thoracic rib. Stretching between the two ribs is a thin sheet of muscle fibres, the homologues of the thoracic intercostal muscles: they are divided close to the cervical rib, so as not to injure the pleura, and what corresponds to Sibson's fascia is carefully divided along its inner border. Before this can be done, the lowest trunk of the plexus, which arches over the cervical rib, must be freed and retracted downward and inward. Before freeing the rib carefully from the cervical pleura it is divided at its junction with the tip of the transverse process and the seventh cervical vertebra.

Frequently the anterior extremity of the rib is found to extend farther forward and to join the first rib opposite the scalene tubercle, the scalenus anterior being inserted into both structures In dealing with this condition the third part of the subclavian artery is exposed

at the lower and inner angle of the wound, freed from its fascial sheath, and retracted downward and inward. This allows the detachment of the insertion of the scalenus anterior from the tip of the cervical rib and also the removal of the outgrowth of bone which is sometimes thrown out to meet the cervical rib

If the rib is rudimentary it is completely embedded in the substance of the scalenus medius In such cases a fibrous band frequently extends downward and forward like a bow-string, to be attached to the first rib at or distal to the scalene tubercle. As the first dorsal nerve arches over this band on its way to join the eighth cervical nerve, it is important to remove the band along with the rudimentary rib. The best access to it is obtained by opening up the interval between the upper and middle trunks of the plexus by small goitre retractors.

The operation is completed by suturing the cervical fascia with catgut and the skin with fine silkworm gut and clips. No drain is inserted

Adson removes the supernumerary rib by an inter-plexar route as depicted in Fig 36.

Adson and Coffey now believe that the removal of the rib is unnecessary, inasmuch as the subclavian artery and the brachial plexus are immediately relieved from pressure and irritation by detaching the scalenus anterior from its insertion.

THE SCALENUS SYNDROME

The surgery of the cervical rib has been described in its simplest form but much work in recent years has pointed out the complexities of the problem of the pressure effects associated with cervical ribs, rudimentary first ribs, and the so-called normal first rib Walshe and others believe that the problem of cervical rib as described gives rise to an unreal and artificially simplified conception of the problem not substantiated by the multiplicity of the factors involved They describe two categories of clinical syndrome : (1) those with an abnormal upper thoracic outlet , and (2) those with a normal thoracic outlet but with an altered topographical relationship between this and the shoulder girdle The first group includes cases of cervical rib and rudimentary first rib , the latter are the normal first rib syndrome and the scalenus syndrome and perhaps also acroparæsthesia In the first group the outlet is asymmetrical, one side being narrower than the other and tilted. Of even greater interest is the frequent existence of other skeletal abnormalities—scoliosis deformed vertebræ (wedge shaped), Klippel-Feil syndrome, Sprengel's deformity, syringomyelia. Muscular anomalies concern the scalenus muscles. The inconstant scalenus pleuralis arises from the anterior tubercle of the seventh cervical transverse process and is inserted into the inner border of the first rib and fascia on the

pleura. Its presence as one of the bands of Sebilleau may compress the lower root of the brachial plexus.

The subclavian artery may be abnormal in course or shape. Lastly, distortion of the costo-clavicular gap may occur and play an important role in the production of symptoms. Rudimentary first ribs are said to be longer than cervical ribs, associated with greater deviation and more often accompanied by vascular manifestations. It is pointed out that the unceasing respiratory movement of the thorax and the frequent shoulder movements cannot but aggravate existing maladjustments between arteries, nerves and bones This oft-repeated friction, stretching and compression of soft tissues, may lead to considerable reactionary

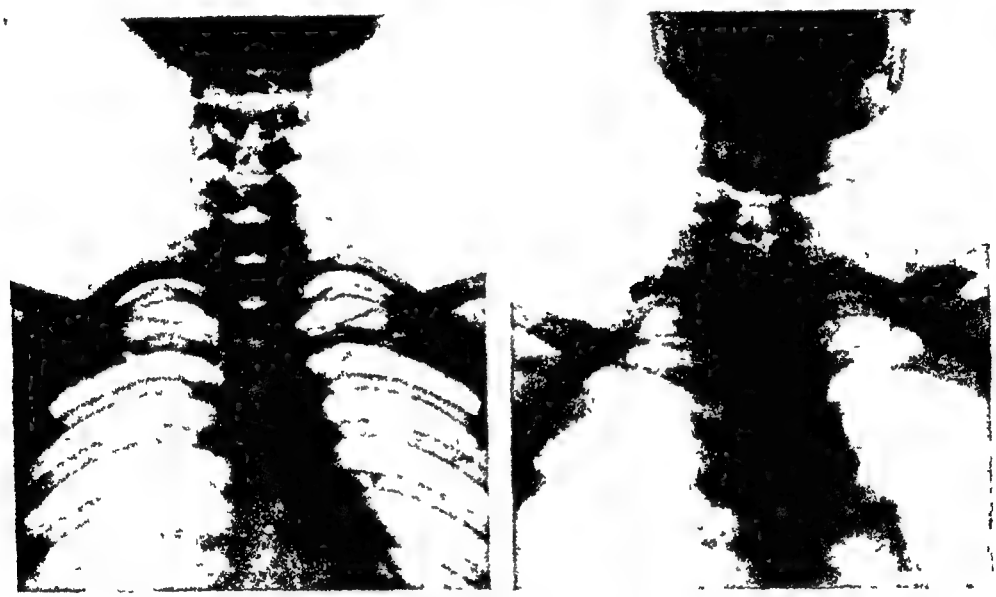

FIG. 37 —Bilateral Cervical Rib, with Unilateral Symptoms.
The first rib appeared to be causing pressure also, so part of it was removed

changes Thus the walls of the subclavian artery may become worn and the artery may be bound to the first rib by scar tissue which can also drag on the stellate ganglion already tethered to the artery by the annulus of Vieussen, this perhaps explaining the sympathetic phenomena occasionally encountered. The effects on the neuro-vascular bundle may be physiological in muscular atrophy and drooping of the shoulder, anatomical in anomalies of bone and muscle attachment, and pathological in the reactionary soft tissue changes produced.

The vascular symptoms are more difficult to explain than the neurological. At first it was thought that the circulatory disturbances were caused by stretching or kinking of the subclavian artery over the rib or by a thrombosis of the artery or a combination of these factors. Later Todd, Telford and Stopford explained them on the basis of pressure or friction on the sympathetic fibres occasionally situated in the lowest trunk of the plexus in contact with the rib. It was suggested that the

irritation produced spasm of the vessel wall, obliteration of the vasa vasorum, and eventually thrombosis and occlusion. This hypothesis was supported by the fact that the thrombosis does not extend higher than the pectoralis major tendon, the more proximal part being innervated by a periarterial plexus not subjected to friction and not like the brachial by branches from the cerebro-spinal nerves

These views are criticized by Walshe and others as they say the anatomy of the sympathetic supply to the upper extremity is not as suggested and that long standing irritation should lead to structural impairment and paralysis with vasodilation, increased warmth, redness, and sweating Costo-clavicular compression is thus held to account for many of the pressure effects associated with cervical, rudimentary, or even normal first ribs in relation to both nerves and vessels. Evidence to support its occurrence has been adduced from venograms and it has been seen to occur at operations

The symptoms develop gradually with an onset in early adult life and they may be divided into sensory, motor and vascular groups. They are usually referred to the distribution of the lower trunks of the brachial plexus, the eight cervical and first dorsal roots. The sensory changes are predominantly referred to the forearm and hand with pain and paræsthesia along the median aspect of the arm and forearm and in the fourth and fifth fingers, and sometimes relieved by raising the arm and shoulder. There may be pain elsewhere than in the area of the brachial plexus, e g in the middle of the clavicle or over the scapula Stopford points out that in the objective sensory disturbances the loss of protopathic sensibility is greater than that of epicritic and suggests that this dissociation is characteristic of nerve compression Trophic sores were noted in two of Stopford's cases Motor features consist of weakness and varying degrees of atrophy of the hand muscles Vascular changes common particularly in the costo-clavicular type take the form of coldness and discoloration, sometimes with attacks resembling Raynaud's disease A further abnormality that has been seen is dilatation of the third part of the subclavian artery

In addition to the accepted clinical investigation and radiology, postural tests are recommended If the shoulders are braced back and downwards the costo-clavicular space is narrowed and alteration in the radial pulses may be noted Hyper-extension of the neck tightens the scalene muscle and tends to raise the first rib, giving rise to a similar effect No absolute conclusions can be drawn from these tests though they are useful as additional evidence.

Conservative treatment is only suitable in mild cases but if there are established neurological signs early operation is advisable. A supra-clavicular approach is effective in most cases but the scalenus anticus muscle should not be divided, unless it is producing compression Bands, fibres or constricting structures must be carefully and deliberately divided or excised to leave the neuro-vascular bundle free A posterior approach to the first rib from behind has many advantages, particu-

larly as it can conveniently be combined with a limited pre-ganglionic sympathectomy.

CONGENITAL WRY-NECK
(Torticollis)

This is a deformity characterized by lateral inclination of the head towards the shoulder, accompanied by torsion of the neck and deviation of the face. It is caused by unilateral contracture of the sterno-mastoid, with secondary shortening of the fascæ and the other muscles of that side of the neck.

Etiology

Many theories have been advanced to explain the development of torticollis. It is claimed by some that there is justification for the hereditary theory, because cases with co-existing congenital deformities, such as club-foot or congenital dislocation of the hip, have been described.

Nové-Josserand and Vianny think it is ischæmic in origin. They state that the middle part of the sterno-mastoid muscle is supplied by an "end artery"—a branch of the superior thyroid—and they have noted that in every case of wry-neck the lumen of the sterno-mastoid artery has been obliterated at the anterior border of the muscle.

It is generally held that trauma is the primary cause of this deformity. The usual belief is that during labour a temporary acute obstruction of the veins of the muscle occurs, and that this is rendered permanent by patchy intravascular clotting in the obstructed venous tree. In the early months of life this clotting is evidenced by the development of the sterno-mastoid tumour of infancy. The tumour eventually disappears, its place being taken by fibrous tissue which later contracts. The mechanism, therefore, is very similar to that which produces the so-called ischæmic contracture of the flexor muscles of the forearm (Volkmann's contracture).

Clinical Features

The condition first becomes evident in the first few months of life when the mother notices an elongated swelling in the lower half of the sterno-mastoid muscle This swelling is at first tender, and the child cries bitterly if it is palpated, or if the muscle is stretched in any way. Gradually the swelling and the tenderness subside, but by the end of the first year of life it is noticed that the muscle is tense. This tenseness is due to the development in the substance of the muscle of a band of fibrous tissue which, by a slow but progressive contraction, pulls the head into the characteristic attitude, so that the ear on the affected side appears to be pulled down towards the sterno-clavicular joint of the same side, while the face is rotated towards

the opposite side If the deformity is not corrected, a gradual atrophy of the face on the affected side develops and becomes increasingly evident with the growth of the child. As growth continues, changes take place in other tissues, all the soft parts on the affected side undergo adaptive shortening, while the bones of the cervical and upper thoracic spine acquire a fixed scoliotic deformity

Pathology

A sterno-mastoid tumour appears about two or three weeks after birth as a spindle-shaped swelling occupying the position of one sterno-mastoid muscle. It may affect only the sternal head, but frequently both heads are implicated The tumour gradually becomes absorbed and finally disappears in from four to six months after birth. On microscopical examination it is found to consist of young cellular fibrous tissue, containing, here and there, remnants of the original muscle fibres, which are seen to be undergoing degeneration

At the end of about a year, changes, hitherto confined to the sterno-mastoid muscle, become evident in other structures in the neck The muscle has now been reduced to fibrous tissue which has contracted, and there is also some thickening and contraction of the deep cervical fascia and of the scalenus anterior and medius The vessels on this side of the neck likewise become shortened in the late stages of the condition, and are smaller in calibre

The majority of cases show, in their later stages, a well-marked asymmetry of the face, which on the affected side becomes shorter from above downwards, and wider from side to side In addition, on the affected side the frontal eminence is flattened, while there is a well-marked protrusion of the occipital region on that side The vault of the skull is thrown backwards on the affected side and forwards on the opposite side, giving rise to a deformity which is comparable to that seen in the thorax in cases of thoracic scoliosis and hence the name scoliosis capitis is sometimes, and quite accurately, applied to it Occasionally an exostosis appears on the clavicle at the site of attachment of the clavicular head of the sterno-mastoid.

Diagnosis

The recognition of congenital wry-neck should, theoretically, present no difficulty, but some cases are obscure Every case should be X-rayed to exclude any vertebral anomaly which may be the primary error.

There is often a history of difficult birth, although cases have been reported after a Cæsarean section The early fusiform swelling may have escaped notice, but the later cord-like contraction of the sterno-mastoid is characteristic.

Treatment

The treatment should be begun at an early stage, as the development of the deformity may thus be arrested in mild cases. It is

doubtful whether it is wise to manipulate and stretch the sterno-mastoid muscle while the tumour is tender. In these cases it may be better to operate as soon as the child is strong enough, say at the age of a month, and to excise the tumour. The cause of the condition is thus removed and further changes are prevented

In mild cases, however, manipulation and exercises are sufficient. The head, having been grasped by the hand, is moved into a position in which the deformity is over-corrected, the object being to stretch the affected sterno-mastoid. The manipulation must be performed

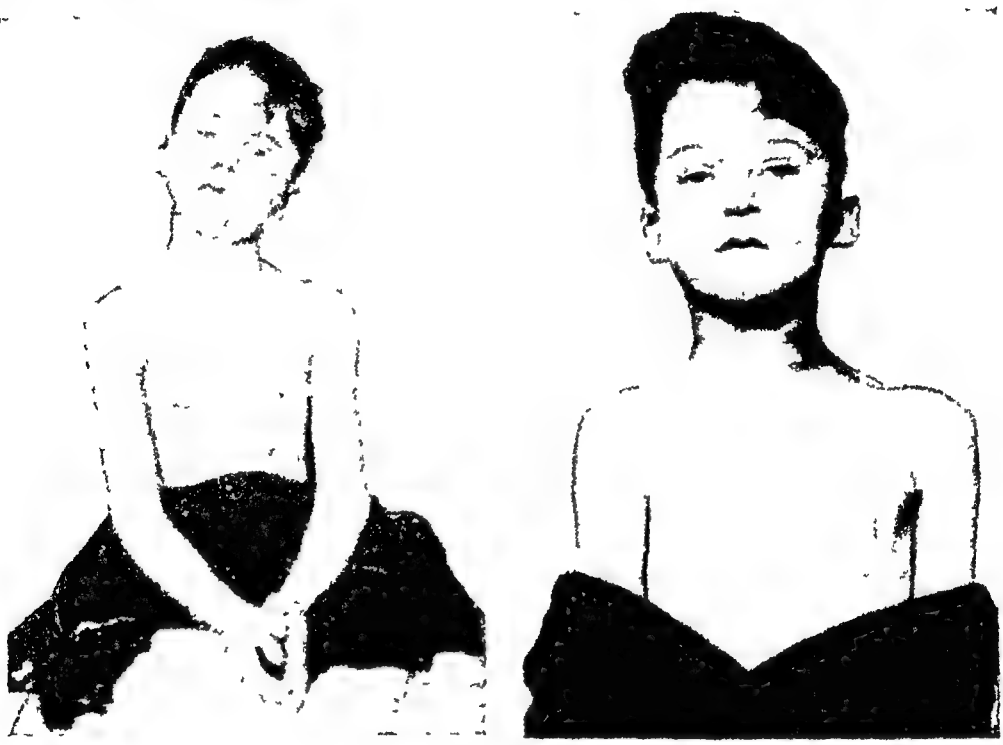

FIG. 38.—Congenital Wry-Neck

Before and after open division of the shortened structure

gently. If this is carried out daily there will probably be little or no evidence of contracture at the end of a few months

When the child is not seen until the age of 2 or 3 years, operation is usually indicated, for at that date manipulation is not likely to stretch the fibrous cord which replaces the muscle Subcutaneous tenotomy is not advised, as it is impossible to ensure that all the shortened structures will be divided and there is a danger of injuring the great vessels at the root of the neck.

These objections are not applicable to the open operation. It can be performed through a comparatively short incision so that the scar is insignificant The operation is carried out under general anæsthesia, the head being laid over a sandbag so that the shortened muscle is rendered prominent. An incision 1½ inches in length is made ½ inch above and parallel to the clavicle, with its centre over the attachment

of the affected muscle. In making the incision the skin is pulled down over the clavicle so that there is no risk of injuring the vessels at the root of the neck The muscular heads are defined and, a flat dissector having been slipped beneath their deep surfaces, each head is divided When the muscle has retracted, the deep cervical fascia is divided, and, if necessary, the carotid sheath and the scalenus anterior During the operation the head is gradually manipulated into the correct position, in order to bring any shortened structures into prominence The wound is closed without drainage by means of fine interrupted horse-hair sutures. After the dressing is applied the head may be placed in an over-corrected position, and retained there by means of a bandage or by a special apparatus

FIG 39 —Congenital Wry-Neck
The asymmetry of the face is characteristic

The after-treatment, which is of great importance, should be continued for about six months. It consists of active and passive movements to prevent any recurrence of the deformity.

When it is desired to avoid a visible scar, a muscle-slide operation may be carried out, as advocated by Lange. An incision is made over the origin of the sterno-mastoid from the mastoid process; this lies entirely in the hairy scalp. The muscle is erased from the mastoid process and from the superior curved line of the occipital bone The operation is inadvisable where more than 1 inch of lengthening is required, as greater mobilization may damage the spinal accessory nerve

OTHER FORMS OF WRY-NECK

Spasmodic Wry-neck

The spasmodic type of wry-neck occurs most commonly in adults, and is obvious as soon as the patient is examined. Clonic contractions of certain muscles produce jerking motions of the head, which is suddenly and violently pulled over to one side, while the face is rotated towards the opposite side The greater the attention paid to the patient, the more violent do the spasms become. The sterno-mastoid and the trapezius on one side and the posterior rotators of

the opposite side act together, so that the result is a typical torticollis. At first the spasms may be controlled by the patient, but later they are quite involuntary and, indeed, may spread to the facial muscles, the muscles of the mouth, and even to those of the shoulder.

Etiology

The question of etiology is interesting though rather mysterious. Though long considered a neurosis it is now believed to be an expression of some lesion of the basal ganglia. There are various types, and Critchley conveniently relegates them into four groups.

(1) Psychogenic cases. A group where the head movement is a habit spasm or tic, and usually found in younger patients.

(2) Following epidemic encephalitis and with or without a Parkinson syndrome.

(3) As a part of a widespread striatal syndrome it may be seen in progressive chorea, athetosis or other affections of the basal ganglia.

(4) The pre-senile progressive cases occur in middle or later life and form the largest group.

Ocular torticollis is recognized by the presence of abnormal movements of the eyeballs.

Treatment

Sedative drugs and re-educative exercises should be tried, while fixation of the head and neck in a poroplastic jacket may bring some relief though on the whole the results are not encouraging. Surgical measures are carried out in organic cases, and consist of resection of the spinal accessory nerve on one side and of the posterior primary divisions of the first three cervical nerves on the other, often combined with a bone graft in the occipito-cervical space. This has given considerable benefit in many cases, the results being better than those following division of the affected muscles. The author does not advocate operative measures as the results are disappointing.

The Operation. Dandy advocates resection of the sensory and motor roots of the first, second, and third cervical nerves through a high cervical laminectomy in which the laminæ of the upper three vertebræ are removed. He uses a median vertical incision. The spinal accessory nerves are divided intraspinally at the level of the foramen magnum only in order to obtain better exposure of the first cervical motor branch. When this part of the operation is concluded, the patient is turned on his back, the spinal accessory nerves are then exposed and divided through two small incisions in the neck and the central ends doubled back and sutured in this position to prevent regeneration The extra-spinal resection is added lest some of the anterior filaments escape in the intra-spinal operation.

Other forms of wry-neck demand only brief notice. The *acute form* occurs during some infection of the neck, such as infected glands. The

traumatic form follows injury which has resulted in the formation of fibrous tissue with subsequent shortening. A *paralytic form* may develop as a result of division of the spinal accessory nerve during the operation for tuberculous cervical glands.

CONGENITAL RADIO-ULNAR SYNOSTOSIS

In congenital radio-ulnar synostosis one or both forearms are fixed at birth in a position midway between pronation and supination as a result of fusion of the proximal ends of the radius and ulna In some cases the condition is hereditary, and it is equally common in both sexes.

Morbid Anatomy

There are three types of synostosis of the radius and ulna, and the condition may be unilateral or bilateral

In the *true congenital radio-ulnar synostosis*, the upper end of the radius is imperfectly formed, being fused to the ulna for a distance of several centimetres and appears to grow from its upper end The bony union is of an intimate nature, and there is no compact layer intervening between the spongiosa of the radius and that of the ulna The head of the radius may be fairly complete and fused to the ulna, or may be absent. This "headless" type is sometimes classified as a separate variety The shaft of the radius arches forwards more than usual, and is longer and stouter than that of the ulna, suggesting that there has been either some arrest in the growth of the ulna, or stimulation in growth of the radius The lower ends of the bones are almost invariably separate, although Appraille has observed synostosis of the distal ends as well, while Melchior has reported a co-existing Madelung's deformity. Primary synostosis is usually bilateral, in over 80 per cent of the recorded cases both forearms have been affected

In the *second type*, there is a congenital dislocation of an ill formed head of the radius, and the radius and ulna are anchored at some point a short way distal to their upper extremities, usually in the region of the coronoid, by a short, thick, interosseous ligament. The radius is relatively longer and stouter than the ulna, but shows the same curvature as in the primary type Though not a true synostosis there is no trace of movement.

In the *third type*, the head of the radius is present but is unformed and, together with the upper part of the shaft, is fused with the upper end of the ulna

Etiology

Congenital radio-ulnar synostosis is essentially an arrest of development. The radius and ulna develop from a single mass of mesoderm as a pair of separate cartilaginous rods. From about the fifth week, the volar aspect of the developing arm is applied to the trunk, so

that the radial and ulnar cartilaginous rods are in a position midway between pronation and supination. If the normal separation into distinct rods does not occur at the upper part of the developing bones, or if chondrification and later ossification extends across the mesoderm filled interval between their upper ends, a congenital radio-ulnar synostosis develops.



FIG 40—Congenital Superior Radio-ulnar Synostosis

The radiographic appearance of an example of the disease in a boy 8 years old

Hamilton has suggested that the deformity represents a partial reversion to one of the lower types of vertebrate forelimbs, since fusion of the radius and ulna is normally found in bats, camels, and some ungulates

The type of synostosis associated with dislocation of the radial head is the result of some factor which operates at a later period of fœtal life than in the case of the true synostosis. Wilkie believes that in some cases the synostosis may develop after birth, when, owing to increased movement, the periosteum of the two bones is irritated and possibly lacerated at the points where they lie in contact. New bone is, in consequence, laid down. In a case which he reported, the abnormality had not been noted until the child was 5 years old.

Clinical Features

The main feature is fixation of the forearm in a position of mid-pronation Movements of the elbow joint are usually free, although extension may be limited. Wrist movements are often unduly free There is no movement of the radius on the ulna, however, and there appears to be firm osseous union between the bones

In a unilateral case the affected forearm is thinner than its neighbour, and has a curious twisted appearance, due to an alteration in the axis of the principal groups of muscles At the point normally occupied by the head of the radius there may be a well-marked sulcus, owing to the head being displaced backwards or forwards, or being imperfectly developed. The limitation of movement in the forearm is to some extent compensated for by rotation of the humerus, but the palm can never be fully supinated. The functional disability is therefore considerable, although there may be little or no complaint, since the normal use of the hand has never been experienced

Treatment

At first sight, it seems obvious that an operation is indicated. Wilkie, however, points out that the bony bridge is only part of the deformity, and that the soft tissues are not normally developed. He therefore doubts whether surgical intervention should ever be undertaken, an opinion with which the author is in entire agreement. In support of this, it is to be noted that the recorded results of operation are disappointing In the type associated with dislocation of the head of the radius, where the soft parts are more normal, the prospect of helpful intervention is more hopeful, but, in any case, prognosis should be guarded. If the pronation is extreme it can be reduced by osteotomy, but in most cases the disability does not warrant operation.

CONGENITAL ABSENCE OF THE RADIUS

Absence of the radius is a rare developmental error, but important because it is the commonest cause of club-hand, in which the hand

is permanently deviated from the normal axis of the forearm. In rather less than half the cases the deformity is bilateral. The condition is sometimes hereditary; it frequently co-exists with other forms of congenital anomaly, notably harelip, cleft palate, and certain forms of congenital club-foot.

FIG. 41.—Bilateral Congenital Absence of the Radius and Thumb.

The boy writes well and is able to play games with his fellows, and, in spite of a bilateral club foot of slight degree, plays football

ETIOLOGY

The actual etiology is unknown, beyond the fact that it arises at an early stage in the development of the limb bud. Its association with other developmental errors would suggest that the cause is to be found in some inherent abnormality in the developing mesoderm which should form the forearm bones

PATHOLOGY

Usually the whole radius is absent, but occasionally, when the defect is only partial, a small portion of it remains, generally at the upper end. When a small fragment of radius is present the ulna may be fused to it, giving rise to a form of radio-ulnar synostosis The ulna, which may attain a considerable size in many cases, is short, thick, and curved, and the concavity of its curvature is nearly always directed towards the radial side of the forearm.

The carpus often shows associated abnormalities, amongst which may be noted absence of the scaphoid, or fusion of that bone with neighbouring carpal bones. More rarely the lunate is absent.

When the radius is totally absent, the biceps is usually inserted into the lacertus fibrosus, though in some cases the muscle is either completely absent, or fused with the brachialis anterior or the coraco-brachialis. The *brachialis* is absent in about half the number of cases, and when it is present it is usually short and stout, and appears to be a continuation of the short head of the biceps. Occasionally it is continuous with the extensor carpi radialis longus, and the two may be inserted into the ulna. The extensor carpi radialis longus and brevis are frequently absent, or fused with the extensor digitorum communis, while the extensor pollicis longus may also be lacking, or fused with neighbouring tissues. The flexor pollicis longus and the pronator quadratus are rarely present. The radial nerve usually terminates at the elbow, and there is often no radial artery.

Fig. 43.—Congenital Dislocation of both Ulnæ.

Clinical Features

The wrist appears enlarged, and dorsiflexion of the hand is impaired. In severe cases pronation and supination are limited. The wrist is loose, insecure, and irritable. In long-standing cases the lower extremity of the radius is bent or curved forward.

Pressure on the ulna reduces it into line with the radius, but the deformity recurs immediately the pressure is released, owing to the laxity of the ligaments of the lower radioulnar joint.



Fig. 44.—Bilateral Congenital Dislocation of the Ulnæ

Treatment

In recent or acute cases, dorsiflexion of the wrist, maintained by a short plaster case and with a pressure pad over the prominent head of the ulna, offers the best prospect of relief. The plaster should not interfere with the movements at the metacarpo-phalangeal joints.

In cases of longer standing operation is indicated, and may be

directed either to the ligaments or to the bones. Gibson points out that in the traumatic cases the torn triangular fibro-cartilage is the key to the situation. He stitches this into place and puts the hand in a position of dorsiflexion and full pronation. This position is maintained by plaster for about six weeks. Gibson found the swelling to consist of the extensor tendon pushed dorsally through a tear in the deep fascia by the head of the ulna. The dorsal route of exposure gives excellent access.

Osteotomy of the lower end of the radius is recommended by some, the articular surface being rotated backwards into its normal position and the correction maintained by a plaster cast.

Henry Milch has described an operation for the recurrent type

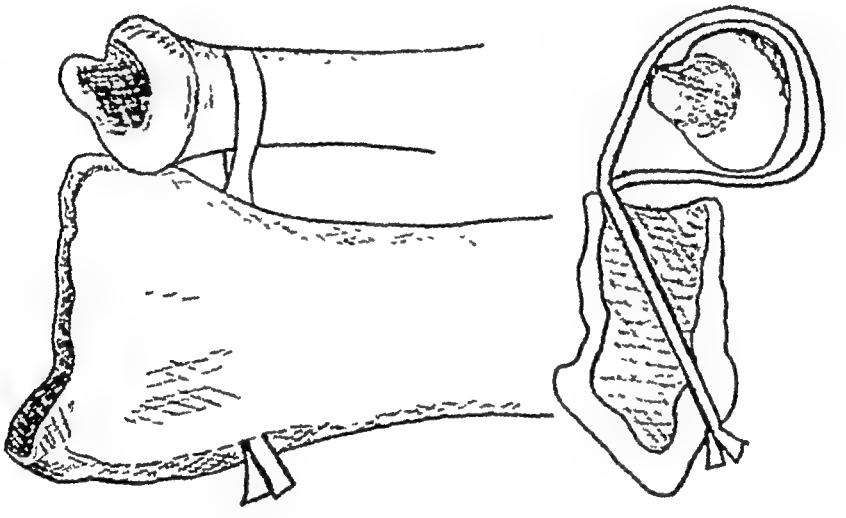

Fig 45.—Operation for Recurrent Dislocation of Ulna

of ulnar dislocation. A strip of fascia is passed around the lower end of the ulna, and then both ends of the fascia are carried through a drill hole in the radius running from the posterior and ulnar aspect forward and laterally to penetrate the outer radial cortex about 3½ centimetres above the radial styloid. He suggests that the anterior and posterior radio-ulnar ligaments should be pleated at the same time.

Darroch advocates the simpler operation of subperiosteal resection of the lower end of the ulna, and this gives as satisfactory a result as the more elaborate procedures.

SYNDACTYLISM

Syndactylism—web fingers or web toes—is a congenital anomaly in which two or more digits of the hand or foot are bound together. It is said to occur in one in every 2,500 births. About twice as many males as females are affected. The defect is produced by an arrest of development before the fingers have become completely separated

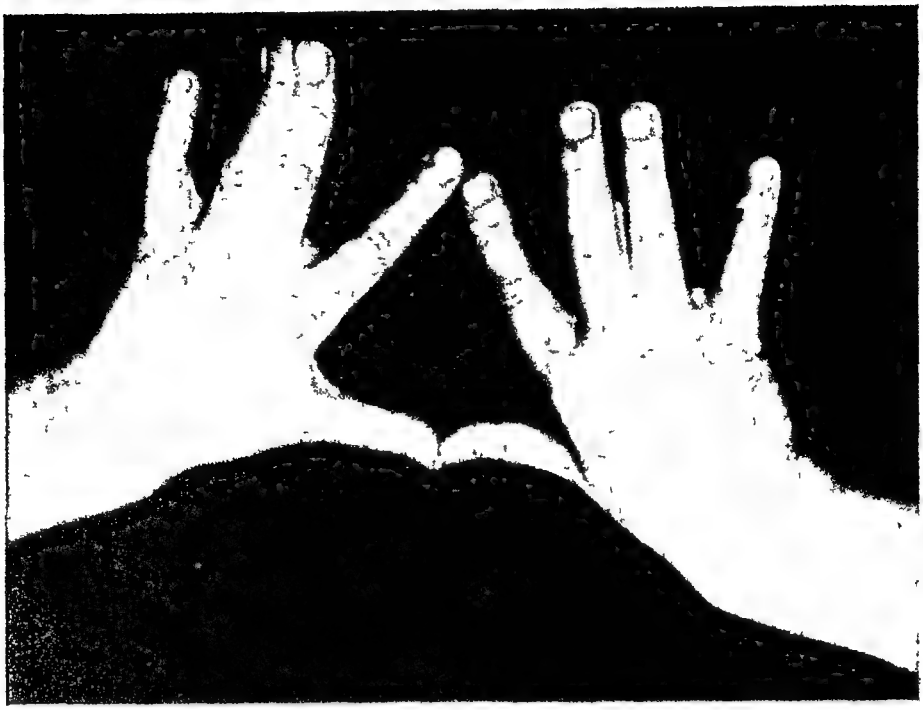

FIG. 46.—Syndactylism of Fingers
Complete degree on left side

FIG 47.—Syndactylism.
The distal phalanges are fused

from one another. In the fœtus the fingers do not grow out from their webs until the seventh week, but as the thumb is differentiated as early as the seventeenth day, it is rarely affected. The tissue connecting the two fingers may vary from a thin diaphragm of skin and subcutaneous tissue to a fusion which includes the bone to a greater or less degree, and in some cases the adjacent finger-nails may coalesce.

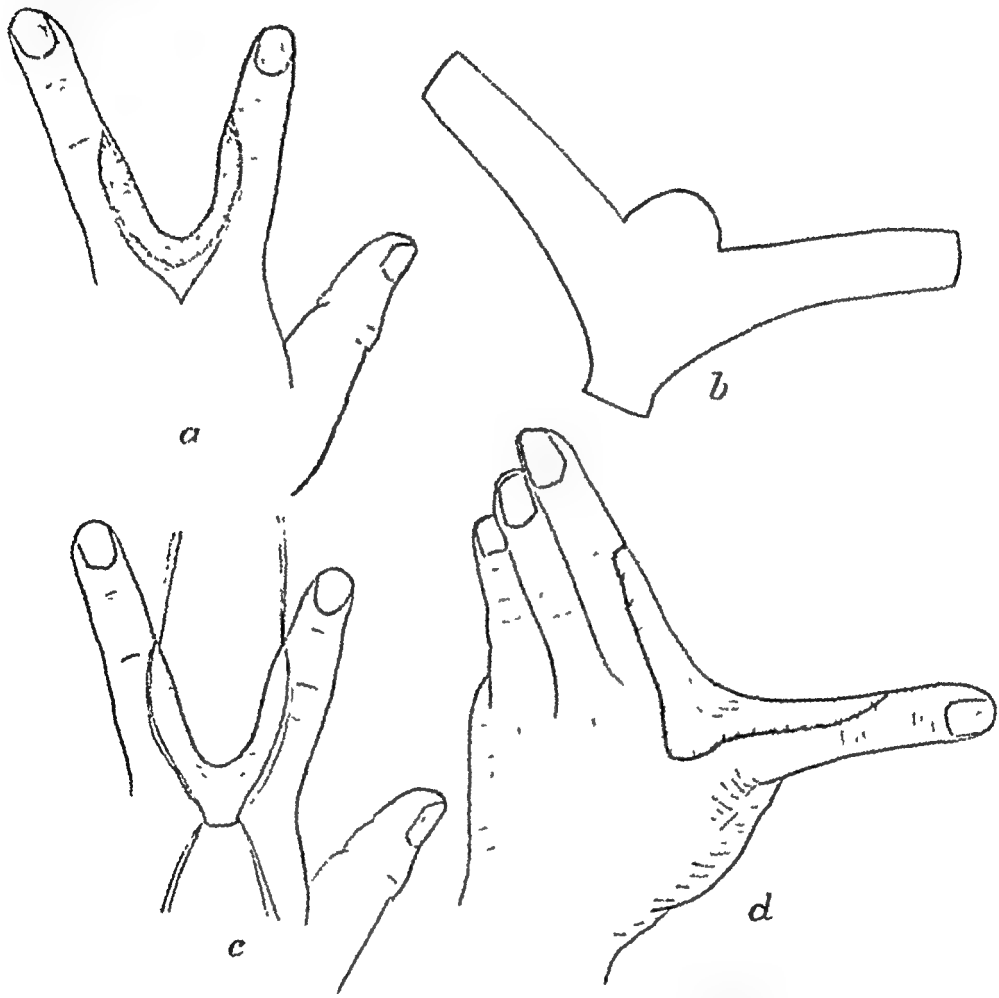

Fig. 48.—Full thickness Skin Graft for Web-fingers.
Stages of Operation described

The fusion may also involve the tendons and digital nerves and sometimes may extend proximally to include the metacarpals and carpal bones. In mild cases its only importance lies in the cosmetic aspect, but when several fingers are involved there may be serious impairment of function of the hand.

Treatment

The age at which to operate is important. Bunnel says that if there is reasonably good function the fingers will develop normally and operation may be delayed until the age of six or more, but not too long as children will develop complexes

SOCUR, R "Congenital Pseudarthrosis of the Tibia," *Rev. Orthop*, Paris, 1946, **32**, 15.

CONGENITAL TALIPES EQUINO-VARUS

BROWNE, DENIS · "Talipes Equino-varus," *Lancet*, Nov 3, 1934, 969.
MERCER, W "Congenital Abnormalities of the Foot," *Practitioner*, 1946, **156**, 88

ARTHROGRYPOSIS MULTIPLEX CONGENITA

LEWIN, P "Arthrogryposis Multiplex Congenita," *Jour Bone and Joint Surg*, 1925, **7**, 630
MIDDLETON, D S . "Studies on Pre-natal Lesions of Striated Muscle as a Cause of Congenital Deformity," *Edin Med Jour.*, July, 1934, 401.

CONGENITAL HIGH SCAPULA

CRITCHLEY, M : "Sprengel's Deformity with Paraplegia," *Brit. Jour Surg.*, 1927, **14**, 243.
ELMSLIE, R C . *Proc Roy Soc Med*, 1925, Orth, **18**, No 8, 25
GREIG, D. M . "Congenital High Scapula," *Edin Med. Jour*, 1924, **31**, 22.

CONGENITAL SHORT NECK

GILLIES, H D · *Proc Roy Soc Med.*, June, 1934, 1008
KLIPPEL et FEIL "Anomalie de la Colonne Vertebrale," *Bull et Mém Soc Anat de Paris*, 1912, **87**, 85

CLEIDO-CRANIAL DYSOSTOSIS

CYRIAX, E F. "A Case of Cleido-Cranial Dysostosis," *Edin Med Jour*, 1923, **30**, 600
FITCHET, S M · "Cleido-cranial Dysostosis Hereditary and Familial," *Jour Bone and Joint Surg*, 1929, **11**, 838
GREIG, D M *Edin Med Jour*, 1916, **16**, 49.

CERVICAL RIB

ADSON and COFFEY *Ann. Surg*, 1927, **85**, 839
LEWIS and PICKERING *Clinical Surgery*, 1933–4, **1**, 354
TELFORD and STOPFORD "The Vascular Complications of Cervical Rib," *Brit Jour Surg*, 1931, **18**, 557

THE SCALENUS SYNDROME

LEARMONTH, J R *Thorax*, 1947, **2**, No 1, 1
MERCER, W. "Brachial Pressure Neuritis," *Edin Med Jour*, 1923, **30**, 650.
OCHSNER GAGE and DE BAKEY "Scalenus Anticus (Naffziger) Syndrome," *Amer Jour Surg*, 1935, **28**, 669
STOPFORD, J S and TELFORD, E D "Compression of the Lower Trunk of the Brachial Plexus by a First Dorsal Rib," *Brit Jour Surg*, 1919, **7**, 168
TELFORD, E D and MOTTERSHEAD, S : *B M J*, 1947, **1**, 325.
WALSHE *et al* *Brain*, 1944, **67**, 141

CONGENITAL WRY-NECK

ADSON, A W, *et al* "Spasmodic Torticollis," *Jour Bone and Joint Surg*, 1946, **28**, 299
DANDY, W E "An Operation for the Treatment of Spasmodic Torticollis," *Arch Surg*, 1930, **20**, 1021
MIDDLETON, D S · "The Pathology of Congenital Torticollis," *Brit Jour Surg*, 1930, **18**, 188

CONGENITAL RADIO-ULNAR SYNOSTOSIS

FAHLSTROM, S "Radio-Ulnar Synostosis," *Jour Bone and Joint Surg*, 1932, **14**, 395.

BIBLIOGRAPHY

The following text-books have been consulted freely:

BEESLEY and JOHNSTON: *Surgical Anatomy*
BRITTAIN, H. A.: *Architectural Principles in Arthrodesis*
BUNNELL, S.: *Surgery of the Hand.*
CAMPBELL, W. C.: *Operative Orthopædics.*
CUNNINGHAM: *Text-book of Anatomy*
GIRDLESTONE, G. R.: *Tuberculosis of Bone and Joint*
ILLINGWORTH and DICK: *Text-book of Surgical Pathology*
STEINDLER: *The Upper Extremity*
,, *Operative Orthopædics*
WHITMAN: *Orthopædic Surgery*

II. CONGENITAL DEFORMITIES

CONGENITAL DISLOCATION OF THE HIP

BADGLEY, C. E.: *Jour. Bone and Joint Surg.*, 1949, **31A**, 341
BROWNE DENIS: *Proc. Roy. Soc. Med.*, 1948, **41**, 388
BRUCE, J.: "Congenital Dislocation of the Hip." University of Edinburgh Thesis for the Syme Fellowship.
COLONNA, P. G.: *Jour. Bone and Joint Surg.*, 1953, **35A**, 179.
GILL, A. B.: *Jour. Bone and Joint Surg.*, 1943, **25A**, 1.
HASS, J.: "Congenital Dislocation of the Hip," 1951. Charles C. Thomas, Illinois.
HILGENREINER: *Ztschr. f. orthop. Chir.*, 1908, **69**, 30.
LE DAMANY, P.: *Ztschr. f. orthop. Chir.*, 1908, **21**, 129.
MERCER, W.: "The Care of the Cripple," *Health Horizon*, April 1950.
MULLER, G. M. and SEDDON, H. J.: *Jour. Bone and Joint Surg.*, 1953, **35B**, 342.
PLATOU, E.: *Jour. Bone and Joint Surg.*, 1953, **35A**, 843.
PONSETI, I.: *Jour. Bone and Joint Surg.*, 1944, **26A**, 775.
SCOTT, J. C.: *Jour. Bone and Joint Surg.*, 1953, **35B**, 372.
,, "Congenital Dislocation of the Hip," British Orthopædic Association Meeting, May 1956.
SOMERVILLE, E. W.: *Jour. Bone and Joint Surg.*, 1953, **35B**, 363 and 568.

CONGENITAL GENU RECURVATUM

MCFARLAND, B. L.: "Congenital Dislocation of the Knee," *Jour. Bone and Joint Surg.*, 1929, **11**, 281.

CONGENITAL ANGULATION OF THE TIBIA

MIDDLETON, D. S.: "Studies on Pre-Natal Lesions of Striated Muscle as a Cause of Congenital Deformity," *Edin. Med. Jour.*, July, 1934, 401.

CONGENITAL PSEUD-ARTHROSIS OF THE TIBIA

HENDERSON, M. S.: "Congenital Pseudarthrosis of the Tibia," *Jour. Bone and Joint Surg.*, 1928, **10**, 483.
MCFARLAND, B. L.: *Brit. Jour. of Surg.*, 1939, **27**, 706.

JANSEN: *Feebleness of Growth*, 1931.
,, *Achondroplasia*
JONES, HUGHES: *Jour Anat*, 1932, **66**, 565.
KNAGGS, R. L. "Achondroplasia," *Brit Jour. Surg*, 1927, **15**, 10.

CHONDRO-OSTEO-DYSTROPHY

BRAILSFORD, J F: *Amer Jour. Surg*, 1929, **7**, 404
MORQUIO. *Archiv. Méd d'Enfants*, 1929, **32**, 129
WRIGHT, DICKSON: *Proc Roy Soc Med*, 1931, **24**, 25

DYSCHONDROPLASIA

BRAILSFORD, J F. *Radiol of Bones and Joints*
HUME, J B. "The Causation of Multiple Exostoses," *Brit. Jour. Surg*, 1929, **17**, 236
HUNTER and WILES: *Brit Jour. Surg.*, 1935, **22**, 507
OLLIER *Bull Soc Chir Lyons*, 1899, **3**, 22

METAPHYSIAL ACLASIS

GREIG, D M: *The Pathology of Bone*, Edinburgh, 1931.
JANSEN: *Robert Jones Birthday Volume*
VOORHAEVE *Acta Radiol*, 1924, **3**, fasc. 5, 407.

POLYOSTOTIC FIBROUS DYSPLASIA

ALBRIGHT, F, *et al* *New Eng Med Jour*, 1937, **216**, 727.
HELFET, A J: *Brit Jour Surg*, 1939–40, **27**, 651
MURRAY, R G., *et al* *Brit Jour. Surg.*, 1946–7, **34**, 48.

MONOSTOTIC FIBROUS DYSPLASIA

SCHLUMBERGER, H G *The Military Surgeon*, 1946, **99/5**, 504

OSTEOGENESIS IMPERFECTA

ALBERS-SCHONBERG. *Arztz*, 1904, **9**, 2
FAIRBANK, H A T. "Some General Diseases of the Skeleton," *Brit. Jour. Surg.*, 1927, **15**, 120
FERRANDU, S: *Chir Org Movim*, 1943, **29**, 271
KNAGGS, R L *Inflammatory and Toxic Diseases of Bone*, Bristol, 1926.

OSTEOPETROSIS

ALBERS-SCHONBERG *Munch med. Wochenschr*, 1904, **51**, 365
BRAILSFORD, J. F: *The Radiology of Bones and Joints*, London, 1934
ELLIS *Proc Roy Soc Med*, 1934, **27**, 1563.
PIRIE *Amer Jour Roent*, 1930, **24**, 147.

RICKETS

ANDERSON *Brit Jour Child Diseases*, 1933, **21**, 194
HARRIS *Bone Growth*
HESS, A amd LEWIS, J M "Clinical Experiences with Irradiated Ergosterol," *J A.M.A*. 1928, **91**, 783
MELLANBY: *M R C Special Reports*, No 61.
SHEERNAN. *J A M A*, 1927, **1**, 24

CÆLIAC RICKETS

HARRIS: *Bone Growth*
PARSONS. *Amer. Jour Dis Children*, 1932, **43**, 1293

RENAL OSTEODYSTROPHY

ASHCROFT, G V.: "Renal Rickets," *Jour Bone and Joint Surg*, 1926, **8**, 279
BROCKMAN, E P.. "Some Observations on the Bone Changes in Renal Rickets," *Brit Jour. Surg*, 1927, **14**, 634

GREIG, D M · *Edin Med Jour.*, 1917, **18**, 281
WILKIE, D. P. D · "Congenital Radio-Ulnar Synostosis,' *Brit Jour. Surg*, 1914, **1**, 366.

CONGENITAL ABSENCE OF RADIUS

KATO, K "Congenital Absence of Radius," *Jour Bone and Joint Surg* 1924, **6**, 589.

MADELUNG'S DEFORMITY

ANDERSON, W. V. · Personal Communication
GREIG, D. M "Congenital Distal Dislocation of the Ulna," *Edin. Med. Jour.*, 1924, **31**, 373
MILCH, HENRY "Dislocation of Inferior End of Ulna,' *Amer Jour. Surg.*, Sept, 1936, N S 1, 141.

SYNDACTYLISM

BUNNELL, S "Surgery of the Hand"
DAVIS, J S and GERMAN, W J . "Syndactylism,' *Arch Surg*, 1930, **21**, 32.
KANAVEL, A. B.: "Malformation of Hands," *Arch. Surg.*, 1932, **25**, 303.

DYSTROPHY OF FIFTH FINGER

THOMAS, A. R : *Lancet*, June 20, 1936, 1412.

III. GENERAL AFFECTIONS OF THE SKELETON

FAIRBANK, H A. T. "Generalized Diseases of the Skeleton,' *Proc Roy Soc Med.*, 1935, **28**, 1611
KNAGGS, R L · *Inflammatory Diseases of Bone*, Bristol, 1926
LERICHE and POLICARD *Normal and Pathological Physiology of Bone*, Paris, 1926
SHEARER, W S *Edin Med Jour*, 1954 **61**, 101

DEVELOPMENT OF BONE

FELL and ROBISON *Biochem Jour*, 1929, **23**, 767
GREIG, D M *Bone Pathology*, Edinburgh, 1931.
HARRIS . *Bone Growth in Health and Disease*, Oxford, 1933
KEITH *Jour Anat*, 1920, **54**, 101
McEWAN *Growth of Bone*, Glasgow, 1912.
ROBISON · *Biochem. Jour*, 1923, **17**, 286.
STUMP · *Jour Anat*, 1925, **59**, 136

OSTEOPOROSIS

ALBRIGHT F Harvey Lecture, 1943, **38**, 123
,, *Ann Intern Med*, 1947, **27**, 861
COOK, A M "Osteoporosis," *Lancet*, 1955, **1**, 877–82 and 929–37.
CUTHBERTSON, D P *Biochem Jour.*, 1930, **24**, 1244.
DEITRICH, J E, WHEDON, G D and SHORR, E *Amer Jour Med*, 1948, **4**, 3
KENYON, C M, KOCH, F. C and LOTWIN, G *Endocrinology*, 1940, **26**, 26.
McLEAN, F C and URIST, M R "Bone . An Introduction to the Physiology of Skeletal Tissue," London, 1955. Cambridge University Press
SISSON, H A *Jour Bone and Joint Surg*, 1952, **34B**, 275
VOGT, J H . *Acta Med Scand.*, 1949, **135**, 221
WEINMANN, J P In *Progress in Clinical Endocrinology*, Ed S Soskin, New York

ACHONDROPLASIA

FAIRBANK, H A. T *Proc Roy Soc. Med*, 1935, **28**, 1611
HARRIS: *Bone Growth in Health and Disease.*

IV AFFECTIONS OF BONES

DOWNES, W G and MCKEOWN, R. M · *Archives of Surgery*, 1932, **25**, 94.
KNAGGS, R L : *The Inflammatory and Toxic Diseases of Bone*, Bristol, 1930
WEINMAN, J P and SICHER, H . *Bone and Bones*, London, 1947.

OSTEOMYELITIS

ALTEMEIER, W. A and HELMSWORTH, J A. *Surg, Gyn and Obst*, 1945, **81**, 138
BAER, W S . "The Treatment of Chronic Osteomyelitis with the Maggot," *Jour Bone and Joint Surg*, 1931, **13**, 438
BUCHMAN and BLAIR . *Archives of Surgery*
FLOREY and FLOREY . "General and Local Administration of Penicillin," *Lancet*, 1943, **1**, 387
HAMILTON, J F "Osteoid Osteoma," *Surg, Gyn and Obst*, 1945, **81**, 465
HENDERSON "Chronic Osteomyelitis associated with Malignancy," *Jour Bone and Joint Surg*, 1936, **18**, 56
MCADAM, I W. J. · *Brit Jour. Surg*, 1945, **33**, 167.
MERCER, W "Acute Hæmatogenous Osteomyelitis," *Postgrad Med J.*, **27**, 327
ORR, H W "The Treatment of Osteomyelitis and other Infected Wounds by Drainage and Rest," *Surg, Gyn, and Obst*, 1927, **45**, 446
PRIGGE, E K *Jour Bone and Joint Surg.*, 1946, **28**, 576
ROBERTSON, D E "Acute Hæmatogenous Osteomyelitis," *Jour Bone and Joint Surg*, 1927, **9**, 8
SEDDON and FLOREY *Lancet*, 1942, **1**, 755
STARR, C L *Archives of Surgery*, 1922, **4**, 567.
WISHNER, J. G · "Chronic Sclerosing Osteomyelitis" (Garies), *Jour Bone and Joint Surg*, 1933, **15**, 723

TUMOURS OF BONE

BAKER, P L, *et al* *Jour Bone and Joint Surg*, 1954, **36A**, 704
BATSON, O V *Ann Surg*, 1940, **112**, 138
BENNISH, E L, *et al* . *So Clin North Amer*, 1953, **35**, 865
BIGNOLD, A C : *Ann Roy Coll Surg.*, 1956, **18**, 28
BLOODGOOD, J *Jour. Bone and Joint Surg*, 1926, **8**, 470, 727
CADE, S *Jour Roy Coll. Surg Ed*, 1955, **1**, 79
EMERSON, K and JESSIEMAN, A G *New Eng Med Jour*, 1956, **254**, 252.
EVANS, R W · "Histological Appearances of Tumours," 1956, Livingstone, Edinburgh
EWING, J "Neoplastic Disease," 1928, Saunders, Philadelphia
FITTS, W. T and RAVDIN, I S *Amer. Jour Surg*, 1953, **85**, 282
GESCHICKTER and COPELAND *Ann Surg.*, 1949, **129**, 724
GREENING, P W *Lancet*, 1956, **1**, 728
LEWIS and MACKENZIE · *Brit Jour Surg.*, 1956, **43**, 380.
MABREY, R E · *Am. Jour Cancer*, 1935, **25**, 501
MACDONALD and BUDD *Surg, Gyn and Obst*, 1943, **77**, 413.
MCWHIRTER, R. · Personal Communication
MORRIS-JONES, H *Brit Jour Surg*, 1953, **41**, 63.
THOMSON, *et al* *Jour. Bone and Joint Surg*, 1955, **37B**, 266

SYPHILITIC DISEASE OF BONE

LEES, DAVID · *Venereal Disease*, Edinburgh, 1931.

V AND VI TUBERCULOSIS OF BONES AND JOINTS

CROFTON, J. : Edinburgh Personal Communication.
GIRDLESTONE, G R · "The Place of Operations for Spinal Fixation in the Treatment of Pott's Disease," *Brit Jour. Surg*, 1923, **10**, 372

CLAIREAUX, A.: *Jour Path. Bact*, 1953, **65**, No. 2, 291, 306
HUNT, F C.. "Renal Infantilism," *Amer. Jour Dis. Child*, **34**, 234.
KELLET, C E *Proc. Roy Soc Med.*, 1928, **22**, 142
PARSONS: *Arch Dis. Child*, 1927, **2**, 1

OSTEOMALACIA

FAIRBANK, H. A T "Some General Diseases of the Skeleton," *Brit Jour. Surg.*, 1927, **15**, 139
MAXWELL, PRESTON. *Proc. Roy Soc Med.*, 1934, **28**, 265.

PARATHYROID OSTEODYSTROPHY

ALBRIGHT, AUB and BAUER "Hyperparathyroidism," *J A M.A.*, 1934, **102**, 1276
DAWSON, J. W and STRUTHERS, J. W · "Generalized Osteitis Fibrosa," *Edin. Med Jour*, 1923, **30**, 421
ELMSLIE, R C *Robert Jones Birthday Volume.*
FAIRBANK, H A. T. · "Some General Diseases of the Skeleton," *Brit Jour. Surg*, 1927, **15**, 120.
HUNTER, D. and TURNBULL · "Hyperparathyroidism: Generalized Osteitis Fibrosa," *Brit Jour. Surg.*, 1931, **19**, 203
STRUTHERS, J. W.. *Edin Med. Jour*, 1933, **40**, 37.
TAYLOR, HERMON. *Brit. Jour. Surg.*, 1935 **22**, 561

ACROMEGALY

CUSHING *Diseases of Pituitary Body*
DOTT and BAILEY: *Brit Jour Surg*, 1925 **13**, 319
KNAGGS, R L.. *Inflammatory and Toxic Diseases of Bone*, Bristol, 1930.

POST-TRAUMATIC OSTEODYSTROPHY

FONTAINE and HERMANN *Annals of Surgery*, 1933, **97**, 26
MIDDLETON and BRUCE *Edin Med Jour*, 1934, **41**, 49
SUDECK · *Arch f Klin Chir.*, 1900, **42**, 147.

MYOSITIS OSSIFICANS PROGRESSIVA

MAIR *Edin Med Jour.*, 1932, **39**, 13.

OSTEITIS DEFORMANS

ALBRIGHT, AUB and BAUER: "Hyperparathyroidism," *J.A.M.A*, 1934, **102**, 1276
ALBRIGHT, *et al.* · *New Eng Med Jour.*, 1944, **231**, 343
GILL, A B · "Bone Metabolism," *Jour. Bone and Joint Surg*, 1936, **18**, 953.
KNAGGS, R L. *Inflammatory and Toxic Disease of Bone*, Bristol, 1926.
MERCER, W and DUTHIE, R B · "Some Observations on the Osteitis Deformans of Paget," *Jour Roy Coll Surgs. Edin*, 1955, **1**, 58.
PAGET *Med Chir Trans London*, 1877, **50**, 37.

INFANTILE CORTICAL HYPEROSTOSIS

CAFFOY, JOHN: *Proc Roy. Soc Med*, 1956, **50**, 347.

RETICULO-ENDOTHELIAL DISTURBANCES

FRASER, J "Skeletal Lipoid Gra. " *Brit Jour Surg*, 1935, **22**, 88.
GAGE "Bone Changes in H. *Brit Jour Radiol*, 1933, **6**, 297.
GOSMAN, M C. "Xanthomato. Jan 9, 1932.
MERCER, W and DUTHIE, R B · ranulomatosis," *Jour. Bone Joint Surg*, 1956, **38B**, 2

KENDALL, E C.. *Proc Mayo Clinic*, 1949, **24**, 298
KERNWEIN and LYON: *Annals of Surgery*, 1942, **115**, 267.
KERSLEY, G. A.· *Amer. Jour. Med. Sc*, 1954, **227**, 503
KINDERSLEY, C E : "The Immobilization Treatment of Rheumatoid Arthritis," *Proc Roy. Soc. Med*, 1935, **29**, 237.
KING, E. J. S . "On Some Aspects of the Pathology of Hypertrophic Charcot's Joints," *Brit Jour. Surg*, 1931, **18**, 113
KUZELL, W. C *J.A.M A.*, 1952, **149**, 729
MCMURRAY, T. P.· Osteo-arthritis of the Hip Joint," *Jour. Bone and Joint Surg*, 1935. **22**, 716
MAGNUSON, P. B : "Debridement in Arthritis," *Jour Bone and Joint Surg*, 1939, **21**, 269.
MERCER, W.· "The Surgery of Rheumatoid Arthritis," *Bull. Hosp for Joint Dis.*, 1954, **15**, 101.
" "Osteoarthritis of the Hip," *Ed Med Jour*, 1951, **58**, 1951
NATHAN, P W : "Acute Osteomyelitis and Arthritis of the Hip," *Surg, Gyn. and Obst*, 1932, **54**, 52
PEMBERTON, R.· *Arthritis and Rheumatoid Conditions.*
" "The Newer Outlook upon Chronic Arthritis," *Surg, Gyn and Obst*, 1932, **54**, 334.
SMITH-PETERSEN, M N . "Treatment of Malum Coxæ by Acetabuloplasty," *Jour. Bone and Joint Surg*, 1936, **18**, 869
" "Cap Arthroplasty of the Hip," *Jour Bone and Joint Surg*, 1939, **21**, 269.
SMYTH, C J. and HUFFMAN, E R : *Med Clin N. Amer*, 1955, **39**, 543
SNORRASON, E.. *Act. Med. Scand*, 1952, **142**, 259.
TALKOV, *et al.* *New Eng. Med. Jour*, 1942, **227**, 395
WATSON-JONES, R : "Arthrodesis of the Hip," *J A M A.*, 1938, **110**, 278
WAUGH, W G · *B M J.*, 1945, **1**, 873.
WILES and BUTTER· *J.A.M A.*, 1930, **94**, 1053.
WILLCOX, *et al* *B M J* 1947, **4501**, 483.
ZINNER, N., *et al* : *Acta Med. Acad Sc. Hung*, 1955, **7**, 217.

IX AFFECTIONS OF THE EPIPHYSES

BERNSTEIN, M. A.· "Osteochondritis Dissecans," *Jour Bone and Joint Surg*, 1925. **7**, 319
BUCHMANN, J.· "A Résumé of the Osteochondritides." *Surg, Gyn and Obst*, 1929, **49**, 447
CALVÉ J. "A Localized Affection of the Spine suggesting Osteochondritis of the Vertebral Body, with the Clinical Aspect of Pott's Disease," *Jour Bone and Joint Surg*, 1925, **7**, 41
GREENWOOD, H H . "The Relation of Tuberculosis to Kohler's Disease," *Brit Jour. Surg*, 1927. **15**, 245
HENDERSON, M. S . "Chronic Osteitis of the Semilunar Bone (Kienbock's Disease)," *Jour Bone and Joint Surg*, 1926, **8**, 504
KEY, J A · "Epiphyseal Coxa Vara or Displacement of the Capital Epiphysis of the Femur in Adolescence," *Jour. Bone and Joint Surg*, 1926, **8**, 53
KIENBOCK, R · "Juvenile Malacia of the Neck of the Femur of Hypophyseal Origin," *Ztschr. f. Orthop Chir*, 1932, **57**, 408
MOFFAT, B W : "Kohler's Disease of the Patella," *Jour Bone and Joint Surg*, 1929, **11**, 579.
MOUCHET, A : "Metatarsal Epiphysitis," *Jour Bone and Joint Surg*, 1929, **11**, 87
PLATT. H : "Pseudo-Coxalgia," *Brit Jour. Surg*, 1921, **9**, 366
SCOTT, J C : "Modern Trends in Orthopædics," 1956, Butterworth, p 246
THOMSON, J. C M *Jour. Bone and Joint Surg.*, 1956, **38A**, 141
WARDLE, E N.· "Etiology and Treatment of Slipped Epiphysis of the Head of the Femur," *Brit Jour Surg*, 1934, **21**, 313.

GIRDLESTONE, G. R. "The Operative Treatment of Pott's Paraplegia," *Brit. Jour Surg* 1931, **19**, 121.
" *Tuberculosis of the Hip*
HENDERSON, M. S. and FORTIN, H. J "Tuberculosis of the Knee Joint in the Adult," *Jour Bone and Joint Surg*, 1927, **9**, 700
MERCER, W. "Treatment of Tuberculous Disease of the Hip Joint," *Edin Med. Jour*, 1929, **36**, 171.
MITCHELL, W. R. D. "Tuberculous Disease of the Ankle and Tarsus," *Brit. Jour. Surg*, 1940, **28**, 71
ROBERTSON LAVALLE. *Bull et Mém Soc. Nat de Chir.*, 1926, **53**, 955.
SEDDON, H. S and STRANGE, F A. S: "Sacro-iliac Tuberculosis," *Brit. Jour Surg*, 1940, **28**, 193
SEDDON, R A. and BUTLER, R W. "Pott's Paraplegia," *Brit. Jour. Surg*, 1935, **22**, 738
SUMMERS, G J. Edinburgh Personal Communication.
THOMAS, D. F. *Lancet* 1950.

VII NON-TUBERCULOUS AFFECTIONS OF JOINTS

COMPERE and ADAMS. "Hypertrophic Pulmonary Arthropathy," *Surg., Gyn. and Obst*, 1935, **61**, 312
GOOBAR, J. P. *Rev. Méd Cordoba* 1954, **42-6**, 177-84
KEY, J A "Hæmophilic Arthritis," *Annals of Surgery*, 1932, **95**, 198.
KING, A J, *et al* *Brit. Jour. Ven Dis.*, 1946, **22**, 1
KLING, D H: "Aspiration of Joint Effusions," *Annals of Surgery*, 1931, **94**, 389
LEES, DAVID: *Venereal Diseases*. Edinburgh, 1931.
MATTINGLEY, S *B M J.*, 1957, **1**, 139
PUTTI, V. and ZANOLI *Chir d. org di movimento*, 1927, **6**, 539
REICH, R S "Purulent Arthritis," *Jour Bone and Joint Surg*, 1928, **10**, 554
TODD, A H. "Syphilitic Arthritis,' *Brit Jour Surg*, 1927, **14**, 260.
YEGG, W B. *Rocky Mountain Med Jour.*, 1955, **52**, 438.

VIII. CHRONIC ARTHRITIS

ADSON, A W. and ROWNTREE, L G. "The Surgical Indications for Sympathetic Ganglionectomy and Trunk Resection in the Treatment of Chronic Arthritis," *Surg, Gyn and Obst*, 1930, **50**, 204
ALLISON, N and COONSE, G. K. "Synovectomy in Chronic Arthritis,' *Archives of Surgery*, 1929, **18**, 824
BARTELS, E. F *Ann Int Med*, 1955, **42**, 1, 10
BRAY, E A and HENCH, P S "Tuberculous Rheumatism," *Jour. Bone and Joint Surg*, 1934, **16**, 839.
CAPENER, N "Modern Trends in Orthopædic Surgery," 1950
CURRIE, J. P. *Lancet*, 1952, **2**, 15
FRYKHOLM, R. *Acta Chir. Scan.*, Suppl 160
GIBSON, A. "The Etiology of Rheumatoid Arthritis," *Jour. Bone and Joint Surg*, 1928, **10**, 747.
GOLDING, F C. "Protrusio Acetabuli," *Brit. Jour Surg*, 1934, **22**, 56
HARRISON, *et al.* *Jour. Bone and Joint Surg*, 1953, **35B**, 598
HARROLD, A J *Jour Bone and Joint Surg.*, 1956, **38B**, 532.
HENCH, P S, *et al*. *Proc. Mayo Clinic*, 1949, **24**, 181
HOLLANDE, *et al*. *J.A M A*, 1945, **129**, 593.
HYBBINETTE, S. "Graber-Duvernay Operation for Chronic Arthritis of the Hip," *Svenska Lakaresallskapets Forhandlinger*, 1935, 288
JUDET, *et al* "Resection-reconstruction of the Hip," *L'Expansion Scientifique Française*.

YOUNT, C. C. . "The Rôle of the Tensor Fasciae Femoris in certain Deformities of the Lower Extremity," *Jour Bone and Joint Surg*, 1926, 8.
,, "An Operation to Improve Function in Quadriceps Paralysis," *Jour. Bone and Joint Surg*, 1938, **20**, 314.

CEREBRAL PALSY

BARNETT . "Orthopædic Surgery in Cerebral Palsy," *J.A M.A*, 1952, **150**, 1396
CAIRNS, SIR HUGH: "Hemispherectomy in the Treatment of Infantile Hemiplegia," *The Lancet*, 1951, Sept. 8, 411
CARLSON . Personal Communication.
COLLIER: *Proc Roy Soc Med*, 1923–4, Neurol. Sect
CROTHERS, B.: "Changes of Pressure inside Fœtal Cranio-vertebral Cavity," *Surg, Gyn. and Obst*, 1923, **37**, 790.
DURHAM, H A. "An Operation to Correct Internal Rotation in Spastic Paralysis," *Jour Bone and Joint Surg*, 1938, **20**, 339.
EGGERS, G. W. N · *Jour Bone and Joint Surg*, 1950, **32A**, 80.
,, *Jour Bone and Joint Surg*, 1952, **34A**, 827
FALCONER, D S · "Two New Mutants, 'Trembler' and 'Reeler,' with Neurological Actions in the House Mouse," *Jour of Genetics*, 1951, **50**, 192.
FORSTER: *Proc Roy Soc Med*, 1911, Surg Sect.
HOLORAN, IRENE M "The Incidence and Prognosis of Cerebral Palsy," *B M J.*, 1952, **1**, 214.
,, "The Employability of Cerebral-Palsied Young People," *The Medical Officer*, 1955, **94**, 337
INGRAM, T. T S · "A Study of Cerebral Palsy in the Childhood Population of Edinburgh," *Arch Dis Childhood*, 1955, **30**, 150
JOSEPHY, H "The Brain in Infantile Cerebral Palsy," *Ill. Med Jour.*, 1947, **91**, 3
KRYNAUW *Jour. Neurol and Neurosurg, Psychiat*, 1950, **13**, 243
PHELPS, W Personal Communication
POLLOCK, G A "The Place of Orth Surg in the Treatment of Cerebral Palsy," Published by The British Council for the Welfare of Spastics. 1955.
PUTNAM, T J. · "Treatment of Athetosis," *Arch. Neurol Psychiat.*, 1933, **29**, 504
ROYLE *Med Jour of Australia*, 1924, **1**,, 77.
,, *Med Jour of Australia*, 1928, **2**, 436
SCAGLIETTI, M O "Le Détachement des muscles gastrocnemieus dans le traitement sanglant du pied équin spastique," Sixieme Congrès International de Chirugie Orthopédique Berne 1954 Imprimerie Lielens Bruxelles, 1955
STOFFEL *A J.O S*, 1912, **10**, 611.

XI AFFECTIONS OF NERVES

ABERCROMBIE, M and JOHNSON, M L · *Jour exp Biol*, 1942, **19**, 266
BALLANCE and DUEL *Arch Otolaryng*, Chicago, 1932, **16**, 1
BONNEY, G *Brain*, 1954, **77**, 588.
BROOKS, D M *Jour Bone and Joint Surg*, 1949, **31B**, 17
DOUPE, *et al* *Jour. Neurol, Neurosurg, and Psychiat*, 1944, **7**, 33
GARLAND, H and MOORHOUSE, D. . "Compressive Lesions of the External Popliteal (Common Peroneal) Nerve," *B M.J*, 1952, Dec. 27, 1373
HENDRY, A M *Jour Bone and Joint Surg*, 1949, **31B**, 42
HUGHES, J. R *Jour Bone and Joint Surg*, 1948, **30B**, 581
KLEINBERG, S "Operation for Obstetrical Paralysis." *J.A M A*, 1932, 98, 294
MERCER, W. "A Splint for Median Paralysis," *B M J*, 3 3 1923
,, "Brachial Pressure Neuritis," *Ed Med Jour*, Dec 1923.
SEDDON, H J "Augogenous Grafts for the Repair of Peripheral Nerves," *Brit. Jour Surg*, 1947, **35**, 151.

X PARALYSIS

Poliomyelitis

BADHAM, J.: *London Med Gaz*, 1834, **15**, 215.
BARR, J G · *Proc. Inter. Polio Congress*, 1949, 211 Lippincott
BLOUNT *Jour. Bone and Joint Surg*, 1949, **31A**, 464
BODIAN, D.: *Amer. J. Hyg*, 1952, **55**, 414.
,, *Proc. Inter Polio. Congress*, p 78
,, *Proc Inter Polio. Congress*, p 62
BRITISH MEDICAL JOURNAL "Maintaining Immunity to Poliomyelitis," Leading Article. 1958, **1**, 1227
BUNNEL, S. *Jour Bone and Joint Surg*, 1938, **20**, 274
CAPENER, N.: "The use of Orthopædic Appliances in the Treatment of Anterior Poliomyelitis," *Post-Grad Med. Jour*, 1949, **25**, 21
CLARK, J M P.. *Brit. Jour Surg*, **34**, 180.
COLMER, G · *Amer Jour Med Science*, 1843, **5**, 248
DICKSON, F D.. "An Additional Report upon an Operation for Stabilizing Paralytic Hips," *Jour. Bone and Joint Surg.*, 1928, **10**, 712.
DUNN, NAUGHTON. "Reconstructive Surgery in Paralytic Deformities of the Leg," *Jour. Bone and Joint Surg.*, 1930, **12**, 299.
,, *On Stabilising Operations on the Foot*, Bristol, 1922
,, *Proc Roy. Soc Med*, 1928, **22**, 243.
ELMSLIE, R. C: "Modern Operative Surgery," 1934 Cassell, London
ENDERS, J F, WELLER, T H and ROBBINS, F. C · *Science*, 1949, **109**, 85.
GREEN, W T. · *Inter Polio Congress*, 1949, 170 Lippincott
GREEN, W. T. and ANDERSON, M *Jour Bone and Joint Surg*, 1947, **29**, 659.
GRICE, D S.: "Extra Articular Arthrodesis of the Subastragalar Joint for Correction of Paralytic Flat Feet in Children," *Jour Bone and Joint Surg*, 1952, **34A**, 927
,, "Further Experience with the Extra Articular Arthrodesis of the Subtalar Joint," *Jour Bone and Joint Surg*, 1955, **37A**, 246
HENDERSON, M S. "Reconstructive Surgery in Paralytic Deformities of the Lower Leg," *Jour. Bone and Joint Surg*, 1929, **11**, 810.
HOKE *Amer Jour Orth Surg*, 1921, **19**, 494
HORSTMANN, D M. and MCCOLLUM: *Science*, 1953, **82**, 434
,, ,, ,, ,, *Proc Soc, Exp. Biol.*, New York, 1952, **79**, 417
IRWIN, C. E. Campbell's "Operative Orthopædics," 2nd Ed, 1949. 1372
JAMES, D J and BRADEN, S. "The Use of Curare in Treatment of Paralysis," *Jour Neurosurg*, 1942, **3**, 74.
KRUSEN, F H · "Observations on the Kenny Treatment of Poliomyelitis," *Proc of Mayo Clinic*, 1942, **17**, No 29
KUHN, W G. (JR) · "The Care and Rehabilitation of Patients with Injuries of Spinal Cord and Cauda Equina, Preliminary Report on 113 Cases," *Jour. Neurosurg*, 1946, **3**, 68
MCDONALD, I B, *et al*: "Anterior Rhizotomy The Accurate Indications of Motor Roots at the Lower End of the Spinal Cord,' *Jour Neurosurg*, 1946, **3**, 421
MITCHELL, G. P · "Deforming factors in Poliomyelitis," *Lancet*, 1952, **2**, 451
,, "Poliomyelitis and Exercise," *Lancet*, 1953, **18**, 90.
RATLIFF, A H. C "The Short Leg in Poliomyelitis," *Jour Bone and Joint Surg*, 1957, **39B**, 4, 781
RITCHIE RUSSELL, W. · "Poliomyelitis," 1952, p 28 Arnold, London.
RUSSELL, W R · *Brit Med Journ*, 1947, **2**, 1023
SCHLESINGER, E B *Lancet*, **66**, 600
VAN HEINE Monograph 1940
WILSON, J L. *Pediatric Clinics on N Amer*, 1953, Vol **1**, No 1A.

The operation is done in two stages. At the first stage a U-shaped flap taken from the dorsum of the hand is turned between the roots of the fingers This flap is turned back on the dorsum and the proxi part of the web divided. The dorsal flap is then pulled through and sutured to the anterior aspect of the root of the finger. The gap between the adjoining aspects of the two fingers is kept open by means of a small glass rod inserted into the aperture and secured in place by a dressing. The rod should remain until the channel heals by granulation tissue; this generally takes five or six weeks.

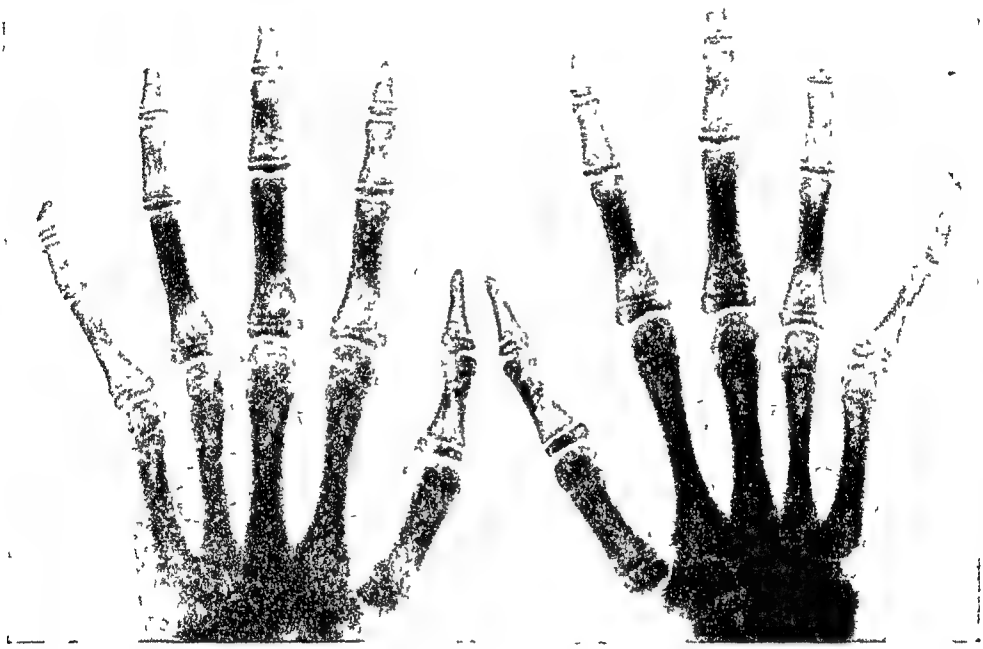

Fig 49 —Dystrophy of little finger

The graft operation as described by Kanavel avoids scars running across the creases of the finger but great care must be taken not to injure the digital nerves and vessels. If more than one interdigital cleft is webbed only one web is dealt with at a sitting, since the vitality of the finger may be jeopardized by injury to the vessels or by bilateral compression of them in the case of skin graft

When free full-thickness skin-grafts are used, the web is divided by an incision which begins one half-inch down the palm from the metacarpo-phalangeal crease, and is carried round to the head of the metacarpal on the dorsum. The edges of the skin are freed, and the fingers widely separated An accurate pattern of the defect is cut from flexible tin foil, and in making it the normal outline of the web should be borne in mind Especially should it be noted that from the flexor surface of the palm the web inclines dorso-proximally to the knuckle and an attempt is made to restore this anatomic conformation,

SEDDON, H. J. . "The Practical Value of Peripheral Nerve Repair," *Proc. Roy. Soc. Med*, 1949, **42**, 427
" "Peripheral Nerve Injuries," M.R.C. Report, 1954.
SLYER: *J. J. Orth. Assoc.*, Aug., 1916.
SLESSOR, A. J.: "Peripheral Nerve Injuries," *Edin. Med. Jour.*, 1951, **13**, 27.
STEINDLER: *Reconstructive Surgery of the Upper Extremity*, 1923. D. Appleton and Co., N.Y.
TINEL: *Nerve Wounds*.
YOUNG, HOLMES and SAUNDERS. "Nerve Regeneration," *Lancet*, 1940, **2**, 128.
ZACHARY, R. B.: "Peripheral Nerve Injuries," M.R.C. Report.

XII. CIRCULATORY DISTURBANCES OF THE EXTREMITIES

BARKER, BROWN and ROTH: "The Effect of Tissue Extract on Intermittent Claudication," *Amer. Jour. Med. Sc.*, 1935, **189**, 36.
BARKER and SLADEN. "Acrocyanosis," *Jour. Nerv. and Ment. Dis.*, 1907, **34**, 745.
BROWN, ALLEN and MAHORNER: *Thrombo-Angiitis Obliterans*, Philadelphia, 1928.
BROWN, G. E.: "Thrombo-Angiitis Obliterans," *Surg., Gyn. and Obst.*, 1934, **58**, 297.
BROWN, G. E. and HENDERSON, M. S.: "Arterial Vascular Disease of the Extremities," *Jour. Bone and Joint Surg.*, 1927, **9**, 613.
BUERGER, L.: *The Circulatory Disturbances of the Extremities*, Philadelphia, 1924.
COHEN, M. B.: "The Intracutaneous Salt Solution Test," *J.A.M.A.*, 1925, **84**, 1561.
HERMAN and REID. "Peripheral Vascular Diseases," *Annals of Surgery*, 1935, **102**, 321.
LASKEY and SILBERT. "Thrombo-Angiitis Obliterans: Relief of Pain by Peripheral Nerve Section," *Annals of Surgery*, 1933, **97**, 60.
LINTON, R. R. and MENENDEZ, C. V.: *Ann. of Surg.*, 1955, **142**, 568.
OSCHNER, A. and DE BAKEY, M.: "Thrombophlebitis," *J.A.M.A.*, 1940, **114**, 117.
" " *Surgery*, 1939, **5**, 491.
POPOFF: "Digital Vascular System," *Arch. Path.*, 1934, **18**, 295.
RATSCHOW, M. *Med. Klin.*, 1954, **49**, 691.
" *Angiology*, 1956, **7**, 61.
ROSS, J. PATERSON: "Sympathectomy and its Indications," *Medical Annual*, 1937, 479.
SCOTT, W. J. M.: *Annals of Surgery*, 1935, **102**, 331.
SCUPHAN, G. W. and TAKATS, G. DE: *Arch. of Int. Med.*, 1935, **56**, 331.

XIII. AFFECTIONS OF THE SPINE

AIRD, IAN: *B.M.J.*, 1955, Nov. 5th, 1110.
ALBEE, F. H.: "Spondylolisthesis," *Jour. Bone and Joint Surg.*, 1927, **9**, 427.
ALLAN, F. G.: *Jour. Bone and Joint Surg.*, 1952, **34B**, 421.
BALF, C. and INGRAM, E. T. S.: *B.M.J.*, 1955, **2**, 163.
BAUWENS, P., *et al.*: *B.M.J.*, 1955, Nov. 10, 1306.
BOSWORTH, D. M.: *Amer. Jour. Surg.*, 1945, **67**, 61.
BRAILSFORD, J. F.: "Deformities of the Lumbo-sacral Region of the Spine," *Brit. Jour. Surg.*, 1929, **16**, 562.
CALVÉ, JACQUES: "A Localized Infection of the Spinal Body," *Jour. Bone and Joint Surg.*, 1925, **7**, 41.
CAPENER, N.: *Brit. Jour. of Surg.*, 1932, **19**, 374.
CYRIAX, JAMES: *B.M.J.*, 1948, **1**, 251.
EGGERS, C. W. N.: *Amer. Acad. Orth. Surg. Lectures*, 1955, **12**, 221.
ELLIOT. *Lancet*, 1946, **1**, 47.

GHORMLEY and KNICKLEY: *Jour. Bone and Joint Surg*, 1944, **26**, 811
GILMOUR, J: "Adolescent Deformities of the Acetabulum," *Brit Jour. Surg*, 1939, **26**, 670.
GURI, J. P: "Pyrogenic Osteomyelitis of the Spine," *Jour Bone and Joint Surg*, 1946, **28**, 29
HELFET, A J.: *Brit. Jour. Surg*, 1940, **27**, 651
HIBBS, R A "A Report of Fifty-nine Cases of Scoliosis Treated by the Fusion Operation," *Jour Bone and Joint Surg.*, 1925, **6**, 3
JAMES, J. I. P: *Jour Bone and Joint Surg.*, 1954, **36B**, 685.
KEDDIE, J T. C.: *Jour. Roy Soc Prom. of Health*, 1955, **75**, 789
KLEINBERG, S. *Scoliosis*, New York, 1926.
,, "The Results of Spine Fusion for Scoliosis," *Jour Bone and Joint Surg.*, 1929, **11**, 66.
LE MESURIER: *Jour Bone and Joint Surg*, 1941, **23**, 521
LEWIN, P "The Galeazzi Treatment of Scoliosis," *Surg, Gyn and Obst*, 1933, **56**, 79.
LOWMAN, C L. "The Relation of the Abdominal Muscles to Paralytic Scoliosis," *Jour Bone and Joint Surg*, 1932, **14**, 165
MERCER, W: "Spondylolisthesis," *Ed. Med Jour*, 1936, **43**, 545
,, "Spondylolisthesis. Suggestions for Treatment," *Amer Jour Surg*, 1939, **43**, 367
,, "Anomalies of the Fifth Lumbar Vertebra," *Liverpool Med-Chi Jour*, 1938, **46**, 38
,, "Low Back Pain of Obscure Origin," *Post-Grad Med Jour.*, Oct 1937
,, "Sacralizaton of the Transverse Process of the Fifth Lumbar Vertebra," Communication to the British Orthopædic Association, 1933
NEWMAN, P H. *Annals of R.C S* Eng, 1955, **16**, 305
O CONNELL, J E A. *Jour Bone and Joint Surg*, 1951, **33B**, 8
PENNYBACKER, JOE: "Sciatica and the Intervertebral Disc," *Lancet*, April 27, 1940, 177
PHELPS, W. M *Clinics*, 1943, **2**, 981
SMITH, *et al.* *Jour Bone and Joint Surg*, 1938, **20**, 823
SMITH-PETERSEN, *et al*: *Jour Bone and Joint Surg*, 1945, **27**, 1
STEINDLER, A: "The Compensation Treatment of Scoliosis" *Jour Bone and Joint Surg* 1929, **11**, 820.
TOURNEY, J W, *et al*. *Jour. Bone and Joint Surg* 1950, **32A**, 249

XIV. AFFECTIONS OF THE SHOULDER JOINT

BANKART A B. "Recurrent Dislocation of the Shoulder," *Brit Jour Surg*, 1939. **26**, 23
,, "Recurrent Dislocation of the Sterno-Clavicular Joint," *Jour Bone and Joint Surg.*, 1939, **26**, 320.
BRAINE, *et al* *Proc Roy Soc Med*, 1948, **41**, 509
BUNNELL, S: "Fascial Graft for Dislocation of Acromio-Clavicular Joint," *Surg., Gyn and Obst*, 1928, **48**, 563
DE PALMA *Bull. Hosp Jt Dis*, 1953, **14**, 35
GILCREEST, E L: "The Common Syndrome of Rupture, Dislocation and Elongation of the long Head of the Biceps," *Surg, Gyn and Obst*, 1934, **58**, 332
HENDERSON, MELVIN: *J.A M A.*, 1930, **95**, 1653
HUGHES, G S R: *Brit. Jour of Surg.*, 1948, **36**, 158
MERCER, W: "Recurrent Dislocation of the Shoulder," *Ed Med Jour*, 1937, **122**.
OSMOND-CLARK, H: *Jour. Bone and Joint Surg*, 1948, **30B**, 20.
OVERPECK, D O and GHORMLEY, R K: "Paralysis of the Serratus Magnus Muscle, *J A M A.*, 1940, **114**, 1994

PARSONAGE and TURNER: *Lancet*, 1948, **1**, 973
SPURLING, R. G.. *Jour. Int. Coll Surg*, 1947, **10**, 502.
TOURNEY and KRAUS: *Jour. Neur. and Psychopath*, 1924, **5**, 115
WATSON-JONES, R. Various communications and articles.

XV. AFFECTIONS OF THE KNEE JOINT

BLAIR, H. G "Rupture of Cruciate Ligaments," *S G.O.*, 1942, **74**, 855
BRANTIGAN, O C and VOSHELL, A. F. "The Mechanics of the Ligaments and Menisci of the Knee Joint," *Jour Bone and Joint Surg.*, 1941, **23**, 44
CAVE, E F. and C. R: *Jour Bone and Joint Surg*, 1950, **32A**, 347.
DAVIES, D V and EDWARDS, A W: "Cysts of Semilunar Cartilages," *Annals R.C.S, Eng.*, 1948, **2**, 142
FAIRBANK, H A. T.: "Osteochondritis Dissecans," *Brit Jour Surg*, 1933, **21**, 67.
FISHER, A G. TIMBRELL. *Internal Derangements of the Knee-Joint*, 1924
FREIBERG, A H.. "Osteochondritis Dissecans," *Jour Bone and Joint Surg*, 1923, **5**, 1
GALLIE, W. E and LE MESURIER, A. B: *Annals of Surgery*, 1927, **75**, 592.
GREEN, W T and BANK, H H. *Jour. Bone and Joint Surg*, 1953, **35A**, 26.
MERCER, W.: "A New Knife for the Removal of the Meniscus," *Jour. Bone and Joint Surg*, 1939, **21**, No 2, 474
,, "Recurrent Dislocation of the Patella," *Ed. Med Jour*, 1937, **123**.
,, "Rupture of External Lateral Ligament," *Ed Med Jour*, 1937, **124**.
ROUILLARD and BOUSSER. "Pellegrini-Stieda's Disease," *Bull et Mém. des Hôp de Paris*, 1931, **47**, 1739
SMILLIE, I S.: "Injuries at the Knee Joint," 1951.

XVI AFFECTIONS OF THE FOOT

GIRDLESTONE, G R: "A New Operation for Hallux Valgus," *Jour Bone and Joint Surg*, 1937, **19**, 30
GRICE, D S 'An Extra-articular Arthrodesis of the Subastragular Joint for Correction of Paralytic Flat Feet in Children," *Jour. Bone and Joint Surg*, 1952, **34A**, 927
,, *Jour Bone and Joint Surg*, 1955, **37A**, 250.
HARRIS, R I. and BEATH, T: *Jour. Bone and Joint Surg*, 1948, **30B**, 624
INGE and FERGUSON "Surgery of Sesamoid Bones," *Archives of Surgery*, 1933, **27**, 466
JACK, E A: "Ætiology of Hallux Rigidus," *Brit Jour Surg*, 1939, **27**, 492
,, "Naviculo-cuneiform Fusion in the Treatment of Flat Foot," *Jour Bone and Joint Surg*, 1953, **35B**, 75.
,, "Bony Anomalies of the Tarsus in Relation to the Peroneal Spastic Flat Foot," *Jour Bone and Joint Surg*, 1954, **36B**, 530
JANSEN, M "March Foot," *Jour. Bone and Joint Surg*, 1926, **8**, 262
JOPLIN, R J.: "Sling Procedure for Correction of Splay Foot, Metatarsus Varus and Hallux Valgus," *Jour Bone and Joint Surg*, 1950, **32A**, 779
LEWIS: "Treatment of Chilblains by Phenoxybenzamine," *Lancet*, 1957, **2**, 1521.
MCBRIDE, E D.: "Conservative Operation for Bunions," *J A.M A.*, 1935, **105**, 1164
MCDOUGALL, A "Footballer's Ankle," *Lancet*, 1955, Dec., 1219
MERCER, W.: "Injuries of the Foot," *Practitioner*, 1931, **127**, 203
OSMOND-CLARK, H: "Congenital Vertical Talus," *Jour Bone and Joint Surg*, 1956, **38B**, 334
PEABODY and MURO: "Congenital Metatarsus Varus," *Jour Bone and Joint Surg*, 1933, **15**, 171
ROSS SMITH, N.: "Hallux Valgus and Rigidus Treated by Arthrodesis of the Metatarso-phalangeal Joint," *B M J*, 1952, Dec. 27th, 1385

STRAUS, F H. . "Marching Fractures of the Metatarsal Bones," *Surg. Gyn. and Obst*, 1932. **54**, 171.
WILES, P : *Med Ann.*, 1956, p 303.

XVII SOME COMPLICATIONS OF TRAUMA

ABBOT, L C and SANDERS, J B. · "Operative Lengthening of the Tibia and Fibula," *Annals of Surg.*, 1939, **110**, 961
BATCHELOR, J. S. · *Proc. Roy Soc Med*. 1945, **38**, 689
BENNETT, G E. : "Lengthening of the Quadriceps Tendon," *Jour Bone and Joint Surg.*, 1922, **4**, 279.
BLOUNT, W R : *Jour. Bone and Joint Surg.*, 1943, **25**, 319.
BOST, F. C and LARSEN, S J. : *Jour. Bone and Joint Surg.*, 1956, 38A, 567
COLONNA, P. C . *Jour. Bone and Joint Surg*, 1937, **19**, 945
GILL, A J : *Jour. Bone and Joint Surg.*, 1939, **21**, 710.
GIRDLESTONE, G. R. . *Tuberculosis of the Hip*, Oxford University Press, 1925.
GRIFFITHS, D L · *Jour. Bone and Joint Surg*, 1948, **30B**, 280
MERCER, W. : "Fractures of the Neck of the Femur," *Ed Med Jour.*, 1940, **47**, 317.
" "Some Complications of a Colles' Fracture," *Jour. C S.M Med Gym*, July 1935
" "Fracture-dislocation of the Talus," *Ed. Med. Jour.*, Aug. 1928.
PATRICK, J · "Un-united Fracture of the Neck of the Femur," *Jour. Bone and Joint Surg*, 1949, **31**, 66
PITMUSTER, D. B. : "Operative Arrest of Longitudinal Bone Growth," *Jour. Bone and Joint Surg.*, 1933, **15**, 1.
SEDDON, H. J. : *Jour. Bone and Joint Surg*, 1956, **38B**, 152.
THOMPSON, F R · *Jour. Bone and Joint Surg*, 1956, **38A**, 13.
THOMSON T. C : *Jour Bone and Joint Surg.*, 1944, **24**, 366.
WHITE, J. W and STUBBINS, C G. . "Growth Arrest for Equalizing Leg Length," *J A.M A*, 1944, **126**, 1146
WILSON, B P and THOMPSON, T. C. · "A Clinical Consideration of the Methods of Equalizing Leg Length," *Annals of Surg*, **1039**, 110, 992

XVIII. MANIPULATIVE SURGERY

BANKHART, A. S B · *Manipulative Surgery*, London, 1932.
MENNELL, J. B. . *Backache*. 1931.
RICHARDSON, A T *Proc Roy Soc Med*, 1956, **50**, 142.
WATSON-JONES, R. : Adhesions of Joints and Injury," *B M.J*, 1936, **1**, 925.

XIX ARTHRODESIS AND ARTHROPLASTY

ALBEE, F. H. : *Annals of Surgery*, 1929, **89**, 404
" "Original Features in Arthroplasty of the Knee with Improved Prognosis," *Surg., Gyn and Obst*, 1938, **47**, 312.
KEY, J. A. : *South. Med Jour.*, 1932, **25**, 909
KUHNS, *et al* · *Jour. Bone and Joint Surg.*, 1953, **35A**, 929
MERCER, WALTER : "Treatment of the Flail Elbow-Joint with a New Operation of Arthrodesis," *Lancet*, 1923, **1**, 796
" Some Orthopædic Problems," *Edin. Med. Jour.*, 1931, **38**, 198
PATTERSON, R. : "Carpo-metacarpal Arthroplasty of the Thumb," *Jour. Bone and Joint Surg*, 1933, **15**, 240.

XX. AFFECTIONS OF SOFT TISSUES

CARP, L. and STOUT, A P. : "A Study of Ganglion," *Surg., Gyn. and Obst*, 1928, **47**, 460.

DICKENSON, M. A : "Snapping Hip," *Amer Jour Surg.*, 1929, 6, 97.
ISELIN, M. : *Surgery of the Hand*, 1940
JONES, E. : "Operative Treatment of Chronic Dislocation of the Peroneal Tendons," *Jour Bone and Joint Surg*, 1932, **14**, 574.
KANAVEL, A B. *Infections of the Hand.*
KANAVEL, KOCH and MASON · "Dupuytren's Contraction," *Surg., Gyn and Obst.*, 1929, **48**, 145
KING, E S J : "The Pathology of Ganglions," *Aus. and New Zealand Jour. Surg*, 1932, **1**, 367.
MERCER, W : "Tennis Elbow," *Practitioner*, 1950, **164**, 293.
,, "Bursitis," *Brit. Encyclop Med. Prac.*, Vol. 3.
,, "Dupuytren's Contraction," *Ibid.*, Vol. 4
SCHNEIDER, C C : "Stenosing Fibrous Tendovaginitis over Radial Styloid (De Quervain)," *Surg, Gyn. and Obst.*, 1928, **46**, 846

INDEX

Abbott and Saunders, on complications of leg-lengthening, 941, operation for leg-lengthening, 942
Abdominal obturator neurectomy, in cerebral palsy, 548
Abduction shoulder splint, in poliomyelitis, 536
Abscess, in tuberculosis of the spine, 287, 297, of the hand, 1030
Absence of radius, congenital, 88
Acetabulum, in congenital dislocation of the hip, 21, intrapelvic protrusion of, 466, "wandering," in tuberculosis of the hip, 342
Achondroplasia, 115
Aclasis, metaphysial, 127
Acrocyanosis, 633
Acromegalic arthritis, 184
Acromegaly, 182
Acromio-clavicular joint, recurrent dislocation of, 781
Acute infective arthritis of infants, 396
Acute spreading infections of the hand, 1018
Acute synovitis of the shoulder joint, 767
Adamantinoma, 262
Adamantine epithelioma, 262
Adams, on congenital talipes equino-varus, 53
Adductor tenotomy, in cerebral palsy, 584
Adhesions, 949, peri-articular, of shoulder joint, 776
Adolescent round back, 741
Adson and Coffey, on cervical rib, 73, 78
Adson and Rowntree, on treatment of rheumatoid arthritis, 433
Aird, on examination of patient in low back pain, 661
Albee, arthrodesis of wrist, 391, on diagnosis of sacro-iliac tuberculosis, 381, on manifestations of joint tuberculosis, 336, on rheumatoid arthritis, 425, on sacro-iliac strain, 680, operation for combined sacro-iliac and low lumbar tuberculosis, 382, for congenital absence of radius, 91, for recurrent dislocation of the patella, 837, in tuberculosis of spine, 329
Albers-Schonberg, disease, 138, on osteopoikilosis, 143
Albright, disease 131, on parathyroid osteodystrophy, 174, 175
Albright and Reitersteen, on osteoporosis, 107
Alkaptonuric arthritis, 474
Allison, on synovectomy in rheumatoid arthritis, 433
Ambulatory treatment in tuberculosis of the spine, 314
Amputation, in osteomyelitis, 225, in vascular disease of the extremities, 656
Amyotonia congenita, 517
Anderson, operation for congenital absence of radius, 91
Anderson and Green, on equalization of the lower limbs, 941
Angio endothelioma, 262
Angio sarcoma, 262
Angulation of tibia, congenital, 50
Ankle, arthrodesis of, 938, 966, aspiration of, 401, bursitis, 987, optimum functional position, 402, tuberculosis of, 374
Ankle, painful conditions of, 891, sprains 891, traumatic arthritis, 891
Anterior rhizotomy, in cerebral palsy, 580
Anterior spina bifida, 760
Anterior spinal decompression operation, 293
Anterior tibial syndrome, 625
Antero-posterior curvature of the spine, 741
Apophyseal articulations, osteoarthritis of, 688
Appiaille, on congenital radio-ulnar synostosis, 86
Aran-Duchenne type of paralysis, 619
Arches of the foot, 854
Arm abduction plasters, 14
Arterial reconstruction, in treatment of vascular disease, 654
Arteriosclerosis, 639
Arthralgia, 411
Arthritis, acute infective of infants, 396, alkaptonuric, 474, chronic, 421, gonococcal, 405, gummatous, 411, hæmophilic, 414, of brucellosis, 420, osteoarthritis, 443, plastic, 411, pneumococcal, 404, pyogenic, 392, rheumatoid, 422, subtaloid, 890, suppurative, of interphalangeal joints, 1029, syphilitic, 409, tertiary syphilitic, 411, traumatic, of the

ankle, 892, tuberculous, 465, villous, 442
Arthrodesis, extra-articular, of shoulder, 385, of subtaloid joint, 555
for the sequelæ of trauma, 964
in infective arthritis, 964, in neuropathic arthritis, 964, in osteoarthritis, 452, in paralysis, 452, in rupture of finger tendons, 1004, in tuberculosis, 963, in tuberculosis of hip, 358, Brittain's method, 361, Hibb's method, 359, in un-united fracture of femoral neck, 932
intra-articular, of shoulder, 967, in tuberculosis of knee joint, 373
naviculo-cuneiform, for flat foot, 871
of ankle, 938, 966, of elbow, 969, Brittain's method, 970, author's method, 969, of first metatarso-phalangeal joint, 878, of hip, 965, of hip, in osteoarthritis, 457, of knee, 965, of sacro-iliac joint, 682, of shoulder, 967, of shoulder, in poliomyelitis, 553, of spine, 970, of wrist, 391, 971
posterior, in spondylolisthesis, 671, author's method, 671
talo-calcaneal, extra-articular, for flat foot, 871
talo-navicular, for flat foot, 871
triple in poliomyelitis, 556
Arthrography, in congenital dislocation of the hip, 37
Arthrogryposis multiplex congenita, 62
Arthropathy, hypertrophic pulmonary, 418, tabetic, 412
Arthroplasty, 972, capsular in congenital dislocation of the hip, 45, indications for, 973, in osteoarthritis, 452, 458, Judet, of hip, 460, modified cup, in un-united fracture of the neck of the femur, 931, of carpo-metacarpal joint, 978, of elbow, 977, of hip, 458, 978, of knee, 979, osteotomy of femoral neck, 434, Smith-Petersen cup method, 458, technical considerations, 975
Arthrotomy, exploratory, in tuberculosis of joints, 338
Aspiration of joints, 6, 399, of ankle, 401, of elbow, 403, of hip, 400, of knee, 401, of shoulder, 402, of tuberculous joints, 340, of wrist, 403
Ataxia, in cerebral palsy, 571
Athetosis, in cerebral palsy, 570
Athlete's foot, 903
Autogenous nerve grafting, 601
Avulsion of the lesser trochanter of the femur, 509
Axhausen, on epiphysitis, 482, on etiology of adolescent kyphosis, 746
Axhausen and Nageotte, on neuropathic joints, 472
Axillary thrombosis, spontaneous, 800
Axonotmesis, 595
Badgely, on congenital dislocation of the hip, 25
Baker, *et al*, on adamantinoma, 263
Ballance and Duel, autogenous nerve grafting, 601
Bankart, method of manipulating the elbow in tennis elbow, 962, operation, for dislocation of the clavicle, 783, for recurrent dislocation of the shoulder, 779
Barham Carter, on anterior tibial syndrome, 625
Barlow's disease, 158
Barr, on prevention of drop-foot in poliomyelitis, 559
Batchelor, operation in un-united fracture of neck of femur, 933, plaster, in congenital dislocation of the hip, 35
Batson, on metastatic tumours of bone, 265
Beadle, on function of spine, 742
Beattie, on etiology of osteitis deformans, 196
Bechterew's disease, 752
Beck, drilling of fragments in non-union of fractures, 921
Benedict, on osteomyelitis, 226
Bennett's operation for lengthening of the quadriceps tendon, 946
Berck tray, in tuberculosis of the hip, 354
Bergmann, on epiphysitis, 481
Beyklirch, on claw foot, 892
Biceps, injuries of, 1004, strain of, 766, rupture of long head of, 788
Biceps brachii, dislocation of, 784
Biotrophic osteoma, 232
Bipartite patella, 832
Blood vessel tumours, 262
Blount, blade-plate fixation osteotomy in un-united fracture of femoral neck, 930, epiphyseal stapling technique, 930, method of stapling for equalization of lower limbs, 941
Blount and Schmidt, Milwaukee brace in scoliosis, 736
Bodian, on etiology of poliomyelitis, 522, 523, 529
Bone, calcification of, 101, enchondral ossification, 103, developmental diseases of, 114, growth of, 104, Haversian systems, 102, necrosis, 111, organic structure of, 100, ossification of, 102, osteoporosis, 107, pathological subperiosteal bone formation, 112, remodelling process, 105, the development of, 98, *et seq*, the rôle of the blood in the development of, 98
Bone block operation, for recurrent dislocation of the shoulder, 780
Bone cavities in osteomyelitis, treatment of, 223
Bone diseases, classification of, 113, cœliac rickets, 160, focal osteitis fibrosa, 131, genu valgum, 156, genu varum, 155, melorheostosis Leri, 142, osteitis deformans, 191, osteitis fibrosa

juvenilis chronica, 131, osteomalacia, 167, osteopathia striata, 143, osteopetrosis, 138, osteopoikilosis, 143, parathyroid osteodystrophy, 171, renal oestodystrophy, 162, rickets, 141, scurvy and scurvy rickets, 158, thyrotoxic osteoporosis, 179
developmental diseases, 114, achondroplasia, 115, chondrodystrophia foetalis, 115, chondro-osteodystrophy, 120, dyschondroplasia, 122, Engelman's disease, 144, generalized osteochondritis, 122, metaphysial aclasis, 127, multiple enchondromata, 126, multiple osteochondritis, 122, osteogenesis imperfecta, 133, osteopetrosis, 138, polyostotic fibrous dysplasia, 131
heterotopic bone formation, 111
metastatic tumours of, 261
myositis ossificans progressiva, 189
necrosis, 111
operations on, in cerebral palsy, 581, in osteomyelitis, 208, *q v*.
pituitary disturbances, 180, acromegaly, 182, cretinism, 181, dwarfism, 180, giantism 182
post-traumatic osteodystrophy at joints, 186
resection of, for shortening of limb, 568
reticulo endothelial disturbances of, 198, histiocytic granulomatosis, 200, Hodgkin's disease, 182, lipoid granulomatosis 200, lympho-granuloma, 199
syphilitic disease of, 268
tuberculosis of, 272. See *Tuberculosis of bone*
tumours of, classification, 229, non-osteogenic, 253
Bone-graft, autogenous, 922, cancellous 925, in non-union of fractures, 922, in un-united fracture of neck of femur, 929, massive inlay, 924
Bone lengthening operation, 941
Bone shortening operation, 944
Bonney, on obstetrical paralysis, 622
Bornholm's disease, 691
Bost and Larsen, method of leg lengthening, 943
Bosworth, on tennis elbow, 993, type of graft in spinal fusion, 715
Bothe, on sympathetic operations in rheumatoid arthritis, 434
Brachial plexus, lesions of, 616, complete plexus syndrome, 617, infra-clavicular lesions, 617, lower arm syndrome, 619, root supply, 617, supra-clavicular lesions, 617, upper arm syndrome, 618
Brackett, exposure of posterior compartment of knee joint, 852
Bragard's sign, in prolapsed intervertebral disc, 707
Brailsford, on articular facets of the 5th lumbar vertebra in low back pain, 664, on chondro osteodystrophy, 120, 122, on etiology of osteitis deformans, 196, on Madelung's formity, 91, on multiple enchondroma, 127, on neuro-pathic joints, 170, on osteopetrosis, 139, 143
Brantigan and Voshel, on anatomy of the knee joint, 806, on functions of the anterior cruciate ligament, 823
Brevicollis, 65
Bristow, on snapping shoulder, 785
Brittain, arthrodesis of ankle, 939, of elbow, 970, of shoulder, 385, of wrist, 972, extra-articular arthrodesis in tuberculosis of hip, 361, multiple graft operation in tuberculosis of spine, 331, on genu valgum, 156, 157, 828, 829
Brittle bones classification of, 133
Brockman, on congenital talipes equino varus, 53, 56, 61, 62, on renal rickets, 165, operation for congenital talipes equino-varus, 59
Brooks, on results of autogenous nerve grafting, 601
Browne, Denis, on club foot, 52, *et seq.*
Bruce, on congenital dislocation of the hip, 23, on post-traumatic osteodystrophy, 187
Brucella spondylitis, 694
Brucellosis, arthritis of, 420
Bryant's triangle, 6
Buerger, exercises in treatment of vascular disease, 645, on thrombo-angiitis obliterans, 638
Bunions, 986 See *Hallux valgus*
Bunnell, incision in Dupuytren's contraction, 999, on syndactylism, 95, on treatment of stenosing tendo-vaginitis at the radial styloid, 1013, operation for paralysis of thumb, 553, pull-out wire method of repair of rupture of extensor pollicis longus, 1006
Burrows, Jackson, on epiphysitis, 481
Bursæ, affections of, 985, bunions, 986, calcaneau, 986, housemaid's knee, 989, kyphotic, 986, miner's elbow, 992, porter's shoulder, 985, student's elbow, 992, tailor's ankle, 985, weaver's bottom, 985, removal of, in hallux valgus, 877
Bursitis, gouty, 987
infectious, 987
of elbow, 992, olecranon, 992, tennis elbow, 993
of foot and ankle, 987
of hip, 990, ischio-gluteal, 992, psoas, 991, trochanteric, 990
of knee, 988, infra-patellar, 989, popliteal, 990, pre-patellar, 989, semimembranosus, 990, sub-crural, 767

of shoulder, 767, sub-acromial, 767, sub-coracoid, 768
syphilitic, 935
traumatic, 986

Cade, on osteosarcoma, 239, 240
Calcanean bursæ, 986
Calcanean spurs, 889
Calcaneo cavus deformity, two-stage fusion for, 561
Calcaneus, epiphysitis of, 494, mal-union of fractures of, 934
Calcification, in development of bone, 101, of the supraspinatus tendon, 772
Caliper, weight-bearing, in poliomyelitis, 536
Calot's jacket, in tuberculosis of the spine, 316
Calvé's disease of the spine, 720
Campbell, operation for drop-foot, 560, for genu recurvatum, 543, of transference of crest of the ilium, 541
Cancellous osteoma, 230
Cannon, on circulation of the extremities, 630
Capener, on cartilage changes in osteoarthritis, 446, on spondylolisthesis, 665
Capsular arthroplasty, in congenital dislocation of the hip, 45
Capsulorrhaphy, in recurrent dislocation of the shoulder, 780
Capsulotomy, posterior, in flexion contraction of the knee, 948
Carbuncular infections of the hand, 1018
Carlson, on cerebral palsy, 575
Carp and Stout, on etiology of ganglia, 983
Carpal bones, osteoporosis of, 509
Carpal tunnel syndrome, 606
Carpo-metacarpal joint, arthroplasty of, 978
Carrell-Dakin treatment of osteomyelitis, 220
Cartilaginous hypertrophy, 241
Cartilaginous loose bodies in joints, 840
Causalgia, 626
Cave, on treatment of chondromalacia in the patella, 834
Cellulitis, dorsal, 1037
Celluloid jacket, in tuberculosis of the spine, 316
Cerebral palsy, 569, *et seq*, atonic form, 571, diagnosis, 574, etiology, 572, mixed type, 572, pathology, 573, prognosis, 577, treatment, 578, non-operative, 578, of deformities in various regions, 582, arm, 582, foot, 586, hip, 583, knee, 585, operative, 580
Cervical intervertebral disc, protrusion of, 790
Cervical rib, 70
Cervical spine, clinical features of tuberculosis of, 302, osteoarthritis of, 797
Cervical sympathetic nerve, lesions of, 619
Chalky bones, 140
Charcot's joints, 412
Charnley, arthrodesis of knee, 966
Cheilotomy, in osteoarthritis, 452
Chemotherapy, in tuberculosis of the spine, 307
Chilblains, chronic, 903
Chondrodystrophia fœtalis, 115
Chondroma, 240, solitary cystic, 241, synovial, 848
Chondromalacia of the patella, 833
Chondromatous osteoclastoma, 252
Chondrosarcoma, 445
Chordoma, 253
Chown, on renal rickets, 166
Chronic arthritis, 421
Circulatory disturbances of the extremities, 629, *et seq*
classification of, 631
methods of investigation, 640
primary obliterative disturbances, 636
arteriosclerosis, 639
embolism and thrombosis, 637
thrombo-angitis obliterans, 637
primary vasomotor lesions, 632
acrocyanosis, 633
erythromelalgia, 634
immersion foot and hand, 635
Raynaud's disease, 632
treatment, 644, amputation, 656, arterial reconstruction, 654, general measures, 644, lumbar ganglionectomy, 651, neurectomy and tenotomy, 655, paravertebral injection, 646, sympathetic denervation, 646, thoracic sympathectomy, 648, thrombo-endarterectomy, 653
Circumflex nerve, lesions of, 615
Clark, operation for congenital flat foot, 856, for transposition of pectoralis major, 551
Clavicle, dislocation of medial end of, 783
Claw foot, 892, Lambrinudi's operation, 896
Claw toe deformity, in poliomyelitis, 546
Cleido-cranial dysostosis, 67
Club-foot, congenital, 52 See *Talipes equino-varus*
Clutton's joints, 410
Coates, Vincent, on rheumatoid arthritis, 432
Cobb, on conditions predisposing to scoliosis, 722, on recumbency in treatment of scoliosis, 734
"Cock-up" wrist splint, in poliomyelitis 536
Codivilla, on congenital pseud-arthrosis of the tibia, 51
Codman, on osteosarcoma, 237, on rupture of supraspinatus tendon, 775, reactive triangle, 236
Cœliac rickets, 160
Coller and Maddock, on skin temperatures, 642
Colonna, on capsular arthroplasty in congenital dislocation of the hip, 45, reconstruction operation, in ununited fracture of neck of femur, 933

since an artificial perpendicular web is unsightly. The graft is taken from a thin and hairless part of the arm or thigh. In cutting the graft, semicircular tongues should be made on it to fit into the incisions prolonged into the palm and on the dorsum (Fig. 48 (a)). To restore the normal dorsal inclination of the web, the two arms of the graft are cut at an obtuse angle (Fig. 48 (b)).

The graft is accurately trimmed and applied with pressure sponges and dressings after the careful technique imperative in free full-thickness skin-grafting, especial care being taken to see that the fingers are adequately separated and the correct pressure applied to the web, to ensure free motion at the metacarpo-phalangeal joint, and the proper dorsal inclination of the web previously mentioned.

The grafts are sutured and held in place by winding the digits with ribbons of paraffin gauze. After covering with Vaseline gauze mild pressure is applied with strips of sponge rubber. Direct application of wax strut may also be used. In either case the fingers are held apart by a suitable moulded lead splint.

DYSTROPHY OF THE FIFTH FINGER

A curious dystrophy of the fifth finger, where there is a lateral curve of the distal phalanx, has been described by Kirner and by Kohler. The condition is often bilateral, is more common in females, and occurs round about the age of 10 The finger appears to be short and the tip curves outwards There is no pain or tenderness, and, in fact, beyond the deformity, there are no symptoms. No cause is known, though A. R. Thomas suggests it is the result of an osteochondritis, since in one case the epiphysis was sclerosed and the bone structure was lost. The author's case was a young girl of 11 with the condition on both sides. There was no evidence of sclerosis or other pathology, and it seems more appropriate to place the condition in the congenital section.

Eden, on cervical rib, 75
Eggers, division of patellar retinaculæ, in cerebral palsy, 581
Elbow, arthrodesis of, 969, arthroplasty of, 977, aspiration of, 403, bursitis of, 992, drainage of, 403, Langenbeck's excision of, 389, manipulation of, 961, Bankart's method in tennis elbow, 962, optimum functional position, 403, tennis, 993, tuberculosis of, 387
Elliot, on fibrositis, 690
Ellis, on osteopetrosis, 141
Elmslie, on calcification of the supraspinatus tendon, 772
Elœsser, on neuropathic joints, 472
Embolism, 637
Enchondroma, single, 241
Enchondromata, multiple, 126, 242
Encysted tuberculosis, 274
Engelman's disease, 144
Enostosis, 230
Eosinophilic granulomatosis, 203
Epicondylalgia, 993
Epicondylitis, 993
Epidermophytosis, 903
Epiphyseal coxa vara, 498
Epiphyseal growth, arrest of, 567
Epiphyseal stapling, 568, as method of correction in scoliosis, 740
Epiphyses, affections of, 479, displaced non-articulating, 840
Epiphysitis, 479, of the calcaneus, 494, 891, vertebral, 495, 746
Erb-Duchenne type of paralysis, 618, 620
Erb's juvenile type of muscular dystrophy, 516
Erysipeloid whitlow, 1020
Erythema pernio, 903
Erythromelalgia, 634
Ewing's tumour, 259
Examination, in congenital dislocation of the hip, 28, *et seq*, in low back pain, 661, of an orthopædic case, 3, *et seq*, radiological, 6
Excision, of fascia, in Dupuytren's contraction, 998, of joint, in osteoarthritis, 452, of limbus, in congenital dislocation of the hip, 40
Exostoses, multiple, 127, removal of, in hallux valgus, 877
Exostosis, 231, irritative, 231
Extensor pollicis longus, rupture of, 1006
Extra-articular arthrodesis of shoulder, 385, of subtaloid joint (Grice), 555

Facio-scapulo-humeral type of muscular dystrophy, 516
Fairbank, on achondroplasia, 119, 122, on congenital coxa vara, 496, 497, 499, on diagnosis of scurvy, 160, on eosinophilic granulomatosis, 203, on gargoylism, 206, on infantile cortical hyperostosis, 198, on melorheostosis, 142, on osteochondritis dissecans, 843, on X-ray appearances in osteitis deformans, 194
Fanconi, on renal osteodystrophy, 164
Farber, on histiocytic granulomatosis, 200
Fell, Miss, on development of bone, 103
Felon, 1021
Felty's syndrome, 442
Femur, avulsion of the lesser trochanter of, 509
head of, in congenital dislocation of the hip, 21
un-united fracture of neck of, 927, arthrodesis, 932, blade-plate fixation osteotomy, 930, bone-graft, 929, Brittain's arthrodesis, 933, Colonna reconstruction operation, 933, combined graft and nail method, 929, Girdlestone pseudarthrosis, 932, McMurray osteotomy, 930, modified cup arthroplasty, 931
Ferguson, method of measurement of curvature in scoliosis, 729
Feyer, operation for congenital absence of radius, 91
Fibrinous loose bodies in joints, 840
Fibrocystic disease, generalized, 171, regional, 131
Fibroma, 246
Fibrosarcoma, 246, periosteal, 253
Fibrositis, 690, secondary, 691
Fibrositis ossificans progressiva, 190
Fibrous dysplasia, monomelic, 131, monostotic, 131, 133, polyostotic, 131
Fibrous loose bodies in joints, 840
Finder, on X-ray appearance in discoid lateral cartilage, 820
Findlay, on rickets, 153
Finger, mallet, 1002, trigger, 1011
Finger web, infection of, 1037
Finsterer's sign, in Kienboch's disease, 511
Fisher, exposure of knee joint, 851, on anatomy of the knee, 803 *et seq*, on loose bodies of joints, 848
Flat foot, 856, acquired, 857, congenital, 856, incipient, 862, mobile, 862, peroneal, 872, rigid, 863, static, 858, spasmodic, 872, voluntary, 863
treatment, 864, contrast foot baths, 866, correction of footwear, 866, electrical treatment, 866, exercises, 867, manipulation, 870, operations, 871, supports, 870
Flat head, 483 See *Osteochondritis deformans coxæ juvenilis*
Flexion contracture of the knee, 947
Flexors of elbow, operation in paralysis of, 551
Foerster, on circulatory disturbances, 630
Foot, affections of, 854, ankle, painful conditions of, 891, arches of, 854, athlete's foot, 903, bursitis, 987, chilblains, 903, claw foot, 892, examination of, 863, flat foot, 856, Freiberg's infraction, 885, hallux rigidus, 879, hallux valgus, 875,

Compact osteoma, 230
Compere, *et al.*, on indications for leg shortening, 943, 944
Congenital coxa vara, 496
Congenital deformities 18 *et seq.*, absence of radius, 88, angulation of tibia, 50, arthrogryposis multiplex congenita, 62, brevicollis, 65, cervical rib 70, cleido-cranial dysostosis, 67, club-foot, 52, dislocation of hip, 19, dislocation of knee, 48, dislocation of shoulder 69, dystrophy of fifth finger, 97, genu recurvatum, 48, high scapula, 63, Klippel-Feil syndrome, 65, Madelung's deformity, 91, myodystrophia fœtalis, 62, 63, primary deformities, 18, pseud-arthrosis of the tibia, 50, radio-ulnar synostosis, 86, scalenus syndrome, 78, secondary deformities, 18, short neck, 65, subluxation of the wrist, 91, syndactylism, 93, talipes equino varus, 52, tibial kyphosis, 50, torticollis, 81 wry-neck, 81
Congenital hypothyroidism, 184
Congenital osteosclerosis, 138
Cook, on osteoporosis, 107
Cope, on lesions of the shoulder joint, 764
Copeland and Geschickter, on chondromatous osteoclastoma, 252
Cordotomy, in cerebral palsy, 580
Costo-transversectomy, in spinal tuberculosis, 292, 321
Cowan, on healing of fractures, 920
Coxa plana, 483 See *Osteochondritis deformans coxæ juvenilis*
Coxa vara, 496, acquired, 497, congenital, 496, epiphyseal, 498
Cretinism, 184
Critchley, classification of spasmodic wry-neck, 85
Crofton, on chemotherapy in tuberculosis of spine, 307
Cruciate ligaments, operation for reconstruction of anterior, 825, for reconstruction of posterior ligament, 826, rupture of, 823
Cruveilhier's sign, in rupture of biceps, 1005
Cuneiform tarsectomy, in congenital talipes equino-varus, 61
Cup arthroplasty, modified, in un-united fracture of neck of femur, 931
Cuthbertson, on ætiology of osteoporosis, 107
Cyriax, on fibrositis, 690, treatment of tennis elbow, 994
Cysts, of semilunar cartilages, 821, of short bones of hands and feet, 243

Dactylitis, syphilitic, 271, tuberculous, 332
Dale, on classification of autonomic nerve endings, 630, on differential diagnosis of vertebra plana, 721
Dandy, operation for spasmodic wry-neck, 85
Darroch, operation for congenital subluxation of wrist, 93
Davis and Edwards, on cysts of the semilunar cartilages, 822
Dawbarn's sign, in sub-acromial bursitis, 768
Débridement, Magnuson's operation in osteoarthritis, 452
Deitrich Whedon and Short, on ætiology of osteoporosis, 107
Deltoid, strain of, 766
Denervation of the hip, in osteoarthritis, 456
De Palma, on peri-articular adhesions of the shoulder joint, 776
Deutschlander, on march foot, 883
Developmental diseases of bone, 114
Diaphysial aclasis, 127
Dickson, combined graft and nail method of treating un-united fracture of the femoral neck, 929, operation for paralysis of gluteus maximus, 549
Discoid lateral cartilage of the knee, 819
Dislocation, acromio-clavicular, 781, of biceps brachii, 784, of hip, congenital, 19, of knee, congenital, 48, of medial end of clavicle, 783, of patella, recurrent, 834, of shoulder, congenital, 69, of shoulder, recurrent, 777
Displacement osteotomy McMurray, of hip, 462
Distal type of muscular dystrophy, 517
Dorsal cellulitis, 1037
Dott, on anterior spinal decompression, 293, on indications for operation in Pott's paralysis, 291, on results of operation for prolapsed intervertebral disc, 719
Doub and Badgley, on X-ray appearances in tuberculosis of the spine, 301
Doupe, on causalgia, 628
Douthwaite, on gold treatment of rheumatoid arthritis, 430
Drilling of bone, in non-union of fractures, 921, in osteoarthritis of the hip, 456
Drop-foot, prevention of, in poliomyelitis, 559, Campbell's operation, 560
Duchenne type of muscular paralysis, 514
Dunn, Naughton, operation for flail foot, 557
Dupont, on osteopetrosis, 141
Dupuytren's contraction, 995
Duthie and Barker, on osteomyelitis, 209
Dwarfism, Fröhlich's adiposo-genital, 181, "Loram" type, 181, pituitary, 180
Dyschondroplasia, 122, hereditary deforming, 127
Dystrophy of the fifth finger, 97

Ecchondroma, 241
Edelstein, on radiological appearances in adolescent kyphosis, 746

classification of, 1014
diffuse synovitis, 1031
infection of the bursæ, 1031
infection of finger web, 1037
infections of palmar spaces, 1034, dorsal cellulitis, 1037, hypothenar space, 1036, retrotendinous central palmar space, 1036, superficial pretendinous central palmar space, 1037, thenar space, 1035
infections of synovial sheaths 1030
tenosynovitis, 1024, of index, middle and ring fingers, 1027, of little finger, 1026, of thumb, 1027, treatment, 1028
treatment, 1038
whitlow, 1015
Hand-Christian-Schuller's disease, 200
Harris, on achondroplasia, 115, 118, on cœliac rickets, 161, on coxa vara, 504, on development of bone, 105, on scurvy, 158 159, on talo-calcanean bridge in congenital flat foot, 857
Harrison, on cartilage changes in osteoarthritis, 445
Hass, on congenital dislocation of the hip, 19, 20, 25, operation for winged scapula, 788
Haversian systems, 102
Heel, painful conditions of, 887
pathological conditions, 890, epiphysitis of the calcaneus, 891, pyogenic infection, 891, tuberculosis of the calcaneus, 891
traumatic disturbances, 887, bursal enlargements, 888, calcanean spurs, 889, plantar fibrositis, 889, subtaloid arthritis, 890
Hemeke, on cleido cranial dysostosis, 68
Helfet, on treatment of malacic diseases of bone, 757
Hemispherectomy in cerebral palsy, 580
Henderson, on incidence of cervical rib, 72
Henderson and Adson, on rheumatoid arthritis, 425
Hendriks, on snapping scapula, 787
Hendry, on treatment of obstetrical paralysis, 622
Heitz, on thyrotoxic osteoporosis, 180
Heterologous osteoma 230
Heterotopic bone formation, 111
Heuter's sign, in rupture of biceps, 1005
Hey, William on internal derangement of the knee, 801
Hibbs, operation, in tuberculosis of the hip, 339, in tuberculosis of the spine, 329
High scapula, congenital, 63
Hilgenreiner's line in congenital dislocation of the hip 30, 31
Hip, arthrodesis of, 359, 457, 965, arthroplasty of, 458, 978, aspiration of, 1001, bursitis of 990, congenital dislocation of, 19, flexion contracture of, 538 Gudlestone arthroplasty of 459, Judet arthroplasty of, 460, optimum functional position, 401, osteoarthritis of, 453, snapping, 1039, tuberculosis of, 341
Hip spica plaster, 14
Histiocytic granulomatosis, 200
Hobo, on osteomyelitis 209
Hodgkins' disease, 199
Hoffa's disease, 831
Horner's syndrome, in paralysis of cervical sympathetic nerve, 619
Horstmann, on etiology of poliomyelitis, 522
Horstmann and McCallum, on etiology of poliomyelitis, 522
Housemaid's knee, 989
Howship's lacunæ, 247
Hughes, on ætiology of spontaneous axillary thrombosis, 801
Hunt, Dame Agnes, treatment of hip flexion contracture, 539
Hunter, on functions of muscle, 695, on parathyroid osteodystrophy, 178, on treatment of osteitis deformans, 197
Hunter and Wiles, on dyschondroplasia, 125
Hydrarthrosis, 411, intermittent 465, symmetrical, 465
Hyperidrosis 902
Hyperostosis, 230, infantile cortical, 197
Hyperpituitary syndromes, 182
Hypertrophic pulmonary arthroplasty, 418
Hypoplasia of the mesenchyme, hereditary, 133
Hypothenar space, infection of, 1036
Hypothyroidism, congenital, 184
Hypotonia, infantile, 517
Hysterical joints, 416

Ilio-femoral methods of extra-articular arthrodesis of the hip, 359
Ilio-tibial band, contraction of in poliomyelitis, 541
Immersion foot 635
Immersion hand, 635
Inequality of length of the lower extremities, 562
leg equalization, 562, leg lengthening, 563
Infantile cortical hyperostosis, 197
Infantile hypotonia, 517
Infantile polyneuritis, 518
Infantile scurvy rickets, 158
Infectious bursitis, 987
Infectious fibrositis, 691
Infiltrating tuberculosis, 274
Infra-patellar bursitis, 989
Infra-patellar pad, affections of, 830
Inge and Ferguson, on fracture of the sesamoid bones, 904
Ingrowing toe nail, 900
Insufflation of oxygen gas, treatment of ischæmia by, 645
Intermittent hydrarthrosis, 465
Intervertebral disc, developmental and

hammer toe, 898, heel, painful conditions of, 887, hyperidrosis, 902, immersion, 835, ingrowing toe-nail, 900, Kohler's disease, 885, manipulation of, 956, march foot, 883, metatarsalgia, 880, metatarsus atavicus, 873, metatarsus brevis, metatarsus primus varus, 873, movements of, 855, onycho-cryptosis, 900, onychogryphosis, 901, peroneal flat foot, 872, sesamoid bones, fracture of, 904, spasmodic flat foot, 872, static disturbances, 854, subungual hæmatoma, 901, subungual exostosis, 902, tendo-calcaneus, shortening of, 897, strain, 862, unstable foot, 856
Footballer's ankle, 892
Fractures, delayed union of, 917
healing of, 110
mal-union of calcaneus, 934, of Pott's fracture, 936
march, 883
non-union of, 918, treatment, 920, bone-grafting, 922, drilling the fragments, 921, mechanical, 920, Sen's operation, 921
of neck of femur, 927
of tibial spine, 829
Fragilitas ossium, 134
Frame reduction of congenital dislocation of the hip, 34
Fraser, on lipoid granulomatosis, 201, on non-tuberculous affections of joints, 399, on rickets, 149, on tuberculosis of bone, 273, 276, on vertebral tuberculosis, 284, 295
Freiberg's infraction, 885
Friedreich's ataxia, 519
Fröhlich's adiposo genital dwarfism, 181
Frozen shoulder, 776
Frykholm, on operative treatment of cervical root pressure, 800
Functional, or postural, scoliosis, 725

Gaenslen's sign, in low back pain, 662
Gage, on Hodgkin's disease, 199
Gait, in congenital dislocation of the hip, 28, in tuberculosis of the spine, 297
Gallie, arthrodesis of sub-taloid joint, 936
Ganglion, 892
Gangrenous whitlow, 1020
Gargoylism, 206
Garland and Moorhouse, on lesions of lateral popliteal nerves, 625
Garré, on sclerosing non-suppurative osteomyelitis, 227
Gaucher's disease, 200
Genu recurvatum, congenital, 48, in poliomyelitis, 543, Campbell's operation for, 453
Genu valgum, 156, 828
Genu varum, 155
Giantism, 182
Gibbon and Landis, on diagnosis of vascular disease, 642
Gibson, on congenital subluxation of wrist, 91, 93
Gilchrist, on reduction of dislocated biceps brachii, 785
Gill, on prognosis of congenital dislocation of the hip, 32, on un-united fracture of the femoral neck, 932
Gilmour, on intrapelvic protrusion of the acetabulum, 467
Girdlestone, arthroplasty of hip, 459, on non-union of fractures, 919, on operative treatment of rheumatoid arthritis, 440, on tuberculosis of bone, 273, on tuberculosis of the knee, 364, on tuberculosis of the vertebral column, 289, 322, pseudarthrosis, in un-united fracture of neck of the femur, 932
Globus pallidus, coagulation of, in cerebral palsy, 581
Gluteus maximus, tendon transference in paralysis of, 547
Gluteus medius, paralysis of, 549
Gold salts, in rheumatoid arthritis, 429
Goldthwaite sign, in low back pain, 662, 680, in sacro-iliac tuberculosis, 380
Gonococcal arthritis, 405
Gout, 475
Gouty bursitis, 987
Graber-Duvernay, on drilling of bone in osteoarthritis of the hip, 456
Graft, Bosworth's posterior spinal, 715
Greig, on congenital dislocation of the shoulder, 70, on development of bone, 104, on metaphysial aclasis, 127, on synovial chondroma, 848
Gree, extra-articular arthrodesis of sub-taloid joint, 555, talo calcaneal extra-articular arthrodesis, 871
Gruber, classification of cervical rib, 71
Gruta, classification of myositis ossificans circumscripta, 912
Guérin, on Dupuytren's contraction, 996
Gummatous arthritis, 411, osteomyelitis, 271

Hæmangioma, 262
Hæmophilic arthritis, 414
Haglund's disease, 888
Hallux rigidus, 879
Hallux valgus, 875
treatment, conservative, 876
treatment, operative, 876, arthrodesis of first metatarsophalangeal joint, 878, excision of proximal half of phalanx, 877, McBride's operation, 878, radical operation, 878, removal of exostoses and bursæ, 877
Hamilton, on congenital radio-ulnar synostosis, 88
Hammer toe, 898
Hand, acute infections of, 1014
abscesses of, 1030

semilunar cartilages, injuries and displacements of, 807, tibial spine, fractures of, 829, Timbrell Fisher's exposure of, 851, tuberculosis of, 364
Knock-knee, treatment of in poliomyelitis, 543
Koch, on treatment of Dupuytren's contracture, 998
Kohler's disease, of the metatarsal head, 885, of the tarsal navicular, 492
Konig, on osteochondritis dissecans, 841
Korvin, on osteochondritis deformans coxæ juvenilis, 485
Kraft, on melorheostosis, 142
Krynauw and Cairns, hemisphereotomy in cerebral palsy, 580
Kuhns, on arthroplasy of the knee, 981
Kummel's disease, 720
Kyphosis in adolescence, 744, Lovett's classification, 745, muscular type, 745, osseous type, 746, true adolescent kyphosis, 746, treatment, 745, 747
Kyphosis in adults, 748, senile osteoporosis of the spine, 754, spondylitis ankylopoietica, 748, spondylosis deformans, 753, spondylosis osteoarthritica, 752, true senile kyphosis, 752, Von Bechterew's disease, 752
summary, 755
treatment, 756
Kyphosis, congenital tibial, 50
Kyphosis, in tuberculosis of the spine, 298
Kyphosis, senile, 741
Kyphotic bursæ, 986

Laguere's sign, in low back pain, 662
Lake, on hallux valgus, 875
Lambrinudi, on adolescent kyphosis, 747, operation for claw foot, 896, operation in paralysis of the foot, 558
Laminectomy and grafting, in spinal tuberculosis, 293, 323
Landouzy and Dejerine, type of muscular dystrophy, 516
Lange, operation for congenital wry-neck, 84
Langenbeck's excision of the elbow joint, 389
Lasegue's sign, in low back pain, 662, in sciatica, 698
Leakey and Silbert, on treatment of vascular disease, 655
Lateral ligaments of the knee, rupture of, 827
Lateral popliteal nerve, lesions of, 624
Learmonth, on operations on nerve lesions, 598
Le Damany, on congenital dislocation of the hip, 24
Leg, canalization, 562, lengthening, 563, 941, shortening, 576, 943
Leg lengthening operation, 941
Leg shortening, Compere on, 943, operation, 944

Legg, on epiphysitis, 480, on osteochondritis deformans coxæ juvenilis, 487, operation for paralysis of gluteus medius, 549
Legg-Calvé-Perthes' disease, 483
Leri, on melorheostosis, 142
Leriche, on neuropathic joints, 472, on post-traumatic osteodystrophy, 188 syndrome in circulatory disturbances of the extremities, 637, 640
Letterer-Siwe disease, 205
Leveuf, on congenital dislocation of the hip, 25
Lewis, on acrocyanosis, 634, on chronic chilblains, 904, on erythromelalgia, 634, on Raynaud's disease, 633
Lewis and Pickering, on cervical rib, 75, on investigation of vascular disease 642
Ligamentum patellæ, rupture of, 1010
Limbus, excision of in congenital dislocation of the hip, 40
Lipoid granulomatosis, 200
Lipoma, 262
Lipoma arborescens, in osteo-arthritis, 444
Lippmann-Cobb, method of measurement of curvature in scoliosis, 729
Lobstein's disease, 133
Loose bodies in joints, 838, acute inflammatory sequestra, 848, cartilaginous, 840, classification of, 839, detached osteophytes in osteoarthritis, 847, in tabes dorsalis, 847, detached portions of articular surface, 841, displaced non-articulating epiphyses, 840, fibrinous, 840, fibrous, 840, necrotic synovium, 840, osteo cartilaginous, 840, osteochondritis dissecans, 841, synovial chondroma, 848, tuberculous sequestra, 848
Looser's zones, in osteomalacia, 171
Loram type of dwarfism, 181
Lordosis, in congenital dislocation of the hip, 28, in tuberculosis of the spine, 298
Lovett, on X-ray changes in rickets, 150
Low back pain, 659, examination of the patient, 661, Laguere's sign in, 662, Gaenslen's sign in, 662, Goldthwaite's sign in, 662
associated with congenital errors, 663, kissing spines, 672, sacralization of the transverse process of the fifth lumbar vertebra, 673, spondylolithesis, 664, sprung back, 673
associated with pathological changes, 688, Brucella spondylitis, 694, fibrositis, 690, marginal polyspondylitis, 688, osteo arthritis, 688, pyogenic osteomyelitis of the spine, 691, spondylosis deformans, 688
associated with static or postural errors, 695
from traumatic causes, 677, injuries of intervertebral joints, ligaments and

degenerative changes, 742, fracture of the cartilage plates, 743, prolapsed, 699, anatomy of, 699, pathology of, 700
Intervertebral joints, ligaments and muscles, injuries of, 686
Intra-articular arthrodesis, of the knee, 373, of the shoulder, 967
Intrapelvic protrusion of the acetabulum, 466
Ischæmia, treatment by insufflation of oxygen gas 645
Ischio-femoral method of extra-articular arthrodesis of the hip, 361
Ischio gluteal bursitis, 992
Iselin, classification of acute infections of the hand, 1014, on course of gangrenous whitlow, 1020, on diffuse synovitis, 1032, on infection of retro-tendinous central palmar space, 1036, on palmar cellular spaces, 1034, on whitlow of first phalangeal space, 1024, of second phalangeal space, 1022, treatment of tenosynovitis 1028

Jacoby, on snapping scapula, 787
Jaffe, on Letterer-Siwe disease, 206
Jaffe and Bodansky, on parathyroid osteodystrophy, 175
Jaffe and Lichenstein, on histiocytic granulomatosis, 200
James, grouping of cases of idiopathic scoliosis, 730, *et seq.*
Jansen, on achondroplasia 118, on march foot, 884, on metaphysial aclasis, 129
Joint debridement in osteo-arthritis, 452
Joint mice, in osteo-arthritis, 444
Joints, acute infections of, 392
acute infective arthritis of infants, 396
aspiration of, 399, ankle, 401, elbow, 403, hip, 400, knee, 401, shoulder, 402, wrist, 403
Charcot s disease, 469
Clutton's joints, 410
drainage of, 400, ankle, 402, elbow, 403, hip, 401, knee, 401, shoulder, 403, wrist, 403
gonococcal, 405
hæmophilic arthritis, 414
hypertrophic pulmonary arthropathy, 418
hysterical, 416
neuropathic, 469
operations on, in cerebral palsy, 581
optimum functional position of, 401, ankle, 401, elbow, 403, hip, 401, knee, 401, shoulder, 403, wrist, 404
plastic arthritis, 411
pneumococcal, 404
pyogenic, 392
syphilis of, 409
tuberculosis of, 335
Jones and Lovett, classification of claw foot, 893, on cartilaginous loose bodies 840, on myositis ossificans circumscripta, 916, on treatment of Pott's paraplegia, 323
Jones, Hughes, on achondroplasia, 117
Jones, Lewis, on cervical rib, 72
Jones, Sir Robert, on tuberculosis of the hip, 343, on X-ray appearances in tuberculosis of the spine, 301
Jones, Wood, on cervical rib, 70
Josephy, on cerebral palsy, 574
Judet, arthroplasty of hip, 460

Kanavel, on infection of retro-tendinous central palmar space, 1036, operation for syndactylism, 96, sign, in tenosynovitis, 1026
Kaplan on hallux valgus, 875
Keith, on metaphysial aclasis, 129
Keller, operation for hallux valgus, 877
Kennon, on osteomyelitis, 214, 216
Keon-Cohen, on stenosing tendo-vaginitis at the radial styloid, 1012
Kersley, on rheumatoid arthritis, 431
Kettle drummer s palsy, 1006
Key, arthrodesis of the knee, 966, classification of coxa vara, 496, on epiphyseal coxa vara, 499, on hæmophilic arthritis, 415
Kienbock's disease, 509
Kindersley, on immobilization in rheumatoid arthritis, 432
King, on cysts of semilunar cartilages, 822, on etiology of ganglia, 983, on neuropathic joints, 470, *et seq*
Kirschner, on march fracture, 884
Kissing spines, 672
Klapp, on tenosynovitis, 1024
Klippel-Feil syndrome, 65
Klumpke's paralysis, 619, 620
Knaggs, on achondroplasia, 117, on acromegaly, 182, on osteitis deformans, 194, 196, on osteogenesis imperfecta, 134, 136
Knee affections of, 802, anatomy of, 802, arthrodesis of, 965, arthroplasty of, 979, aspiration of, 401, bursitis of, 988, congenital dislocation of, 48, cruciate ligaments, rupture of, 823, cysts of semilunar cartilages, 821, discoid lateral cartilage, 819, flexion contracture of, 947, flexion deformity of, 542, genu recurvatum, 48, genu valgum, 156, 828, genu varum, 155, housemaid's, 989, infra-patellar pad, affections of, 830, intermittent hydrarthrosis, 465, fracture of tibial spine, 829, lateral ligaments, rupture of, 827, loose bodies, 838, manipulation of, 957, optimum functional position, 401, osteoarthritis of, 464, osteotomy of, 948, patella, bipartite, 832, patella, habitual dislocation of, 834, Pellegrini-Stieda s disease, 231, problem of the stiff joint, 944, *et seq*,

Phemister, on non-union of fractures, 919, on retardation of growth, in inequality of leg lengths, 940
Pituitary disturbances, 180, dwarfism, 180
Plantar fibrositis, 889
Plantaris tendon, rupture of, 1009
Plaster of Paris, 8, *et seq*, hip spica, 14, Tobruk, 14
Plaster of Paris jacket, in tuberculosis of spine, 315
Plaster of Paris shell, in tuberculosis of spine, 309, posterior, 309, anterior, 310
Plaster sores, 15
Plastic arthritis, 411
Platoŭ, on prognosis of congenital dislocation of the hip, 32
Platt, on cysts of bone, 243, on displaced non-articulating epiphyses, 841, on multiple enchondromata, 243, on osteochondritis deformans coxæ juvenilis, 483, on prognosis in congenital dislocation of the hip, 32, on rupture of tendons, 1001, on solitary cystic enchondroma, 241, on traumatic ulnar neuritis, 608
Pneumococcal arthritis, 404
Poliomyelitis, 521, *et seq*, course of, 524, types of, 524, treatment, 631
of acute stage, 531, of respiratory difficulty, 532
of convalescent stage, 533, apparatus, 536, abduction shoulder splint, 536, below-knee appliances, 537, "cock-up" wrist splint, 536, spinal brace, 537, weight-bearing caliper, 537
of residual stage, 537, contracture of ilio-tibial band, 541, deformities of foot, 545, of hip, 538, of knee, 542, soft tissue contractures, 538
operations to increase stability of a joint, 553, *et seq*
Pollock, George, on cerebral palsy, 569, *et seq*
Polyostotic fibrous dysplasia, 131
Poly-spondylitis marginalis, 753
Polyspondylitis marginalis osteophytica, 688
Poncet, on tuberculous rheumatism, 466
Ponseti, on prognosis in congenital dislocation of the hip, 32
Ponseti and Friedman, grouping of cases of idiopathic scoliosis, 730, *et seq.*
Popliteal bursa, 990
Popoff, digital glomal system, 631
Porter's shoulder, 985
Position, optimum functional of joints, 401, ankle, 401, elbow, 403, hip, 401, knee, 401, shoulder, 403 wrist, 404
Posterior capsulotomy, in flexion contracture of the knee, 948
Post-traumatic osteodystrophy at joints, 186
Post-traumatic para-articular osteoma, 852
Postural exercises in scoliosis, 734
Postural scoliosis, 725
Pott's disease, 284, fracture, mal-union of, 936
Preiser's disease, 509
Pre-patellar bursitis, 989
Primary obliterative disturbances of the extremities, 636, arteriosclerosis, 639, embolism and thrombosis, 637, thrombo-angiitis obliterans, 637
Primary vaso-motor lesions, 632, acro cyanosis, 633, erythromelalgia, 634, Raynaud's disease, 632
Procaine block, in diagnosis of vascular disease, 643
Progressive muscular atrophy, 519
Prolapsed intervertebral disc, 699
Protein replacement in osteomyelitis, 218
Protrusion of cervical intervertebral disc, 790
Pseud-arthrosis, Gridlestone, in un-united fracture of neck of femur, 932, of tibia, congenital, 50
Pseudo-coxalgia, 483
Pseudo-hypertrophic muscular paralysis, 514
Pseudomyxoma, 233
Psoas bursitis, 991
Pulp space infection of the hand, 1021
Purulent blister, 1015
Pyogenic arthritis, 392, purulent type, 393, routes of infection, 392, sero-fibrinous type, 393, serous type, 392, treatment, 395
Pyogenic osteomyelitis of the spine, 691
Pyriford frame, in tuberculosis of the hip, 353

Quadricepsplasty, 946
Quiet hip disease, 483

Radial nerve, lesions of, 610, transplantation of, 612, transposition of, 611
Radiotherapy, for tumours of bone, 267
Radio-ulnar synostosis, congenital, 86
Radius, congenital absence of, 88
Ramisectomy, 649
Ram's horn nail, 901
Ratliff, on inequality of length of the lower extremities, 562, on osteochondritis deformans coxæ juvenilis, 487
Ratschow, on treatment of ischæmia by insufflation of oxygen gas, 646
Rawl, on gold treatment of rheumatoid arthritis, 430
Raynaud's disease, 632
Reaction of degeneration, in affections of nerves, 593
Recklinghausen's disease, unilateral, 131, 171
Rectus femoris, rupture of, 1009
Recurrent dislocation, of the acromio-clavicular joint, 781, of the patella, 834, of the shoulder, 777
Reiter's disease, 441, syndrome, in gonococcal arthritis, 408
Renal dwarfism, 163

muscles, 686, lumbo-sacral strain, 683, sacro iliac strain, 677
referred from other regions, 696
Lower limb plasters, 14
Lumbago 690
Lumbar ganglionectomy, 651
Lumbar spine, clinical features of tuberculosis of, 304
Lumbo-sacral strain, 683
Lunato-malacia, 509
Lymphogranuloma, 199

McAdam, on osteomyelitis, 218
McBride, operation for hallux valgus, 878, "toe to mouth" test for sacro-iliac pain, 680
McDougall, on traumatic arthritis of the ankle, 892
McEwan, on the rôle of the periosteum in the development of bone, 101
McFarland, on congenital high scapula, 65, on congenital pseudarthrosis of the tibia, 52, operation for overlapping fifth toe, 905
McLean and Urist, on osteoporosis, 107
McMurray, displacement osteotomy of the hip, 462, on lesions of the semilunar cartilages, 811, osteotomy in ununited fracture of the femoral neck, 930
McWhirter, on X-ray appearances in osteosarcoma, 238
Madelung's deformity, 91
Maffucci, on dyschondroplasia, 126
Magnuson, joint débridement in osteo arthritis, 452, in rheumatoid arthritis, 441
Main en trident, in achondroplasia, 117
Malignant bone aneurysm, 233
Malignant osteoclastoma, 252
Mallet finger, 1002
Malum coxæ senilis, 453
Manipulation, 949, choice of cases for, 951, contra-indications, 952, in tennis elbow, 962, Mennell on, 961, of individual joints, 956, elbow, 961, foot, 956, hip, 959, knee, 957, shoulder, 961, spine, 959, wrist, 962
Marble bones, 138
March foot, 883
Marginal polyspondylitis, 688
Marie's sign group in hypertrophic pulmonary arthropathy, 418
Martin, on abduction of the shoulder joint, 764, on pyogenic osteomyelitis of the spine, 691
Mau, on myositis ossificans progressiva, 190
Mauck, on operative treatment of injuries of medial collateral ligament of the knee, 828
Maxwell, Preston, on osteomalacia, 168
Medial collateral ligament of the knee, old injuries of, 827, operative treatment, 828
Medial popliteal nerve, lesions of, 626
Median nerve, lesions of, 602
Melchior, on congenital radio-ulnar synostosis, 86
Mellanby, on rickets, 145, 146, 153
Melorheostosis (Leri), 142
Meningocele, 758
Mennell, on manipulation of the shoulder, 961
Mercer, arthrodesis of ankle, 938, of elbow, 969, in spondylolisthesis, 671, treatment of snapping hip, 1040, of tennis elbow, 994
Mercer and Duthie, on etiology of osteitis deformans, 196
Metaphysical aclasis, 127
Metastatic tumours of bone, 264
Metatarsalgia, 880
Metatarsus, affections of the bones and joints of, 873, atavicus, 873, brevis, 873, hypermobile, 874, primus varus, 873
Meyerding, on Dupuytren's contraction, 995
Middleton, on congenital angulation of the tibia, 50, on congenital high scapula, 63, on mechanism of congenital deformity, 62, 63, on post-traumatic osteodystrophy, 187
Milch, operation for congenital subluxation of wrist, 93
Milkman's syndrome in osteomalacia, 171
Mills, on tennis elbow, 994
Milwaukee brace, in scoliosis, 736
Mitchell, George, on poliomyelitis, 721, *et seq*
Mitchell, W R D, on tuberculosis of the ankle, 376
Monomelic flowing hyperostosis, 142
Moore and De Lorimer, on melorheostosis, 142
Morley, on genu valgum, 156
Morquio, on chondro-osteodystrophy, 122
Morton and Scott, on normal vasodilatation level, 642
Mott, on rôle of periosteum in regeneration of bone, 919
Movable periosteal osteoma, 230
Muller and Seddon, on congenital dislocation of the hip, 32, 43
Murphy, on cervical rib, 72, 73
Murray, on heterotopic bone formation, 111
Murray and Selby, on development of bone, 103
Muscles, in congenital dislocation of the hip, 22, 23
injuries of, 1000 *et seq*, rupture of, 1000
operations on, in cerebral palsy, 581
Muscular dystrophies, 514, amyotonia congenita, 517, distal type, 517, facio-scapulo-humeral type, 516, Friedreich's ataxia, 519, infantile hypotonia, 517, juvenile type of Erb, 516, myotonia atrophica, 518, progressive muscular atrophy, 519, peroneal muscular atrophy, 520

Short leg, the problem of the, 939
Short neck, congenital, 65
Shoulder, affections of, 763, arthrodesis of, 553, 967, aspiration of, 402, bursitis of, 767, 992, calcification of supraspinatus tendon, 772, congenital dislocation of, 69, dislocation of acromio-clavicular joint, recurrent, 781, dislocation of biceps, 784, dislocation of medial end of clavicle, 783, dislocation, recurrent, 777, drainage of, 402, manipulation of, 961, muscular strains, 765, biceps, 766, deltoid, 766, rotators, 767, supraspinatus, 766, neuralgic amyotrophy, 789, osteo-arthritis of cervical spine, 797, peri-articular adhesions, 776, porter's shoulder, 985, protrusion of cervical intervertebral disc, 790, rupture of long head of biceps, 766, snapping scapula, 786, snapping shoulder, 785, spontaneous axillary thrombosis, 800, sprain, 765, Sprengel's shoulder, 63, supraspinatus tendon, lesions of, 770, synovitis, 767, tuberculosis of, 383, winged scapula, 787
Shoulder girdle syndrome, 789
Sign, Brogard's, in prolapsed intervertebral disc, 707, Cruveilhier's, in rupture of biceps, 1005, Dawbarn's, in subacromial bursitis, 768, Gaenslen's, in low back pain, 662, Goldthwaite's, in low back pain, 662, 680, Heuter's, in rupture of biceps, 1005, Kanavel's, in tenosynovitis, 1026, Laguerre's, in low back pain, 662, Lasegue's, in low back pain, 662, in sciatica, 698, Pagenstecher's, in rupture of biceps, 1005, Tchirkin's, in spondylolisthesis, 668, Tinel's, in affections of nerves, 593, Trendelenburg's, in congenital dislocation of the hip, 29, tripod, in poliomyelitis, 530, Ullman's, in spondylolisthesis, 669
Sissons, on osteoporosis, 107, 108
Slessor, on causalgia, 628
Smillie, method of inter-metacarpal fusion, 606, on contra-indications to manipulation of the knee, 946, on lesions of semilunar cartilages, 807, 819, on location of adhesions in the knee joint, 945, on treatment of osteochondritis dissecans, 847
Smith and Jones, on fractures of the tibial spine, 829
Smith-Petersen, arthrodesis of sacro-iliac joint, 682, on differential diagnosis in lumbo sacral strain, 685, treatment of rheumatoid arthritis of the hip, 440
Smithwick, on methods of thoracic sympathectomy, 648
Smithwick and White, on treatment of vascular disease, 656
Smyth and Huffman, on gout, 475
Snapping hip, 1039
Snapping scapula, 786
Snapping shoulder, 785
Socin, on congenital pseudarthrosis of the tibia, 52
Soft tissues, affections of, 982, *et seq*
Solitary cystic chondroma, 241
Somerville, on congenital dislocation of the hip, 25, 27, 40
Sorell, Mme, on treatment of paralysis in tuberculosis of the spine, 322
Soto-Hall, on treatment of neuropathic joints, 474
Soutter, operation for flexion contracture of the hip, 539
Spasmodic flat foot, 872
Spasmodic wry neck, 84
Spina bifida, 757
Spina bifida occulta, 759
Spina ventosa, 332
Spinal caries, 284
Spine, affections of, 659, antero-posterior curvature of, 741, arthrodesis of, 970, kissing spines, 672, Kummel's disease, 720, kyphosis in adolescence, 744, low back pain, 659, lumbo-sacral strain, 683, manipulation of, 959, osteoarthritis of, 688, osteotomy of, 751 prolapsed intervertebral disc, 699, pyogenic osteomyelitis of the spine, 691, sacralization of the transverse process of the fifth lumbar vertebra, 673, sacro iliac strain, 677, sciatica, 697, scoliosis, 721, spina bifida, 757, spondylitis ankylopoietica, 749, spondylolisthesis, 664, spondylosis deformans, 753, spondylosis osteo arthritica, 752, spring back, 673, vertebra plana, 720
Splint, Denis Browne, in club foot, 57, Forrester-Brown, in congenital dislocation of the hip, 33, 34, Putti, on congenital dislocation of the hip, 33
Spondylitis ankylopoietica, 748
Spondylitis brucella, 694
Spondylitis deformans, 741
Spondylolisthesis, 664, Tchirkin's sign in, 668, Ullman's sign in, 669
treatment, 670, author's method, 671, posterior arthrodesis, 671
Spondylosis deformans, 688, 753
Spondylosis ossificans ligamentosa, 688
Spondylosis osteo arthritica, 752
Spontaneous axillary thrombosis, 800
Spotted bones, 143
Sprain of the ankle, 891
Sprain of the shoulder joint, 765
Sprengel's shoulder, 63
Stapling, epiphyseal, 568, in scoliosis, 740
Starr, on osteomyelitis, 211, 219
Static flat foot, 858
Steindler, on cleido-cranial dysostosis, 69, on obstetrical paralysis, 620, opera-

Renal osteodystrophy, 162
Renal rickets, 162
Resection of head and neck, in rheumatoid arthritis of the hip, 979
Resection-reconstruction of hip (Judet), 460
Reticulo endothelial disturbances of bone, 198
Reticulum-cell sarcoma, 261
Retro-tendinous central palmar space, infection of, 1036
Rheumatic fibrositis, 691
Rheumatism, tuberculous, 465
Rheumatoid arthritis, 422
Rhizotomy, anterior, in cerebral palsy, 580
Rib resection, in scoliosis, 740
Rickets, 144, annular, 134, cœliac, 160, renal, 162, scurvy, 158
Rider's bone, 112, 231
Risser, on iliac apophysis, 736, turnbuckle plaster in scoliosis, 737
Ritchie, method of testing muscles, 594
Ritchie Russell, on etiology of poliomyelitis, 523, on respiratory involvement in poliomyelitis, 533
Ritter, on osteochondritis of upper end of the tibia, 492
Roaf, on wedge resection in scoliosis, 740
Rob, on arterial reconstruction in vascular disease, 654
Roberts, on bone defect in spondylolisthesis, 665, on X-ray examination in low back pain, 662
Roberts and Cohen, on osteitis deformans, 192
Robertson, on osteopetrosis, 141
Roofe, on prolapsed intervertebral disc, 700
Root section, in treatment of vascular disease, 649
Ross Smith, operation to arthrodese the first metatarso-phalangeal joint, 878
Roth, on bursal enlargements of the heel, 888
Round shoulders, 744
Royle, operation in paralysis of the thumb, 552
Rupture, of long head of the biceps, 766, of muscles, 1000, of supraspinatus tendon, 774, of tendons, 1001

Sacralization of the transverse process of the fifth lumbar vertebra, 673, treatment, 676
Sacro-iliac joint, arthrodesis of, 682, manipulation of, 682, strain of, 677, tuberculosis of, 379
Salk vaccine, in prophylaxis of poliomyelitis, 531
Sarcoma, reticulum-cell, 261
Sargent, on cervical rib, 73
Scaglietti and Silverskiold, operation for pes equinus in cerebral palsy, 587
Scalenus syndrome, 78
Scapula, congenital high, 63, snapping, 786, winged, 787
Schanz, osteotomy in congenital dislocation of the hip, 47
Scheuermann's disease, 746
Schlesinger, on muscle spasm in poliomyelitis, 529
Schlumberger, on monostotic fibrous dysplasia, 133
Schmidt, on osteochondritis deformans coxæ juvenilis, 487
Schmorl, on adolescent kyphosis, 747, on intervertebral discs, 742, 743, on osteopoikilosis, 143, on spondylosis deformans, 754, on true senile kyphosis, 752
Schoemaker's line, 6
Sciatica, 697
Sciatic nerve, lesions of, 624
Sclerosing non-suppurative osteomyelitis, 227
Sclerosing sarcoma, 234
Scoliosis, 721, examination of the patient, 727, postural, 725, prognosis, 730, structural 726
treatment, 733
conservative, 734
operative, 736, epiphyseal stapling, 740, excision of hemivertebra, 740, internal jack method, 740, rib resection, 740, wedge resection, 740
in tuberculosis of the spine, 298
Scott, on congenital dislocation of the hip 40
Scurvy, 158
Scurvy rickets, 158
Sectional plasters, 13
Seddon, on paraplegia in tuberculosis of the vertebral column, 289, on syndrome of interruption in nerve lesions, 594, on Volkmann's ischæmic contracture, 907, 908, 911
Semilunar cartilages, lesions of, 807, cysts of, 821, displaced lateral cartilage, 819, displaced medial cartilage, 809, diagnosis, 812, treatment, 815 lateral semilunar cartilage injuries, 819
Semimembranosus bursitis, 990
Sen, step-up operation for non-union of fractures, 921
Senile kyphosis, 741, true, 752
Senile osteoporosis of the spine, 754
Sequestra, acute inflammatory, 848, removal of, in osteomyelitis, 222, tuberculous, 848
Seigling, on osteomyelitis, 225
Sesamoid bones of the great toe, fracture of, 904
Sever, on obstetrical paralysis, 620, operation for, 622
Shearer, on general affections of the skeleton, 114
Shelf reconstruction operation, in congenital dislocation of the hip, 44
Shepherd, Mrs, on results of arthroplasty, 979
Shore and Fletcher, on varieties of osteoarthritis of the spine, 688

CHAPTER III

GENERAL AFFECTIONS OF THE SKELETON

Our knowledge of bone and its pathology has been extensively added to during the last few years, but despite this, it cannot yet be said that the mechanism of abnormalities in bone structure, and of the response of bone to harmful agents is completely understood. Formerly its structure was considered stable to a marked degree. Indeed, with it was associated a conception of a constancy of form and structure above all other tissues Perhaps the most significant addition to modern knowledge of bone, in sharp contrast to former views, is the realization that bone is a structure of extraordinary instability and sensitivity. Thus it is now appreciated that the osseous tissues are huge reservoirs of the all-important element, calcium, and that the calcium content is constantly altering in response to innumerable stimuli. In addition it is regarded as a connective tissue impregnated with lime to give it durability, it is usually taken that bone acts the part of a scaffolding on which the soft tissues of the body are clothed; and it serves to protect the vital structures it encases and affords leverage for the muscular system

Of no less interest is the response of bone to fluctuations in its blood supply and to alterations in hormonal activity, the place it occupies in the reticulo-endothelial system, and the exact method of its development, growth and maintenance A proper understanding of these important questions demands some description of the normal development and physiology of bone

Bone consists of organic and inorganic materials. The organic materials are the proteins and fats, etc, which make up the structure of the cells and intercellular substances The inorganic matter consists in the main of calcium, phosphate and carbonate

The Role of the Blood in Bone Formation.

An adequate supply of calcium, phosphorus, magnesium, and other elements is necessary for the normal metabolism of bone. These elements are brought to the bones by the blood serum, which may be viewed as a saturated solution of calcium and phosphorus in a balanced ratio of ten units of the former to four of the latter.

Calcium, phosphates and carbonates, the main constituents of the inorganic part of bone, are present in the blood in various forms, and to understand bone physiology it is necessary to have a clear picture of these substances in solution.

tion for claw foot, 869, for contracture of plantar fascia, 544, of flexor transposition in paralysis of elbow, 551, test, in low back pain, 868
Stenosing tendo-vaginitis at the radial styloid, 1012
Step-up operation of Sen, in non-union of fractures, 921
Still's disease, 421, 441
Stirling, on complications of Osgood Schlatter disease, 491
Stoffel, operation for wrist flexion in cerebral palsy, 582
Stopford, on scalenus syndrome, 80
Structural scoliosis, 726
Struthers, on parathyroid osteodystrophy, 171
Stump, on the development of bone 101
Subacromial bursitis, 767
Subaponeurotic bursæ, 986
Sub-coracoid bursitis, 768
Sub-crural bursitis, 990
Subcutaneous cellular tissue of hand, infections of, 1021
Subcutaneous fasciotomy, in Dupuytren's contraction, 998
Subcuticular infections of the hand, 1015
Sub-deltoid bursitis 767
Sub-gluteal bursa, 990
Subluxation of the wrist, congenital, 91
Sub-periosteal resection in osteomyelitis, 221
Sub-taloid arthritis, traumatic, 890
Sub-taloid joint extra-articular arthrodesis of, 555
Subungual exostosis, 902
Subungual hæmatoma 901
Sudeck's atrophy, 186
Sulphonamides, in osteomyelitis, 218
Superficial pre-tendinous central palmar space, infection of, 1037
Supraspinatus tendon, lesions of, 770, calcification, 772, rupture, 774, incomplete, 773, operation for, 776, tendinitis, 771
Sympathetic denervation, in post-traumatic osteodystrophy, 188
in vascular lesions of the extremities, 646
Sympathetic system, operations on in rheumatoid arthritis, 434
Syndactylism, 93
Synostosis, congenital radio-ulnar, 86
Synovectomy, in rheumatoid arthritis, 433
Synovial chondroma, 848
Synovial sheath, infection of, 1024, 1030
Synovitis, acute, of the shoulder joint, 767
Syphilis of joints, 409, arthralgia, 411, classification, 409, Clutton's joints, 410, gummatous arthritis, 411, hydrarthrosis, 411, Parrot's syphilitic osteochrondritis, 410, plastic arthritis, 411, symmetrical hydrarthrosis, 410, tertiary syphilitic arthritis, 411, Todd's classification, 413
Syphilitic arthritis, tertiary, 411
Syphilitic bursitis, 987
Syphilitic disease of bone, 268, dactylitis, 271, inflammation at the epiphyseal line, 270
Syringomyelia, 520
Syringo-myelocele, 759

Tabetic arthropathy, 412
Tailor's ankle, 985
Talipes calcaneus, in poliomyelitis, 546
Talipes equino-varus, congenital, 52
arthrogryposis multiplex congenita, 62
Brockman's operation, 59
cuneiform tarsectomy, 61
idiopathic type, 52
muscular type, 61
myodystrophia fœtalis, 62
osseous type, 62
Talipes equinus, in poliomyelitis, 546
Talipes valgus, in poliomyelitis, 545
Talipes varus, in poliomyelitis, 546
Talo-calcaneal extra articular arthrodesis, for flat foot, 871
Talo-navicular arthrodesis, for rigid flat foot, 871
Tarsus, tuberculosis of, 378
Tavernier, denervation of hip, in osteoarthritis, 456
Taylor, on osteitis deformans, 196, on skeletal changes in parathyroid osteodystrophy, 175
Tay Sach's syndrome, 200
Tchitkin's sign, in spondylolisthesis, 668
Telangiectatic sarcoma, 233
Telford and Simmons, on erythromelalgia, 637
Telford and Stopford, on cervical rib, 74, on scalenus syndrome, 79
Tendinitis of the supraspinatus tendon, 771
Tendo-calcaneus, rupture of, 1007, shortening of, 897
Tendons, dis-insertion of, 1002
dislocations of, 1010
lengthening of, in poliomyelitis, 542
operations on, in cerebral palsy, 581
rupture of, 1001, biceps, 1004, extensor pollicis longus, 1006, ligamentum patellæ, 1010, plantaris, 1009, rectus femoris, 1009, tendo-calcaneus, 1007
transfer, for regional deformities in poliomyelitis, 544, *et seq.*
Tennis elbow, 993
Tenosynovitis, 1024, treatment, 1028
Tenotomy, adductor, in cerebral palsy, 584
Tertiary syphilitic arthritis, 411
Thenar space, infection of, 1035
Thomas, flexion deformity test in tuberculosis of the hip, 344, on obstetrical paralysis, 620, splint, in tuberculosis of the spine, 312
Thomson, on treatment of Osgood-Schlatter disease, 491, operation of quadriceps plasty, 946

Virchow, on myositis ossificans circumscripta, 914
Veelcker, on snapping scapula, 786
Volkmann's ischæmic contracture, 906
Von Bechterew's disease, 752
Von Recklinghausen, disease, 108, 171, on myelo-meningocele, 759
Voorhoeve, osteopathia striata, 143
Vrolich's disease, 133

Waldenstrom's sign, in osteochrondritis deformans coxæ juvenilis, 185
Wallerian degeneration of nerve fibrils, 589
Walshe, on cervical rib and scalenus, syndrome, 78, 80
Watkins, on affections of the shoulder joint, 763
Watson-Jones arthrodesis of ankle, 939, on adhesions of joints, 950, on congenital pseud-arthrosis of the tibia, 51 on delayed union of fractures 917, on osteochondritis dissecans, 844, on post-traumatic osteodystrophy, 188, pin method of arthrodesis of the hip, 457
Waugh, on local treatment of osteoarthritis, 470
Weaver's bottom 987
Wedge plaster method of correcting flexion deformity of the knee, 542
Wedge resection, in treatment of scoliosis, 740
Westergreen, on blood segmentation rate in brucella spondylitis, 695
White and Smithwick, on investigation of disorders of the peripheral circulation, 640, 642
White and Stubbin, on equalization of the lower limbs, 941
Whitlow, 1015, acute spreading infections, 1018, carbuncular infections, 1018, complications of, 1029, extension to fascial spaces of the palm, 1030, osteomyelitis and bone necrosis, 1030, suppurative arthritis, 1029, erysipeloid, 1020, felon, 1021, gangrenous, 1020, of first phalangeal space, 1024, of second phalangeal space, 1022, paronychia, 1016, infection of subcutaneous cellular tissue, 1021, pulp space infection, 1021, subcutaneous infection, 1015, sub-ungual, 1017, superficial, 1015, tenosynovitis, 1024, *et seq*
Whitman, frame, in treatment of tuberculosis of the spine, 311, on incidence of vertebral tuberculosis, 284, operation for winged scapula, 788
Wilkie, on congenital radio-ulnar synostosis, 88
Williams and Timmins, on incidence of osteomyelitis, 209
Willis, on bone development in spondylolisthesis, 664, on chondromatous osteoclastoma, 252
Wilson, on cervical rib, 74, on frequency of various types of infection, 1015, on respiratory involvement in poliomyelitis, 532, on treatment of acute hand infections, 1038
operation, for overlapping of fifth toe, 905
Wilson and Thomson, on methods of dealing with unequal leg lengths, 940
Winged scapula, 787
Winnet Orr treatment of osteomyelitis, 220
Wormian bones, 138
Wright, Dickson, on multiple osteochondritis, 122
Wrist, arthrodesis of, 971, aspiration of, 403, congenital subluxation of, 91
drainage of, 403
manipulation of, 962
optimum functional position of, 401
tuberculosis of, 390
Wry-neck, acute, 85, congenital, 81, paralytic, 86, spasmodic, 84, traumatic, 86

Yegg, on intermittent hydrarthrosis, 465
Young, on sympathetic operations in rheumatoid arthritis, 434
Young and Medawar, on treatment of peripheral nerve lesions, 600
Yount, division of ilio-tibial band, 541

Zachary, on anterior tibial syndrome, 626
Zadek, on congenital coxa vara, 496
Zanoli, on myositis ossificans circumscripta, 914
Zimmer, on osteopoikilosis 143

SAWAI MAN SINGH MEDICAL COLLEGE LIBRARY
Accn. No.....
Date.....
Price.....
JAIPUR.

epithelium and intestinal mucous membrane cells liberate this enzyme The phosphatase of young mesenchymal cells is more active in a more alkaline solution and is known as alkaline phosphatase. The normal is 5 to 15 King and Armstrong units, or 2 to 9 Bodansky units per c c. of blood plasma The phosphatase of prostatic epithelium is more active in a relatively acid solution and is known as acid phosphatase, the normal being 1 to 3 King and Armstrong units or 0 to 1 2 Bodansky units per c.c of blood plasma. In prostatic carcinoma without bone metastases the blood acid phosphatase is usually raised When metastases to bone have occurred both acid and alkaline phosphatase are raised

Phosphatase acts by breaking down phosphate esters to liberate the phosphate as an ion This results in an upset of the solubility product constant and a precipitation occurs of the calcium phosphate-calcium carbonate complex. As alkaline phosphatase is produced by active bone cells a rise of blood alkaline phosphates is a sign of increased bone formation In Paget's disease where there is a marked destruction of the bony trabeculæ there is a high blood alkaline phosphatase as long as the patient is up and around, and under the stimulation of strains and stresses compensatory bone is being laid down. On bed rest, where the stimulation to new bone formation is absent, the blood phosphatase drops closer to normal. Phosphatase is destroyed by the liver and in liver disease there is also an increase of both acid and alkaline phosphatase

There are two main factors controlling the calcium balance between blood serum and spongy bone . (1) the phosphate content of the serum (the amount found normally in the blood serum is from 1 5 to 4 units per 100 c c. in adults and from 5 to 12 units in children) ; (2) the parathormone content of the serum Increase in the amount of parathormone leads to increased solution of calcium and phosphate from the bones The excess of calcium is largely got rid of by excretion, but there may be a rise for a time at least in the serum calcium. It is generally accepted that an increase in parathormone acts mainly by hastening the excretion of blood phosphate in the urine, though in high doses it apparently acts to some extent also by dissolving the calcium phosphate of the bones.

Organic Structure of Bone.

Mesenchymal cells, or cells whose function is to support or connect, all have a common origin—the primitive mesenchymal cell. When they proliferate they pass through this primitive stage (de-differentiation) and thus ordinary granulation tissue, healing fractures, healing tendon, etc all contain masses of primitive mesenchymal cells. When these primitive mesenchymal cells mature they differentiate into the type eventually needed The change in the main is in the inter-cellular substance and so reticular cells have fine reticular fibres in their inter-cellular substance, fibroblasts have collagen or elastic fibres, osteoblasts have collagen fibres with the addition of precipitated salts, and cartilage

Salts when dissolved in water become ionized and when the solution is saturated the product of the constituent ions of the salt is a constant (e g. calcium × phosphates = K). This constant is known as the solubility product and varies with different types of salts. Thus for calcium phosphate K = 55 and differs from the K of calcium carbonate. When the product of calcium × phosphates is greater than K a precipitation of this salt occurs. Similarly, calcium carbonate will precipitate if calcium × carbonate is greater than K.

Precipitation of these salts can be induced by the addition of calcium chloride which raises the number of calcium ions and upsets the equilibrium with resulting precipitation of calcium phosphate or calcium carbonate.

Calcium, phosphates and carbonates are present in the blood in ionizable and non-ionizable forms. The ionizable form is as salts, and the non-ionizable as proteinates or esters. These latter compounds, being ionizable to a much less degree, can be added to a saturated solution without upsetting the solubility products and precipitating the salt. Thus calcium is present in the blood serum in excess of its saturation point as calcium proteinate, and phosphates in excess as phosphate esters.

The total blood calcium is between 9 and 11·5 mg. per cent. About 50 per cent. of this is non-ionizable calcium being attached to proteins of the blood and known as the non-diffusible fraction. The ionizable part is the part physiologically active and normally is 4·25 to 5 25 mg per cent. A decrease in the blood proteins will result in a drop of total plasma calcium and if there is a concomitant rise of the diffusible fraction the total blood calcium will be apparently normal. Thus in parathyroid adenoma where the diffusible calcium is raised an associated low blood protein can give a normal total blood calcium. In multiple myeloma the raised blood protein may result in a raised total blood calcium but the ionizable fraction may be normal.

A rise in calcium, phosphate or carbonate ions in the blood will lead to precipitation of calcium carbonate-calcium phosphate complex, and a drop will result in increased solubility of calcium carbonate-calcium phosphate complex from the bone.

Mineral calcium is mainly responsible for maintaining the physico-chemical equilibrium necessary for the normal irritability of muscle and nerve, and its exact role is to lessen irritability at the neuro-muscular junctions in the myocardium and in striped and unstriped muscle Despite its essential function there is no conservation of it in the body, and the spongiosa of the skeleton forms its only reservoir Phosphorus is essential for the regulation of the acid base reaction of the body fluids, and is likewise stored in the spongiosa of the skeleton. Normally the blood serum is a solution in biological equilibrium with the calcium phosphate of the bones.

Another important constituent of blood is the enzyme phosphatase. Varying cells, notably primitive or young mesenchymal cells, prostatic

reason have an affinity for calcium and White has shown heterogeneous cartilage implanted in the abdominal wall of rabbits becomes the site for calcium deposition, the phosphates and carbonates being in similar proportion to these minerals in bone.

Ossification.

Ossification is the laying down in an orderly manner of calcium carbonate-calcium phosphate complex in the intercellular substance of a mesenchymal cell To study this process one must consider what occurs at the bone cell surface.

Among the mesenchymal cells there percolate tissue fluids and its flow increases and decreases with the volume of blood supply to that region. The content of the tissue fluid is similar to that of blood plasma. Phosphatase is liberated by the young mesenchymal cell and this results in a break-down of phosphate esters liberating phosphate, upsetting the ionic equilibrium, and precipitating calcium in the intercellular substance. If the flow of tissue fluid is too rapid it will upset this local phenomenon by dilution with normal tissue fluid Thus an increased blood flow will prevent calcification occurring and on the contrary will rapidly remove the carbon dioxide produced by the metabolism of the cell with a resulting drop of carbon ions which increases the solubility of calcium, and decalcification of the cell matrix occurs. This phenomenon is known as halisteresis

If the circulation is abnormally slowed the carbon dioxide concentration in the tissue fluid will increase, raising the carbonate ion concentration and precipitating calcium carbonate-calcium phosphate complex Thus increased blood supply results in osteomalacia, and decreased blood supply results in osteosclerosis One can see that for bone to remain relatively static a delicate equilibrium must be maintained.

The concentration of ionizable calcium is 5 mg per cent and to supply sufficient calcium for rapid ossification, as occurs in fractures or epiphyseal growth, massive amounts of blood would have to be made available To obviate this a local ready calcium supply in the form of calcified tissue is necessary It is only a step further that is required to build the bony structure of the body. A typical capillary is an endothelial-lined tube surrounded by mesenchymal cells Proliferation of these cells occurs close to the capillary where nutrition is optimum and they displace the older cells outwards in an increasing ring Calcium is precipitated in the matrix of these maturing cells, and the cells further away, because of the increased carbon dioxide concentration, acquire a heavier precipitate of calcium than the central paravascular cells The cells in their calcified matrix are known as osteocytes After histological preparation when these cells shrink the space in which they lie is called a lacuna, and connecting these lacunæ are small channels known as canaliculi The addition of layer upon layer of precipitated calcium in mesenchymal cells around the central capillary, like the leaves of an onion, is known as a Haversian system The centre, where the capillary runs, is the Haversian canal which contains, in addition to an

cells have chondro-mucin. When these varying tissues grow they pass through the primitive mesenchymal cell stage.

There is good evidence to show that the intercellular substance of osteocytes and fibroblasts are identical except for the presence of precipitated salts in the osteocyte Some people believe that there are differences besides those mentioned but this only complicates an already complex picture.

Stump, and a host of other observers, demonstrated that the bone-forming cells were derived from a primitive mesenchymal cell which was found between the cartilage model—to which it gives rise—and the perichondrium, also a product of it. Stump indeed proved that the cartilage model of the future bone degenerated and was destroyed in advance of the invading mass of osteogenic tissue, and he also showed that there was no difference in the mechanism of enchondral and membrane bone formation, save that the former was preceded by a temporary cartilage scaffolding.

One can accept fibroblasts and osteoblasts as being the same type of cell and interchangeable, the so-called osteoblasts having in addition to collagen fibres a crystalline precipitate of calcium carbonate-calcium phosphate complex. The latter gives the bone rigidity and results in its fragility; the fibres hold the crystals together, giving the bone elasticity. Thus a defect in the mineral content gives a soft pliable bone such as in rickets, and a defect in the fibres an inelastic highly fragile bone as in fragilitas ossium.

The term osteoblast when it is used here merely denotes a fibroblast with precipitated calcium salts in the matrix.

Calcification.

Calcification and ossification are distinctly different and although the relative amounts of calcium carbonate and calcium phosphate may be the same the crystalline structure is different.

A simple place to study calcification is in fat necrosis In trauma to the breast or acute pancreatitis necrosis of fat cells results in fatty acid liberation These combine with the calcium of tissue fluids to form insoluble calcium fatty acid compound known as saponification. The fatty acid radicle is slowly replaced by carbonates and phosphates leaving behind calcium carbonate and calcium phosphate which are relatively insoluble This is calcification and its presence is an irritant to the tissues of the body and elicits a foreign body reaction resulting in inflammation and fibrosis.

In tissues which are undergoing slow death and pass through the fatty degeneration stage, going on to necrosis, there is a liberation of fatty acids and possible calcification · e.g. ischæmic necrosis of the centre of a fibroid or the centre of an old avascular scar Calcification also occurs in tuberculous caseous material which contains a definite proportion of fats and in xanthomatous placques where fatty acids occur too, e g. arthroma.

The non-viable intercellular substances of cartilage for some unknown

entities known as osteoclasts which play an important part in the removal of calcium from bone tissue There is strong evidence to the contrary and we may accept osteoclasts as foreign body giant cells which remove cellular debris after most of the calcium in absorbing bone has been removed by halisteresis

After the appearance of the original centre of ossification, continued growth in length depends on the continued proliferation of cartilage cells beyond it (interstitial growth), and on their gradual degeneration and on the calcification and invasion of their matrix by osteogenic cells and blood-vessels from the diaphysial ossification-centre Growth in diameter of the cartilaginous end is by differentiation of cartilaginous cells from the fibrous perichondrium (appositional growth) Throughout the growth period of post-natal life a fine balance is maintained between the two processes, so that the proliferating cartilage is not completely replaced by bone until full longitudinal development has been attained. Instead, at either end of the bone there is an area of cartilage which by continued proliferation is responsible for the future growth in length of the bone—the epiphyseal cartilage. Greig has suggested that the term "cartilage of conjugation" would be more appropriate, since the mass of cartilage on the side of the disc away from the shaft acquires after birth a secondary centre of ossification and the plate is situated between the two centres Ossification in this secondary centre occurs in identical manner to that of enchondral ossification of the shaft.

Bone Growth.

Bone growth in the immature occurs mainly at the epiphyseal plates. Growth to a lesser degree occurs subperiosteally and under the watchful eye of the "Remodelling Process" makes the bone most efficient. Where strains occur new bone is laid down and where there is no strain the bone is removed making for lightness and strength—its ultimate aim.

A typical long bone consists of a shaft capped at both ends by cartilaginous bulbs and surrounded by the connective tissue layer, the periosteum The part which the periosteum plays has been a common source of discussion by commentators on bone pathology since the time of Duhamel McEwan showed that the periosteum acted the part of a limiting membrane to bone, but had *per se* no bone-forming properties, and the accretion of surface bone is due not to the activity of the periosteum but to a layer of primitive connective tissue cells situated between the periosteum and the bone. This has often been regarded as a second or deep layer of the periosteum, but some workers choose to regard it as more intimately connected with the cortex of the bone All observations subsequent to McEwan's classical work have confirmed his view of periosteal function, and though the phrase periosteal bone is still employed, it is not meant in its literal sense The term "sub-periosteal" bone is more accurate and equally descriptive

The main blood supply of the shaft is through the nutrient artery and the periosteal vessels The nutrient artery supplies the medulla

arterial capillary, a venous capillary, nerves, lymph vessels, and, in cortical bone, a Sharpey fibre. It is thus readily seen that for ossification three factors are important: (1) young mesenchymal cells; (2) a blood supply; and (3) a readily available source of calcium—e g. calcified tissue or bone

THE DEVELOPMENT OF BONE

The growth of bone begins early in fœtal life. In most parts of the skeleton a cartilaginous model of the future bone is laid down, and the subsequent process of ossification is known as enchondral ossification. In a few cases there is no preceding stage of chondrification, and this variety of bone development is known as membranous ossification.

Enchondral Ossification.

It has been demonstrated beyond the possibility of error that though a distinction is usually made between the two types of bone development, there is, in fact, no essential difference. At those situations in the developing embryo in which enchondral bone is later to be formed, there occurs first a condensation of the *primitive connective tissue*. This is followed by enlargement, and then separation, of the cells by the deposition of an extra-cellular matrix of chondromucin, until a model in cartilage of the future bone is produced. The mesenchymal cells on the surface of the model at the same time give rise to a peripheral sheath of fibrous tissue—*the perichondrium*—between which and the surface of the model, they persist in their primitive form

It is interesting at this point to note that the pattern of the model is predetermined. Miss Fell has shown that an isolated rudiment of a chick femur, cultivated in vitro, develops and maintains its characteristic form. Murray and Selby have also grafted a small basal piece of the posterior limb bud of an early chick embryo on to the chorio-allantoic membrane of an older chick, and found it develop—in the absence of its usual surroundings, and in the absence of the strains and stresses to which it is normally subject—into a well-shaped femur. It is not in dispute that the ultimate perfection of the adult bone may be attained as a result of environmental stimuli, but the original pattern is inherited and surprisingly perfect.

In either membranous or enchondral bone the first change discernible preceding ossification is spotty degeneration of the mesenchymal or cartilage cells in the centre of the diaphysis. Calcification occurs at these points of degeneration, and the vascular perichondrium now shows activity with an outgrowth of capillaries which invade the calcified areas. The primitive mesenchymal cells surrounding these capillaries grow and in their intercellular substance is laid down calcium phosphate-calcium carbonate complex. True bone is then formed The capillaries in the centre of the bone show a markedly increased blood flow preparing it for its new rôle of hæmopœtic bone marrow and this hyperæmia results in absorption of calcium and the organic cellular debris is removed by macrophagic giant cells. Some believe that these giant cells are distinct

trabeculæ are gradually removed to form a medullary cavity, and thereafter the constant deposition of successive layers of new subperiosteal bone is simultaneously accompanied by the removal of bone on the medullary aspect of the cortex In the vicinity of the epiphyseal cartilage, where the new trabeculæ are constantly being laid down, they are just as constantly being recast into an arrangement suitable to withstand the forces of weight-bearing or use This area of the growing bone is usually known as the metaphysis, and is normally the widest part of the bone Since the bone grows in length by increments to the metaphysis, the girth of the bone would become too great, and its shape would be other than tubular. The expanded ends of the shaft, therefore, are subjected to a remodelling process which preserves the tubularity of the bone

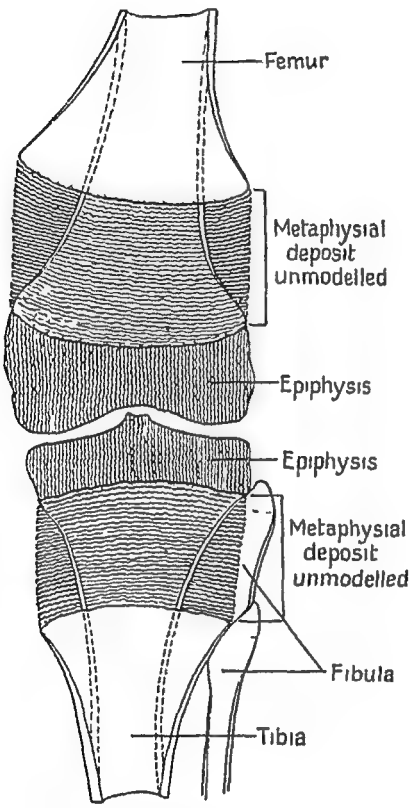

Fig 50 —Diagram to show the Normal Remodelling Process at the Metaphysis and the Area of Bone Removed (after Keith)

Every strain is a trauma in miniature eliciting its highly localized inflammatory response mild enough to act as a stimulant with the proliferation of the primitive mesenchymal cells and the laying down of new bone Without this stimulant effect at sites where strains do not occur the cells become quiescent, their former circulation now being in excess and there is now a relative hyperæmia with bone absorption. In the medulla of the bone added to the absence of the stimulation of strains the capillary spaces enlarge to form the sinusoids of the marrow and with this increased circulation the bone is absorbed. Thus in the centre of the shaft the bone is completely absorbed and this is known as the bone marrow Further out only the central part of each Haversian system is absorbed leaving a thin rim of bone This is spongy bone More peripheral yet the whole of each Haversian system is calcified and this is known as compact bone

The remodelling process is not confined to developing bone Thus in the adult bone special needs are frequently met by readjustment of the osseous struts In diseases associated with bone deposition there is a constant building up and subsequent remodelling In fractures the reparative material is largely removed leaving only that which binds cortex to cortex

It should be pointed out here that strains and stresses act on bone

(10/11ths of the bone diameter) and extends as far as the metaphysis The periosteal vessels ramify and then pass into the bone communicating with the deeper vessels. The mesenchymal cells around these periosteal vessels form the cortical bone, and the arterial and venous capillaries are accompanied by collagen and elastic fibres which pass with them through Volkman's canal in the cortical bone only. These fibres are known as Sharpey fibres and are continuous through the periosteum with tendon and ligament fibres.

This cortical bone is compact and hard, the Haversian systems being perpendicular to the long axis of the bone and the haversian canals here being known as Volkman's canals. Bending or torsional force on a supporting pillar acts mostly through the outer rim, therefore it is this cortical bone that must withstand the major part of a disrupting force acting on the bone shaft. Ossification in the subperiosteal region is much slower than at the epiphysis. There is an absence of a zone of preliminary calcification and the needed calcium is derived from the adjacent compact bone and blood.

Stimulation of the primitive mesenchymal cells deep to the periosteum will result in new bone formation, and in traumatic hæmatoma, inflammatory œdema or malignancy there can result sub-periosteal new bone formation and it is this type of new bone formation that gives the clue to the etiology. If persistent hyperæmia such as an adjacent ulcer or hæmangioma occurs, bone absorption will result.

At the epiphyseal plate Harris has emphasized that, histologically, three zones are to be observed. The first is the zone of *proliferating cartilage*. Traced towards the shaft it will be found that the proliferating cells arrange themselves in longitudinal columns or palisades, the number of cells in each palisade being in the region of five. Beyond this is a zone in which the cells of the palisade have become enlarged and degenerate, and the chondro-mucinous framework has become calcified. This area is known as the zone of *calcified cartilage* or *preliminary calcification*. The last zone—nearest the ossified shaft—is that of *active osteogenesis* In this zone the capillary loops grow and abut on the zone of preliminary calcification. The primitive mesenchymal cells around the loops proliferate and begin to ossify. Calcium is absorbed from the adjoining zone of preliminary calcification and the remaining organic material is removed by giant cells. The Haversian systems formed here are parallel to the long axis of the bone and further in form the medullary bone or cancellous bone of the shaft.

The zone of preliminary calcification is important in that a deficiency of calcium or irregular calcification will result in deranged adjacent ossification.

The Remodelling Process.

The subsequent history of the bone is of equal interest. Once formed, there begins almost at once a remodelling process which adapts the bone to suit the stresses and strains to which it is subject. This occurs throughout the bone. Thus, in the centre of the shaft the

young men in plaster for several weeks and carrying out metabolic studies

2 *Nutritional Factors.* Severe protein deficiency resulting from malnutrition or failure in absorption or abnormal protein excretion can result in osteoporosis of bone and improvement can be obtained by increasing the available protein

Accompanying such a deficiency, the calcium and phosphorus intake is reduced and forms part of the circumstances leading to senile osteoporosis

Scurvy due to deficiency in vitamin C can also produce osteoporosis of bone as well as its other more obvious hæmorrhagic manifestations.

3. *Endocrine Factors* Osteoporosis is a common complication in Cushing's syndrome resulting from a basophil adenoma of the pituitary, or from disease of the adrenal cortex. These give rise to an excess of the anti-anabolic S hormone, which also acts on sugar metabolism (Albright, 1943) and has now been identified as a gluco-corticoid hormone. Accompanying the generalized osteoporosis, there are other endocrine disorders, of sexual characteristics, of obesity and of diabetes mellitus

In Von Recklinghausen's disease of bone, with hyperparathyroidism resulting from an adenoma, as an early manifestation there may be osteoporosis of the skull and spine, before the appearance of the fibrocystic lesions, osteoclastomata and stone formation.

Post-menopausal osteoporosis may result from ovarian insufficiency with diminution in œstrogen secretion. It has been shown experimentally that certain animals respond to œstrogen treatment by hyperossification, but in man this has not been confirmed and the relationship and response of bone to the sex hormones is still uncertain That there is some sex hormonal factor in producing this condition may be inferred by the incidence being so very much higher in women than in men

In other endocrine diseases such as in acromegaly and gigantism, resulting from pituitary dysfunction, or in hypothyroidism of cretinism or myxœdema or thyrotoxicosis, osteoporosis has been recorded

4 *Other pathological diseases* which replace the normal bone architecture, e g , myelomatosis and tumour invasion

Pathology

There is reduction in the thickness of the cortex with the intermedullary contents being made up of a yellow and fatty cancellous bone tissue In this on microscopy, and on micro-radiography of undecalcified bone specimens (Sissons, 1952), there is a reduction in the number and size of the trabeculæ and in the number of osteoblasts present This results in a marked reduction in the mechanical strength of the involved bone which therefore fractures or crushes with minor trauma

Clinical Features

Most cases which come forward because of symptoms, and for treatment, are in the senile and post-menopausal groups of osteoporosis

as they do on soft tissue. Depending upon the degree of trauma, a mild degree may act as a stimulant and a severe degree may result in necrosis. Between the two are various degrees of inflammation.

The strains and stresses within the limits of tolerance of the bone will result in new supportive trabeculæ. A strain of severer degree may result in inflammation instead of stimulation and may result in osteoporosis. This is seen in the so-called March Fracture where the strain is beyond the tolerance of the bone, and severe osteoporosis occurs with compensatory new bone formation. When a strain acts in a mechanical direction perpendicular to the usual line of force, such as an aneurysm of the aorta adjacent to the vertebræ, the degree of bony absorption is extreme with very little if any new bone formation

OSTEOPOROSIS

This condition has been defined by Sissons (1955) as a structural change in bone, whereby the supporting tissue is reduced in amount, but remains highly mineralized. Albright and Reiferstein (1948) have pointed out that it is a disorder of protein metabolism which is reflected in abnormal trabeculæ formation, but the metabolism of calcium is normal and the trabeculæ which are present are normally calcified.

Because of this definition Cook (1955), in a complete review of this subject, has emphasized how it must be clearly differentiated from such terms as *decalcification* in which on radiological or post-mortem appearances the bones appear deficient in minerals, or *halisteresis* in which the bone mineral is removed to leave only protein-like structures in osteoid tissue or uncalcified matrix; but the latter is an artificial state and does not occur in nature, and should not be used.

Attempting to clarify the existing ambiguity on the nomenclature of these conditions, as seen on radiography as a reduced bone density, McLean and Urist (1955) prefer to term the condition—*Bone Atrophy*. This may be systemic (i.e., osteoporosis), or regional, or local as seen typically in the *Atrophy of Disuse* in the limb bones.

Aetiology

It is a response of the bony skeleton to a number of otherwise unrelated disturbances which can be considered under the following headings:

1. *Mechanical Factors*—in which through immobilization of the whole body or a part of it for the treatment of fractures, post-operative procedures, tuberculosis, etc. or resulting from conditions such as anterior poliomyelitis, rheumatoid arthritis, and traumatic paraplegia, there is a general or local osteoporosis of bone. Cuthbertson (1930) first pointed out how, accompanying muscle loss and osteoporosis, there is a negative nitrogen balance, resulting from an increased urinary excretion of nitrogen, in cases of immobilization, with or without injury. This work has been followed by other workers and Deitrich, Whedon and Shorr (1948) have confirmed this later finding experimentally by immobilizing healthy

Treatment

1. *Ambulation* must be encouraged, and support given to the diseased spine in the form of a light plaster jacket or to the pathological fracture of the femur by a walking non-weight-bearing caliper. Internal fixation is unsound in principle because of the loss in mechanical strength of the surrounding bone

2. *Dietary.* A high protein diet must be prescribed.

3. *Hormonal*

(*a*) Oestrogen therapy Oestrogens have been shown to produce hyperossification and because of this Albright (1947) gave it to patients suffering from idiopathic osteoporosis with quick relief of the symptoms but rarely structural improvement It can be given as 1 mg./day orally or by injection as œstrogen dipropionate 2 mg./day for a period of four weeks with a following rest of two weeks before recommencing the drug This may produce uterine bleeding, and this is an indication to stop treatment.

(*b*) Androgen therapy These have been shown to produce an increase in the bone matrix, the body weight and musculature (Kenyon *et al*, 1940; Weinmann, 1950) Because of this Cooke recommends the giving of testosterone propionate 10–20 mg. daily by injection or methyl testosterone 30 mg /day by mouth in combination with the œstrogens. The latter combination may prevent the masculinizing effects of the androgen

The Healing of Fractures

Generally the healing of a wound of bone follows the same principles as the healing of a wound in other tissues. The typical fracture of bone is featured by the appearance of a hæmatoma between the bone ends The source of this blood is from torn blood vessels of the medulla, of the Haversian and Volkman's canals, and the periosteum, and damaged adjacent soft tissues

Fibrinous clotting occurs and is soon replaced by fibrous tissue in the form of undifferentiated connective tissue from the periosteum, Haversian and Volkman's canals, and surrounding soft tissues On the fourth day these primitive connective tissue cells begin to differentiate into fibrocartilaginous cell types.

Soon after there is a degeneration in the matrix of the connective tissue cells and fibrocartilaginous cells and calcification begins to occur. Blood vessels grow in from the bone ends and about them ossification begins, the source of calcium being necrotic bone fragments, areas of calcification, bone ends, and blood Thus it is seen that the so-called enchondral and membranous ossification occur side by side This mass of blood clot, fibrous tissue, fibro-cartilaginous tissue and ossifying tissue is known as the callus and occurs between the sixth and twenty-first days The breaking strength of the fracture rises during this time It falls during the twenty-first to thirtieth days when the medullary

and can be more realistically termed idiopathic and spinal osteoporosis The other forms of osteoporosis are usually discovered incidental to the main disease process, by radiology. Pathological fractures—especially of the femoral neck—commonly arise because of this condition.

1. *Pain* is in the nature of a lumbar backache which radiates around the trunk or down the lower limbs. It is aggravated by movement or jarring and although suggestive of a nerve root compression, this is rarely seen.

Acute sudden onset of pain with localized tenderness in the chest or back is most suggestive of a pathological fracture of a rib or vertebral body.

2. *Loss of height* may have been noted by the patient, with the appearance of a thoracic kyphosis and an approximation of the rib margin to the iliac crests. The patient usually appears older than her years.

3. *Radiographic Appearances.* The involved bone has a "ground glass" appearance because of loss of definition of the trabeculæ. In the spine, the vertebral bodies become flattened but biconcave in shape with increase in the intervertebral spaces, and varying degrees of collapse and wedging may be seen.

Healing of the pathological fracture is usually accompanied by little callus formation. In the pelvis, the typical appearance of loss of density is observed.

The long bones are rarely affected, and never the skull, although it has been recorded in osteoporosis accompanying Cushing's disease.

4. *Biochemistry.* The serum calcium, phosphorus and alkaline phosphatase are within normal limits. The total plasma-protein and plasma albumin may be low, but is of little value from the diagnostic aspect.

5. *Biopsy.* Specimens by trephining can be obtained from the iliac crest or the spinous process of the lumbar vertebræ and are of value. (Vogt, 1919)

Differential Diagnosis

1. *Osteomalacia* It is a condition of hypocalcification which radiologically may resemble osteoporosis but results from a failure in calcification of the bone matrix due to a calcium and vitamin D deficiency. This arises either from a malnutrition state or a failure in absorption in the condition of steatorrhœa, and can be differentiated clinically. The plasma phosphorus level is lowered with an increase in the serum alkaline phosphatase.

2 *Secondary osteoporosis* of other diseases such as hyperparathyroidism, either primary from tumour of the parathyroid gland or secondary to renal dysfunction of phosphate excretion, Cushing's syndrome, acromegaly, etc., can be identified by the features of the primary disease.

When heterotopic bone forms adjacent to bone as a result of trauma it is known as myositis ossificans traumatica, the calcium deposit being the bone itself, and when it forms in tissues away from bone it requires a calcium deposit in the form of calcified tissue. Even osteogenic sarcoma, reputed by some to arise from a specialized osteoblast, cannot form bone in its metastases unless an adjacent calcium depot is available Thus in pulmonary metastases ossification will only occur if adjacent to an old calcified tuberculous gland or scar

Heterotopic bone has now been reported in a wide variety of situations—the muscles of the thigh, the adductors of the hip (rider's bone), in the muscles of the forearm following dislocation of the elbow (myositis ossificans), in the breast, in the scar of abdominal section, in the tongue, etc. In the majority of instances it follows trauma.

The Haversian system of the new bone is formed around the granulation tissue capillaries present in a subperiosteal hæmatoma or around an area of preliminary calcification that has elicited an inflammatory reaction about it

Pathological Subperiosteal Bone Formation

When the periosteum is elevated by trauma or inflammatory œdema granulation tissue fills this subperiosteal area as it would in a break in the skin surface With the available calcium depot of the adjacent bone ossification can occur. The type of bone formed varies in different pathological conditions A simple and yet accurate explanation of the pathology can be obtained by consideration of similar conditions in the cutaneous tissue

Of importance are ·

1. *The degree of necrosis* In skin it is known as slough and in bone as sequestra. Acute virulent infections give massive sloughs or sequestra Tuberculosis gives sloughs or sequestra of lesser degree and syphilis less necrosis still

2. *The amount of hyperæmia* In the skin hyperæmia manifests itself as redness, in bone as osteomalacia In acute affections of the skin hyperæmia is exaggerated, and in acute osteomyelitis osteoporosis begins to manifest itself early, at the seventh day, and is obvious radiologically in fourteen days

3. *The amount and character of fibrous tissue.* The amount and the character of the fibrous tissue formed depend upon the type of irritant A well healed aseptic skin incision will heal with a minimum of fibrous tissue, and a well healed periosteal wound does so with practically imperceptible bone changes In some skin, especially in regions of increased mobility, as the shoulder or the face, the fibrous tissue hypertrophies to give irregular fibrous tissue masses called keloids Similarly in cases where the raised periosteum is the site of muscular attachment the muscular movement will result in irregular bone masses forming subperiosteally. Healed skin after acute sepsis usually results in a scar

cavity forms and then slowly rises until normal breaking strength is gained on the forty-fifth day. The excess callus and bone is removed by the remodelling process.

Non-union or delayed union, provided there is a continuous hæmatoma between both ends, is usually due to hyperæmic factors. Of these, infection and mobility at the fracture site are practically all-inclusive Hyperæmia removes calcium from the fracture site and if it persists long enough will seriously impair available calcium sources by decalcifying bone ends, fragments and calcified callus tissue. The decalcification results in the apparent cyst formation that occurs in non-union of fractured navicular, or absorption of the neck in non-union of a fractured neck of the femur. When this occurs the treatment is to remove the hyperæmic factors and restore the necessary calcium by the use of bone grafts.

Bone Necrosis

Bone necrosis usually occurs from toxic factors, ischæmia, or a combination of both. The common causes are: (1) fractures depriving bone of blood supply (grafts: artificial fractures); and (2) osteomyelitis. When bone dies it usually undergoes slow absorption. The bulk of the calcium is removed by halisteresis and the organic elements by foreign body giant cells. Because of the inflammatory response it elicits there is a decalcification of the surrounding bone to a much greater degree than that of the avascular necrosed bone. An X-ray in three weeks will reveal decalcification of the surrounding bone and gives the avascular bone the appearance of increased density.

In bone grafts the avascular compact bone is absorbed more slowly than the avascular cancellous bone where there is a larger area of bone exposed to tissue fluids and invading granulation tissue. This allows a higher concentration of calcium for adjacent ossification, its only disadvantage being the lack of splinting quality which compact bone possesses. With the gradual removal of avascular bone its place is taken by ingrowing capillaries and primitive connective tissue cells which undergo ossification.

Heterotopic Bone Formation

The occurrence of bone in tissues other than skeletal is an occasional and interesting phenomenon and one whose pathology has given rise to some dispute. Such bony deposits are known as "heterotopic bone," and have to be distinguished from calcification of extra-osseous tissues.

It can be seen from the previous sections that heterotopic ossification can occur wherever there is (1) adequate calcium deposits; (2) adequate blood supply, and (3) proliferating embryonic connective tissue cells

Murray by his revealing experiments has done much to solve this formerly baffling riddle. If a healing wound in experimental animals is implanted with calcium carbonate bone tissue is formed. In heterotopic bone formation the important factor is a calcium depot.

(i) In the child
Hypopituitarism
Hypergonadism
Hypothyroidism.
(ii) In the adult
Menopausal œstrogen lack
Disuse atrophy
Localized and post-traumatic osteodystrophy
(b) *Excess stimulation of growth of the primitive connective tissue cells.*
(i) Child—gigantism:
(1) Hyperpituitarism
(2) Hyperthyroidism (Pituitary effect).
(3) Hypogonadism
(4) Increased circulation
(Local gigantism)
(ii) Adult—Acromegaly·
(1) Hyperpituitarism.
(2) Hyperthyroidism
(6) *Diffuse "Inflammation" of the Connective Tissue Cells*
Syphilitic osteoperiostitis.
Myositis ossificans progressiva
Paget's disease
(7) *Bone Marrow Affection*
Reticulo-endothelial disturbances
Diffuse malignant involvement—Hodgkins. Myelogenous leukemia.

In the examination and diagnosis of these conditions Shearer says "If a bone lesion as seen radiographically does not show reactive change in the adjacent bone or periosteum, which suggests an inflammatory process or the invasive character of a neoplastic process, you should then have in mind the possibility of a dysplasia Study then the localization, is it involving primarily metaphyseal bone or does it, in some conditions, involve only the epiphyses or only the small bones? Study then the nature of the abnormal process Is it merely an arrest of growth; does the appearance suggest a cartilage dysplasia or a fibrous dysplasia? Then proceed to carry out a survey of the skeleton to show the distribution of the abnormal bone Do not forget to note whether the condition is associated with a generalized osteoporosis or whether bone, apart from the involved area, is normal Then consider the findings in relation to the full history and clinical examination as well as biochemical blood analysis Having done this I think you will at least make an intelligent approach to the correct diagnosis, and will usually reach a satisfactory conclusion"

DEVELOPMENTAL DISEASES OF BONE

The common developmental diseases of bone apart from the obvious endocrine errors can all be arranged in two groups

(1) *Errors in the proliferation and calcification of the cartilage model*
Achondroplasia
Chondro-osteo-dystrophy
Dyschondroplasia.

of soft fibrous tissue, and in the subperiosteal region with a similar infection the new bone resembles that of ordinary cortical bone.

Recurrent flares up of infection lead to irregular masses of sclerotic tissue and granulation tissue, and in the subperiosteal region to irregular masses of sclerotic and porotic bone.

Syphilis which results in dense fibrous tissue formation in its skin manifestations, results in hard dense sclerotic bone in the subperiosteal region.

GENERAL AFFECTIONS OF THE SKELETON

Our knowledge of bone diseases and their origin is still too incomplete to permit of a classification at the same time comprehensive and scientifically accurate. The following table is suggested only as a convenient one for discussion:

Classification of General Bone Disease

(1) *Developmental*
- Achondroplasia.
- Chondro-osteo dystrophy.
- Dyschondroplasia.
- Multiple enchondromata.
- Metaphysial aclasis.
- Osteogenesis imperfecta
- Polyostotic fibrous dysplasia.
- Osteopetrosis.

(2) *Deficiency in Inorganic Constituent of Bone*

In the infant it manifests itself as rickets and in the adult as osteomalacia.

(a) *Insufficient absorption of calcium or phosphates.*
- Low intake—starvation—Rickets
  - Osteomalacia.
- Defective Absorption
  - Vitamin D deficiency.
  - Defective Fat Absorption—Biliary deficiency.
    - Pancreatic deficiency.
    - Cœliac disease.
- Chronic Diarrhœa.

(b) *Excessive Secretion of Calcium or Phosphates.*
- Renal Rickets.
- Acidosis.
- Hyperparathyroidism.

(3) *Excess of Inorganic Constituent of Bone*
- Decreased phosphate excretion—Hypoparathyroidism.

(4) *Organic Deficiency*

(a) Decreased intake—Starvation.
- Chronic Diarrhœa.

(b) Excessive Utilization or Loss.
- Chronic infection.
- Albuminuria.
- Liver Disease.
- Toxic Thyroid.

(5) *Metabolic Dysfunction*

(a) *Interference with growth of the primitive connective tissue cells.*

In the child it manifests itself as *dwarfism* and in the adult as *osteoporosis*.

study of fœtal cases that some information as to the underlying basis of the error has accrued.

Clinical Features

At birth, a typical achondroplast has a normal-sized body, very short, fat, flabby limbs, and a large head, with a characteristic depression at the root of the nose The small stature is largely due to the

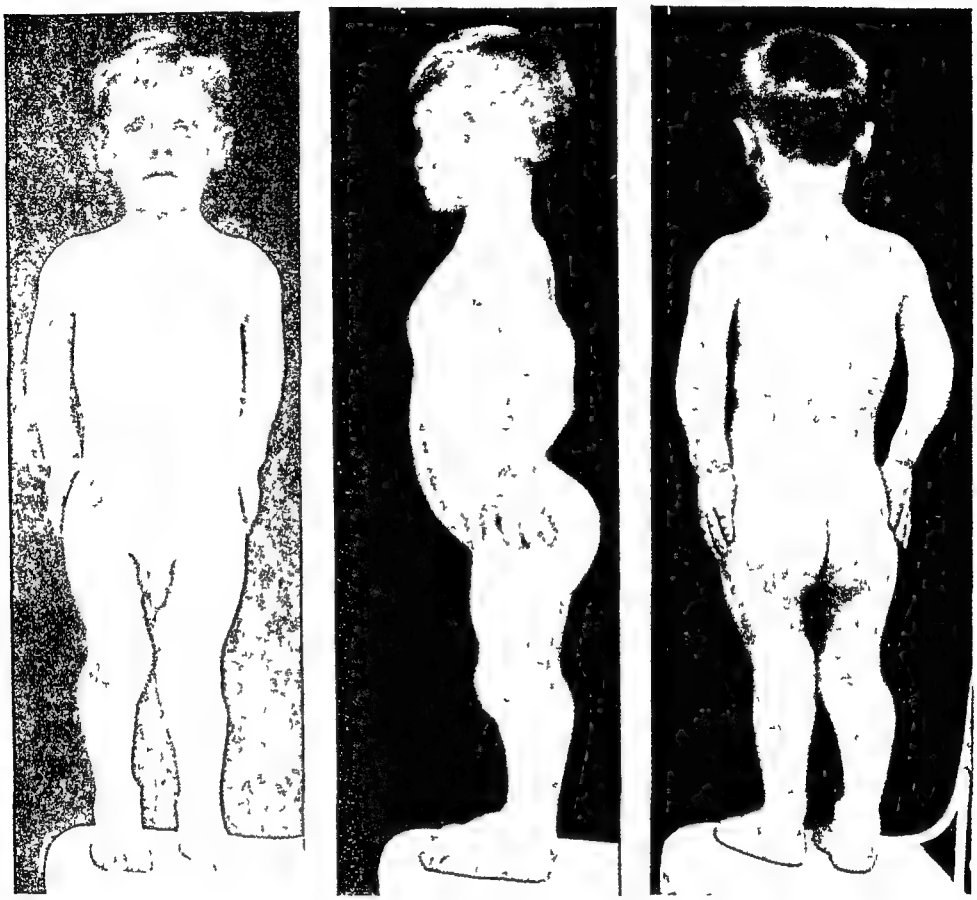

A B C

Fig 51 —Achondroplasia

A, B and C The characteristic appearance of a child suffering from achondroplasia

absence of growth of the lower extremities, and becomes increasingly evident during childhood The child walks at the usual age, teeth appear at the normal times, and the rolls of fat which disfigure the limbs slowly disappear. Growth is permanently retarded, however, and the child is recognized as an unmistakable dwarf long before adult life is reached The smallest cases recorded are Brock's, a woman, aged 23, who measured 97 centimetres, and Bailey's, aged 27, measuring 104 centimetres

Standing erect, the tips of the fingers may only reach the great trochanter or the iliac crests, whereas in the normal person they extend

Metaphysial aclasis
Multiple enchondromata.
Polyostotic fibrous dysplasia
(2) *Errors in the primitive connective tissue cell structure*
Osteogenesis imperfecta.
Osteopetrosis.

The epiphyseal cartilage proliferates normally in columnar fashion and in due course undergoes maturation, degeneration and calcification. If the chondroblast is defective multiple pathology may occur as a result of the failure or an irregularity in the maturation and calcification of the cartilage cells.

If the failure of maturation and calcification is diffuse the lack of the zone of preliminary calcification will result in a retardation of epiphyseal ossification and dwarfism.

If the failure is irregular multiple pathological pictures will appear depending on the site of the abnormal chondroblast.

A central immature chondroblast, if it continues to proliferate will form an enchondroma which gives the bone an apparent cystic appearance, and if peripheral this proliferating chondroblast will result in an ecchondroma If ossification occurs in relation to this peripheral group of cartilage cells an exostosis results. The primitive connective tissue cells may continue to proliferate when there is an absence of calcium in the adjacent zone of preliminary calcification and a fibrous tissue mass may occur. The resultant picture is a conglomeration of stunted growth, exostoses, enchondromas, ecchondromas and cystic appearance, and when one of these predominates names have been applied to the clinical picture.

Achondroplasia—Dwarfism
Metaphysial aclasia—Exostoses
Dyschondroplasia—Cyst formation
Multiple chondromata—Enchondromas
Chondro-osteodystrophy—a mixture of all.

ACHONDROPLASIA

(Chondrodystrophia fœtalis)

In the disturbance known as achondroplasia, the development of the bones laid down in cartilage is at fault. The membranous bones are formed, and continue to develop, normally. The disease has been known since the earliest times, for achondroplasts are dwarfs with easily recognizable features Their intelligence is often above average, and their physical strength great. The Egyptian goddess Ptah was an achondroplast, and achondroplasts were regularly installed as court jesters in the Middle Ages. Achondroplasia has been characterized by Harris as the most extensive form of perverted bone growth compatible with post-natal viability. There are different degrees of the disorder nevertheless, and in very severe cases the fœtus dies *in utero* and is aborted A number are stillborn and it is as a result of the

The Skull. The portion of the skull developed in cartilage—the base—is grossly abnormal Instead of the usual centres of ossification for the pre- and post-sphenoid and the basi-occiput, there is an irregular single mass of bone formed by synostosis of the individual centres. In consequence of this synostosis, the growth of the skull base is retarded—it remains short while the remainder of the skull grows normally. The vault comes to be more globular in form, and is expanded to make room for the developing brain since little or no contribution to the available intracranial space is made by the base. The fontanelles are correspondingly enlarged.

The smallness of the base of the skull is responsible for the marked depression at the root of the nose and for the flattening of the face.

The Vertebral Column. The vertebral column is of normal length, but the centres of ossification of the bodies may be smaller than normal. Often there is a long regular kyphosis at the lumbo-dorsal region or it may be lower so that all the lumbar vertebræ are included and the sacrum is horizontal The most striking feature is the early synostosis between the body and the arch, which in some cases is so severe as to lead to marked diminution in the calibre of the vertebral canal

The membranous bones, the ribs and sternum, are of normal adult development

Histological Features

The most striking feature of the histology of the growth area of the achondroplastic long bone is the great absence of cartilage proliferation, so that the normal—and necessary—palisade arrangement is absent. Ossification is accordingly greatly hindered by the absence of the normal scaffolding It does take place—and the achondroplastic bone grows in length, but the process is very slow. The deposition of sub-periosteal bone, on the other hand, proceeds at normal pace, so that the diameter of the bone is maintained The retardation at the growth-line may lead to an indragging of the periosteum which is attached to the growth-cartilage, and the osteogenic layer of the infolded periosteal shelf may deposit a layer of compact bone over the peripheral part of the metaphysis This is a secondary phenomenon

Harris has drawn attention to another feature—a widespread mucoid degeneration of the cartilage cells, the cells become swollen, the capsules distended, and the matrix of semifluid consistence The mucoid change is patchy, and intervening between the mucoid areas may be areas of normal cartilage proliferation, and of ossification, but the presence of the mucoid areas renders the normal growth in length and the maintenance of the exact form of the bone impossible

The Explanation of the Process.

Achondroplasia appears sporadically, but there is a distinct hereditary tendency.

The exact nature of the process is not known. Jansen attributed

to the lower part of the thigh. The central point of the body, normally at the umbilicus, is situated much higher, sometimes as high as the xiphoid process. While the proximal segment of the limbs is most affected, the achondroplastic hand is also short and broad, with the fingers of equal length. With the hand outstretched, the fingers diverge in a characteristic fashion, to which Marie has applied the term "main en trident"

The short limbs, especially the lower, are often curved. This is due to an angular displacement of the two components of the knee, the articular surface of the tibia looking slightly outwards.

The trunk is practically normal, and the impression conveyed is of the body of an adult to which are fitted four childlike limbs.

The head is both absolutely and relatively enlarged. Its shape is rounded and markedly brachycephalic. The face is broad, and at the root of the short nose is a characteristic depression or indentation. The upper alveolar processes protrude, and prominence of the lower jaw results in prognathism. The sacrum is tilted and in consequence contracture of the pelvic inlet follows, while the outlet is correspondingly increased.

Intellect. Achondroplasts are usually of normal or even above normal intelligence, and frequently they are lively and amusing. In some cases, however, the intellect is impaired and they are backward for their age.

Because of their deformed bodies they have strong feelings of inferiority and are emotionally immature and are often vain, boastful, excitable, fond of drink, and sometimes lascivious Sexual development is usually normal, but may be retarded. Dwarfs are very muscular and excel in feats of strength; they are frequently employed in theatres and circuses, partly because of their strength, and partly because of their grotesque appearance.

Pathology

The Long Bones of the Limbs. These bones are exceedingly short. In other respects the shaft is normal, the muscular prominences are pronounced, and the thickness of the shaft is often equal to that of the normal bone The ends of the bones roughly preserve their usual form. Hughes Jones has pointed out that in the achondroplastic fœtus the epiphysis is practically indistinguishable in size and shape from that of the normal. It would seem, however, that this is not invariably the case, and Knaggs believes that the epiphyses are disproportionately large, and roughly shaped.

The long bones are often abnormally curved or bowed, and all changes tend to be most marked in the proximal bones of the limbs, though the metacarpals and metatarsals also show characteristic changes

The short bones of the limbs—the os calcis, etc.—are usually remarkably normal in architecture.

and this can be done by an X-ray examination of the epiphyses The epiphyseal outline is distinct, as there is a considerable deposit of lime; in rickets, on the other hand, the epiphyseal outline is blurred and ossification delayed.

Achondroplasia may be confused with cretinism, but in the latter there is mental deficiency and stupidity. In cretinism the essential feature is delay in ossification. In some cases it is associated with stippling of the epiphyses and calcium deposits.

Prognosis

The prognosis varies with the degree of the affection, but apparently the achondroplast may live to a considerable age.

Treatment

No known treatment has any effect on the course of the disease.

CHONDRO-OSTEO-DYSTROPHY

Chondro-osteo-dystrophy includes a number of complicated and ill-understood deformities, some of which have previously masqueraded



Fig 53 —Chondro-osseou-dystrophy. Morquio type

under a different name The earliest cases were reported about the same time by Brailsford and Morquio

In well-marked cases the individual is dwarfed and often late in walking. The intelligence may or may not be normal

Pathology

According to Brailsford, this condition, which bears a superficial resemblance to achondroplasia, is really distinct from it in that the

it to increased amniotic pressure, either from hydramnios or undue smallness of the amnion, both of which he supposed to lead to ischæmia and consequent disturbance in growth. Fairbank has suggested a hereditary defect in the inherent pattern of the bones There is some suggestive evidence that a like condition in animals is associated with an error in development of the pituitary gland, and it may well be

FIG 52.—Achondroplasia

(a) Typical appearance of the bones of the arm Squat, short and broad, with broadened metaphyses. (b) Similar changes in the leg bones

that an endocrine disturbance is the factor responsible for the deficient proliferation, or for the degeneration, of the cartilage

DIAGNOSIS

With such a very striking clinical picture, there should be little difficulty in diagnosis. The disease has to be differentiated from rickets,

an irregular and imperfect manner (Brailsford). Sometimes the development of the articular processes is also defective, and when this is so one or more of the vertebral bodies, usually at the apex of a kyphus, may be squeezed backwards out of line with the remainder of the spine

Brailsford believes that various degrees of the anomaly may be encountered Thus the whole skeleton may be involved ; or only the spine , or the spine and hips , or the whole skeleton may be affected, but the condition is arrested before deformity arises.

Clinical Features

In many cases the attention of the parents is attracted by the occurrence of a spinal kyphosis at the dorso-lumbar or cervico-dorsal region This, according to Brailsford, may be so marked and the other evidences so obscure as to lead to a diagnosis of spinal caries Later, other features arise, though they may even precede the spinal deformity. There is a failure to gain normal height and the development of symmetrical deformities which increase, with progressive crippling, until the child is unable to walk without aid. The typical appearances are those of a round-backed, knock-kneed, flat-footed child who stands with hips and knees flexed in a crouching position, with the head thrust forward and sunk between high shoulders, looking not unlike a case of cervical caries and walking in the waddling manner of a duck (Morquio, 1929.) By the age of 5 or 6 the child has usually developed into a dwarf of striking appearance, since the trunk is small out of all proportion to the length of the limbs

In addition to the swelling at certain of the joints, deformity may arise, for example ulnar club-hand, coxa vara, and genu valgum

Fairbank points out that in some cases there is also enlargement of the liver and spleen, mental deficiency, and corneal opacity.

MULTIPLE OR GENERALIZED OSTEOCHONDRITIS

Under this description Dickson Wright has reported a case in which almost every epiphysis in the body became fragmented and distorted, as in the common osteochondritis deformans juvenilis There was an associated retardation of growth in the spine

Several other examples of multiple foci of osteochondritis have been reported, but in several there have been changes in the metaphysis also, and Brailsford and Fairbank believe that the disease is a particular type of chondro-osteo-dystrophy

DYSCHONDROPLASIA

(Ollier's disease)

There has been a tendency in the past to regard the condition which Ollier described in 1899 as dyschondroplasia as identical with

child is apparently normal at birth, and it is the subsequent development of the skeleton which is at fault.

The growth in length of the shafts of the long bones is interfered with, and at each end of the shaft the metaphysis is irregular. The epiphyseal cartilage is increased in thickness, and the articular cartilage is also thicker than normal. The epiphyseal centres of ossification usually appear as multiple foci, which gradually fuse, but in joints subjected to pressure, the irregular epiphysis appears to be unable to withstand the strain, and distor-

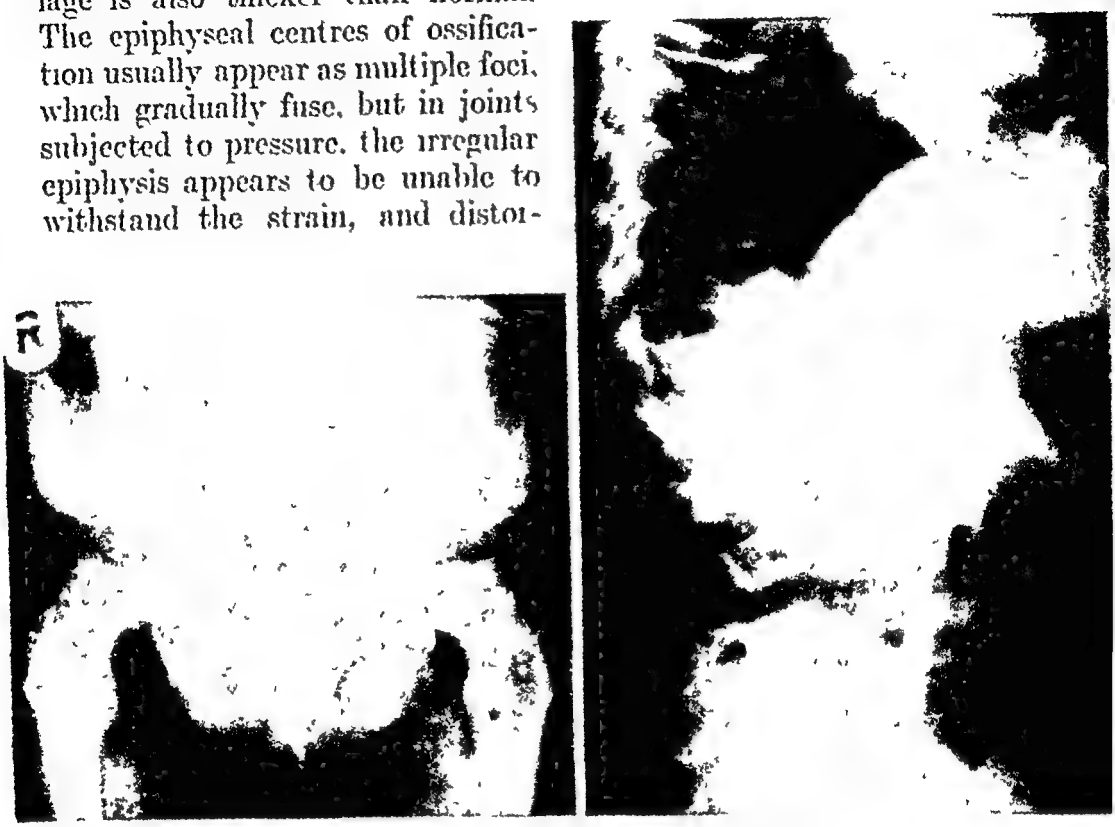

(a) (b)

Fig 54.—Chondro-osteo-dystrophy (a) Characteristic appearance of pelvis, showing ape-like shape of the pelvis and the large irregular acetabulae (Dr Wm McLeod's case) (b) The appearance of the spine, showing tongued vertebral bodies (Dr Wm McLeod's case)

tion, compression, or fragmentation of the epiphyseal bone occurs.

In the forearm the ulna grows more slowly than the radius, and a degree of club-hand may develop. At the hip, coxa vara may result with an appearance in the epiphysis similar to that of Perthes' disease.

The changes in the vertebral column are very important. The dorso-lumbar and cervico-dorsal areas are the most commonly affected sites, and in these segments the vertebral bodies may be irregular in shape, size and position, the middle third of the anterior surface projecting forwards like a tongue beyond the upper and lower thirds. The upper and lower angles of the body may show gross irregularity of outline; the vertebral bodies may be compressed and deformed by the weight of the superincumbent spine, giving rise to clinical deformity, and when the secondary centres appear they do so in

(c)

FIG. 55.—(c) Dyschondroplasia of the Pelvis

well as differentiation. Sometimes one or more of these processes will be delayed and the dissociation of each evokes its own characteristic symptoms.

RADIOLOGICAL APPEARANCES

The typical appearances may be seen near the ends of the diaphysis in the long bones—humerus, femur, radius, etc , or in the short long bones of the hands and feet Usually the more rapidly growing ends of the bone are involved

The metaphysis is usually broadened and its texture poor It presents a cystic appearance bridged across by a series of fine septa which tend to run in parallel lines or stripes in the long axis of the bone Occasionally small exostoses project from the surface These are less well formed than in metaphysial aclasis, and are usually taken to represent the diaphysial limit of the affected area of the bone.

the condition variously known as metaphysial aclasis, diaphysial aclasis, or hereditary deforming chondrodysplasia. There are good reasons for separating the two lesions, but it is nevertheless certain that cases intermediate between them occur. Indeed, there are some who regard all the congenital anomalies of cartilage growth at the growing ends of the long bones as variations on a single theme.

Dyschondroplasia may be unilateral or bilateral; it is perhaps more common as a unilateral affection and occasionally it may be confined to a single bone.

Pathology

The disease is one affecting cancellous bone formation in the metaphyseal region so that cartilage persists abnormally. Six different processes, and probably more, have to co-operate harmoniously in order that the bones shall attain their proper size, shape, structure and composition when completing their growth. These processes are resorption, tubulation, cancellation, cell division, cell enlargement, as

(a) (b)

Fig. 55.—Dyschondroplasia (a) Of the Right Tibia (Mr Mason Brown's case). (b) Of the Hand.

presents itself on both sides It is a hereditary retardation phenomenon transmitted without regard to sex

The disease usually becomes apparent during the first years of life. When unilateral, it is seen that one limb is not growing at the same rate as its fellow. When bilateral, the general growth appears to lag. Sometimes the enlargement of the affected hand bones is the earliest feature to attract attention

Later deformity may appear. It is due to weight-bearing, or to unequal affection of the metaphysis, and a consequent difference in the growth rate between the affected and unaffected parts

Maffucci has described a syndrome that bears his name and in which dyschondroplasia is associated with cavernous hæmangiomata and phleboliths of the soft tissues. The bone and soft tissue lesions seem to be entirely independent in their distribution.

Prognosis

The prognosis as regards life appears to be good In some cases quoted by Hunter and Wiles, death occurred from the supervention of sarcoma ; in others anæmia resulted, apparently from the restriction of the available marrow space.

Deformity and secondary arthritis are constant sequelæ.

Treatment

This condition is not a disease but attests to a lack of harmony among the various processes of normal bone growth, and surgical interference is warranted only when there is a mechanical interference with joint function and after epiphyseal growth has ceased

Multiple Enchondromata

This term was formerly applied to a disturbance of growth in which multiple cartilaginous tumours were present in the shafts of the short long bones of the hands and feet Ollier pointed out originally that such a condition accompanied the changes in the metaphysis of long bones which he called dyschondroplasia Nevertheless, multiple chondromata were usually regarded as a distinct entity. Hume suggested that they were often present in association with metaphysial aclasis, but that there are obvious differences has of late been stressed by Fairbank, Brailsford, Hunter and Wiles, amongst others It is now generally believed that in all cases multiple enchondromata are a manifestation of dyschondroplasia

In the account of dyschondroplasia, it was indicated that in contradistinction to the metaphysial changes of the long bones, the features met with in the short long bones may be different In this situation considerable deformity may arise as a result of the presence of masses of cartilage in the bone ends Thus the bone may be grossly expanded, and the expansion may be regular, with faint bony

In the short long bones the appearances may be exactly similar, or there may be multiple enchondromata.

In the ilium Hunter and Wiles have pointed out that the disease affects a fan-shaped area, with the apex at the nutrient artery; a characteristic appearance of striping is again produced.

The ischium and the pubis may appear fluffy and stippled, due to the presence of small rounded areas of cartilage.

The epiphyses are unaffected at birth (Hunter and Wiles) but later may also appear speckled.

As the child grows, the striping of the bones is replaced by irregular mottling and speckling, and the affected bones are stunted.

Differential Diagnosis

Hunter and Wiles point out that a positive diagnosis can be made on three main points:

1. The onset is in early childhood.
2. The changes are limited to the ends of long bones.
3. Biopsy reveals that the clear areas in the radiogram are composed of cartilage.

Metaphysial aclasis can be excluded by its striking hereditary tendency, by the invariable presence of multiple exostoses which are pedunculated and usually point away from the end of the bones. In metaphysial aclasis, the metaphysis is always expanded and the sides of the broadened area are usually parallel; there is a sharp line of demarcation between the expanded area and the normal shaft—an appearance well described by Keith as "trumpeting." In dyschondroplasia the metaphysial expansion, when present, is fusiform in outline.

Multiple enchondromata. The appearance of multiple enchondromata may be present in radiological studies of the hands and feet in dyschondroplasia. When multiple enchondromata occur alone, therefore, there is some justification for regarding it as a localized form of the more extensive disease.

In *osteopathia striata* there are lines of increased density in the metaphysis. The less dense areas, however, are not due to masses of cartilage but to bones of normal texture.

In *osteopoikilosis* there are again rounded or elongated areas of increased density, but these are scattered throughout the entire bone, and are often arranged in the long axis of the bone.

The age of onset, the number of bones affected, and the characteristic metaphysial change are sufficient to exclude the generalized fibrocystic diseases.

The Clinical Features

The clinical picture is characterized by its extreme polymorphism. In some cases only a single bone is affected, while in others the condition

the cristal border of the ilium, the vertebral border of the scapula, and occasionally at the neuro-central synchondroses of the vertebræ.

The two principal features of the disease are—

1. The unmodelled metaphysis
2. The exostoses.

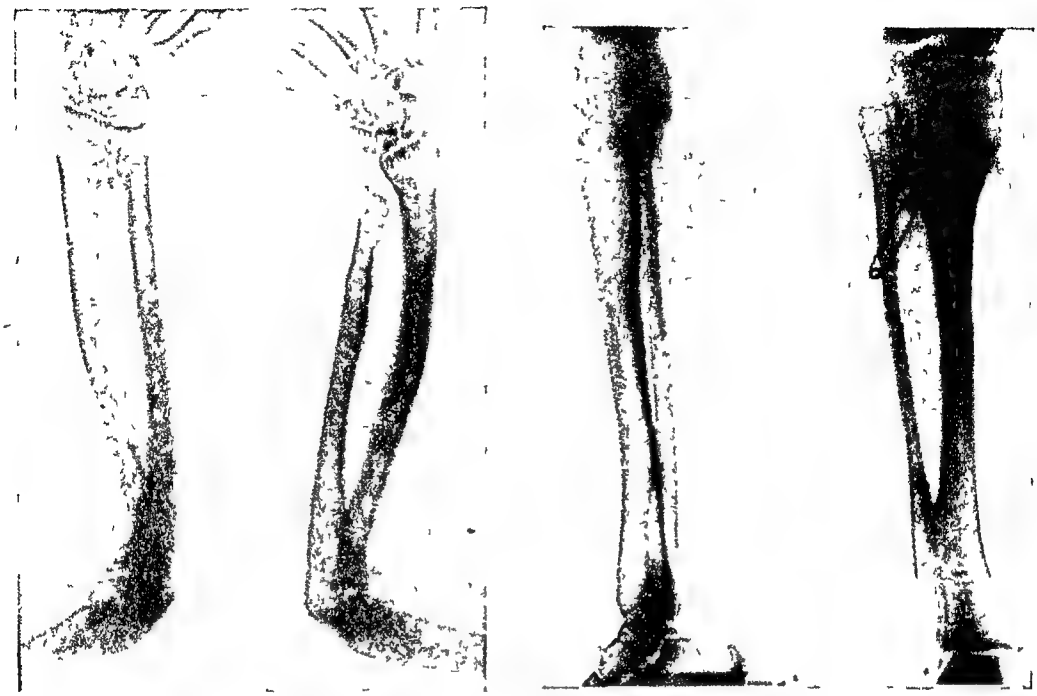

(a) (b)

FIG 56 —(a) Metaphysial Aclasis of Forearm Bones, (b) Metaphysial Aclasis of Leg Bones

The Unmodelled Metaphysis. This may or may not be the most striking part of the anomaly The central part of the shaft is usually of normal cylindrical form, and of normal calibre. As the bone is traced towards its extremity it will be found that instead of the calibre of the bony tube increasing gradually, there is an abrupt increase in diameter, and the extremity of the bone—the metaphysis —is in the form of an irregular cylinder with roughly parallel sides. In the growing bone this cylinder is composed of ill-trabeculated bone and the surface is covered with a layer of cartilage continuous with the epiphyseal cartilage In many cases irregular projections—exostoses—appear on the surface, and occasionally surface projections may be present without increase in the size of the parent bone

The Exostoses. These are the most singular feature Normally most marked at the extremities of the bone, they may be found at practically any part of the shaft Frequently an exostosis marks the junction of the normally calibrated shaft and the expanded extremity. At this situation they are irregularly spiky Others occur in relation

striations along the periphery of the expanded area. These striations have been likened by Brailsford to the striations of onion layers. As the chondromatous tissue grows, more and more of the bone is destroyed, until little may remain of the affected bone save a few scattered bony fragments embedded in irregular striped masses of exuberant chondromatous tissue.

Clinical Features and Treatment

The hand and foot disturbance is often associated with gross deformity of a most unsightly nature, and the considerable weakening of the bones which results may lead to pathological fractures.

Brailsford points out that judiciously performed operative removal of the excess cartilage in the areas of greatest deformity or maximal weakness will improve the appearance and minimize the risk of fracture.

METAPHYSIAL ACLASIS

(Multiple exostoses, diaphysial aclasis, hereditary deforming dyschondroplasia)

This is one of the most interesting of the developmental growth disturbances, and may well prove important as an intermediate condition between achondroplasia and the other disturbances of enchondral ossification.

The disease affects only those bones, or portions of bones, which are developed both from cartilage and from membrane, and it has a well-marked hereditary tendency.

The most characteristic features of metaphysial aclasis are a failure of remodelling of the metaphysis and the occurrence of multiple outgrowths or exostoses from the surface of the shaft of many of the long bones. In addition there is often some stunting of skeletal growth. Originally known as multiple exostoses, the disease was renamed diaphysial aclasis by Sir Arthur Keith, but later Greig pointed out that it was really a metaphysial affection and suggested the title here employed—metaphysial aclasis.

Pathology

The membranous bones of the skeleton are immune, as are those developed entirely within cartilage, such as the tarsal and carpal bones and the epiphyses of the long bones. The condition affects those parts of the skeleton where bone arising in cartilage comes to be surrounded by a sheath of sub-periosteal bone—hence it is found at the growing ends of the long and the short long bones. It is most marked where growth is most extensive and most prolonged, i.e. the distal end of the femur, the proximal ends of the tibia and fibula, the distal ends of the radius and ulna, and the proximal end of the humerus. It is also well seen at the medial and lateral ends of the clavicle, at

at birth, obvious evidence of its presence appears only after seven or eight years, when growth is speeded up and the exostoses become apparent Exostoses situated towards the mid-shaft have commenced to grow at an early age, and been gradually displaced to their mid-shaft position by subsequent growth in length of the bone

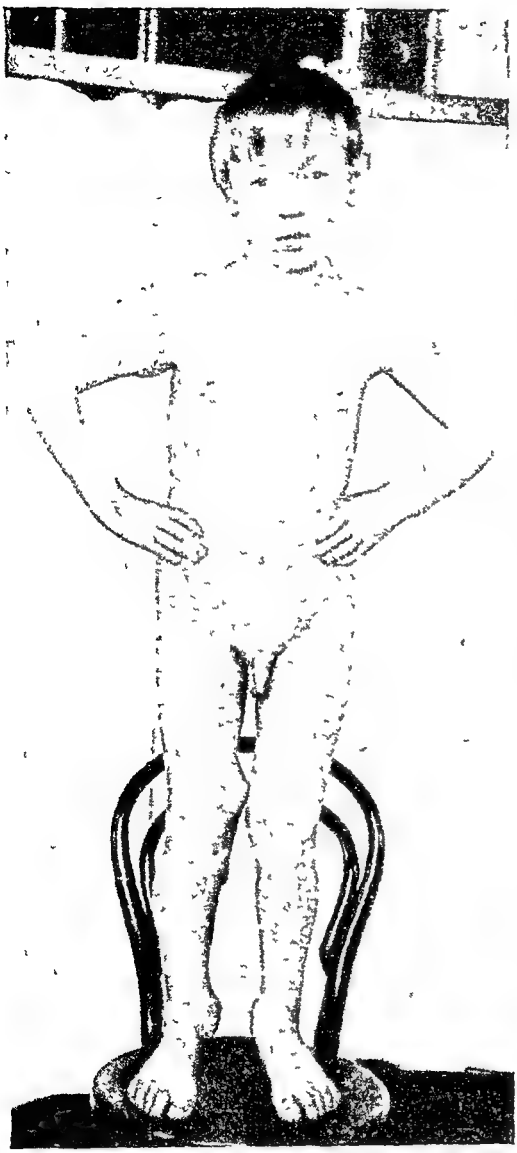

Fig 57 —Metaphysial Aclasis Multiple Exostoses (Hereditary Deforming Dyschondroplasia) —An example of the disease in a boy 10 years old (Professor Edwin Bramwell's case)

Note particularly the multiple exostoses around the upper end of the right humerus

Clinical Features

The process may be local or diffuse. When local, one of the extremities is involved, while the remainder of the skeleton is normal. In the diffuse type there may be extensive distortion and deformity of the whole skeleton.

The stature is short or even dwarfed. In addition the limbs may show deformities of the nature of bowing, or knock-knee. Fracture from slight trauma is common, but the fragments unite as readily as in normal individuals.

The most typical feature is the presence of numerous exostoses. These are most common at sites of active growth, such as the knee and shoulder The projections are hard, the skin overlying them is normal, and the soft tissues move easily on them.

They may be associated with pain if the tumour presses on a peripheral nerve or a nerve root, or if the process is inadvertently fractured.

They are also liable to interfere with the free play of associated tendons, or may even act as a mechanical obstruction to joint movement, in which event they may give rise to considerable disability.

A bursa may form over the projection and become from time to time inflamed.

Radiological examination shows an irregularly expanded metaphysial mass, with little or no compact cortical bone. The

to the unmodelled extremities and these tend to be more globular in shape. As the shaft increases in length those exostoses at first near the epiphyseal cartilage are displaced farther up the shaft In addition they may become obliquely disposed to the shaft, with their extremity directed away from the extremity of the bone.

The exostoses are composed of poorly trabeculated bone in direct continuity with the bone of the shaft. During the years of growth the exostosis is surmounted by a cap of cartilage, from which progressive growth in size of the exostosis may take place

In association with the above features there is usually well-marked interference with growth in length of the affected bones. From irregularity of the ossification at the epiphyseal line some cartilage cells are not ossified. Those that are central, if they continue to grow, form enchondromas while the peripheral ones form exostoses. It is essentially a failure of maturation of the cartilage cells. In the forearm the growth of the ulna is more interfered with than that of the radius, and in consequence, it may be, the radius becomes curved, or dislocation occurs at its proximal extremity. In the leg the fibula lags behind the tibia. In the forearm and the leg an exostosis from one of the bones may cause pressure absorption of the adjacent surface of the neighbouring bone.

The changes in the short long bones are essentially similar and are not to be confused with multiple enchondromata, which is part of the disturbance of *dyschondroplasia*

Two occasional complications of metaphysial aclasis must be mentioned:

(*i*) The occasional growth of a *chondroma* which projects from the surface of the bone near the epiphyseal cartilage. Such a tumour may attain great proportions and is liable to become chondro-sarcomatous

(*ii*) *Osteogenic sarcoma* may arise in one of the exostoses, sometimes following, but occasionally in the absence of, operative removal. This leads to rapid increase in size of the exostosis.

The Nature of the Process.

Keith originally showed that the essential factor in the disease is a failure of the normal remodelling process which trims the metaphysis down to the calibre of the remainder of the bone. To this normal remodelling and adapting process Jansen applied the term "tubulation" In addition to the failure of normal tubulation, however, the exostosis possesses a power of continued growth equal to that of the parent bone Keith accordingly supposed that the growth of the sheath of sub-periosteal bone did not keep pace with the growth of bone from the growth cartilage, and the absence of the normal bony ferrule left the cartilage of the growth disc uncovered on the surface, and free to give rise to irregular excrescences.

The Time Factor in Metaphysial Aclasis.

Though the tendency to the disease is usually inherited and present



(*a*) (*b*)

FIG 58 —(*a*) Polyostotic Fibrous Dysplasia showing Pigmentation (*b*) Polyostotic Fibrous Dysplasia (Albright)

FIG 58 —(*c*) Polyostotic Fibrous Dysplasia The same case 8 years later (By courtesy of Dr Wm McLeod)

architecture of the interior is altered. The normal cancellous tissue is replaced by a mass of less dense tissue, in which islands of normal ossification may be observed.

The exostoses appear as definite projections from the metaphysial region. Their structure is similar to that of the metaphysis—clear interior, with a thin shell of cortical bone

Prognosis and Treatment

The disease has no effect on the general health, but there may be grave disability as a result of nerve pressure or interference with joint movement. Malignant degeneration with formation of osteogenic and chondrosarcomata has been recorded.

The only treatment indicated is the symptomatic one of removing exostoses which are giving rise to trouble.

POLYOSTOTIC FIBROUS DYSPLASIA

(Osteitis fibrosa juvenilis chronica; osteodystrophy fibrosa; regional fibrocystic disease; osteitis fibrosa in multiple foci; unilateral Recklinghausen's disease; osteodystrophic fibrosis cystica generalisata, focal osteitis fibrosa; osteitis fibrosa disseminata; Albright's disease)

Although the etiology of this disease is unknown the essential lesion appears to be a congenital disorder of the bone-forming mesenchyme. Other theories presented are those of a neurological lesion stimulating the pituitary to abnormal secretion, and a hyperphosphatemia stimulating the parathyroids to give a chronic hyperparathyroidism The latter is the basis of aluminium acetate treatment where one attempts to fix the phosphates of the bowel as an insoluble aluminium phosphate and thus reduce the hyperphosphatemia.

The disease usually appears in childhood or puberty with cyst formation in the diaphysis or metaphysis, but rarely in the epiphysis, of long bones The bones most frequently involved are the femur, tibia, humerus and radius Bending deformities of the weight-bearing bones and pathological fractures with slow or non-union are frequent occurrences. Blood calcium and phosphates are usually normal and occasionally the alkaline phosphatase is raised, probably denoting compensatory osteogenesis. The parathyroids are normal.

The X-ray shows expansion of the bone and thinning of the cortex with numerous trabeculated cystic areas which contain giant cell collections, fibrous tissue, and collections of cartilaginous tissue It is usually a unilateral disease affecting multiple long bones. When it affects only one bone it is then known as monostotic fibrous dysplasia, and when restricted to one limb as monomelic fibrous dysplasia

The treatment is that of the deformities and prognosis is good as it is a self-limiting disease. The use of aluminium acetate has been suggested

In differential diagnosis from hyperparathyroidism, this latter

(*d*) Vitamin deficiency
Rickets
Osteomalacia.
Scurvy

1 *Hereditary Hypoplasia of the Mesenchyme* (*Familial Fragility*)

The long slender bones are usually affected and on X-ray have wide marrow and narrow cortex, or small marrow spaces with normal cortical thickness

It is a hereditary dominant disease, never skips a generation, and has no predilection for a sex. Fractures appear at about the eighth year The stature is stunted, the joints hypermobile, china blue sclera, and deafness frequently appears after adolescence. Among adults with blue sclera 60 per cent. have associated fragile bones, and 60 per cent. have associated deafness

2 *Osteogenesis Imperfecta* (*Osteopsathyrosis congenita, Annular Rickets ; Vrolich*)

Knaggs has made a comprehensive contribution to the pathology of this condition. He has shown that in osteogenesis imperfecta the epiphyseal cartilage is of normal extent and the zone of calcified cartilage is normal in appearance ; but that in the zone of ossification—the metaphysis—the trabeculæ are slender and delicate, and widely separated by interstices filled with cellular connective tissue or fibrous marrow. No cross trabeculæ are present as a general rule The periosteum is thick, and there is no compact cortical layer of bone, but delicate and discrete sub-periosteal trabeculæ.

Fig 59 —Osteogenesis Imperfecta Cystica (By courtesy of Dr Wm McLeod)

The bones as a general rule are shorter, smaller and thinner than corresponding bones of normal individuals at a comparable age, so that the general skeletal development tends to be stunted

In most cases there have been many healed fractures, many in bad position The consequent deformity, producing as it does shortening of the affected bones, adds to the dwarfing already present from the feeble osteogenesis.

The Histopathology

The essential feature of the histopathology of Fragilitas Ossium is a scattered defect of the primitive mesenchymal cells in which there is a

disease rarely occurs in the adolescent. The blood calcium and phosphate changes of hyperparathyroidism are absent and on X-ray the unaffected parts of the bones have a normal appearance and do not present the diffuse osteomalacic appearance of hyperparathyroidism.

Albright's syndrome is a variation of polyostotic fibrous dysplasia where the disease is in a female and is accompanied by sexual precocity and flat pigmented areas of skin. Here it is thought by some to be due to excessive hormonal secretion. Prolan A causes sexual precocity in the female but not in the male and this is strongly suggestive of excessive Prolan A being related to the bone pathology.

MONOSTOTIC FIBROUS DYSPLASIA

In this condition a single bone is the site of partial replacement of its substance by fibrous tissue, with or without the additional presence of osteoid. If present, osteoid is occasionally calcified and cysts are occasionally formed Any bone may be involved. The blood chemistry is within normal limits. The clinical findings are local swelling where the bone is superficial and pain if the lesion is near a joint Schlumberger suggests that the condition may represent a disturbance of the normal bone reparative process following trauma.

OSTEOGENESIS IMPERFECTA

According to the time of origin of idiopathic osteopsathyrosis various terms have been applied to the same pathological process Osteopsathyrosis may be essential or idiopathic, also called Lobstein's disease, or secondary to a number of other conditions such as simple or inflammatory osteoporosis, rickets, osteomalacia, etc Osteogenesis imperfecta or Vrolich's disease has in common extreme fragility of bones but it originates in fœtal life and does not carry the characteristic hereditary features, furthermore it causes dwarfism with micromelia and is responsible for a poor general condition.

A useful classification of brittle bones is—

1. Hereditary type—hereditary hypoplasia of mesenchyme
2. Non-hereditary congenital type—osteogenesis imperfecta (osteopsathyrosis congenita, or annular rickets, or Vrolich) a fœtal, b. infantile, c adolescent
   (i) Osteopsathyrosis with white sclera.
   (ii) Osteopsathyrosis with blue sclera.
3. Acquired type
   (a) Idiopathic
      Osteosclerosis fragilis generalisata
      (Marble bone · Albers Schonberg's disease)
   (b) Osteoporosis.
      Disuse
      Trophic.
      Local disease.
      Pressure.
   (c) Endocrine—hyperparathyroidism

activity of primitive mesenchymal cells attempting to compensate for the weakness of the bone.

Clinical Features

It is possible to recognize several types of clinical case. In all of these the pathology is similar, and the difference, which is largely one of age, is the result of the different grades of severity of the disease.

In the *fœtal form*, the disease is severe and the child is stillborn or survives only a very short time There are multiple fractures, some healed, at birth, while the cranium shows grossly imperfect ossification, and consists merely of a membranous bag with a few plaques of poor bone embedded in it It is probably the damage imposed on the imperfectly protected brain during labour that results in stillbirth.

In the *infantile form*, a less severe form of the disease is present. At birth there may be some stunting and evidence of fractures, but the ossification of the skull is more advanced The child survives for a year or two, but the bones are fragile and break at a touch The skull may assume a globular shape and may appear large in proportion to the rest of the body True hydrocephalus may develop, and this again may be related to intracranial damage at birth

In the *adolescent type*, often called osteogenesis imperfecta tarda, the child may appear normal at birth, and during childhood the only disturbance observed may be a special liability to fractures from comparatively minor injuries The ossification of the skull may be almost perfect, but one or two soft areas may be found on examination. As time passes, the tendency to fracture on slight provocation is lost

The disease may on rare occasions be encountered first in adult life, when a case which was slight at birth and during adolescence becomes active, or when a case which has regressed spontaneously is re-activated.

Prominent features are

1 The stunting of growth.

2 The occurrence of fractures from trivial violence. The fractures are often sub-periosteal and unite readily, often more so than in normal bone, and the callus is often more dense than in normal bone. The fractures are distinctive in that they cause little or no pain or tenderness—largely because they are sub-periosteal It is largely for this reason that so many are allowed to heal with deformity. Sometimes the fractures are associated with mild febrile attacks.

3. The occurrence of blue sclerotics. This has been observed in the infantile and late types of fragility, and is due to increased visibility of the pigmented choroid through an abnormally translucent sclera. Apparently there is no alteration in the thickness of the sclerotic or in its histological structure, so that its translucency is said to be due to some alteration in the quality of the fibrous tissue composing it In this connection it is interesting to note that when blue sclero-

failure of maturation and calcification. These abnormal cells enlarge to resemble in appearance cartilage cells. Normally at the epiphyseal line the primitive mesenchymal cells should arrange themselves in an orderly manner about the invading capillaries of the metaphysis. The arrangement is irregular and as bone is elaborated the swollen defective primitive mesenchymal cells are enclosed within the irregular Haversian systems A similar pathological differentiation of the primitive mesenchymal cells occurs in the subperiosteal region where there is no normal compact bone.

The Nature of the Bone formed. The bones are extremely fragile. This is partly due to the absence of a well-formed cortex, to the sparse and widely separated trabeculae, and the nature of the osseous substance which is less compact than the ordinary laminated bone. The bone is liable to undergo osteoclastic absorption and also in late cases, appears to undergo spontaneous disintegration

Etiology

There is a well-marked hereditary factor in osteogenesis imperfecta. Beyond that, nothing positive is known of its cause Knaggs has made the suggestion that since the outstanding feature of the disease is a failure to produce osteoblasts there is an inherent and hereditary inability on the part of the mesoderm to produce this highly specialized cell In consequence it produces the best cell of which it is capable—the cartilage cell—so that only, or mainly, metaplastic bone is laid down.

Fig 60.—Osteogenesis Imperfecta, showing Deformities.

Of innumerable etiological factors only thyroid dysfunction seems to constitute a positive finding, the basal metabolic rate usually being increased by 30 per cent Cortical supra-renalism may also be considered but the role of the spleen in osteopsathyrosis is rather dubious.

The raised serum alkaline phosphatase which is a frequent finding is probably due to the

and often deformed shaft, the ends of the bones are expanded and show coarse cancellation with poor density Ultimately the long bones may appear as two poorly calcified end bulbs joined by a slender rod of denser bone.

The ribs are usually bent sharply downwards at their angles, and the thorax is therefore greatly deformed. This may be accentuated by the occurrence of scoliosis. The pelvis shows asymmetrical and irregular deformity. The skull shows irregular ossification, with islands of denser bone in a poorly calcified matrix—the so-called Wormian bones.

Diagnosis

The diagnosis is usually evident, but occasionally rickets may afford some difficulty, especially since fractures are common. In rickets, however, the radiological picture is characteristic—the epiphyseal cartilage is broad and fuzzy, the edge of the metaphysis to the zone of calcified cartilage is irregular and poorly defined, and the metaphysis itself is cup-shaped and expanded. On the other hand, the rarefaction of the rest of the bone is considerably less than in osteogenesis imperfecta

Prognosis

In the majority of cases death is the outcome Occasionally adult life is reached, but the constant occurrence of fractures, the repeated confinement to bed, and the forced inactivity make it burdensome. In only a very few cases is the condition apparently arrested, and the liability to fracture lost

Treatment

No specific treatment is known Measures, dietetic and otherwise, to promote the general well-being are indicated Care should be exercised in handling children with the disease, but when fractures occur they are treated along the usual lines, and if healing takes place with deformity osteotomy may be carried out

OSTEOPETROSIS

(Albers-Schonberg's disease, marble bones, osteosclerosis fragilis generalisata, congenital osteosclerosis)

Albers-Schonberg, in 1904, was the first to describe a rare bone disease associated with increased density of the skeleton Less than 40 examples of the condition have been described, and the disease has been known by many titles, some of which are indicated above. The condition has not infrequently affected several members of a family, and there have been minor differences in the pathology of the

tics are present without fragility of the bones there is a peculiar liability to sprains and joint disturbances.

4. The skull shows broadening of the forehead, angular projections above the zygoma, a downward tilting of the axis of the orbit, ear and auditory canals, and an underhung jaw.

Radiological Appearances

These depend on the age of the patient and the severity of the condition. The bones in severe types may show practically complete absence of cancellous texture, the cortex appearing as a faintly

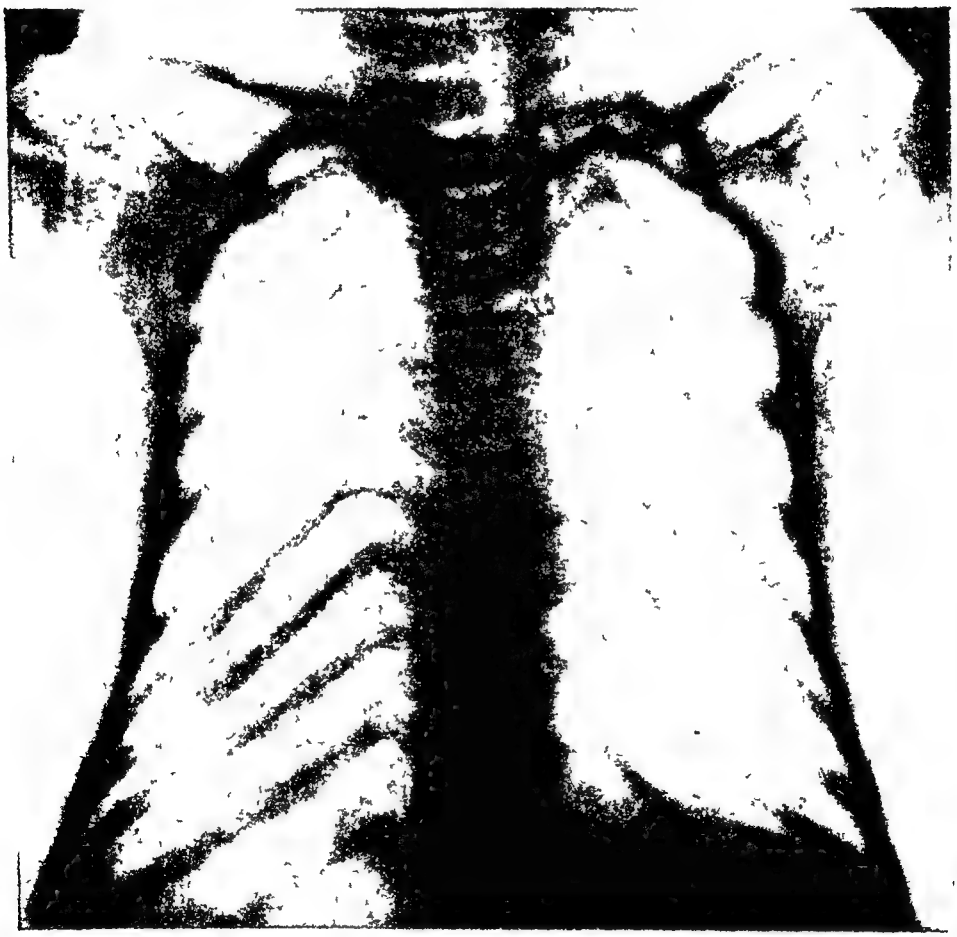

Fig 61.—Osteogenesis Imperfecta.

The radiogram of the chest wall of a child suffering from osteogenesis imperfecta Note the delicate outline of the ribs, and the existence of fracture at the angle of practically every rib

pencilled line The bones are shorter than normal, and occasionally broader. In less severe types the long bones are stunted, diffusely rarefied, and may have expanded club-shaped extremities. Fractures, or old deformity following fractures, are often apparent. In adult cases the shafts of the bones appear to shrink, and show a dense, relatively thick cortex with no medulla. In sharp contrast to the slender

bone density in osteopetrosis is not an index of increased strength. Thus it is said to be possible to cut a so-called "marble" bone with a knife, the sensation experienced being similar to that on cutting chalk, so that Pirie has suggested the name "chalky bones" for the

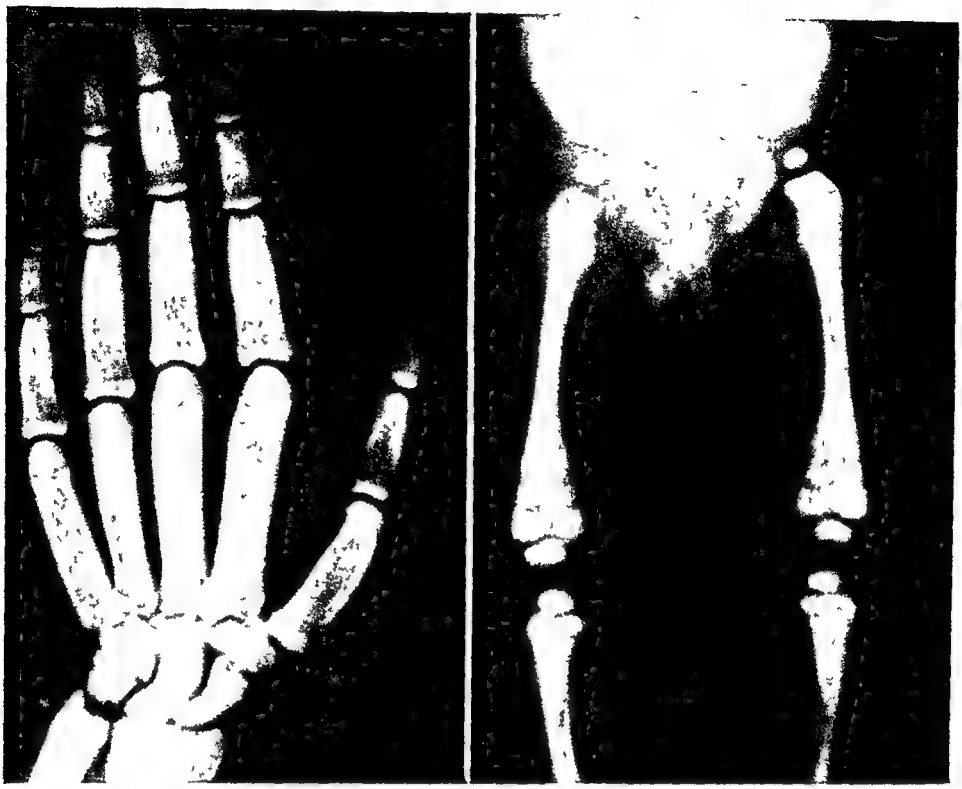

Fig 62 —Osteopetrosis

condition Brailsford is probably correct when he suggests that conflicting statements on this point are due to the fact that the brittleness of the bones depends on the age of the patient and the stage of the disease, since the liability to fracture steadily decreases after adolescence

Histopathology

Microscopically the affected areas are seen to consist of a conglomeration of calcified cartilage masses, bone, necrotic bone, and sclerotic fibrous tissue It is noticeable that the tissues are avascular, the marrow spaces being filled with sclerotic tissue with very few capillaries.

Secondary Pathological Changes. Two sets of symptoms secondary to the bone changes are of importance, as it is usually for these that the patient seeks advice. They are due to the involvement of the hæmopoietic and nervous systems by encroachment of the thickened bone.

The progressive sclerosis of the long bones gradually reduces the medullary cavity and the bone marrow to a degree incompatible with normal blood formation. At first over-activity of the residual marrow

disease in individual families, though it tends to be true to type in the members of any particular group.

Pathology

In this disease both the membrane and cartilage bones are involved. The characteristic change is the increased density and thickness, and complete loss of trabeculation of the affected bone. Any or all of the bones may be affected, and the condition is usually symmetrical. In the case of the long bones, the usual differentiation into cortex and medulla is lost, and the change may affect any part of the bone but is most common at the metaphysis. In the growing long bone, there is no alteration in the size or appearance of the epiphyseal cartilage, but the bony nucleus of the epiphysis may show similar changes. In addition to the loss of architecture the bone density is grossly increased, and the texture appears closely granular. The increased thickness of the bone indicates that the condition affects not only the bone developed from the epiphyseal cartilage, but that growing from the sub-periosteal osteogenic layer.

The most marked changes are found in the most rapidly growing extremities of the long bones—the lower end of the femur and radius, and the upper end of the tibia and the humerus.

Brailsford points out that if hard rays are employed in radiographing the bones it becomes apparent that there are lines of increased density alternating with faint lines of decreased density, though the effect of the whole is to indicate a greatly increased general density.

The ribs are similarly affected—thick, dense, and apparently structureless. The vertebræ may be uniformly dense, or a dense zone at the upper and lower thirds of the body may be separated by a zone of normal density in the middle, indicating that the process is affecting the bone laid down from the cartilage end plates of the body The skull may be so dense that no detail of its architecture can be made out, as in a case of Norman Dott's reported by White The bones of the carpus and tarsus are ringed by a layer or layers of dense bone, the result of peripheral accretions.

The extent of the change depends on the age at which the disturbance begins If it does not commence till after birth, the first indication is a dense streak at the extreme limit of the metaphysis, but if it has commenced *in utero*, even at birth a considerable part of the diaphysis may show the change The disease progresses during the growth period by the addition of further dense accretions, both sub-periosteal and from the epiphyseal cartilage, so that in the adult the bones still show the characteristic changes.

Relation of Increased Density to Bone Strength. It is well known that so-called marble bones are liable to fractures, especially in the adolescent It was for this reason that it was originally grouped with fragilitas ossium. It is generally accepted that the increased

ATYPICAL FORMS OF OSTEOPETROSIS

Melorheostosis (Leri).

The condition was first reported by Leri in 1922, and since then more than thirty cases have been reported. It is a rare condition in which certain bones, or portions of a bone, are petrosed but different in certain ways from ordinary "marble bones." The distinguishing features are: (1) the changes are confined to one limb; (2) the outline of an affected bone is definitely distorted, (3) the presence of pain, often severe; and (4) limitation of movement in the joints formed by the affected bone. The affection is usually limited to one limb, and occasionally to one bone of a limb.

Pathology

A portion of the cortex of one of the limb bones is irregularly enlarged, sufficiently to give rise to a swelling with an undulating surface. Between one undulation and another, a linear band of increased density may extend, which has been likened to a "flow" of hyperostosis The condition is sometimes known as "*Monomelic Flowing Hyperostosis*" Leri employed his original title because the hyperostotic areas in appearance resemble "candle drippings"

Sometimes the lesion is associated with deformity of the affected bone. Thus in the lower limb, bowing of the femur and of the tibia is common.

Kraft has lately distinguished three types of the disease:—

1. Where a whole extremity is affected—in this the dense cortical proliferation appears as a regular and continuous flow from shoulder to fingers, or hip to foot Usually it is limited to one side of the bone, and in some cases appears to occupy the distribution of a nerve or vessel without having any apparent relationship to them

2. In the second group, only half the extremity, the proximal half, is involved

3 In the third group a whole extremity is irregularly involved, and there are multiple interruptions of the flow

Etiology

Nothing is known of the etiology of the condition, but it has been suggested by Moore and De Lorimer that the deformity associated with it is the result of overloading a bone less well adapted to withstand strain, or to the mechanical leverage effect exercised by the hyperostotic processes Fairbank suggests that fibrosis of the marrow may be the fundamental change present.

Clinical Features

Apart from the deformities, or the swellings resulting from the local lesion, there may be "rheumatic pains" in the affected extremi-

results in an increase of reticulocytes and nucleated red cells in the peripheral blood, but later a true aplastic anæmia develops. In attempted compensation there is enlargement of the liver, spleen, and lymphatic glands of the body.

In the skull the thickening is apt to restrict the size of the foramina, leading to pressure on, and paralysis of the cranial nerves. Thus blindness, nystagmus and ocular palsies may arise. Occasionally the density of the bones of the skull may lead to hydrocephalus, and when the clinoid processes are grossly increased there may be injurious pressure on the pituitary, with signs of hypopituitarism.

In considering the diagnosis it is to be noted that a condition closely resembling "marble bones" is found in those working in cryolite, a compound of fluorine, sodium and aluminium, while Speder (1936) found the same condition in the phosphatic zones of Morocco in the local inhabitants as well as in animals. The condition is said to be due to the ingestion of fluoride of calcium.

Etiology

Osteopetrosis is a hereditary and frequently congenital disease. It is inherited as a recessive gene and frequently blood relatives of both parents manifest the disease.

The etiology of osteopetrosis is obscure There is no doubt, however, since it affects membrane bone and cartilage bone, and may commence *in utero*—as soon as the earliest centres of ossification are laid down—or after birth, that it is a defect of the *ossification processes.*

Various theories have been proposed Thus Robertson found in his case a high vitamin D content of the diet, but this is not general.

Dupont's theory that the primary factor is parathyroid over-activity is founded on the discovery of a parathyroid adenoma in a case of his own. There is some experimental evidence to support this, as it seems that while daily injections of parathormone in animals leads to mobilization of skeletal calcium, the reverse is obtained if the injections are prolonged, for the osteoblasts are stimulated to deposit bone.

Ellis suggests that while it is difficult to credit the theory of a continued hyperparathyroidism, it may be that periods of parathyroid activity alternate with periods of normality, and in support of this he quotes Brailsford's observations on the lines of alternating density which appear on special radiography.

The most probable explanation is that of early maturation of the fibroblasts with resultant sclerosis and relative ischæmia The lack of blood supply prevents the necessary local changes in the tissue fluid to elicit decalcification of the calcified cartilage cells and nutrition of formed bone is reduced It must be pointed out that this calcium is absorbable if the proper blood supply were available (in fractures through this region) The presence of masses of calcified cartilage, bone, necrotic bone due to ischæmia, and sclerotic fibrous tissue can be explained on this basis

ENGELMAN'S DISEASE

This unusual condition is characterized by symmetrical fusiform enlargement and sclerosis of the shaft of the long bones, associated with changes in the skull The condition is seen most commonly in males and usually in childhood. Pains in the legs and head may be complained of, weakness and difficulty in walking, sometimes with a waddling gait, are common. The essential feature is the bilateral hyperostosis of the shafts of the long bones. This may be palpable The epiphyses are not involved The bones affected, in order of frequency, are the femur, tibia, humerus and fibula In the skull increased density of the base and frontal region has been found

Biopsy shows nothing but sclerosis. The only condition resembling this condition is infantile cortical hyperostosis. This occurs with the first years of life and tends to recover within a few months In Engelman's disease the bone changes extend and other bones become involved.

DEFICIENCY DISEASES OF BONE

Classification

Deficiency in Inorganic Constituent of Bone

In the infant it manifests itself as rickets and in the adult as osteomalacia

(*a*) *Insufficient absorption of calcium or phosphates*

Low intake—starvation—Rickets
Osteomalacia

Defective Absorption
Vitamin D deficiency
Defective Fat Absorption—Biliary deficiency.
Pancreatic deficiency
Cœliac disease

Chronic Diarrhœa

(*b*) *Excessive Secretion of Calcium or Phosphates*

Renal Rickets
Acidosis.
Hyperparathyroidism.

RICKETS

While the whole question of the utilization of calcium and of the calcium-phosphorus-bone ratio is the most complex and interesting part of calcium metabolism, there are two other factors to be considered, viz calcium absorption and calcium excretion Calcium must be present in the diet in sufficient quantity before absorption of the required minimum ($\frac{1}{2}$–1 gm. daily) is possible A sufficiency of calcium is of paramount importance during the growing period, and in its absence bone of a soft, partially calcified type (osteoid tissue) is laid down

ties It is usually accepted that the pain is a sequel to chronic arthritis of the joints of the limb, with which the condition is usually associated. There is usually limitation of movement at the affected joints Occasionally, there is an indefinite complaint of progressive muscular weakness.

Osteopetrosis with Superimposed Disturbances.

Brailsford has brought forward evidence to show that metabolic and other diseases of childhood may be superimposed on the original changes of osteopetrosis This is an important observation, and no doubt accounts for some of the complicated skeletal diseases of childhood, as well as rendering their clinical diagnosis difficult

Rickets and renal rickets may modify the picture by leading to imperfect calcification of areas of developing bone alongside the hyperostotic areas of osteopetrosis. This has been borne out pathologically by the demonstration of osteoid tissue in the metaphysis of bones where the diaphysis showed the usual changes.

The condition is also occasionally associated with diffuse deposits of calcium in the kidney, lungs, vessel walls and ligaments, and in this form again the metaphysial area is thickened and poorly calcified.

Osteopathia Striata (Voorhoeve).

In this condition, zones or striæ of dense bone are found in the long axis of a long bone or in the ilium. The condition gives rise to a characteristic X-ray appearance, which is, perhaps, its main significance, for it does not give rise to clinical evidence, nor does it induce secondary pathological changes.

OSTEOPOIKILOSIS

(Osteopathia Condensans Disseminata or Spotted Bones)

This condition was described by Albers-Schonberg in 1915. It is characterized by the presence of dense spots in large numbers in the long and short bones. The skull, vertebræ and ribs seem to be exempt. The spots, which may be very numerous, are round, oval or lanceolate with their long axes parallel to the long axis of the bone. They are usually uniformly dense, but may have clear centres, and are grouped towards the end of the bone in the epiphysis. They give rise to no symptoms, and are usually discovered by chance. Schmorl found that they consisted of numerous closely packed trabeculæ in the lamellæ lying mostly in a longitudinal direction.

Various skin lesions—dermatofibrosis lenticularis disseminata and scleroderma have been found in a number of cases of osteopoikilosis overlying the bony lesions

Its cause is unknown Zimmer attributed the bone condition to maldevelopment of a limb bud due to metameric disturbance.

and phosphates remain at a normal level, the bone performing its reservoir function over that of supporting function. When rickets is due more to calcium deficiency in the diet, with a normal phosphate intake, the blood phosphate may be raised with a resultant low blood calcium and tetany

Calcium and phosphates are excreted in the urine. The kidney has a renal threshold for phosphates and when this is lowered by an excess of parathormone hormone, or when the plasma phosphate exceeds the normal threshold, the phosphate ion is excreted, taking calcium ions with it. When there is some upset of the blood buffers by acidosis, such as in diabetes, excess phosphates are excreted to bring the blood buffers back into equilibrium This also results in an associated calcium loss The blood phosphatase is 3·5 mg. per cent. in the adult and 5 mg per cent in the growing child.

Rickets is a disease of the lower classes, and is especially common in industrial districts where poor housing, mal-nutrition, smoky atmosphere and lack of sunlight are common These factors favour a lack of vitamins, and it is now generally assumed that rickets is a deficiency disease due to lack of Vitamin D Improved conditions have reduced its incidence in this country, but in the industrial towns of the English Midland and Northern Counties the disease is still prevalent, and a Rickets Clinic established recently in Sheffield had as many as 500 children attending for treatment Mellanby believes that, while the grosser manifestations are less frequent, a considerable proportion of children of the hospital classes show sufficient bone changes to indicate that they have passed through a period of defective bone calcification short of florid rickets.

The commonest type of the disease begins during the early years of infancy and is extremely rare after the age of four. It is known as *infantile rickets* Comparable disturbances may arise at other age periods, however—*late rickets* and *osteomalacia*

Pathology

The main interest of the orthopædic surgeon is in the bony manifestations of the disease, but the metabolic disturbance affects most of the body tissues.

The Skeletal Changes. The bones of the skeleton are soft and porotic, and bend easily from the weight of the body or from other external causes. Normally the epiphyseal line of the long bones is a well-defined narrow strip of cartilage 2 mm deep, but in rickets it forms a wide irregular band and the metaphysis is broad and irregular from excessive proliferation of the cells of the epiphyseal line The bone deposited is patchy in distribution and uniformly poor in calcium salts

The histology of the process is instructive The cartilage in the proliferating zone is hyperplastic, but instead of the normal palisade

Mellanby has particularly stressed the dietetic aspects of the problem, and has shown that two types of diet are bad.

1. A diet containing substances which promote growth, without at the same time supplying a sufficiency of calcium.

2. Foods which encourage growth, but which interfere with the retention of calcium salts in the body and so prevent its deposition. The actual absorption of calcium is governed by the Vitamin D content of the body, which may be obtained from the diet, or synthetized in the body by the action of sunlight (or ultra-violet radiation) on the sterol of the skin Nevertheless, the absorption of calcium is difficult, because so much of the calcium in the diet is insoluble, and what is soluble is so liable to be precipitated if adverse conditions obtain. Thus alkaline carbonates may throw its soluble salts out of solution, while an excess of split fat in the bowel (as in cœliac disease) leads to the combination of free fatty acid with the calcium to form soaps

Acidity of the intestinal contents favours its absorption, as does systemic acidosis deliberately produced by ammonium chloride

Calcium which is absorbed from the alimentary tract but remains unused is at once excreted by the urine and fæces. Similarly an excess of calcium in the blood—by depletion of the spongiosa—leads to excessive secretion by the kidneys It is apparent, therefore, that efficient calcium metabolism depends on a variety of factors, and when any of those factors are upset, the skeletal system is apt to show coincidental changes The majority of these skeletal disturbances were originally considered as bone diseases This they undoubtedly are, but the modern tendency is to approach their consideration through the underlying metabolic derangement. Except for hyperparathyroidism all deficiencies of the inorganic components of bone are usually known as rickets, infantile or juvenile, or osteomalacia in the adult.

For the sake of clarity these are depicted as single entities yet it is seldom that they occur in this manner. When an avitaminosis D is present there is usually a deficiency in the general diet of calcium and phosphate and thus hastens the clinical appearance of pathology.

Chronic diarrhœa or defective fat absorption not only prevents calcium or phosphate absorption, but also that of Vitamin D. The resultant picture—rickets—is the accumulative product of these variants The basic pathology names the type of rickets—thus classical rickets if Vitamin D, renal rickets denotes renal disease; osteomalacia denotes a starvation process, etc.

Deficiency of calcium in the growing body effects a deficiency of calcium in the epiphysis at the zone of preliminary calcification. The ensuing imperfect osteogenesis results in dwarfism The deficiency of calcium in the Haversian systems gives a soft pliable bone with resultant bending deformities, e g genu varum or valgum, coxa vara, kyphosis, etc

Because of the sensitive equilibrium mechanism the blood calcium

The Deformities of Rickets. During the active phase of the disease, enlargement of the metaphysial segments of the long bones gives rise to obvious swellings at the bone ends. These are especially prominent at the costo-chondral junctions, and at the lower end of the radius and tibia

Fig 64 —Rickets Leg bones, showing Deformity in a Case of Healed Rickets

The coxa vara, bowing of tibia, and resulting buttress, are shown

When the child is able to crawl or to walk, the long bones of the lower limb may become bent The femur becomes bowed anteriorly and to the lateral side. The neck-shaft angle of the femur may be diminished (coxa vara), the tibia bowed, or the knee may assume a valgus attitude.

The pelvic deformities are of most importance to the obstetrician. The whole pelvis may be flattened, or it may assume a trefoil shape as in osteomalacia (q.v.)

The skull is broadened, the forehead square, and bosses of new bone may form in the parietal and frontal regions

The vertebral column may come to assume exaggerated curvatures

The Production of Rickets. Rickets is not due to any inherent defect in the skeletal system This fact has been clearly established by experimental and therapeutic researches, which have also demonstrated that the essential factor is a disturbance of the calcium-phosphorus metabolism on which the growth and maintenance of bone is so absolutely dependent.

Experimentally, rickets can be produced by withholding fresh foods, and by feeding with a diet containing an ill-balanced amount of calcium and phosphorus It has been quite definitely shown that disturbance of the mineral content of the diet has no part in the production of human rickets, but a constant feature of the latter disease is a low content of phosphorus in the blood serum. Rickets can be prevented, not by the administration of phosphorus, but by the addition to the dietary of Vitamin D—or by exposure to ultra-violet radiation, which synthetizes Vitamin D from the sterol in the skin

The action of Vitamin D is to promote the absorption of calcium and especially of phosphorus from the bowel

The Effect on the Bones. Normal ossification demands a sufficiency of calcium and phosphorus and in correct proportions In

arrangement of the cells, the proliferated cells are arranged more haphazardly. The extent of the zone is increased.

In the zone of calcified cartilage the deposit of lime salts in the intercellular matrix is greatly deficient, or even absent.

In the zone of ossification the bone deposited by the osteogenic cells from the diaphysis is poor in quality, deficient in lime, and of

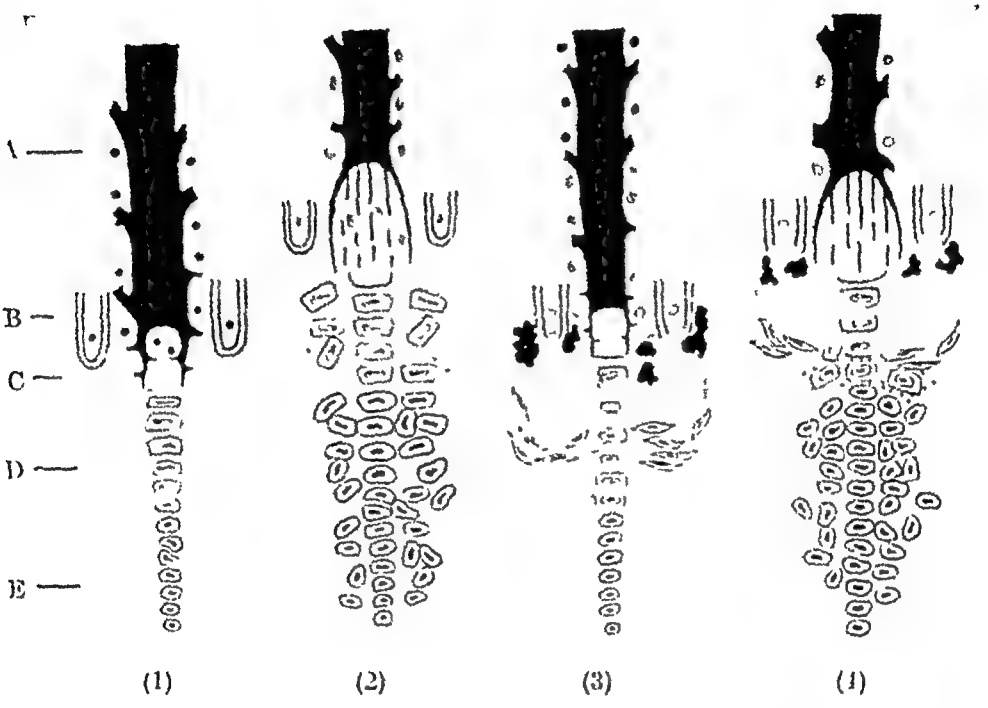

FIG. 63.—Diagram to Show the Characters of the Growth Area in Various Conditions.

In (1), a normal bone, note the regular column of proliferated cartilage and of calcified cartilage cells.

In (2), rickets, note the irregular and excessive proliferation of cartilage cells, the poor lime deposit, in the zone of calcified cartilage, and the scanty bone formation in the ossification zone. The whole growth area shows a greatly increased thickness.

In (3), simple scurvy, there are intrametaphysial hæmorrhages and a fibroblastic reaction. New bone as it is formed is broken up by the hæmorrhage.

In (4), scurvy rickets, in addition to the changes in rickets (as in (2) above) there are the evidences of scorbutic capillary hæmorrhage.

A—Diaphysis, B—Capillary with accompanying osteoblastic invasion, C—Zone of ossification, D—Zone of calcified cartilage, E—Zone of proliferating cartilage. (After H. A. Harris.)

patchy distribution. Associated with this is a poor development of the bone marrow. Fig. 63 (2).

In the metaphysis the bony trabeculæ are weakened by lack of calcium and the continued strain stimulates connective tissue hyperplasia so that the extremity of the bone appears misshapen and unmodelled.

These changes are most marked at the most actively growing part of the bones, and only affect the bone being deposited during the active phase of the disease. Bone formed before that is for the most part normal, while bone formed after the active phase of the disease is passed is also normal.

rickets this is lacking and as a result soft, irregularly formed, and poorly calcified bone is laid down.

Symptoms

The early symptoms of the disease are grouped by Fraser as follows :

1. Excessive perspiration, especially of the upper half of the body.

Fig. 65.—Rickety Coxa Vara with Bilateral Subtrochanteric Fracture (Dr Armstrong's case.)

2 Restlessness during sleep.

3 Disinclination to be moved or to use the limbs

4. Evidences of catarrh of the mucous membranes, e.g. recurrent diarrhœa, constipation, and bronchitis

5 Evidences of irritability of the central nervous system—convulsions, laryngismus or other types of spasmophilia

In a typical case of rickets, the clinical picture is very characteristic,

marked difference in size between the end of the shaft and the epiphysis.

4. In the *fourth stage* the characteristic increase in breadth of the metaphysis is still present, but the bone is now clearly defined, and shows a normal content of lime salts This stage marks the end of the process, the bone being now completely repaired

FIG. 70 —Rachitic Deformity of the Tibiæ and Fibulæ after the Condition has Healed.

DIAGNOSIS

There should be no difficulty in diagnosis when the complete picture has developed, but the disease may occasionally be confused with congenital syphilis and infantile scurvy The congenitally syphilitic child has usually other signs of syphilis, but occasionally the chief lesion may be a syphilitic osteochondritis. The epiphyseal region is tender, œdematous, hot, painful, and swollen, there is loosening and separation of the epiphysis, which can usually be moved on the shaft, with the production of muffled crepitus The epiphysis may even be

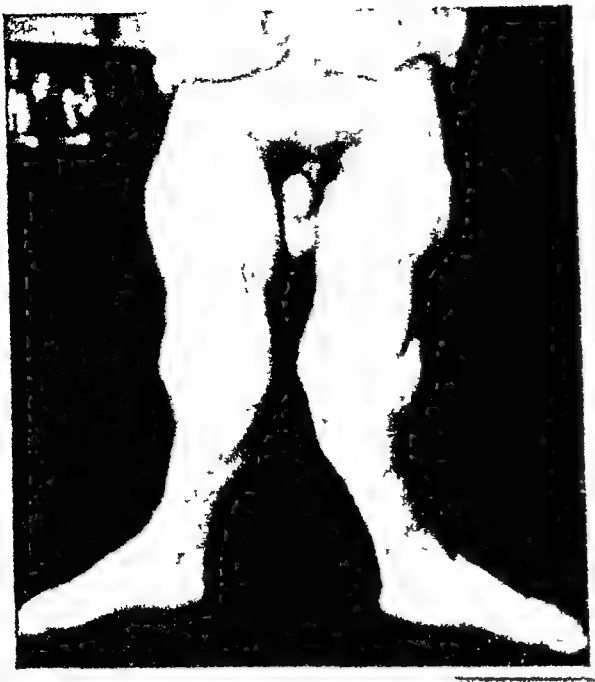

Fig. 68.—Genu Valgum.

This is the natural standing position of the patient, and shows the external rotation of the tibiæ as well as the knock knees.

area containing one or more indistinct centres of ossification. The metaphysis is splayed out, and deficient in lime shadow. There may also be evidence of a thickened periosteum, while fractures of the long bones are frequently seen.

2. In the *second stage*, the epiphysis appears as a mottled, irregular, ill-defined shadow. The metaphyses are ragged, but are now broader than normal, running out from the side where the pressure is greatest. Periosteal thickening has disappeared, but, if bowing has occurred, the cortical part of the affected bone will be thickened on the side of the concavity of the curve.

3. In the *third stage* the shadow becomes denser, and at the end of the metaphysis a dense line appears. This is due to the deposition of lime, and, while it is often considered characteristic of scurvy, it also occurs quite frequently in rickets. The epiphyseal shadow is more clearly outlined, but is still inclined to be mottled rather than clean cut. This is essentially the stage of repair. The most characteristic feature is the

Fig. 69.—Rickets in the Acute Stage.

The activity of the disease is evidenced by the fluffy expanded epiphyses.

When the deformity is most marked towards the middle of the shaft, osteoclasis is a quicker method of correction, while the anterior form of bow-leg should be treated by osteotomy.

In severe degrees of anterior bow-leg the deformity may resist correction at one sitting, and several osteoclases or osteotomies may have to be done at different levels on the tibia, at intervals of three or four months The osteotomy may have to be accompanied by a simple transverse tenotomy of the tendo-calcaneus to permit it to lengthen to a corresponding degree.

Slow osteoclasis is dangerous and not over eight seconds should be taken to fracture a bone by the osteoclast. Apart from the great mechanical benefit of the operation, there is an enormous mental one, for the patient who has hitherto looked dejected and ashamed of himself now assumes a self-confident poise.

GENU VALGUM

Knock-knee is so common during infancy that it can hardly be regarded as an abnormality Morley found it to be commonest among children aged 3 to 3½. At this age 22 per cent. of children were found to have a knock-knee of 2 inches or more. Only 1 to 2 per cent. of children aged 7 years and over have an equivalent amount of knock-knee. The type common in this country is the "idiopathic" type and is caused by growth at the outer side of the epiphyseal plate at the lower end of the femur proceeding rather more slowly than at the inner side.

The deformity of knock-knee has been considered to be a complication of rickets, and though this is so in some cases Brittain has pointed out that the vast majority are due to laxity of the knee ligaments, quadriceps insufficiency, and over-weight. (See Chapter XV) Morley found that it was not associated with valgus feet, flat-foot at the age at which the child started to walk, or illness as judged by the number of days spent in bed.

There is an inward projection of the knees, and the leg deviates from the long axis of the femur at an abnormal outward angle The deformity arises because the line of weight transmission through the femur passes to the outer side of the centre of the knee joint; the lateral condyles of the femur and tibia have thus to bear more weight than the medial Bone, softened by rickets, is readily compressed, and conversely, the absence of any great weight-bearing strain on the medial aspect of the knee allows the bone in that situation to develop more rapidly than on the outer side As the deformity is developing, the tibia rotates outwards on the femur, as a result of traction by the lateral ham-strings Marked eversion and outward rotation of the tibia are, therefore, often present

Usually a child of 3 or 4 is able to stand with the medial condyles of the femur and the medial malleoli approximately touching. Care

lying free in a cavity filled with pus There is usually a history of parental syphilis, and the child responds to anti-luetic treatment

In infantile scurvy, swelling also occurs; it is not limited to the region of the epiphysis but encroaches on the shaft There are usually hæmorrhages in other situations, and the general signs of scurvy are present

Treatment

The treatment may be considered under three headings—the medical treatment, the prevention of deformity, and the treatment of existing deformity.

1. Medical Treatment, Prophylactic and Curative. A full discussion of this aspect of rickets is out of place here, but some points may usefully be considered. Mellanby has stressed the fact that while a milk diet—cow's or human—is by far the best for infants, yet in many cases the milk does not contain a sufficiency of vitamin D, and should therefore be supplemented by substances rich in the vitamin —cod liver oil and halibut liver oil being satisfactory.

A largely cereal diet is particularly bad, for cereals in some obscure way interfere with the action of vitamin D and may render an otherwise sufficient amount of the vitamin inactive

Rickets may be cured by administration of one of the vitamin D containing foods, or by one of the standard preparations of the vitamin (e.g. calciferol). The effect of this is enhanced by the addition of a calcium preparation (calcium carbonate or calcium phosphate). Ultra-violet light therapy is an invaluable adjunct

2. The Prevention of Deformity. When the bones are so soft that they are easily bent by pressure, or muscle strain, the child's movements should be so controlled that little or no pressure is exerted upon the limbs He should not be allowed to sit, stand, or walk, but should lie on his back most of the time, and only be allowed to roll about in bed. In difficult children it is often advisable to fit "rickets" splints These are narrow strips of wood, which extend from the crest of the ilium to beyond the sole of the foot. They are firmly fastened to the body and limbs by bandages, and prevent the child from sitting up or getting on to his legs To take the place of exercise, which is precluded by the position or by the splints, massage should be instituted.

3. The Treatment of the Established Deformity. Findlay has pointed out that in cases of very bad deformity in young children a rickets-producing diet may be given, so that when the bones become soft the limbs may be straightened by wrenching and splinting. When the alignment has been improved, a bone-hardening, anti-rachitic diet may then be recommenced He has successfully treated a case in this way.

Deformity is more usually corrected, however, in one of four ways . by splints, by gradual manipulation, by the osteoclast, or by osteotomy.

a large window cut so that two-thirds of the circumference of the plaster is removed After the osteotomy the plaster is straightened until the angle no longer exists and the thigh and the leg make a straight line. The plaster gap is then filled by turns of plaster of Paris. The position is checked by an X-ray After two months the plaster is removed and the child is then allowed up on a walking caliper, and carefully supervised for some months until the fracture has fully united and any tendency to recurrence of the deformity has disappeared.

SCURVY AND SCURVY RICKETS

The anti-scorbutic vitamin C is found in the majority of fresh food stuffs—fruit juices, green vegetables, and to a lesser extent in potatoes, milk and raw meat Since it is destroyed by heating at 100° C., it is absent in dried, canned, and preserved foods, and in vegetables subjected to prolonged boiling.

The absence of vitamin C from the diet gives rise to the clinical condition of scurvy, the characteristic symptom of which is hæmorrhage in various parts of the body. The orthopædic surgeon is concerned with its manifestations in bone.

The disease most commonly occurs in infants of from six to eight months who have been fed exclusively on artificial food which has had its vitamin content destroyed in the process of manufacture or which has never possessed a vitamin C content at all. It also occurs in adults who are deprived for a time of fresh food—as in old people living alone, and subsisting on an inadequate diet of bread and tea.

A diet deficient in vitamin C need not of necessity be deficient in the other vitamins Nevertheless it is frequently so and if there is, in particular, a deficiency in vitamin D, a rachitic element may be added to the scorbutic in the case of the growing child, while in the adult there may be some evidence of osteomalacia

Thus it is well to distinguish two varieties of scorbutic disturbance in the young ·

(*1*) *Scurvy*

(*2*) *Infantile Scurvy-rickets* (Barlow's disease).

Pathology of Scurvy

The cardinal feature of scurvy is defect in the formation of certain intercellular substances which results in hæmorrhage—from the gums, the alimentary tract, the subcutaneous tissues, and in bone The hæmorrhage is capillary in origin, and occurs at sites at which new capillaries are sprouting—in bone, for example, at the most actively growing metaphyses and beneath the periosteum It is thought that vitamin C controls the nutrition of capillary endothelium, or the amount of intercellular cement which binds the endothelial cells together.

The pathological change in the affected bone has been well described by Harris

must be taken to make sure that the knees are straight and that the patellæ face exactly upwards: the legs are brought together with moderate pressure which is applied firmly enough to compress subcutaneous fat as this tends to exaggerate the appearance of the deformity. Any marked separation of the malleoli when the knees are in apposition indicates the presence of knock-knee. When knock-knee is present, the child walks in an unsightly manner, since the knees rub together, and the line of gravity is transposed to the outer side of the knee joint. The gait is lurching, with an exaggerated side-sway of the body at each step to preserve balance. Falls are common. Synovitis of the knee arises from joint-strain. The deformity disappears when the knee is flexed, since the posterior surfaces of the condyles with which the tibia articulates in full flexion are not affected.

If there is deviation from the normal type of knock-knee an underlying cause must be looked for. Such cases are those where the knock-knee is excessive—over $3\frac{1}{2}$ inches: where the amount of deformity is asymmetrical, where the child is short in stature for its age. This might rarely be due to an epiphyseal dysplasia or to an endocrine disorder, or where there is a family history of knock-knee or other bony deformity, or it could be due to a metabolic disorder such as Fanconi's syndrome (Morley).

The prognosis is excellent if the amount of abnormality is not excessive, that is, over $2\frac{1}{2}$ inches. Correction usually occurs even if there is 3 inches at the age of 3. The child then should be under regular observation and continued progress is an indication for active treatment.

Treatment

Toddler's knock-knees can safely be ignored and in children under 7 can also be safely left alone unless it is excessive or unless an underlying cause, such as epiphyseal damage from an old fracture or renal rickets, is present.

The only conservative treatment that may possibly be helpful in the mild case is an inner wedge of $\frac{1}{8}$ to $\frac{3}{16}$ inch to the heels. It satisfies the worried mother but there is considerable doubt whether recovery is assisted.

More active treatment is occasionally necessary and in cases which resist this treatment, a Jones's walking knock-knee brace may be used or a mermaid splint especially for night use.

In cases of any severity, it is much better to perform an osteotomy of the femur, the bone being divided in the supracondylar region from the lateral side. Brittain's suggestion of doing the operation in children through a window in a bilateral plaster-of-Paris spica is a good one. This method minimizes the possibility of gross displacement of the bone ends and so a reasonably perfect position is assured. A line is drawn on the anterior surface of the plaster through the long axis of the limb, an angle being made at the site of the proposed osteotomy. The operation is carried out on the lateral aspect of the limb through

are similar to those of rickets, i e. the metaphysis is swollen and its extremity uneven The epiphyseal cartilage is broad and fuzzy. In most cases transverse striations of denser bone may be detected in the neighbourhood of the metaphysis. Harris believes that these striations are indicative of periodic arrests of growth, but most people regard them as indicating bands of more perfect bone deposited during periods of temporary improvement in the disease.

The Blood Chemistry in Cœliac Disease

In cœliac rickets there is invariably a lowered serum calcium content Impaired fat digestion results in insoluble calcium soaps with decreased fat absorption The occurrence of tetany is the result of the low serum calcium.

Etiology of Cœliac Rickets

In cœliac disease there is inadequate utilization of the fat of the diet Since the natural fats are valuable sources of vitamin D, there is probably some resulting deficiency of the vitamin. In addition, the excess of free fatty acid leads to precipitation of the calcium of the diet as insoluble soaps There is, therefore, deficient absorption of these minerals from the alimentary tract The mechanism of the bone changes is thus similar to that of rickets—the blood circulating in the bone has a low serum calcium, and in consequence bone which is actively growing is laid down in a poorly calcified form and in irregular manner The late onset of the bony changes is due to the effect of growth. Parsons suggests that, in consequence of the fat-deprivation, there is virtually starvation, and therefore arrest of growth The absorption of calcium, though greatly diminished, appears to be sufficient to calcify the fragile bones of cœliac disease so long as there is little or no growth, but directly any considerable growth appears, this defective absorption results in the development of what is, for all practical purposes, rickets

Treatment

Since the mechanism of the disease is so exactly comparable to rickets, Parsons advocates the use of (1) ultra-violet therapy; (2) irradiated ergosterol, (3) a fat-free diet.

Deformities which demand it are treated along similar lines as the post-rachitic deformities

RENAL OSTEODYSTROPHY

The association of chronic renal disease with changes in the skeletal tissues in young subjects was first reported by Lucas in 1883 Since then many complete and instructive studies have been made, amongst others, by Parsons and by Barber The latter in particular has made

Pathology

The bone changes appear only in late and long established cases and are similar to those of rickets. The metaphysis is broad and irregular, the palisade arrangement of cartilage cells is lost, and in place there is an irregular hypertrophy of the cells. The zone of calcified cartilage is narrow and its calcium content is poor or absent, while the osteogenic process is retarded or arrested, and instead of bone there is deposited an imperfect type of osteoid tissue.

Clinical Features

In association with the characteristic appearance of cœliac disease —pallor, cachexia, muscular hypotonicity, and abdominal swelling— there is lack of body development—stunting. In addition there may be skeletal deformity. Genu valgum in particular is a common feature. Enlargement of the distal ends of the radius and ulna are also

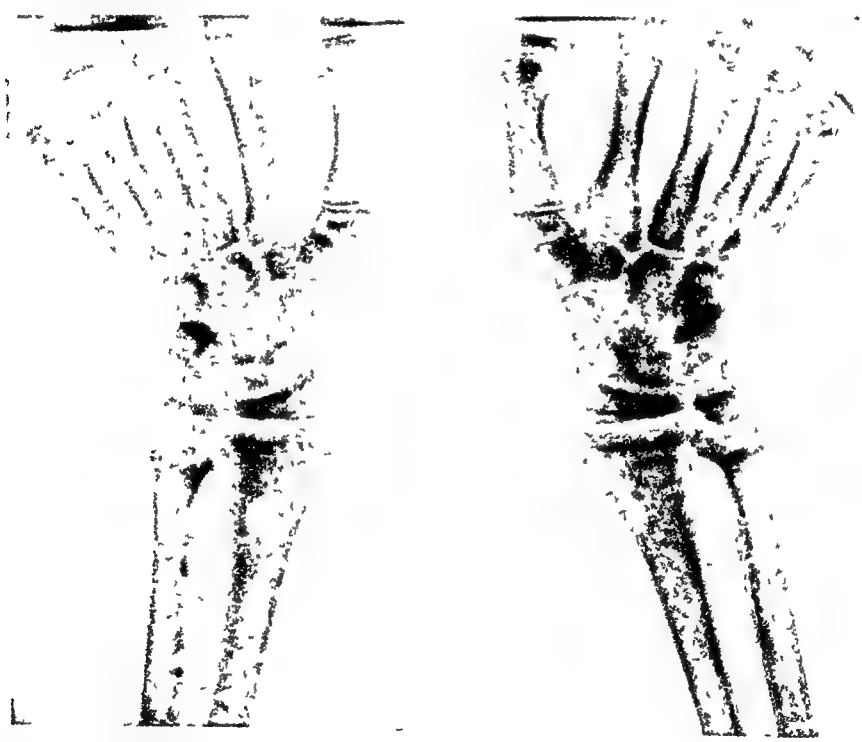

Fig. 72.—Cœliac Rickets (Professor Fraser's case)

frequent signs, but occasionally still more extensive deformation may be present—enlarged costo-chondral junctions, Harrison's sulcus, kyphosis, coxa vara, bow leg, etc Fractures may occur with mild trauma.

There may be recurring attacks of tetany.

Radiological Appearances

The X-ray appearances are very variable, but the whole bone is usually fragile and porotic. Parsons believes that the other changes

thickening, softening and deformity, and later by recalcification and hardening

The Skull Changes. Knaggs describes three stages in the pathology of the skull changes. In the first, or *vascular stage,* there is a deposit of finely porous bone beneath the pericranium, and this is red in colour, due to the permeation of a very vascular connective tissue. In the second stage—of *advancing sclerosis*—the thickness of the skull

FIG. 82.—Paget's Disease of the Femur, with pathological Fracture of Neck

is still more increased, and the calvarial sutures obliterated The bone on the inner table is very condensed but still finely porous. On the outer table there is also a narrow layer of dense but fairly porous bone. In the area between the tables, the bone is again red and spongy in texture and its interstices are packed with vascular connective tissue In the stage of *diffuse complete sclerosis* the condensed type of bone is present for the most part throughout the whole thickness of the calvaria.

coarsely piebald appearance. Ultimately the distinction between outer and inner table is lost, and the latter also acquires a ragged worm-eaten appearance The base of the skull may show comparable changes

Changes in the Spine. The changes in the spine are less frequent than in the skull, though the monostotic form is often seen in the lumbar bodies and is essentially a problem in X-ray diagnosis. They consist of a woolly appearance of the bodies, with coarse striæ at the periphery, and horizontal striæ near the upper and lower surfaces. The bodies may be flatter and squatter than normal, and abnormal curvatures may be present

The Pelvis. The pelvis tends to assume a trefoil shape, as a result of the pressure of the femoral heads. The bone appears thick and massive, but the texture of the bone is altered; it now appears mottled and blurred, while occasionally coarse striæ are apparent throughout the cortex.

The Long Bones. The affected bones show increased thickness due to enlargement of the cortex. The bones are variously deformed: usually the natural curves of the bone are accentuated, but sometimes the deformities are more bizarre and the femur may show an S-shaped deformity. The texture of the bone in the early stages is porous—the bone appears stippled from irregular absorption Later there is a granular appearance throughout the thicker cortex from the deposition of calcium salts, while still later the amorphous granular change in the cortex is replaced by coarse longitudinally running trabeculæ which gradually become distinct and defined. As regards the individual bone, this stage may be taken to mark the end of the process.

In addition to deformation by bending the bone is liable to pathological fracture during the stage of granular amorphous calcification.

Occasionally ovoid translucent areas covered by a thin layer of cortex occur. These are cysts and resemble in many respects the cysts of parathyroid osteodystrophy. Calcification of arteries is also a common feature.

Fairbank (1951) has described four typical radiological appearances which can be seen in most bones

1. A honeycomb or spongy appearance—which is the commonest and most widespread manifestation.

2. A striated appearance, as seen in the pelvis, sacrum, and the calcaneum.

3. A uniform and increased density, which is most frequently seen in the vertebræ

4. The occurrence of true cystic areas, as seen in the pelvis or long bones.

The Pathology of Osteitis Deformans

The Bone Changes. The bone changes are characterized by

intervening period of about three months when the patient is allowed freedom in bed, unhampered by any apparatus During this time he is measured for an ordinary Thomas's walking caliper, and a patten is fixed to the boot on the sound side

Ambulatory treatment is divided into stages so that full function is attained gradually It is of the utmost importance that the caliper should fit the patient correctly. Two things at least are essential for a properly fitting splint · the tuberosity of the ischium must rest on the ring of the caliper and not slip through it, and there must be a space between the heel of the foot and the heel of the boot when the patient is standing upright. If these conditions are fulfilled no weight is transmitted through the hip joint, and this avoidance of weight-bearing must be assured during the first stage of ambulatory treatment, when the patient uses his caliper, and crutches, with a patten on the sound side. The patient is usually advised to wear his caliper for at least a year, during which time he should be examined at regular intervals; though the patten is removed after about six months, and the crutches discarded three months later. After all apparatus has been discarded, he is asked to report every three months for three years. This constant supervision may appear irksome, but the examination occupies only a few minutes, and is imperative if the best possible results are to be achieved

3. Operative Treatment.

In any consideration of operative treatment of the tuberculous hip joint, it is obvious that chemotherapy has allowed us to return to the more radical methods of local attack, some of which, in years gone by, were disappointing because they were so often followed by sinus formation and dissemination of the disease We must, however, always bear in mind that tuberculosis is a general disease and that the joint lesion is but a metastatic manifestation of it Thus the involvement of the deeply situated glands, inaccessible, insidious, and in issue far more dangerous than the lesion itself, should ever be in our minds. This makes the sanatorium regimen still imperative

Children responded well to this regimen, with healing of the adenitis, as well as of the concomitant bone lesion, but this took a long time. Many of our patients required sanatorium treatment for five years or more in the days before the introduction of chemotherapy This period of prolonged immobilization led to many complications, such as premature fusion of the epiphyses, with shortening of the extremities and resultant stunting, both physical and mental, as well as other forms of morbidity

It was also noted that adults did not respond so well and often had reactivation of the glandular focus with a substantial late mortality from associated lesions

Streptomycin and associated drugs have allowed us to make a direct surgical attack on the joint, in patients seen early, therefore, we may hope for a mobile joint, and in patients seen late, a shorter period of

and the ligaments are drawn over it by interrupted sutures of medium kangaroo tendon.

"Before the kangaroo tendon sutures are drawn over the lower end of the spinal graft a segment is removed from its uppermost surface and into it one end of the lateral graft is half-mortised and the other wedge-shaped end is driven into the cleft in the ilium prepared for its reception.

"The skin wound is closed and the patient placed on the back on a fracture bed for a period of not less than five weeks. There should be no necessity for further treatment" (Albee's *Orthopædic Surgery*, p. 411).

TUBERCULOSIS OF THE SHOULDER JOINT

Tuberculosis of the shoulder joint is rare, particularly in children. Shropshire Orthopædic Hospital reports 27 out of a total of 2,922 cases of tuberculous disease of the spine and joints, a percentage of less than 1.

Pathology

The disease originates, as a rule, in the head of the humerus. The commoner form is the so-called caries sicca, a dry atrophic form with much wasting of muscle, pain and limitation of movement, but no abscess.

The other form is the florid type with much thickening of the synovial membrane. The head becomes eroded, its place being filled by fibromyxomatous and granulation tissue. The muscles contract and pull the head hard against the glenoid which also becomes eroded. Finally the whole joint becomes destroyed, and filled with pus. In many cases the apex of the adjacent lung is infected either primarily or secondarily.

Symptoms and Signs

An insidious onset is characteristic, doubtless because this is not a weight-bearing joint, and because the early limitation of movement —abduction—is to some extent masked by the mobility of the scapula on the chest-wall. In the early stage there is dull aching in the front of the joint and at the insertion of the deltoid. This may be referred to the elbow and forearm

Limitation of abduction and of lateral rotation are marked, the joint swells, the muscles atrophy markedly, and soon it is necessary to support the arm in a sling. An abscess may form at a later stage and rupture through the capsule anteriorly, pointing in front of, or behind, the insertion of the deltoid. Subcoracoid dislocation, from disintegration of the joint and destruction of the ligaments, may follow. A radiogram shows at first an irregular outline of the head of the humerus with erosion of the joint line. Later the destruction of bone

diseased focus in Babcock's triangle or in the acetabular region is approached and is thoroughly eradicated, the area being packed with cancellous-bone chips. Penicillin and streptomycin powder are used locally. It is necessary to immobilize the joint in plaster for a few weeks (in the case of femoral foci) or by fairly heavy traction (in the case of acetabular foci). A certain proportion of hips will still heal by fusion or may require arthrodesis later, but it is remarkable how many will have mobility at the end of treatment. A long period of follow-up is necessary in order to be able to tell whether the mobility and cure are going to be permanent. Although some patients will show extension of the osseous disease process and may require arthrodesis at a later stage (the price of delay in applying definitive treatment), we may gain a mobile hip and all of its benefits in many patients. If the chemotherapy is continued long enough, reactivation, or flare up, of the tuberculosis is less likely to occur.

In every case where arthrodesis is to be expected the question of the operative production of this is to be considered, as in many cases conservative treatment does not cure the disease but produces a state of chronic invalidism; and also in many favourable cases it takes a very long time for recovery to be effected. It is a wise practice however to treat all cases, and certainly all children, conservatively for at least a year, and to reserve consideration of operation only for those cases which do not show a good response within such a period. It has been stated that there are four main indications for operation—(1) in an adult patient, (2) failure of conservative treatment to arrest the disease after one year; (3) relapse, especially the recurrence of pain and deformity after conservative treatment; (4) certain destructive lesions, e.g. the formation of sequestra in the head or neck of the femur, or in the acetabulum

Arthrodesis. *Damaged articular cartilage*. If the patient comes under treatment at such a late stage that the articular cartilages are obviously irretrievably damaged, then bony fusion is necessary One now need only wait until the patient's general resistance has been built up in order to overcome the general toxæmia of the bacillary invasion, this is aided greatly by the use of chemotherapy. Arthrodesis is performed on the same lines as an arthrodesis of the spine, and, to the same extent, forms an internal splint, by this means the operation hastens the fusion of the joint, and shortens the convalescence of the illness It is inadvisable before the age of ten years, and even in older patients the author does not recommend it, unless there is definite disease in the bone It is indicated in patients who have frequent painful attacks, with extreme shortening, and a tendency to increasing deformity, especially if there are signs pointing to a relapse.

Various methods of arthrodesis of the hip have been described, some of them even opening the joint and removing tuberculous debris before grafting bone into the surfaces. Grafts, however, are usually absorbed in the presence of tuberculous disease, and accordingly two

immobilization, an earlier and quicker fusion, and fewer, if any, complications.

There is no doubt that the best results are now obtained by the use of streptomycin in combination with other drugs and surgery. These do not supersede a sanatorium regimen, but merely reduce the time for which it is necessary.

It has been pointed out that the hip joint may be affected with tuberculosis in three ways: an extra-articular focus, synovial disease, and an intra-articular lesion with destruction of the cartilage. These lesions may be treated in the following ways.

1. *Extra-articular focus.* Even before the days of streptomycin an extra-articular focus was excised with some measure of success, when it was accessible. It is much safer to do so now, and it should be carried out, of course, before the adjacent joint becomes involved. After antibiotics have been administered, the excision is carried out. It is a good practice to fill the cavity, after a thorough removal of all diseased bone, with cancellous bone chips and to use streptomycin and penicillin powder locally. One can, with confidence, look forward to a complete reconstitution of the bone and, of course, a mobile hip.

2. *Synovial disease.* In synovial disease, with a tense full joint and with the synovial membrane and capsule ballooned out due to an effusion, there is every prospect of obtaining a mobile joint if the streptomycin and other drugs can reach it in sufficient concentration and if, of course, the joint surfaces are undamaged. The tuberculous exudate does not contain proteolytic enzymes, such as those seen in the exudate of pyogenic infection: the cartilage tends, therefore, to persist until a later stage when it is covered by the tuberculous pannus of unhealthy granulation tissue. Early diagnosis and decompression are essential in order to save the joint, and, therefore, biopsy is justified, apart from diagnosis, to relieve tension and to allow the penetration of the chemotherapeutic agent. We must, therefore, in carrying this out, remove as much of the diseased synovial membrane as possible, together with part of the capsule. This will inevitably turn the tide in the patient's favour and will lead to a higher percentage of mobile hips. Synovial membrane regenerates rapidly. After removal of the diseased synovial membrane at operation, fresh normal synovial tissues, carrying young blood vessels through which the antibiotics can circulate freely, will form. The only form of immobilization necessary during this treatment is by skin traction. Nutrition of the limb must be maintained.

3. *The Intra-articular lesion. Intact articular cartilage.* Up to a few years ago, even the intra-articular lesion was considered to be cured only when there was bony fusion, but it is recognized that there are still some cases in which, although the lesion is intra-articular, most of the articular cartilage is still intact. Therefore, there is still the possibility of obtaining a mobile hip, at least for many years. The

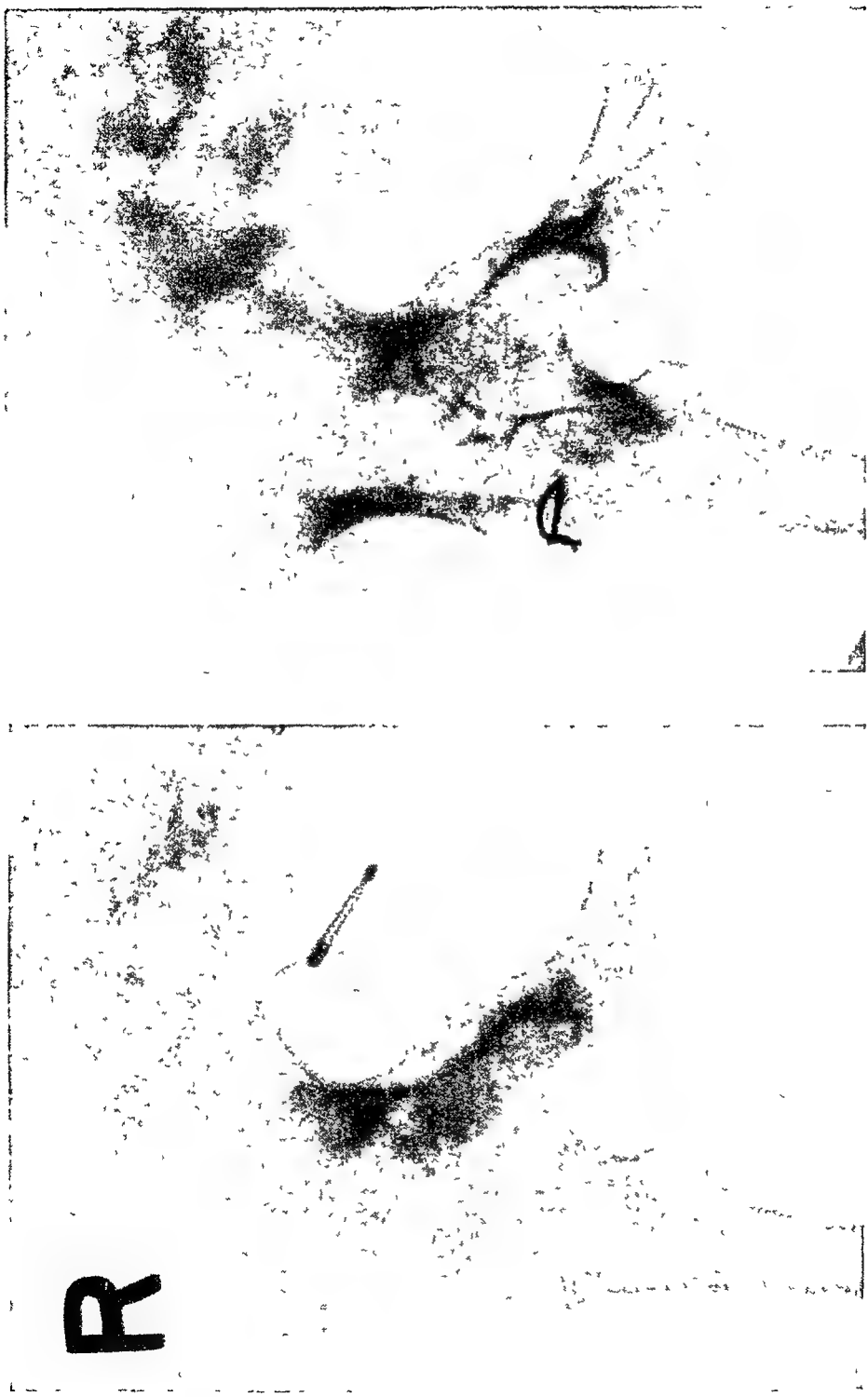

(a) (b)

FIG 169 —Tuberculous Disease of the Hip (a) just healing without Osseous Union and with Pain (b) Hibbs' extra-articular arthrodesis produces a painless hip in good functioning position

methods are described here The author performs the method described by Brittain.

Ilio-femoral Methods of Extra-articular Arthrodesis. In both methods described it is of the utmost importance to keep the parts firmly fixed after the graft has been inserted and so the Hibbs and the ileal graft operations are carried out with a complete plaster case on and a large window cut out to expose the operation area. Union of the graft has been secured in a much higher percentage of cases since this has been done.

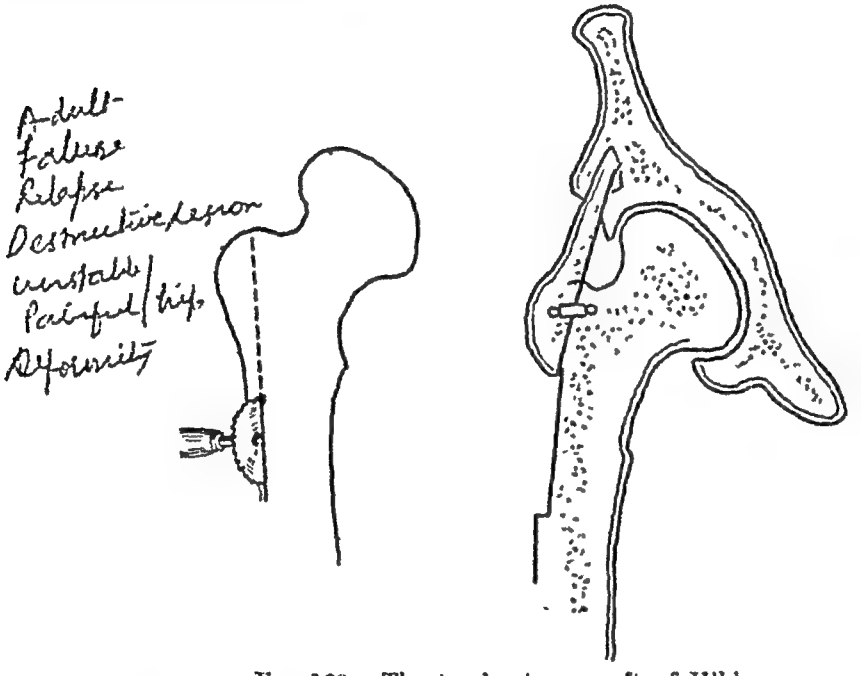

Fig 168.—The trochanteric graft of Hibbs.

(*1*) *The Trochanteric Graft* (Hibbs). This operation is a simple one, and is carried out through a Smith-Petersen incision (Fig. 169). The upper end of the femur having been exposed, the periosteum is incised across the line of the base of the trochanter and elevated The lateral mass of the trochanter, with 2–3 inches of the cortex of the femur, is separated with a chisel, leaving the muscle and the periosteal attachments at its upper end undisturbed. A portion of the ilium above the upper rim of the acetabulum is elevated, without disturbing the muscular or periosteal connections, or loosening its upper attachment. The detached trochanter and part of the shaft are now transposed, by turning the lower end under the elevated mass of the ilium, and making contact with the cancellous bone of the neck from which the cortex has been removed. The thigh has already been abducted and flexed to the "optimum" position, and, after suture of the wounds, a double spica plaster is applied to the pelvis and legs. The fusion which takes place in these cases appears to be primarily between the transposed trochanter, ilium, and neck of the femur, and finally between

from the tibia. The great trochanter is now exposed with a 3-inch straight incision, and a subtrochanteric osteotomy in the same direction as in a McMurray osteotomy performed, the site and direction being indicated by the X-ray. The ischium is entered and divided just below the acetabulum and is contacted about 1½ inches deep to the femur. Traction is now put on the limb and a second osteotome—both calibrated—is now inserted alongside the first and by means of the calibration and a second X-ray it may be seen how much farther the second osteotome may be driven. When the requisite length has been achieved, i.e. the ischium divided, the second osteotome is removed and the graft

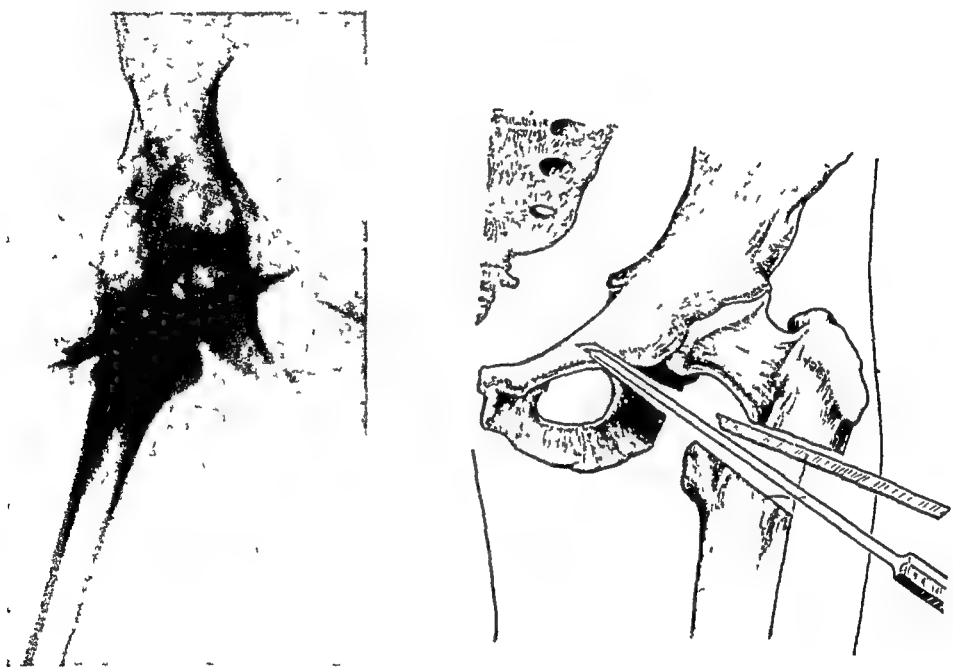

(a) (b)

FIG. 171.—Arthrodesis by the ischio-femoral method

inserted, and pushed and hammered home, so that it is firmly impacted in the ischium The limb is then abducted and displaced medially so that the lower fragment abuts against the ischium below the graft. Brittain's twin osteotome may be used for the operation though it is usually rather large The author prefers to do this operation by means of an open approach from the posterior aspect. This allows identification of the sciatic nerve and, if thought necessary, open inspection of the joint with relief of tension and thereby improved blood supply, and removal of necrotic debris.

(*b*) **Secondary Operations.** To correct an old fixed adduction-flexion deformity some form of osteotomy is usually employed

In cases of sound bony ankylosis with adduction-flexion deformity, a sub-trochanteric or a trans-trochanteric osteotomy may be performed and the deformity reduced By this means the excess of

the remnants of the head and the acetabulum. It will be noted that this is an *extra*-articular fusion designed to effect internal splinting, not to eradicate disease.

(2) *Ischio-femoral Method of Extra-articular Arthrodesis* (Brittain). Brittain has pointed out that the above methods have a common disadvantage in that while fusion is taking place the hip joint is subjected to the predominant force of adduction, and that any graft from the ilium to the great trochanter may lose contact at either end. In both methods there is a distracting force on the graft, while in that of Brittain the force is one of compression. Calvé and Trumble have both suggested, and in the latter case carried out, the obvious alternative of an ischio-femoral arthrodesis Brittain, however, has simplified the method and made it a more practical proposition. This operation

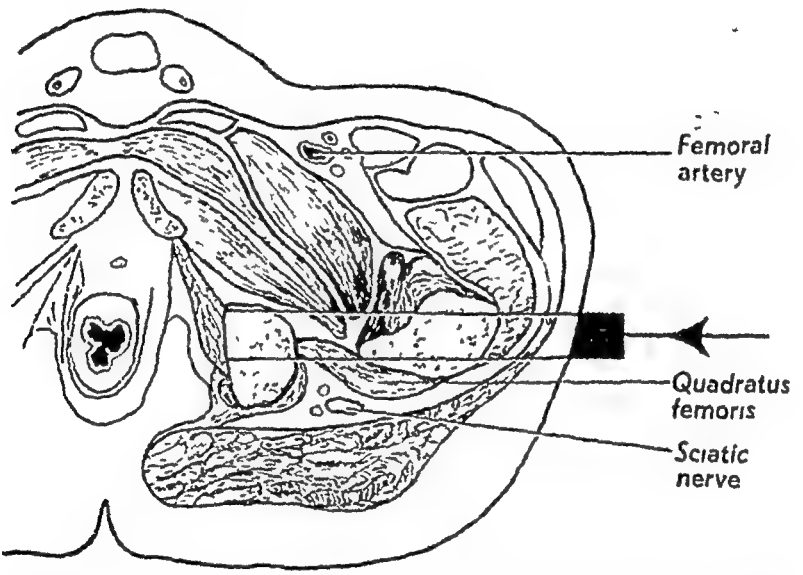

FIG 170—The Route of Brittain's Operation (After Campbell)

"consists of a subtrochanteric osteotomy through which the ischium immediately below the acetabulum is incised by a wide osteotome and a space made in it to receive a flat massive tibial bone graft This is embedded deeply in the ischium and its outer part remains between the fragments of the osteotomy."

The Operation. With the patient in position on an orthopædic table a preliminary X-ray is taken with a measuring rod strapped on the leg at the level of the trochanter and a Michel clip at a point in the groin at the junction of the upper two-thirds and lower third of a line joining the anterior superior spine and the symphysis. By means of the measuring rod the point of entry of the osteotome on the outer aspect of the shaft of the femur can be accurately plotted and the Michel clip will indicate from its position the direction to drive the osteotome While the radiogram is being developed the stout thick graft which includes the anterior crest and the medial margin is cut

fragments The incision is made a little more anteriorly and a series of drill holes made in the femoral shaft in a semicircular line with its concavity downwards. The actual severance is made with a narrow osteotome cutting through successively the bridges of bone between the drill holes. The ends are thus more ragged and irregular and tend to hold their position better.

The leg is put up in traction for a period of three weeks, during which time a certain amount of soft callus forms round the bone section. An anæsthetic is now given and the deformity corrected by abducting the limb to the required extent. Since the desire is to get the limbs of equal length, and in such a position that they will be parallel when walking, the amount of abduction must be carefully estimated. While the operator abducts the affected limb, his assistant adducts the good limb to its full extent until they are of equal length. Equality of length, however, is secondary in importance to the limbs being parallel and if through contraction of the abductors etc. on the good side through long-continued abduction equality of length cannot be obtained then one must be content with the maximum amount of compensation of length permitted with the limbs parallel to each other. Great care must also be taken that the lumbar spine is freely movable before such an operation is carried out, as of course it is necessary for the patient to flex his spine to compensate for the altered position of his pelvis. After the required manipulation has been carried out the limb and pelvis are placed in plaster for about three months, and it may be necessary then to fit a walking-caliper for a further month or two, until union is quite firm.

TUBERCULOSIS OF THE KNEE JOINT

Tuberculosis of the knee is second in frequency to that of the hip joint, and, like it, is most common in childhood, though frequently seen later. In over 4,000 cases admitted to East Fortune Sanatorium, the knee was involved in 13 per cent. of the cases of bone and joint lesions. It is always secondary to active disease in other parts—usually the lymphatic glands—a point that must never be forgotten in the treatment Two anatomical points to be noted are the large extent of synovial membrane, and the marked vascularity due to the late junction of the femoral and tibial epiphyses Growth of the leg takes place in this region, disease of the joint, therefore, is serious because of its possible effect on stature, although in the author's experience shortening is much more serious in hip disease.

Pathological Anatomy

The disease may begin either in bone, usually in the femoral or tibial epiphysis or, more rarely, in the patella or in the synovial membrane Hibbs and Smith believe that in 85 per cent of cases the disease is primarily synovial, and this is borne out by the author's experience. Girdlestone describes three groups of cases:

(1) Osseous foci irritating but not infecting the joint These foci are

shortening from the adduction is overcome and the strain on the lumbar spine relieved.

METHOD. A 4-inch lateral incision is made over the proposed site for osteotomy and the femur exposed. To make certain of the exact site of the bone cut, it is wise to elevate the soft structures of the shaft in the region of the lesser trochanter and actually palpate the trochanter before making the bone section. But usually the exact site of the osteotomy is ascertained by taking a preliminary X-ray photograph while having a measuring rod alongside the bone, as is done



FIG 172.—Lorenz Bifurcation Osteotomy
The body-weight is borne directly on the top of the femoral shaft now

in performing a McMurray osteotomy. If the abduction correction is carried out immediately there is a chance that the contracted adductors may displace the upper end of the lower fragment inwards and upwards (see Fig. 172). This is a serious and shortening complication, and one that is extremely difficult to rectify so no attempt is made to reduce the deformity now, but it is made quite certain that the shaft of the femur is completely divided.

To Prevent Displacement of the Fragment. A drilling method of osteotomy is sometimes used to prevent the displacement of the

detached, leaving the bones exposed At the same time softening and stretching of the ligaments tend to produce subluxation of the tibia, which slips backwards and rotates laterally. Inflammation takes place round the joint, leading to thickening, so that the spindle-shaped tumour known as a "white swelling" is formed

Symptoms and Signs

At an early stage there is stiffness and swelling. Tenderness and local increase in heat soon develop in and around the joint, and as the disease extends, pain and lameness supervene The combination of muscular atrophy with enlargement of the joint gives an appearance of great swelling. Flexion and subluxation of the tibia are seen in the later stages, followed by peri-articular abscesses and sinuses.

Fig 175 —Genu Recurvatum resulting from absence of proper support after Excision of the Knee for Tuberculosis

Swelling. The joint being superficial, swelling is soon apparent, and may be due to synovial thickening, or the presence of fluid. Evidence of fluid is obtained by palpation of the supra-patellar pouch with the palm of one hand, while the other palpates the patella and the pouches on either side of it When due to synovial thickening, the swelling is usually semi-elastic.

Limp. At first, when walking, the patient holds the knee moderately flexed to lessen the effect of the body-weight, but free extension is possible Later, however, it is limited.

Pain, at first moderate, later becomes acute The joint is easily tired and any sudden movement increases the pain Night cries are common.

Muscular Atrophy and Spasm. Atrophy is greater than can be accounted for by disuse and probably arises from some trophic disturbance Spasm affects the hamstrings, and the biceps, acting on the head of the fibula, pulls the leg backwards and rotates it laterally.

Shortening. The disease, by stimulating growth locally, may at an early stage cause lengthening, but in the more destructive lesions shortening is the rule, from retardation of growth and destruction of bone.

extra-articular, but in contiguity Excision of the focus without entering the joint may save the latter. Patients with this type of disease form only a small proportion

(2) Osseous foci discharging into the joint. There is no evidence that this type, when healed, ever leaves a freely mobile joint.

(3) No visible osseous focus This group is radiologically synovial Here the outlook is relatively favourable.

In the later stages these three usually co-exist, so that when the disease has lasted for a time no definite opinion can be given concerning the original site

The synovial membrane is thickened, grey, and translucent, and in places gelatinous or even caseous Fluid is present in varying amount, and adhesions form so that the outlying synovial pockets become loculated Granulations spread under and over the cartilage, which, being eroded by pressure and friction, may become

Fig. 173.—Advanced Tuberculous Disease of the Knee Joint.

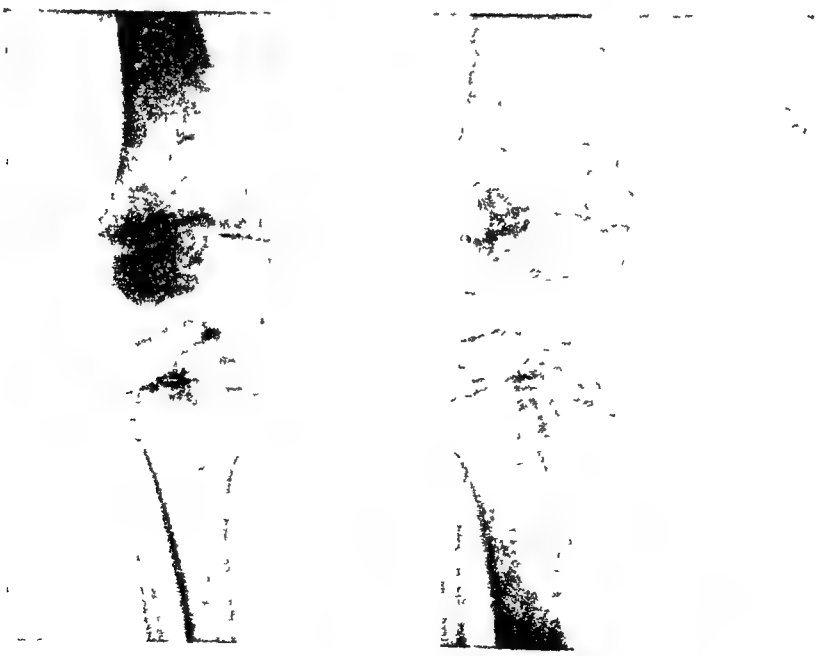

(a) (b)

Fig 174 —Extra-articular disease showing the possibilities of adequate treatment.

(a) 30 1 46 (b) 9 6 48

In cases of doubtful synovial disease the author carries out a biopsy of the inguinal glands, and if this is negative a diagnostic synovectomy in all patients over nine years of age. Since the treatment under that age will be immobilization in any event a synovectomy is not indicated

Differential Diagnosis

Chronic Traumatic Synovitis. After injury, enlargement of the joint may persist unduly. In children it is wiser to treat such a case as tuberculosis until the fluid has been examined.

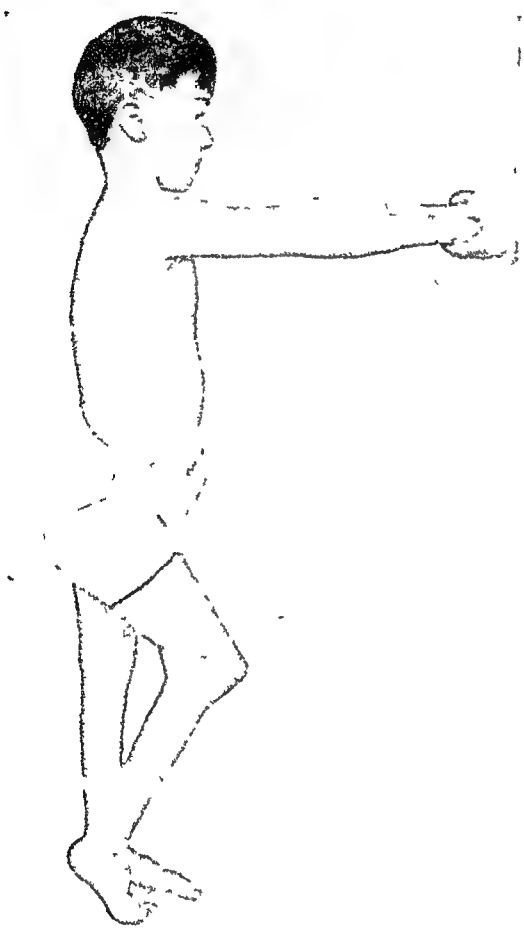

Fig. 177.—Tuberculosis of the Knee.
Flexion deformity caused by insufficient support after operative excision

Sub-acute Infective Synovitis may simulate a tuberculous joint, especially when a focus of disease in the bone suddenly bursts into the joint Aspiration will reveal the nature of the condition.

Gonorrhœal Synovitis. From an early stage this is more acute and painful, fixation of the joint is very marked, and there is a history of gonococcal infection.

Rickets generally affects more than one limb and there are signs in the gums, teeth, and elsewhere The disease is epiphyseal rather than articular.

Functional affections often simulate tuberculous disease, but positive physical signs are few in number and variable in their manifestations. A reflex stiffness of the knee, though more often the hip, may be caused by phimosis in young children, but is usually sudden in onset and exaggerated.

Acute Rheumatism is polyarticular, sudden in onset, and responds to salicylates quickly. Cardiac involvement and marked sweating are suggestive. Charcot's joint, hæmophilia, and arthritis deformans, should present no difficulty.

Syphilis. The symmetrical arthritis of congenital syphilis (Clutton's joints) is also to be remembered in that the knees are more often

Diagnosis

The history may reveal the likelihood of human infection, some previous manifestation of tuberculosis, or some loss of health and vigour. When a child develops a chronic swelling of the knee joint of an indolent character, with flexion and limitation of movement, diagnosis is, as a rule, easy, but there can be no certainty without histological or bacteriological examination.

Calvé emphasizes the importance of infection of the regional glands

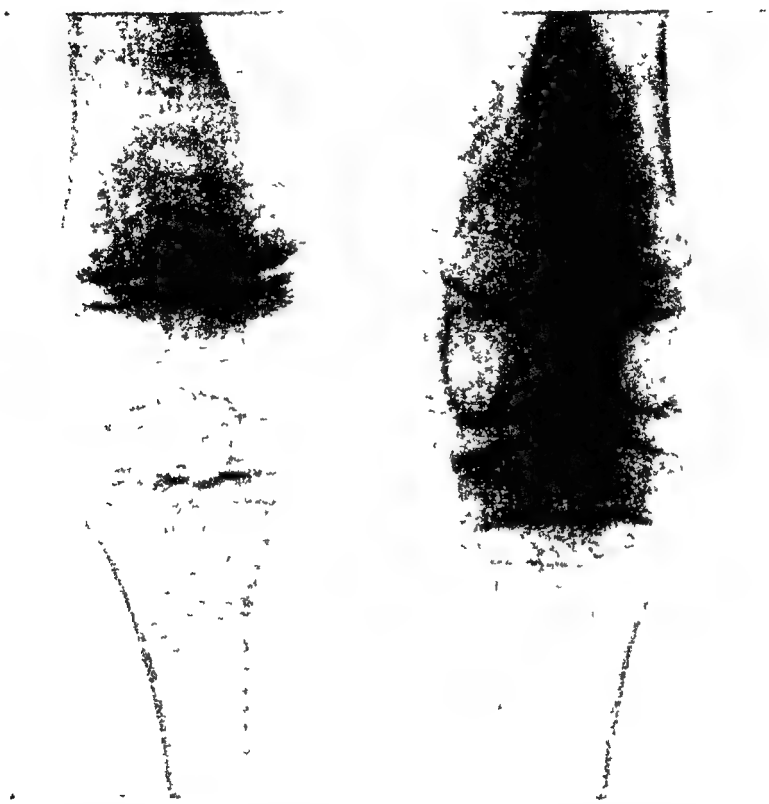

Fig. 176.—Tuberculous Disease of the left Knee Joint.

Growth has been activated, and there is now actual lengthening of the diseased leg. This is unusual though not uncommon.

in the groin proved by biopsy as an aid in diagnosis. An X-ray picture may be of value in showing signs of early disease, especially if comparison be made with the sound knee. Bilateral disease is very rare.

Provisional diagnosis and immediate appropriate treatment is the only safe course in the doubtful synovial type in children.

If all the signs of inflammation in the joint disappear after a few weeks' immobilization, Thomas's test is carried out: the immobilization is remitted and if no recurrence follows this freedom, further freedom is allowed, and the child who has had a toxic arthritis from a throat or other focus is soon without symptoms. But if the condition is tuberculous, warmth and swelling of the joint, and limitation of movement recur.

Treatment

As the patients suffer from tuberculosis of which the arthritis is only one manifestation, all need general treatment—preferably in a sanatorium—by physical rest, heliotherapy, selected diet, etc.

Local treatment is divided into conservative and operative.

Fig. 179.—Tuberculosis of the Knee. The result of operative fixation.

Conservative Treatment.

At an early stage, when the disease is acute and painful, and the joint flexed, rapid relief is obtained by traction in the recumbent position. Adhesive plasters are fixed to the leg and a Thomas's knee-splint with a knee-flexion piece applied. The knee piece permits of the pull being made in the line of the deformity, and, as treatment progresses, it can be adjusted daily until full extension is obtained. Great care must be taken to avoid backward displacement of the tibia. Correction of the deformity by wedge-plaster-of-Paris methods, or by "brisement forcé" should not be carried out. If, owing to the onset of ankylosis, the deformity does not respond to traction, operative excision must be considered.

When the knee is in a good functional position, that is, just short of complete extension, consideration has to be given, as in hip-joint disease, to the ultimate aim of treatment.

In the child, an attempt may be made to get a movable joint, and, as long as there is a possibility of this, traction may be continued. In view of the possibility of ankylosis, the joint should be very slightly flexed. Traction is applied to the leg, either by plaster or domette strapping or circular bandages. Domette slips easily and has to be adjusted daily, but is preferable after the more acute stage, as it has no tendency to irritate the skin. The splint is tilted at its lower end, or the bed is slightly raised, to allow the body-weight to act by counter-extension. This method is preferable in the young child, in the presence of sinuses, and wherever there is any hope of a mobile knee.

When the bone is seriously involved, ankylosis is the aim. For children under nine years of age a plaster-of-Paris case should be used. It is applied from the toes to include the pelvis, and accurately moulded

affected than any other joint. Furthermore, the two sides are by no means always simultaneously involved so that the diagnostic symmetry may not appear.

Prognosis

The immediate mortality is small—the osseous type of lesion bearing the greater mortality. Tuberculosis of the knee is seldom fatal; rather is it evidence of an infection which is often fatal.

Fig 178.—Subluxation of the Knee from extensive untreated Tuberculous Disease.

The functional result improves in proportion to early diagnosis and efficient treatment After excision a big proportion—as many as 88 per cent—get a sound bony ankylosis. Cases of bone disease do so only if the focus remains extra-articular.

In adults, the best result that can be expected is an ankylosed knee, and this can be secured most quickly and effectively by operation.

allowed to get up, but care must still be taken to protect the joint from weight-bearing and movement.

Favourable signs are the absence of pain or other evidence of active disease, good general health with gain in weight, and satisfactory evidence from X-ray examination.

In the ambulatory stage the patient wears a Thomas's knee-splint which at this stage is fitted with a patten end to make it impossible for the child to walk on his affected leg, and a patten is fitted on the boot of the sound limb. This splint is to be worn night and day for about six months.

At the end of this period, when treatment has lasted at least eighteen months, the third stage is commenced. The pattens are discarded, and the splint converted into a "walking caliper." The lateral bars at their distal ends are turned into a box in the heel of the boot, care being taken that, when standing in this splint, the heel of the foot does not quite touch the insole of the boot This ensures that no weight is brought to bear on the weak joint The splint is kept in position by the usual thigh and calf straps It is discarded at night, but worn throughout the day for at least two years, at the end of which time there should be little risk of recurrence This long period of immobilization does not lead to fixation in synovial disease Free and normal movement returns gradually and progressively in the synovial type of disease in children, once the knee is set free, and if the disease is soundly healed.

During succeeding years it is recommended that the patient be seen at intervals of from three to six months for some years, to prevent, if possible, any deformity or recurrence of the disease

Operations.

In children under fifteen years of age conservative treatment is recommended because its results are reasonably good. Further, the soft vascular bone of the epiphysis bends easily, even after the operation of arthrodesis, so that in any case a splint is necessary for a long period. If there is radiological evidence, however, of destruction of cartilage or there is subluxation arthrodesis is indicated in patients over nine years of age. The epiphyseal cartilage is sufficiently far from the end of the bone to leave the surgeon a margin for excision without damaging the growth centre Shortening of the limb does not therefore usually result beyond that due to interference with growth by the tuberculous process In adults the conditions are different the best that can be hoped for from conservative treatment is ankylosis, and this can be more rapidly and efficiently secured by operation Operation, therefore, is recommended unless there is some definite contra-indication, and indeed should invariably be carried out on the bony focus, in view of the higher mortality from osseous disease treated by immobilization

to the leg. This treatment should be continued for at least a year, the plaster case being changed at intervals of a few months if necessary, but it is essential that immobilization be continuous. There should be no remission of fixation during this period since the disease might

Fig 180—Tuberculosis of the Knee. Genu Recurvatum.
Radiogram of the same case as Fig. 175.

start afresh Plasters which do not include the hip and ankle are useless.

Ambulatory Treatment.

When treatment either by traction or by a plaster case has lasted for twelve months, the patient may, if conditions are favourable, be

patient is a child it is necessary until bone growth has ceased, otherwise a flexion deformity may occur at the epiphysis.

In the after-treatment it must not be forgotten that, though the operation removes the local disease, the primary foci remain and in most cases are hidden. The treatment by antibiotics and in the sanatorium must be long continued. Surgery without adequate after-care of the whole person is futile and a poor service to the patient.

Good bony ankylosis occurs in 88 per cent. of cases according to Henderson, of the Mayo Clinic. Failure to secure union may be due to operating while the disease is active or the patient's general condition too poor; to active tuberculosis elsewhere, to pyogenic infection from a sinus; or to ineffective immobilization. Amputation is only rarely indicated. It is carried out when either the patient or the limb has little prospect of recovery, and so is done in the very old, the very septic, the very ill and in those cases where the bone destruction is too extensive for arthrodesis.

TUBERCULOSIS OF THE ANKLE

In over 4,000 cases admitted to East Fortune Sanatorium the ankle was involved in 2·6 per cent. of the cases of bone or joint lesions. The joint is resistant to treatment, especially in adults, owing to the weight it has to support, its complex character, and the free communications of its synovial spaces.

Pathology

In early cases, in children at least, the disease may be seen to be in one of three groups as is common in other joints:

(*a*) Extra-articular osseous disease;
(*b*) Synovial disease,
(*c*) Intra-articular osseous disease.

(*a*) The extra-articular type may be in the neighbouring soft tissues in the bony structure, as for example the bone abscess seen often in the calcaneus but also in the talus and cuboid

(*b*) In the synovial type there is generalized decalcification of the bones with synovial thickening.

(*c*) The intra-articular type forms the largest group, and the ankle joint itself is the usual site though other smaller joints may appear to be the initial site.

Sinus formation occurs in the great majority of cases, though here this does not appear to have the same malign influence that it has in other joints and a sound though fibrous ankylosis usually results in children.

Extra-articular osteo-synthetizing operations are impossible in this joint because of its anatomical conformation.

Intra-articular Excision Arthrodesis. The best operation is an arthrodesis between the joint surfaces which is designed to promote bony fusion and to remove all diseased parts. This operation is carried out in adolescents and adults up to 50, but in children, only after about the age of 15, and when osseous foci are present. It should be delayed, however, in all cases until the general condition has been improved, and the local activity of the disease has been checked by treatment. Contra-indications to the operation, in addition to childhood, are:

(1) Active phthisis
(2) Extensive involvement of the shafts of the femur or tibia.
(3) Septic infection of sinuses.

The Operation. A tourniquet is used as it makes the operation easier, and because with it the patient loses less blood and the likelihood of toxæmia is lessened; but it should be removed, so that complete hæmostasis may be secured, before the nails are inserted. A U-shaped incision is made round the knee, with the connecting bar of the U distal to the tibial tubercle. The incision is deepened until the ligamentum patellæ is exposed. This is cut across above its insertion, and the joint is then flexed and opened. The flap is then dissected up and the supra-patellar pouch exposed The cruciate, medial, and lateral ligaments are divided and the diseased area exposed. All diseased tissue is now removed and a synovectomy carried out as completely as possible A thin shaving of bone is now removed with a small frame saw from the articular surfaces of the tibia and femur so that both retain their normal curves and fit accurately to each other The cartilaginous surface of the patella is similarly removed. This method allows easy adjustment of the angle of the arthrodesis. The joint is then extended to 170° and the ends of the bones are accurately adjusted.

In all cases it is better to retain apposition of the bones by the use of two excision pins or bone pins. These are inserted through the skin on both sides of the tibia below the joint and are easily removed in about six weeks. No drain is inserted.

After-Treatment

A plaster-of-Paris cast is applied from the toes to the crest of the ilium The knee joint is fixed at an angle of 170°, which is just short of full extension. A window may be cut over the incision and through it the stitches and nails removed Union should be complete in four to six months, when the plaster may be removed and a Thomas's walking caliper substituted This is worn for from six to nine months in the case of an adult or until the X-rays show sound union, but when the

Fracture of the Calcaneus has certain points of resemblance, but the radiogram removes any difficulty.

Prognosis

W. R D Mitchell has pointed out in an interesting monograph the extraordinary difference in the prognosis in children and in adults He says that it is uniformly good in children and equally bad in adults, and his figures appear to bear this out Over 95 per cent. of children adequately treated and over 80 per cent not so well treated give good results A good result is where the disease is arrested and no disability results. In adults only 27 per cent were able to go back to work with



Fig 183 —Fungating Ulcer arising from Synovial Disease of the Ankle.

the disease cured, and he believes that there is no guarantee that these cures are permanent.

Treatment

Following on Mitchell's convincing paper, with which the author is in substantial agreement, the treatment is somewhat different in the child under 17 and in the adult

(*A*) *In Children*

The treatment is entirely conservative locally along with the very important general treatment already laid down

Immobilization. This is carried out fully and continuously and during the greater part of it the child should be in bed.

(*a*) If there are no sinuses a plaster-of-Paris case is applied from above the knee to the toes It should be fairly light and moulded to the bony prominences It has the disadvantages of hiding the formation of abscesses and of preventing local heliotherapy, but, on the other hand, it fixes the joint as no other method does However, if an abscess does form it won't suffer by being enclosed, and if it discharges it will soon make its presence known The foot is placed at a right angle, care being taken to avoid eversion. This casing may be removed

Symptoms and Signs

Limp and pain are the earliest symptoms. The pain is more acute in those lesions that spread from the bone, being intensified by pressure on the calcaneus, either by increased plantar flexion, or by lateral compression of the bone. The first deformity is dorsiflexion, to relieve tension on the talus, but later, with the progress of the disease, plantar flexion and equino-valgus deformities develop, both of which relieve the pressure of the weight of the body on the foot. The patient then walks stiffly, and on his toes. Swelling is evident in front of the joint in bone disease, and round the malleoli in synovial disease. Local heat and redness may be present, and there is the usual limitation of movement from muscular spasm. In the later stages, abscesses and sinuses are common. The radiogram shows rarefaction, and foci of disease in the talus

Fig 181.—Tuberculosis of the Ankle.

The clinical appearance of synovial disease in the ankle-joint

Diagnosis

A chronic mono-articular arthritis with limitation of movement, pain and tenderness and evening pyrexia is probably tuberculous. The osteoporosis seen on X-ray examination is characteristic Biopsy is not carried out as it is apt to produce sinus formation.

Fig 182.—Tuberculosis of the Ankle

Advanced disease with sinus formation, necessitating amputation

Differential Diagnosis

Chronic Traumatic Synovitis often results from a severe sprain, but the tenderness is usually localized over the ligaments. The swelling is a general puffiness and the X-ray film is negative.

Arthritis Deformans. As a rule, other joints are affected and there is usually less pain and an absence of muscular spasm. The radiogram is helpful, there being a mottling of the bones. Diagnosis, however, may be difficult.

case. The duration of each stage, however, varies greatly. The onset of pain, an increase of swelling, or of limitation of movement, fever, or loss of weight, may necessitate delay in the passage from one stage to another. Should a sinus develop, as it frequently does, it is not interfered with surgically unless a definite sequestrum is present. In such a case the sequestrum is removed with the least possible trauma. Otherwise the sinus is kept covered with sterile gauze changed sufficiently frequently to prevent secondary infection.

Traction methods, from their difficulty of application, have not been popular, for the relief of pain, they are not superior to efficient fixation.

There appears to be no place for operative treatment in the ankle of a child.

(*B*) *In Adults*

The result of treatment in adults is bad probably because patients won't stand the necessarily prolonged immobilization and inactivity when their only complaint is a "sore ankle" and treatment therefore often becomes a compromise.

In an uncomplicated case in an adult conservative treatment is continued for six months and the case is reviewed at the end of that time, and unless there is a marked improvement more radical measures are suggested. If the disease has not progressed or is improving, then immobilization is continued. In the majority of cases in adults, however, the disease has extended in spite of treatment, and amputation is advocated. The disease is shortened, metastatic involvements from this area are prevented, a long illness is cut short, and with the modern type of prosthesis the patient is little handicapped by losing his limb. Mitchell believes that there is little justification for the less radical procedures such as scraping, excision, astragalectomy, and arthrodesis in this joint.

TUBERCULOUS DISEASE OF THE TARSUS

As in the ankle joint, the talus is frequently the seat of the primary disease, it may, however, originate in the calcaneus The mid-tarsal joint is most frequently involved Two varieties are described. In one, the disease starts near the surface of the bone and spreads rapidly to the neighbouring joints, while in the other, which is frequently seen in the calcaneus, the disease is deeply seated in the substance of the bone and is difficult to diagnose from a Brodie's abscess Endarteritis of the nutrient vessel is common.

Symptoms

Pain is an early symptom, but is usually less severe than in disease of the ankle joint. Inversion and eversion are limited when the posterior bones are infected, while in cases of more distal infection, movements at the mid-tarsal joints of the foot are also restricted. Swell-

in from three to four months to permit of X-ray examination, after which it is reapplied for a similar period.

(*b*) If sinuses are present or expected, a right-angled foot splint of the crab type, or a celluloid moulded case, is used. The foot is retained in the splint with encircling bands of adhesive plaster and a firm bandage applied over all to improve the immobilization.

It is inadvisable to allow walking at this stage as the diseased foot and ankle readily become œdematous.

At the end of about eight months, or when recalcification is complete as judged by a series of X-rays, the splint may be substituted in those cases where plaster-of-Paris was in use. This allows the minimum of

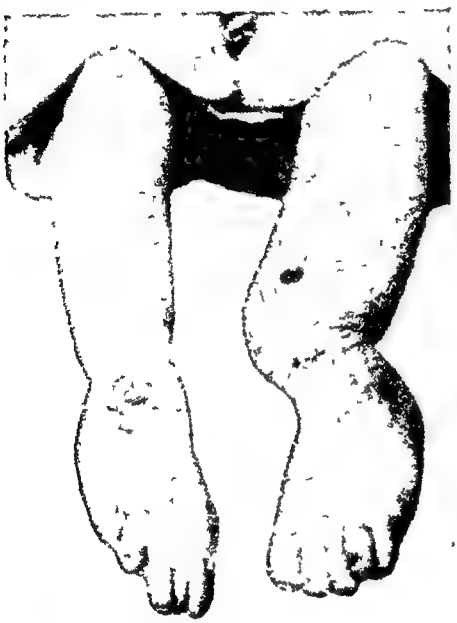

Fig 184—Bilateral Ankle Disease of long standing and with little active Disease

Fig 185—X-ray of Bilateral Ankle Disease

movement and permits of careful observation After four months' use, the splint is discarded entirely at night, a short walking caliper being worn during the day. This, if properly applied, relieves the foot and ankle of a certain amount of weight-bearing. Careful fitting is essential. The upper cuff of the caliper must lie smoothly round the leg immediately below the head of the fibula and the medial condyle of the tibia, and when fitted into the shoe, the patient's heel must be clear of the insole If attention is directed to these two points the ankle will be relieved of the weight of the body which will now be brought to bear on the head of the fibula and the condyle of the tibia The short walking caliper is worn for a further period of at least six months

The above description applies to the treatment of a straightforward

infected with tuberculosis in children, but at the termination of the growth period the disease is more common and is not infrequently bilateral Of the bone and joint lesions admitted to East Fortune Sanatorium, 3 per cent. involved the sacro-iliac joint and slightly less than half of these were complicated by lesions at other sites All but one of the cases occurred after the age of 15.

The disease may originate in the lateral mass of the sacrum, or may spread thence from the lumbar vertebræ It is also seen not infrequently in association with a tuberculous hip The synovial membrane then becomes infected and finally, by extension, the ilium. *Abscess formation* is the rule and usually occurs early in the disease, often as the first sign though it is likely, of course, that the disease has been of a latent or symptomless character in such cases According to Elmslie it is rarely that pain and abscess are coincident, as once an abscess is diagnosed it has broken through its confining walls and relieved the tension that causes the pain

In the great majority of cases the abscess is situated over the posterior aspect of the joint, much less commonly in other regions such as the groin or gluteal region It is rare in the pelvis. In a considerable number of cases a sinus results from this collection of pus

Symptoms

The onset is frequently insidious and an abscess is often the earliest indication. Usually, pain and tenderness are the first symptoms.

Pain is felt most commonly as a sciatica or in the hip or lumbar region, or over the joint. It is increased by movement, and is worse at night owing to the increased strain on the pelvic joint when the lordotic curve is obliterated. The pain is increased by the strain of sitting for long periods, stair-climbing, or stooping. In women it is aggravated at the menstrual periods It is referred to the sacrum or the back of the thigh and is increased by jars, sudden turns as in bed, and often by coughing or laughing. In sacro-iliac disease suggestive attitudes are frequently observed. In the standing position the body is inclined away from the diseased side, and on rising the hands are used to support the spine and at the same time to keep it rigid. Only short steps are possible in walking owing to the accompanying spasm of the hamstrings

Motion is limited in various ways Forward bending with straight knees is limited, but with the knees flexed and the hamstrings relaxed, as in sitting, the extent of flexion is increased—in this respect differing from what is found in lumbar disease Extension and lateral flexion are also limited It will be found that straight leg-bending in the recumbent position is limited, and usually pain is produced when the movement is attempted on either side. This is known as Goldthwaite's sign.

ing is evident on the dorsum of the foot, over the region of the disease. A limp and an equino-valgoid deformity complete the picture.

An X-ray examination shows general osteoporosis, and often a focus of disease in one of the bones.

Diagnosis

A diagnosis is made from the swelling, limp, deformity, and X-ray appearances. Kohler's epiphysitis of the navicular has to be considered in the differential diagnosis.

Fig 186.—Tuberculous Disease of the Calcaneus with a central Sequestrum.

Treatment

Treatment is similar to that carried out in disease of the ankle joint, but operation is more frequently called for, usually that of sequestrectomy.

TUBERCULOSIS OF THE SACRO-ILIAC JOINT

The sacro-iliac articulation is a true joint, with all the usual joint structures, and therefore subject to all joint diseases. It is rarely

described here, the extra-articular method of Albee, and Smith-Petersen's one which, though intra-articular, appears to give very satisfactory results. Whatever operation is carried out, it should, like all other similar operations, be reserved until any acute features have settled down and healing has started.

An anterior shell is made for the patient some time before, and he gets an opportunity of becoming accustomed to the prone position.

The best incision for exposure is that of Smith-Petersen. It is a semilunar one along the posterior two-thirds of the iliac crest, curving around the posterior iliac spine, then running parallel with the fibres of the gluteus maximus for a distance of 2 to 3 inches.

1. Smith-Petersen's Operation. This is carried out as described on p. 683 Should any tuberculous material be met with, an attempt at local eradication of the disease is made and replacement by cancellous chips of bone—of course under an antibiotic cover.

2. Albee's Operation for Combined Sacro-iliac and Low-lumbar Disease. "The posterior-superior spine, the wing of the ilium, and the first spinous process of the sacrum are reached by a curved incision. The spinous processes of the last one or two lumbar vertebræ are split, with their attached ligaments, by the author's (Albee's) thin, wide osteotome, forming a gutter to receive the ends of the graft. A cleft is made in the posterior wing of the ilium by driving a thin osteotome ½ inch in width into it just anterior and medial to its posterior-superior spine and in a direction laterally from within outward The lateral graft, which is later secured, is formed with a wedge end to be driven into this cleft, the other end being joined by a carpenter's half-mortise to the spinal graft.

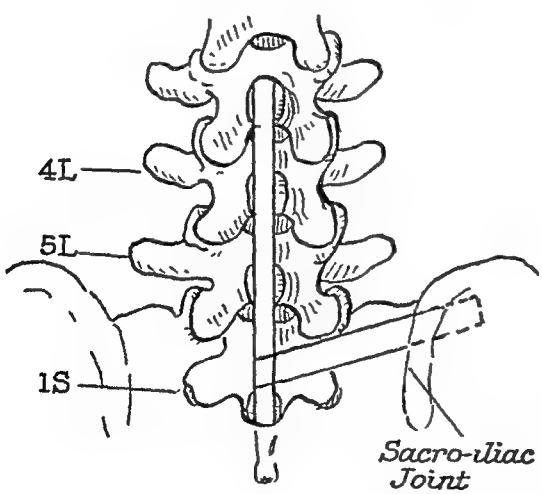

Fig. 187.—Tuberculosis of the Sacro-iliac Joint. Albee's operation for fusing the sacro-iliac and lumbo-sacral joints

"A surface of the sacrum is denuded to furnish additional contact with the graft. The wound is packed with a saline compress and, with the patient still in the prone position, the leg is flexed and a graft of sufficient length removed from the crest of the tibia by the motor-saw to furnish material for the spinal graft and the lateral bridge to the ilium The width of the graft should be three times the thickness of the cortex. The thickness should include the whole cortex, periosteum, endosteum, and a small amount of the adhering marrow. The spinal graft is placed in its prepared bed

Diagnosis

Albee says that the following symptom-complex is pathognomonic of an affection of the sacro-iliac joint.

1. Pain at the joint on turning over while in the recumbent position.
2. Discomfort when lying on the back.
3. Pain on sitting on the affected side, relieved by sitting on the opposite buttock.
4. Pain in the joint on forward bending.
5. Pain on pressure over the joint.
6. Listing of the spine to the opposite side.
7. Positive Goldthwaite's sign.

The conditions likely to be confused with sacro-iliac disease are arthritis of the hip, disease of the lumbar vertebræ, lumbago and sciatica X-rays are not particularly helpful in the early stages, but in time show erosion of the joint line, foci in the ilium or sacrum, or some alteration in the joint line, but unlike most tuberculous joints very rarely decalcification.

The prognosis is reasonably good especially as an isolated uncomplicated lesion. A sinus or an associated lesion increases the mortality rate.

Treatment

Conservative treatment follows the same lines as that of Pott's disease of the lumbar vertebræ. Recumbency with adequate protection and immobilization of the joint are indicated; these can best be carried out by a double spica of plaster of Paris, extending from below the nipples to below both knees The pelvic part of the plaster should be firmly moulded to the contour of the pelvis, and retained in place for from twelve to fifteen months. Thereafter prolonged protection of the joint is necessary. Where there is extensive destruction of the joint it is wiser to put traction on the legs while in a Jones' abduction splint This tends to prevent upward dislocation of the ilium on the sacrum This is also useful where sinuses are present. Most cases heal by bone fusion

Operations.

In some cases an attempt is made to shorten the length of treatment by an operative fusion. It is very doubtful whether the operation achieves this purpose, and indeed Seddon has stated that the gain is only about one month, in that the average treatment conservatively is eighteen months and by operation seventeen months. Operation may be of use, however, where a stable bone fusion is slow or where the disease has healed by fibrous union. It is, of course, contra-indicated in the presence of a sinus and is not advisable in children or where there are other lesions, though if there is a lesion in the lower lumbar vertebræ a double spinal fusion operation may be considered.

Methods of arthrodesing this joint are numerous. Two of these are

(*f*) It may follow the course of the posterior primary division of the intercostal nerve or its branches. Occasionally a thoracic abscess under tension transmits the pulsation of the aorta to the spinal column below the area of disease and an X-ray will show anterior erosion of the bodies just as in an aneurysm This is known as an aneurysmal syndrome.

(*iii*) *Lumbar Region*

(*a*) A lumbar abscess may extend forwards to enter the sheath of the psoas, and may then gravitate downwards until it appears below the inguinal ligament on one or other side of the femoral vessels

(*b*) It may pass down in the sheath of the psoas, and then pass laterally deep to the fascia iliaca to appear just medial to the anterior superior spine of the ilium

(*c*) It may track forwards without entering the sheath of the psoas. and infiltrate along the lines of the great vessels; thus it may accompany the external iliac and femoral vessels into the thigh, or the hypogastric vessels into the cavity of the pelvis

(*d*) It may extend laterally into the sheath of the quadratus lumborum, and so become superficial above the crest of the ilium.

(*e*) It may follow the dorsal branches of the lumbar arteries, and point below the last rib close to the spinal column.

(*f*) The abscess may also follow the course of the posterior primary division of a lumbar nerve, to point some distance from the middle line of the back.

Pott's Paraplegia.

Paraplegia occurs as an unfortunate sequel to Pott's disease in 11 per cent of cases according to the statistics of Butler and Seddon. Age has little influence on the onset of paralysis, although it is more commonly seen in childhood because of the relatively higher incidence of the disease at this age period.

Paraplegia is rarely met with in disease below the level of the first lumbar vertebra since the cord has terminated below this point, and as thoracic disease is far more common than cervical disease the majority (85 per cent) of paraplegias accompany thoracic lesions. In addition to the greater frequency of disease in the upper and middle thoracic region, the narrowing of the bony canal here and the difficulty in securing complete fixation during treatment increases the probability of paralysis

The error responsible for the paralysis may arise in the bones, the membranes, or in the cord itself

(1) *Bone Causes* Pressure on the cord as a result of the angulation of the anterior wall of the bony canal may, though rarely, give rise to paralysis, and symptoms of cord compression may also arise in the presence of a partial dislocation of the vertebra, a sequestrum, the extension of tuberculous granulations into the canal, or a cold abscess.

may remain, but more usually it becomes further disseminated along one or several courses. It may pass backwards and invade the vertebral canal—a serious complication, resulting, as it usually does, in pressure on the spinal cord. It may track forwards and become diverted by various anatomical structures such as blood-vessels, nerves, or muscles. The abscess may therefore come to be situated at a considerable distance from the site of the original disease, and a knowledge of the possible situations of cold abscesses, and the factors which determine them, is consequently of great importance.

(*i*) *Cervical Region.* The pathway traversed by tuberculous debris in disease of the cervical spine is determined by the attachment of the cervical fasciæ.

(*a*) It may collect behind the prevertebral fascia, in front of the vertebral body, constituting one variety of retropharyngeal abscess; ultimately such an abscess points at the posterior edge of the sterno-mastoid muscle

(*b*) It may penetrate the prevertebral fascia, and so enter the mouth or one of the visceral compartments of the neck.

(*c*) It may track between the lateral surface of the vertebra and the posterior cervical muscles, and, perforating the deep cervical fascia, appear on one or other side of the spinous process

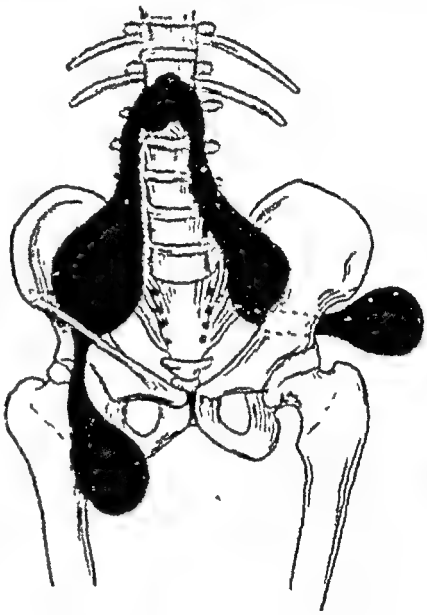

FIG. 119.—Abscess Formation in Pott's Disease

Diagrammatic representation of the various courses which a tuberculous abscess arising from the thoraco-lumbar spine may take (After Calot)

(*ii*) *Thoracic Region* In thoracic Pott's disease the abscess is usually small and frequently remains in close contact with the spine; not uncommonly it gives rise to paralysis from pressure on the cord. If the abscess is large it may extend in a variety of ways:

(*a*) It may perforate the anterior longitudinal ligament and occupy the posterior mediastinum.

(*b*) It may pass laterally through the pleura, giving rise to a tuberculous empyema.

(*c*) It may gravitate downwards beneath the medial arcuate ligament and assume the characteristics of a lumbar abscess.

(*d*) It may track backwards between the transverse processes.

(*e*) It may extend along the intercostal vessels and reach the surface, either with the lateral or the anterior intercostal branches.

Fanconi in 1931 described a case of renal diabetes in which there was retardation of growth The features of Fanconi's syndrome are resistant and intractable rickets, hypophosphatæmia, renal glycosuria, acidosis and, in some cases, calcinosis. It is an affection of early life usually beginning within the first two years of life Early signs are retarded development, loss of appetite, gastro-intestinal disturbances, bouts of fever, and albumin and casts in the urine. Plasma phosphatase is raised and the excretion of calcium and phosphorus is excessive Rachitic bowing of the legs and fractures may occur Fanconi suggested that the condition is tubular renal rickets as opposed to glomerular renal rickets and results from hereditary inadequacy of the tubular epithelium

The Radiological Appearances

Parsons has given the most comprehensive account of the X-ray changes in renal rickets and it is his descriptions that are followed here He finds that the bone changes fall into three well-defined groups

(*1*) *Atrophic Type* The whole bone is fragile and porotic and the epiphyseal cartilage broad and irregular. The metaphysis is broadened, and its extremity uneven and ragged These changes, of course, are similar to those seen in rickets

(*2*) *The Florid Type.* In this type, as in ordinary rickets, the end of the metaphysis becomes cup-shaped from the greater absence of calcium in the central axis of the bone than beneath the periosteum. The broadening of the metaphysis is also more marked

(*3*) *The Woolly, Stippled, or Honey-combed Type* In this type the

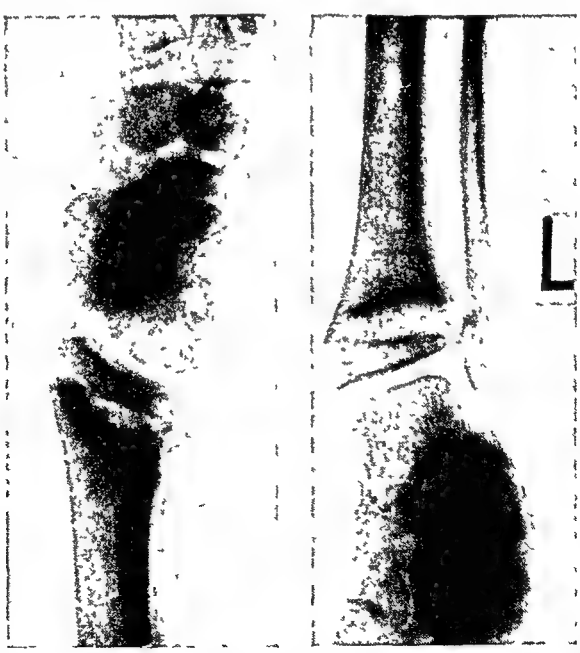

Fig 73 —Renal Rickets at the lower ends of Tibia and Radius

Note the "cupping" of the diaphysial end, but no gross changes in the shaft The epiphyses at the lower end of both femora and at the upper ends of both humeri were separated.

especially detailed observations on the bone changes, and has emphasized the fact that the disturbance of growth may be so great as to lead to dwarfism. He has applied the term Renal Dwarfism to this extensive type of the disease, which is also known as Renal Rickets.

Clinical Features

In a number of cases symptoms are present from early days of life: in others, the child is normal for a few years before symptoms arise.

These may be considered in two groups:

1 Those pertaining to the renal lesion.

2. Those pertaining to the disturbance of growth.

(1) *Features pertaining to the Renal Lesion.* The most prominent kidney signs are polydipsia and polyuria. Indeed, thirst is often the earliest evidence of the disorder The urine is of low specific gravity, and the urinary output may be as much as 1,200 to 3,700 c.c. daily. Albumen and casts are usually present at some stage of the disease, and the cardiovascular symptoms of renal origin may appear, though rarely. Ultimately signs of kidney failure—headache, drowsiness and gastro-intestinal disturbance—arise, and ultimately death occurs from uræmia From the time of onset of the disease, tests of urinary function show a marked lowering of renal efficiency. The blood urea is constantly raised. Thus in eight cases reported by Barber the blood urea varied from 73 to 300 mgm. per cent., while Ogilvie records a case where the blood urea shortly before death was 490 mgm. per cent.

(2) *Features pertaining to Disturbance of Growth.* The children are always stunted in growth, often to a degree not equalled by any other form of infantilism. The body-weight is correspondingly small, though malnutrition is not present Patients surviving beyond puberty may show infantilism as well as dwarfism. The mental development is normal up to the age of puberty. The secondary sex characteristics do not develop, however, and after the age of puberty mental sluggishness is the rule.

The Bone Changes. Genu valgum is the commonest manifestation of renal rickets, but there may also be enlargement of the epiphyses at the wrist and ankles, a costo-chondral rosary, Harrison's sulcus, or bow leg. Occasionally bending occurs at the enlarged epiphyses.

The age of onset of the bony changes is variable. Genu valgum becomes apparent only between eleven and fourteen years, but Parsons has found bone changes as early as sixteen months. The average age of recognition of deformity is between five and seven.

Cases have been described with an associated hyperplasia of the parathyroid gland and these were interpreted as a composite picture of osteitis fibrosa and true rickets Others suggested that the parathyroid hyperplasia resulted from the inability of the kidneys to secrete phosphorus and that the parathyroid hyperplasia in turn was responsible for the bone lesions

The blood serum shows an extreme degree of lipæmia and a high grade of nitrogen retention. It has usually been found that the blood phosphorus value is high, while the serum calcium is low or normal. It is low when tetany is present. Chown has lately pointed out that in some cases, and in all cases at some period, the reverse obtains and there is hypercalcæmia, and increased excretion of calcium by the kidney. This can be explained as a result of immobilization of his patients in bed.

The Cause of Renal Osteodystrophy

The nature of the essential disturbance in so-called renal rickets is not positively known. In the usual view there is, in consequence of a pathological renal state, an endogenous disturbance of calcium and phosphorus metabolism The kidneys are unable to excrete phosphate, so that it tends to accumulate in the blood serum Part of it is thrown out into the gut, where it combines with the calcium of the diet and so prevents the absorption of the latter. In this way, a low calcium form of what for all practical purposes is rickets develops The serum calcium may be maintained at a comparatively normal level by the withdrawal of calcium from the spongy skeleton This is the view to which Shipley and Parsons subscribe.

Chown has recently brought forward another possible explanation In a case of his own, he discovered aplasia of the pituitary. The infant died at an early age, but characteristic bone changes were already present, along with well marked thirst and polyuria. The kidney changes, on the other hand, were apparently slight and consisted of compression and destruction of the renal tubules by calcareous deposits There was hypercalcæmia. Chown regards the pituitary changes as significant. Pituitary disease in childhood is itself often associated with dwarfing of the stature and infantilism, while polyuria and thirst are the features of diabetes insipidus, which is due to a lesion of the associated diencephalon. He supposes that the bone changes are also attributable to the pituitary disturbance, which in some way, at present obscure, is known to govern the growth of the skeleton. Excess of calcium—derived either as an excess from the diet or from the maintenance of absorption and cessation of the growth of the skeleton—leads to increased renal secretion of the mineral. It is the lowered renal excretion of calcium which in his opinion leads to the calcium deposits in the renal substance, and secondary destructive and sclerotic changes in the kidneys. In this view, renal rickets is a misnomer and the condition would be more appropriately called pituitary rickets These views are of great interest, but cannot be held as proved, and the first explanation is at the moment the more generally acceptable.

Another possible explanation is that the chronic illness results in upset of growth of the cartilage cells with improper maturation and calcification.

metaphysis is grossly increased and appears irregularly honey-combed or stippled or woolly, the bone appearing moth-eaten as if it were being eaten away sub-periosteally.

The changes do not progress to a uniform degree in all the bones of the skeleton, but in the majority of cases the type of change—atrophic, florid or woolly—is constant for all the bones affected.

The Pathological Changes

The radiological examination of a patient with renal osteodystrophy is directed to the demonstration of calcification in the kidneys, irregularities of the renal pelves and ureters by pyelography and changes in the skeleton. Calcium deposits in the kidney, with or without calculus formation, may be found in hyperparathyroidism but are not common in chronic nephritis.

Radiological changes in the skeleton depend on the duration of the disease. In early cases there is only osteoporosis. Later the typical appearances of renal osteitis fibrosa are seen.

The renal lesion is typical of chronic interstitial nephritis. On occasion (as in Brockman's case) there has been in addition a condition of congenital cystic disease

The Skeletal Changes. Parsons has had an opportunity of observing the bone changes in a typical case. The epiphyseal cartilage showed increased thickness, the calcified zone was the site of an irregular deposit. The metaphysis was broadened, and contained islands of cartilage amongst ill-formed osteoid tissue. In consequence of the presence of so much cartilage, the metaphysis is apt to be bent on the shaft, leading to considerable deformity, which may simulate displacement of the epiphysis

Brockman has described the histological differences at the growth disc in ordinary and in renal rickets. Instead of excessive proliferation of cartilage cells and abundant formation of osteoid tissue with little if any fibrosis in the adjacent marrow as in rickets, we find in renal rickets a partial or complete failure of the normal proliferation of cartilage cells and an absence of proper cartilage columns. The formation of bone is limited, and that which is formed is being actively absorbed by osteoclasts. There is much fibrous tissue extending into the adjacent marrow while the rest of the red marrow is completely fatty. The vascularity of the juxta-epiphyseal region is increased though islets of cartilage may be found deep in the metaphysis This picture is possibly due to protein deficiency. Usually in the growing child there is very little difference between renal and ordinary rickets except for the underlying etiology.

The Blood Chemistry in Renal Osteodystrophy

Chemical analysis of the blood is essential in establishing the type of renal dystrophy and in excluding hyperparathyroidism.

The Nature of the Bone Changes

All the bones of the skeleton show marked rarefaction, and are so soft as to be cut readily by the knife. Frequently the bones are grossly deformed The trabeculæ of the bones are attenuated or absent, and the interstices of the spongy bone filled with vascular fibro-fatty connective tissue.

The Histological Appearance

The trabeculæ of the bones are thin and eroded, and in places replaced by fibrous tissue or osteoid tissue. Osteoclastic activity is marked, and the Howship's lacunæ large. The interstitial tissue is vascular and consists of young connective tissue

The Deformities

Any of the bones of the skeleton may become grossly deformed, but bones subjected to muscular strains, or the influence of posture or gravity are the most grossly disturbed. The lower limb bones are therefore more affected than the arm bones, and curvatures of the femur and tibia and coxa vara are common Kyphosis is also frequent The changes in the pelvis are amongst the most interesting. The pressure of the femoral heads is associated with medial displacement of the acetabula. The angle of the pubic symphysis therefore becomes more acute, and the pubis projects as a sharp beak The sacral promontory rotates forwards under the body-weight, and the upper pelvic aperture therefore assumes a trefoil shape This particular form of pelvis has been used as an argument against the resemblance between rickets and osteomalacia, since in rickets it is more usual to find a flat pelvis. Preston Maxwell has disposed of the objection with certainty, however, for he has demonstrated that when the rachitic infant is carried about in a sitting posture, a typical tri-radiate, or trefoil, pelvis develops, whereas if the infant is not walking and is kept on its back the typical flat pelvis results The rib deformities are similar to those of rickets In some cases multiple almost symmetrical radio-translucent bands of diminished density resembling fractures appear in the cortex of the bone There have been many suggestions to explain the mechanism of pseudo-fractures. Some believe they are the result of erosion of the softened cortex by contained arteries

The blood chemistry examination usually shows little deviation from normal values for calcium and phosphorus, although the phosphorus values tend to be high Normal serum phosphatase is also found.

The Cause of Osteomalacia

Formerly regarded as an endocrine or toxic disturbance, modern opinion is unanimous that osteomalacia is an adult form of rickets, in which as a result of lack of calcium the lime stores of the skeleton are depleted in an attempt to preserve the circulation of this essential element.

Prognosis

Complete cure of the skeletal dystrophy may occur if the individual survives, for after the age of sixteen or seventeen there is much less liability to tetany, and the demand for calcium to ossify the bones is in abeyance.

During the course of the disease there may be remissions associated with improvement in kidney function and better excretion of phosphate.

Nevertheless, the ultimate prognosis as to life depends on the renal pathology. The renal dwarf is especially liable to intercurrent infection which is especially apt to prove fatal. The occurrence of bone deformities is itself a grave omen, and the average duration of life after their appearance is said to be less than two years. It is important for the surgeon to remember this, as operative interference is not only of little avail but is almost certain to hasten a fatal issue

Treatment

The treatment of patients suffering from osteodystrophy with chronic nephritis is purely that of the underlying renal disease. Treatment is of little avail in bilateral polycystic disease of the kidneys and in bilateral renal hypoplasia. Where there is a congenital lesion of the renal tract, such as a posterior urethral valve, early surgical removal of the obstruction may be life-saving. Surgical intervention if it is to be successful must be undertaken before puberty. When the bone changes are advanced the renal damage is usually considerable.

The most striking results have been obtained in hyperchloræmic renal acidosis and nephrocalcinosis. An organic acid such as citric acid should be given in conjunction with sodium citrate to aid absorption of calcium from the intestines. Vitamin D should also be given in those cases to help calcification of the skeleton In the active stage of the osteodystrophy, weight-bearing should be prevented, and splints may be applied to limit deformity until spontaneous remission of the disease occurs Threatened renal failure, of course, precludes an anæsthetic

OSTEOMALACIA

Deficient absorption of calcium and phosphorus in infancy leads to rickets If similar conditions prevail in adolescence "late" rickets may ensue. Even in the adult, when all bone growth has ceased, bone is not in a static condition, but is constantly being absorbed and reformed Osteomalacia is a metabolic disease of bone in which there is a deficient mineralization of the bony matrix due to the lowered concentration of calcium or phosphorus or both in the body fluids as a result either of impaired absorption from the gastro-intestinal tract or of increased renal excretion.

2. Starvation Osteomalacia. This form of bone softening is occasionally observed in circumstances of great food deprivation, and is due partly to an absolute lack of calcium in the diet and partly to avitaminosis. It was seen in an extreme form in Russia during the starvation period following the revolution, and in Vienna. It is occasionally met with in the depressed industrial centres of the North of England

3. The Osteomalacia of Idiopathic Steatorrhœa. In this disease there are fatty stools, dilatation of the colon, and anæmia. The history usually goes back to infancy, and the lack of skeletal development is due to inability to absorb calcium as a result of the excess of free fatty acid in the bowel In more severe and long standing cases the changes of cœliac rickets appear. At any time in the course of the disease, if the supply of calcium for absorption is insufficient for general requirements the deficiency may be made good by withdrawing calcium from the bones, so that bone absorption occurs and, in some cases, the features of osteomalacia.

Clinical Features

All varieties of osteomalacia are rare in this country, but the puerperal form is common in China. The most prominent symptom is backache across the loins or in the dorsal region and sometimes about the hip Often there is acute aggravation of the pain due to spontaneous collapse or fracture of the bones. A reduction in height from spinal collapse is frequent, while the back may show clinically an arched kyphosis in the dorsal region, collapse of the whole back with flat lumbar region, and characteristic deep furrows in the soft parts. There is also great muscular weakness, which may simulate paresis, especially where atrophy is present as well The muscular hypotonicity may lead to an uncertain, feeble gait. Ultimately the individual may become bedridden. Occasionally signs of tetany may arise.

Radiography

The X-ray picture is final. There is a calcium deficiency of the bones, especially the vertebræ, which may be wedge-shaped but more characteristically fish-tailed with marked bi-concavity and enlarged discs. The vertebræ are compressed, especially in the lumbar region, in some cases irregularly so

The Course of the Disease

The duration of the disease, if untreated, varies from five to twenty or more years, depending on the exact factors producing it In the pregnancy type, there is often remission when pregnancy and lactation have terminated

Treatment

The administration of a diet of high calcium value, combined with

The deficiency of $Ca_3 PO_4$ may be due to defective absorption from :

1. Inadequate amounts in the dietary ,
2. Lack of vitamin D ;
3. Gastro-intestinal disease which prevents the absorption of the lime.

It may be contributed to by excessive excretion of calcium and it is not unlikely that more than one factor is operative in individual cases. The following clinical types may be recognized :—

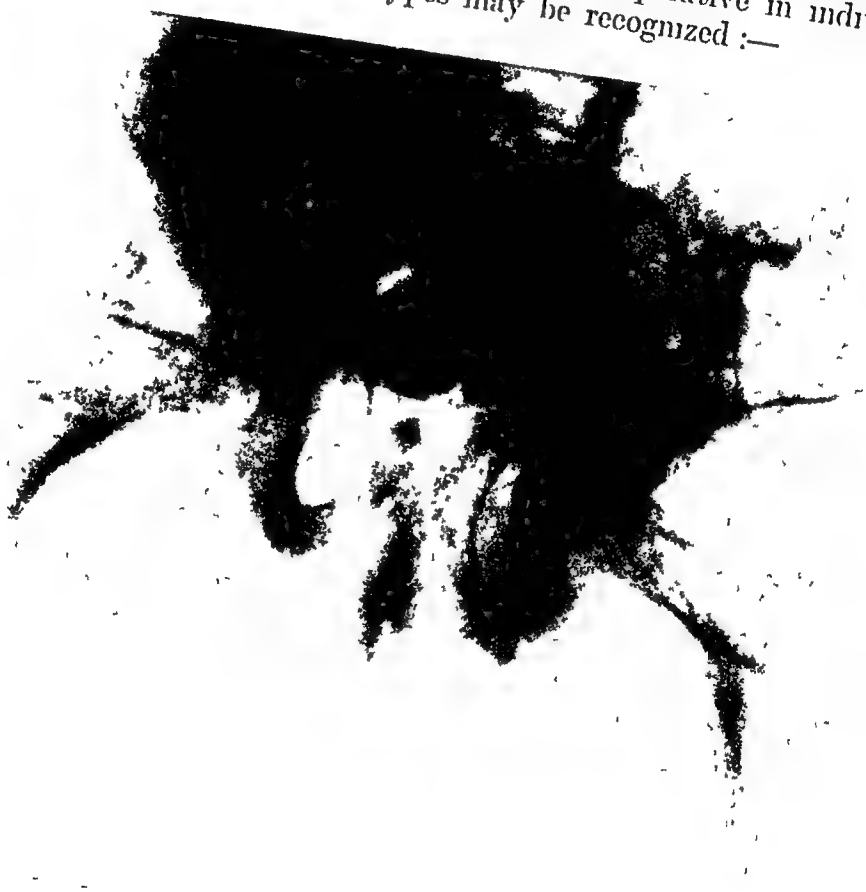

FIG 74.—Osteomalacia

A radiogram from a severe case of osteomalacia The effect of weight-bearing on the bones is well seen

1. Osteomalacia of Pregnancy. In the late months of pregnancy a large surplus of calcium is necessary for ossification of the fœtal skeleton, and during lactation there is added excretion of calcium in the milk In this type, however, the essential factors are a lack of sufficient calcium in the diet to supply the additional requirements, or insufficient amount of vitamin D to permit of the absorption of a sufficient quantity In other words, there is either a relative or an absolute lack of calcium. It is sometimes urged that the term osteomalacia be reserved for this osteoporosis of pregnant women, but the bone changes and the basic cause of the other forms are so precisely similar that this serves no useful purpose

position in these words, "a definite clinical and pathological entity exists in which the growth of a simple parathyroid adenoma is apparently the cause of progressive decalcification of the skeleton, attended by secondary degenerative changes in the bones, and profound general debility, leading, in the absence of appropriate treatment, to a fatal result."

Clinical Features

The disease may affect either sex, but is more common in women. The majority of cases occur in the third, fourth and fifth decades, but it has been observed as early as fourteen years of age, and as old as sixty No predisposing causes are known.

The most common initial feature is increasing severe pain and tenderness in the bones, especially felt in the lower limbs and back Sometimes at the beginning one bone alone is affected. Usually the pain is associated with general weakness and accompanied by pallor and debility Hypotonia and muscular weakness are common

Often the next event is a fracture from trivial injury The fracture takes a long time to heal but eventually unites, often in a position of deformity In the absence of fracture pain becomes continuous and generalized. The limbs become grossly deformed till the patient is bedridden

Occasionally the development of a tumour—in the maxilla or the mandible—may be the earliest evidence, while occasionally fracture is the earliest sign, or general asthenia may initiate the disease and be far advanced before the bone changes become apparent.

Anorexia and nausea, vomiting and abdominal cramps are common, and occasionally attacks of renal colic with hæmaturia occur, due to the development of a renal calculus

Radiological Features

The radiological appearances consist chiefly of irregular diffuse rarefaction, with absorption of the compact bone and cyst-like degeneration.

In the skull the bones show a well-marked stippling, but the opaque areas are small—pinhead in size, according to Brailsford—which serves to distinguish them from the grosser mottling of Paget's disease

The vertebræ are less dense and show central collapse The upper and lower surfaces are concave and the intervertebral discs are correspondingly swollen.

The pelvis shows coarse striations amongst which large clear cyst-like spaces are usually visible

The femur shows loss of trabeculation. Deformity is common—coxa vara, bowing, and cyst-like spaces may be present at the extremities and in the middle of the shaft. Over the cysts the bone may show a slight fusiform enlargement, but nothing is found comparable to the cortical expansion over a giant-celled tumour. Similar appearances are found in the other long bones, and in the short long bones of the hand and foot

a sufficiency of vitamin D, and exposure to sunlight or artificial heliotherapy are curative.

4. Milkman's Syndrome. Multiple spontaneous idiopathic symmetrical fractures were described by Milkman in 1930 and are now considered not to be a disease entity but a clinical description of a condition revealed by X-ray examination and met with in cases of hypocalcification of the skeleton. It occurs in association with osteomalacia, hunger osteopathies (Looser), cœliac disease, idiopathic steatorrhœa, and even in severe rickets. Looser in 1920 described certain multiple lesions in bones which he regarded as pseudo-fractures: these are now known as Looser's zones.

The syndrome is more common in females and occurs in adult life from 20 to 60 The cause in most cases is osteomalacia The onset is slow and insidious with periods of intermission. The patient suffers from pains usually in the back; pain and tenderness may be complained of before there is any X-ray evidence. Progressive weakness eventually renders the sufferer unable to walk. There are no diagnostic signs other than the X-ray pictures

X-ray Appearances. The bones are less dense than normal. The pseudo-fractures are inclined to be symmetrical and have special and distinctive features. In addition to long bones they are seen at sites seldom if ever affected by fracture except from trauma; e.g rami of pubis and ischium and the scapulæ. In a typical Looser zone the clear band is not a mere crack but is of considerable width, even as much as a centimetre. There is no callus and no sclerosis

The cause of the general porosity of the skeleton which forms the background of the syndrome should be disclosed by the usual investigations

As soon as the osteomalacia responds to treatment provisional callus and sclerosis appear and consolidation of the fracture proceeds satisfactorily.

PARATHYROID OSTEODYSTROPHY

A decade ago there was no proof of the relationship between parathyroid activity and the metabolism of calcium and phosphorus The discovery of the parathyroid hormone placed in our hands the explanation of generalized osteitis fibrosa of von Recklinghausen (Hunter). It has now been shown, in more than eighty-two cases, that in the latter disease there is almost invariably a profound disturbance of calcium metabolism and a parathyroid tumour, the removal of which brings about amelioration in the symptoms of the disease. There has been a tendency in the past few years, therefore, to employ the term von Recklinghausen's disease or generalized fibrocystic disease as synonymous with hyperparathyroidism For reasons which will become apparent there is some evidence that this is not absolutely correct The term parathyroid osteodystrophy, suggested by Struthers, has been employed here. Struthers has very succinctly defined the present-day

The New Bone Formation. In the mass of fibrous tissue, spicules of new bone are formed, first by metaplasia from the connective tissue On the original spicules, osteogenic cells derived from the connective tissue become ranged in successive rows, and secrete successive layers of extracellular mucinous matrix. If this matrix becomes calcified, laminated bone results Often the calcification is poor, and the layer of matrix is then only an osteoid tissue lamella.

The Giant Cell Areas. Macroscopically these vary from large reddish brown masses to minute foci Microscopically they are composed of masses of giant-celled osteoclasts in a matrix of connective tissue. The distribution of the giant-cell areas is of some significance They are arranged in clusters round areas of hæmorrhage, or in relation to unabsorbed bony spicules, and their cytoplasm frequently contains red blood cells and hæmosiderin.

The Cysts. The cysts vary in size, but may be as large as a plum They contain a thin brownish fluid, and are apparently formed by the liquefaction of the connective tissue

The cysts in the giant cells areas, when common or large, seriously weaken the bone and render it specially liable to fracture.

The Changes in the Blood Chemistry

According to Albright, hyperparathyroidism in its active phase is unique in producing a high serum calcium together with a low serum phosphorus. The calcium estimate varies from 11·5 to 23 6 mgm. per 100 c.c., and the phosphorus from 3 6 to 1 0 mgm per 100 c c.

The excretion of calcium and phosphate in the urine is augmented, while the serum phosphatase is high.

The Parathyroid Adenoma. It has been demonstrated by Turnbull that the parathyroid enlargement is not neoplastic, but of the nature of a functional over-activity. Usually one of the four parathyroids is affected, but on several occasions two have been the site of change.

Metastatic Calcium Deposits. Metastatic calcification is common in parathyroid osteodystrophy, the commonest site being the arteries, lungs, kidney and stomach wall. Renal calculi are also prone to occur. The metastatic deposits are of interest in that, unlike the calcification which occurs in diseased tissues, they occur in healthy cells.

The Origin of Parathyroid Osteodystrophy. The relationship between the disturbances of the parathyroid gland and the bone changes is now completely proved by clinical and experimental evidence Removal of the overfunctioning parathyroid leads to a dramatic arrest of the disease; while the prolonged administration of parathormone—the active principle of the gland—leads to skeletal changes, metastatic deformity, and disturbance of the blood chemistry in no wise differing

One further radiological feature is seen in a number of cases—the presence of extra-osseous calcium deposits. These most usually take the form of renal calculi, salivary, biliary or pancreatic calculi.

The Pathology of Parathyroid Osteodystrophy

The Skeletal Changes. In brief, the bone changes consist of progressive absorption and softening of the bones, and deformity, together with a certain measure of new bone replacement — osteogenesis. Two other features call for notice—the occurrence of collections of giant cells (osteoclastomata) and the formation of cysts

The Softening and Absorbing Process. This is the most obvious and striking change, and may proceed until the bone is converted virtually into a fibrous tissue cylinder, which cuts easily but feels gritty from the presence of scattered spicules of newly formed bone. The girth of the affected bone is usually increased, but the periosteum is normal Deformity is usually present due to the effect of gravity, weight-bearing, or muscular action on the softened bone When the bone is sectioned vascular granulation tissue is seen to occupy it from end to end, and the cortex is thin and spongy in texture The cancellous tissue of the ends may be practically replaced by the connective tissue

Fig 75—Osteitis Fibrosa Cystica of the Femur

Histologically the significant change is the widespread degree of osteoclastic activity The Haversian canals are slowly enlarged into big irregular spaces lined by a zone of osteoclasts lying in lacunæ in close apposition to the bone they are eroding. The spaces are filled with vascular tissue, with many capillaries, and endothelial cells, and as the bone is destroyed spindle-shaped fibroblasts appear. Adjacent spaces eventually come to communicate with each other, as the bone between them is removed, and as the amount of fibrous tissue increases pari passu with the bone removed, the capillaries are slowly obliterated.

from those occurring in the disease. The bone effects, then, are due to the circulation of an excessive amount of parathormone.

The Action of the Parathormone is to disturb the calcium-phosphorus ratio in the serum It stimulates the excretion of phosphate so that the serum phosphate falls and the serum calcium rises, as calcium phosphate is mobilized from the bones. The excess of calcium is excreted along with the phosphate in the urine, more calcium phosphate is dissolved from the bones, and so a drain on the calcium phosphate of the skeleton is established. It is probable that large doses of parathormone also act directly on the bone as well as through the phosphate mechanism. The direct effect is most likely to stimulate the osteoclastic activity.

The Cause of the Hyperparathyroidism is not known. Arguing from analogy with hyperthyroidism, it is likely that the stimuli producing parathyroid hyperfunction can be derived from many and varied sources.

The Nature of the Bone Changes. Jaffe and Bodansky were the first to reproduce experimentally the features of parathyroid osteodystrophy by parathormone injections in rabbits. Taylor in this country, however, has afforded us the most illuminating account of the skeletal changes It appears that in the stage of decalcification, the rapid removal of calcium is attended by marrow hæmorrhages, probably as a result of damage to the capillary endothelium from the local concentration of calcium in the capillary vessels of the bone. It is only after the occurrence of the hæmorrhage that the connective tissue proliferation, and the giant cell increase are found, and Taylor suggests that they are both reactions to the damage caused by the marrow hæmorrhages.

The Formation of Urinary Calculi is due to the increased excretion of calcium and phosphate in the urine The calculi may be formed in the pelvis, or in the collecting tubules, actually in the parenchyma They lead to sclerotic changes in the kidney. Albright points out that if the disease is of short duration and the amount of calcium in the diet is high, the bone changes may be later in appearing, but the formation of urinary calculi is an early feature In long-standing disease, with low dietetic calcium, the reverse obtains

The Diagnosis of Parathyroid Osteodystrophy depends on the demonstration of the hypercalcæmia and hypophosphæmia in association with the characteristic bone changes. It must not be forgotten, however, that in some cases the initial feature to attract attention is a lesion other than the skeletal one—i e the occurrence of urinary calculi. In multiple and recurrent urolithiasis, therefore, it is desirable to investigate the plasma content of calcium and phosphate

There is a second form of parathyroid enlargement which occurs in chronic renal disease and is due to persistent raised phosphates of the blood with a concomitant depression of the blood calcium. This low

sclerotics are usually blue, and the individual is dwarfed. The blood chemistry is normal, and the radiological picture characteristic.

Multiple Myeloma. The radiological appearance of multiple myeloma may simulate closely the appearance of parathyroid osteodystrophy, especially in the collapse of the vertebræ, the occurrence of punctate areas of diminished density in the skull and long bones, and fine mottling of the pelvic bones The blood calcium-phosphorus ratio is as a rule normal, while an abnormal protein—the Bence-Jones proteose—may appear in the urine Raised blood protein frequently results in raised total blood calcium but the diffusible fraction remains normal Biopsy may be demanded

Prognosis after Operation

After parathyroidectomy, the prognosis is good. Hunter finds in the majority of cases that the bone pains are immediately abolished There is usually a marked gain in weight, and crippled individuals have even been able to dispense with sticks and crutches.

Some authorities also claim that removal of the parathyroid swelling is followed after some months by increased density of the bone shadow on radiological examination.

Treatment

In the presence of generalized osteitis fibrosa, the neck should be explored for parathyroid tumour, even in the absence of a palpable swelling

A wide exposure should be aimed at, for Walton points out that it may be necessary to continue the search behind the trachea, or down into the mediastinum

Normally, there are at least two parathyroid bodies on each side, and in some individuals there may be three or four. The superior bodies, though variable in their lateral and vertical position, are usually situated between the pretracheal fascia and the posterior part of the capsule of the thyroid gland, and may be found around the veins at the root of the neck and in the thymic region

The inferior bodies, although usually described as also lying between the fascia and the thyroid capsule, may lie below the inferior thyroid artery, and beneath the pretracheal fascia, in this case they are only visible from the posterior surface or after division of the fascia. When misplaced they should be sought for in the region of the œsophagus and in the superior mediastinum

The enlarged parathyroid has a characteristic yellowish-brown appearance which renders it distinctive even to the naked eye.

After operation, a diet rich in calcium should be arranged, while ultra-violet radiation is a useful procedure Convalescence is frequently associated with tetany, but this may be controlled by administration of calcium gluconate, irradiated ergosterol and parathormone.

POINTS IN DIFFERENTIAL DIAGNOSIS BETWEEN HYPERPARATHYROIDISM AND OTHER BONE DISEASES (*after* ALBRIGHT)

Disease	Differential Points as Regards			Serum		Plasma Phosphatase	Miscellaneous
	Symptoms	X-ray Appearance	Biopsy	Calcium	Phosphorus		
Hyperparathyroidism with bone involvement	Bone pain, deformity, fracture, tumour, polyuria, those related to stones	Increased radiability, generalized deformity, cysts, tumours, fractures, stones	Rarefied bone, fibrosis of marrow, osteoclasts + + +, osteoid tissue only slightly increased, osteoblasts + + +	High	Low	High	All age groups
"Senile" osteoporosis	No bone tumour, polyuria or stones	No cysts, tumours or stones	No fibrosis of marrow, osteoclasts normal, osteoid tissue normal or decreased, osteoblasts decreased	Normal	Normal or low	Normal	Old age
Paget's disease	Bones enlarged, no polyuria, stones infrequent	Polyostotic but not generalized, bones hypertrophied, e g thickened skull	May occasionally be difficult or impossible to differentiate	Normal or slightly high	Normal or slightly high	Very high	Runs in families, predilection for weight-bearing bones, seldom seen under 40, arteriosclerosis + + +
Osteomalacia	No bone tumour, polyuria, or stones.	No tumours or stones, bending deformities + + +.	Osteoid tissue + + +, osteoblasts + +, osteoclasts decreased	Normal or low	Low	High	Practically absent in this country except with fatty diarrhœa
"Solitary" cysts	Confined to cysts	No generalized changes, cysts may be multiple	Cannot differentiate if taken from lesion	Normal.	Normal.	Normal	
Solitary benign giant-cell tumour	Confined to tumour	No generalized changes	Cannot differentiate if taken from lesion.	Normal	Normal	Normal	
Osteogenesis imperfecta	Fractures + + +, no bone tumour, polyuria or stones	Cysts rare, no tumours or stones	No fibrosis of marrow, osteoclasts normal	Normal	Normal.	Normal or very slightly elevated.	Hereditary, often coupled with blue sclerœ and deafness, improves after cessation of growth
Multiple myeloma	Can cause same bone symptoms and renal symptoms	Can be almost indistinguishable.	Tumour tissue	Normal or high.	Normal or high.	Normal	Bence-Jones proteinuria

activity, and eventually become so weak that spontaneous fractures occur. Apart from definite fractures, deformities may arise from weight-bearing or from muscular action. Thus kyphosis or scoliosis, and pelvic asymmetry may be present. Deformity is less common in the long bones.

The cause of the increased excretion of calcium is not known, but Hertz has shown that the calcium excretion and skeletal rarefaction are greater after the administration to animals of the thyrotropic factor of pituitary secretion than after equal amounts of parathormone, and it may be that the effects on the calcium metabolism are due to simultaneous stimulation of the parathyroid glands by this pituitary hormone.

In addition to the above, increased protein metabolism may result in a deficiency of the connective tissue elements of the bone. This occurs only when the limit of body tolerance is exceeded. A milder degree of hyperthyroidism through stimulation of the eosinophilic cells of the pituitary will result in an increased skeletal growth.

THE PITUITARY DISTURBANCES

The pathogenesis of the skeletal changes in pituitary disease is closely connected with the function of the cells composing the anterior lobe of the pituitary body Normally two varieties of cell can be distinguished In one—the chromaphobe cells—the cytoplasm is agranular, while the other variety—the chromaphil—contains large coarse granules. The granular chromaphil cells are further differentiated by the staining reactions of the granules. Thus those that take up the acid stains are known as oxyphil or eosinophil cells ; the term basophil is applied to those with an affinity for the basic dyes

Modern experimental work has assigned specific functions to the different cells Thus the acidophil cell is regarded as concerned with skeletal growth , the basophil cells with the development and maintenance of the sexual and reproductive apparatus

Skeletal disturbances may be produced as a result of either a diminution or an excess of the growth factor of the eosinophil cells.

Excessive secretion leads to—

(*a*) **Giantism**, when the process occurs before the epiphyses have united with the shafts of the long bones

(*b*) **Acromegaly**, when it occurs later, in adult life

Diminution in secretion leads to—

Dwarfism.

The Pituitary Dwarfisms

The term dwarf is applied to an individual whose physical dimensions are considerably beneath those peculiar to his race It is often

Orthopædic treatment is directed merely towards the adequate protection of the softened bones from all deforming stresses and strains. Urological treatment is directed towards removal of calculi and maintenance of renal function

After the disease has been arrested and recalcification of bone occurs, the established deformity may be corrected by the usual means, e.g. osteotomy.

If for any reason a cervical exploration is contra-indicated, treatment should consist of the prevention of deformity, the exhibition of irradiated ergosterol to increase the deposition of bone, and such general measures as are rendered necessary by the patient's wasted condition.

Thyrotoxic Osteoporosis.

In thyrotoxicosis there is a marked increase in the general metabolism. Its effect on bone and its structure is less well known and understood. In hyperthyroidism the serum calcium and phosphorus are normal, but there is exaggerated excretion, sometimes to as much as eight times the normal. In association with this, the bones undergo very marked rarefaction, through the agency of increased osteoclastic

FIG 76.—Thyrotoxic Osteoporosis.

The leg bones in a case of hyperthyroidism showing extreme porosis with pathological fracture

The Skeletal Changes

The growth of all parts of the skeleton is delayed or arrested. The epiphyses remain ununited for a prolonged period, and the metaphysis terminates in a line of dense bone The histological change is an absence of division of the cartilage cells in enchondral bone, and absence of division of the primitive connective tissue cells in the membrane bones.

Etiology

The usual cause of hypopituitarism is a tumour or cyst (suprasellar cyst) compressing and destroying the gland In some cases where the dwarfing is already present at birth, there is said to be an aplasia of the gland, or a failure of differentiation of the eosinophil cells

THE HYPERPITUITARY SYNDROMES

Giantism

This condition begins before the epiphyses have been fused with the shaft, and the growth of the skeleton is speeded up, and becomes excessive There is also thickening of the jaw The mental development is subnormal, and the body strength often surprisingly slight.

In the majority of cases some of the features of acromegaly develop later.

Pathology

The bones of the skeleton show increased thickness and length; the membrane bones are also hypertrophied.

Histological Features

At the epiphyseal cartilage growth of the cartilage cells is active, but the orderly palisade arrangement is lost, the cells being arranged in irregular groups. The amount of matrix is increased. The number of vascular buds and the number of advancing osteogenic mesenchymal cells is increased, so that osteogenic activity is maximal

In the sub-periosteal area, as in the membrane bones, the osteogenic cells show increased proliferation, and there is rapid new bone formation The layers of bone may be more irregular as well as more numerous than normal

Acromegaly.

The manifestations of acromegaly appear after skeletal growth has normally ceased, and the disease is characterized by an unevenly distributed exaggeration of ossification Lawford Knaggs made a comprehensive study of the disease and attributes the irregular distribution of the process to the effects of local pressure and traction.

extremely difficult to assign the responsibility for dwarfism to any particular organ, but in the case of the pituitary types there are often other features.

There are two main types:

(1) *Fröhlich's adiposo-genital type* in which skeletal stunting is

FIG 77.—Achondroplasia and Acromegaly.
These two lads were great friends

associated with general obesity, genital hypoplasia, and often stupidity or idiocy.

(2) *The "Lorain" type* in which there is no mental or other change, but only lack of skeletal growth. Such individuals remain, it has been said, "attractive and graceful children."

Etiology

Acromegaly is due to the circulation of an excessive amount of the growth factor of the eosinophil cells of the anterior lobe of the pituitary. There is either a hyperplasia of these cells, or else a tumour —eosinophil adenoma—composed of these cells.

Fig. 78.—Acromegaly, showing large hands, and big face with thick lips.

Pathology

The Skeletal Changes. There are deposits of porous bone in the alveolar margins of the jaws, leading to great elongation of the face and projection of the chin. The ramus of the jaw is narrow and elongated. The malar bones are also the site of a similar deposition, and the vault of the skull may be thickened. The skull change begins, or is most marked, in the frontal bone, and the deposits occasionally take the form of osteomata growing from the inner table of the skull The foramen magnum is usually displaced forwards, and the pituitary fossa enlarged from the presence of the mass, or adenoma, of hyperplastic eosinophil cells

The thorax is massive, due to the increased length of the ribs, which is partly the result of the exaggerated bone growth and partly the result of the hypertrophy of the lungs

In the long bones the most obvious changes are found towards the extremities, which are more massive than normal and less well

The prominent features of cretinism are:

1. Signs of mental deficiency.
2. Anomalies in genital development.
3. Disturbance of growth.

The last is the most obvious and constant evidence. The cretin is a dwarf. The long bones are short, while the ossification of the skull is delayed, and the fontanelle closes late—as late, sometimes, as twenty years The root of the nose is depressed, from defective growth of the base of the skull. The vault of the skull may appear large in comparison with the body. Apart from these features the growth of the cretin is fairly proportionate

The Nature of the Skeletal Changes

The principal skeletal changes are the late appearance of the epiphyses and of bones whose ossific nuclei develop after birth, e g the carpal and the tarsal bones, and the delayed union of the epiphyses. Indeed the epiphyses may remain separate from the shaft well into adult life. Despite this, growth is largely in abeyance, ultimately fusion takes place

Radiological Appearances

The distinctive interference with the ossification process is, of course, apparent In addition, the shafts of the long bones appear short, with a thick cortex, but their calibre is diminished. Towards the extremities of the bones the size approximates more nearly to normal The epiphyses are not only late in appearing, but small and often irregular in ossification so that they appear fragmented, and show a superficial resemblance to osteochondritis

There may be delay or arrest in fusion between the two halves of the neural arch or the neuro-central synchondrosis, while disturbance of normal ossification of the vertebral bodies is common

The Pathology of the Bone Changes

The nature of the bone error is simple. There is an arrest of both enchondral and sub-periosteal new bone formation. This is due, not to lack of calcium, for this is often in excess in the zone of calcification, but to arrest of the proliferation of the cartilage, and to arrest of osteoblastic activity.

The other features, the genital hypoplasia and the idiocy, do not concern us here.

Treatment

The administration of thyroid extract is curative if treatment is begun in infancy It is interesting to note that since epiphyseal fusion is delayed, the administration of thyroid may produce growth in stature even in the adult

Etiology

Leriche attributed the condition to hyperæmia induced by a local autonomic axon-reflex initiated by the injury. This is, of course, an invariable accompaniment of injury—indeed, it is the factor that initiates healing Why it becomes prolonged, and why it is associated with so much pain, is not clear The other theory—that the condition results from the liberation of histamine from injured tissues—is also concerned with the explanation of the hyperæmia, and not with the other features of the disease Watson-Jones has suggested it is due to a disuse atrophy Middleton and Bruce draw attention to the fact that after sympathetic denervation in these cases there is immediate relief of pain, and recovery of movement, while the osteoporosis is left unaffected They suggest, therefore, that the injury sets up a persistent reflex consisting, on the one hand, of a painful sensation caused by afferent fibres running in the sympathetic system, and, on the other hand, of a reflex efferent impulse causing vasodilation and consequent osteoporosis. Probably a vicious circle is inaugurated, the local hyperæmia keeping up the pain and the pain the hyperæmia. The associated attenuation of the trabeculæ is due to disuse of the affected limb

Prognosis

Mild cases may clear up with little or no residual disturbance of function, but the recovery is protracted, and this is the less usual result More often there is permanent limitation of movement at the affected joint, and in many cases the former bone density is never renewed. In some cases there is permanent ankylosis. Within these limits the outlook varies considerably with the site of the osteodystrophy. In the foot, complete recovery may be expected in most cases In a few, there is left a rigid flat foot or a form of spastic flat foot In the type following Colles's fracture, permanent limitation of movement is the rule, while the mild cases following sprains are often followed by complete recovery At the knee and the shoulder some permanent stiffness is frequent

Treatment

1. Simple Conservative Measures. The usual physiotherapeutic measures are uncertain in their effects. Diathermy or radiant heat sometimes leads to improvement in mild cases Massage and forced movement are difficult to apply because of the pain, and are of no service in improving the condition Complete rest, in a suitable splint or plaster of Paris, affords most relief Deep X-ray therapy is said by some workers to be helpful.

2. Sympathetic Denervation. Operations on the sympathetic system for the relief of post-traumatic osteodystrophy were introduced by Leriche and his associates They recommended a peri-arterial sympathectomy on the main vessel of the affected limb. Middleton

The stiffness is often so great that there is complete loss of function in the part It is partly the result of protective muscle-spasm.

The vasomotor phenomena vary. At first the affected part is warmer than its fellow, but soon becomes cold. Cyanosis is frequent and there is usually œdema The skin is glossy, and covered in the early stages by diffuse, sour-smelling perspiration.

Pathology

The sequence of the pathological changes can best be followed by serial radiography.

In the first phase, the affected bones show irregular areas of



Fig 80—Changes in Elbow Region in Same Case as Fig. 79.

rarefaction, with some diminution in their general density. This stippled osteoporosis is, at the beginning, confined to the spongiosa, largely because this is the site where the mineral content of the bone is most labile Subsequently, however, progressive decalcification takes place and spreads to the cortex, so that the whole bone acquires a glassy appearance These stages have been named by Middleton and Bruce the stages of stippled rarefaction, and of cortico-lamellar attenuation. For a long period the joint surfaces remain intact but ultimately, in the polyarticular areas, the individual small bones become fused In the latest stages, when the acute atrophy has subsided, calcium may be deposited in the capsule of the joint and lead to permanent ankylosis.

bone are not laid down in the actual fibres of the muscle, but in the connective tissue between the fibres, which later disappear as a result of pressure atrophy. It is this fact that has led Greig to suggest the name "fibrositis ossificans progressiva."

Mau has given an excellent account of the pathology He states that in the earliest stages the interfibrillary connective tissue proliferates and gives rise to a network of embryonic mesodermal tissue, which is particularly abundant around the vessels. In this primitive type of connective tissue lime salts are deposited, and eventually bone elaborated by the connective tissue cells. Occasionally, instead of bone, the connective tissue proliferation leads to the formation of a mass of cartilage.

As a general rule, when bone formation is about to commence, the cells of the proliferated mesenchymal network become small, with scanty cytoplasm and dark staining nuclei.

These changes are not present at the same stage in all the muscles. The muscles of the back (erector spinæ, latissimus dorsi) and of the neck are the first to show change, but ultimately the disease spreads to involve the major part of the muscular system.

Clinical Features

The disease begins in infancy and early childhood and progresses in a series of acute exacerbations followed by remissions of varying duration. During the acute attacks there may be slight evening rise of temperature, but this is by no means constant.

The initial feature is the occurrence of a swelling, at first soft and fluctuant, in relation to one or more of the muscles, particularly of the back. The swelling may be tender at first, and the overlying skin a bluish-red colour. Occasionally the swelling disappears completely, more usually it shrinks, leaving a hard but small nodule of bone in its wake During subsequent attacks, more and more muscles may be implicated, and the deposits in the muscles originally involved grow larger. On occasion the new bone may actually induce a pressure atrophy of the skin, with the development of an ulcer which discharges white amorphous calcium. As the disease progresses, there is interference with the function of the affected muscles, and eventually the individual is confined to bed When the rib muscles are affected, breathing is carried on by the diaphragm alone, but death eventually ensues from respiratory complications.

In a large number of the reported cases, some congenital abnormality of the fingers or toes has been present, usually microdactyly.

Etiology

There is some evidence that hereditary transmission through the females to the males—as in hæmophilia and certain of the muscular dystrophies—may play some part in myositis ossificans progressiva.

and Bruce found that this afforded only temporary relief, and it would appear that operation on the sympathetic ganglia is more rational A thoracic ganglionectomy in the case of the upper limb, and a lumbar ganglionectomy in the case of the lower limb, is carried out. Since neither of these operations is easy and since, in any case, the milder cases show a tendency towards spontaneous and progressive amelioration, sympathetic operations should be considered only in extreme cases

The effect of sympathectomy is evidently to break the afferent path of the reflex and, with the disappearance of pain and the return of function, the hyperæmia settles down.

3. The Use of Drugs. The use of acetylcholine by ionization has given promising results. Acting as a para-sympathetic stimulant its effects are therefore similar to a temporary sympathetic denervation. Tetraethylammonium bromide has recently been used as a sympathetic depressant.

4. Orthopædic Treatment. As the acute phase subsides, it is often necessary to augment the range of movement at the affected joint by judicious manipulation.

MYOSITIS OSSIFICANS PROGRESSIVA

This rare disease is the most striking of all varieties of heterotopic ossification It is characterized by the progressive development of bone in the muscles, tendons, ligaments and fasciæ of the body, and usually begins in childhood during the growth period.

The disease is infrequent in this country, but appears to have a predilection for the Anglo-Saxon races, and it is by no means uncommon in France Males are more apt to be affected than females, in the ratio of 4 1.

Pathology

The striking feature of the disease is the replacement of the muscles, tendons and aponeuroses by masses of bone, mostly attached to the skeletal framework In some cases masses of bone also lie free in the body of the muscle. Most of the skeletal musculature may be involved, but the muscles of facial expression, the diaphragm, the laryngeal muscles, and the tongue escape. Joint capsules may be similarly converted into bone

The bones of the skeleton may show in association some rarefaction

The new bone formed may be densely hard, or so soft as to cut easily with the knife If the masses of bone are examined the denser bone is found towards the centre, and the softer, more spongy bone, towards the periphery.

The Histopathology

A study of the minute structure of the lesions of progressive myositis ossificans reveals the important fact that the deposits of new

Compression of the cranial nerves in the foramina appears if and when the lumen of the foramen is encroached upon with auditory and visual disturbances Spinal cord compressions producing paraplegia have also been reported in a number of instances.

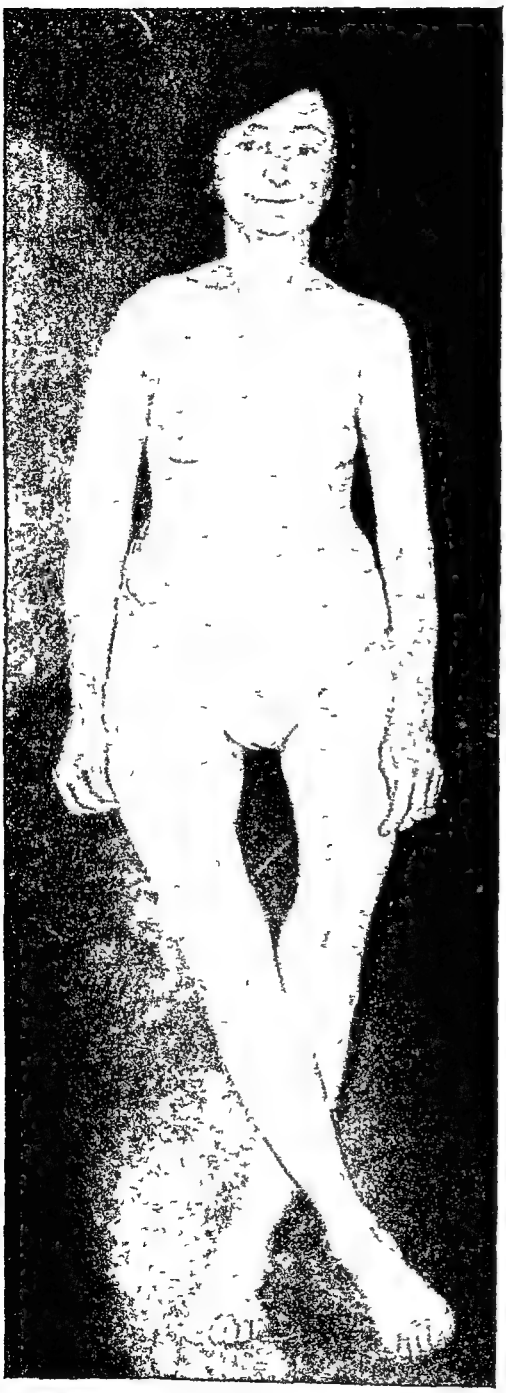

Fig 81 —Paget's Disease of the Skeleton.

Spontaneous fractures from trivial violence are wont to occur, especially in the femur and the tibia.

There is one other risk to which sufferers from Paget's disease are liable—the development of osteogenic sarcoma in one of the affected bones

Varieties of Osteitis Deformans

(1) *Monostotic Form* One bone is involved and is most commonly the tibia, but in 75 per cent of cases this will progress to give the generalized form.

(2) *Polyostotic Form* Often beginning unilaterally it may persist as a one-sided affection.

(3) *Facial Type.* In certain of the recorded cases enlargement of the jaws has been a feature. Either the upper or lower jaw, or both, in whole or in part, may be involved.

Radiological Features

Roberts and Cohen found that the bones most commonly involved, in order of frequency, were—skull, tibia, femur, pelvis, then less frequently, radius, hand, foot, humerus, and ulna

Changes in Skull. The earliest change is a blurring of its surface outline, together with some flattening (from softening) Later progressive thickening takes place in the outer table, but the new bone is not regular and appears as irregular islands of dense bone, giving the calvarium a mottled or

There is occasionally a rheumatic family history as well, and Mau attaches some importance to the possibility of a subacute rheumatic myositis as a precursor of the osseous deposits

The trauma of birth has been blamed, but as Mau points out, injury probably does little more than determine the site of primary change. Of more significance is the frequent history of antecedent infection—chicken pox, scarlet fever, cervical adenitis. The exact cause, however, is not known, but it must act through the production of phosphatase in the cells of the proliferated mesodermal network. Mau suggests that in addition to this developmental factor there is a superadded, but not understood, disturbance of the calcium metabolism

Treatment

No treatment is known to stay the course of the disease. Various drugs, mineral and endocrine, have been employed without effect, and X-rays and heliotherapy are apparently useless

OSTEITIS DEFORMANS

Osteitis deformans was described in some detail by Sir James Paget in 1876, and is often known as Paget's disease. It is certain, however, that examples of the disease were known previous to this, and the name of the disease had already been proposed by Czerny in 1873.

The disease has a fairly universal distribution in the human race, and has also been identified beyond doubt in horses and monkeys

Clinical Aspects

The disease usually begins between the ages of thirty-six and fifty and Roberts and Cohen point out that in those first seen at later ages there is usually a history of some years' standing. The sex incidence is practically equal. It is often unilateral to begin with and the onset of the disease is insidious and its progress slow. Pain in the lower limbs, thigh or hips is often the initial feature and is present in 30 per cent. of patients with this disease It may be aggravated by exercise, or be more pronounced at night. Muscular cramp, or tenderness on palpation of the muscle may be complained of.

Sometimes the onset of deformity first attracts the patient's notice —gradual bowing of the legs or the development of a spinal curvature are common in this respect. Gradual increase in the circumference of the head may be a notable feature; the patient's attention may be directed to it by the frequent necessity for larger sizes in headwear.

Later, the gait becomes ungainly, partly as a result of deformity, partly because of the muscular weakness Arthritis ultimately supervenes, particularly in the weight-bearing joints, and still further disturbs the gait

Other symptoms are the result of the primary effects. Thus headache and vertigo may result from the cranial thickening.

of new bone is a striking feature. As Girdlestone says, osteogenesis does not occur except at a distance in time or in space from an active tuberculous lesion.

To summarize these important phenomena, there is a diminution in blood supply; degeneration of the marrow, invasion by bacilli; absorption of the lamellæ; central caseation, and a failure to deposit sub-periosteal bone

The centre of the body being caseous, the superimposed weight of the vertebral column is now borne by the fragile shell of compact bone, which sooner or later collapses An angular deformity—kyphus, gibbus, or hunchback—now results, for the neural arch is swung upwards on the fulcrum of the articular processes when the short arm lever of the vertebral system, formed by the diseased body, descends (collapses). As a result of the collapse the tips of the adjacent spines are widely separated. Such deformity is most marked in thoracic caries, since owing to the normal dorsal curvature the weight is thrown chiefly on to the anterior part of the vertebral body, which therefore completely collapses. In the cervical region collapse rarely occurs because the weight is transmitted chiefly through the articular processes The deformity, therefore, is a comparatively slight one. In the lumbar region also the deformity is small, since, owing to the normal lumbar lordosis, the body-weight is borne chiefly by the posterior parts of the vertebral body, and collapse is incomplete.

Associated Changes

Abscess Formation. When the body of the vertebra collapses there is expressed from it a collection of tuberculous detritus, consisting of granulation tissue, caseous matter, disintegrated bone lamellæ and bone marrow. This collection is known as a "cold" abscess, and is the commonest complication of Pott's disease; it is said to occur in 20 per cent of cases At first, the debris collects under the anterior longitudinal ligament on the front of the vertebral bodies: there it

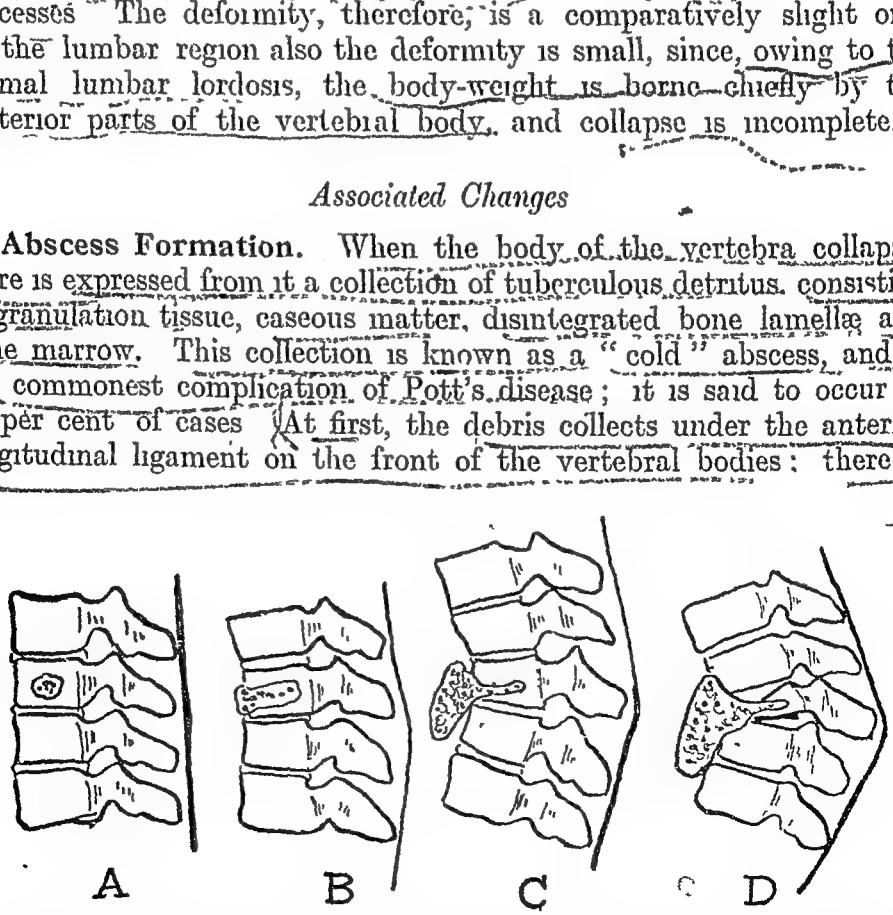

FIG 118—The Growth of a Tuberculous Focus in the Body of a Vertebra
Showing the collapse of the body and the production of the gibbus

times apparent at an early stage in an X-ray as an increase in density of the vertebral body.

(2) *Metaphysial Tuberculosis* (intervertebral articular type) where the disease arises near the epiphyses of the body and, therefore, close to the intervertebral disc. The infection in this, the commonest type of disease, is chiefly in the body of the epiphysis. The disc is infected at an early stage and is rapidly narrowed.

(3) *The Anterior or Periosteal variety*, where the primary focus is deep to the periosteum on the front of the body, beneath the anterior longitudinal ligament

(4) *Appendiceal Tuberculosis*. Occasionally the transverse process is affected, and, more rarely, the vertebral arch

(5) A true tuberculous arthritis as found in the limbs occurs in the occipito-atlanto-axial group of joints

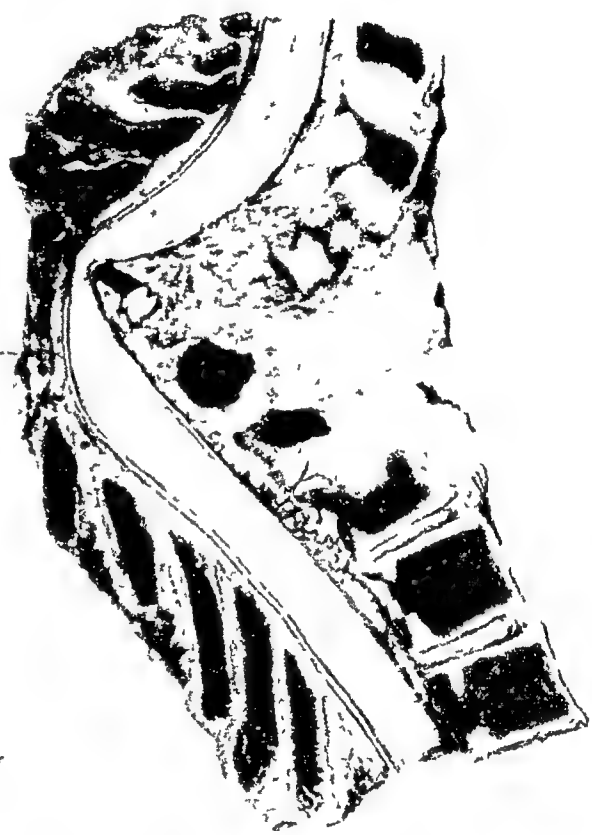

FIG. 117.—Tuberculosis of the Spine producing Angulation

The Sequence of Pathology. The disease begins as an infection of a single vertebra and each of the component tissues is ultimately involved The primary error is a nutritional disturbance of the marrow, following a tuberculous endarteritis; the marrow is converted into pale myxomatous tissue which provides the ideal pabulum for the growth of the tubercle bacillus In the devitalized tissue the bacillus settles down, and a typical tuberculous follicle develops until it is visible to the naked eye as a small yellow-grey nodule As this nodule grows, the lamellæ over a wide area are progressively rarefied and eventually disappear. Since the strength of the vertebra depends on the internal structure of its body, it follows that with the disorganization of its lamellar structure its strength is seriously compromised, especially as there is practically never any subperiosteal new bone formation save in the later stages Indeed, in the vertebral column, tuberculosis seems to exercise an inhibitory effect on new bone formation, in contrast to the long bone in which the deposit

(B.) Paraplegia of late onset. < Type one Type two

In this type the outstanding characteristics are the late and gradual onset, the incompleteness of the paralysis and the high percentage of permanency in comparison to the first group.

The onset is variable from a few months to many years after the apparent quiescence of the disease. Muscular spasticity is usually the first sign Sensory changes may be lacking throughout but there is usually widespread but incomplete anæsthesia. Pain is rarely felt, but there may be a little backache or irregular pains down the limbs Even at its height late-onset paresis is typically incomplete and the legs are seldom devoid of slight voluntary power

Type 1. Unsound healing or recrudescence of the disease. In this group the paralysis follows usually soon after the apparent cure, perhaps a year or so after the patient has been allowed up The healing has been unsound and the weakened spine has given way before the pressure of body weight and the strain of movement The risk of this complication is run by every patient who is allowed up after an inadequate period of bed rest, etc, or with inadequate protection, and, according to Girdlestone, is an argument in favour of posterior fusion where there is any doubt about the stability of the spine.

Type 2. Paralysis occurring at a late stage and associated with great deformity. This group occurs at a much later period and is more insidious in its onset The patient may lead a normal life for many years after the treatment of his disease, and nothing is noticed apart possibly from a slowly increasing deformity of the spine. Then after a long interval—which may be as long as forty years—the patient complains of a little weakness of the lower limbs or inco-ordination in walking which marks the onset of paraplegia In this type of case the cause is comparable to the paraplegia sometimes seen in scoliosis where the symptoms are apparently due to the prolonged friction and dragging of the cord against its irregular and angled bed. It may also be stretched by movements and by the fact that the cord is fixed by its nerve roots—so the friction of movement is aggravated The cord is almost invariably shrunken longitudinally and so comes to lie hard up against the anterior wall of the spinal canal and the narrow and deformed spinal canal makes it peculiarly susceptible to compression There is usually an absence of any clinical signs of tuberculosis or radiographic signs of compression. Queckenstedt's test is always negative because the cord lies hard against the floor of the spinal canal and there is passage for the cerebro-spinal fluid posteriorly.

Prognosis

In Group A, though the paralysis is often complete, if the patient is seen in good time the paralysis is usually curable if the tuberculosis can be arrested. None the less, it has to be realized that there are cases where this is not so and the paralysis may be permanent though the

A relatively intact disc may be found in the middle of the diseased area pressing on the cord.

(2) *Causes in the Membranes.* When the meninges are at fault, the cause is usually a pachymeningitis, or more rarely a leptomeningitis; these result in thickening of the membranes and in obliteration of the blood and lymph vessels Pachymeningitis was previously held to be a very common cause of paraplegia but Butler and Seddon found little evidence of this in their series.

(3) *Causes in the cord.* The nervous tissue of the cord is practically never infected with tuberculosis but an early form of paralysis may be due to circulatory change in the cord in the neighbourhood of the lesion without gross compression. Girdlestone says this is associated with the early and most active stage of the disease when there is vascular engorgement in the epidural space, infiltration, lymphatic obstruction, and as a rule some mild circumferential compression of the theca. The spinal cord may be flattened from pressure or œdematous as a result of vascular stasis. In the earlier stages the paresis is transient and as a rule relieved quickly by immobilization.

Girdlestone describes two main groups of paralysis which are distinguished by their onset in relation to the duration of the disease.

A. Early: associated with primary activity.

B. Late: after apparent arrest of the disease.

(A.) Paraplegia of early onset.

This type is found in early active Pott's disease. Usually the Pott's disease has been recognized before the paresis, although the reverse may be the case, except in children in whom the disease is usually discovered earlier. The progress is usually rapid, often being accelerated by lack of treatment The first symptoms are muscular weakness, inco-ordination and spasticity. Pain in the back or referred to the involved nerve roots is common. The awkwardness of gait and spasticity proceed until walking becomes impossible. There is first a paralysis in extension, with increasingly frequent attacks of general flexor spasm, and it eventually becomes a paralysis in flexion, indicating a complete loss of conductivity of the pyramidal tracts. In exceptional cases the compression is sudden enough to cause an initial flaccid paralysis from spinal shock Where the paralysis is in extension it is incomplete, pyramidal or possibly vestibulo-spinal tracts having partially escaped compression. Seddon says this early type may be due to a swelling which is almost entirely fluid, tuberculous pus, or mainly inflammatory tissue, a granuloma, or a caseating mass. He also points out two uncommon types—one where there is pressure from a circumscribed, perhaps encapsulated, tuberculous focus arising from the back of the vertebral body. It may proceed thereafter to destruction of the vertebral bodies. The other type is where there is posterior spinal disease affecting the neural arch which may be recognized radiographically.

tuberculous disease becomes cured. The prognosis is better in the young than the old, while the longer the paralysis has existed the poorer the outlook. Gradual onset is less harmful than a sudden crush. The more complete the sensory loss and the deeper the motor paralysis, the worse the outlook. Loss of sphincteric control indicates a greater pressure and for that reason a less favourable prognosis.

Treatment

Pott's paralysis is becoming rarer because of earlier diagnosis and more prompt and effective initial treatment. The method of treatment—conservative or operative—will depend on the type of case and whether occurring early or late in the disease.

The Decision between Conservative and Operative Treatment.

In the earlier (A) type of paralysis a natural recovery with conservative treatment may be expected when the motor paralysis is incomplete, sensation is intact, and some control of the sphincter retained, and particularly when there is no radiological evidence of an abscess under tension. But with a motor paralysis in extension, with a paravertebral tension abscess, and with increasing spasticity, it is possible that conservative treatment may be effective, but as there is a considerable chance of its failure it is wiser to relieve the pressure by operation.

In the later (B) type of paraplegia two distinct groups are to be considered—those with compression of the spinal cord and those with long continued vertebral deformity but little compression. An analysis of the cause is the first step. Stereoscopic lateral radiograms are taken and from a clear view of the boundaries of the spinal canal evidence of recrudescence of the disease is looked for as well as any pressure on the cord from angulation, a ridge of bone, a prominent sequestrum, or a tense abscess. A tense abscess is spherical on one or both sides of the spine. The latter is the so-called dumb-bell abscess. Lumbar puncture, examination of the spinal fluid and Queckenstedt's test give further help. An early analysis of each case is undertaken in order to discern as clearly as possible the cause of the paralysis, followed by a careful assessment of the value of operation, whether decompression or synostosis. Synostosis diminishes the accumulation of debris by eliminating the grinding movement of respiration and in so doing favours the arrest of the disease. It is believed that the paraplegias due to recrudescence of the disease are more amenable to treatment and therefore have a better prognosis than those associated with the late mechanical effects of severe angulation.

Dott proposes four principal indications for operation:

(1) A rapidly progressive paresis which is advancing daily and is nearing total paralysis. Procrastination should not be risked. An immediate operation is carried out.

(2) The case in which paresis advances over weeks or months in spite of effective fixation and postural correction. The paralysis should not be allowed to advance too far but there is not the same element of urgency.

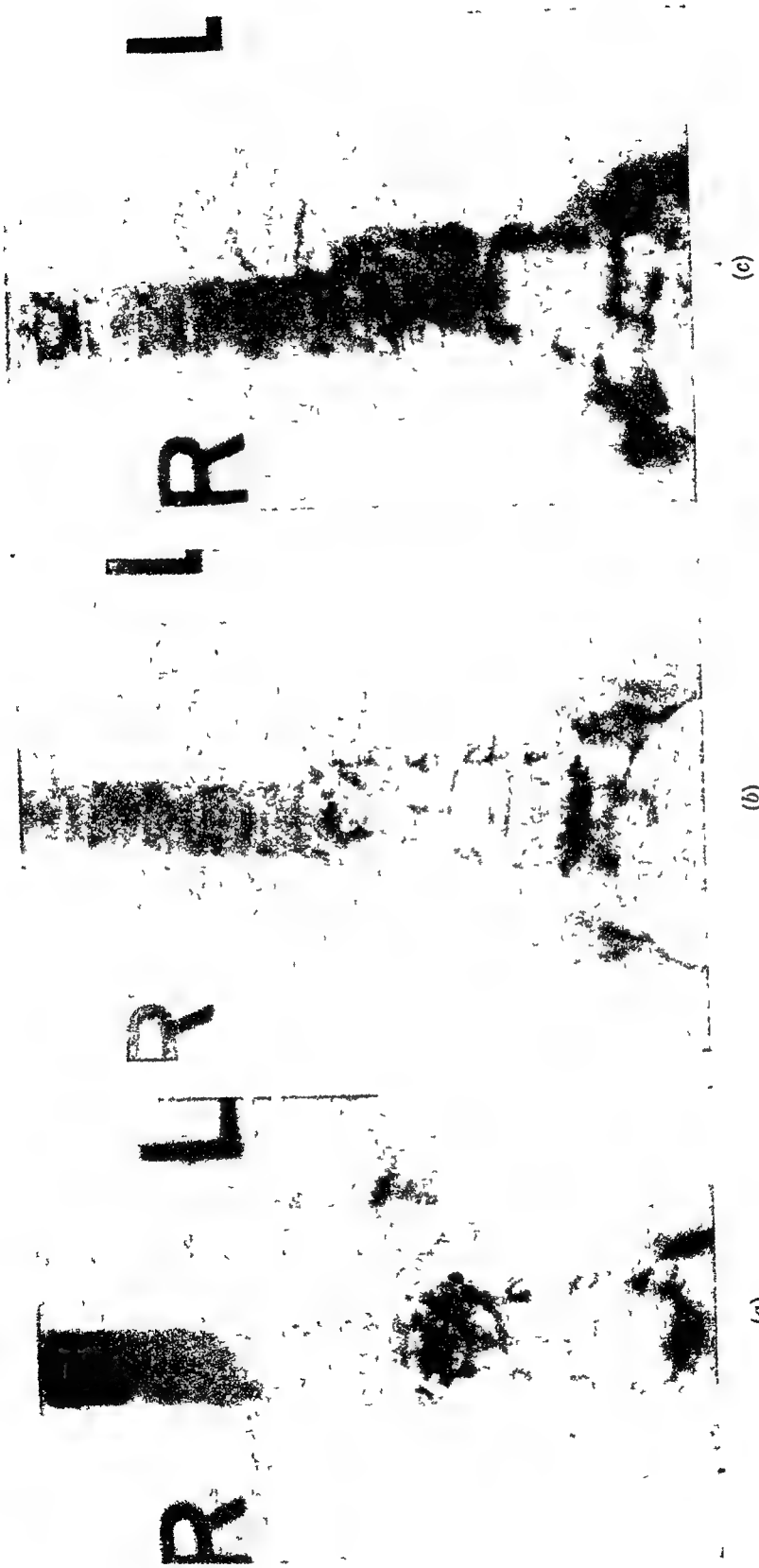

(a) (b) (c)

FIG. 121.—Tuberculosis of the Spine

(a) Disease affecting the lumbar region with a typical lateral displacement and the formation of a Psoas abscess on the left side (28 1 27)
(b) A later stage—10 months later—of lumbar disease (30 11 27)
(c) The appearance after 19 months' treatment (30 10 28) Healing is taking place and the bones are better defined The abscesses are now calcified

This occurs rarely and probably it is wiser to do a more thorough exploration as described below.

2. *Laminectomy and Grafting.* Girdlestone advises this in cases where there is no radiological evidence of a paravertebral abscess. (See p. 323.)

3. *Anterior spinal decompression operation.* This is carried out in cases of severe early paralysis without abscess, absence of recovery after evacuation of an abscess, late paralysis from continued activity or recrudescence, and in late cases where compression is believed to be due to a bony ridge. Dott has emphasized the importance of exposing the internal gibbus and decompressing the anterior surface of the theca there since the compressing agent is always anterior and in most cases is solid and must be directly exposed and removed. A skin incision is made curving widely to one or other side of the external gibbus. The superficial muscles are cut near the spine and the erector spinæ displaced inwards to give a flap closure. The posterior ends of several ribs are removed along with their corresponding transverse processes and the corresponding pedicles and adjacent portions of the vertebral bodies. This gives access to the internal gibbus. Care must be taken that too much of the neural arch is not removed as lateral luxation of the spine might then occur. The more prominent the gibbus the easier is this lateral approach to it. The anterior surface of the theca is fully exposed and as the compressing agent is removed fluid pulsation can frequently be seen to return to the theca. It is interesting that in several of Dott's cases he found the compressing agent was a retro-pulsion of a persisting intervertebral disc lying as a transverse bar against the anterior surface of the theca.

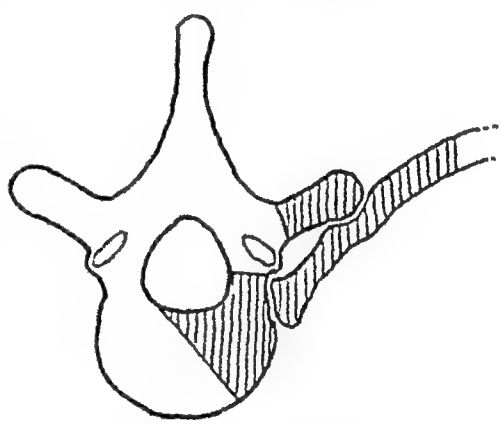

Fig. 120.—The extent of bone removal in anterior spinal decompression.

Mode of Repair in Vertebral Tuberculosis.

Healing of spinal caries occurs by the absorption of tuberculous debris and its replacement by fibrous tissue, a fibrous ankylosis occurring between the diseased bodies. Later, ossification occurs, again principally in the region of the primary disease; to a lesser extent, some new bone formation takes place in relation to the posterior arch, and adjacent laminæ and pedicles may thus become fused together. The new bone is soft and yields easily, so that unless adequately protected it may be unable to withstand the superincumbent body-weight, even though the tuberculosis is completely eradicated. Thus it happens that under the strain of ill health or overuse the deformity may actually increase, and give rise to backache after the disease is

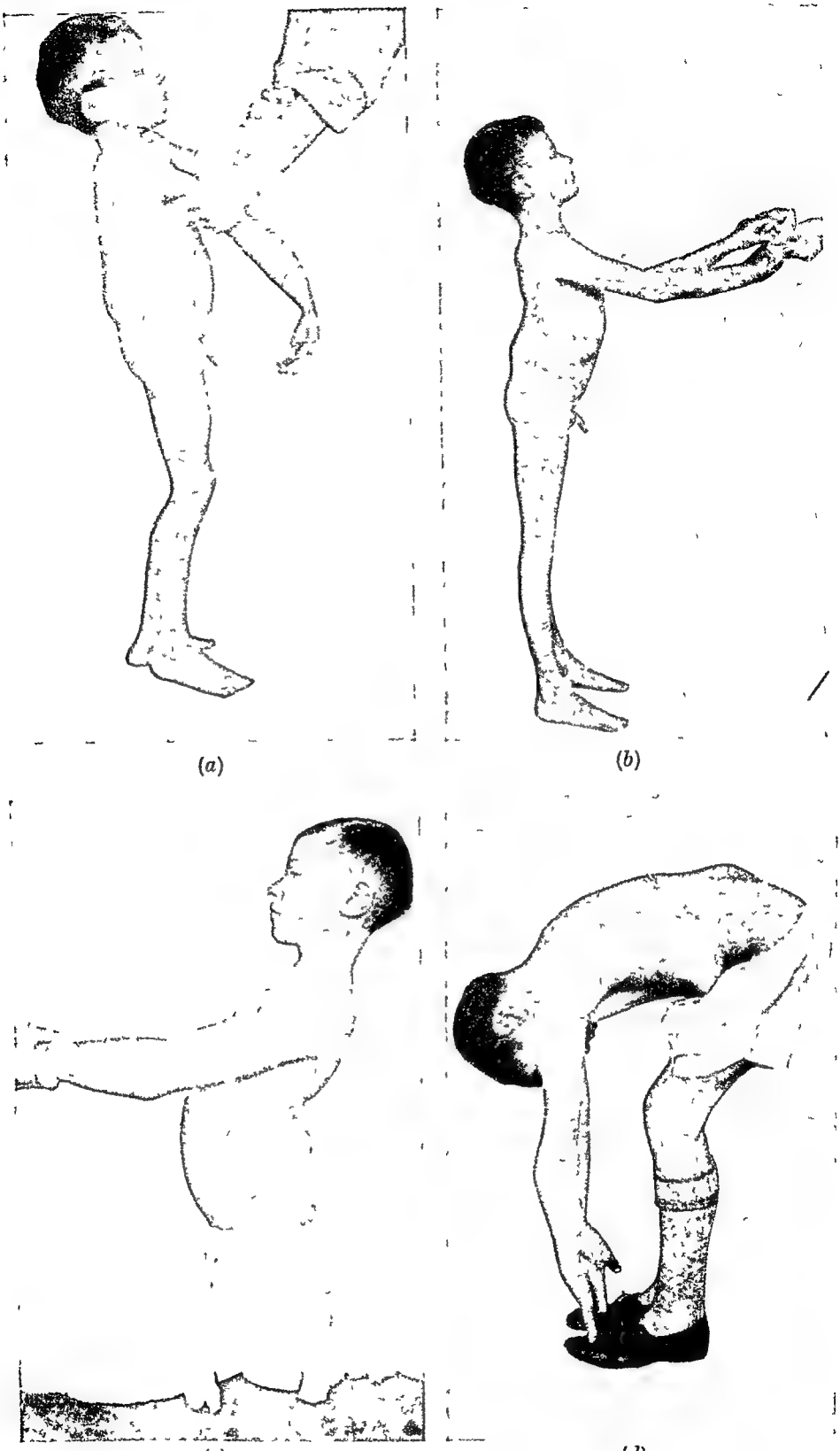

FIG 122 —Tuberculosis of the Spine

(a) Disease of the lumbar region with kyphus formation
(b) The same case at a later stage of treatment
(c) The disease is now healed and the presence of the deformity has been balanced by the compensatory curves below and above
(d) Forward flexion is performed with ease and freedom from pain, although there is still a remnant of the disease in the presence of a gibbus

completely healed. The cure of the disease in the lumbar region frequently results in complete bony union between two adjacent vertebræ with virtually no deformity.

Symptoms of Spinal Tuberculosis

Before the actual onset of characteristic local symptoms, there is a prodromal period, frequently preceded by one of the exanthemata. During this stage there is often some deterioration in the general health. There may be lassitude, loss of weight, a poor appetite and often an evening rise of temperature. These symptoms last for a few weeks or months, but eventually the evidences of spinal trouble appear. These are:

1. Pain. The occurrence of pain is usually the first indication of spinal disease The pain may be either local, i.e. experienced in the back, or referred along one of the spinal nerves In either case, it is frequently severe, because of the free and complex nature of the movements of the spinal column, and because of the close proximity of the spinal nerves. When felt locally, the pain is acute and stabbing, and situated over the affected vertebræ. It is aggravated by pressure on the spinous process, or by the rotation of the vertebra produced by pressing on the transverse processes

Fraser suggested the employment of a viscero-sensory reflex test to elicit the pain. If a cold sponge is drawn down the back over the tips of the spines, sudden severe pain is experienced when it passes over the area of the disease.

The referred pain is referred to the distribution of the sensory nerves, it is less acute, but exacerbations may occur. The skin areas supplied by the related nerves are hypersensitive to pressure.

In caries of the cervical spine the area of referred pain is usually situated over the occiput, and in the arms, in thoracic disease it takes the form of intercostal neuralgia; in thoraco-lumbar disease, of "girdle pains" or epigastric pain The reference in disease of the lumbar spine is to the hips and legs.

2. Night Cries are less frequent in spinal disease than in tuberculosis of the larger joints, but do occasionally occur in disease of the cervical or thoracic vertebræ. They are reliable evidence of the activity of the tuberculous process

3. Paraplegia. The pathological explanation of the various forms of paralysis has already been discussed in some detail, it remains to consider the associated clinical features.

The paralysis may manifest itself early or late in the course of the disease, it may even arise after apparent cure. In any event, it is important to search for its earliest evidences, since the prognosis may be noticeably altered by appropriate treatment.

Whether early or late, the paraplegic symptoms develop gradually.

FIG 123 —Tuberculosis of the Spine
The typical attitude in disease in the cervical region The head requires support

In low thoracic and upper lumbar disease, the thorax and head are thrown backwards; the abdomen is prominent; the patient walks with the legs far apart, and waddles—the so-called "alderman's" gait.

In lower lumbar disease there is pronounced lordosis, and the chest is thrown forwards till the last rib and the iliac crest may be actually in contact.

3. Irregularities of the Spine. The patient is stripped to expose the whole spine. Inspection may then reveal the presence of angulation, deformity, lateral deviation, lordosis, flattening or boarding, or paravertebral swelling

(*a*) *Angulation of the Spine* (*Kyphosis*). This is the most common sign, it is the result of the collapse of the affected vertebra or vertebræ and varies in degree with the extent of the disease When a series of vertebræ are affected the projection is slight and gradual, but when only one body is diseased the angulation is localized and prominent The anterior type of disease, which affects a long segment of the column, is associated with a long gradual curvature similar to that of the ordinary round shoulders.

(*b*) *Scoliosis* Lateral deviation often complicates kyphosis, indeed the case may be mistaken for one of simple scoliosis

(*c*) *Boarding.* The normal antero-posterior curves may be obliterated, even though the vertical axis of the spine is straight Such "boarding" or "flattening" is the result of muscular rigidity, and as it is one of the earliest clinical signs to appear, its recognition is of great importance

(*d*) *Lordosis* The spines above and below the site of the disease may show exaggerated forward curvature, to compensate for the kyphosis.

FIG 124.—Tuberculosis of the Spine
In the presence of thoracic disease a coin is picked up from the floor in this way

If the child has been able to go about, he may notice some stiffness and tiredness, or may show a fresh tendency to stumble or trip. There is difficulty in mounting stairs. These symptoms are all the result of muscular spasticity; sensory changes, if they occur, do so only a considerable time after the appearance of the motor phenomena.

4. Abscess Formation. The situation of abscesses in connection with disease in the various segments of the spine has been previously described; the investigation of these sites is an essential part of the investigation of any case of spinal caries, but the presence of certain symptoms will attract particular attention to the possibility of abscess formation.

The retropharyngeal abscess of cervical disease is associated with dysphagia and dyspnœa; abscesses in disease of the upper thoracic vertebræ are usually anterior, and may therefore involve the recurrent laryngeal nerves and give rise to dyspnœa and vocal changes.

In the lumbar spine, the debris seeks the surface usually as a psoas abscess, and the presence of infective material is so apt to induce irritation and spasm of the muscle that there is often persistent flexion and lateral rotation of the limb, any attempt to overcome these deformities being attended with great pain.

The Physical Examination

A "routine" method of examination should be employed in investigating all cases of spinal tuberculosis. This should take note of the patient's general appearance, standing attitude, and gait, and must include a minute examination of the spine and pelvis. An X-ray examination is essential in every case.

1. The General Appearance. A systematic general examination may demonstrate the presence of other signs of tuberculous infection. In general the body nutrition is poor.

2. Attitude and Gait. There is often a strained and expectant facial expression, for the child is in continual dread of any sudden jar or movement. When the disease is active, no matter the situation, the patient walks with the leg joints semi-flexed, to lessen the jar of sudden movements. In addition, disease in each situation is associated with a characteristic gait or attitude.

In upper cervical disease, the position of the head is similar to that in wry-neck, but the face is not rotated. In lower cervical disease, the head is thrown backwards, and to one side.

In upper thoracic disease, the shoulders are raised, and the arms and shoulders drawn backwards. The head appears sunken, owing to the apparent shortening of the neck, and the attitude is aptly referred to as the "military attitude"

In mid-thoracic disease, the antero-posterior diameter of the chest is considerably increased, and owing to the shortening in stature the patient appears stunted and the arms seem unduly long.

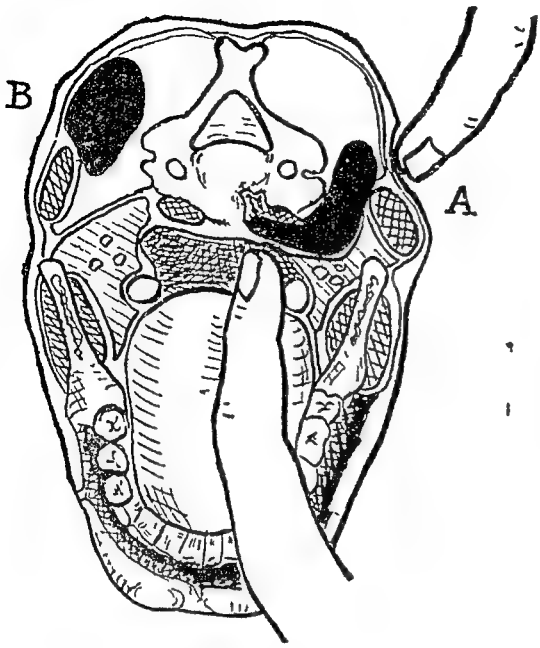

FIG 126 —Abscess from Tubercle of the Cervical Region.

It may be palpated bidigitally through the mouth, (A) differing in this respect as well as in site from the glandular abscess (B) (After Calot)

disturbances present. The paralysis may be incomplete, or may at first be complete and become incomplete later. Its extent and nature depend on the level and the amount of cord involvement.

When the infection is in the cervical region, the phrenic, accessory, and hypoglossal nerves may be affected The arms are implicated before the legs.

In thoracic disease there is spastic paralysis of the legs, without involvement of the sphincters.

In low thoracic and lumbar caries the lower limbs are paraplegic and the sphincters sometimes paralysed as well There are trophic disturbances, and often bed sores The legs atrophy, and remain cold and lifeless The motor paresis results in awkward jerking movements, an ataxic gait, and

FIG 127 —Tuberculosis of the Spine

A psoas abscess appearing in the thigh, having escaped from the pelvis under the inguinal ligament

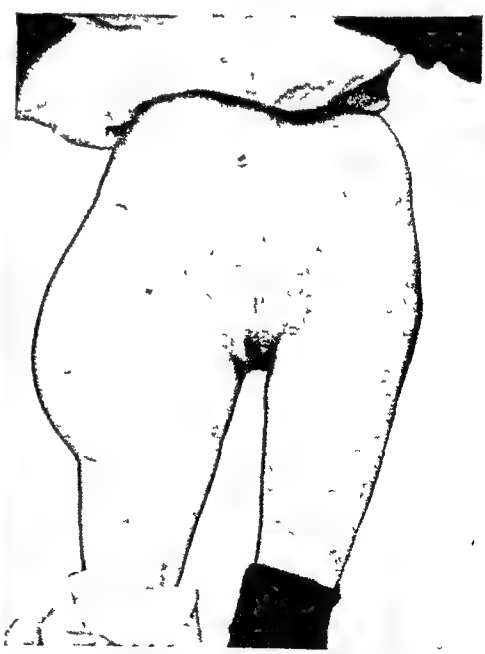

FIG 128 —Tuberculosis of the Spine

A large abscess has tracked down from the spine and appears in the region of the great trochanter

(e) *Para-vertebral Thickening.* The width of the column at the site of the disease may be increased, or a cold abscess may be seen pointing at one or other side. Such thickening is better distinguished by palpation, the finger being drawn down the back on either side of the spinous processes.

The exact extent of the deformity should be recorded in permanent fashion; this is best done by means of good photographs, taken from the back and from the side of the patient.

4. The Movements of the Spine. The natural efforts to protect the diseased vertebra result in a spastic contraction of muscles which effectively limits the spinal movements. This muscular rigidity is the most characteristic sign of Pott's disease. To elicit it, the antero-posterior, lateral and rotatory movements of the spine are carefully tested.

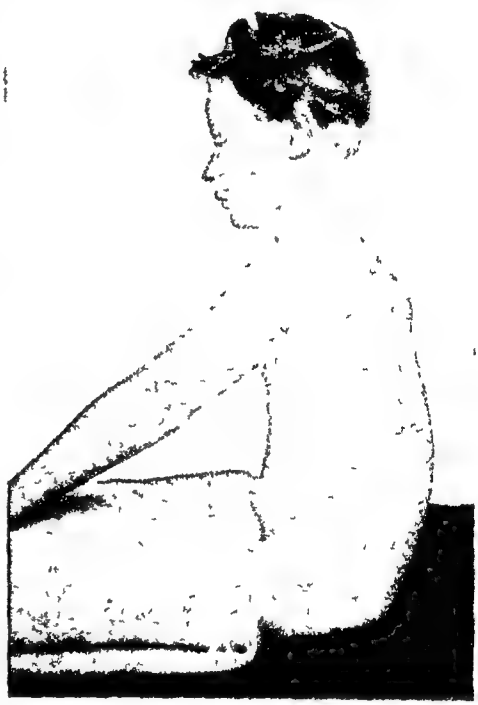

FIG. 125.—Tuberculosis of the Spine

The deformity in the region of the upper thoracic vertebræ, indicative of underlying disease

Cervical Region. Flexion, extension, and lateral movements are limited in tuberculosis of any part of the cervical spine, rotation is also limited when the atlanto-axial joint is implicated

Thoracic Region All movements are limited, but particularly that of flexion, and the normal thoracic curvature is replaced by an area of flattening. When the patient is asked to pick up some object from the floor, he does so by flexing the leg joints to lower himself, and by keeping one hand on his knee to support the back and to avoid the unpleasant consequences of a sudden jar. In assuming the upright posture he slowly rises, the supporting hand or hands being gradually advanced up the thigh—the so-called "climbing" up his legs manœuvre.

Lumbar Region. The normal lordosis is obliterated, and the sacro-spinalis shows marked boarding.

5. Examination for Cold Abscess. All possible abscess sites should be explored These are the pharynx, the triangles of the neck, the loins, the iliac fossæ, the groins, the gluteal, and the ischio-rectal regions. Sometimes the abscess is recognized only on X-ray examination.

6. Paralysis. The paralysis is spastic, with occasional involvement of the bladder and rectum, only very rarely are sensory

and there is a want of clarity in the detail of the bones. As healing takes place, the decalcification becomes less marked. Ultimately the diseased vertebræ form a continuous mass, the intervertebral spaces having disappeared, and the adjacent bodies fused.

A Summary of the Clinical Features of Tuberculosis in Special Regions.

(*i*) *Cervical Region*

(*a*) Limitation of head and neck movements from muscle spasm.

FIG 130 —Tuberculosis of the Spine.
Epiphyseal disease of the contiguous epiphyses of the first and second lumbar vertebræ

FIG 131 —Tuberculosis of the Spine
The disease affecting the upper lumbar region with collapse of the upper vertebræ

(*b*) Pain over the affected vertebræ, aggravated by pressure on the top of the head, and referred to the back of the head and the course of the cervical nerves.

(*c*) Deformity resembling wry-neck, with the normal cervical concavity, or "lordosis," obliterated

(*d*) The head is usually supported by the patient's hands.

stumbling and dragging of the toes; sensory changes are rare, but there may be pain in the body or limbs, and derangements of cutaneous sensation. The deep reflexes are exaggerated in the early stages, but disappear progressively as cord degeneration proceeds.

7. Changes in the Thorax and Pelvis. The chest shows a variable degree of alteration. When there is a high thoracic gibbus, the chest is flattened, and the sternum slopes downwards and forwards, while the ribs have an increased downward inclination.

In low thoracic disease, the chest is barrel-shaped, while in lumbar caries, the whole chest is displaced forwards and downwards, the last rib often being in contact with the iliac crest.

These errors in configuration are readily appreciated on inspection

8. Changes in the Heart and Great Vessels. The position and size of the heart are often changed, especially in disease of the upper thoracic spine.

The kyphosis results in some displacement of the heart, the base being forced downwards and the apex tilted to a higher level. The myocardium may be hypertrophied, since the great vessels are often kinked opposite the deformity. These changes are detected by the usual clinical methods

FIG. 129 —Tuberculosis of the Spine.
Tuberculous abscess coming to the surface through the lumbar triangle

9. Radiographic Examination. The examination is completed by an X-ray investigation, both an antero-posterior and a lateral view of the spine being taken The diagnosis is thus confirmed, the degree and extent of the disease estimated, the presence of a cold abscess detected, and any evidence of healing determined.

The lateral view is particularly valuable, as it shows evidences of the disease long before the other. Jones states that irregularity at the anterior edge or corner of the vertebra is characteristic of early tuberculosis. Doub and Badgley believe that narrowing of the intervertebral disc is the earliest and most constant X-ray sign in tuberculosis of the spine Later, as the spine becomes "buckled," the vertebral body becomes wedge-shaped. In addition, during the active stage, the affected vertebræ are less dense, decalcification has occurred,

(*f*) Occasionally cough, vomiting, and slow pulse from pressure on the recurrent laryngeal nerves and vagus

(*g*) Head and body turned simultaneously when patient looks to the side

(*h*) Grunting breathing from pressure on the intercostal nerves.

(*iii*) *Thoracic and Thoraco-lumbar Disease.*

(*a*) Angular gibbus and muscular rigidity

(*b*) Often palpable thickening of spine

(*c*) Girdle pain, or pain over affected spines

(*d*) Pain radiating to lateral aspects of the thighs.

(*e*) Iliac, or psoas abscess

(*iv*) *Lumbo-sacral Disease.*

(*a*) Deformity slight

(*b*) Vertebral thickening

(*c*) Funnel-shaped deformity of pelvis

(*d*) Neuritis and referred pain as in lumbar disease

(*e*) Often flexion, and pseudo-rigidity, of the hips

(*f*) Psoas abscess.

Diagnosis

The recognition of spinal caries is not difficult when a well-marked kyphosis is present, but if the results of treatment are to be at all satisfactory, a diagnosis must be made at a substantially earlier stage Further, the presence of a gibbus is not invariable, even in late spinal tuberculosis, with paraplegia, the "hump" may be absent. The important findings which establish the diagnosis are rigidity, pain, slight spasticity, abscess formation, and the radiological appearances previously discussed.

Differential Diagnosis of Pott's Disease

The early diagnosis may be anything but an easy matter; tuberculosis may be mistaken for a variety of conditions In this connection, it will simplify matters if the differential diagnosis is considered on a regional basis

Cervical Pott's Disease. Cervical caries may be confused with:

(*i*) *Congenital Torticollis* This to some extent resembles Pott's disease in the abnormal position of the head and neck, but in torticollis movement is painless, and the shortened sternomastoid is very obvious. The face also is rotated towards the opposite shoulder, and is small and atrophied on one side, while the cervical spine itself is quite flexible In that acute form of torticollis which is secondary to arthritis of the cervical spine, there is a more acute history than in Pott's disease, while there is usually a co-existing inflammatory lesion elsewhere, e g tonsillitis. The condition also, as a rule, subsides rapidly under appropriate treatment.

(*ii*) *Developmental Abnormality.* A deformity is sometimes seen

(e) Abscess in the retropharyngeal or suboccipital regions.
(f) In cases with cord pressure paralysis of the arms before the legs.
(g) Occasionally sudden death from dislocation.

(ii) *Low Cervical and Upper Thoracic Regions.*
(a) Marked rigidity, with angular kyphosis.

FIG. 132.—Tuberculosis of the Spine
"Dumb-bell" abscess in the lower thoracic region

FIG. 133.—Tuberculosis of the Spine
A "dumb-bell" abscess arising from disease of the seventh and eighth thoracic vertebræ

(b) Pain along the branches of the cervical or brachial plexus
(c) Abscess in the retropharyngeal or supraclavicular regions, or in the mediastinum
(d) Cord symptoms less common; if present, arms first affected.
(e) Occasionally, dilatation of the pupil from pressure on the sympathetic system.

(*ii*) *Sacro-iliac Disease.* This is rare in childhood. The pain and tenderness are situated directly over the joint Spinal movements are unrestricted, but flexion of the thigh with the knee extended is abruptly arrested by pain in the sacro-iliac region.

(*iii*) *Low-Back Strain.* Here the symptoms arise suddenly after injury, and the spinal movements are restricted and painful. Tenderness can usually be elicited at the point of injury, and one or other of the sacro-spinales may be in spasm. Radiological examination is negative, and the limitation of spinal movements obviously voluntary and due to pain. The condition is relieved by rest.

(*iv*) *Secondary Carcinoma.* This is distinguished from its age incidence—over 40—by a greater degree of pain, by a total collapse rather than an erosion, and by the absence of involvement of the disc A primary growth is, of course, present, but may not always be discovered.

(*v*) *Pyogenic Disease* This may be primary or part of a general infection The pedicles and laminæ are just as often involved as the body The diagnosis from tuberculosis is made from the history, sudden onset, high fever, leucocytosis and acute pain

(*vi*) *Spondylitis Ankyloporetica.* This ankylosing disease of the spine occurs between 18 and 25 years of age and usually starts in the lower part of the spine, often in the sacro-iliac joints. It begins with pain and rigidity, and in the early stages is difficult to distinguish from tubercle although an X-ray of the sacro-iliac joints should identify the disease

(*vii*) *Osteo-arthritis.* In the elderly this is a common cause of pain in the lumbar region and often with a sciatic radiation. It is easily diagnosed by an X-ray which shows sclerosis and osteogenetic reaction rather than decalcification and erosion.

Prognosis

Vertebral tuberculosis is always a serious condition. In children the mortality is considerable, but in adults there is even greater threat to life, and a correspondingly higher death-rate There appears to be little doubt that results have been greatly improved with the advent of antibiotic treatment. Sven Johansson in 1926 reported on 91 cases treated between 1909 and 1923 of whom not quite one-third were treated by surgical fusion and the rest conservatively. The mortality rate was 28 per cent. There have been few studies of the therapeutic results of operative evacuation of the lesion combined with chemotherapy but Johnson *et al* (1953) reported 78 cases of tuberculous spondylitis treated by operation without any deaths Kaslert (1953) reported 489 patients treated by this method but with local treatment through a drainage tube After 45 months the mortality was 1 75 per cent. 93 5 per cent were healed out of 250 investigated with an observation period of 15–45 months These are extremely good results in comparison with earlier conservative treatment. In some cases the evacuated area was filled with bone chips.

without signs or symptoms. An X-ray may show fusion of vertebræ or absence of one half. There is no decalcification, but such conditions are apt to give symptoms in later life from mechanical strain.

(*iii*) *Sarcoma.* Sarcoma is accompanied by severe local pain, often by paralysis, and by a certain degree of deformity, it is, however, rare in childhood. The distinctive features are the severity of the symptoms, sensory changes, the presence of a palpable tumour, and early and progressive paralysis The X-ray picture is usually diagnostic

Tuberculous Disease of the Thoracic Vertebræ. Thoracic Pott's disease must be distinguished from ·

(*i*) *Rickets.* Kyphosis may arise as a sequel to rickets, but there are usually evidences of the disease in other regions. The kyphosis itself can usually be corrected without difficulty; muscular spasm is absent, and pain is an unusual feature

(*ii*) *Scoliosis* In scoliosis, the spinal deformity takes the form of a lateral curvature, and pain and muscular rigidity are absent. Inevitable and constant changes take place in the shape and direction of the ribs; these are readily apparent on inspection. In early cases, an X-ray picture may serve to establish the diagnosis.

(*iii*) *Osteochondritis.* This is a rare condition, also called Calvé's disease, and of the same nature as Perthes' disease. It is the result of an aseptic necrosis and shows a flattening of the vertebral body without involvement of the disc.

(*iv*) *Schmorl's disease* This is the result of a defect in the upper or lower growth plates of the vertebral body so that the disc herniates through them into the body of the vertebra. Localized backache may be present, but there is no deformity and the X-ray distinguishes the condition.

(*v*) *Aneurysm.* This serious condition may produce in the thoracic region localized spinal pain and anterior erosion of the vertebræ, simulating an anterior periosteal type of tubercle. The erosion is, however, clear-cut and regular, without involvement of the discs and without decalcification.

(*vi*) *Scheuerman's disease, or vertebral epiphysitis.* In this condition an ill-defined pain in the back is present in the lower thoracic region of a child of about 12 years of age. A radiogram shows an irregularity of the epiphyseal disc, most marked at the anterior edge of the body. The clarity of the intervertebral disc is lost and there may be some wedging of the vertebræ

Lumbar Disease. Tuberculosis of the lumbar vertebræ may be mistaken for:

(*i*) *Hip-Joint Disease* In this condition there is usually a limp, from contraction of the psoas muscle; the joint also is kept in a flexed position. Symptoms directly referable to the spinal column are unusual; movement at the joint is painful, and its range limited in all directions.

intermittent streptomycin, resistant organisms will emerge in a proportion of cases

3. Isoniazid, 100 mgm. twice a day, together with P.A.S. 5 gm. twice daily.

With any of these combinations the incidence of drug resistance should be exceedingly low, if not avoided altogether. The existence of bone or joint tuberculosis always indicates that there has been a hematogenous dissemination of the disease, and one is as concerned in trying to knock out other cryptic foci of tubercle bacilli as to deal with the more obvious lesion. Both for the immediate effect on the more obvious lesion and the effect on the cryptic lesions, Crofton strongly favours really prolonged chemotherapy He thinks that a year should be the minimum period of time in which to continue treatment, but in fact in most orthopædic lesions it is desirable to continue treatment until the bone lesion is really well healed and in most cases it is wise to continue for eighteen months to two years. After the first six months or so of treatment with a combination involving streptomycin, it is reasonable to switch to the isoniazid and P A S. combination in order to save the patient so many injections. This combination, being taken entirely orally, is also very convenient after the patient has left hospital

(B) Local Treatment

The local treatment is also important, unless it is faithfully and efficiently carried out, the general treatment is of little avail

The object of the local management is to secure immobilization of the affected region of the spine, and in this way to give nature an opportunity to heal the condition The exact details depend to some extent upon the conditions operative in each particular case—whether it is uncomplicated, or whether there is a gibbus, an abscess, a fistula or paralysis Each of these different types of case must be considered, and treated, on its merits

The Treatment of an Uncomplicated Case.

The majority of cases of Pott's disease may be placed in this category. The treatment is divided into stages—the first, that of complete recumbency; the second, the stage of ambulation; and the third, the stage of convalescence The treatment is carefully graduated, the patient passing by degrees from one stage to another, when symptoms pointing to activity or recrudescence of the disease are absent.

Nature, be it noted, in endeavouring to protect the carious vertebræ, immobilizes the vertebral column by keeping the muscles contracted in involuntary spasm. In so doing, however, the spasm increases the tendency of the diseased vertebræ to collapse, and thus inaugurates or aggravates an angular deformity. The ideal method of treatment seeks to allay the spasm, to immobilize the spine, to prevent deformity, to arrest the progress of the disease and finally to cure it.

Wilkinson treated 65 cases of spinal tuberculosis by evacuation of the paravertebral abscess and curettage of the vertebral body under an antibiotic cover and early results were good. Bony ankylosis was obtained in 36. There was no mortality and the duration of treatment was greatly shortened as compared with conservative treatment.

The prognosis is greatly influenced by certain factors, viz. the stage of the disease at which treatment is begun, the efficiency of the treatment and the site of the lesion. In the last connection, it may be said that tuberculosis of the thoracic vertebræ is the least favourable, since abscess is a common complication, paraplegia a frequent consequence, and the proximity of the thoracic structures a further danger.

When adequate treatment is applied early the outlook is greatly improved Mortality figures in the sanatoria are low. The gibbus if recent will not only be arrested in its progress but will be effaced. Abscesses will be less frequent and paralysis rare and if it supervenes will usually be cured

TREATMENT OF TUBERCULOSIS OF THE SPINE

(A) General Treatment

Efficient general management is of the utmost importance in tuberculous disease of the spine. Indeed it is the actual "curative" factor in the treatment; it consists of the usual anti-tuberculous measures, as, for example, improved hygiene, healthy surroundings and a liberal nutritious diet An open-air régime is specially to be recommended, indeed these patients thrive best when out of doors from morning till night Cod-liver oil and tonics should be given freely.

The advent of chemotherapy has fundamentally altered the treatment of tuberculous disease of bone and joint Streptomycin is tuberculostatic as well as tuberculocidal and this is of great advantage since it gives the orthopædic surgeon a far greater control of the course of the disease at any stage, especially in combination with para-aminosalicylic acid (P A S) and isonicotinic acid hydraside (isoniazid)

The following combinations advocated by Crofton of Edinburgh are most satisfactory in lesions of bone and joint

1 Streptomycin sulphate, one gram daily intramuscularly, combined with isoniazid 100 mgm twice a day by the mouth. This is suitable for younger patients under the age of 40.

2 Streptomycin sulphate, one gram intramuscularly three times weekly, together with sodium P.A.S. 5 gm. and isoniazid 100 mgm., both given twice daily by the mouth This combination is suitable for patients over the age of 40 The lower dosage of streptomycin largely avoids vestibular damage which is more likely to occur with daily streptomycin in older people. It is important that both P.A.S. and isoniazid should be given If only P A S. or isoniazid is given with

is applied to the patient's back, from head to foot, the legs should be slightly abducted, the knees flexed, and the arms abducted to a right angle. Laterally, the plaster bandages should reach the anterior margin of the lateral aspect of the body Where necessary, the case may be strengthened by incorporating aluminium strips When the shell has set, it is marked with a pencil to show where it may be trimmed, and especially the area to be removed from the gluteal region for nursing purposes. It is now lifted off the patient's body, and to do this it may be necessary to ease the edges off from the sides of the body. When completely set and dry the marked edges are cut off and the shell lined with thin felt. Straps and buckles are fixed to the shell in about four places—chest, pelvis, thigh and leg. These serve to retain a further degree of immobilization in the recalcitrant patient

As patients who are being treated in a plaster shell should be turned over frequently to have their backs attended to, it is a useful plan to make a lid, or anterior shell, in which they can lie while receiving this attention. The anterior shell is placed in position and the two cases are strapped together, and thus a complete plaster box is formed in which the patient is securely held The box is now rolled over and the posterior shell lifted off By this means the skin of the back can be exposed and treated with methylated spirit and boracic powder without interrupting the immobilization at all The condition of the skin is of particular importance when methods of correcting the deformity are in use, as the skin is then more subject to pressure necrosis. Where foot pieces are used, and they are only necessary in the posterior shell, they are quite separate from the plaster case so that they do not form a fulcrum for the patient to lever himself up by pressing his feet against the foot supports. This would seriously detract from immobilization of the spine Hence foot pieces of aluminium are slipped into the leg gutter of the plaster

Although the treatment of Pott's disease by a plaster shell appears to be somewhat elaborate, there is no real difficulty and its use need not be limited to a well-equipped hospital. In the case of children, of course, the shell has to be repeatedly changed as the patient outgrows the preceding one

(*b*) *Anterior Plaster Shell* This is a very comfortable method and the one of choice in treating low thoracic and lumbar disease and is applied with the patient lying on his back The hyper-extension is achieved by allowing his head and neck to drop to a lower level than the area of disease by an appropriate arrangement of small pillows The plaster is made in the same way as the posterior one. It is found that defæcation and micturition are performed in an even more cleanly manner than with a posterior shell The anterior shell has the further advantage that when the child tries to look about him the tendency is for the spine to be hyper-extended, whereas in the dorsal decubitus the tendency is towards flexion. The result, therefore, is that in the anterior shell there is less likelihood of the formation of a gibbus. The

Recumbency.

Recumbency should be advocated at the start of treatment in all forms of the disease, and both before and after any operation. Some authors, however, have pointed out what they believe to be special indications

These are:

(a) Acute symptoms.
(b) Paralysis
(c) Psoas spasm or muscular contracture.
(d) Lateral deviation of the spine
(e) Abscess formation
(f) When ambulatory treatment has been tried and found unsatisfactory.
(g) When the presence of infection in the disease area precludes any attempt at operative treatment.

In my own opinion, once the diagnosis is made, recumbent treatment is absolutely vital.

Methods of Fixing the Spine in Recumbency.

Fixation of the spine in the recumbent position in full extension affords more complete immobilization than any form of ambulatory fixation, and is therefore attended with greater and more rapid relief of symptoms. The necessity of rest in the recumbent position, during the whole period of activity in Pott's disease, is not now seriously disputed, but the methods of achieving this rest are many and varied. Rest alone, however, is not enough to prevent the displacement of the vertebræ. Success can be obtained with certainty only by something which will retain the two segments of the diseased spine. I believe that the treatment by plaster is the most efficacious, the most simple and the most practical.

(i) *Treatment by Plaster Shell*

Believing that effective fixation is an absolute necessity for the treatment of tuberculosis of the spine, I give precedence to fixation in a properly made plaster shell. The other methods of splint, frame, special bed, etc, in spite of their apparent simplicity, are, when one reckons up everything, much more complicated, more difficult to apply and to look after, and much less comfortable for children. The plaster shell is made for the individual case and is accordingly much more comfortable and fits more accurately.

Plaster shells may be of two types, posterior or anterior, and in constructing them, it is necessary to make the shell with the patient's body hyper-extended as far as the activity of the disease allows.

(a) *Posterior Plaster Shell* To make the shell, the patient is placed face downwards, on an ordinary operating table, and the hyper-extension is achieved by laying an arrangement of pillows under the upper part of the thorax and it may be under the pelvis. The body is covered with a single layer of white lint. A series of broad plaster bandages

(2) that the general condition is good, and there is reason to believe that the tuberculous process has been arrested,

(3) that the kyphosis is not increasing;

(4) that the temperature remains normal;

(5) that the weight is increasing,

(6) that the radiographic appearances are satisfactory.

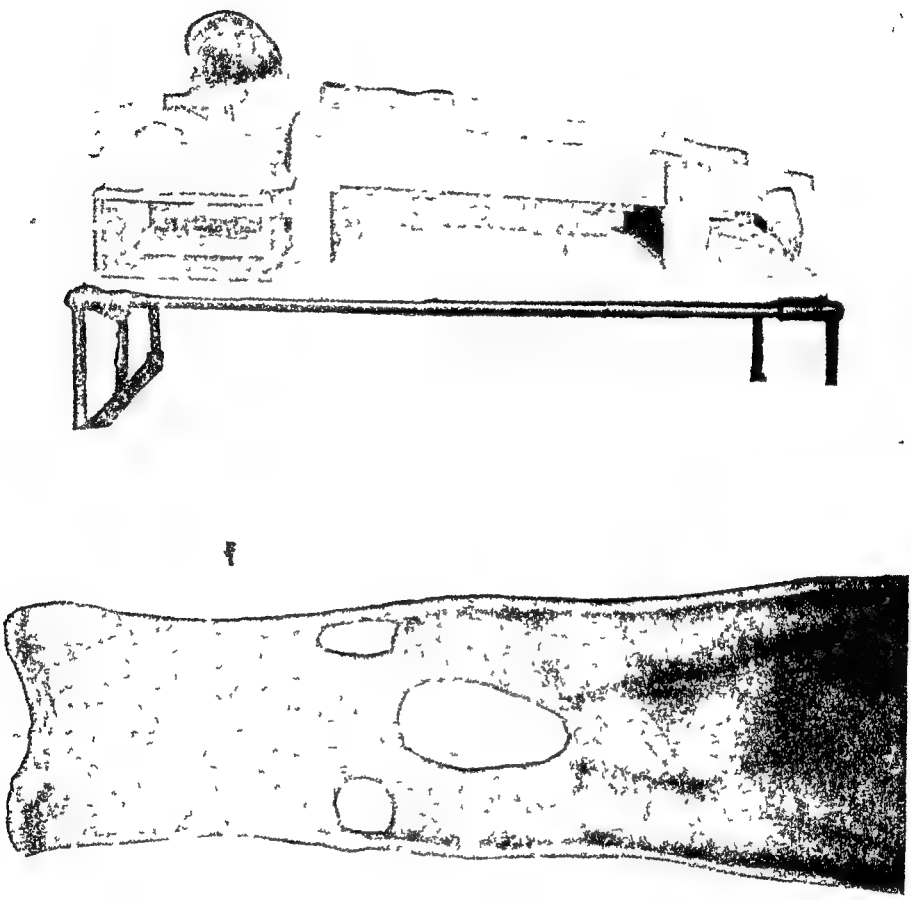

FIG 137 —Anterior Shell of plaster of Paris used in the post-operative stages of Hibbs' and Albee's operations

A special wooden frame is used in conjunction with it

Should it be decided to discontinue recumbent treatment, the patient must be kept under close observation for some time after, since unfavourable symptoms may recur He is usually kept in bed on a firm mattress but without retentive apparatus for a few months Any return of pain, the appearance of paralysis, deterioration in general condition, the development of abscesses, or increase in kyphosis, imperatively demands the resumption of recumbent treatment

Ambulatory Treatment.

When the child is finally allowed upon his feet, the spine must

shell is mounted on a wooden frame and the head is supported on a box and pillows. The author believes that the anterior shell should be universally adopted unless there are contra-indications to its use. These would appear to be, a large abscess, such as a psoas, sinuses which require dressing anteriorly, paraplegia or spasm. It is quite impossible to have a spastic patient in an anterior shell, since the spasmodic movements quickly initiate sores on his knees.

This method is particularly useful for the nursing of cases after arthrodesing or other operations on the spine. The patient need only be turned on to a posterior shell once a week for cleaning purposes. The method is depicted in Fig. 137.

(*ii*) *The Whitman Frame*

The Whitman frame is also a useful method for fixing the spine while the patient is recumbent, but it has to be supplemented by special appliances when the disease is in the upper thoracic and cervical regions. The frame is a modification of that evolved by Bradford; it was designed to enable the deformity to be corrected, to give more direct support to the patient, and to interfere as little as possible with the clothing and the nursing. It consists of a rectangle of ordinary galvanized gas-pipe, or steel tubing of small diameter. A frame is made for each individual patient; it should be about 6 inches longer than the patient, and about three-fourths of his width, the lateral bars lying opposite the articular surfaces of the shoulder and hip joints. The frame is completed by the addition of a strong canvas cover, which stretches between the lateral rods, and is laced up the back. Rubber squares laid under the buttocks protect the canvas from being soiled. Two thick pads of felt are sewn to the part of the canvas which is going to support the diseased vertebræ, or the gibbus, when present. These lie parallel to each other, and should be placed on either side of the spinous processes; they are usually about 7 inches long and 1 inch thick. Their function is to fix the part more firmly, and to guard the gibbus, or the spines of the diseased vertebræ when there is no deformity, from undue pressure. Wearing only an undershirt and stockings, the child is placed on the frame and fixed there by straps, or by an "apron" piece. The child should be comfortable on the frame; and clothing other than the undershirt should be made large enough to be easily applied over the frame, in order to avoid undue disturbance.

When necessary the shoulders may be fixed to the frame, and when the lower segments of the spine are involved, the legs may be restrained by applying a broad swathe round the thighs. When muscular spasm is a marked feature, traction may be applied quite simply by adding the necessary fittings to the original frame.

As soon as the child has become accustomed to the restraint, the frame may with benefit be further adjusted. Originally it was thought that the deformity could be made to disappear by gradually angling the frame opposite the gibbus. Since the shoulders and the pelvis

As each bandage is applied, therefore, it is carefully moulded over the bony points, and especial attention is paid to the pelvis where all the weight is borne After the plaster has "set," the edges are trimmed, and segments of appropriate size cut out, one over the front of the abdomen, to allow for any abdominal distension, and one over the gibbus to prevent undue pressure. The plaster must be thoroughly dry before the patient is allowed out, as the chilling effect of a damp jacket may have serious consequences.

Calot used a somewhat similar jacket during the recumbent stage, but in addition to the anterior window he cut a vertical trap-door over the gibbus, under the edges of this posterior opening he packed pieces of felt which exerted a certain amount of corrective pressure on the kyphus.

Fig 140 —Tuberculosis of the Cervical Spine A celluloid collar used in the later treatment of the disease

When the disease is situated in the higher thoracic vertebræ the jacket should reach well above the affected bones. In cervical caries the support is usually of the "Minerva" type, the plaster extending upwards as far as the jaw, mastoid, and occiput Alternatively a "fillet" support may be employed; in this jacket the head is kept extended by carrying a band of plaster round the forehead, while in front the plaster does not reach so high. Calot's "grand" jacket may also be used This jacket leaves the throat, jaw and face free, but is moulded up over and round the head and down to include the forehead.

Whichever type of jacket is advocated, it should be worn for at least eighteen months, it is then discarded in favour of a removable celluloid jacket

The Celluloid Spinal Jacket. The celluloid spinal jacket is fashioned over a cast or mould of the patient's spine The cast is made by applying, and accurately moulding, a series of plaster-of-Paris bandages to the trunk, to form a light plaster shell. When hard, the shell is bivalved and removed, and the two halves later joined The reconstituted shell is now filled with plaster cream, which hardens to form an exact replica of the patient's torso Successive layers of modified cheese cloth or muslin are applied in single layers to the cast, each layer being brushed over with a solution of celluloid in acetone.

still be carefully protected, and numerous methods have been devised towards this end. Usually a plaster-of-Paris jacket, or some form of brace, such as that devised by Thomas, is used, the writer mainly relies on the plaster jacket, as it has to be made for each patient, and therefore fits perfectly and is comfortable, in addition to affording excellent support to the spine. It has the further advantage that it cannot be removed without the knowledge of the surgeon.

Application of the Plaster Jacket. The plaster bandages may be applied with the patient in the erect position, but are more usually applied by the sectional method as previously described. In this way, the jacket can be more accurately moulded to the various prominences and depressions of the trunk. If applied in the erect position, it is desirable to relieve the diseased vertebræ of any superincumbent weight and this is most easily done by suspending him by means of a cotton sling passed under the chin and below the occiput A thin vest may be worn, alone, or with the bony prominences further protected by felt pads. The undervest should be thickly impregnated with boracic acid, to diminish the risk of verminous infestation, which often makes the life of the poorer class of patient wellnigh intolerable

Fig 138 Fig 139

Fig 138 —Tuberculosis of the Spine A plaster case for high Thoracic Disease

A window is cut over the gibbus to prevent undue pressure Note the "baldness" over the occiput from long-continued decubitus

Fig. 139.—Tuberculosis of the Cervical Spine. Plaster jacket with fillet support.

The essential moulding of the plaster and the abdominal window are shown

The plaster should be applied closely, sores are much more liable to develop in loosely fitting plasters, indeed the majority of so-called pressure sores are in actual fact "friction" sores. In addition, a loose-fitting jacket deprives the spine of much of its support.

FIG. 142 —Tuberculosis of the Spine A well-moulded Celluloid Jacket for use in the Convalescence of Lumbar Disease

of about a year; it is better to continue treatment for two years too long than for two months too short At first the apparatus is removed only for a short period each day, and then reapplied; gradually the intervals of freedom are increased until ultimately the support can be dispensed with altogether

Should there be any return of pain, or any increase in the degree of the deformity, the support is immediately replaced, and its use continued for a further prolonged period.

RECUMBENT TREATMENT AS APPLIED TO INDIVIDUAL REGIONS

Each segment of the vertebral column has its individual peculiarities of structure and function; in spinal caries, therefore, there are special difficulties to be overcome in each region, and special complications to be anticipated and prevented For this reason, the recumbent treatment may require to be modified or supplemented according to the vertebral area involved

The Cervical and Upper Thoracic Regions. As the cervical vertebræ are of small size, the disease is usually limited in extent The truly transverse direction of the transverse processes limits the amount of wedging here. The prognosis as regards recovery from the disease is good, and there is usually little or no apparent deformity, since the

FIG. 143 —Tuberculosis of the Spine A low Celluloid Jacket used in a case of Lumbar Disease in the late convalescence.

The high anterior extension prevents any undue spinal flexion (Same case as Fig 122)

About twenty layers are necessary to make a strong jacket. When completed, a series of holes is made in the jacket for ventilation purposes; the edges are then bound, and the necessary straps and buckles affixed.

It forms a very light and strong support; in addition it is fairly cheap to make, easily kept clean, and can be quickly removed It is usually worn over a light undervest, and since it is quite comfortable, it need not be removed at night

(a) (b)

FIG. 141 —Tuberculosis of the Spine Celluloid jackets used in (a) low, and (b) high thoracic disease.

Convalescent Stage.

It cannot be too strongly urged that spinal tuberculosis is a slow and extremely chronic disease For this reason, treatment, to be effective and reasonably certain, must be prolonged over a considerable period, and convalescence should not be hurriedly begun Furthermore, each patient must be supervised carefully during convalescence, lest any recrudescence of the disease occur. Calot stressed the desirability of erring by excess, rather than by default, of precautions, and this is indeed true.

The convalescent treatment of vertebral caries begins when consolidation of the collapsed bodies is complete; it may be several years after the start of treatment, but again it is important to realize that the decision rests on something more convincing than on the period of time which has elapsed.

During the recumbent and ambulatory stages radiographic examinations should be made at frequent intervals. So long as there is any cavitation, any unevenness in the bone shadow, or evidence of decalcification, it may be concluded that the disease is not yet healed. When the lime content has been restored to normal, when pain and muscular spasm have been entirely abolished, and when the general condition is good, the possibility of convalescence may be considered

The Convalescent Regime. This should extend over a period

Where the disease is situated in the lower cervical region or in the upper thoracic region a useful method is by means of a posterior shell with hyperextension, as is depicted in Fig 136. Straps are used to fix the head down in the capital socket of the plaster After the necessary period of recumbency a plaster jacket of the "fillet" support type, as shown in Fig 139, may be used, and in the later stages of the disease a celluloid collar, such as is seen in Fig 140

The Thoraco-lumbar Region. It is difficult either to prevent or to cure deformity resulting from disease of the upper thoracic vertebræ, hence round shoulders and a short neck are frequent sequelæ. Paralysis not infrequently occurs, and when it does immobilization must be complete In thoracic disease the fixation may sometimes be secured, in children, by means of a Whitman frame, but for the majority of cases some form of plaster case, and preferably an anterior shell, is the best form of apparatus, the shell restricts the movements of the shoulder, and therefore of the affected vertebræ also, rather more efficiently. Recumbent treatment should be continued for from eight to twenty-four months

In the lumbar region the prognosis is good Healing takes place quickly and the trunk is left only a little shorter and broader than before, though a peculiar erectness of attitude may persist Here, too, the preferred method of treatment is by the anterior plaster shell, for it has the additional advantage of preventing the contraction of the psoas muscle which is so common and which may result in grotesque deformity This contraction is usually evidence of an abscess at the origin or within the substance of the muscle, and during the active stage of the disease is attended with pain. If, however, the abscess is of considerable dimensions it may prevent the use of the anterior shell and a posterior one may have to be substituted for it. In early cases the psoas contraction yields to sustained traction, but in old neglected contractures the shortened tissues may have to be divided by open incision, and the deformity thereafter corrected by forcible manipulation

In uncomplicated cases, recumbent treatment should be continued for six to eighteen months, when there is an abscess, or when psoas spasm is present, the period of recumbency should be prolonged.

Treatment of the Complications of Pott's Disease

The Abscess. In most cases of Pott's disease, an abscess is present at one time or another, but unless it is associated with pressure symptoms, or appears as a palpable tumour, its occurrence can only be presumed. It is more common in connection with disease in the lower parts of the spine, where the size of the vertebræ is relatively large.

The abscess consists of a central mass of caseous debris, with a limiting wall of granulation tissue The contents are often entirely

great mobility of the cervical spine compensates considerably for any local fixation.

Some method of extension should be used during the recumbent stage, and this is best carried out by weight traction. A leather strap is passed round the forehead and occiput, with a chin strap attached, and the whole apparatus is connected with a weight and pulley over the head of the bed; the usual weight required is two or three pounds. Should any lateral support be necessary, it may be supplied by means



FIG. 144.—Tuberculosis of the Spine. The treatment of Cervical Disease by means of box and traction.

The reading desk is shown at the top of the bed. It can be swung forward, and books, etc., held in position by rubber bands to allow reading without straining the eyes or the neck.

of a box enclosing the head and neck, in this case the straps pass to the pulley through the bottom of the box. Hyperextension is also easily obtained by placing a U-shaped pillow behind the nape of the neck.

Traction and recumbency are continued in this way for about nine months; the extension may then be released, but the cervical spine should be immobilized for a further nine months between sand-bags. When the tuberculous disease is actually situated in the occipito-atlantoid region a similar method of treatment is employed, but here the prognosis is not so good, since the disease is in close proximity to the vital medullary centres. Sudden death may occur from compression of the spinal cord, and abscess formation is a common and dangerous complication.

neighbourhood. The transverse process is then cut through at its base and removed after its costal attachment has been divided. The medial end of the rib is now lying in a periosteal tube attached only by its head, and it is removed by combined twisting and traction Occasionally the removal of the rib opens the abscess cavity, but if it does not, the tunnel should be explored gently with the finger, and when the wall of the abscess is located it is opened with a blunt instrument. Where more than one rib is resected the neurovascular bundle between the two is encircled with a double ligature, tied in two places, and divided

Occasionally also when more than one rib is removed a longitudinal incision in the line of the costo-transverse joints may be employed with advantage

Costo-transversectomy has certain advantages · it attacks the main cause of the paraplegia, the abscess cavity, and by emptying the abscess reduces the pressure on the cord and the toxicity of the focus. Drainage of the material after costo-transversectomy is away from the cord—not around it as after laminectomy The operation does not weaken the bony spine. The technique is not difficult, nor is there any great operative risk. A relatively large canal is formed through which it is possible to evacuate not only fluid pus, but granulation tissue, bone sand, and caseous material. Any further collection of pus that may form after costo-transversectomy will come to the surface at the site of operation.

Lumbar Region. Abscesses in the lumbar and iliac regions are deeply situated and rarely call for specific treatment; indeed, 70 per cent are spontaneously absorbed. If they become superficial they are aspirated

In the event of their becoming secondarily infected, evidences of toxic absorption may arise; in that case the gravity of the case is greatly increased, and the abscess must be opened forthwith A vertical incision is made along the lateral border of the sacro-spinalis, between the last rib and the crest of the ilium. The dense fascia is divided, to expose the quadratus lumborum The muscle is split longitudinally to the lateral side of the transverse processes, the lumbar arteries being carefully avoided. The contents are evacuated and the cavity drained

The Paralysis.

The occurrence of paralysis is evidence of the activity of the disease, and absolute recumbency must be ensured immediately, along with fixation and traction, or hyperextension In early and mild cases, especially in children, this is sufficient, but in adults, operation must be seriously considered Mme Sorell does not advocate operation; she finds that, in early cases, the large majority are relieved by conservative measures, whereas in a majority of the late cases, the condition persists even after operation.

Girdlestone, on the other hand, whole-heartedly advocates opera-

liquefied; the fluid is then of a creamy colour, with pieces of cheese-like material floating in it In the absence of secondary infection, the fluid is sterile.

At any stage an abscess may become stationary, and later be absorbed. Occasionally it appears early, and grows rapidly, in which case the disease is usually an acutely destructive one

The more usual history is that the swelling slowly increases in size, and under the influence of tension and gravity follows the line of least resistance towards the surface of the body Its course may thus be directed by fascial planes, muscle sheaths, nerves, or vessels The treatment of abscess by injection is fully considered in the chapter on Tuberculosis of Joints.

Active Treatment of Abscess in Various Situations.

Cervical Region Abscesses in connection with cervical disease usually become evident in the retropharyngeal space, and, to avoid their pointing and rupturing into the septic pharynx, they should be evacuated from the neck Two methods are available.

(1) The abscess may be aspirated through a needle inserted behind the posterior border of the sterno-mastoid. This is the better method, provided the contents are not too thick to be drawn through the aspirator.

(2) Should aspiration not be feasible for any reason, the abscess must be evacuated by open operation. A vertical incision is made behind the sterno-mastoid muscle, care being taken to avoid the accessory nerve The transverse processes of the vertebræ are exposed between the sterno-mastoid and the splenius capitis and levator scapulæ muscle, the abscess is located by following the anterior surface of the processes. After the cavity has been cleansed with pledgets of gauze, the incision is completely closed. Abscesses from middle cervical disease usually point in the supraclavicular region, and there is no difficulty in their treatment by aspiration

Thoracic Region. Abscesses from thoracic disease rarely call for operative interference, though occasionally they may press on the respiratory tract, and give rise to dyspnœa of a spasmodic nature. If this spasmodic dyspnœa is frequent and severe, it may be wise to evacuate the abscess contents by costo-transversectomy.

Costo-Transversectomy. *Operative Technique* The operation is performed on the left side A transverse incision, 7 cm. in length, is made over the vertebral end of the rib corresponding to the apex of the gibbus The rib is exposed, and the periosteum carefully elevated on the superficial and deep surfaces. The rib is then divided with nibbling forceps 4 cm from the tip of the transverse process of the corresponding vertebra, great care being taken to avoid perforating the pleura If a hole is made in it, and this can easily be done, it is closed temporarily with a swab until the whole of the rib is removed Attempts are then made to stitch the pleura using a free graft of fascia from the

completely, but only over the area in which the laminæ are to be removed A wide portion of each lamina is then excised, until sufficient bone has been removed to relieve all pressure. The spinal dura is not opened, but the debris is evacuated from the sides or the front of the theca Two identical grafts—the so-called "twin" grafts—about three-eighths of an inch wide are now cut from the tibia with an electric saw. These are laid, one on either side of the central portion of the spine, with their periosteal surface deep; it may be necessary to make the grafts flexible by means of a series of transverse cuts if there is much angular curvature. When the graft has been placed *in situ*, the edges of the supraspinous ligament, carrying with them the flakes previously detached from each spinous process, are sewn together over it. The patient remains on the plaster shell for three or four months.

In the operation of spinal fusion many now use multiple cancellous grafts from the iliac crests These probably have greater osteogenic power and produce fusion more quickly. The author favours this method

In the presence of paralysis, the greatest care is necessary to avoid the formation of bed sores, and the onset of troublesome contracture deformities Massage is contra-indicated, however, as it is likely to irritate the affected nerve centres and augment the paralysis.

The Gibbus.

To the patient, the most important feature of Pott's disease is undoubtedly the deformity, and, though the surgeon should recognize that it is only a symptom, a good deal of consideration should be given to the possibility of correcting it, in view of the mental distress for which it is responsible Ideally, the treatment of spinal tuberculosis should seek to prevent the development of a gibbus, but this ideal is difficult to realize The reduction of an established kyphosis is difficult, and should not be rashly undertaken In this connection, it may be stated that deformities of relatively short duration respond better to remedial measures, while the most favourable situation is undoubtedly the middle segment of the spine—the middle and lower thoracic vertebræ—as there a greater amount of leverage can be exerted on the deformed vertebræ Correction of the gibbus is really a misnomer, since we tend rather to hide or camouflage the deformity by making compensatory curves below and above it. To open out a curve formed by collapsed vertebræ might well reactivate the disease and would certainly delay it enormously since healing must be by co-aptation of the neighbouring vertebræ

Methods of Minimizing Angular Deformity.

Only gradual methods can be considered sufficiently free from danger to warrant their employment These are instituted after the acute stage The rapid correction of tuberculous deformities under anæsthesia stands utterly condemned

The gradual methods in common use are

(*i*) *The Whitman Hyperextension Frame* as described (p. 311).

tion in paraplegic adults, whether the paralysis appears early or late. He aims at relieving the cord compression, by costo-transversectomy, by laminectomy, or by both, and in addition, performs a twin-graft-fixation. Costo-transversectomy is carried out particularly when a spherical, or nearly spherical, prevertebral abscess is shown in the X-ray film, for this appearance suggests that a collection of debris is being held up under considerable tension by the prevertebral fascia, and, since it has been unable to escape upwards or downwards, has tracked backwards and compressed the cord

Jones and Lovett recommend operation when the paralysis is of long duration, and especially when sensory symptoms are present. Whitman insists on eighteen months' conservative treatment before operative interference is considered

The choice of operation lies between:

1. Costo-transversectomy, to evacuate the abscess.
2. Laminectomy.

After the laminectomy, Girdlestone inserts a graft to bridge the opening and compensate for the loss of bone tissue.

1. Laminectomy and Bonegrafting. (Girdlestone.) The operation is carried out with the patient lying on a plaster shell The incision is made slightly to the left of the mid-line to keep the scar away from the spinous processes The spines are now exposed, and

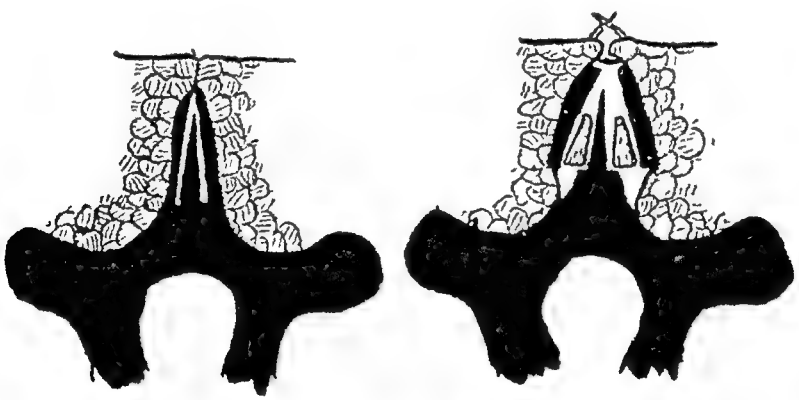

FIG 145 —Tuberculosis of the Spine Girdlestone's modification of Albee's Arthrodesis of the Spine (After Girdlestone)

Over the area of pressure lamination is done by removal of the laminæ at the base of the spinous process

an incision made over their apices, and carried by a dip of the knife from the spine through the interspinous ligaments over the required area Two saw-cuts are next made into each spinous process; these cuts pass forwards and slightly laterally to right and to left, and lever two thick flakes of bone laterally from the lateral aspects of each spine. An osteotome is then used to separate these lateral flakes completely from the central portion; they are carried laterally along with the periosteum of the posterior surface of the laminæ, exposing the laminæ

so was given up. But with the protection from such things as dissemination and sinus formation such operations are now successfully carried out with gratifying and quick results. It is highly improbable that antibiotics can reach the tuberculous area, especially if of any duration, as the surrounding fibrosis of attempted healing forms an impenetrable barrier This is one of the main reasons for opening up the diseased area.

Cases showing clinical and radiological evidence of activity are subjected to operation Evidence of activity includes abscess formation, clinically or radiologically confirmed, poor general condition, or a rise of sedimentation rate. Operation is considered even though there is no sign of abscess

Removal at an early stage of toxic products from large abscesses and bone lesions should improve the possibilities of controlling the disease. Nor are other tuberculous manifestations any contra-indication except in extreme cases Skeletal tuberculosis should be treated before lung or urinary disease In this way the patient's power of resistance is increased and better conditions are ensured for continued chemotherapy of lungs and kidneys respectively. In cases of slight changes and without noteworthy clinical symptoms the progress is watched before interfering

1 *The Radical Operation* The surgical approach to the diseased area varies with the localization of the lesion. In the upper cervical spine a postero-medial incision is used ; in the lower cervical spine the incision is made in the supraclavicular region.

In spondylitis of the thoracic spine the vertebræ are exposed by costo-transversectomy The transverse process is chiselled off and about 5 cm of the rib is excised According to the extent of the process, two or three ribs are excised

When an abscess is present it is usually entered after the rib has been excised The rib is often found to be destroyed by direct contact infection from the abscess In some cases the abscess is not found until blunt dissection with the finger has been made along the side of the vertebral bodies In the cases without abscess blunt dissection is also made, whereupon the lesion can be reached The lesion is entered from the side on which the abscess shadow is largest and most bulging, or if this can not be ascertained, from the side where the destruction in the bone is most marked, and where it opens at the surface of the vertebral body

In cases of lumbar spondylitis the operation is done by extraperitoneal exposure, in the beginning by large muscle split incision, but, because of the difficulty of access in many cases, a change may be made to an incision as for nephrectomy with cutting through the abdominal muscles and, if necessary, resection of the twelfth rib By this large extraperitoneal exposure a good view is obtained of the psoas region and of the anterolateral parts of the lumbar vertebræ At operations on the right side the access is rendered difficult by the vena cava.

(*ii*) *Wedge Block Method.* Good results can also be obtained by this simple method; the gibbus may be improved, and certainly compensatory curves can be produced above and below the kyphosis, which effectively mask the deformity in the event of its incomplete correction.

The patient lies prone, and a series of wedges are introduced to support the upper part of the trunk to the required extent (Fig. 146). The effect of the wedges can be enhanced by arranging a pad over the gibbus and pulling it against the kyphosis by tapes attached, over the head of the bed, to weights. At the same time a counter pull can be applied to the spine above the level of the gibbus by traction strings which pass over the shoulders, and are attached to weights at the lower end of the bed The patient is kept in this position for the



Fig 146 —Tuberculosis of the Spine The first stage in correction of a Low Thoracic or Lumbar Kyphosis

greater part of the day, and the wedges supply a convenient means of leverage in straightening out the deformity. In old cases where the gibbus is rigid, and there is no "give," a considerable æsthetic improvement is obtained by the production of compensatory lordotic curves This is well demonstrated in Fig. 122, where the posture of the body has been greatly improved, despite the fact that the gibbus is still prominent

The great risk of forcible corrective methods is the separation of partially healed opposing surfaces, with consequent delay in "cure." While it can be truly said that no method is absolutely immune from danger, the evil potentialities are, in the author's opinion, reduced to a minimum in the above procedures.

Operative Treatment.

The approach to the treatment of tuberculosis of bone and joint has materially altered in the last decade and operations of a curative nature, as opposed to stabilization, that would have been highly dangerous before, are now possible with antibiotics. Removal of tuberculous foci was attempted years ago but usually with a high mortality and

makes the modern operation possible and relatively free from danger, especially dissemination and the production of sinuses.

2. Spinal Fusion. It has for long been recognized that some form of "internal splint" which effectively controls or prohibits the movements of the spinal column would be a reasonable and rapid method of attacking Pott's disease Indeed, it may be said that the spine is ideally constructed and situated for the adoption of such procedures, since the joints can be easily and completely arthrodesed without intruding on the actual area of disease—i e. an ideal extra-articular fixation can be carried out.

When the spondylitis is already on the way to healing, as a result



Fig 147.—Tuberculosis of the Spine The second stage of Correction of a Kyphosis The pulley and weight traction is applied now

of conservative measures the graft may contribute considerably to the stabilization of the defective spine, and to the maintenance of the result already achieved Following the necrotic process, subluxations in the intervertebral joints certainly result from the dislocation of the bony fragments This, no doubt, leads to seriously altered statics in the whole vertebral column and to manifestations of insufficiency of the muscular and ligamentous apparatus, with pain We must admit, however, that the juvenile organism is able to adjust itself to even a very severe deformity over a very long period of time, although increasing manifestations of fatigue appear ultimately. These are often interpreted as indications of recurrence of the tuberculous inflammation, whereas they are, as a matter of fact, merely signs of static insufficiency.

When a psoas abscess is present it is easily found and usually yields a tract directly to the vertebral lesion If it does not do so, or when no abscess is present, the lateral parts of the vertebræ are exposed, and, if necessary by the aid of radiographic examination with indicator, the bone lesion can be attacked before it has broken through the cortex.

Irrespective of the site of the lesion the subsequent operative procedure is as follows ·

The abscesses are thoroughly drained and the tuberculous granulations removed The sinus tracks are followed, so that no gravitation abscesses are overlooked. No attempt is made, however, to remove the whole wall of the abscess The outer abscess membrane is left intact. Histologically it may be regarded as the body's defence zone against the tuberculous process and as such it is of value.

For the same reason, the aim is not to perform a complete resection of the bone lesions in healthy bone tissue. Such a resection would also involve great technical difficulties Sequestra of bone and of intervertebral disc tissue are removed. If it is difficult to see the bone cavity, one has to use a spoon to make sure that most of the diseased tissue has been removed. The procedure is completed by washing with physiologic saline solution, by which some further sequestra and granulations may appear. Slight diffuse bleeding cannot be avoided, but this usually ceases after washing with hydrogen peroxide In those cases in which a radical evacuation of the lesion is thought to have been ensured and in which internal fixation is considered to be of value, the cavity is filled with bone chips from the iliac crest Streptomycin powder is applied both in the bone cavity and in the abscess, and the wound closed by primary suture

Pre- and post-operative orthopædic treatment. Immediately after the diagnosis has been established and the decision to operate has been made, the patient is placed in a plaster bed When the patient has got accustomed to lying day and night in the plaster bed, the operation is carried out There is no necessity to wait until the disease has reached a more favourable stage, but the operation should be performed as soon as possible in order to eliminate the adverse effect of toxic products that are present in abscesses and bone lesions

After operation the patient is immobilized in the plaster bed for some months In uncomplicated cases the patient is then allowed to be ambulant wearing a plaster jacket, which usually after four to six months is exchanged for a corset When the process is considered to have healed, light physiotherapy may strengthen the muscles of the back and eliminate the need of an external support

In cases of recurrence of sinuses or abscesses the patients are kept in the plaster bed until healing of the sinus is achieved

All operations are carried out under an anti-biotic cover. This means that anti-biotic drugs are prescribed for several days before the operation, if they are not already being administered. This is what

It aims at inducing ankylosis at five distinct points: viz. the lamina and the articular process on each side, and the spinous process in the mid-line.

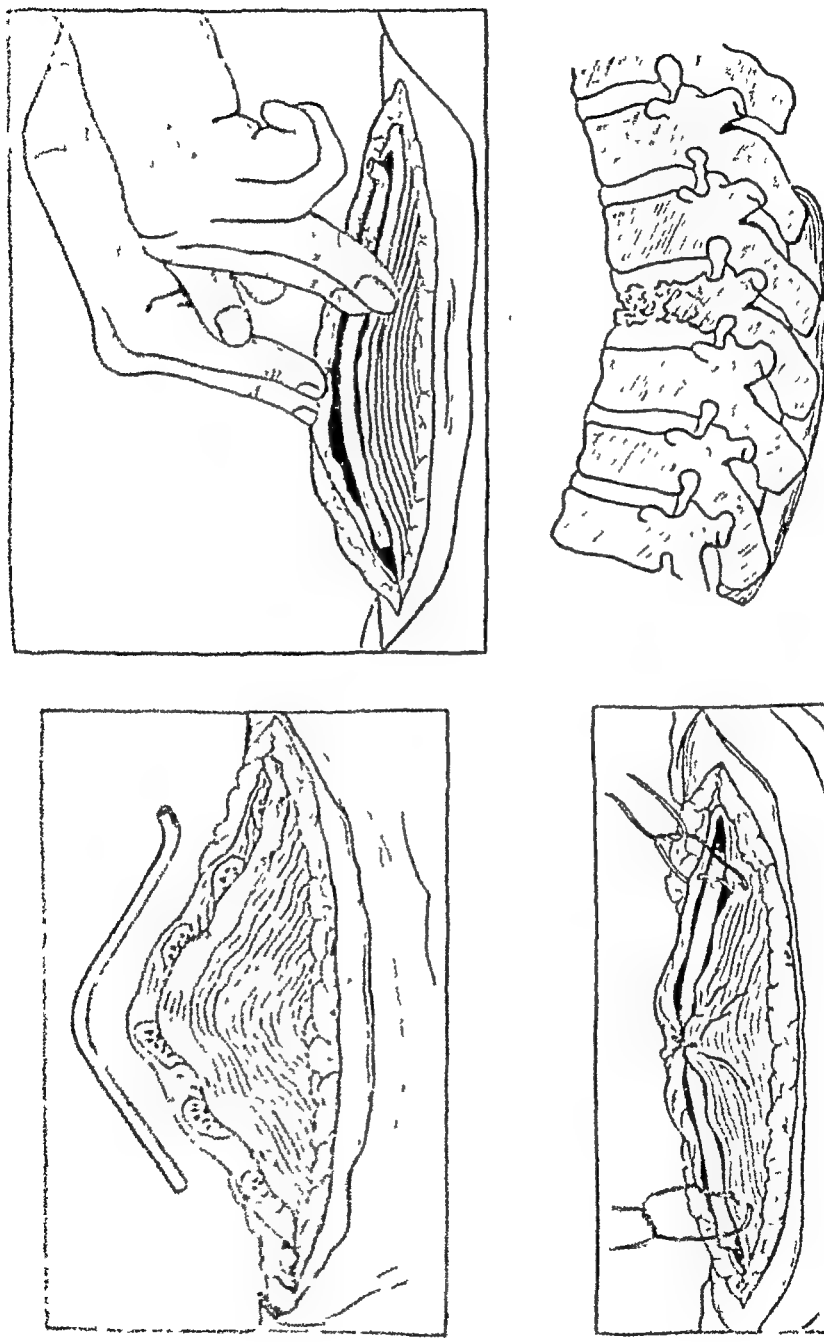

FIG. 118.—A series of diagrams to illustrate the stages of Albee's operation for Immobilization of the Spinal Column

The following is an account of the operation:

A longitudinal incision is made directly over the tips of the spinous processes; it passes through the skin, supraspinous ligament and the periosteum. The periosteum is split over both the upper and lower

In such cases operation does seem to be indicated, but it is directed towards the relief of symptoms and not against the disease itself.

Indications and Contra-indications for Operation. In Albee's opinion, the main indications for operation are:

1. Pain.
2. Muscle Spasm.
3. Increasing Deformity.
4. Abscess Formation.
5. Paraplegia.

Actually it is usually carried out when the activity of the disease has ceased and healing is in progress in cases where deformity might be expected in the absence of further support, and also to expedite healing and to make it more certain. It is most useful in the thoracic region as lumbar disease usually heals well without the assistance of internal grafts.

Operation is contra-indicated where there is secondary infection with high fever. In all operations, and especially where there is no gibbus to mark with certainty the site of disease, it is advisable to have a localizing radiogram done by using a piece of metal over the supposed site and marking it with a scratch in the skin.

1. Albee's Operation. It is Albee's technique that is most usually followed in performing the operation of spinal fixation. It is certainly attended with less shock, and can be more quickly performed than that of Hibbs, but the graft is comparatively rigid, and while to some extent it can be adapted to the curvature of the spine—by rendering it flexible by means of a series of transverse saw-cuts—yet in the presence of marked angular deformity it is unsatisfactory.

The following details are taken from Albee's original description:

"Through a curved incision the spinous processes are exposed, the supraspinous and interspinous ligaments are divided longitudinally, and the spinous processes split in half nearly down to the neural arches; one half of each spinous process is fractured completely at its base and displaced laterally. The graft bed thus prepared presents a median longitudinal gutter, into which a graft of sufficient length, which has been removed from the tibia by a motor saw, is placed. The graft may be curved to fit the gibbus by sawing a series of transverse cuts on its narrow side. The graft is immobilized by sutures of kangaroo tendon or catgut, and the supraspinous ligament, muscles and fascia are sutured over this. The graft should be sufficiently long to include at least two vertebræ above and two below the site of the disease."

2. Hibbs' Operation. This operation has the advantage of materially decreasing the external deformity, and can be used regardless of the extent of the gibbus. It is also more likely to be followed by a strong periosteal reaction with a subsequent deposit of new bone, and ultimately by a greater degree of fusion.

Brittain described his operation as follows.

"The aponeurosis covering the erector spinæ is incised on each side of the spinous processes throughout the length of the wound, the incisions being separated by ½ inch The laminæ are denuded of muscle by elevators on each side, as in the operation by Hibbs The spinous process in the lower angle of the wound is cleared with an elevator on each side and also on its inferior aspect. The processes are divided at their base with bone forceps, starting with the most inferior and proceeding up the wound, the interspinous ligaments and the aponeurosis being left attached. They are reflected upwards in one attached piece at the upper angle of the wound. The laminæ, which have been cleared laterally as far as the lateral vertebral joints, are roughened with bone elevators. It may be desirable to remove the cartilage from the lateral vertebral joints also. Where possible, the periosteal surfaces of the laminæ are raised up, but are left attached to the laminæ at the outer margin of the wound. The lower half of the bases of the spinous processes are removed and the chip grafts are poured into the prepared bed throughout the length of the wound Their disposition is important They should be placed fitting accurately with each other and with transverse grafts on the weak points between the vertebræ, as a bricklayer places his bricks The processes are then replaced and the aponeurosis carefully sutured on each side, thus enclosing the grafts in their bed and supplying an extra layer of bone on the superficial aspect It might be said that the 'lid' is put on the box"

After Treatment

After all these operations the patient is placed in a previously made plaster shell in which he is immobilized for at least six months Thereafter a plaster jacket is worn for a similar period.

The operative treatment of spinal tuberculosis is in high favour in America and a high percentage of successful results is recorded In 90 per cent of Hibbs' cases, the disease was apparently arrested, while Albee reported 92 per cent. of successes. In this country opinion is more guarded, and the operation is reserved, with but few exceptions, for adult cases

TUBERCULOSIS OF THE SHORT LONG-BONES OF THE HANDS AND FEET

The short long-bones of the hand and foot—the metacarpals, metatarsals and phalanges—are frequently the site of tuberculous infection during childhood The condition is alternatively known as tuberculous dactylitis, or spina ventosa, the latter in virtue of the aching pain (spina), and the spindle-shaped swelling (ventosa)

The disease becomes increasingly uncommon after the age of five. Up till then, the bone demands a lavish blood supply, which is provided by the large nutrient vessel, but after that age, the nutrient

borders of the spines and laminæ, and stripped back on either side to the base of the transverse process.

The joints at the base of the transverse processes are now destroyed, by curetting their opposing cartilaginous surfaces. The adjacent edges of each lamina are now bared of periosteum and ligament, and, with a gouge, small portions are elevated and arranged to form substantial bony contact The lower piece from the lamina above is turned downwards to make contact with the lamina below, while the upper flake from the lower is turned up to establish contact with the upper lamina.

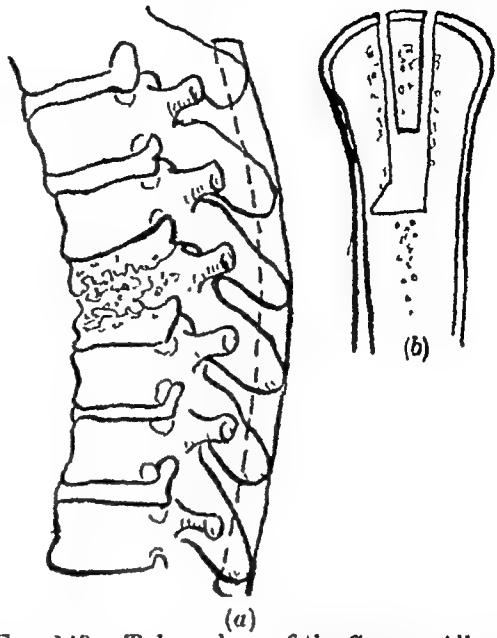

Fig 149 —Tuberculosis of the Spine Albee method of Spinal Fusion.
(a) The graft *in situ*
(b) The method of insertion

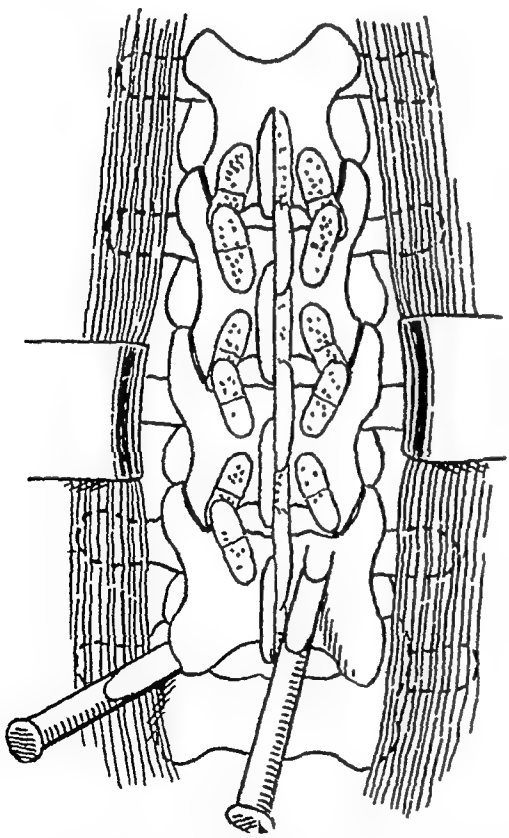

Fig 150.—Hibbs' Method of Arthrodesing the Spine

Each spinous process is now incompletely fractured at its base, and turned down to come into apposition with the fresh bone of the spinous process immediately below. The entire sheath of periosteum and split supraspinous ligament is now brought together over the processes, sutured with strong catgut, and the subcutaneous tissues and skin approximated.

3. Multiple Graft Method of Brittain. This method is useful in the thoracic area, especially if there is much kyphosis, making the fitting of a single graft difficult. The grafts are cut from the anterior surface of the tibia by a series of parallel cuts one-twelfth to one-eighth of an inch apart, and the long strips are cut into lengths of about 1 to 1½ inches.

vessel gradually diminishes, and with it the liability to tuberculous inoculation of the marrow.

The disease usually affects more than one bone, and not infrequently its distribution is symmetrical. The hand is rather more frequently involved than the foot. The interior of the bone is converted into tuberculous granulation tissue, the lamellæ being absorbed, or forming sequestra. Successive layers of new bone are deposited below the periosteum as the disease extends in the interior. Should the tuberculous debris penetrate the shell of new bone, a superficial cold abscess develops.

Clinical Features

A fusiform or spindle-shaped swelling gradually becomes apparent in the situation of one of the short long-bones. The swelling is not associated with any great degree of disability, but occasionally is painful.

After persisting for a considerable time, it may gradually recede, and the condition be spontaneously cured More commonly, a cold abscess forms which gradually erupts on the surface, with the formation of one or more sinuses, usually on the lateral aspect of the fingers. Such sinuses are apt to prove intractable, and discharge of pus and sequestra may continue for a long time.

Healing is apt to be followed by deformity, in the nature of shortening or contracture.

On radiological examination, the affected bone appears expanded; there is a deposit of new sub-periosteal bone, and the centre of the shaft is occupied by a cyst-like cavity.

Diagnosis

Tuberculous dactylitis must be distinguished from:

(1) *Syphilitic Dactylitis.* Here the new bone formation is more abundant; the Wassermann reaction is positive, and there are usually other evidences of specific infection.

(2) *Multiple Central Enchondromata* There is little or no new bone deposit, and the enlargement is less likely to be fusiform

Treatment

The outlook in tuberculous dactylitis is good; the parts react well to the usual immobilization treatment.

In the hand, fixation is easily secured by anterior and posterior splints, which enclose the whole hand and are held in position by adhesive strapping

When the foot is infected, a plaster of Paris case is applied for six months or longer to control both the foot and the ankle. When multiple sinuses are present, it may be advisable to amputate the digit, since a quicker cure results. The great toe must always be treated along conservative lines, its retention is all-important for the later function of the foot.

Fig 151 —Tuberculous Dactylitis of the 3rd Metacarpal

Fig 152 —Tuberculosis of Bones (Boy 3 years old) Shortening of the middle finger, the result of Tuberculous Disease of the Metacarpal Bone

underlying bone, and at the same time, the capsule and tissues may be involved

Muscular spasm is a common accompaniment, so that the bone-ends are pulled together, ground and eroded The debris thus formed is the main constituent of the pus which is found in or around the joint Not infrequently a segment of bone becomes detached and forms a sequestrum.

Repair may occur at any stage, either spontaneously from the recuperative power of the patient, or initiated by appropriate treatment. Healing results in the formation of fibrous tissue from the granulations, leading to dense fibrous adhesions and ankylosis. The abscess may be acute or chronic, the latter being the so-called residual abscess, merely the debris of the burned-out disease.

Histopathology. In the early stages there is a collection of endothelial cells, surrounded by lymphocytes Giant cells are formed from the fusion of endothelial cells and surround the amorphous material Occlusion of blood-vessels, aided by the toxins, leads to disintegration and caseation Bacilli escape from this focus to form new tubercles, which in turn coalesce, and so enlarge the area of disease. When the active process subsides the tuberculous nodule becomes encapsuled but remains as a potentially active focus

Symptoms

The early signs are those of a chronic inflammation—an insidious mono-articular synovitis In addition to fluid in the joint there is swelling of the synovial membrane and the capsule, and the peri-articular structures are œdematous There is early and persistent muscular atrophy, and muscular spasm is also a characteristic symptom Pain is irregular, and when present may be referred to some distal part of the limb, as for instance the medial side of the knee in hip joint disease; it may be constant or elicited only by movement The early limitation of movement of the joint is a reaction to the pain, the muscles contracting to steady the limb Deformity, unless prevented by appropriate mechanical treatment, sets in early, and is caused, in the early stage, by muscular spasm, and later, by organic muscular shortening This muscular shortening, in addition to producing flexion, may cause an actual displacement of the bones, such as is so frequently seen in a tuberculous knee, where subluxation with backward displacement of the tibia on the femur occurs

Shortening of the limb is produced in two ways, either there is a retardation of growth in length, at the epiphysis, or, at a later stage, shortening from actual bone destruction

Albee states that the common manifestations of joint tuberculosis in the order of their appearance are stiffness; limitation of movement, alteration of position, pain, night cries, elevation of surface temperature and tenderness, muscular rigidity and spasm; swelling, muscular atrophy, alteration in bony outlines; and abscess formation.

CHAPTER VI

TUBERCULOSIS OF JOINTS

Infection of a joint with tuberculosis is nearly always secondary to an infection of some other area, usually the lymphatic glands at the root of the lung or in the mesentery The lymphatic disease is the primary lesion, and, in most cases, more dangerous than the joint lesion, since it is deeply seated, not susceptible to radical treatment, and easily overlooked. The infecting organisms are either the bovine or human type of the tubercle bacillus These can be differentiated as a result of animal inoculation, although the lesions they produce are identical. In infection of the human type, introduction may be by inhalation. The drinking of infected milk and the ingestion of infected butter are responsible for the bovine type which is commonest in children.

Etiology

Tuberculous arthritis is chiefly met with in childhood, the great majority of patients being under 14 years of age. There is frequently a history of trauma which may determine the site of infection, but cannot be considered an important antecedent Direct hereditary transmission is rare The more probable event is infection of a susceptible child from without

Pathology

As a rule there is a primary infection of lymphatic glands from which the bacillus spreads by the blood-stream or the lymphatics to the synovial membrane or the bone A mild septicæmia may ensue An injury near a joint may lead to infection of the epiphysis with subsequent joint implication Symptoms suggestive of joint disease arise when the synovial membrane becomes inflamed.

In the bone, a small collection of tubercles is found, and these are seen microscopically to be made up of endothelial cells with, as a rule, a few giant cells The process extends towards the joint and at the same time circumferentially, the bony trabeculæ being eroded. There is in the early stage a non-tuberculous synovitis, but the synovial membrane soon becomes thickened, hyperæmic, and studded with tubercles. Granulations spread from the synovial infection over and under the cartilage, with resulting ulceration and exposure of

of the synovial membrane, and an irregularity of the joint outline. The later films show clearly a gross destructive lesion of the joint with absorption of bone, loss of continuity of the joint, and dislocation With healing there is gradual replacement and condensation of bone, but any gross deformity persists

(4) **Wassermann Reaction.** In all doubtful cases it is the rule to exclude syphilis by the Wassermann reaction.

(5) **Exploratory Arthrotomy.** An exploration of the joint should be regarded as a last resort, though there is no doubt that it is a justifiable procedure in adults and, in the writer's opinion, in children. Microscopically, there is marked similarity to syphilis which must always be remembered, and indeed, a certain histological diagnosis may be impossible. The tissue, however, may be cultured or a guinea-pig inoculated.

(6) A biopsy of the regional lymph nodes where possible is often useful. The inguinal gland may show evidence of tubercle in a doubtful knee joint.

Differential Diagnosis

Acute pyogenic arthritis is distinguished by its sudden onset, subsequent clinical history, and radiological appearance.

Syphilis is similarly differentiated, a positive Wassermann reaction is helpful.

Epiphysitis may present great difficulty, but it gives a very distinctive X-ray picture.

Prognosis

Once the joint is invaded, complete restoration of function is unlikely, so much so that, when perfect cure results, the diagnosis is open to doubt But though the joint function may be greatly disturbed, the danger to life is not serious if treatment is efficiently carried out. Where death ensues, it is usually due to secondary infection or some other complication The mortality, which is comparatively low, is greater in spine and hip cases, and less in the upper than in the lower extremity.

Treatment

The treatment must be both local and general It may be conveniently discussed under four heads—(*a*) general, (*b*) local, (*c*) operative, and (*d*) the treatment of complications

(a) **General Treatment and Chemotherapy** (see p 307)

Rest, liberal diet, and hygienic surroundings are essential.

Heliotherapy is scientific treatment by light-rays. In this country, for obvious reasons, dependence is placed chiefly on artificial sunlight. It is claimed that, by its judicious use, physiological functions are stimulated, muscular tone restored, the bones strengthened, and cir-

In addition to those local signs there are some of a more general nature. The patient's health suffers and he fails to gain, or actually loses, weight, growth is retarded, and there is pyrexia. Pain and loss of sleep account for some of these constitutional signs, but the pyrexia is an indication of toxæmia due to active disease.

Complications. The most frequent complications are abscesses, secondary infection of sinuses, and tuberculous meningitis. Secondary infection is the most common late complication, and gives rise to increased fever, night sweats, and wasting. The prolonged suppuration leads to waxy disease.

Diagnosis

The only positive evidence that a joint infection is of a tuberculous nature is the identification of the organism from the joint or its neighbourhood, the histological identification of the disease in tissue from the joint, or the reproduction of the disease by the inoculation of a guinea-pig with material from the joint

Various methods may be used to establish the diagnosis of tuberculosis in chronic arthritis, any one of which may be misleading. Nevertheless, by making use of all of them, a correct diagnosis may be achieved.

(1) The Guinea-Pig Test. This is the most convenient method when there is fluid available for inoculation. It is obviously better to inject two guinea-pigs in every case. In arriving at a conclusion, distinction has to be made between the case with an actual infection of the joint and a symptomatic synovitis from a para-articular focus; the fluid from the latter is sterile The guinea-pig test, then, is decisive only when the result is positive, whereas a repeatedly negative result does not preclude tuberculosis.

(2) The Tuberculin Test. A positive Mantoux test is of significance only in the first three or four years of life, after which 50 per cent of the population give a positive reaction. On the other hand, Sundt points out that a negative Mantoux reaction does not preclude active bone or joint tubercle. He says that the only convincing proofs are, firstly, the absolutely negative result of all tuberculin tests, including the subcutaneous up to an injection of 10 mgm. of old tuberculin, and secondly, a focal reaction that, both objectively and subjectively, is undoubtedly positive. The focal reaction is not devoid of danger, however, and it is doubtful, too, whether it is specific.

(3) Radiographic Appearance. There is no picture that is entirely typical of joint tuberculosis in any of its stages, but the following points are at least suggestive At an early stage, the X-ray examination is usually negative The earliest sign is decalcification of the bones related to the affected joint. Later signs are a localized area of diminished density in the bone, an increased joint space, thickening

Subsequently, careful supervision is essential until a reasonable certainty of cure is established

(c) Operative Treatment.

In the majority of cases, conservative treatment is the method of choice, but certain conditions definitely indicate operation The duration of the disease tends to be shortened thereby, though interference with joint function is more likely to result

The operation of excision may be advisable in a destructive lesion in an adult, but it is not attended with favourable results in the young child, chiefly because the disease is usually more extensive than is shown in the radiogram and therefore excision of a considerable area of bone is necessary. This would naturally interfere with growing epiphyses and lead to a shortening of the limb in later years A more direct attack upon the tuberculous area in the joint is now advocated in many cases, along with the administration of anti-tuberculous drugs It is believed that because of the surrounding fibrosis and the ischæmia from endarteritis the drug cannot reach the joint in sufficient concentration Partial capsulectomy and synovectomy removes tissues in which the circulation is defective These structures re-form easily and quickly and revascularization occurs in the tissue kept healthy by streptomycin so that the drug obtains access to the subchondral bone on which the integrity of the joint depends Wilkinson has shown the success of such a method of attack He operated on 26 children's hips and lost the function of only four joints On the other hand, this method is not successful in adult joints owing, he thought, to the poor state of the cartilage

In addition to excision of tuberculous joints there are important extra-articular forms of operation, whereby a joint is fixed by means of an internal splint without any damage to the joint-tissues which are the site of the disease These operations, which are described elsewhere, are carried out more frequently in diseases of the spine and hip.

(d) Treatment of Tuberculous Abscesses.

A residual abscess is more easily cured than an acute one The tendency in the treatment of both is to be conservative, and a considerable number of abscesses disappear under this treatment A more active therapy is indicated when there is tension of the skin, or where pressure is being exerted on vital parts

Aspiration. It is sometimes possible to effect a cure by repeated emptying of the abscess A wide-bore needle is inserted obliquely through healthy skin and pushed on until it enters the abscess cavity, the contents of which are removed by aspiration Before withdrawing the needle anti-tuberculous drugs are injected After withdrawal the puncture is sealed with collodion The method may be repeated and if the pus is fluid enough its removal and the drug injection may effect a cure But in many cases the content cannot be aspirated and so a more radical attack is nowadays justified

Chemotherapy has its greatest value in restoring to tuberculous tissues their powers of healing and thereby allowing tuberculous abscesses

culation and respiration improved. The degree of pigmentation induced is an index of the efficacy of the treatment, and it is said that even a negro becomes darker if the response is satisfactory.

Although light treatment is so important, it must not be forgotten that fresh air, and especially exposure to fresh air, is almost as beneficial In many of the cases, tuberculin is used to improve the natural immunity. A small quantity of 5–10 per cent. Moro's ointment rubbed into the skin once a week may be useful in children.

(b) Local Treatment.

The local treatment includes reduction of deformity, traction, fixation of the joint in the desired position, and protection until the healing is complete.

Reduction of Deformity. It is of the utmost importance to secure the limb in such a position that, should ankylosis supervene, the greatest possible functional utility will be attained. Attention must therefore be directed to the reduction of any deformity, and to the fixation of the joint in the desired position. A flexed knee, for instance, must be more or less extended, and a dropped wrist dorsiflexed. This reduction is commonly effected by gradual traction. The pull, made at first in the line of the deformity, is modified in direction as the stiffness diminishes, until the desired result is secured. Rapid reduction, under an anæsthetic, a method known as "Brisement Forcé," is to be deprecated on account of its risks.

When the deformity is reduced, a decision must be reached on the ultimate aim—a stiff, painless joint, or a movable one? The prognosis will be based on the extent of the disease as shown by the radiogram.

When the bone is diseased a stiff joint is probable, though sometimes, after a long period of fixation with ankylosis in view, a surprising degree of movement remains. The joint is encased in plaster of Paris, except in very young patients or in those with sinuses, and in order to obtain complete immobility, the plaster case should include the joints on both sides of the affected one. The duration of this treatment depends on many factors—age, site of disease, etc, but a minimum period of six months is indicated. In certain joints a splint may be used as an alternative during this period, e g. the Pyrford frame in hip cases.

When the disease is mainly synovial, with little affection of bone, a movable joint should be the aim. The extent of movement will depend on the length of adhesions between the joint surfaces, hence the object of treatment in these cases is to keep the surfaces as far apart as possible by means of traction, which is more frequently used in the lower limb. The duration of treatment in this phase is approximately the same as in the fixation stage and lasts until there is no evidence of active disease and healing is far advanced or complete.

The last stage is that of protection, care being taken to guard the joint against injury. During the first few months of this stage, the patient is confined to bed, but finally ambulant treatment is employed.

upwards by the muscles acting on the head, giving rise to the so-called "wandering" or "migratory" acetabulum.

At a later stage, the pus which has formed bursts through the capsule, and spreads in the lines of least resistance. It may point in the groin, in the neighbourhood of the great trochanter, or, by perforating the acetabulum, appear as a pelvic abscess.

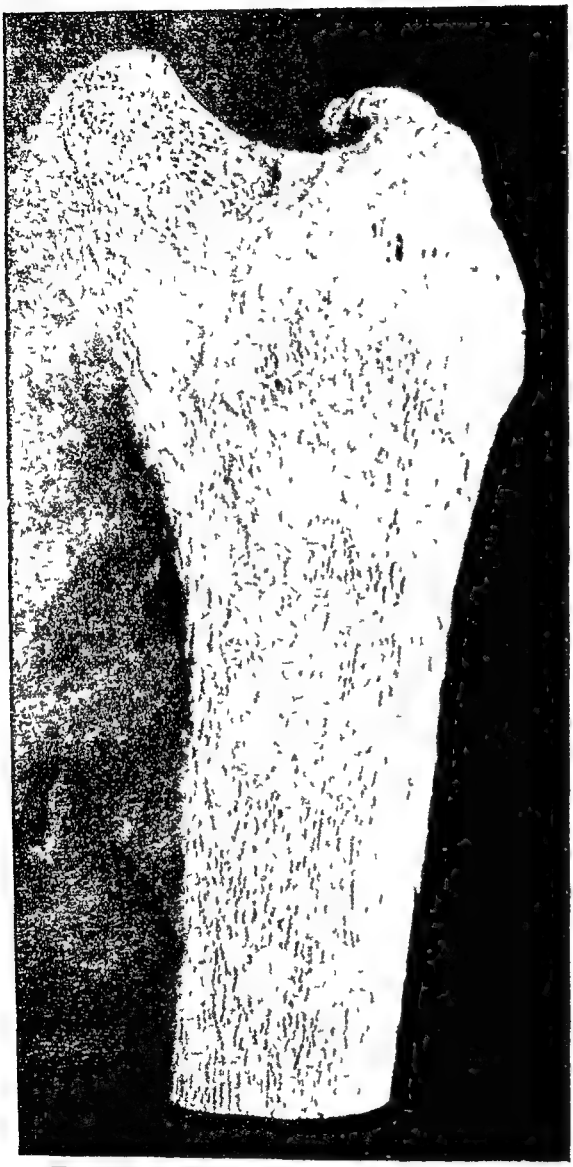

FIG. 154.—Tuberculosis of the Hip Joint

The disease has resulted in complete destruction of the femoral head and the proximal portion of the neck

If left untreated, healing may take place eventually by absorption, and connective tissue encapsulation, but there results much distortion, deformity, and ankylosis of the joint.

SYMPTOMS

The disease is insidious in its onset and chronic in its course.

As a rule, before definite signs appear, there is evidence of malaise, the child being pale and apathetic and the appetite poor. One of the first symptoms is stiffness of the limb which is present on first getting out of bed, but passes off during the forenoon; it returns, however, on a subsequent day and causes the child to limp. Both stiffness and limp tend to persist more and more. Pain may be absent in the early stage, or, when present, be referred to the knee. Later the child begins to cry out during sleep, though, on awaking, there may be no complaint of pain. This cry is elicited by the so-called "starting-pains" caused by the friction of the two diseased surfaces whose movement is permitted by the muscular relaxation that sleep produces. The symptom signifies ulceration of the cartilages of the joint.

Among the symptoms of general debility, loss of weight and evening fever are often noted. Should an abscess form, the pyrexia will be

to be treated under the ordinary principles of surgery. The abscess is opened and thoroughly evacuated along with any sequestra present. If, as often happens, there is a tract down to bone, the bone may be curetted and soft unhealthy bony debris removed Bleeding is controlled by packing for a short time. Should there be a large bony defect it may safely be filled with cancellous bone chips from the iliac crest. Streptomycin and penicillin are left in the area and the wound closed up Systemic cover is continued with the appropriate antibiotic drugs

TUBERCULOSIS OF THE HIP JOINT

As a rule, tuberculous disease affects the hip joint before the age of 10. Its incidence is less than that of spinal disease, the ratio being about 7 to 10. In over 4,000 cases admitted to East Fortune Sanatorium the hip was involved in 18 per cent. of the cases of bone and joint lesions. It is slightly commoner in males The infection, as with all tuberculosis of bone, is invariably secondary to a primary site elsewhere in the body.

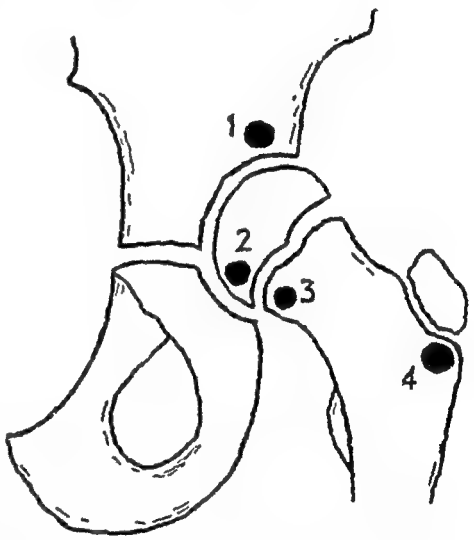

Fig 153 —The Four Bone Sites of origin of Tuberculosis of the Hip Joint

Pathology

The usual initial bone site of the disease is in the upper part of the acetabulum or in the so-called Babcock's triangle, i e. the lower half of the neck of the femur near the epiphyseal line or in any of the other three sites noted in Fig 153, but it may be synovial in origin In the neglected case the sequence of the pathology is as follows.

When disease begins near the epiphyseal cartilage of the head of the femur—a place where the circulation is active and the growing bone less resistant—an area of infected granulations forms, which spreads towards the joint. These granulations extend gradually over and under the cartilage, which they ultimately destroy, and finally attack the bones comprising the joint. In the early stage there is a simple effusion but the fluid soon becomes infected with tubercle and the whole joint is invaded by the disease The synovial membrane becomes thickened, œdematous, grey and ulcerated, and the bones, denuded of their protective cartilage, are eroded, and sequestra may form As the disease progresses, the head of the femur is partly absorbed, the remnants being dislocated from the acetabulum on to the ilium, where a false joint is formed. This is constantly pushed

leg is carried, and the attitude is now one of flexion, adduction, and medial rotation, with apparent shortening. As the bone becomes eroded and wasted, the real shortening supervenes, and increases as the dislocation of the head of the bone develops There is, in addition, retardation of growth from disturbance of the epiphysis.



Fig 156 —Multiple Joint Disease in adolescence

Palpation corroborates the findings of inspection

The range and freedom of movements are determined by comparison with those on the sound side, and are limited in all directions. In the early stages this limitation can be more easily detected if the child is placed in the prone position and attempts made to carry out the movements of hyperextension and medial and lateral rotation of the hip These are markedly less than on the sound side

Thomas's flexion deformity test is carried out The good knee and hip are flexed on the abdomen and the child is asked to lay his affected leg flat on the table. If he cannot do this actively or with slight assistance then there is a flexion deformity present and the test is positive.

Records are taken of the degree of atrophy and of the amount and type of shortening In estimating the shortening, attention is directed to the distances between the anterior-superior spine and the tip of the medial malleolus, and between the latter point and the umbilicus Comparison is then made with similar measurements on the opposite side.

Radiographic Examination. At an early stage nothing abnormal is noted. The earliest sign is a slight haziness due to synovial œdema In a few cases, owing to its excessive thickness, it is possible to delineate the synovial membrane, above and below the head. With great effusion the ends of the bones are farther apart than on the sound side. As bone atrophy develops, the affected side gives a thinner shadow, and, still later, an area of destruction is seen, most commonly in Babcock's triangle, on the inferior aspect of the cervical side of the epiphysis.

Finally, when the cartilage is eaten away, and more and more bone eroded, the joint outline disappears The erosion is most marked on the upper hemisphere of the head and the upper part of the acetabulum. These erode each other, leading to dislocation, with a "migratory acetabulum."

more marked. At a later stage pain and deformity, coupled with general weakness, preclude walking. The general health deteriorates rapidly when abscesses form, especially if sinuses result

Sir Robert Jones described three types: (1) a rapid severe type which is acutely painful and rapidly destructive, (2) the usual type with moderate pain but no great general disturbance, and (3) a slowly progressive form with little pain, marked deformity and stiffness, going on without grave bone change for many years. The last type is very resistant to treatment

Physical Signs

Lameness is one of the first signs In the early stages it is caused by stiffness or flexion deformity, the body bending forwards

Fig. 155 —Tuberculosis of the Hip
A severe case showing the adduction flexion deformity and the lordosis

to compensate for inability to extend the hip Later a further limp is produced by pain, the child hastening to take the weight from the affected side Lastly, there is the limp from real shortening.

Inspection. The examination should be carefully carried out with the patient undressed, and the general effect of the illness may sometimes be seen in the pallor and emaciation. The affected thigh may be visibly wasted, the atrophy extending to the gluteal muscles. The deformity, and the resulting limp, are now obvious, differing according to the stage of the disease. In the early stage there is flexion, abduction, and lateral rotation, to increase the joint capacity and relieve tension on it, and also to lessen jolting on walking There is apparent lengthening of the leg The flexion at the hip abolishes the normal gluteal fold. As the disease progresses, the joint is unable to tolerate any strain, so that crutches become necessary, the

Subacute mono-articular arthritis of the hip is not uncommon in children. If non-tuberculous, it will disappear after a few weeks' rest The child should be examined every fortnight for a few months.

Hysteria is recognized by the variability of the symptoms, the marked hypertonus of the muscle, and the absence of wasting.



(a)



(b)

FIG 158.—(a) An old healed Tuberculous Hip Joint, with flexion-adduction Deformity and a considerable degree of Shortening

(b) The lordosis is obliterated and the amount of actual flexion deformity is now evident

Upper neurone lesions exhibit spasm which is gradually overcome by pressure There is no wasting and usually there are signs of the disease in other parts of the limb.

In reflex irritation, as from inflamed glands or injured adductors or phimosis, limitation is not general as in hip-joint disease.

2. Abscesses in the Region of the Hip. It may be difficult to

The diagnostic value of radiography is not great in the early stages of this disease—and indeed negative radiographs do not exclude tuberculosis—but is useful at a later stage in indicating the site and severity of the lesion.

In children the Mantoux intradermal test is a valuable procedure in that a negative result will count against tuberculosis, but it is only in young children that a positive result can be considered of any particular value The test should be tried with 1 1,000 dilution and if this is negative repeated with 1 · 100 dilution.

Wassermann Test. If syphilis is suspected a serum test should be carried out A positive Wassermann does not necessarily mean a

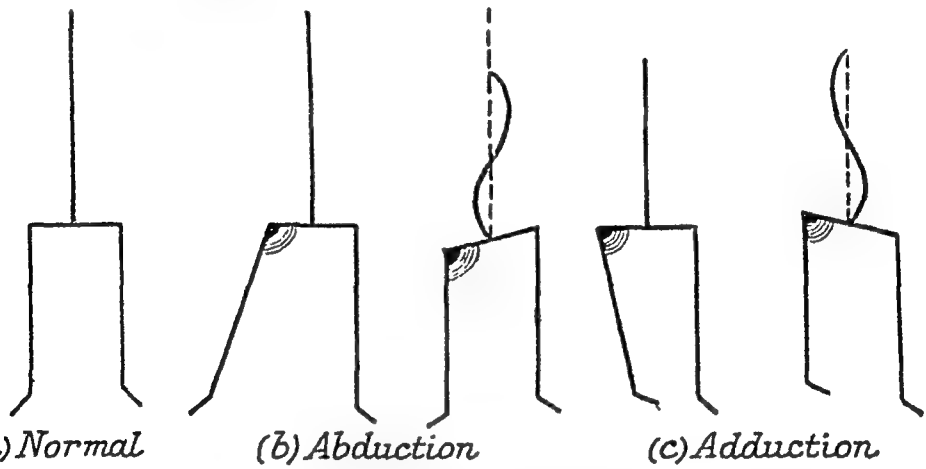

FIG. 157 —Tuberculosis of the Hip

Diagrammatic representation of the effects of a fixed joint in abduction and adduction When abducted the pelvis is tilted to permit of the legs being parallel, with an apparent lengthening When adducted the tilting produces apparent shortening The spine flexes laterally to allow the head to assume its erect position and scoliosis results

syphilitic arthritis—a very rare condition. It signifies activity of the virus which must be taken into account in treatment.

DIAGNOSIS

The diagnosis is made from the history, the symptoms, and from the physical examination, including the radiograms The results of the tuberculin tests can never be taken as final, and a definite diagnosis can be made only by the discovery of tubercle bacilli in the fluid or tissue from the joint It may be necessary to inoculate a guinea-pig and note the results

DIFFERENTIAL DIAGNOSIS

Various diseases may simulate a tuberculous hip. These may be grouped under the symptoms they produce, viz limitation of movement, abscess, limp and pain.

1. Limitation of movement, in tuberculous disease, is caused by spasm of muscles and is observed, therefore, in every direction.

of the femur is in an abnormal position, and certain movements are increased in range. A radiogram is decisive.

(*b*) *Coxa Vara.* Lateral rotation is increased and there is marked deformity. X-ray examination is of the greatest value.

(*c*) *Pseudocoxalgia* (Perthes' Disease). Many examinations may be required before a diagnosis can be made in this condition. There is less muscular wasting in Perthes' disease, while the radiogram will show more bone changes, which in the early stages of a tuberculous hip are few. In Perthes' disease the movements are not limited in all directions as in tuberculosis.

FIG 160 —An Early Case of Synovial Disease
Note the decalcification especially marked in Babcock's area

4. Pain in the region of the hip may be the predominant symptom in the following diseases

(*a*) *Osteomyelitis* The main features in this disease are local tenderness and toxæmia A differential white blood count shows a polymorphonuclear leucocytosis , in tubercle there is a lymphocytosis

(*b*) *Slipped Epiphysis* The pain, eversion, shortening, and absence of wasting are suggestive. X-ray examination at once reveals the nature of the condition

(*c*) *Poliomyelitis* has a more sudden onset, often arising during an epidemic ; the muscles are markedly hyperæsthetic and tender In a few days the joint can be moved freely in all directions.

trace these to their source. If acute there is little difficulty ; if subacute the possibility of hip disease must be considered. The result of treatment, and the examination of pus from the abscess, should be specially noted If the abscess is tuberculous, it must be differentiated from a tuberculous infection of the subgluteal, or psoas bursa, in which

FIG. 159 —Tuberculous Focus in the Acetabulum.
Activity of the disease is seen in the fluffy outline, decalcification, and the cavity in the acetabulum

the limitation of hip movements is not general. It is in these cases that a complete X-ray examination is likely to be of diagnostic value.

3. Limp. Lameness may be due to several conditions

(*a*) *Congenital dislocation* of the hip is present from birth, the head

when the cure has been established. The most important part of the conservative treatment is, of course, that with antibiotics (see Treatment of Pott's Disease, p. 307).

2. Local Treatment.

This will vary according to the extent of the disease. If it is advanced, there is probably some deformity present, usually a combination of flexion and adduction, from strong muscular contraction. Before further treatment can be initiated, this deformity must be corrected and any pain that is present alleviated. If the patient is seen before pain and deformity have developed, curative treatment is commenced at once.

(*a*) **Stage of Acute Symptoms.** When the patient is suffering acute pain in the joint, is unable to move without great distress, and is frequently wakened at night by pain arising from friction between the inflamed joint surfaces, no treatment gives speedier relief than traction applied to the limb by means of webbing, strapping and bandages. Plaster strapping is often preferable to the less stable webbing. It gives a more certain pull and requires less adjustment, though it has the disadvantage of being more irritating to the skin. After the application of the extension strapping, the limb is placed in a Thomas's knee splint to steady it and ensure extension in the proper direction. The actual pull on the extension may be by a weight led over a pulley at the foot of the bed, or by the "Spanish windlass" method, which acts by the twisting of the two lateral extension cords, already looped over the end of the splint, with a small lath of wood. If the weight method is used, the amount required is approximately one pound for every year of age, the foot of the bed being raised so that a counter-extension is formed by the weight of the body. To steady the pelvis and to prevent compensatory movements of adduction of the other leg, a long Liston splint is applied to the opposite side of the body.

The correction of the adduction during the period of treatment by traction is occasionally complicated by the development of a genu valgum, owing to the traction exerted by the lateral pull on the medial collateral ligament of the knee joint. This complication is prevented by a special method of incorporating the traction plaster in a plaster-of-Paris mould extending to the mid-thigh. The method is seen in Fig. 163

The actual degree of deformity is estimated, in the first place, by getting rid of the compensatory tilting of the pelvis from lordosis, and by the abduction of the opposite leg, the traction being then arranged to pull in the line of the deformity This direction can be adjusted by fixing a Thomas's splint to wooden uprights and cross-bars fixed to the bed.

The extension pulls on the opposing joint surfaces, thereby abolishing the spasm of muscle, which causes flexion adduction, providing rest, relieving pain, and correcting deformity Each day this traction is inspected and its direction modified, and in a few weeks the deformity

area in which the sequestrum lies is then exposed by a suitable ion. The involucrum is identified and peeled off the sequestrum a blunt dissection. If the sequestration has extended beyond limits of the original gutter, the involucrum should be incised itudinally at either end by a knife or osteotome, and the sequestrum ly extracted. Granulations should not be curetted. If it is still ble enough, the involucrum should be forced to collapse, so that cavity left may be made as small as possible. If the sequestrectomy been too long delayed and the involucrum has become hard and rosed, it may be desirable to supplement the evacuation of the uestra by an operation of the type discussed in the succeeding section If the extent of the disease is great, operation may leave an involum so weak and fragile that it will be unable to support the limb. this event the limb should be carefully supported after the operation a plaster-of-Paris case or by some alternative method of splinting, d this should be continued until the newly formed bone is sufficiently rong to bear weight or withstand muscular traction. Radiograms, y demonstrating the amount of new bone formation, are the most ficient indicators of this stage.

Treatment of Bone Cavities. The history of the case with bone avities is depressing, there is continuous or intermittent suppuration nd sinus formation with acute exacerbations, followed by re-operation nd further disappointment. The patients relate, more in sorrow than n anger, how they have been operated on or scraped ten, twenty, or it may be thirty times, and they illustrate their story by pathetic little collections of fragments of necrosed bone which have been collected as melancholy souvenirs of this prolonged discomfort. These cavities are prevented from closing because their walls are unable to collapse in the way that soft tissue cavities collapse and heal.

Before operation on a bone cavity, a clear picture of its location should be obtained by stereoscopic radiograms, both antero-posterior and lateral, after the injection of lipiodol. Methylene blue injected into the sinus tracts aids a block excision

The obstacles to healing found in chronic bone cavities are the incollapsible deep walls, the avascular fibrous and infected tissue in the neighbourhood, and the presence of sequestra in the cavity. The operation to deal with these elements is a sculptural procedure designed to ensure the complete removal of devitalized bone, etc, and so to alter the contour of the remaining bone that natural healing may take place.

Preliminary Penicillin or other chemotherapeutic drugs. In the chronic stage of osteomyelitis penicillin has not proved so brilliantly successful as in the acute stage, mainly because of the difficulty of getting the drug to the part One of the most important characteristics of the lesion is its poor blood supply. The sequestra and much of the scar tissue are avascular and therefore beyond the reach of any chemotherapeutic agent carried in the blood stream, and accordingly it is little use to treat a case of chronic osteomyelitis with penicillin unless it is combined

that is not often thought of is the development of malignant disease. Benedict recently collected twelve personal observations of the formation of cancer in old cases of osteomyelitis. Most of the cases had had a discharging sinus for thirty years The growth is always an epithelioma, and the prognosis after amputation is said to be good.

Unusual expressions of osteomyelitis

Osteoid Osteoma, so named by Jaffe, is a benign bone lesion of slow growth It starts with a proliferation of the local bone-forming mesenchyme and particularly its osteoblasts. It is most commonly



FIG 96 —Extensive formation of bone

seen in the second and third decades of life, and males are affected twice as commonly as females The principal complaint is pain, varying from a mild degree to one of great severity It is intermittent at first but becomes more constant It is localized usually to a small area on the surface of the affected bone—this small area on examination is tender, often œdematous, and with the periosteum palpably thickened, but the skin is not reddened. The neighbouring bone shows considerable reaction It affects most commonly the long bones

The X-ray picture has two aspects—the manifestation of the osteoid osteoma proper and that of the reaction which it has set up in the surrounding tissue A typical X-ray picture shows an area about 1–2 cm in extent the centre of which shows small areas of rarefaction and condensation. This is surrounded by a narrow area of condensation which in turn is succeeded by a zone of rarefaction. The surrounding

pedicle which leaves the transplant viable All abnormal tissue—sinus tracts and infected granulation tissue, sequestra, eburnated or abnormal bone, are removed radically so that all remaining tissue appears normal and has a good blood supply. Where the cavity is a deep one with high walls these are gouged or nibbled away to convert the cavity more into the shape of a saucer—hence the name sometimes used of saucerization.

Primary closure of the skin and superficial fascia over the wound should be done even if it is necessary for the operator to make a relaxing incision on one or both sides of the original wound. Finally the limb is placed in a plaster-of-Paris case and kept in a somewhat elevated position for three to four days. In shallow cavities saucerization may be sufficient to produce healing, but in most cases more is required and there are two ways in which the cavity may be filled up.

(*a*) *Muscle filling.* The bone defect, if shallow, may be obliterated by slight displacement of surrounding muscles; if deep, a muscle pedicle is formed, the gap filled and the flap sutured into the defect.

(*b*) *Bone-chip filling.* The cavity is filled with cancellous bone chips from the ilium in those cases where muscle tissue is not available for filling. This method is often done in two stages, the first step being the complete excision of infected and avascular tissue as described. The cavity is then lightly packed with gauze wrapped round a Carrel-Dakin tube. Through this penicillin solution—2·4 c c containing 500 units per c c —is instilled every four hours The penicillin is locally useful now that the avascular surroundings have been excised. In ten days' time when the defect is covered by a thin layer of healthy granulation tissue the second stage is carried out. Cancellous chips are removed from the iliac crest and the iliac wound closed and dressed The bone defect is now exposed and gently irrigated with normal saline and the surrounding skin prepared with ether and alcohol The grafts are placed in the defect till it is filled. The soft tissue and skin are closed with, if necessary, relaxing incisions and the part immobilized in plaster

Since osteomyelitis affects the growing ends of long bones it is to be expected that there may be some effect on growth. This has been investigated by Sergling who examined 241 cases of long-bone infection and found 5 per cent. showed overgrowth, 31 per cent growth arrest, and in 64 per cent. growth was undisturbed. Seventy-eight per cent. of the cases of shortening had their initial disease in the upper femoral epiphysis. Infections in this region have the gravest significance, therefore, not only in respect of the immediate mortality but also in the ultimate prognosis.

Am[illegible] for Osteomyelitis.

[illegible]litis, especially when affecting the trigone of the femur, may [illegible] that are uncured, and, indeed, incurable. The only [illegible] such cases, the author believes, is amputation. The [illegible] compensated for by the remarkable improve- [illegible] untoward development in very chronic cases

TUMOURS OF BONE

The subject of "Bone Tumours" is confused because there has been failure between pathologists, radiologists, and clinicians to agree upon a generally acceptable terminology.

1. In response to injury, infection, or in consequence of maldevelopment or hormonal disturbance, localized overgrowth of bone, cartilage, or fibrous tissue may occur These lesions present as bony swellings and the clinician has by custom (and, for many reasons, convenience) described these as "Tumours" although they are not, in a pathological sense, neoplasms Such "tumours" are self limiting, yet structurally they have a similar appearance to true neoplasms The old nomenclature used the terms "osteoma" or "chondroma" for such lesions and, hallowed by tradition, the practice has continued.

2 In bone there are not only cells concerned with the formation and the maintenance of the calcified osseous structure—the truly "osteogenic" tissues—but many other elements are present—marrow (hæmopoietic) tissue, fat, nerves, blood vessels, and, forming a sheath over the surface of the bone, there is a condensation of fascia (fibrous outer layer of the periosteum). Further, certain tissues are included within bony spaces and canals—teeth, epithelial linings of air sinuses, the notochord From each of these structures tumours may arise and again by custom they are often described as "Bone Tumours".

3. The presence of bone in a tumour is not of diagnostic significance and the term "osteogenic" has, in consequence, been frequently misused

(*a*) In certain tumours ossification may be a function of the tumour cells and in such instances these cells can be regarded as neoplastic osteoblasts. It is correct, therefore, to employ the terms osteoma, or osteosarcoma, or osteoblastic-sarcoma.

(*b*) Ossification within the stroma of a neoplasm may arise consequent upon local changes in the calcium metabolism and circulation, but in such cases it is usually possible to differentiate between the true tumour cells and those which are in juxtaposition to the new bone spicules and by which the bone is obviously formed The same phenomenon is of frequent occurrence in many mesoblastic tumours completely dissociated from bone formation, as for example the true fascial fibroma or the uterine leiomyoma

(*c*) A further difficulty arises from the reaction of the normal tissue adjacent to the tumour—especially a malignant one. As the result of increased vascularity, or by pressure of the tumour in a direction perpendicular to the normal lines of stress on the trabeculæ there may be marked absorption There may be mechanical compression of the blood vessels with consequent ischæmic necrosis and sequestrum formation. Thus around any tumour there may be seen decalcified osteoid tissue, necrosed bone and multinucleated giant cells (osteoclasts) removing the debris.

(*d*) In addition to the destruction there is frequently beneath the periosteum new bone formation which is reactionary in type. The

bone is sclerosed to a varying depth. The area is often just beneath the periosteum but may lie in the cortex. If situated deeply the overlying bone shows considerable sclerosis. If incompletely removed it [illegible]

At operation the osteoma appears as a mass of [illegible] friable cancellous-like bone, the cut surface [illegible] flecks mixed with pearly grey osteoid. [illegible] consists of vascular richly cellular enlarged type of [illegible] nective tissue representing all the elements [illegible] ment of membranous bone from the [illegible] fully formed fibrous tissue. In the fibrous [illegible] osteoid, calcified osteoid, and atypical [illegible] osteoblasts and osteoclasts. The [illegible]

1. The sclerosing non suppurative osteomyelitis of [illegible]
2. Brodie's abscess;
3. Osteogenic sarcoma, and
4. "Ewing's tumour"

Surgical removal of the lesion is all that [illegible] and lasting relief. The nidus and some of the [illegible] be removed with a curette but this removal [illegible] otherwise there is a danger of recurrence of the [illegible] care should be taken to pick out the symptoms [illegible] the nidus) for histological examination. [illegible] the primitive mesenchyme of osteogenesis [illegible] unsatisfactory here.

Sclerosing Non-suppurative Osteomyelitis.

This was described by Garré in 1893. It may [illegible] pyrexia, local pain and swelling, or more often it is [illegible] The temperature and soft tissue swelling subside but [illegible] persists as a dense fusiform swelling. Tenderness [illegible] of on deep pressure. It has been confused with sarcoma, and Ewing has stated that many sarcomata cured by amputation were examples of this lesion. By many it is attributed to spread from some undiscovered focus of infection. The long bones, particularly the tibia and femur, are the usual sites.

A typical X-ray shows a symmetrical thickening of the cortex with some narrowing of the medulla. The bone production is on the shaft. There is no involvement of the periosteum, no bone destruction, and no change in the soft tissues.

Where there is persistent pain operation of either guttering the bone or the drilling of multiple holes through both cortices may alleviate it.

This osteomyelitis of Garré is said to produce a temperature, apparently in that respect differing from an osteoid osteoma, but the later stages of the latter condition are remarkably like the Garré condition and it may be that they are both inflammatory in origin, though Jaffe considers the osteoid osteoma a true benign tumour.

	Cell Type predominating	*Simple Tumour types*	*Malignant*
B.	Chondroblast Tumour cells show active cartilage formation.	Chondroma	Chondrosarcoma
C.	Fibroblast Tumour cells show active collagen formation	Fibroma	Fibrosarcoma
D	Osteoclast Tumour cells show active bone destruction by giant cells	Osteoclastoma	Malignant osteoclastoma

2. *Tumours arising from Tissues normally found in Bone but not participating in Bone Formation.*

A Tumours arising from fibrous tissue, forming the non-osteogenic outer layer (fascial) of the periosteum—
- periosteal fibroma
- periosteal fibrosarcoma

B Tumours arising from the elements of bone marrow—
- myeloma
- reticulum cell sarcoma
- Hodgkin's disease of bone

C Tumours arising from blood vessels—
- hæmangioma
- hæmangioblastoma

D Tumours arising from adipose tissue—
- lipoma
- lipo-sarcoma

E Tumours arising from nerves

3 *Tumours arising from Included Tissues.*

4. *Metastatic Tumours of Bone.*

1. TRUE BONE TUMOURS

OSTEOMA[1]

A true osteoma, although rare, is found in the orbit, nasal sinuses, external auditory meatus, and the oral side of the mandible. This tumour is usually composed of tissue as dense and hard as ivory, and is frequently termed "ivory exostosis" It is usually small, sessile, single and grows slowly . its surface is smooth, but may be slightly nodular As it grows it tends to become more conical. When these tumours grow from the inner table of the cranial bones, they may cause pressure on the brain

[1] Descriptive terms commonly include the following:

(1) Osteophyte—when localized and tendritic, (2) Hyperostosis—when growth is diffuse, (3) Enostosis—when growth occurs into the medullary cavity, (4) Compact Osteoma—Osteoma Durum or Eburneum—when it is smooth and hard, (5) Cancellous Osteoma (Osteoma Spongiosum or Osteoma Medullare)—when it consists of soft, spongy bone, (6) Parosteal osteoma—when it occurs outside the periosteum, (7) Movable Periosteal Osteoma, or disconnected osteomas—when growing in tendon, muscle, or fascial planes, (8) Heterologous Osteoma—occurring in meninges, lung, diaphragm, parotid or skin

degree of this reaction varies, and is observed not only in association with tumours which arise primarily in bone but in metastatic lesions It occurs, for example, in secondary tumours of the prostate and in relation to the meningiomata. In part at least the "sunray" spicules observed in the osteosarcoma and the new bone laid down parallel to the shaft and called "Codman's triangle" by the radiologist is non-neoplastic reaction. A very striking example is the "onion layers" seen in Ewing's tumour which is in character typically a secondary neuroblastoma of adrenal origin.

4. Bone develops from primitive mesenchyme. From this by differentiation there develops a common immediate precursor of those cellular elements which are identified in growing and adult bone, the osteoblast, the chondroblast, the osteoclast, and the fibroblast. The ultimate offspring possess individually characteristic functions, the production of bone, of cartilage, the absorption of bone, or the production of collagen. The cells also possess in marked degree an ability to undergo a metaplasia in response to the differing physiological needs of the body and to trauma or disease. Indeed, some observers regard these cells not as specific types but as variants of one cell type serving temporarily different functions

In tumours derived from these cells the same power of metaplasia is commonly manifest, and accordingly within the same tumour widely different histological pictures are observed. Thus while the predominant feature may be cartilage formation, in other areas there may be well-marked ossification or only fibroblasts with collagen fibres In anaplastic tumours the de-differentiation may have been so marked that it is impossible to adduce the cell type from which it came—the pathological diagnosis being an undifferentiated sarcoma

A further important point has to be stressed The histological characteristics of a tumour do not indicate that the neoplasm has necessarily been derived from a specific and the same cell type. While the tumour may possess those features which warrant the name osteosarcoma, it cannot be assumed that it arose from osteoblasts. It may have done so, but equally it could be the result of neoplasia and metaplasia of other elements or from the parent mesoblast cell.

Classification of Bone Tumours

1. *True Bone Tumours.* Neoplasms arising from cells of mesenchymal origin, derived from a common ancestry and whose function is primarily skeletal bone formation. These tumours fall into four main groups according to the predominant cell type present. By reason of the mutability of the cells metaplasia is common and intermediate stages are found

	Cell Type predominating	*Simple Tumour types*	*Malignant*
A.	Osteoblast Tumour cells show active ossification	Osteoma	Osteosarcoma

along the fibrous tissue planes and septa, and the subsequent deposit of new bone is therefore rough, or irregular in shape, and elongated, in the long axis of the muscle amongst whose fibres it is being deposited.

Occasionally a similar effect may follow tears of tendon and muscle fibres, without actual damage to the periosteum. In such cases, the new bone laid down has, apparently, no continuity with the adjacent bone.

The inflammatory types are perhaps most commonly observed on the plantar aspect of the os calcis following plantar fasciitis. In this case, the periosteum is raised not by a hæmatoma, but by a mild inflammatory effusion, but the subsequent stages in the development of the calcanean osteoma or spur are similar to the traumatic type described above.

Fig 98 —Exotosis of the Lower End of Femur

Biotrophic Osteoma.

In structure and etiology such osteomata are identical with those occurring in metaphyseal aclasis. A process of bone develops projecting towards the diaphysis and capped by a detached fragment of epiphyseal cartilage. As the shaft of the bone grows in length the "osteoma" assumes an acute angle with the shaft and directed away from the epiphyseal plate The "osteoma" continues to grow, new bone being formed by the cartilaginous cap, but this growth ceases simultaneously with the fusion of the adjacent epiphysis or if the cartilaginous cap is removed. When fully developed, the marrow of the shaft is continuous with that of the cancellous tissue of the osteoma When fully formed, the osteoma consists of a shell of compact bone enclosing cancellous tissue, with a cap or tip of cartilage It is usually pedunculated, with a bulbous extremity It occurs during adolescence, never after the epiphysis has united, and boys are more frequently affected than girls The condition may be familial

These exostoses are commonest at the extremities of the bones, especially at the ends where the epiphyses are the last to join the shaft The lower end of the femur, the upper end of the tibia, and the upper end of the humerus are consequently the commonest sites

In the differential diagnosis from a biotrophic osteoma the clinical course is decisive but is of little importance as the indications for surgical interference are identical.

Exostosis. Bone may form due to abnormal growth or imperfect remodelling to an excessive degree in varying parts of the skeleton and to these a variety of names has been given depending on the site and etiology. These are not true tumours, as their growth will cease with the removal of the underlying cause or with cessation of general skeletal growth. The term "Exostosis" is used to differentiate such lesions from true neoplasms.

Irritative Exostosis results from lesions causing a proliferation of fibroblasts or granulation tissue in the neighbourhood of bone. A localized bony growth will appear because of ossification occurring in the inter-cellular substance of fibroblasts

Traumatic osteomata are most frequently observed in relation to the femur, beneath the quadriceps, in relation to the adductor magnus (the so-called Rider's Bone) or in relation to the medial collateral ligament of the knee joint (Pellegrini-Stieda's disease) The condition is also not infrequent at the elbow, the exostosis forming in the intermuscular planes of the brachialis following dislocation

Fig 97 —Exostosis of Tibia growing into the Fibula

Injury leads to the formation of a sub-periosteal hæmorrhage, the periosteum being detached by muscular traction. If the periosteum remains intact, the hæmatoma may become absorbed, but if the periosteal reapposition and the absorption of the blood clot are prevented by ill-advised movements or massage, the clot is invaded by mesoblastic elements and bone is laid down. The resulting exostosis in this case is smooth and firmly adherent to the bone.

If the periosteum ruptures, the blood escapes into and percolates

has been given. When much new bone is formed the terms, sclerosing or ossifying sarcoma, have been used descriptively.

The osteosarcoma is relatively rare, the incidence in Great Britain being 1 per 75,000 of the population. It may occur at any age period, but has a decided predilection for the second decade. In older individuals it is an occasional sequel to Paget's disease, and rarely to other osteodystrophies.

The tumour arises in the metaphysis where normally the growth is more active. The large majority are found in the lower limb, especially the lower metaphysis of the femur and the upper end of the tibia 52 per cent occur in the femur; 20 per cent. in the tibia; and 9 per

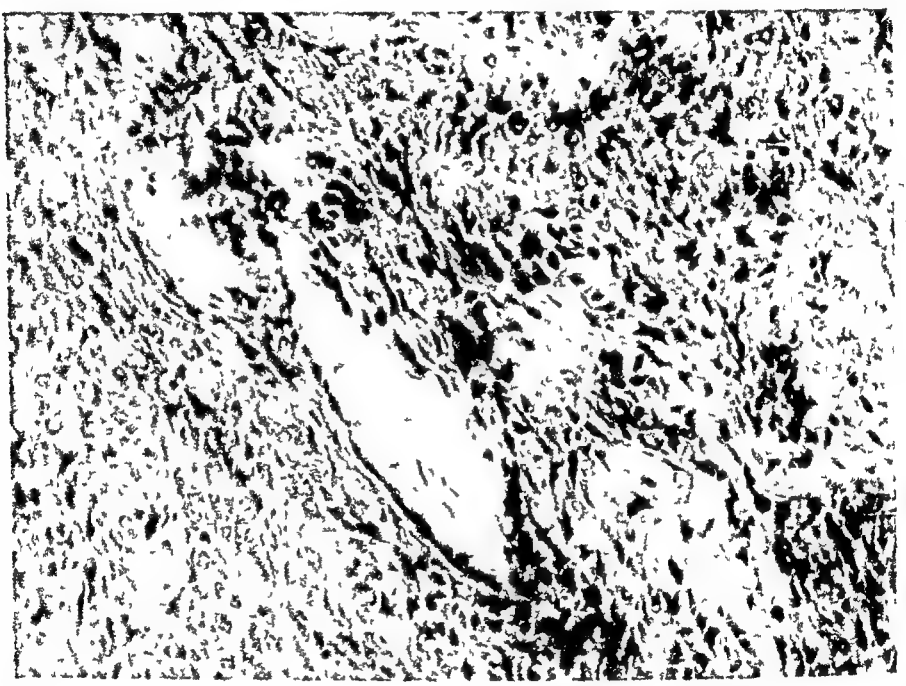

Fig 99 —(c) Microscopically the Tumour shows both Bone Destruction and New Bone Formation There is Pleomorphism and much Mitotic Activity

cent in the humerus. In the femur 82 per cent occur at the lower end and 9 per cent. in the greater trochanter; they are very rare in the head and neck. In the tibia 90 per cent affect the upper medial aspect. In the humerus the upper end is the most commonly involved, and it is very rare to find osteogenic sarcoma below the deltoid tubercle. Less usual sites are the radius, where it is extremely rare to find osteogenic sarcoma at the lower end—a common site for osteoclastoma; the ulna, where there is also an immunity of the lower end; the ilium and the scapula. For some reason the short long bones appear to be rarely affected.

The tumour initially may appear to originate beneath the periosteum or more centrally in the shaft of the bone, but there would appear to be no reason to assume that these constitute different types of tumour.

The summit of these growths is often covered by an adventitious bursa, and not uncommonly they interfere with the free action of muscles or tendons, or with the movement of joints. Exostoses are frequently found growing from the epiphyses of flat bones such as the scapula and the innominate.

(A) OSTEOSARCOMA

The term "osteosarcoma" is employed to designate those tumours which appear to arise from cells principally concerned with bone forma-

(a) (b)

FIG 99 —(a) Osteosarcoma of Femur Male aged 17 years (b) Showing pathological fracture

tion and in which this characteristic is maintained as a predominant feature of the neoplasm.

As in the case of the osteomata a variety of names have been applied to this neoplasm. These are essentially descriptive of some variant in appearance and are given here only to prevent confusion or seeming omission.

Myxosarcoma, pseudomyxoma and osteochondrosarcoma are self-explanatory terms. Where the bone absorption is predominant due either to the degree of vascularity or the malignancy of the tumour the terms telangiectatic or osteolytic sarcoma have been applied. In very vascular tumours with pulsation the name malignant bone aneurysm

be deposited layers of new bone arranged parallel to the shaft This area is triangular in shape and is usually referred to as Codman's reactive triangle

The consistency of the tumour is influenced chiefly by the degree of differentiation.

If the sarcoma grows rapidly and the periosteal reaction is weak, pathological fractures may occur. This at once provides an outlet for the expanded tumour and leads to its ultimate phase of infiltration of the soft tissues More frequently this phase is reached by perforation of the periosteal capsule The tumour then changes its line of growth and infiltrates the surrounding tissues in a centrifugal direction It then possesses a pedicle, passing through the perforation, and the fan-like structure is lost, the tissue having no evident arrangement. The muscles become stretched and atrophied until the tumour is eventually covered with glossy skin

Ulceration of the skin is rare but may follow operative exploration or biopsy Cartilage is even more resistant than the skin owing to its inability to be absorbed without preceding necrosis.

Histology

While the most frequently observed cell is small and spindle shaped and with a hyperchromatic nucleus, great variation in cell form is invariable. In shape the cells may be polyhedral or round or less commonly cuboidal or even columnar: they vary considerably in size, and the arrangement too varies, in some the spindle cells are arranged in bands as in a cellular fibroma, in others they assume palisade, alveolar or columnar formation and simulate epithelium The degree of pleomorphism is most marked in the extreme anaplastic tumours in which there are often giant multinucleated cells of bizarre shapes. Mitosis is usually well marked.

The intercellular substance may be scanty or considerable and in character may be myxomatous, cartilaginous, osteoid, or osseous, according to the degree of differentiation and metaplasia which are occurring. When there is rapid destruction of bone, cells of the osteoclastic type are found

The blood vessels are numerous and possess only thin walls The degree of vascularity varies within wide limits—in some instances being so extreme that during life the tumour may pulsate and simulate an aneurysm.

The formation of bone in these tumours would appear to proceed from the primitive malignant cell to ossified tissue directly, without any intervening stage of chondrification, but where cartilage is present in these tumours this too may become ossified

The histological picture varies not only between different tumours but also between different sections taken from the same tumour. Evans has put it truly thus, 'Different areas of the same tumour may show,

From its initial situation the tumour extends in two directions—(i) towards the medulla, and (ii) to the sub-periosteal area. In the medulla the bone trabeculæ are decalcified and destroyed, and the tumour appears as an irregular mass permeating the medullary cavity and frequently extending for a considerable distance along the medullary canal. At first the periosteum offers an impenetrable barrier and is only raised off the bone. Beneath the membrane the tumour may extend widely, ensheathing the bone and producing a fusiform swelling. The periosteal separation stops short at the attachment of the periosteum to the epiphyseal cartilage. Similarly the intramedullary part of the tumour does not transgress the cartilage of the epiphysis—a useful point in distinguishing it from an osteoclastoma.

FIG 100 —Osteosarcoma of the Head of the Tibia
The tumour is evidently affecting all the elements of the bone

The tumour varies greatly in appearance. It may be soft, fleshy and vascular, with areas of hæmorrhage and necrosis, or it may be greyish-white and solid when it contains cartilage or bone In the first type, there is little or no new bone formation, the tumour is largely a destructive one. The new bone may be arranged as scattered islands throughout the tumour which impart a gritty sensation on cutting, and that found beneath the periosteum is sometimes arranged at right angles to the cortex as a series of radiating spicules. To this arrangement is attributable in part the "sun-ray" appearance in the radiographs This peculiar arrangement is due to the vessels which pass perpendicularly from the periosteum to the cortex and along which the bone is laid down, and as already noted some of this new bone may be reactionary On the diaphysial side of the tumour, the periosteum is often stripped for a short distance, and here there may

and becomes stretched instead of infiltrated as in carcinoma. Dilated veins may be evident at an early stage

The size, shape, outline, and consistency of the tumour are well perceived on palpation Occasionally, when the periosteal capsule is thin, there is crackling In very vascular tumours a pulsation and bruit can be felt The rapidity of growth and the increase of size depend on the malignancy, but after the periosteal capsule has been perforated the rate of growth increases rapidly. Pathological fracture is not typical of osteogenic sarcoma, since the swelling and pain usually keep

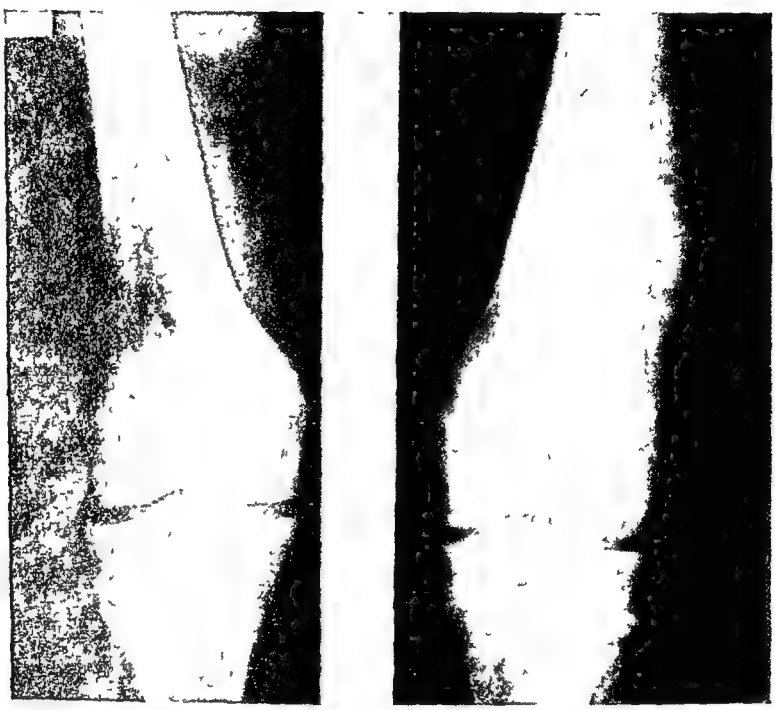

FIG 102 —Osteosarcoma of Femur, showing sun ray appearance.

the patient off his feet There may be some initial pain and effusion into the nearest joint, but movement is free and painless.

Later, general dissemination of the tumour takes place While the lymphatic stream occasionally plays a definite role, spread by the blood-vessels is predominant Pulmonary metastases are the most frequent The first clinical signs of these are usually those of a diffuse bronchitis, but occasionally the cough, dullness, fever and leucocytosis suggest a diagnosis of pneumonia

DIAGNOSIS

The early clinical feature of pain, especially about a metaphysis, in a young person not otherwise explained indicates the need for radiological examination. The X-ray appearances have been summarized by McWhirter thus:

(*a*) The sclerotic type, usually found at puberty, where dense new

when integrated, the complete range of structural variation exhibited by osteosarcomatous lesions."

These variations have in the past led to much confusion and a variety of names purporting to distinguish distinctive tumours have been employed. The continued use of these terms is to be deprecated.

Clinical Course

Pain, especially at night, is usually the first symptom and precedes the tumour by days, weeks or months. The pain is intermittent. It is due to the severe sensitiveness of the periosteum, and such pain in the long bone of a young adult should arouse suspicion of sarcoma. Less commonly there is only a tired feeling, and a slight limp.

A second common feature in the clinical history is trauma. History of trauma, however, is often unreliable, and suggested for purely mercenary reasons, moreover it is not difficult to connect any part of the body with the memory of some previous injury. Codman believes that trauma is the exciting cause of all osteogenic sarcomata, while maintaining that the particular trauma to which the onset is attributed by the patient is seldom the causal one. Sarcomata differ from carcinomata in that a single, rather than a repeated or more chronic injury, is liable to precede their development. In a large series of cases there are the most varied intervals, ranging from a few days to a year or more, between the trauma and the appearance of the tumour. The interval between the injury and the appearance of the pain or tumour is about one month in approximately one-third of all cases of osteosarcomata.

Fig. 101.—Osteogenic Sarcoma of Lower End of Femur. The dilated veins are notable.

The general condition is good until a late stage in the disease, although night pains may keep the patient in misery, and cause rapid deterioration. Occasionally there is pyrexia accompanied by leucocytosis. The clinical picture in the terminal stages is unlike that seen in carcinoma. The patients tend to become anæmic rather than cachectic, their haggard, pallid appearance is characteristic. The skin, too, reacts differently; it preserves its mobility and natural colour for a long time

This risk is, of course, increased where an exploratory operation is carried out prior to amputation.

Considerable argument has prevailed on the relative merits of amputation and disarticulation In amputation there is always risk that extension of the lesion along the bone marrow may be more proximal than suspected and diseased tissues thus left behind. It is therefore regarded as sound practice to prefer disarticulation. The same argument applies to local excision in these lesions and this practice has fallen into disuetude.

Cade and others have recently produced evidence of considerable weight that pre-operative radiation has a place in management and indeed that radiation therapy without amputation may give satisfactory results. The position, however, is still awaiting final judgement.

Osteosarcoma in Paget's disease

It has been estimated that in approximately 5–10 per cent of cases of Paget's disease sarcomatous changes occur While histologically the disease is similar to that arising *de novo* in younger patients, the neoplastic change takes place at a much later age—usually over 50 years The tumour is more diffuse in character and appears to arise simultaneously at multiple sites.

(B) CHONDROMA

A chondroma is a benign tumour arising from the cartilaginous elements of the developing bone It grows slowly, and is generally lobulated, and encapsulated by fibrous tissue Calcification frequently occurs in the fibrous septa dividing the lobules, while the intercellular matrix may undergo mucoid degeneration, particularly in the large chondromata which grow from the innominate bone.

Malignancy has been frequently reported occurring after the trauma of operation in incomplete removal. The usual sites of growth are the fingers, toes, sternum and ribs, more rarely the vertebræ and metaphyses of long bones, especially of the lower limbs It usually appears in the third decade and when malignancy supervenes it frequently does so after the age of 35.

Microscopically there is a chondroid matrix containing cartilage cells, encapsulation and lobulation are present, and calcification and mucoid degeneration are common.

The capsule is formed by vascular connective tissue which sends septa into the tumour substance, thus dividing it into lobules.

The arrangement of the cells is irregular and the fibrous content varies so that there is a mixture of hyaline and fibro-cartilage, and frequently elastic tissue The tumour may be lobulated by septa from the vascular connective tissue capsule The tumour grows by apposition of cartilage cells derived from the connective tissue perichondrium. When ossification does occur they are known as osteochondroma.

irregular bone occurs in the metaphysis and there may be a few spicules projecting from its surface.

(*b*) The osteolytic type—usually metaphysial. An eccentric translucent gap is found and at its edges a gradual increase of density to that of the normal bone

(*c*) The mixed type—usually metaphysial but frequently in the mid-shaft showing irregular areas of bone formation and absorption.

(*d*) Radiating spicule type—which is the least common, contrary to general impression This is usually found at puberty in the metaphysial region, the spicules being distinctive in that they are parallel and not radiating and each spicule does not taper but remains the same breadth from the base to the end.

The radiological diagnosis, however self-evident in the grosser cases, cannot be finally conclusive in the early lesion. To make a diagnosis involving such grave decisions in regard to treatment and of such serious prognostic significance demands a higher degree of certainty and accordingly histological proof is required. It has been held by some that biopsy increases the risk of spread of the disease The evidence is not convincing that this is so and by taking all possible measures to seal by diathermy raw surfaces the chances of dissemination are minimal. Further, the added risk in any given case in view of the already grave prognosis appears justified when compared with the chance that amputation may be carried out unnecessarily on equivocal clinical and radiological findings

Prognosis

No neoplasm is regarded with more dread than osteosarcoma. It is certainly of all bone tumours one of the most fatal, and some observers have suggested that those cases reported as "cures" are indeed examples of erroneous diagnosis.

Thomson *et al* have reported a small series of well-authenticated cases in which four patients out of 32 survived for three years Cade has reported a larger series with a 12 per cent survival rate over five years.

Treatment

In bone sarcoma as in other malignant diseases the question of treatment is still an open one.

Operation is still the most generally employed measure. Removal of a limb is a procedure no surgeon can accept readily and the diagnosis must be established by biopsy to make the procedure justifiable In addition there must be no evidence of metastatic spread

Cases of osteosarcoma are often seen in which, in spite of the fact that amputation was performed immediately after the subjective onset of the disease, death has followed from pulmonary metastases. It appears that dislodgement of emboli from malignant bone tumours is incomparably more rapid than any malignant tumours in soft tissues.

The common sites are the epiphyseal plates, articular cartilage, the cartilaginous parts of ribs, and the symphysis pubis Such lesions are frequently a local manifestation of a generalized chondro-osteodystrophy.

Their cessation of growth when skeletal growth ceases and the absence of abnormal differentiation are strong evidence against their classification as tumours. They rarely, if ever, become malignant and may be multiple, especially in the short long bones of the hand and foot.

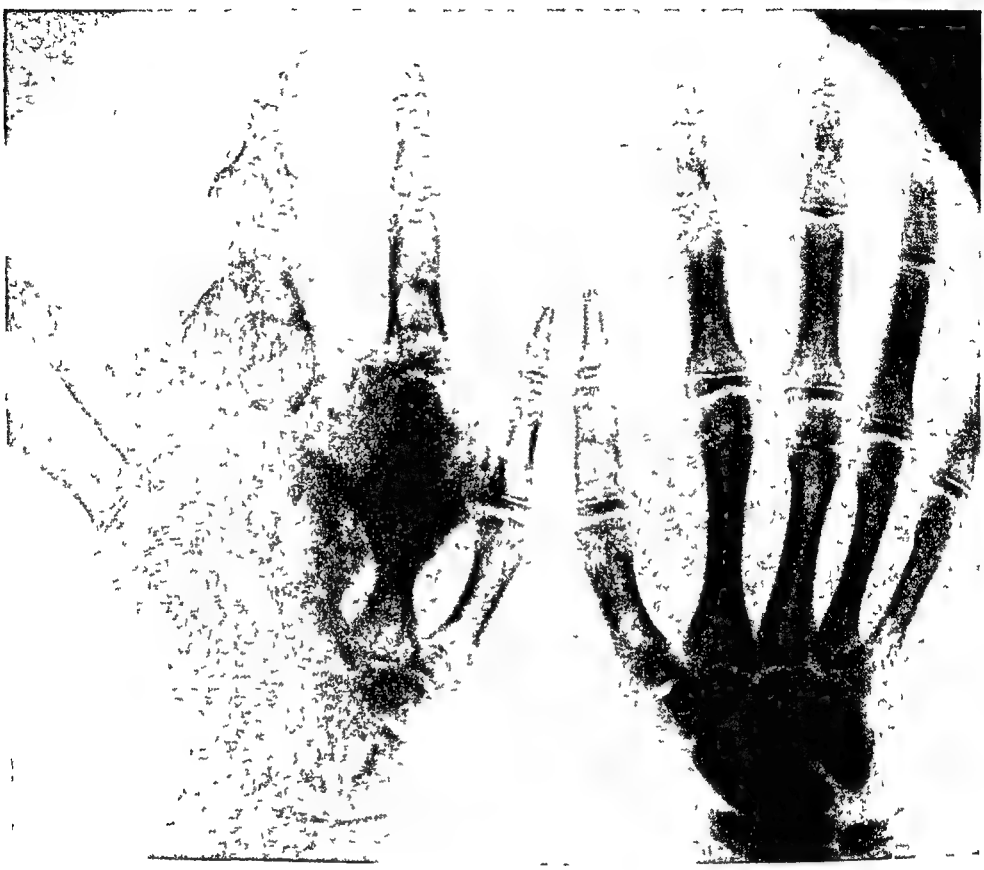

Fig 103 —Multiple Chondromata of the Hands

Treatment

The well-formed fibrous capsule enables the tumour in most cases to be cleanly excised, and even in the case of very large tumours, this may be accomplished with surprising ease

(a) Multiple Enchondromata

Multiple enchondromata occur in childhood, and affect the short long bones of the hand and foot, so that the part may be distorted, and appear to be of excessive size They arise in the centre of the shaft as a collection of cartilage cells which, in process of growth, gradually expand the surrounding cortex

It has been suggested that these tumours arise as a result of deficiency in the nutrient vessel, and an imperfection in the early

Clinical Features

The tumour may attain a very large size and destroy the adjacent bone, undermining its structure without showing the histological criteria of malignancy Occasionally pathological fracture may be the first evidence of its presence, or by its position and size it may give rise to deformity, pressure on nerves, or interfere with movement of adjacent joints

When a chondroma occurs in the small bones of the hand or foot it is known as a solitary cystic chondroma, and when it occurs elsewhere within a bone as a single enchondroma. This latter term may give rise to confusion as it includes both chondromas and cartilaginous hypertrophy

The differential diagnosis is mainly by that of its clinical course—those representing true tumours will not stop growing at the cessation of general skeletal growth.

Radiological Signs

The X-ray picture is generally held to be characteristic—a dense shadow, with a feathery outline composed of calcified spicules or "splastics" (Platt) In the absence of calcified or ossified areas in the tumour, the tumour is virtually invisible, though it may be suspected from the greater density of the soft tissues in relation to the bone.

(i) *The Solitary Cystic Enchondroma.*

In the short long bones of the hand and foot there is occasionally found a solitary enchondroma. They usually occur in the metaphysial region of a proximal phalanx or metacarpal, and seem to be especially common in the little finger. The tumour arises insidiously, and remains symptomless for long, and attention is often directed to it through trauma, or the occurrence of a pathological fracture

The tumour is at first composed of cartilage cells, but has a decided tendency to undergo myxomatous degeneration In the process of growth it may greatly expand the cortex of the affected bone. Usually benign, malignant change has supervened on numerous occasions.

Treatment

Platt points out that during the stage of active cortical expansion, or after the occurrence of pathological fracture, the cyst should be curetted and its cavity cauterized, bone grafts being inserted where the integrity of the parent bone has been threatened. In this way rapid and permanent healing results. When the cyst wall is thick, and is not giving rise to symptoms, it should be left alone.

(ii) *Cartilaginous Hypertrophy*

This always arises from existing cartilage and when it occurs mainly in the confines of bone is known as enchondroma, and when on the surface, ecchondroma

The histological appearances are those of osteitis fibrosa, with absorption of the trabeculæ of the affected bone, and fibrous tissue replacement. Giant cells may or may not be present. According to Bloodgood, Geschickter and Copland, these cysts should be further subdivided into:

(1) A group corresponding histologically to osteitis fibrosa

(2) A group in which amongst the fibrous stroma of the tumour there are a few scattered giant cells smaller than those of the typical giant cell tumour—the giant cell variant of the bone cyst

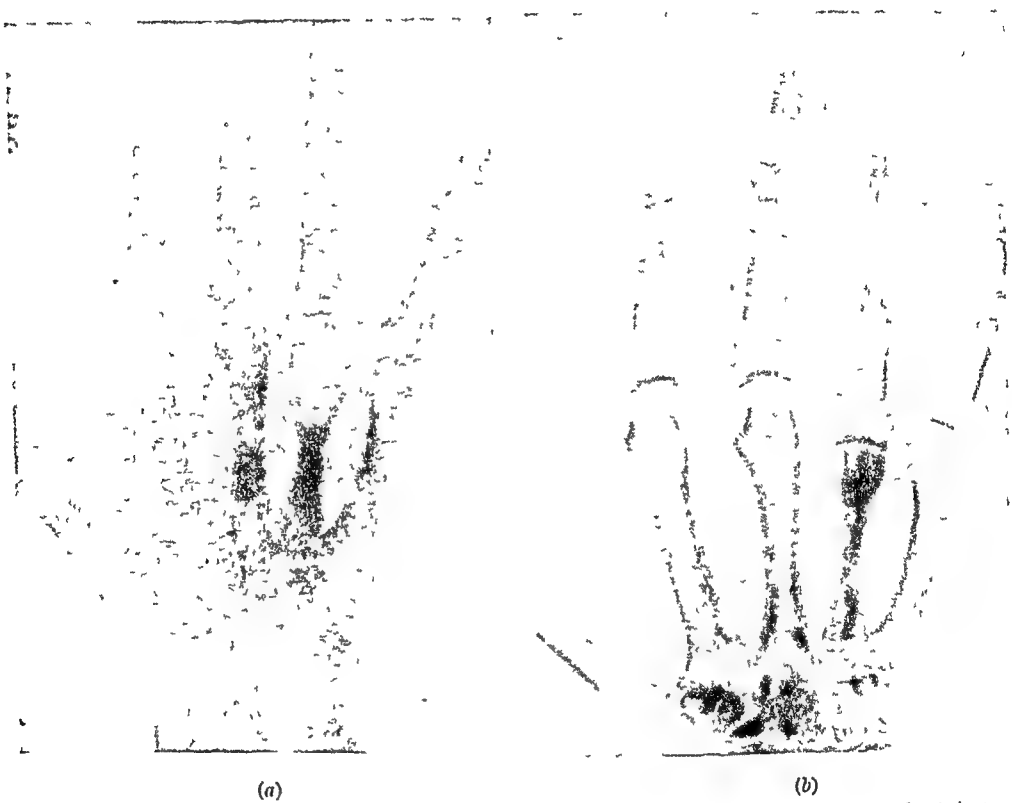

FIG 105—(a) Chondroma of Fourth Metacarpal, (b) After excision and implantation of bone-graft

(3) A group in which large numbers of typical giant cells are scattered throughout the stroma of spindle-celled connective tissue which, however, predominates—the spindle-celled variant of the giant cell cyst

In this way these observers seek to draw attention to the frequent relationship between osteitis fibrosa and giant cell tumour, though the latter, in its classical form, is not found in the short bones of the hand and foot

CLINICAL FEATURES

From the clinical aspect, symptoms arise when trauma results in a fracture, or when the enlarging cyst produces pain, and this directs attention to a gradually increasing swelling. The hand is more often affected than the foot.

vascularization of the cartilaginous framework has left within the centre of the shaft isolated islands of cartilage, which have later assumed proliferative activity.

The tumours are simple, they are deforming and ugly, but otherwise harmless. If left alone they may disappear when growth in length ceases.

TREATMENT

Platt believes that operative treatment is indicated when the tumours are rapidly growing, and have become unsightly or a source of inconvenience Complete excision, with curettage and cauterization of the tumour bed, is essential. Should this procedure lead to the collapse of the fragile bony shell of the affected bone, he recommends that the shell be packed with autogenous bone chips, and the part carefully splinted. The tumours should be dealt with at successive operations

FIG. 104 —Osteochondroma of the Femur
This was a benign tumour

Other Cysts of the Short Bones of the Hands and Feet.

Reference may here be made to cysts of the hand and foot of other than chondromatous origin.

These also arise insidiously, and may be present for long before attention is focussed on them through the complication of a pathological fracture

Platt, in a valuable paper, analyses the pathological and clinical aspects of this important condition In certain of his cases, the appearance of the cyst at operation bore a close resemblance to the morbid appearance in osteitis fibrosa cystica—the cyst was imperfectly filled, and sometimes even empty, and the lining was composed of thick fibrous tissue which peeled off easily. These characteristics serve at operation to distinguish between this variety of bone cyst and the cystic enchondroma.

supposed to be simple, is undertaken every effort should be made to ensure that the operation is complete and, if possible, the capsule of the tumour unopened

(C) FIBROMA

Benign fibrous tumours of bone are rare lesions and closely allied to the fibrous dysplasias. Accordingly they may be regarded as derived from cellular elements of the bone-forming series, but the exact histogenesis is still obscure and indefinite. Bingold has described a small series occurring chiefly in the second decade and characteristically situated in the metaphysis

The cellular and collagenous fibrous content of the tumour varies; the fibres are usually arranged in whorls. Growth is slow and unlimited, and mucoid or necrotic degeneration frequently occurs Ossification is also common but differs from the normal in that the bone is laid down in an irregular manner because of the original irregular pattern of the fibroblasts Very rarely does organized compact bone make its appearance When the bony structure is organized and growth, although slow, is unlimited, this is known as a true osteoma.

When situated periosteally it is known as a periosteal fibroma or exostosis if calcification has occurred, when in the medullary cavity—central fibroma, when in the bone substance it has the clinical picture of a bone cyst The condition is closely allied to fibrous dysplasia of bone but the presence in the latter of bone trabeculæ undergoing resorption is regarded as of differential significance

(C) FIBROSARCOMA

Examples of osteosarcoma with a predominantly fibroblast element are recognized but are regarded as variants of the osteosarcomata rather than a separate type of tumour.

Medullary fibrosarcomata have been distinguished by Thomson *et al* in reports from Scarff's laboratory, in these tumours definite collagen formation has been the predominant feature There has been early destruction of bone but in some ossification has been present. It is of possible significance that these tumours appear to have a much more favourable prognosis than osteosarcoma, there being a 25 per cent. five-year survival rate.

The same authors differentiate a spindle cell sarcoma which is distinguished by the complete lack of intercellular substance, occurs in a younger age group, and is more radio-sensitive.

It is difficult to classify these tumours which are not yet clearly distinguished or generally recognized. It may be that they have a similar histogenesis to the simple tumours noted above and from their location within the bone there is prima facie evidence that they arise from tissues of the bone-forming series.

RADIOLOGICAL SIGNS

At first the cyst is located at the metaphysial area of the affected bone, but gradually becomes displaced down the shaft as the bone grows. The cortex is usually expanded, and the trabeculæ are largely destroyed, though traces of them may be seen as fine streaks running through the otherwise structureless area There is no sub-periosteal new bone reaction

The radiological signs are similar to those of the cystic enchondroma, and the two lesions cannot therefore be distinguished on X-ray examination, but only at operation—the chondroma is filled with bluish-white translucent material, the cyst with crumbly brown tissue—and on histological examination.

(B) CHONDROSARCOMA

Chondrosarcomata arising in the same age-group as osteosarcoma have been described, but there is good reason to believe that such cases represent that variant of the tumour in which the chondromatous potentialities of the tumour cells have been prominent rather than a specific type of tumour. Such lesions which are characteristically not the sequel to any obvious dystrophy, run a course similar in all respects to osteosarcomata and histologically show elements both illustrating osteogenesis and simulating fibroblasts.

In contradistinction there is a definite and larger group of chondromatous tumours, malignant in character, which develop in pre-existing lesions both developmental and of innocent neoplastic nature For these the term " secondary chondrosarcoma " has been coined. It is a term which is ambiguous and to be avoided but it nevertheless in some sense indicates the character of the majority of chondrosarcomata

The age incidence of malignant change is usually between 35 and 55 years The diagnosis of the change is difficult for the transition may be gradual or occur in only one part of a pre-existing mass. Suspicious features are increased rate of growth and pain. Radiologically there is greater bone destruction with splintering of osseous structure. Biopsy studies are liable to be inconclusive

A feature of special note is that these tumours tend to grow into and along veins and thus cause pulmonary metastases

While amputation or adequate excision are associated with a relatively good prognosis, partial removal is liable to increase the malignancy and be followed by rapid recurrence and secondaries.

Thomson *et al* have reported 50 per cent. alive and well five years after treatment.

It has long been held that incomplete operative removal of simple chondromata, especially those in relation to secondary centres of ossification, is liable to lead to malignant change and a recurrence of the tumour This may be so but it is difficult to exclude the possibility that in these cases malignant change had preceded the operative intervention. None the less, it is accepted that when the removal of a chondroma, even if

epiphysis, explaining its relative quiescence. In most cases it is undoubtedly progressive in that 45 per cent. are discovered by pathological fracture.

The pressure of the cyst on the surrounding veins and lymph channels results in venous stasis and increasing amounts of fluid in the cyst, giving rise to a vicious cycle. The increased pressure in the cyst tends to point down the marrow of the shaft—the line of least resistance Cysts rarely heal spontaneously.

The granulation tissue of the brown node may undergo maturation. Here collagenous fibrous strands cross through the original brown node

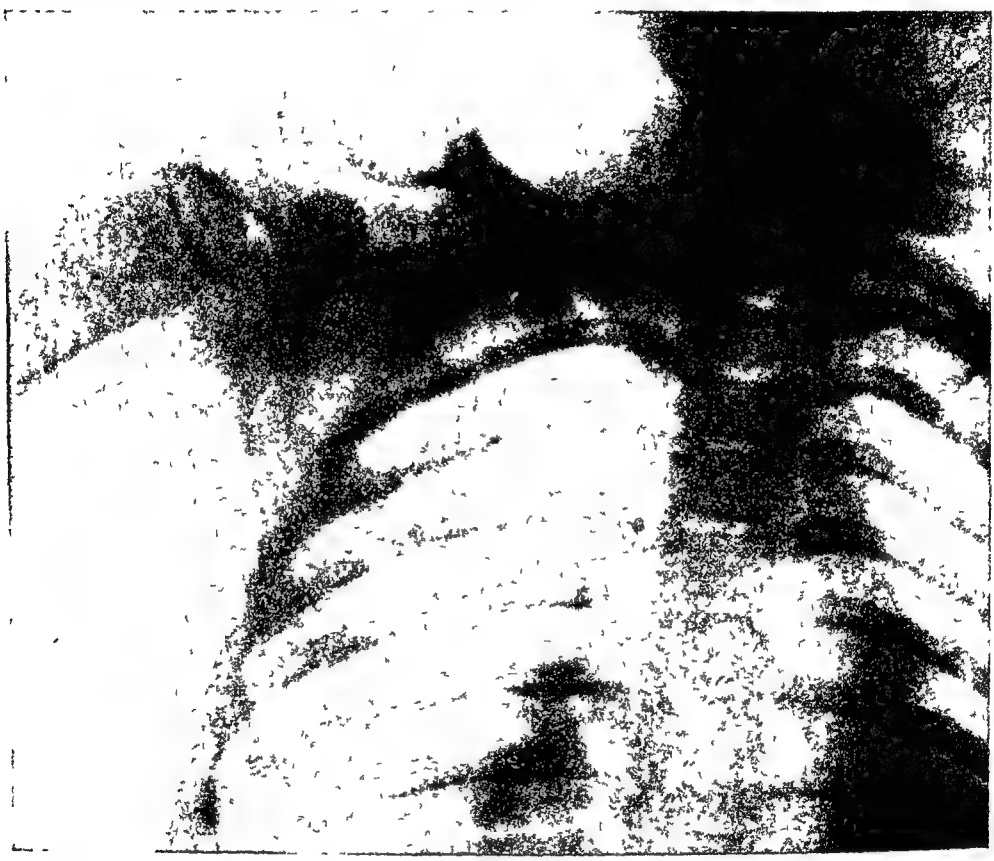

Fig 106 —Osteoclastoma of Clavicle

and undergo ossification An X-ray then shows the "soap bubble" appearance Providing fluid cysts are not present spontaneous healing of the brown node may occur.

The original lesion, being central, at first does not markedly weaken the bone as the cortex of a pipe always supports the greatest stresses. Thus compensatory bone formation is slight and occurs in the subperiosteal region This has frequently been wrongly referred to as expansion of the bone

In osteitis fibrosa cystica—a generalized disease due to abnormal parathyroid secretion—there are localized areas of bone where as the

(D) OSTEOCLASTOMA

Lesions of bone associated with the presence of giant cells arise from a variety of causes and because of certain histological similarities are frequently confused

The presence of osteoclasts which may well be, as already noted, but a functional variant of the osteoblast or at any rate a cell derived from a common ancestor, is a constant feature during the removal or remodelling of bone whether the changes result from physiological or pathological causes.

The typical osteoclast is a large cell containing a variable number of centrally placed nuclei which remain, however, distinct each from its neighbour. Each nucleus is identical with the others, ovoid in shape and basophilic in its staining reaction. When there is increased phagocytic activity the nuclei come to occupy a more peripheral position. These cells are found closely applied to the margin of bone trabeculæ upon which they exercise an eroding effect. Such erosion produces the recesses in which they are found in normal bone and named Howship's lacunæ

(*a*) Taylor, Jaffe and others have shown that the occurrence of areas of increased giant cell activity appears as a reactive phenomenon after marrow hæmorrhage, and when the lesion is somewhat more than minimal, cyst formation is common Such lesions closely simulate a true tumour. Typically such occur in young persons Because of the susceptibility of the ends of the long bones at this age period to trauma small hæmorrhages not infrequently occur where the capillary loops abut on the epiphysis.

Usually this hæmorrhage undergoes absorption, but in hyperparathyroidism or other unknown predisposing factors—endocrine or osteodystrophic—the bone is not capable of withstanding normal stresses and strains and repeated trauma to the delicate granulation tissue occurs with increasing vascularity and hæmorrhage and granulation tissue Giant cells appear to remove blood pigment and decalcified bony trabeculæ This decalcification is a result of the increased vascularity and the pressure of this mass in an unphysiological direction. With repeated use of the affected bone hæmorrhage increases and more and more granulation tissue appears with numerous phagocytic giant cells. This is known as a brown node and on histological examination the granulation tissue is infiltrated with new and old extravasated blood.

The granulation tissue may undergo myxomatous degeneration or liquefaction, or extravasated blood may fail to be absorbed There now result cysts with clear, straw-coloured, or brownish fluid If the cyst replaces the whole of the brown node it has a pseudocapsule of fibrous tissue This is known as localized osteitis fibrosa cystica and occurs most frequently between the ages of 5 and 15 and in the mid-shaft. The explanation of this is that in growing bones when the lesion starts in the epiphysis it will gradually be pushed towards the mid-shaft by epiphyseal growth Here also strains and stresses are less at the

destruction may be uniform, or the tumour may grow eccentrically and reach the surface of the bone on one or other aspect. As it progresses, the epiphyseal cartilage may be destroyed, and sometimes the tumour may penetrate the articular cartilage and gain entrance to the related joint, though this is exceptional.

The usual variety of giant cell tumour is composed of reddish-brown soft tissue, resembling vascular granulation tissue, amongst which there may be cystic areas, refractile fatty areas, and bone debris. Situated primarily in the medulla, the tumour leads to progressive destruction of the bone trabeculæ, and gradual attenuation and increased girth of the cortex by compensatory subperiosteal bone. The intramedullary spread of the tumour is limited to the cancellous tissue at the bone end, and it does not possess the same tendency as the osteosarcoma to spread along the medulla. The absorption of the cortex to a mere film gives rise to the characteristic egg-shell crackling, and the weakening of the bone may precipitate a pathological fracture.

The histology varies according to its stage of development During the active phase of formation the main bulk of the tissue is composed of spindle-shaped fibroblastic cells amongst which there are scattered numbers of giant cells. These possess a homogeneous cytoplasm, and contain from ten to thirty nuclei which are usually peripherally disposed. Occasional foam cells containing lipoid material are found and the blood-vessels are well formed When cystic its wall is composed of a thin shell of bone, and occasionally soft reddish cellular tissue is found at its margin Sometimes it has a patchy fibro-membranous lining The cyst usually contains a small amount of brownish fluid The marginal cellular tissue, when present, contains numerous giant cells

Clinical Features

The majority occur in the lower limb, and especially in the vicinity of the knee, though any long bone may be affected, and occasionally the jaw, the flat bones of the skull, the patella, vertebræ, and tarsus

The first symptom is generally pain, and at this time the affected part of the bone is tender This early appearance of pain and tenderness is of great importance, and may suggest a possible inflammatory process The pain gradually increases in severity and ultimately a swelling appears This may be asymmetrical when the tumour grows eccentrically, when the tumour is central the affected bone presents a bulbous-shaped enlargement towards its extremity

Occasionally, pathological fracture is the earliest feature and rarely the tumour is not seen till it has infiltrated the soft parts, the adjacent joint, or even fungated through the skin. When it occurs at a younger age it tends to be less painful and frequently will be completely quiescent until pathological fracture occurs

X-ray Appearance

This also depends upon the stage of development. During the

result of bone destruction and hæmorrhage a reaction occurs which histologically and macroscopically simulates a true neoplasm and in which the outstanding feature is the very large number of active osteoclasts These lesions, however, have one characteristic feature—they spontaneously regress after the removal of the causal adenoma of the parathyroid

(*b*) Malignant giant cells are found in osteosarcomata. These are found especially in the more anaplastic lesions and contain a variable number of nuclei but seldom so many as in the osteoclast The cells are irregular in form and size and this variability is shared by the nuclei Occasionally the nuclei are fused together. These features serve to differentiate such malignant giant cells from the osteoclast.

Fig 107 —Osteoclastoma of the Femur. Male aged 69 years (*a*) Showing pathological fracture.

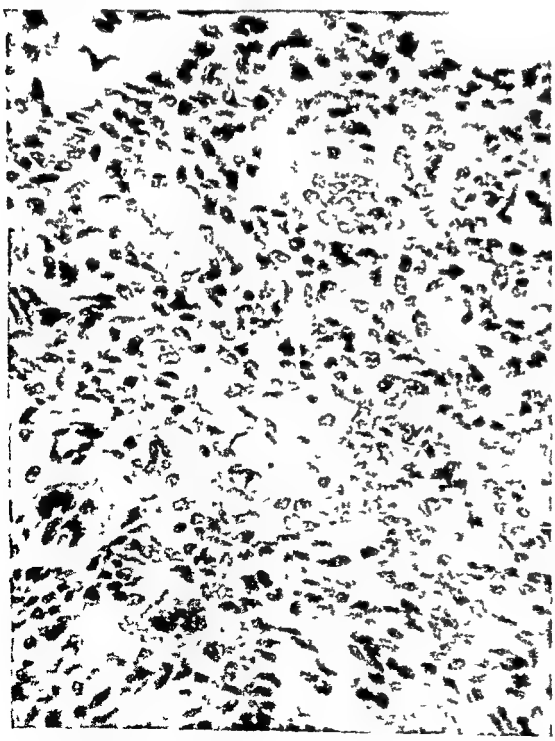

Fig 107 —(*b*) Microscopically typical Multinuclear Giant Cells and Stroma present

True neoplasms occur in patients of either sex and the majority arise in the third decade. The lower end of the femur, upper end of the tibia and the lower end of the radius are common sites. Osteoclastoma of the mandible is a well-recognized lesion.

Characteristically, the benign giant cell tumour pointed out by Bloodgood and his associates, and by Platt, is an epiphyseal lesion, in contrast to the osteosarcoma, which occurs in the metaphysis It begins in the cancellous tissue, and leads to progressive destruction of the bone trabeculæ. Such local

the tumour, in the giant cell tumour the bone structure is entirely replaced. The osteosarcoma, in addition, does not reach the articular cartilage; whereas the giant cell tumour is in direct contact with it When the whole mass has been replaced by a cyst the bone cortex is expanded to form a thin shell overlying the cyst. At its distal end, the cyst may be continued as a pointed extension down the shaft.

Treatment

There are many cases reported of spontaneous cure and many are spontaneously cured when complicated by pathological fracture. This is probably due to the associated immobilization of the affected part with the cessation of trauma and its stimulating effect on hæmorrhage and granulation tissue formation. Such spontaneous cure, of course, indicates that the lesion in question could not have been a true neoplasm

The treatment of this tumour may be either local removal, resection of the affected length of the bone, or radiotherapy. Where the diagnosis is certain the latter is the choice and an increasing percentage of cure is obtained by modern technique. In the first three or four weeks the result of X-ray treatment is an increased vascularity of the connective tissue and the appearance is that of a rapidly growing malignant tumour It eventually results in a radiation endarteritis obliterans of the vascular connective tissue, leading to ossification and cure. Where there is any doubt about the diagnosis a biopsy is carried out Curettage with complete removal of the entire tumour and its covering membrane in the local operation is essential Cancellous chips of bone are used to fill the resulting cavity.

(D) MALIGNANT OSTEOCLASTOMA

A considerable number of cases have been described and are well authenticated in which an osteoclastoma has given rise to metastatic deposits, clearly indicating a malignant character. These secondary tumours show similar histological features to the primary lesion. From the studies which have been made evidence is now accumulating that "malignant change" can be identified in the primary tumour by the anaplastic character of the stromal cells and Thomson *et al.* have stated that it is possible to grade these lesions In some cases spicules of new bone have been found in the metastatic deposits and this is regarded by Evans as an indication that the potential bone-forming properties of the "stromal" cells do justify the inclusion of osteoclastoma among the osteoformative primary tumours of bone

"Chondromatous Osteoclastoma"

Copeland and Geschickter described a lesion not dissimilar to an osteoclastoma but in which the matrix was composed of both mature and immature chondroblasts They described both simple and metastasizing forms of this lesion and regarded it as a seperate entity, a view which is disputed by Willis on the grounds that the stromal cells of the

active phase with young granulation tissue the X-ray appearance is characteristic The end of the bone is enlarged and occupied by a clear cystic tumour. If attempts at spontaneous healing have occurred the swelling will appear multi-cystic because of ossification in mature fibrous tissue strands and osseous trabeculation may be seen at the periphery of the cyst; the cortex is thin and sharply limits the tumour from the

FIG 108 —Osteoclastoma of the Base of the Neck of the Femur

Note the globular shape, with "expansion" of the bone, the soap-bubble trabeculation, and the wall of bone protecting the medullary cavity.

surrounding soft tissue. There is a sharp line of demarcation between the tumour and the unaffected shaft in contradistinction to the appearance of sarcomata and the bone cysts When the whole shell is destroyed, however, it may be difficult to differentiate it from an osteolytic osteosarcoma The appearance of the adjoining periosteum and cortex serves to distinguish it from osteosarcoma, while in the latter some remnants of bone structure will usually be seen in the substance of

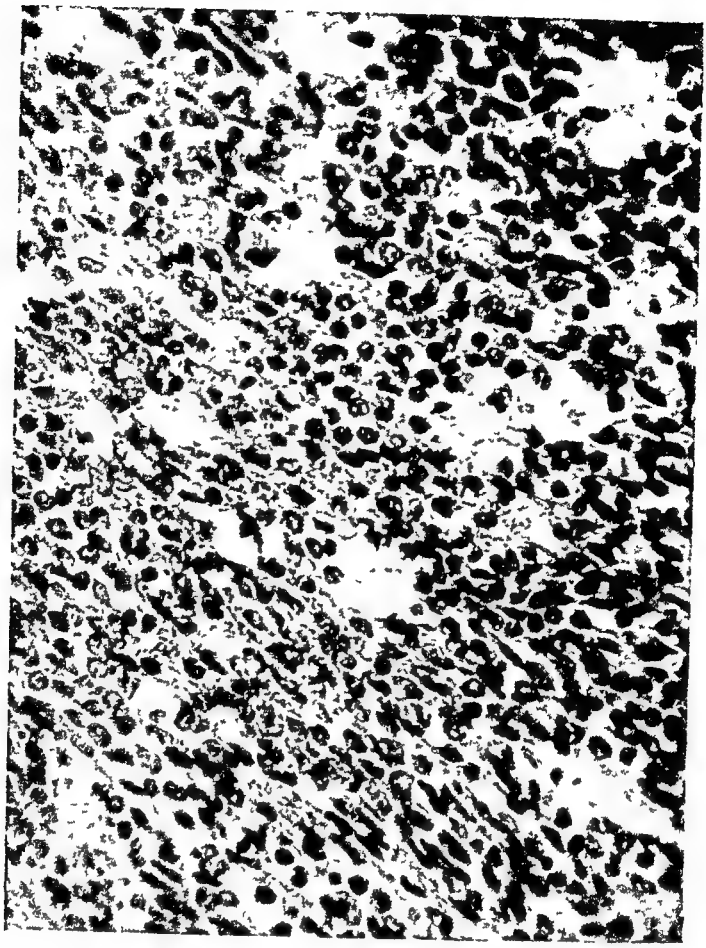

(c)

FIG. 109 —(c) A rapidly growing sarcoma with both round- and spindle-shaped cells No new bone formation is present

The tumour is firm, fibrous, white and glistening, with easily distinguishable fasciculi. Occasionally it is cellular, soft and crumbly, containing cysts. The degree of vascularity varies with the cellularity of the tumour. The tumour may appear to be encapsulated, but the capsule merely consists of the condensed surrounding tissues. It remains localized for a considerable time, but ultimately, as the vascularity and cellularity increase, it becomes more malignant At this stage secondary metastases usually occur in the lungs

Histologically the tumour is a spindle cell fibrosarcoma with a variable degree of collagen formation There is no true ossification but calcification can occur.

CLINICAL FEATURES

While these tumours may arise at any age and one has been observed in a new-born child the majority are seen in patients about 30. Localized swelling, steadily increasing in size and with initially little pain or disability are the main features While the tumour has a broad attachment

osteoclastoma possess the same inherent powers of metaplasia or may arise from a pluri-potential cell, a fact characteristic of all the tumours of this osteogenic group.

2 *NON-OSTEOGENIC TUMOURS OF BONE*

(A) PERIOSTEAL FIBROSARCOMA

This tumour originates in the outer non-osteogenic fibrous layer of the periosteum. It is in character a fascial sarcoma and similar in character to those arising in other sites in the soft tissues. It is extra-cortical and neither invades nor infiltrates the bone. The tumour remains encapsulated for a long time, and as it grows it pushes aside the soft tissues, but rarely infiltrates them.

Secondary changes eventually appear in the underlying bone, but they result from the pressure and the contact of the tumour. Saucer-shaped erosions may occur where the cortex is in contact with the tumour, and areas of new periosteal bone formation at the periphery.

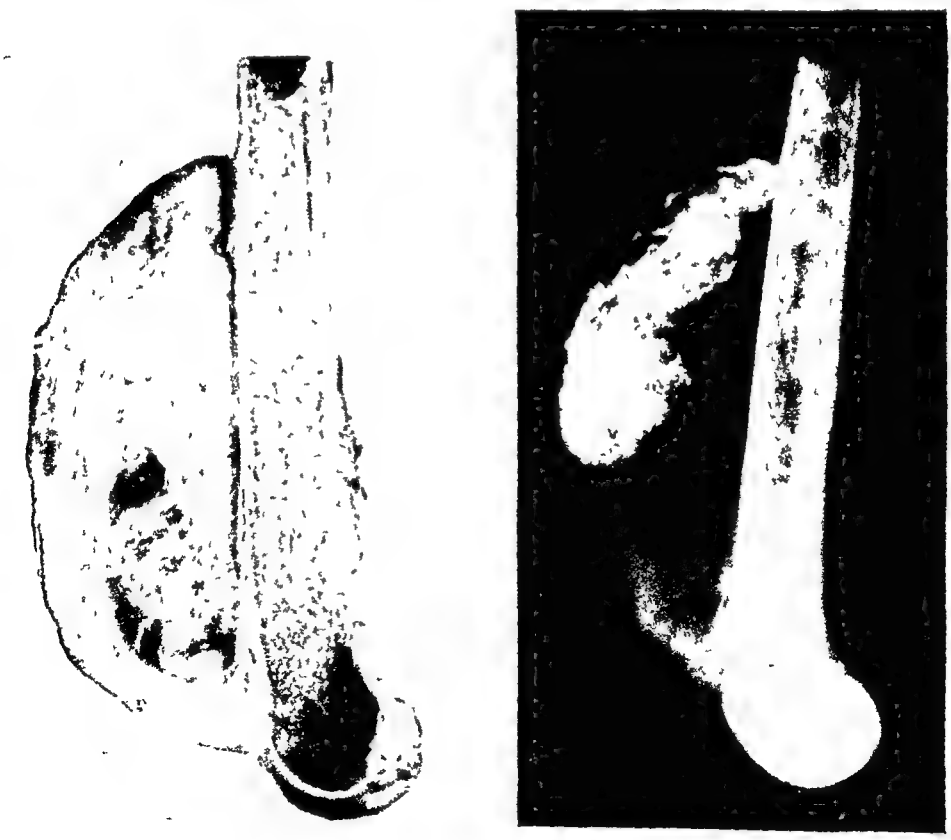

(*a*) (*b*)

FIG 109 —Periosteal Fibrosarcoma of Femur Female aged 25 years (*a*) History of injury 12 years previously, followed by development of a slowly growing tumour One year previously to admission the tumour began to grow rapidly (*b*) Radiological examination shows extensive calcification.

tumours bear a close resemblance—on inspection as well as on radiological examination—to diffuse carcinomatosis Hæmorrhage with cyst formation is common, and pathological fracture is frequent and often precedes extension of the tumour to the soft parts overlying it When the disease is extensive there may be gross restriction of the absolute amount of red marrow, so that anæmia arises.

FIG 110—Myelomatosis of the Femur, etc

Note the trabeculated appearance with no "expansion" of the shaft, the fracture of the neck, and the implication of the ilium

Myelogenous tumours are most commonly encountered in the skull and vertebræ, ribs, pelvis, femur and humerus, but the bones of the peripheral parts of the limbs are only occasionally the site of disease. In many instances small lesions can only be demonstrated radiologically. The sternum frequently contains tumours and sternal puncture in

to the periosteum they appear to have considerable mobility on examination.

A very well-recognized site for these tumours is at the lower end of the femur.

Diagnosis

The X-ray film shows a faintly outlined soft-tissue shadow, the cortex opposite which often shows a shallow saucer-shaped depression. Beyond this, bone changes are conspicuous by their absence

Treatment

Radical removal of the tumour is the operation of choice. The prognosis is especially favourable when the tumour is encapsulated If the operation is incomplete it may be followed by local recurrence and general metastases The operation should be supplemented by a prolonged course of deep X-ray therapy, although its beneficial effects are in doubt.

(B) MYELOMA

It is from the primitive undifferentiated mesenchyme cell that marrow develops and in the process of differentiation progeny of distinctive characteristics are produced. There are the reticulum cell with its fibrils, the plasma cell with its typical cart-wheel nucleus eccentrically placed and showing in the basophilic cytoplasm a characteristic clear area, the cells of the lymphocyte series and the forerunners of the polymorphonuclear cells and erythrocytes of the blood Tumours arising in the marrow can therefore exhibit a wide variation in cell type resembling in greater or lesser detail the cells normally found and affording ample opportunity for complex classification. Such discussion, however, is of little clinical significance

Two common types of tumour are found

(*a*) *The solitary myeloma* Here the cells frequently resemble plasma cells and produce a localized medullary area of bone destruction It has been confused with other cystic lesions Very few cases have been reported in the literature and they usually become multiple with the passage of time

The treatment is by X-radiation as surgical curettage may lead to its dissemination

(*b*) *Multiple myeloma.* This is a rare disease characterized by the development on many parts of the skeleton of swellings, varying in size from a bean to an orange.

Pathology

The affected bones show replacement of their marrow by grey or reddish-grey tumour masses which tend to be circumscribed and oval in shape The bone trabeculæ and adjacent cortex are completely destroyed, and there is no reactive new bone formation, so that the

large amounts of globulin are present in the urine Renal insufficiency is another frequent complication and is believed to be due to plugging of the renal tubules by globulin casts.

In certain myelomata when the tumour is sectioned the cut surface exhibits a bright green colour which is due to a pigment the character of which is not fully understood The colour rapidly fades. To this group of tumours the name of chloroma has been given

The disease is one of adult life and chiefly affects males between the age of 40 and 60 years. A history of trauma preceding the development of individual local lesions is often obtained Pain is a common initial symptom but pathological fracture or paraplegia have been frequently the presenting symptoms Back-ache as an initial symptom is noteworthy and the condition should be borne in mind as the cause of such symptoms in the elderly especially in the presence of osteoporosis and where the pain is not relieved by rest Fever may be observed in the course of the disease, and pathological fracture is not infrequent and egg-shell crackling may be noted on examining the individual lesion While the lungs are not usually involved, death as a rule occurs from visceral metastases

X-ray Appearances

The tumours appear as multiple circumscribed areas of destruction in which the bone texture has completely disappeared The cortex shares in this obliteration.

Diagnosis

Full investigation is carried out This should consist of—radiographic examination of the skull, ribs, and vertebræ, estimation of the total serum proteins and serum albumin and globulin, examination of the urine for Bence-Jones' Protein, and sternal marrow puncture.

The multiple nature of the lesions, the absence of pulmonary metastases, the late age period and the osteolytic character of the radiological picture are the significant features. The most likely error is diffuse secondary carcinomatosis and a thorough investigation for a demonstrable focus in breast, thyroid, prostate or uterus must be undertaken In these cases, however, pulmonary metastases are common and the only line of treatment available is deep X-ray therapy but the course comes to an inevitably fatal end

Solitary myeloma

Rarely, cases have been described of solitary lesions of bone in which on careful examination the histological picture has been that of a myeloma typical of the plasmacyte type and in which other lesions have not been demonstrated Cases of this character in which the local lesion has been resected or treated by radiation have survived without evidence of recurrence or of other foci developing elsewhere in the skeleton and accordingly it is now accepted that solitary myeloma con-

consequence may be a valuable diagnostic procedure. It is difficult to be certain whether we are dealing with something which is multicentric in origin, or is evidence of widespread metastases arising early from a single primary focus. The consensus of opinion is in favour of the first assumption. The disease is closely related to the leukæmias but a point of distinction is made that in the leukæmias, unlike myelomatosis, the plasma cell is rarely the predominant type.

Fig 111 —Multiple Myeloma of the Skull.

Histology

The microscopical appearance of the tumour is very variable and the most common cell type seen resembles the plasma cell but in other cases cells suggestive of myeloblasts, lymphoblasts or occasionally fibroblasts (Cappell) have been observed.

In myelomatosis metabolic disturbance is common, the blood calcium is raised and there is a hyperproteinæmia, the globulin being raised In 50 per cent of patients globulin (Bence-Jones' Protein) is present in the urine, a fact which, however, can also occur in leukæmia, skeletal carcinomatosis and rarely in nephritis.

Amyloid deposits in muscles and joints have been described in 10 per cent. of cases of myelomatosis and is particularly common when

From the medulla the tumour extends in the Haversian canals to the surface. Under the periosteum compensatory layers of new bone are deposited, only to be destroyed. Such shells of new bone are deposited parallel to the shaft of the bone and have been aptly described as "onion layers."

Histology

The microscopical features in these lesions are not specific. The tumour is intensely cellular and usually the cells conform to one type, small, round or polyhedral, arranged in solid cords or sheets. Intercellular substance is minimal. Necrosis is common and the remaining cells arranged round the central blood vessel have sometimes given the appearance which has justified the term "perithelioma." The nuclei are always prominent and mitosis frequent.

Many tumours show a rosette arrangement and within the centre of the rosette by special staining methods fibrils can sometimes be demonstrated. Such a structure is characteristic of a neuroblastoma. Pseudorosette formation is, however, more common but this does not exclude the possibility that these cells are in point of fact neuroblasts but lacking in fibril formation by reason of the de-differentiation which has occurred in a rapidly growing tumour.

Despite the bone destruction, giant cells or osteoclasts are never found, nor is new bone to be discovered apart from the sub-periosteal deposits. The vessels of the tumour and the lymphatics may both contain obvious emboli, for the tumour spreads by the blood and lymphatic systems.

Clinical Features

Despite assertions to the contrary, this tumour runs a protracted course and even where many bones are affected death may be long delayed.

There is usually a history of preceding trauma, often associated with pain; after an interval the pain subsides and the trauma may be forgotten about. Later on, however, there occur intermittent attacks of pain followed by the appearance of a slow-growing tumour in relation to the shaft of one of the long bones. During the attacks of pain the tumour may enlarge visibly and there may be febrile attacks and a leucocytosis, in the succeeding quiet intervals the tumour may appear to shrink in size.

The overlying skin is never affected unless surgical exploration is carried out during one of the acute phases; then the tumour may fungate through the skin. Pathological fracture seldom occurs.

In the late stages multiple deposits appear in the skull, ribs, sternum, pelvis and other long bones. There is then marked cachexia, and secondary anæmia. When the vertebræ are involved there is severe root pain or paralysis, and death usually results from metastatic involvement of the lungs.

stitute a definite disease entity. The condition is almost invariably found as the result of pathological fracture and the diagnosis only made after the histological study.

EWING'S TUMOUR

In 1921 Ewing described a rare lesion of bone characterized by the development of a tumour in the diaphysis of the long bones, occurring in childhood and associated with febrile attacks. The tumour involved rapidly other parts of the skeleton and was radiosensitive. Histologically the identification of the origin of the tumour was difficult and Ewing believed that it arose from endothelial elements in the marrow. Largely by the work of Willis it was demonstrated that in many of the cases diagnosed clinically and radiologically as "Ewing's Tumour" the histological pattern demonstrated a rosette formation which was suggestive if not characteristic of neuroblastomata and further that in these cases which were submitted to full post mortem examination a primary tumour, usually in the adrenal, could be found In other instances the lesion could be identified as a reticulum cell sarcoma In a number of other cases the lesion on fuller examination proved to be metastatic, the primary tumour being located in different sites.

While it is accepted that a majority of the cases presenting these clinical and histological features are in fact examples of metastasising neuroblastomata or reticulum cell sarcomata, there yet remains a small group of reports in which the fullest examination gives no evidence of any primary neoplasm outwith the skeleton and in which the microscopical examination differs both from reticulum cell sarcoma and secondary disease originating in the neural tissues or elsewhere. (Evans, Lamb and Mackenzie) For this group whose origin is unknown the continued use of the term "Ewing's Tumour" is justified

The typical "Ewing's Tumour" usually occurs between the ages of 5 and 15, and is somewhat more common in males The bones most commonly affected are the long bones, and of them it is most frequently found in the tibia. Next in frequency the fibula, the humerus, and the femur are involved The tumour has a decided tendency to the involvement of other bones after the primary focus has been established, indeed it may be diffused throughout the whole skeleton, and the skull and small bones may be affected. Regional lymph glands may be involved

Pathology

The tumour almost invariably begins in the marrow about the middle of the shaft, a feature that serves to distinguish it from the osteogenic and benign giant cell tumours In colour it is greyish-white and has a semi-fluid brain-like consistence Areas of necrosis and hæmorrhage with cyst formation are often present The lamellæ in relation to the tumour mass are destroyed and the appearance of the diffuse, semi-fluid greyish tumour tissue amongst necrotic lamellæ suggests osteomyelitis

The tumour is relatively benign. Although the initial response to radiation is good local recurrence usually takes place A primary course of radiation followed by amputation or radical resection is the most promising method of treatment.

(C) BLOOD VESSEL TUMOURS

Blood vessel tumours in tissue—whether benign or malignant—manifest themselves as lesions of rarefaction with compensatory distal bone formation These tumours are rare but present an interesting problem of diagnosis.

Hæmangioma

Vascular tumours of bone are rare but a number of case reports have established that the most common sites for these lesions are in the skull and vertebral column. Very characteristically in the flat bones bony spicules radiate from the surface giving what is known as the "sunburst" appearance. In the vertebra the characteristic appearance in an X-ray is the presence of vertical parallel lines and increased density In the vertebral column when the body is affected the appearance may suggest tuberculosis, secondary neoplasm or Paget's Disease Collapse of the vertebral body occurs and there may be pressure on the cord

These tumours are benign in character in a majority of instances Treatment is difficult on account of the location of the tumour but should the lesion be present in the more peripheral bones radical excision has been advised

Angio-sarcoma (angio-endothelioma) is *extremely* rare and must be differentiated from the reticulo-sarcoma which may mimic it closely because of the potential endothelial function of reticular cells. This is a very rare tumour, the American Registry containing only two cases It occurs in patients of any age and apparently any bone in the skeleton may be affected The clinical course of the tumour is similar to that of osteogenic sarcoma, save that the pain is later in appearance. Eventually widespread metastases appear, death usually resulting from pulmonary involvement.

Lipoma

Simple lipomata have been described both as arising within the medullary cavity and in relation to the periosteum These tumours are innocent but by their pressure some absorption of adjacent bone may occur Liposarcoma is an excessively rare lesion and the pathological diagnosis the subject of considerable controversy.

3 *TUMOURS ARISING FROM INCLUDED TISSUES*

Adamantimoma

Adamantimoma or adamantine epithelioma, has long been known as an entity and ordinarily occurs in the jaw but also affects the tibia,

X-ray Appearances

There is a diffuse rarefaction towards the centre of the shaft, and extending for a considerable area In the early stages there is condensation without other change Later, from reactive irritation the periosteum throws off "onion-skin layers" parallel to the shaft and rather like osteomyelitis, or more commonly small spicules appear. The last stage is that of gross tumour formation with destruction of the original bone structure.

Diagnosis

Classically the differential diagnosis of Ewing's Tumour is from chronic osteomyelitis but the modern radiologist being well aware of this clinical syndrome which we associate with the name of Ewing's Tumour is unlikely to-day to fail to distinguish an infection from this neoplasm. The chief difficulty lies in an interpretation of the appearances obtained either at biopsy or operation and in those cases where the lesion is metastatic it may be difficult to demonstrate the primary source of the tumour.

The rapid response of many cases labelled Ewing's Tumour to radiotherapy was considered to be of diagnostic significance but this is no longer regarded as correct.

Treatment

Deep X-ray therapy may cause the local lesion to disappear but subsequent local recurrence is the rule Accordingly it has been the practice to follow the primary irradiation by amputation Such treatment will not affect the ultimate prognosis in those cases where the tumour is metastatic.

(B) RETICULUM-CELL SARCOMA

This is a non-bone-producing tumour which occurs in the second to the fourth decades of life and affects particularly the femur, tibia and humerus Pain is often the first complaint, preceding the formation of a tumour. This may invade a large part of the shaft of the long bone but without affecting the health of the patient materially.

The X-ray picture is not characteristic There is an osteolytic lesion in the end of a long bone which later extends throughout the length There is fragmentation of the cortex, and pathological fracture may occur.

Pathology

The shaft is occupied by a pinkish-grey granulation tissue and this in time invades the soft tissue The cells, which are identical with those of reticulum-cell sarcoma of a lymph gland, are larger than a lymphocyte, and have round oval indented or lobulated nuclei with considerable cytoplasm Delicate reticulum fibres pass between the cells which often show a large number of mitotic figures.

pain in the back in sacral tumours. The tumours are locally invasive and tend to recur after removal.

The radiogram usually shows destruction of bone with a shadow of a tumour in the soft tissues There is nothing characteristic in the bony erosion and the diagnosis, though it may be guessed at from the site, is usually made by biopsy. The tumour is slow-growing but malignant and kills by invasion of vital structures. Mabrey estimates that at least 27 per cent of the growths metastasise. This is most common in lumbo-sacral tumours.

Microscopically chordomas are distinguished with difficulty from atypical chondromas and mucoid or signet-ring carcinomas arising in the gastro-intestinal tract. Myeloblastomas originating in the sacro-coccygeal region are usually interpreted as chordomas The chordoma cells are more epithelial in appearance than cartilage and more variable in size There is a great tendency for vacuolization and variability in the size of the nuclei

An attempt at complete surgical extirpation must be made, since these growths are radio-resistant.

4 *METASTATIC TUMOURS OF BONE*

Of all cases of fatal malignant disease one in five will show skeletal metastases The frequency of secondary bone lesions varies according to the identity of the primary tumour Carcinoma arising in the prostate, kidney, breast, bronchus and thyroid and the neuroblastoma of the adrenal notoriously are associated with bone secondaries. It has been averred that carcinoma of the prostate will finally involve bone in 70 per cent of cases, while in lesions of the breast and kidney the estimate is 50 per cent. In contradistinction carcinoma of the stomach shows bone involvement in only 5 per cent. of cases.

Bone may be involved as the result of direct spread of an overlying tumour as seen in the classical case of epithelioma of the leg following varicose ulceration

Spread by the blood stream is more common It is presumed that detached neoplastic cells enter venous channels in the tumour and after passing through the pulmonary circulations where the relatively large size of the capillaries and the constant rhythmic movement of the alveolar walls does not facilitate their lodgement they reach the arterial blood stream The cells finally become arrested in some smaller capillary of the peripheral circulation

This simple explanation, however, does not explain the selective distribution of secondary tumours found In the skeletal system certain sites, the upper end of the femur, the upper end of the humerus, the spinal column, the ilium, the ribs and sternum are very frequently involved while other bones, especially the peripheral bones of the limbs, are relatively immune The sites most prone to secondary malignant disease are the parts of the osseous system where red marrow is found

rarely other long bones. Baker *et al.* reviewed 27 cases occurring in the long bones. The name indicates a tumour consisting of enamel and is misleading, so that until more is known of their pathogenesis it would seem wise to refer to them as "adamantinoma (so-called)" of the long bones. There is some doubt as to whether these long bone tumours are in any way related to such named tumours of the jaw, especially as no enamel has been found in them.

In the above-mentioned review pain was commonly the first symptom and had been present for from 6 weeks to 17 years Tenderness was the initial symptom in one case and had been there for 8 years Sometimes the presence of a tumour or mass first attracted attention.

It is a slow-growing tumour whose origin is unknown. There is no agreement as to whether the epithelial tumour is a basal cell or squamous cell carcinoma Microscopically it consists of solid strands, sheets or whorls of dark staining polygonal or spindle-shaped cells, often with a tendency towards a syncytial character It shows a tendency to form clefts and cysts and in most cases there are collections of cuboidal cells arranged in irregular acini. The treatment of choice is amputation, preferably through the more proximal bone. Baker *et al* base this opinion on the fact that the tumour is almost certain to recur. In 17 of their 27 cases recurrence took place, followed by death in 8 cases. Metastasis was proved by biopsy in 4 cases, further emphasizing the need for radical surgery. It causes local bone destruction Metastases to the inguinal glands have been described.

Neurilemmoma

This is a type of nerve sheath tumour which has had a variety of names in the past, but, as it is generally agreed that it is a tumour of the neurilemma, the term neurilemmoma is in general use

The tumour has been described as growing in bone but these are rare Morris-Jones described three cases in long bones and two in the sacrum Clinically the tumour may show as a cystic swelling. The X-ray shows a destruction of the bone. The common and often only symptom is the physical presence of a tumour. This is always single and circumscribed. The clinical course appears to be benign and local removal appears to be adequate Diagnosis is not made clinically or by radiology, but only by the histology.

Chordoma

Chordoma is a rare malignant neoplasm found at either extreme of the spinal axis and occasionally elsewhere in the spinal column. It is generally accepted as originating from embryonic remnants of the notocord Although in the adult remnants of the notocord persist in the intervertebral discs in the form of nucleus pulposus the majority of chordomas arise either in the spheno-occipital or sacro-coccygeal region and some 60 per cent of them in the latter area. The physical presence of a tumour is usually the first symptom though there is often

Clinical Features

While in a majority of instances skeletal metastases are a late feature of the disease and appear after the nature of the primary lesion has been recognized, it is not infrequent for the initial feature to be caused by the secondary deposit in bone. This is especially common in renal and thyroid carcinomata

Pain related to the spine, hip or shoulder, the development of paraplegia or the occurrence of a spontaneous fracture are the commonest features The presence of a neoplasm will be revealed on radiological examination There may be doubt as to whether the tumour is primary or secondary and occasionally biopsy may be necessary to establish the diagnosis.

Treatment

1 *Palliative* As a palliative treatment some form of radiotherapy is the most likely to produce some benefit Both the linear accelerator and the radioactive cobalt beam unit are used The supporters of the former method point out that its much greater output, and therefore treating capacity, will allow it to treat as many patients in a day as two or more cobalt units

Skeletal metastasis from breast tumours may be treated by adrenalectomy (with or without oophorectomy) or hypophysectomy, both of which, according to Greening, have a mortality rate of 5–6 per cent It is established, however, that some breast cancers are "autonymous" and not hormone dependent so that in the former endocrine surgery is useless The types, however, can be distinguished from a study of the urinary calcium levels in patients with mammary or prostatic cancer and osseous metastasis Hormone therapy with Stilboestril is used for prostate secondaries

2 *Treatment of Pathological Fractures* Although the prognosis is poor in fractures due to cancer, vigorous treatment of the fracture will in most instances relieve pain, shorten hospitalization, make nursing care easier and allow the patient to be moved for supplementary forms of therapy In a significant number of cases, probably about 20 per cent, bone union does occur Two-thirds of the cases of pathological fracture are secondary to breast cancer, and tumour of the kidney accounts for 10 per cent.

In treatment everything possible is done to avoid recumbency. Compression fractures of the vertebræ do poorly in plaster jackets and most do not require immobilization if discovered before compression has proceeded too far In these cases, of course, irradiation and hormone therapy are of value.

The most useful method of immobilization, and particularly in the most common—the upper end of the femur—is by an intramedullary nail It may be done in cases of imminent fracture as judged by X-ray and prevents pain, possible shock, and displacement of fragments. The patient then is in better condition and the procedure less shocking and

in the adult and it is held that the rich capillary network here present is the determining factor. It has been suggested too that the red marrow is a tissue favouring the growth of tumour implants.

Batson has described an alternative route for the dissemination of malignant cells. He has shown that the vertebral venous system, which possesses no valves, communicates freely with the venous channels of the chest wall, the intra-thoracic and abdominal viscera When the intra-thoracic or intra-abdominal pressure rises as in coughing or sneezing or straining a reverse flow of blood in the venous vertebral system can occur. By this method malignant cells, it is postulated, may be carried into the bodies of the vertebræ or reach the central nervous system.

Hæmatogenous spread results in multiple secondary growths which initially are found in the red marrow. These appear as spherical tumours replacing the cancellous bone These nodules expand, destroying the bone as they do so but characteristically causing little reaction beyond the actual limits of neoplastic invasion. Cortical bone and cartilage resist the invasion to a much greater extent The destruction of bone eventually leads to such weakening that collapse or pathological fracture occurs

The occurrence of "solitary" metastases has been described but there is always doubt about the authenticity of such cases. It would seem more probable that such are examples of disproportionate growth of one of a number of secondary deposits which by reason of its site and size attracts attention It is in clinical practice that the suggestion is most commonly raised but in the living subject there can be no opportunity for verification and the experience of pathologists at exhaustive post mortem examinations is that other deposits can almost invariably be demonstrated. Eradication therefore of such "solitary" secondary deposits is most unlikely to have curative value

The majority of secondary tumours are osteolytic. New bone formation resulting from periosteal reaction is, however, occasionally observed. As the periosteum is raised from the underlying bone by expanding tumour in the subperiosteal space it may lay down layers of bone parallel to the surface. These appear radiologically as "onion" layers and are particularly common in secondary neuroblastomata In other instances radiating spicules of new bone, simulating the "sun ray" appearance of the osteosarcomata appear but may be differentiated by greater coarseness and irregularity of the spicules. This latter appearance is especially common in the flat bones.

Metastatic carcinoma of the prostate is associated with new bone formation (osteoplasia, osteosclerosis) The tumour cells produce much acid phosphatase and are responsible for deposition of new bone both in the cancellous zones and below the periosteum. Owing to the osteosclerosis, fractures are less common in secondaries from prostatic lesions

Favourable Effects

1. Recalcification.
2. Decrease in size of the tumour with disappearance of abnormal bone and tissue.
3. Healing of pathological fractures

SYPHILITIC DISEASE OF BONE

Syphilitic affections of bone occur in the inherited and acquired forms of the disease, and in the latter they are more serious in the tertiary stage They differ from tuberculous affections in that the shaft is more frequently involved, while the joints escape. The inflammation is the result of the presence of the Treponema Pallidum which may be demonstrated in the bone marrow 36 hours after infection and prior to the appearance of clinical evidence of disease The granulation tissue that develops from this inflammation differs from ordinary granulation tissue in that the leucocytes are chiefly of the lymphocytic variety This granulation tissue may undergo complete resolution, especially where anti-syphilitic treatment is carried out at an early stage, but if the resolution is delayed long enough, well-formed connective tissue—either fibrous or osseous—may develop. In some cases the granulation tissue may be of such a delicate nature that it dies before any attempt at organization has occurred, and a gumma is formed; such gumma formation results from a general lowering of the vitality of the tissues due to the disease itself, and from the fact that many of the vessels in the perishing tissue are occluded by the proliferation of their endothelial lining

Predisposing causes of Bone Lesions. Bone marrow is one of the chief seats of the Treponema Pallidum, but notwithstanding this widespread infection of the bones it does not by any means follow that a definite syphilitic lesion will develop, the Treponema may be held in check until some influence, often a local one, upsets the state of equilibrium Traumatism, exposure to cold, and dampness may serve the purpose but trauma is not such an important factor as was at one time considered Nevertheless the tibia, the femur, the humerus, and the cranial bones, which are more exposed to extraneous influences, are the most common sites of syphilitic osseous disease

Bone Manifestations.

1. **Ostealgia.** This may vary from a very slight dull ache up to the most excruciating pains Often migratory, usually intermittent, and not infrequently nocturnal exacerbations interfere with sleep. There are no local abnormalities detectable by clinical or radiological examination and a diagnosis of neuralgia or neuritis is often made. Failure on the part of salicylates to give relief should lead to a suspicion of syphilis and blood serological tests will invariably confirm this Anti-specific treatment is rapidly effective

smaller in magnitude than would be so after fracture. The presence of an intramedullary nail does not preclude adequate radiation therapy. Intramedullary nailing may spread tumour cells along the medullary canal but its advantages far outweigh the risk of further spread of the tumour.

Technique

(*a*) *For actual fracture.* Open nailing is used The fracture is exposed by a postero-lateral incision in the thigh. An intramedullary nail of predetermined length is passed up the proximal fragment in retrograde fashion, emerging through the great trochanter and a stab wound in the buttock. The nail is then driven down to the fracture site and the fragments reduced and the shaft aligned. The nail is then passed across the fracture site well down into the distal fragment either with or, usually, without X-ray control.

(*b*) *For imminent fracture.* Closed nailing is used. The nail is passed, under X-ray control, down the medullary canal over a guide pin which has been inserted down the shaft from the greater trochanter region.

Radiotherapy for Tumours of Bone

Although the results from irradiation are still uncertain, it must be considered for certain tumours and situations where surgery has so little to offer. Accurate pathology from biopsy is essential and it is now considered this can be carried out without the possibility of spreading the original tumour.

Indications

1. *Radiosensitive tumours.* The giant cell tumours, or chondromata, respond to radiotherapy and this form of treatment is particularly indicated when the tumour is situated in the flat bones, i e. the scapula or pelvis of adults, or near the epiphyseal plate of children The response is slow and it may take several years for the disappearance of the tumour and recalcification to appear. The Ewing's Tumour is also radiosensitive and there is a good response initially. The osteogenic and reticular cell sarcomata are radio-resistant and possess a marked tendency to metastases to the lungs.

2 *Relief of pain* This palliative effect is worth while even though the survival rate is unaltered, and it has proved of value in pathological fractures resulting from sarcomatous degeneration in Paget's Disease, and in multiple myelomatosis

3. *Tumours in such a situation* that they cannot be removed surgically, or are too extensive to remove without producing gross morbidity and mutilation.

4 *As a pre-operative treatment* and this may even improve the survival rate or the surgical result.

Contraindication — Chondroblastoma

affecting the whole bone, or the greater portion of it, inside its periosteal envelope All parts of the bone are involved, the condition apparently starting in the interior, and spreading up and down to the extremities of the bone, and in young people—especially inherited cases—to the epiphyseal discs. It also spreads outwards through the compact shell, and evidence of periosteal inflammation appears upon the surface of the bone.

The diffuse character of the affection is due to the permeability of the medullary tissue which fills the spaces in the bone, and to the reaction produced in the medulla by the circulation of toxins in a feebly concentrated form.

A bone suffering from this generalized osteoperiostitis is heavier and harder than normal, and shows some periosteal deposit over the whole or greater part of its surface. The interior presents a uniform surface of densely sclerosed bone, involving the cancellous ends, the medullary canal, and the compact bone with its periosteal thickenings. In younger cases the epiphyses may be irritated and a very marked increase in the length of the bone be produced

In both types of this osteitis deep-seated pain in the bone is apt to be specially troublesome, and, when the patient is in bed, it may be of such a distressing and intractable character as to make life almost unbearable When anti-syphilitic preparations have no effect upon these pains, relief may be obtained by gouging a trench in the bone, and so diminishing the tension of the inflammatory products within the bone spaces

Occasionally in both of these types, on section, or in an X-ray photograph, a double outline is seen which is very characteristic of syphilis. A second sheath of compact bone overlies or surrounds the original compact layer, but an intervening space exists which may be filled with cancellous bone or granulation tissue. Such an appearance is due to the fact that the periosteum has been lifted from the bone by developing granulation tissue, and a fresh layer of compact bone formed on its under surface

5. Syphilitic Inflammation at the Epiphyseal Line. Osteochondritis. Most children with inherited syphilis show an irregularity of the epiphyseal line, which results in the line becoming toothed, instead of being a straight line across the bone at right angles to the shaft This irregularity is due to abnormal transformation of cartilage into bone, as a result of which not all the cartilage is changed into bone at the same time, but irregular lines of cartilage extend into the diaphysis.

Epiphyseal lesions may be discovered in the early weeks of life by radiological examination, long before the appearance of localizing signs or symptoms It should be suspected when an infant during the first half-year loses the use of one limb without apparent injury. The upper end of the humerus is the commonest part to be affected and is usually the first to be attacked when several epiphyseal regions are implicated.

2. Periostitis. Periostitis frequently occurs and affects multiple long bones of the extremities The bone changes may be present at birth or develop later They are frequently asymptomatic and are often detectable only by routine radiological examination.

3. The Periosteal Node. The characteristic lesion is a localized swelling of the shaft, oval or fusiform in shape, which involves usually a portion of the circumference, and may, indeed, even surround the bone. This type of lesion is commoner in inherited syphilis but may occur in the acquired form The bone most commonly affected is the tibia, which is often thickened for a considerable portion of its length, and usually upon its subcutaneous surface, the swelling shading off as it passes under the muscles The sharp anterior crest of the tibia is replaced by a rounded surface, whilst the other borders are also apt to lose their definition, and the thickening may be so pronounced in front as to give rise to the impression that the bone has become bent. The femur, humerus and ulna may also be attacked.

Tubby has pointed out important points of differentiation between this curvature of the tibia and that seen in rickets ·

	Rachitic Curves	Syphilitic Curves
Age . . .	Generally under 3	Occurs up to 15
History . .	Signs of rickets present	Syphilis in parents, and signs of inherited syphilis in child
Direction of curvature	Antero-lateral or antero-medial.	Generally purely anterior (*Tibia en lame de sabre*)
Position of curve.	Generally in upper or lower third	Middle of shaft
Crest of tibia	Sharp	Smooth and rounded.
Surfaces of tibia	Flat or concave	Convex

In dried specimens the surface of the new bone is grooved by an enormous number of vascular channels, evidence of the great vascularity of the periosteum in the formative period Later the vascularity disappears as the new bone gradually becomes hard and sclerosed.

These swellings in the early days are painful, tender, and firm, but rarely show any inflammatory redness As organization of the new tissue occurs the swelling ossifies and becomes permanent. In its simplest form the node is a purely periosteal affection, but soon begins to attack the bone itself and spread into it. The compact tissue underlying the node is rarefied, then the cancellous tissue adjacent is involved, lastly the medulla of the central cavity is affected, and in due time the rarefaction gives place to a sclerosing osteitis

The condition is nearly always a local one, and is to be distinguished from the diffuse inflammatory condition to be described next, although more than one node may be found on a single bone.

4. Diffuse Osteoperiostitis. This is a chronic inflammation

CHAPTER V

TUBERCULOSIS OF BONE

Tuberculosis of bone is one of the most serious and one of the most crippling of the maladies of childhood, and, for obvious reasons, its economic importance is great. Its ravages are not confined to the early years, and a fair proportion of cases occurs amongst adults.

Etiology

Certain features of the etiology are of interest.

1. The Nature of the Infecting Organism. The tubercle bacillus of bone infections may be either of the human or the bovine type, and the relative percentage of each has been variously stated by different authorities. Bovine infection used to be four or five times more common in skeletal tuberculous than the human type but a reversal of this has taken place and in a recent investigation of 950 patients 26 3 per cent. had bovine tuberculosis and 73·7 per cent were infected with the human type It is believed that the bovine type is becoming still more uncommon

2. The Route of Infection. Tuberculosis of bone is almost invariably secondary; it is but a local manifestation of a general disease, the original site of which is usually in the bronchial or the mesenteric glands. From the primary focus the bone is invaded usually through the blood-stream, but occasionally the bone infection is by contiguity from a neighbouring tuberculous joint or from infected soft tissues.

3. Predisposing Factors. The factors which favour the development of the disease are general or local. The former may precipitate, or make possible, the infection of the subject with tuberculosis, while the local factors favour its localization in bone. Among the general conditions may be included the Exanthemata, diseases associated with considerable debility such as influenza, and bad hygienic surroundings.

The actual incidence of the disease in bone raises interesting points The resisting power of bone is high, and the experimental production of tuberculous osteitis wellnigh impossible. This immunity of normal bone is due to the powerful resistance offered by the marrow, and it follows, therefore, that before the bone succumbs, the natural defence must be broken down In this connection it has been amply demonstrated that

There is as a rule some thickening about the epiphysis, pain on passive movement, and probably other signs of syphilis Suppuration may take place and separation of the epiphysis result, but when this occurs it is probably the result of secondary infection

6. Gummatous Periostitis: Gummatous Osteomyelitis. Syphilitic inflammation may assume the form of gumma, either on the surface of a bone, or in its interior The condition is usually localized and may show no very definite boundary in either case

The surface gumma resembles an ordinary periosteal node except that it speedily softens at its centre The skin becomes inflamed and ulcerates, and the well-known tough yellow slough is exposed. The slough slowly separates and exposes the bone which is found to be bare and either carious or necrosed Caries is due to the rarefactive influence of the granulation tissue invading the bone, and necrosis to its caseation or to secondary septic infection

A gumma in the interior of a long bone is a serious condition because it is apt to be mistaken for a malignant tumour. It may be responsible for spontaneous fracture.

7. Syphilitic Dactylitis. The importance of syphilis of the phalanges lies in the fact that it may be taken for tuberculosis It is met with chiefly in children and affects any of the toes or fingers, but is commonest in the proximal phalanx of the index finger or thumb. More than one finger may be affected, and marked shortening and deformity result Thickening, increased density, expansion, and even absorption of a bone may take place, and open sores may form. The lesion consists of a gummatous osteomyelitis There is little tendency to break down and ulcerate as in tuberculosis The finger presents a fusiform swelling and though the movements are impaired the condition is usually painless The diagnosis may be made from other signs of inherited syphilis In its early stages the disease is amenable to anti-specific treatment and complete recovery is the rule

Miscellaneous data regarding Syphilis of Bone.

1 The Wassermann and/or Kahn blood serological reactions are positive in all early cases and in approximately 80 per cent. of late bone lesions

2. The ratio of syphilitic arthritis to syphilis of bone is about 1 to 7.

3. Radiological examination during the first six months of life is extremely valuable both in regard to diagnosis and prognosis.

4 Many case histories do not support the common belief that nocturnal pain is so common as was at one time considered but it is nevertheless important to bear it in mind

5 Response to penicillin is similar to that achieved by arsenic and bismuth and, owing to the tendency to relapse, especially in acquired syphilis, evaluation of penicillin in the treatment of bone syphilis is impossible

the resulting clot the tubercle bacilli settle down, and eventually a typical tuberculous follicle is formed, with endothelial cells, lymphocytes, and giant cells. As the original follicle enlarges, others appear around it and fuse with it, until the combined mass is visible to the naked eye as a small white nodule in the centre of the marrow. Caseation later becomes evident at the centre, while there is an attempt at fibrosis at the periphery. If the caseation is the predominant feature the disease in the absence of localizing fibrosis spreads, and the result is an "*infiltrating tuberculosis*," while if the peripheral fibrosis is well marked, the process is arrested and the result is localized or "*encysted tuberculosis*."

Apart from the phenomena in the actual tuberculous nodule widespread changes are apparent in the various bony components

FIG 112.—Tuberculosis of Bone
Disease of the proximal phalanx of the great toe with a small sequestrum

(i) *The Marrow*

During the early days of the disease, immature polymorphonuclear leucocytes appear, which later become fully developed. They are actively phagocytic and contain altered blood pigment After a few days the polymorphs are replaced by lymphocytes and mononuclear cells, whose presence is characteristic of tuberculosis If now the disease becomes arrested, fibrotic changes ensue. The lymphocytes disappear, while the fat cells increase in number, and young fibrous tissue appears in their midst Fibrosed marrow is yellowish-white in colour, and firm in consistence, the microscopical appearance of the fat cells, embedded in fibrous tissue, has been aptly likened to that of a mosaic.

a tuberculous toxæmia is accompanied by a change in the marrow, which undergoes a fibro-myxomatous degeneration, the result of which is to diminish considerably the high degree of immunity.

With regard to the actual localization of the disease in individual bones a second important factor comes into play. Fraser has shown that in certain bones, and in individual localities of the bone, a more direct cause is at work. The blood-vessels which supply the bone become the site of a tuberculous endarteritis, as a result of which the degenerative change in the marrow is aggravated and the liability to infection correspondingly increased.

The Influence of Injury. A history of trauma is common, and there seems little doubt that injury bears some relation to the development of the disease in the particular bone in a patient in whose blood the organism is circulating The injury is usually slight. Extensive injury would be associated with such a profound reaction that there would be little or no chance of an organismal infection surviving The slighter traumata are such, however, that they result in small intra-osseous hæmorrhages or effusions, in consequence of which some degree of vascular stasis occurs. Such a temporary stagnation of the circulation favours the deposition of the organism in the injured area Girdlestone thinks that local injury can be excluded from causal relationship with the lesion unless it occurred more than a month and less than six months before the development of the initial symptoms.

Pathology

The Site of the Infection. The disease may originate in the centre, or at the periphery of the bone. In long bones, like the tibia and the ulna, it arises as a tuberculous osteomyelitis, usually in the metaphysial area, for reasons similar to those which make pyogenic osteomyelitis particularly common in this situation In short long-bones, e g the phalanges, the process often begins in the diaphysis, owing, it is usually held, to the peculiarity in the arrangement of the nutrient vessel, which breaks up to form a network immediately it gains the interior of the bone, in sharp contrast to its behaviour in the long bones in which it finally becomes plexiform in the metaphysis. In the ribs and in the skull, the tuberculous infection is primarily a periosteal one, while in the vertebræ it may commence either as a periostitis, or as an osteomyelitis in the centre, or diaphysis, of the bone. The epiphysis appears to be relatively immune to tuberculous infection, but it does occasionally succumb, especially when the disease extends from an adjacent joint

The Sequence of the Pathology. Reference was made above to the probability of a pre-existent fibro-myxomatous degeneration of the marrow and the preceding endarteritis of the blood-vessels. Under the influence of even a slight injury the weakened vessel walls are liable to rupture, and produce a small extravasation of blood In

lamellæ; the fibrous elements at first persist, but ultimately they merge into the fibrous tissue of the adjacent tuberculous nodule. Both those processes may occur in the same bone.

(*b*) OSTEOSCLEROSIS is the result of osteoblastic activity. The osteoblasts arrange themselves along the surface of the lamellæ and, under their influence, successive layers of new bone are deposited The new bone is distinguished from the original by its greater number of bone corpuscles, and by staining a lighter colour, there is also a distinct line of demarcation between them. Osteosclerosis is characteristic of the chronic types of disease, and tends to limit its progress.

(*iii*) *The Periosteum*

The increased vascularity of the periosteum is one of the earliest signs of tuberculous infection of bone, it is soon followed by subperiosteal thickening, due to a deposit of new bone, which may be either porous or dense. Osteoclasts and osteoblasts are normally present in the deeper layers of the periosteum, and it is to their agency that the production of new bone is due. There is first an activity of the osteoclasts resulting in erosion of the surface of the bone, which therefore becomes rough and irregular. The osteoblasts then proliferate, and a thin layer of new bone is laid down on the uneven surface The preliminary roughening of the bone surface diminishes the risk of the delicate new bone becoming dislodged. On the completion of the first layer a second is begun, numerous conical projections or spines of bone appear on the surface of the first layer, granulation tissue occupying the interspinous intervals The extremities of adjacent spines fuse to form arches, and a layer of porous bone is thus laid down The process is repeated until a series of such layers has been deposited, and the circumference of the bone greatly increased The whole process is an extremely ingenious one since it combines, as Fraser has pointed out, the maximum of strength and the minimum of weight

Dense bone is formed in a similar way, except that in the second stage arches are not formed, and the bone remains compact throughout This is the form of deposit that usually occurs in the neighbourhood of joints

Macroscopic Varieties of Bone Tuberculosis.

The microscopical changes described above are common to all forms of tuberculous lesion In addition every case can be placed, according to Fraser, in one of the following macroscopic groups each possessing distinctive characteristics:

(*a*) Encysted;
(*b*) Infiltrating,
(*c*) Atrophic,
(*d*) Hypertrophic.

1. The Encysted Variety. Here the diseased area has been shut off from the rest of the bone by a limiting wall of fibrous tissue. This is the commonest type of osseous tuberculosis, and the most chronic.

Macroscopic Appearance The size of the follicle varies from a pea

(*ii*) *The Lamellæ*

The lamellar tissue may undergo two types of change. There may be absorption, or rarefaction (osteoporosis), or there may be thickening or increased density (osteosclerosis) Usually both processes are at work simultaneously.

FIG 113 —Tuberculosis of the Lower End of the Radius, with involvement of the Wrist Joint

(*a*) OSTEOPOROSIS Rarefaction of the lamellæ is brought about either by true absorption of bone or by metaplasia. In true absorption, the osteoclasts appear beside the lamellæ, and produce a series of tiny excavations known as Howship's lacunæ. Portions of bone, over a large area, are thus progressively removed and replaced by a fibro-cellular marrow, and the individual lamellæ in this way acquire a worm-eaten appearance In metaplasia the lime salts disappear from the bone

(c) Outside this grey zone there is a red band of congested marrow. The transition is a gradual one, and frequently the line of junction is indicated by a strip of pale pink tissue which represents the area of invasion of the marrow by tubercle.

Microscopic Appearance. The process is inaugurated, as usual, by the accumulation round the bacillary embolus of clusters of endothelial cells. These individual groups coalesce, and a big area of diseased tissue is formed, composed of lymphocytes and endothelial cells with a scanty amount of intercellular fibrous tissue. About this time the diseased vessels become thrombosed, probably as a result of the destruction of the endothelium. Owing to the consequent arrest of the blood supply the resistance of the follicle is diminished, and caseation begins in the centre. The coalescence of adjacent caseating areas produces the typical yellow appearance of the central area



Fig 115—Periosteal Tuberculosis of the Radius.

The process is so rapid that many of the lamellæ are not absorbed before the blood supply is finally cut off and are, in consequence, converted into sequestra. Indeed, when the disease is very rapid, a complete lamellar area may thus become necrosed to form a large sequestrum, which remains in contact with the surrounding bone until it becomes separated by granulation tissue. This form is known as a "composite" sequestrum

Polymorphonuclear leucocytes collect around the periphery in the same way as in an acute pyogenic infection and for this reason it has been suggested that a mixed infection is the dominating factor in infiltrating tuberculosis A modification of the process is sometimes seen in the form of a limiting fibrosis, and as evidence of this a pink band may be seen between the actual infiltration and the marrow.

to a walnut The centre is at first composed of jelly-like substance, through which opaque grey spots are scattered Later, the central mass caseates, but an encapsulating shell of the original gelatinous matter persists, surrounded by a zone of pinkish-white tissue merging at its periphery into the marrow. The marrow is congested, but, being otherwise little affected, is in sharp contrast to the encysted nodule. In course of time the central tissue becomes semi-fluid as the result of degenerative changes, so that the follicle ultimately acquires a cystic appearance. The lamellæ enclosed during the stage of active extension undergo rarefaction and absorption; the disease is so chronic that this is usually complete, but occasionally the absorption is imperfect, necrosis occurs, and small sequestra known as "bone sand" are formed

Microscopically, the lesion in its early stages consists of a loose reticular follicle, corresponding to one of the grey pinpoint foci noted on naked-eye inspection of the bone. The groundwork is composed of branching connective tissue cells, and its interstices are filled with lymphocytes, endothelial cells, and, usually, giant cells.

Fig 114 —Encysted Tuberculous Focus in Humerus

2. The Infiltrating Variety. This is the acute type of bone tuberculosis Nelaton pointed out that it occurs most often in enfeebled infants and in aged people, in whom it actually appears to be the usual type.

Macroscopic Appearance. Three areas of the bone segment are visible.

(*a*) A central area composed of caseous debris This is pale yellow in colour and crumbles when touched, and consists of the rarefied bony framework, the interstices of which are filled with tuberculous debris Nelaton has accurately called it a "pus-forming infiltration."

(*b*) An intermediate zone of grey semi-transparent tissue, merging imperceptibly into the central area and into the outer zone It is here that the tuberculous process is most active, there has been an infiltration of tuberculous granulation tissue between the lamellæ, but it has not yet had time to caseate.

Like the atrophic form, the disease is usually situated at one or other of the extremities of the bone.

Macroscopic Appearance. The bone is diffusely thickened over an area extending from the junction of the metaphysis and the epiphyseal cartilage to about the middle of the shaft. The periosteum is easily detached, and in the later stages there is a deposit of new sub-periosteal bone. When the bone is divided transversely, its cut surface appears dense, strong, and sclerosed. The sclerosis, which is not uniform, is due to endosteal proliferation. In the centre of the shaft there is an area of grey semi-fluid material, embedded in which is a sclerosed sequestrum

Microscopic Appearance

(*a*) Changes in the Blood-vessels. These are the first changes to be observed, and the other effects arise in consequence of them. The vascular changes occur in the primary branches of the nutrient arteries, near their origin, the first departure from normal being the occurrence of an effusion of lymph round the vessel, producing œdema of the vessel wall, which begins to show some endarteritis. The effusion later becomes organized and converted into granulation tissue, while the endarteritis progresses till the lumen is finally obliterated.

(*b*) Changes in the Lamellæ. When the vascular changes have taken place, the lamellæ surrounding the vessels undergo fibrous metaplasia and absorption, in response to the disturbance of nutrition. The space formed by their absorption is occupied by fibro-myxomatous tissue. Outside this central area of absorption sclerosis occurs, from the deposit of new bone on the lamellæ by osteoblasts which have multiplied in the tissue lining the lamellar surfaces. This thickening is purely endosteal, and results in firm, dense bone.

The essential features, therefore, in the production of a hypertrophic tuberculous bone lesion are :

1. The initial endarteritis, induced by the circulation of tuberculous toxins in the blood

2. Consequent disturbance of nutrition which results in absorption of the bony lamellæ surrounding the obliterated vessel, and their replacement by granulation tissue

3. Sclerosis of the peripheral lamellæ in response to the irritation caused by the central changes.

Clinical Features

Tuberculous disease of bone is insidious in its origin, but steadily progressive The disease may be considerably advanced before clinical evidence of its presence is obtained, though often there has been evidence of tuberculous toxæmia for some time previously. The child may have been pale and easily tired, or shown disinclination for his usual pursuits The appetite may have been impaired and the mother may have noticed profuse perspiration during sleep—the so-called "night

While these changes are taking place in the marrow, there is an associated activity in the periosteum which results in the formation of new bone on the surface of the shaft

The characteristic features of infiltrating tuberculosis are therefore:

(*a*) The multiplication of endothelial cells and their aggregation into a dense mass.

(*b*) The early occlusion of blood-vessels, by thrombosis due to destruction of their endothelium

(*c*) Early and rapidly spreading caseation.

(*d*) Necrosis and sequestration before rarefaction is complete.

(*e*) Little attempt by the tissues to circumscribe the process.

3. The Atrophic Variety. The distinctive feature of the atrophic variety is the wasting and atrophy of the bone lamellæ. This is seen most characteristically in caries sicca of the shoulder joint, where the original lamellæ at the upper end of the humerus are replaced by granulation tissue, and bone of a very fine texture is laid down on the surface, increasing the diameter of the shaft.

Macroscopic Appearance. The disease usually attacks the metaphysial area of the shaft The bone end is thickened, but is lighter than healthy bone, and its surface yields to moderate pressure with a peculiar crackling sensation There is usually a thin layer of new sub-periosteal bone, but on cross-section the interior is seen to be composed of granulation tissue in which atrophied lamellæ are scattered. The granulation tissue is reddish in colour and throughout its substance there are numerous spaces which give it a spongy appearance Similar changes may also be found in the epiphysis, even as far as the articular cartilage, which, however, is never itself involved

Microscopic Appearance. The distinctive feature is the conversion of the marrow into a form of granulation tissue—a myxomatous connective tissue characterized by great vascularity, and showing a strong tendency to cystic degeneration. Tuberculous follicles are scattered throughout this mass, and give the section a reticulated appearance. Fibrosis takes place gradually.

The lamellæ are rapidly absorbed by halisteresis and osteoclasis. The periosteum is similarly affected, and a mass of highly vascular subperiosteal bone is deposited. As soon as the new bone is formed, its deeper layers, which adjoin the shaft, are absorbed, leaving a layer of granulation tissue between the shaft and the sheath of new bone. Thus although the circumference of the affected bone is increased, its quality is highly defective

4. The Hypertrophic Variety. This is a rare form of osseous tuberculosis, characterized by a lavish formation of new bone, or osteosclerosis, and in many cases it results in the production of a large sclerosed sequestrum It is possible that syphilis plays a part in this type of bone tubercle Thickening of the lamellæ is the outstanding feature—in contrast to the atrophic variety in which absorption predominates,

The picture in the "infiltrating" type is less characteristic There is a diffuse change consisting of disappearance of the lamellæ, with, here and there, some cavity formation. There is almost invariably a deposit of new sub-periosteal bone, and there may be a composite sequestrum

In the atrophic type the end of the bone is enlarged, but is only a shell of its former self owing to the extensive absorption of the lamellæ. In the hypertrophic type, on the other hand, the bone is also increased in girth, but the disease is usually situated at or about the centre of the shaft, and the density is considerably increased. There is little or no sub-periosteal bone, the sclerosis is endosteal, and occasionally in the centre of the dense area there is a sclerosed sequestrum.

Diagnosis

The diagnosis is reached after considering the history, the clinical examination, and the radiological appearances of the condition.

The history is of value in revealing a story of a gradual onset, possibly some weeks after an injury, and thereafter some interference with function and some swelling of the part and, it may be, pain. The family history may tell of other members infected or of some previous personal trouble with the same disease. There is usually a definite loss of weight, health and energy.

Help may also be sought from the various specific tests—e g the Mantoux intra-dermal test, von Pirquet's cutaneous test, or the focal tuberculin test, since if they are negative tuberculosis can be almost excluded The sedimentation rate is of little value in diagnosis because of its non-specificity An increased rate tells us only that something is wrong in the body, but neither where nor of what kind.

If there is an abscess it should be aspirated, and if neither cocci nor bacilli can be discovered the fluid is centrifuged and a guinea-pig inoculated, killed after six weeks and examined for signs of tubercle. In adults a biopsy of the part or of a regional gland is useful.

Differential Diagnosis

Tuberculosis of bone has to be distinguished from the following:

1. Syphilis of Bone, especially periostitis and osteitis There is usually a history of syphilis, or other signs of its presence, while syphilis of bone is attended with severe pain The radiological appearances are dissimilar, and the Wassermann reaction positive

2. Chronic Osteomyelitis. In this condition, acute or subacute exacerbations occur at intervals, with fever and local inflammatory signs. On radiological examination, there is more necrosis and sequestration, and more sclerosis

3. Sarcoma. The osteogenic sarcoma forms a uniform and more

sweat" of tuberculosis. Ultimately certain features appear which are referable to the local lesion.

Local Signs.

1 Swelling of the affected bone
2. Pain.
3 Muscular wasting.

The local swelling is at first soft and spongy, corresponding to the stage of production of new spongy sub-periosteal bone; later the bone becomes hard. It may or may not be slightly tender to touch. Local reddening of the skin and increased local temperature are uncommon.

Pain is not an invariable accompaniment of bone tuberculosis, as the chronic progress of the disease precludes any great increase in intra-osseous tension. In the early stages, however, a serous effusion beneath the periosteum may give rise to considerable pain, and in the more acute types of the disease—the "infiltrating tuberculosis" type—pus may be held up in the medulla to such an extent that acute pain like that of a pyogenic infection results

A third form of pain is occasionally present—a pain referred to the distribution of nerves which lie adjacent to the bone focus, and which are therefore liable to be irritated

Muscular wasting is a constant feature in bone tuberculosis, but a proportion of this probably arises from disuse of the part.

The Course of the Disease. The disease progresses slowly, and in the commoner forms caseation occurs in the central portion of the shaft. Ultimately the pus extends peripherally and a sub-periosteal abscess forms. If the disease is not checked at this stage the periosteum gives way, the tuberculous debris being extruded into the soft parts, where, following the line of least resistance, it tracks along fascial planes to the surface The skin overlying the abscess reddens, becomes progressively thinner, and ultimately yields, and in this way a tuberculous sinus is formed. If such a sinus becomes infected with pyogenic organisms the prognosis is grave. The child becomes more and more emaciated, the temperature is "swinging," and finally, diarrhœa and albuminuria—evidences of amyloid disease—set in.

Radiological Appearance. The X-ray appearance of bone tuberculosis varies with the type and the stage of the lesion, but in all cases it must be remembered that the radiographic evidence lags behind the disease, and there is thus a delay of, it may be, some weeks after the invasion of the part by tuberculosis before the X-ray shows evidence of it

In the encysted type there is a circumscribed focus, usually in the metaphysis The central region appears as a clear area, all trace of its lamellar structure having been lost. The cavity may, however, contain a sequestrum In the region of the focus the bone is usually rarefied, and there may or may not be a deposit of sub-periosteal bone

TUBERCULOUS DISEASE OF THE VERTEBRAL COLUMN

(Pott's Disease, Spinal Caries)

Tuberculosis of the vertebral column, first described by Percival Pott and since associated with his name, is a slowly developing disease, characterized by pain, spinal deformity, and, occasionally, paralysis.

Incidence and Etiology

Vertebral tuberculosis is essentially a disease of early childhood, the majority of cases starting between the ages of 3 and 5, although in recent years the disease has tended to affect an older age-group.

Pathology

Sites of the Disease. Spinal tuberculosis is met with most frequently in the lower thoracic region Out of a total of over 4,000 cases admitted to East Fortune Sanatorium the spine was involved in 30 per cent. of the cases of bone and joint lesions. Out of 1,284 cases, Whitman found 100 in the cervical, 854 in the thoracic, 317 in the lumbar, and 13 in the lumbosacral segments, and Fraser stated that in 51 per cent of cases of spinal caries, the disease is situated in the region of the tenth, eleventh and twelfth thoracic, and the first lumbar vertebræ. He suggested that this distribution is the result of certain definite influences. In the past, these factors have been considered to be the relatively large amount of spongy tissue in the vertebral bodies, the degree of weight-bearing, and the extent of movement demanded of this portion of the column Fraser pointed out that underlying this explanation is the assumption that the infection is a blood-borne one, but suggested that the importance of the prevertebral lymphatic tissue has been under-estimated. He recalled the fact that the thoracic duct is virtually in contact with the anterior surfaces of the vertebræ at that level, and that into it most of the abdominal lymphatics discharge Since the tubercle bacillus not infrequently gains entrance to the body through the abdominal glands and lymph vessels, it may well be that the close proximity of such an obvious source of infection as the thoracic duct is responsible either for the actual tuberculous infection of these vertebræ, or for a series of degenerative changes which predisposes these bones to the later development of the disease.

At an early stage it is not possible to say how many vertebræ are infected even on a radiogram Double lesions with intervening normal vertebræ are found in 5 to 10 per cent of cases. Tuberculosis in other parts of the body is seen in about 40 per cent. of cases, about half of these being the subject of pulmonary disease

Varieties. The following varieties of vertebral tuberculosis are commonly recognized

(1) *The Central,* in which the spongy tissue of the body is affected This is of the nature of a diffuse osteomyelitis of the body. It is some-

localized swelling at the bone end; its growth is rapid and associated with pain. "Egg-shell" crackling is common

The fibro-sarcoma is also of rapid growth, and pain a marked feature. In either case, the radiological evidence should prevent confusion.

Prognosis

In the average case the outlook is good, for there is a strong tendency to natural limitation and strangulation of the focus The disease is more grave when it affects the very young, when it involves the skull or spinal column, and when sinuses form and become secondarily infected. Death is usually due to tuberculous meningitis, miliary tuberculosis, or amyloid degeneration

The sedimentation rate, although of no value in diagnosis, is use-



Fig 116—Sunlight Therapy.

ful in the prognosis, since any variations in it depend upon degrees of tissue destruction. A rising rate means increase of tissue destruction and accordingly, in the proved tuberculous case, a spread of disease A falling rate means decrease of tissue destruction and consequently healing It is therefore of great value in assessing progress Usually it merely confirms one's clinical impressions, but in certain areas, notably the lungs, it is interesting to note that it is often an early pointer to something going wrong before clinical signs develop.

In this section, reference should be made to the great improvement in prognosis that has attended the efficient sanatorium regime now practically universal in this country The slow but progressive improvement in milk supply should also do much to lessen the incidence of bone tuberculosis

these are undoubtedly the cysts observed occasionally on radiolog examination

Blood Chemistry in Osteitis Deformans

In this disease the serum calcium and the serum phosphorus are usual normal, but there is a very high serum alkaline-phosphatase conten This, however, is by no means specific, for it is a feature of most of th rarefying diseases of bone, and according to Taylor is not related t the cause of the bone disturbance, but is a result of it He suggest that absorption of bone stimulates osteoblastic activity, but the pho phatase is promptly swept into the blood-stream, where it is progressivel destroyed.

The urinary excretion of calcium and phosphorus is on occasion increased and pathological calcification may occur in arterial walls an in the interventicular septum of the heart

Etiology

The origin of Paget's disease is not known. Paget believed it t be inflammatory in origin Lawford Knaggs thought it had a tox basis Others have suggested that it resulted from hyperparathyroidism Beattie states that the only experimental reproduction of Paget's disea has been by the prolonged administration of small doses of Vitamin I

Brailsford regards the disease as a primary localized vascular di turbance with a secondary adverse effect on the bone, and Mercer an Duthie (1956) consider that the vascular disturbance is produced b some form of an arterio-venous malformation not yet demonstrate They found an increase in the bone blood flow sufficient to produ circulatory disturbances compatible with those resulting from an arteri venous shunt and a high blood pressure, and in such cases death fro congestive heart failure is not an unusual occurrence.

Some observations on the diagnosis are made in the table on p 17

Pathological Physiology

The initial lesion is bone destruction without regard to structu the cause of which is obscure. The resultant weakness of the involv bones renders them less resistant to stresses and strains and this lea to a stimulation of osteoblasts and an over-production of bone. T repair is incomplete as the localized disorder causing bone destructi persists The destruction and repair lead to the pathognomonic path logical finding, the so-called mosaic structure.

If a bone containing Paget's disease is immobilized, as after a fra ture, the lack of stress and strain curbs the overactivity of the oste blasts, and the serum phosphatase level, an index of bone formatio falls The initial disturbance causing bone destruction persists a there results a marked imbalance between destruction and formatio The increased calcium and phosphorus coming from the bone leads hypercalcuria and hyperphosphaturia The capacity of the kidney

The skull base shares in the change, but to a less extent, in consequence of its smaller amount of soft spongy bone. Despite the remarkable increase in thickness, the available intracranial space is not encroached upon to any great extent, the new bone being deposited on the external aspect. In the base, however, the neural foramina may be reduced in size.

In **the Spine** the changes are in all respects similar There is thickening, rarefaction, and softening of the various parts and in consequence of the weight-bearing function, some of the bodies may collapse. Secondary changes—synostosis of adjacent bodies, even ankylosis of a segment of the spine—are common. The combined result of the osteitis deformans and its associated deformities is to lead to marked reduction in stature The thickening of the neural arch leads to a reduction in the calibre of the vertebral canal, which may reach a sufficient degree to give rise to evidence of spinal cord compression.

In **the Long Bones** the disease manifests itself by the wholesale removal of the original osseous framework by a growth of vascular connective tissue. In the earliest stages, the vascular connective tissue pervades both the spongy bone and the ivory bone of the cortex; the latter, from patchy absorption, becomes porous and trabeculated. It becomes thickened from the bulk of the connective tissue and the distinction between compact and cancellous bone is completely lost. The periosteum is normal. The thickening of the bone leads to irregularity on the surface, while internally it may lead to considerable reduction in the size of the medullary cavity. As the old bone is progressively resorbed; the connective tissue infiltration demonstrates osteogenic properties, and bone absorption and deposition may thus proceed simultaneously. Ultimately ossification becomes more active, and the enlarged bone is converted into hard, heavy, and apparently strong osseous tissue In the stage of softening and enlargement the bone is apt to become deformed—partly because the soft bone yields to normal gravitational weight-bearing or muscular stresses, and partly, in the forearm and leg, by the fact that one bone may be more involved than its neighbour, and tends to become bent towards it.

The Histology of the Process

In the early stages of the disease there is a diffuse infiltration by young granulation tissue, and the trabeculæ of the bone are attenuated. The Howship's lacunæ are enlarged and occupied by granulation tissue cells or osteoclasts. In the stage of osteogenic activity the sections show numerous trabeculæ of new bone containing an irregular lamellar system which appears typically as a mosaic pattern. These are elaborated from the connective tissue and are irregular in their distribution. They are so numerous that adjacent struts may fuse to enclose an irregular space or lacuna containing connective tissue. These are sometimes erroneously called new Haversian systems Areas apparently of gelatinous degeneration of the connective tissue may be present—

deeply situated and fixed to bone. Pallor and anæmia develop. The B.S R is increased. Fairbank believes that infection—possibly a virus infection—is the probable cause.

X-ray Appearance The cortical walls of the bones which underlie the swellings thicken externally. The subperiosteal shadow encloses a varying length of the shaft or the whole of it. The mandible both early and late is thickened. In time the enlarged porotic bone gradually shrinks away and the shaft resumes its normal appearance, and if this has been curved this is slowly or spontaneously corrected.

Recovery sets in in a few months and is usually complete within 8-12 months

THE RETICULO-ENDOTHELIAL DISTURBANCES OF BONE

The cells forming the lining of the minute blood vascular channels of the bone marrow are part of the reticulo-endothelial system and possess, in common with the other members of this highly important system, powers of considerable activity. The other cell elements of the system are certain adult connective tissue cells (fibrocytes), the endothelium lining blood- and lymph-vessels, the reticulum cells of the spleen, and certain of the large mononuclear cells of the blood.

The functions of the reticulo-endothelial system are as yet imperfectly known, but its cells are typically the scavengers of the body, and their activity is concerned mainly with the removal from the circulating fluid of dead and damaged cells, bacteria, and other foreign or noxious material. It is also energetic in the disposal of such metabolic substances as hæmoglobin and cholesterol.

Red bone marrow consists of blood forming cells as well as reticulo endothelial ones. Affections of any of these resulting in increased volume or vascularity will result in absorption of the adjacent bony trabeculæ In response to continued strain new bone is laid down to buttress the weak site Thus reticulo-endotheliosis or diffuse malignant involvement such as Hodgkin's or myelogeneous leukemia or chloroma will lead to a typical picture. Hodgkin's usually affects spine, skull and pelvis; leukemia usually long bones; and chloroma usually bones of the orbit.

On the other hand, if the malignant involvement elicits a marked response of mature fibrous tissue, such as scirrhous carcinoma, a sclerosis of bone occurs with a heavier bone formation.

In the adult the red marrow is confined to irregular or flat bones or to the ends of long bones. It is here that malignant involvement and bony changes first occur

The reticulo-endothelial tissue of bone is—from the nature of it—mainly congregated at the ends of the long bones and in the spongy bone of the flat and short bones, and it most likely shares in the affections to which the system elsewhere is liable Despite this, bone

excrete calcium may be overtaxed with a resulting hypercalcemia and f fluids are not forced, the diet is not kept low in calcium, and immobilization is not kept at a minimum, a so-called chemical death from hypercalcemia may supervene Although in Paget's disease the broken bone becomes decalcified as a whole, the fracture site shows a rapidly forming and calcifying callus Some local influence which stimulates the osteoblasts is apparently set free at the fracture site.

Treatment

No curative treatment of Paget's disease is known and the most that can be done in the usual case is to relieve the pain Radiotherapy is of considerable benefit in alleviating the bone pain A high calcium diet with a vitamin A and D supplement is recommended by Hunter to compensate for the increased urinary calcium excretion

Internal fixation by some form of intramedullary nailing is worth while for all fractures to relieve pain. Resection of sarcomata should be attempted and the area replaced by some form of prosthesis.

INFANTILE CORTICAL HYPEROSTOSIS

This disease is probably a new entity, since prior to 1930 there are no recorded descriptions, either clinical or radiographic, of a syndrome similar to infantile cortical hyperostosis It is unlikely that earlier clinicians would have overlooked its striking and distinctive clinical and radiographic manifestations

The condition starts in the early weeks of life and is characterized by the formation of subperiosteal bone on the shafts of long bones and on the mandible Males are affected in the proportion of three males to one female. Van Zeben has reported a brother, sister and cousin all with definite signs of the disease

The postnatal disease commonly begins suddenly with swelling of the face and jaw without premonitory signs The infant usually becomes feverish and hyper-irritable In a few cases swellings have first appeared in the legs and arms, and the face becomes swollen three or four days later There is limitation of movement of the limbs and tenderness, but no discoloration, œdema or increased heat The swellings are wood-hard,

Fig 83 —Infantile Cortical Hyperostosis (Mr Mason Brown's case)

show that in some cases the condition actually originates in the bone. The sexes are equally liable, and age bears no relationship to the severity or the frequency of the bone changes. In more than half of the recorded cases pain was the first indication of the osseous spread. Indeed, in not a few instances radiological evidence was delayed for weeks or months or years after the occurrence of the original pain On the other hand, the bone changes are sometimes discovered accidentally.

The pain is of a dull aching, or lancinating, character and may be so severe as to interfere with the function of the neighbouring joints. In the spine there may be girdle pains, and in some cases evidences of cord compression have subsequently arisen.

The bone changes have little or no effect on the constitutional course of the disease.

Diagnosis

Lymphogranuloma of bone is of most interest from the diagnostic point of view, though the occurrence of associated swelling of lymphatic glands and spleen, and the secondary anæmia should make the diagnosis clear.

Treatment

In common with the other lesions of Hodgkin's disease the bone changes appear to respond to X-ray therapy. The pain is relieved and in some cases reparative changes appear in the affected bones.

Histiocytic Granulomatosis

The other three conditions are somewhat rare and obscure but the combined title is preferred because the permanent and constant pathological feature is the presence of numerous histiocytes and granulomatous tissue Farber pointed out in 1941 that anatomically the underlying lesion in eosinophytic granuloma is related to the lesion of Hand-Schuller-Christian disease and that of Letterer-Siwe disease. Jaffe and Lichenstein described these three conditions as different clinico-anatomic expressions of the same disorder.

Lipoid Granulomatosis

Disturbances in lipoid metabolism may give rise to a specific pathological change in the reticulo-endothelial system in which that part of the system situated in the spongy skeleton may participate The actual nature of the lipoid whose metabolism is deranged varies, and so a group of different diseases has been described, though in each the underlying mechanism is similar In Gaucher's disease a lipoprotein of the cerebroside type is at fault, in Niemann Pick's disease a phosphatid lipoid, in Tay Sach's syndrome a cerebroside protein, and in Hand-Schuller-Christian's disease, cholesterol In all of these,

changes have been specifically described in connection with only four of the disorders of the reticulo-endothelial system—

1. Lympho-granuloma—Hodgkin's disease.
2. Histiocytic granulomatosis.
   (a) Lipoid granulomatosis—Hand-Schuller-Christian disease.
   (b) Eosinophilic granulomatosis.
   (c) Letterer-Siwe disease.

The Bone Changes of Hodgkin's Disease

Autopsy records show that involvement of the bone marrow in Hodgkin's disease is more frequent than clinical studies would lead one to suspect, though in the majority of recorded cases the bony lesions have become evident some time after the clinical recognition of the disease elsewhere. Thus in the case of Gage, the characteristic appearance was discovered accidentally through the inclusion of the shoulder in a control X-ray of the chest. The appearance was so suggestive of a neoplastic condition that biopsy was carried out, and revealed the characteristic histopathology of lymphadenoma.

Pathology

The Locus of the Disease in Bone. The vertebral column and pelvis are the bones most often involved. In the vertebral column the bodies of the lumbar vertebræ are the most liable. The cancellous tissue of the upper end of the femur is also a common site. Of the other bones, the diploe of the skull, the ends of the tibia, the lower end of the femur, the ends of the humerus are less commonly affected.

In the cancellous tissue of the affected bone there develops an infiltrating mass of tissue displaying the characteristic histology of Hodgkin's disease The effect on the neighbouring bone is largely coincidental, the cancellous struts are destroyed, and the overlying cortex progressively removed The reaction of the bone adjacent to that undergoing osteolysis varies with the situation. In the vertebræ the destruction is usually so extreme that collapse of one or more of the bodies occurs In the pelvis, areas of rarefaction are surrounded by areas of sclerosis; while in the skull the infiltration is predominantly osteolytic. In the ribs, complete destruction of the affected segment is the rule In the long bones there is often sub-periosteal new bone formation which may be so marked that the lesion resembles chronic osteomyelitis, and is at least definite enough in some cases to simulate a bone cyst. In other cases the lesion resembles sarcoma.

Clinical Features

The bone lesions may appear at any time during the course of the disease, and are apparently quite independent of the exact site of origin of the lesion. It is more than likely that subsequent investigation will

exceeded, the deposits occur simultaneously at different sites in what may be termed "a shower." The distribution of the deposits is widespread. In the skeleton, the diploë of the skull, the cancellous tissue of the mandible clavicle, ribs, pelvis and vertebræ are affected In addition the pleura, the lungs, the liver and the cerebellum have been the site of typical deposits It is apparent that in the skeleton the lesion, though by no means confined to them, yet tends to favour bones developed in membrane.

In this situation, the deposits appear as multiple circumscribed, rounded tumours, which characteristically have a golden yellow or brownish yellow colour

The histology is equally striking The tumours are composed of large, often multinucleated reticulo-endothelial cells, with small nuclei and a finely reticulated cytoplasm. The cytoplasm contains for the most part innumerable globules of lipoid which give the cell a "foamy" appearance The largest foam cells are found away from the vessels, round the vessels are arranged smaller reticulo-endothelial cells, so that, as Fraser demonstrated, the process is evidently one of flow and ebb, the cells congregating round the vessels carrying the excess of lipoid, being charged, and then migrating towards the periphery to make way for others The presence of the deposits of lipoid excites the production of granulation tissue around the periphery and the granulation tissue may infiltrate widely

The Effect of the Granulation Tissue on the Bones is to cause destruction of the bone without new bone reaction. In the skull this gives rise to large defects with irregular margins, in the midst of which the lipo-granulomatous tumours are situated.

The condition in a typical case is well marked on the skull base in the vicinity of the sella turcica. The pituitary gland may be compressed or obliterated and the lipogranulomatous tissue may extend forwards through the superior orbital fissure to collect behind, and protrude, the eyeball. When the collection is marked in the vicinity of the sella, the hypothalamic area of the brain may also be indented. The basisphenoid and the clinoid processes escape.

Clinical Features

The disease, as originally described, consisted of a distinctive syndrome—defects in the membranous bones, exophthalmos, and thirst and polyuria (diabetes insipidus). It is to this triad of effects that the term Hand-Schuller-Christian syndrome is applicable. The exophthalmos is the result of the retrobulbar accumulation of lipoid-laden reticulo-endothelial cells, while the diabetes insipidus is the sequel to the distortion of the hypothalamus

In an individual case, however these striking evidences may be absent until a late stage, while in many cases there are further features Thus interference with the pituitary may lead to retardation

bone changes have been reported or observed, though the main effects of the disease are wrought on the extra-osseous portions of the reticulo-endothelium; but it is only in connection with the Hand-Schuller-Christian disease that the osseous effects have attained a clinical or pathological importance.

Pathology

Fraser presented a very comprehensive review of the condition, and he suggested that the initial change is one of increased lipoid content in the circulating body fluids As a result of this increase, and

Fig. 84.—Lipoid Granulomatosis showing the Excavation of Bone in the Right Temporal Region. (Professor Fraser's case)

in an attempt to adjust the balance, the reticulo-endothelial cells proceed to absorb and deposit the substance, so that accumulation occurs in individual areas That an excess of cholesterol is the essential factor is borne out by the constancy of the hypercholesteræmia, and Fraser suggested that this is the result of a failure on the part of the normal mechanism for maintaining the blood cholesterol content at a constant level. The weight of experimental work appears to suggest that this function is vested in the reticulum of the liver and lungs, though feeding experiments favour the spleen and the lymph nodes as the site of adjustment. It is surmised that a congenital or acquired deficiency in these tissues throws the onus on the reticulo-endothelium elsewhere—especially in bone Fraser supported Chatalon's observation that there is apparently a threshold to cholesterol, and, once

be felt. Blood examination is not characteristic and if eosinophilia is present—and this is not always so—it may rise to 11 per cent

The radiological appearance varies and may simulate other types of disease. Most commonly the lesion is oval or circular, translucent and cyst-like, as though, indeed, a piece of bone had been removed because of its punched-out and sharply defined appearance. In the long bones the lesions are endosteal and usually affect the shafts ; only occasionally is one seen in the epiphysis. There is nothing characteristic or distinctive and the diagnosis is difficult Vertebra plana due to eosinophilic

FIG 85 —The Pelvis affected by Eosinophilic Granulomatosis

granuloma has been described by Compere et al Only one vertebra was affected and this was completely flattened while the neighbouring discs were of normal appearance The early X-ray appearance is osteolytic, then the body of the vertebra disappears. Later the body is flattened and dense

A lesion may resolve spontaneously ; it may heal up after curettage without the aid of radiotherapy, or after radiotherapy alone. The experience of the author is that the affection is very recalcitrant to any form of treatment

PATHOLOGY

The contents of a relatively early lesion consist of soft brownish granulation tissue which may be streaked with yellow necrotic material Patches of hæmorrhage may be present Histologically it shows histiocytes, eosinophils in large numbers, and leucocytes, and large multinuclear giant cells, especially near hæmorrhage or necrosis. The histio-

of growth, and the irritation or tension on the dura mater to irritability and restlessness.

Should the extra-osseous reticulo-endothelium be affected, splenomegaly or hepatic enlargement may be present, and in the latter case jaundice may be observed. The blood shows a cholesterol content which may be raised to as much as 287 mgms. per cent.

Diagnosis

The disease, although at first sight of little more than academic importance, is probably much more common than is realized. The growing number of cases reported in the literature is eloquent witness to this, and Fraser's experience that in two cases an erroneous diagnosis of neoplasm was made, and in one a mutilating and serious operative procedure advised, may well serve to emphasize its clinical significance Fraser also quoted from the literature the case of a child who underwent bilateral removal of the eye for exophthalmos due to skeletal lipoid granulomatosis.

The diagnosis should be based on the age of the child and the characteristic triad of clinical features when present, together with the demonstration of a high cholesterolæmia In all cases a biopsy should be done to make a definite diagnosis.

Prognosis

The disease tends to be progressive, and in many published cases death has resulted from asthenia, or from the contraction of an intercurrent disease.

Treatment

The treatment falls naturally into several distinct parts An attempt is made to reduce the hypercholesteræmia by dietetic means Deep radiotherapy is employed to control the deposits, while in the event of polyuria and thirst from diabetes insipidus, pituitary extract may be exhibited

Eosinophilic Granulomatosis

In this variety a lesion is developed in one or more bones, apparently inflammatory in nature, and closely allied to the lipoid granulomata, though sections reveal an excess of eosinophils and no lipoid deposits.

It is an affection of the young, 64 per cent. occurring under 20 years of age Its cause is unknown, though it is believed to be an infection or toxin of some sort (Fairbank) The lesions, usually multiple, affect the skeleton almost exclusively, although in some cases the glands and the lungs may also be involved The local lesion, though frequently silent, may give rise to local pain and tenderness and even swelling The illness may be initiated by fever Where the skull is affected headache is often a complaint In such cases a hole in the skull may

Hand-Schuller-Christian disease. It usually runs a short and rapidly fatal course and without the secondary deposits of cholesterol esters in the cells of the granulomata. The soft tissues, particularly the viscera, are chiefly affected, although in most cases destructive lesions are found in the skeleton. There is a low and progressive anæmia and lesions are found in the liver and spleen (which are usually enlarged) as well as in glands, lungs, skin, and in the bones of the skull. The X-ray picture closely resembles that of the Hand-Schuller-Christian disease. If the base of the skull is involved the characteristic symptoms of this latter disease—exophthalmos and diabetes insipidus—may develop, although the lesions are without foam cells.

In most cases death ensues within a few weeks. The lesions are of two kinds—nodular and diffuse (Jaffe) The nodular lesions are found in the lymph glands but also in the spleen, skin, and bone marrow The diffuse lesions are found in the lungs, the dura, and in the periosteum overlying a nodular focus

Histologically there is difficulty in distinguishing the condition from the other two forms of histiocytic granulomatosis

The three conditions are compared in the table on page 205.

Gargoylism

This is a form of chondro-osteo-dystrophy characterized not only by dwarfism but also by a heavy, ugly facies, corneal opacity, mental deficiency, kyphosis, distension of the abdomen and enlargement of the liver and spleen Both sexes are affected and few live until growth is complete Fairbank has suggested that it may belong to the group of histiocytic granulomatosis because lipoid deposits have been found in the reticulo-endothelial system. He also states that there is little evidence that heredity plays any part, but familial influences are common

The radiological appearances are interesting and distinctive and bear some general resemblance to the changes seen in Morquio-Brailsford disease In the angular kyphosis one body is usually smaller than the others and is displaced backwards as though squeezed out of line. The displaced vertebral body is concave on its anterior surface, the upper part being deficient and the lower part projecting forward in the form of a "beak" This is most commonly seen in the second lumbar vertebra

There is often delay in the ossification of the carpus The long bones of the hand may be short, thick and honeycombed with the bases of the metacarpals pointed

Fairbank says the condition may remain stationary but as a rule there is gradual deterioration and, of five patients, he says all died before reaching the age of 8 years

cytes may contain droplets and the neutral fat present in the invaded bone or disintegrated cells

Diagnosis

When multiple lesions are present diagnosis from Hand-Schuller-Christian disease is made by the absence of exophthalmos and diabetes insipidus, or on biopsy.

From myelomatosis it is distinguished by the lesions in the skull being larger and less numerous and by the absence of Bence-Jones protein in the urine. Polyostotic fibrous dysplasia has also to be excluded

Letterer-Siwe Disease

This very rare condition, a reticulo-endotheliosis, is met with in infants up to the age of 3 or 4, and is regarded as an acute form of

	Hand-Schüller Christian disease	*Eosinophilic granuloma*	*Letterer-Siwe disease*
Age	Early childhood but occasionally in adults.	Older children, adolescents, and young adults	Infants
Clinical features	Triad of exophthalmos, polyuria, polydipsia, swelling. N B Other pituitary dysfunction	Pain, swelling and local tenderness Systemic manifestations of fever, loss in weight	Low fever, pain and swelling Low-grade anæmia Short and rapidly fatal course in most cases
Localization	Base of skull, spine, ilium, mandible—most common in "membranous bones" Liver and spleen sometimes	72 per cent—solitary lesion involving all bones but mainly ribs, skull, femur, pelvis, humerus Soft tissues rare	Multiple lesions of liver, spleen, glands, skin, lungs and mainly skull
Pathology	Secondary deposition of cholesterol in "foam cells" following formation of granulomata ? unknown infection	Granulomata formation with histiocytes, eosinophils in large numbers, multinucleated cells and areas of necrosis	Eosinophils + +. Foam cells sometimes present True reticulo-endotheliosis
Radiology	Cannot be differentiated		
Blood picture and Biochemistry	Normal Hypercholesteræmia in most cases	"Circulating" eosinophilia Normal.	Anæmia Normal
Prognosis	Slow and benign except in 25 per cent of cases	Good but guarded in multiple lesions.	Fatal

CHAPTER IV

AFFECTIONS OF BONES

OSTEOMYELITIS

Pyogenic infection of the cancellous tissue of bone is known as osteomyelitis

While localized inflammations of the periosteum—periostitis—may occur, organisms are much more likely to attack the marrow of the spongy interstices, and the Haversian systems. Where the process is acute, bone destruction is the rule; and when the process becomes chronic sclerosis occurs.

The Bacteriology of Osteomyelitis. The commonest infecting organism is the staphylococcus pyogenes aureus. Sometimes a staphylococcus albus may be found, in which case the symptoms are less acute. The streptococcus occurs less frequently and is more apt to produce multiple lesions than the other organisms. When the bone is directly infected—from septic wounds—a greater variety of organisms is likely to be present than in blood-borne infections. In addition to those already mentioned, *B. Coli* and the *B. Aerogenes Capsulatus* may be found, particularly in cases where the original injury was a compound fracture The pneumococcus is occasionally isolated and is less virulent than the staphylococcus or the streptococcus Typhoid osteomyelitis is not uncommon especially in the bodies of the vertebrae and ribs, but the gonococcus is rarely found

The Source of Infection. The onset of osteomyelitis usually follows slight trauma In some cases careful inquiry may elicit a history of some general blood infection preceding the injury, since the vast majority are examples of a blood-borne infection The bacteræmia, however, is of a mild type and often its presence is unnoticed. The organisms, however, may have passed into the blood from the tonsils, the respiratory organs, the intestinal canal, genito-urinary tract, or from excoriations, bruises, small wounds or suppurations in the skin.

Certain fevers strongly predispose to the disease, by preparing the "soil" for the growth of pyogenic bacteria Smallpox, malaria, scarlet fever, measles, diphtheria, and influenza, for example, all lessen the vital resistance of bone marrow and favour the development of pyogenic organisms Typhoid fever is not uncommonly followed by chronic

FIG 86 —X-ray of Hands in Gargoylism Note the pointed bases of the metacarpals (By courtesy of Mr Mason Brown)

FIG 87 —X-ray of Spine in Gargoylism (By courtesy of Sir Thomas Fairbank)

the maximum incidence is therefore between 3 and 15 years of age. The responsible factors are the greater liability to trauma and the frequency of mild bacteræmia at this time of life

Boys are more liable to osteomyelitis than girls in a proportion of about 4 to 1 This also, without doubt, is due to their greater liability to injury.

The bones of the lower extremity are more often affected, and, of these, the tibia suffers most frequently The upper end of the tibia is more commonly involved than the lower end; in the femur the lower end—the trigone—is the site of election. The greater amount of growing bone at these areas explains their greater liability to infection. The later the epiphysis joins the shaft, the longer the metaphysis persists in a state of activity, and the greater its liability to become infected

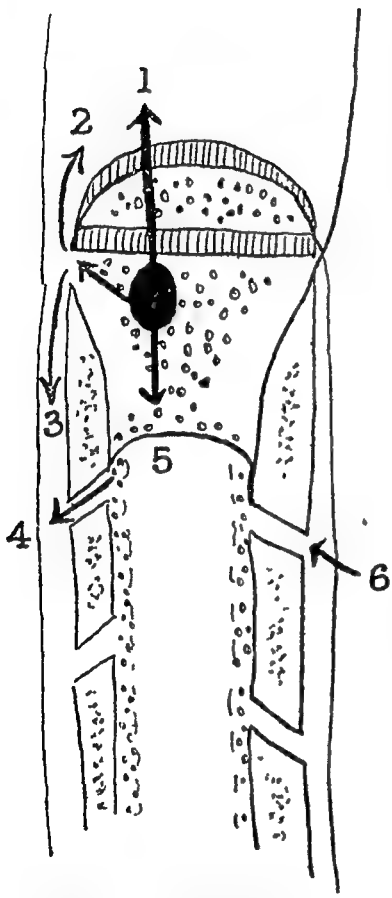

Fig 88 —Osteomyelitis The methods of spread (After Platt.)
1 & 2 Into joint
3 & 4 Into the sub-periosteal space
5 & 6 Into the medulla

Pathology

As the bacteria multiply in this little loculus, an inflammatory œdema is set up in the blood cavity, so that in time the exits and the entrances are completely blocked and what is virtually an abscess results The focus enlarges, until it appears to the naked eye as a circular patch of œdematous and congested marrow. Microscopically an accumulation of inflammatory cells can be seen around the congested vessels.

Depending to some extent on the type and virulence of the organism, the disease may take one of three courses

(*a*) When the patient displays a good resistance or the infection is a mild one, the reaction in the surrounding tissue may be powerful enough to eradicate the organisms before suppuration occurs.

(*b*) When conditions are slightly less favourable, i e when the organisms are more virulent, or the phagocytic power less, a chronic or "Brodie's" abscess may form.

(*c*) The usual sequence of a pyogenic inflammation may occur, the congestion being followed by suppuration and sequestration

When the disease follows either of the first two courses the acute illness gradually abates Should a Brodie's abscess be formed the organisms sometimes retain their vitality for a considerable time, and

osteomyelitis due solely to the typhoid bacillus, but if pyogenic infection is superadded, acute osteomyelitis results. The resistance of marrow is also lessened by exhausting diseases, over-exertion, and inadequate food.

When the organisms are introduced directly through a wound, as in a compound fracture, the suppurative process invades the bone at the point where it is in contact with infected tissue, but ultimately the whole length and thickness may be attacked.

The Localizing Influences. It is universally agreed that a mild bacteræmia precedes the actual onset of the disease. What, then, are the influences which determine the site of the osteomyelitis? The vascular arrangements in the metaphysis, and the influence of trauma are held to be important factors, but the work of Hobo seems to indicate that lack of active phagocytosis in the metaphysis is of even greater import. It has been pointed out more recently (Duthie and Barker, 1955) that the anatomical arrangement at the epiphyseo-metaphyseal junction favours localization of bacteria. They described the up-growth of thin-walled primitive blood vessels in between the trabeculæ of degenerating cartilage cells and suggest the passage outwards of bacteria during a bacteremia, into a perfect culture of degenerating cells

There is no doubt that a preceding trauma has an important localizing influence. The usual type of injury is in the nature of an epiphyseal strain. The reason for this is that in the long bones the epiphyses are the only resilient or elastic tissues, and consequently any strain applied to the limb is borne by them. The effect of the trauma is to cause hæmorrhage and cell-destruction in the region of the epiphyseal cartilage, followed by diminished tissue-resistance.

Children are continually receiving slight injuries of this kind, and as they are to some extent painful, there may be definite limitation of the function of the part from protective muscle spasm, in the lower limb, for example, there may be a distinct limp.

The Route of Infection. The bone may become infected through the blood-stream, through the lymph-stream, by direct continuity from a neighbouring focus of infection, or by direct inoculation from the body surface In actual practice, however, blood-stream infection is by far the commonest, although with the increasing mechanization of our traffic and the greater frequency of compound fractures and accidental wounds, direct infections are becoming more common.

The Incidence of the Disease. Careful statistics show that osteomyelitis is a disappearing disease. In spite of this, however, it appears that the condition comes in definite epidemics. It is believed by Williams and Timmins that these epidemics are coincident with a state of staphylococcal infection in the upper respiratory passages. The lessened incidence is explained by the improvement in the general health and in the housing and sanitary arrangements of the people. The disease is commonest during the period of active bone growth;

vessels—is cut off and its vitality impaired. The necrosis usually involves a considerable area, depending upon the degree of suppuration in the cancellous tissue and the extent of periosteum which is separated from the shaft. If the pus encircles the shaft, necrosis and sequestration of the entire circumference may ensue, forming the so-called tubular sequestrum. Otherwise the sequestrum consists usually of a portion of the outer layer of the cortex and is more or less flake-like in nature.

As the infection spreads, the periosteum is perforated, and the overlying soft tissues invaded. Should the synovial membrane of a neighbouring joint extend beyond the epiphyseal cartilage to the metaphysis, infection may readily extend to the joint In this way an osteomyelitis of the trigone of the femur may lead to suppuration within the knee joint.

FIG. 90 — Osteomyelitis of Upper End of Left Tibia Three months' history.

Treated by resection of upper part of diaphysis of tibia

If the progress of the disease is not arrested either by surgical intervention or death, extensive necrosis of the shaft ensues, the medullary cavity is infiltrated and the sequestrum on its outside bathed with pus, the periosteum being extensively raised from the cortex. The periosteum may show several perforations through which pus is being exuded into the overlying soft tissues.

Ultimately there is a reassertion of natural forces, the vascularity of the periosteum increases and a deposit of new sub-periosteal bone appears, which in time may completely surround the old dead shaft This envelope of new bone is termed an involucrum, and in the early stages is soft, vascular and easily separated from the underlying bone. It is usually incomplete, owing to the perforations which have taken place through the old periosteum, which remain as holes or "cloacæ" in the enveloping involucrum

In the endosteal areas, a similar reaction occurs and vascular granulation tissue forms on the surface of the still-living bone, between it and the sequestrum. In time it produces separation of the sequestrum, or even absorption, should the necrotic bone be small enough. The smaller cortical sequestra may be spontaneously discharged through the cloacæ and thence to the surface by way of sinuses through the soft tissues. Large sequestra take a long time to be extruded and the sinuses persist for a very long time This is one of the reasons for the long duration of convalescence from an attack of osteomyelitis Another and perhaps commoner cause of persistent sinus is the presence of a cavity in the interior of the shaft, the walls of which, being rigid,

under certain circumstances may undergo a recrudescence of activity. In the centre of the cancellous tissue, a cavity filled with thick pus develops, and, owing to the chronic nature of the disease, the surrounding bone is sclerosed and condensed.

Usual Course of the Disease. From the primary focus in the vascular cancellous tissue of the metaphysis, the infection is generally believed to spread with great rapidity to the medullary canal, so that, in a short time, the whole interior of the shaft may be filled with pus. The infection then spreads through the Haversian canals to the periosteum, which is eventually undermined and stripped from the bone by an inflammatory effusion constituting a subperiosteal abscess. The pus is greenish, and oily, and may occupy the whole shaft from epiphysis to epiphysis, it may, however, remain limited as a comparatively small focus in the metaphysis, the extent depending upon the intensity of the infection, and the patient's resistance. Occasionally it reaches the epiphysis, or even perforates the capsule and invades the adjacent joint. Starr, however, disputes this commonly accepted conception of the pathology. He believes that infection of the medullary cavity is secondary not to the metaphysial but to the subperiosteal abscess, and that it spreads from the original metaphysial focus along the line of the epiphysis to the periosteum. Here suppuration occurs and the pus extends rapidly under the periosteum, stripping this structure from the bone surface. The medullary canal is most frequently invaded from the sub-periosteal abscess through the Haversian canals. Starr has given convincing proof of his assertions by necropsy specimens, by X-ray photographs of cases seen at all stages, and by animal experiments

FIG. 89.—Osteomyelitis of the Femur, the disease beginning in the lower metaphysis

The original shaft has formed an extensive sequestrum

At this stage of purulent infiltration, areas of bone are actually bathed in pus The lamellæ are either poisoned by toxins, deprived of their blood supply by thrombosis of vessels, or rendered anæmic by pressure. A large area of cancellous tissue consequently undergoes necrosis, with the formation of sequestra. The compact surface bone is at first more resistant, but when the periosteum is raised its main source of blood supply—the periosteal

cannot collapse and which is so deep that the soft tissues cannot fill it up.

When all the sequestra have been extruded, and when there are no cavities, complete regeneration may be accomplished, the dense compact bone of the shaft being remodelled, and a cancellous interior again fashioned

Tubular sequestra are seldom, if ever, spontaneously discharged.

History of the Disease. Before the actual onset of acute bone symptoms, there is often a period of general malaise. There may have been some local lesion such as tonsillitis, or a more general infection like measles or scarlet fever.

Careful inquiry will usually elicit a history of a slight injury in the nature of a blow or a fall.

The first local symptom is usually severe pain of sudden onset, located in the neighbourhood of the joint, but occasionally the disease is ushered in by a rigor, followed by high fever and severe pain. In either case the abrupt commencement of the illness and the severity of the pain are the two notable features. Thereafter symptoms of severe toxæmia supervene, with, in the more severe infections, delirium and coma which to some extent may obscure the local signs. If, however, the virulence of the organism is not marked and the resistance of the child is good, then there may be a further remission of symptoms when the abscess bursts and the soft tissues are infiltrated with pus. The pus then infiltrates the fascial planes, following the lines of least resistance, until eventually it reaches the surface

Clinical Features

In the acute stages the child has all the appearances of a severe general illness. He is flushed and restless and complains of headache. The tongue is dry and furred and vomiting may occur. The pulse-rate is high—it may be as much as 120 or 140, there is marked pyrexia, and a leucocytosis which may reach as high as 25,000 cells

The child is apprehensive in case the limb should be in any way interfered with and usually screams when it is being exposed. He may object even to the bed-clothes being touched, and sometimes even to his room being entered. With the development of the toxæmia, however, his apprehension diminishes, he becomes apathetic and finally comatose.

When the affected limb is inspected, it will be found to be held in the position that exerts the minimum of pressure on the inflamed bone The neighbouring joints are flexed, in order to relax the capsule and accommodate the serous effusion which they constantly contain. In the early stages no swelling is apparent, but such quickly becomes evident when a sub-periosteal effusion has occurred Reddening of the skin is a late sign, and when present, is localized, like the swelling, to the affected metaphysis Handling the limb elicits extreme pain, the maximum point of tenderness being situated over the original focus

re-absorbed, so that bony intervention at this stage is not indicated. The discharge should be cleared away daily, and the old fear that frequent changes of dressings in themselves will cause re-infection with streptococci and staphylococci need not be entertained if strict asepsis in dressing technique is observed, and local penicillin as a cream or in solution employed. It is likely, however, that infection with penicillin-resistant gram-negative organisms will occur. *Pyocyaneus, proteus,* and *B. coli* are obstinate invaders, but can be treated with proflavine and hibitane solutions but of course chloromycetin is more effective.

The radiological changes in the course of and following penicillin therapy are interesting. Where treatment has been successful there is extensive decalcification, which is progressive for 70 to 140 days. Sub-periosteal bone formation is limited, small sequestra can be seen to become absorbed, and finally recalcification is complete.

In the absence of penicillin therapy the medullary cavity should be more freely drained in order to relieve the medullary tension, arrest infection, reduce the risk of septicæmia, and minimize sequestrum-formation. The affected segment of bone is exposed through an incision passing down to, and through, the periosteum in its whole length. If pus is not found on first opening the periosteum, the membrane is elevated on either side of the incision until it is found, and then it is evacuated. The operation, however, does not end with the drainage of the sub-periosteal abscess; the medulla is exposed also. The cortical bone overlying the affected metaphysis is perforated with a burr or gouge, and from the opening a quantity of infected fluid usually escapes, which may be thin and watery-looking, with fat droplets, or even frank pus. The burr opening should then be enlarged just sufficiently to allow adequate drainage, and in any case should not extend into healthy marrow since this would tend to spread the suppuration. It should be made to one or other side, or to the front or the back of the bone, for should a bone cavity result, it will be more easily obliterated if it is not situated in the centre of the shaft.

There is a wide choice of procedures in the after-treatment of this operation, but for all practical purposes, however, the choice lies between the following two methods:

(*a*) *The Carrell-Dakin Method.* Perforated capillary tubes are inserted into various parts of the gutter, connected with a Carrell-Dakin tube, and through them the wound is irrigated continuously with penicillin solution.

(*b*) *The Winnet-Orr Method.* Orr believes that poor results are due to failure to combine the well-known principles of asepsis, drainage, antisepsis and rest. His suggestions can be summarized as follows:

(1) Adequate drainage, the wound being left wide open to the depth of the affected area.

(2) A post operative dressing that will protect the wound, keep the part at rest, and provide no opportunity for reinfection.

(3) Immobilization, so that movement, pain and muscle spasm are

moderately certain Occasionally, however, the general symptoms are so acute from the start that the local signs are obscured. In deeply-seated areas, such as the upper and lower ends of the femur, swelling, redness and other local signs are very late in appearing, and cannot therefore be used to assist the diagnosis X-rays also are of no assistance in the early stages. Salicylates should not be administered in the hope of eliminating acute rheumatism, as valuable time may thereby be lost.

Differential Diagnosis.

There are certain conditions which are liable to be confused with acute osteomyelitis

1. Acute Rheumatism. In acute rheumatism, as in osteomyelitis, there are both pain and swelling, and also sharply localized points of tenderness; but the onset is more gradual, the pain less acute and more definitely articular, and the swelling confined more definitely to the joint. Further, acute rheumatism affects usually more than one joint at the same time and is "flitting" in nature Difficulty in discriminating between the two conditions is experienced in the main only with the milder types of osteomyelitis in which the onset is less dramatic and the progress relatively slow, but even in these milder cases the toxæmia is always greater than in rheumatism, and the leucocyte count higher

FIG. 92 —Osteomyelitis of the Tibia

Sub-periosteal resection of the shaft had been done in early life and apparently growth had been interfered with The fibula grew normally, with the production of a severe adduction deformity of the foot The condition was treated by osteotomy and bone-grafting

2. Erysipelas. Osteomyelitis may be mistaken for erysipelas because of the redness of the skin, but in the latter there is less pain and general toxæmia In erysipelas the definitely raised margin of the red area is significant.

3. Cellulitis. Cellulitis in the region of the metaphysis should always suggest osteomyelitis, but in pure cellulitis there is no intense pain and the general malaise is less

4. Acute Pyogenic Arthritis. An acute arthritis sometimes leads to confusion, but the manifestations in the joint are usually sufficient to differentiate the two conditions. In acute arthritis spasm of the

or elbow where the other preserves the configuration and length of the limb during healing After resection distortion of the limb is prevented by a plaster case until regeneration takes place.

In the operation the shaft is wrenched away from the end, separation taking place easily at the epiphyseal disc.

Treatment of the Chronic Stage.

The chronic stage is marked by the persistence of sinuses and by the repeated breaking down of wounds apparently healed.

Two factors are responsible for these:

1 The presence of unabsorbed and retained sequestra.

2. The presence of unobliterated cavities.

The treatment of the chronic stage is directed to the eradication of both these conditions. The operations adopted at this stage of the disease, unlike those appropriate to the early acute stages, are not emergency measures designed to save life They are methodical and sometimes tedious undertakings, which, if incomplete or lacking in thoroughness, will have to be repeated at a later date.

FIG 94 —Osteomyelitis of the Femur with Formation of a Sequestrum

Removal of Sequestra. It is essential that all necrotic cortical bone be removed, otherwise a permanent sequestrum, enclosed by an involucrum, will result. It usually takes from two to three months before the sequestrum is isolated and separated from its bed, and at this stage it can easily be recognized in a radiogram, since it is more dense than the neighbouring bone and lies free in the cavity.

The limb is rendered bloodless by elevation, and the application of a tourniquet. This facilitates observation by preventing hæmorrhage.

entirely relieved, and the parts retained in correct position for recovery with a minimum of deformity and instability.

A large incision is made over the infected area, and a gutter is chiselled out of the bone long enough and deep enough to expose the marrow-cavity. No edges of bone should be left overhanging the diseased area, and every care used to avoid any unnecessary damage to the medullary cavity The parts are next manipulated into an optimum position—the arm is abducted, the foot is put up at a right angle; the hand is dorsiflexed, etc. Thereafter, a complete plaster case is applied to the affected part, and retained without being split, and without windows until dressing becomes necessary. This necessity is indicated by the odour of the limb, and till then the wound is not dressed unless there is a continuous rise of temperature or other sign of exacerbation. In the majority of Orr's cases, dressings have been required at intervals of from ten days to four weeks

The author has used this method of treatment both in osteomyelitis and in compound fractures, and has been greatly impressed with his results.

Fig 93.—Osteomyelitis of the Tibia

Sub-periosteal resection of the upper half of the bone has been carried out and regeneration is going on

Sub-periosteal Resection.

This operation may be performed at a later stage of osteomyelitis when the whole or a considerable part of the shaft is necrosed and forms a sequestrum or when, as in some cases, the whole area is riddled with infection. There should be some guarantee that new bone is beginning to form under the periosteum or there may be incomplete regeneration. This is determined by passing a needle through the raised periosteum and gauging its strength, resistance and bone content. Diaphysectomy is usually reserved for one of the bones below the knee

particularly useful when there is a sinus present or an abscess which requires aspiration, and bilateral cases can be effectively controlled by it.

In older and heavier children the Pyrford Frame tends to be unstable, and for them, a very effective and simple method of treatment in this stage where traction is indicated, is by means of the Berck tray. The affected limb is fixed to the bottom of the tray, and the foot of the tray elevated on a special frame so that the patient's body lies at an angle of 45 degrees with the ground. The weight of the body exerts traction on the joint surface and at the same time abduction of the affected side is produced, since a weight naturally tends to swing immediately underneath its support. When the pelvis is tilted, however, the child flexes the spine laterally to get the head under the supporting leg, and in this way may easily produce a scoliosis. Such a case therefore requires careful watching and should not be left in the frame too long Renal calculi are said to form easily in this suspended position but are prevented by frequent lowering and increased fluid intake

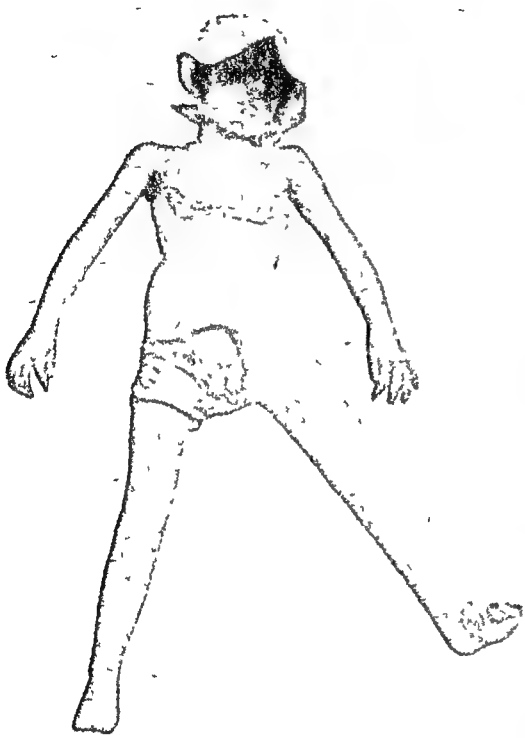

Fig 167 —Treatment of the Second Stage by a plaster-of-Paris case.
Note the moulding to secure immobilization

(*B*) *Cases where ankylosis is the expectation.*

(1) Non-operative methods. In the majority of patients, however, ankylosis is the aim of treatment, and this can best be secured by immobilizing the hip with plaster of Paris In applying the plaster case it has to be borne in mind that the hip will ultimately be fixed in the position chosen. The optimum position for ankylosis varies with age and apparently with the individual surgeon, but it is important to remember that growth will almost certainly be diminished, and probably greatly diminished, and that the only compensation for this, apart from leg-lengthening operations, is an abduction osteotomy. In cases, therefore, where there is much disease in the region of the femoral epiphysis a moderate amount of abduction is permitted The amount of abduction must be problematical since it is not possible to forecast the ultimate length of the leg. The limb is placed in a neutral position of rotation, or just a

will be corrected sufficiently to ensure a useful position should ankylosis ensue, which is known as the optimum functional position. It varies somewhat according to the extent of the disease and the possibilities of treatment, the greater the real shortening, the more extensive must



FIG 162—Tuberculosis of the Hip. The treatment in the acute stage.
The reduction of the deformity is brought about by fixing the unaffected side of the pelvis with a long Liston splint, and applying longitudinal and lateral traction to the affected limb

the abduction be, but even without bone disease abduction is advisable, as, with adhesions in the joint, the tendency during convalescence is towards adduction

It is sometimes recommended that cross-traction should be applied to

FIG. 163—Plaster-of-Paris Case applied to prevent over-stretching of Medial Collateral Ligament of Knee when correcting Adduction by Traction

pull the head away from close contact with the acetabulum. In practice, however, it is not found that this treatment has any advantage, either in the relief of pain, or in its ultimate results This cross-traction can be applied by passing a sling round the upper end of the thigh, attaching a weight to its free end, and allowing it to hang over the edge of the bed (Fig 162) A similar sling and weight are applied round the pelvis

face with the affected arm hanging down over the side of the table. This produces the usual position of the shoulder joint for arthrodesis and is an easy position for the operation. Brittain described his operation thus

"An incision 7 inches long is made, starting at the posterior margin of the deltoid, passing up over the axilla and proceeding down the axillary border of the scapula to 1 inch from its inferior angle. The lower part of the incision may be started first, and the posterior aspect of the axillary border of the scapula cut directly down to bone. The teres major and minor are identified, and an incision is made through the latter down to the axillary border of the scapula, which is cleared with bone elevators The circumflex scapular artery will be seen, and

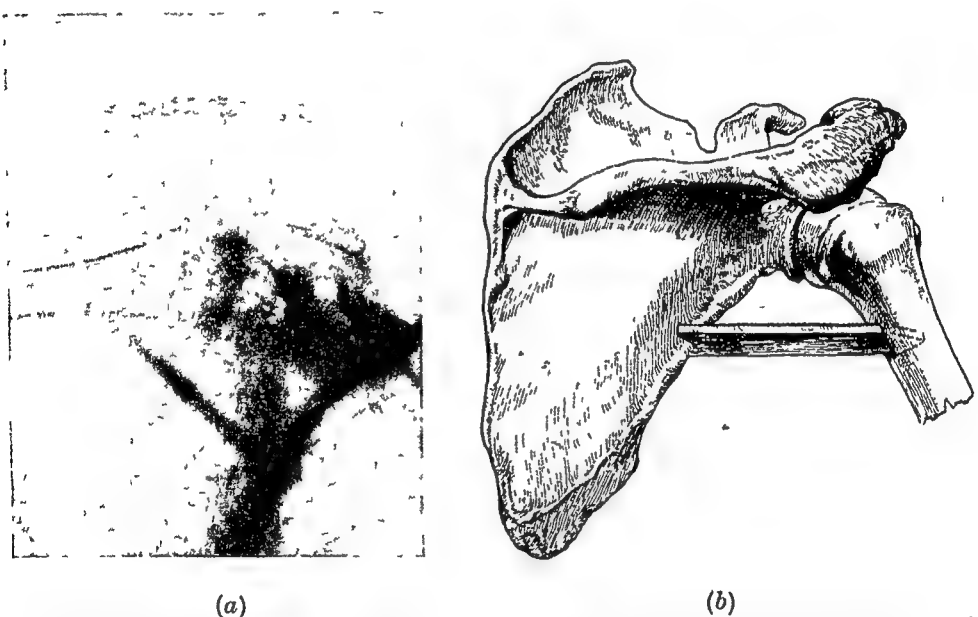

(a) (b)

FIG. 189 —Arthrodesis of the shoulder by the extra-articular method of Brittain A somewhat modified type of graft is shown. The scapula in contact with the graft should be denuded of periosteum and bare bone exposed

should be divided between forceps. The divided teres minor will fall forward and expose the axillary border satisfactorily. The long head of the triceps will be seen arising from below the glenoid This should be defined and the interval between it and the posterior border of the deltoid defined and widened. In the floor of this interval will be seen the lateral head of the triceps arising from the humerus, and an incision is made through this and the humerus exposed. Two inches of the humerus should be cleared and bone elevators passed round the bone. Care should be taken not to prolong this incision too proximally, as the circumflex artery may be severed. The circumflex nerve is not so important, as the shoulder is being fused A drill hole is now made $\frac{1}{4}$ to $\frac{1}{2}$ inch in diameter, and an electric drill may be used for this. The aperture is widened by gouges until it is 1 inch in length and

provides efficient fixation, is comfortable, lessens pain since it takes the weight of the arm off the joint structures, and, when ankylosis takes place, leaves a useful arm.

Operations.

Should the disease be mild in degree the plaster will remain on for about one year although it may be necessary in a growing child to change it during this period. Thereafter an abduction splint will be used and if possible a return to mobility encouraged.

Where the disease is osseous, however, ankylosis is the aim, and this is more likely to be achieved by some form of operative arthrodesis. Operation will be carried out at an earlier period in adults, and more reluctantly in children. In both cases the activity of the disease should have ceased and the resistance of the patient be raised to the optimum degree. Operations are contra-indicated in very active lesions with open sinuses, and in old quiescent lesions that have caused ankylosis and resulted in extreme muscular atrophy, and usually in children.

In adults some osteosynthetizing operation is indicated in most cases in view of the long duration of conservative treatment and the possibility of spread of the disease to the lung. Complete ankylosis is secured much more quickly by this than by any other method and pain is relieved.

Extra-articular Arthrodesis.

(1) High Operation. The ordinary anterior exposure of the joint is used, but prolonged upwards over the shoulder farther than usual to expose the acromion. The deltoid is retracted laterally from the pectoralis major, avoiding the cephalic vein, and is stripped off the clavicle and the acromion. The acromion is now denuded of periosteum on its upper and lower surfaces and a cleft made between the great tuberosity and the humerus, levering the tuberosity off the head in an outward direction The acromion and the outer end of the clavicle are now snipped with bone forceps so that when the humerus is abducted the acromion can be levered and bent into the cleft in the humerus. The tuberosity may be pinned in position by a peg going through the tuberosity, acromion and humeral head. The optimum position for arthrodesis is assured by a plaster jacket as used in the conservative method.

(2) The Low Operation of Brittain. This is an extra-articular operation carried out by bridging the space between the scapula and the humerus through a posterior incision. It is similar to Brittain's hip arthrodesis in that the force exerted on the grafts is one of compression and much more likely to produce bone fusion than in the high type of operation where the force is a distracting one.

A tibial graft is cut in the shape of an arrow—one end pointed and the other bifurcated or forked. The length varies with the patient, but it may be cut generously to about 5 or 6 inches, since if it is too long it can be shortened at the pointed end. The patient lies on his

[illegible] obliterated. Muscular spasm sets in and movement [illegible] At first only the extremes of flexion and extension are affected but later the joint becomes stiff at a mid-position, with the [illegible] fixed rigidly between pronation and supination. Muscular [illegible] prominent and, as in the knee joint, this may cause an exaggerated impression of the degree of swelling. Local heat varies

[illegible] Tuberculosis of the Elbow Joint

[illegible] of the disease. When an abscess forms, it points [illegible] of the abscesses. An X-ray picture shows [illegible] of the joint surfaces, or possibly a focus of disease [illegible]

Differential Diagnosis

[illegible] diseases have to be kept in [illegible] joint [illegible] the joint fidgety disease [illegible]

½ inch in breadth. Precise measurements are now taken of the distance the graft has to traverse, and a suitable area on the axillary border of the scapula decided upon. A notch is made in this to receive the graft, and this notch should be ½ inch in breadth and 1 inch in depth. Fracturing the blade of the scapula is not a serious error, as more new bone will be thrown out by this. At the same time it should be avoided, as it may make the attachment of the graft insecure The point of the arrow graft is inserted into the humerus first, and then by abducting the arm the graft can be carefully inserted into position so that the limbs fall into the notch in the scapula and grasp the bone The more difficult this is to do, the firmer will the graft be secured. It may be found necessary to divide the long head of the triceps, and if so it should be divided above its nerve supply and sutured in whichever position it lies best, over the graft if possible, so that the latter is covered by muscle. The teres minor is sutured and the wound closed in the usual way. The plaster is then completed by long slabs on the arm and across the back and chest, with the patient still lying on his face."

The author has carried out this operation several times now and heartily endorses the sound mechanical principles, and from his results warmly advocates the operation.

After being worn for three to six months the plaster case is removed, and an X-ray taken. When fusion is complete an abduction splint is substituted, and the scapular muscles exercised and re-educated.

See also Chapter XIX for other methods of arthrodesis.

TUBERCULOSIS OF THE ELBOW JOINT

The disease is met with more frequently in this joint than in the shoulder or wrist It is more common in adults than in children. In 4,000 cases admitted to East Fortune Sanatorium the elbow was involved in 1·8 per cent. of the cases of bone and joint lesions.

Pathology

Opinion is divided as to the primary site of the disease. It is commonly synovial, but in some cases a bone focus in the olecranon or in the radius appears to be the original seat, the lateral condyle of the humerus coming next in order of frequency. The disease may be so well established when the patient is seen for the first time that certainty on this point is impossible.

Symptoms

Pain aggravated by movement is at first confined to the joint. At a later stage it may extend to the forearm. Swelling is noted on the back of the elbow on both sides of the olecranon, and the bony

[illegible] the [illegible] bones. A square hole is made with [illegible] as possible to, the ends of the two bones [illegible] ready prepared, may be fitted into it. A [illegible] blade is used. When the bones are [illegible] the three bones are clamped together [illegible] permanent or not, according to the [illegible] infection. The wire is twisted right in [illegible] Plaster is applied as for a shoulder case and [illegible] A window may be cut in the plaster to allow [illegible] results.

[illegible] internal fixation may be achieved by an [illegible] plate applied to the posterior surface. The [illegible] achieved is often effective in an early bone [illegible]

TUBERCULOSIS OF THE WRIST

[illegible] rarely affects the wrist in childhood. Of 3,015 [illegible] joint disease treated in the Hospital for Ruptured and Crippled [illegible] of the upper extremity and only 1 of these [illegible] of the wrist. In adults it is not so rare.

The disease, though it may be synovial in origin, usually starts [illegible] the primary focus being in the [illegible] or thoracic epiphysis. Because of the intricate arrangement of the synovial membrane and the small size of the bones, [illegible] The disease frequently spreads to the [illegible] fibromyxomatous degeneration. [illegible]

[illegible] swelling, deformity, pain and [illegible] Pressure tenderness is seldom evident owing to the superficial [illegible] which also makes examination easy. Pain [illegible] is felt at the site of the disease but later [illegible] throughout the joint. Palmar flexion of the [illegible] at the wrist joint, and frequently [illegible] joint are limited in all directions. [illegible] usually be made out and bone [illegible]

[illegible] of the joint, degenerative [illegible] to treatment, particularly in [illegible] by bone disease.

Treatment

Conservative Treatment. [illegible]

Prognosis

With early and efficient treatment the outlook is hopeful. A useful joint should result in the majority of patients.

Treatment

Tuberculosis of the elbow joint in children is best treated by conservative measures The joint is placed at rest in the position that will be most useful should ankylosis ensue, which in most cases is flexion at a little less than a right angle. In young children, modified fixation may be carried out by a "collar and cuff" method A wristlet of soft leather is applied to the wrist and a leather collar to the neck, the two being fixed together by lacing. This method of treatment has the additional advantage of reducing the angle of flexion if too obtuse. The neck is bent forward, thus fixing the collar to the cuff, and the patient can then free himself by flexing the forearm further and so reducing the deformity. At the next visit the "slack" is taken up and the deformity is in this way finally reduced.

The ideal method of treatment would be the application of a shoulder spica plaster reaching to the fingers, which would ensure immobilization. This method is rarely employed and an example is thus provided of a joint being treated by inefficient immobilization The writer uses the "collar and cuff" method of reducing deformity, and, when the position is corrected, a plaster-of-Paris case, or a celluloid splint, is applied. When the patient feels his arm well and has no pain, he is allowed to use a sling The sling is lengthened gradually and if, in a few days, the arm can be lifted to the point from which it started, recovery is presumed and the arm may be allowed greater freedom. This is a good test of recovery of the joint Usually fixation is required for about eighteen months.

Operative Treatment.

In some cases it may be possible to remove small foci of disease from the olecranon or adjoining bones before the joint is involved. Excision of the elbow joint for tuberculous disease is rarely carried out, as a flail joint is liable to result, but if the disease progresses in spite of conservative treatment, it may be necessary to excise the joint and afterwards to perform arthrodesis

This is carried out by Langenbeck's method through a median posterior incision, the nerves being carefully avoided. The skin flaps are reflected forwards and the triceps stripped upwards after erasing its insertion into the olecranon. The forearm muscles are freed from the humerus and the joint thoroughly opened up. All the diseased synovial membrane and foci in bone are cleared out and the olecranon and lower articular ends of the humerus excised. Arthrodesis is then carried out after the manner advocated by the writer (see Chapter XIX). The remains of the lower end of the humerus are filed into a complete square with an ordinary rough file. The desirable position for ankylosis

CHAPTER VII

NON-TUBERCULOUS AFFECTIONS OF JOINTS

PYOGENIC ARTHRITIS

Purulent infections of a joint cavity are due to the introduction of pyogenic organisms. The commonest of these are the cocci, the staphylococci being the most frequent, although various types of streptococci, pneumococci, gonococci, and meningococci also occur More rarely arthritis may result from the invasion by the bacillus typhosus. The joint reacts by exuding fluid which may later become purulent; the organisms may be cultured from the pus, but in non-purulent cases there may be no growth on culture. The latter type of case is due to the circulation of toxins or of bacteria of considerably limited virulence

The disease is sometimes polyarticular, but in many cases has been superimposed on a wound, and is therefore confined to one joint

The Routes of Infection. The organisms gain entrance as they do in acute osteomyelitis Thus the joint may be infected by the direct implantation of bacteria through a puncture wound, by the direct extension of infection from a compound fracture or an inflamed bone, or the process may result from a hæmatogenous infection, the primary focus being situated in the genito-urinary tract, the respiratory tract, the intestinal tract, the teeth, or the tonsils Occasionally no primary source can be discovered. Acute arthritis may also occur in the course of acute infectious diseases like typhoid fever, pneumonia, influenza, and scarlet fever, and in this event the responsible organisms are the ordinary pyogenic cocci or the specific bacteria causing the febrile condition. Occasionally the joint manifestations are the result, not of the presence of actual organisms in the joint, but of toxins

Pathology

The reaction of the joint is determined by the virulence of the organisms, and the resistance of the individual; in any case there is an exudation of fluid into the synovial cavity, which will be serous, sero-purulent, or frankly purulent, according to the gravity of the disease.

1. The Serous Type. The joint is distended with clear serous fluid and is the site of a mild inflammatory congestion, with dilatation of

The plaster treatment should be continued for at least eighteen months, as a shorter period will inevitably be followed by recurrence. The plaster should fit accurately and be skin-tight or over stockinette at the most After the plaster is removed, a leather lacing wristlet is used for six months to protect the joint for a further period.

In the presence of sinuses a cock-up splint may be used, or a plaster-of-Paris splint with windows cut to allow dressing of the sinuses.

Operations.

In view of the multilocular character of the synovial pockets, the difficulties in curing the disease, the possibility of extension to the lungs, and in general the bad prognosis, the tendency is toward operative treatment. Curetting and excision are not satisfactory, the former because it is so often incomplete, the latter because it tends to be too extensive. The one does not eradicate the disease, while the other, although it removes the disease, too often leaves the wrist flail and the limb functionally incapacitated

Arthrodesis. This is the operation of choice, if it is performed before the formation of sinuses with their inevitable secondary infection It is carried out after the method of Albee and is to some extent extra-articular. An ankylosis is produced between the metacarpals and the radius by inserting a bridge of bone. Consequently absolute immobility of the wrist results, and as the bed in the radius is made deeper in its proximal part than its distal, the wrist is ankylosed in the dorsiflexed position.

"After a dorsal incision has been made, the carpus is exposed, and periosteum incised and elevated over the distal extremity of the radius and third metacarpal bone. With the motor-saw a gutter is prepared, measurements of which are taken with a flexible probe and a bone-graft removed from the tibia and inserted in the prepared bed. The graft is held in place by kangaroo-tendon around the metacarpal bone and by the same material through drill holes in the radius After suturing periosteum and skin, the wound is dressed and the forearm, from fingers to elbow, immobilized in plaster of Paris bandages for at least three months" (Albee's *Orthopædic Surgery*, p. 277).

Brittain cuts a bail graft half an inch longer than the bed and half an inch wide, and inserts it, not flatly, but on its edge. Its shape allows it to be firmly slotted into the bed between the radius and the third metacarpal when traction is put on the wrist The wrist is completely locked in position by the graft (see page 972).

Differential Diagnosis

The differential diagnosis of tuberculous and pyogenic arthritis still presents a problem. The onset of the former may be quite acute and of the latter insidious

The diseases commonly confused are acute rheumatism, an effusion from a neighbouring suppurative process, such as osteomyelitis, and acute infective (non-suppurative) arthritis.

Symptoms

In the absence of suppuration—i.e. in the serous and sero-fibrinous types—the symptoms resemble those of acute rheumatism. Movement, either active or passive, is practically impossible because of the pain, but usually only one joint is involved, in sharp contrast to acute rheumatism. Chronic cases are similar to, and perhaps identical with, rheumatoid forms of arthritis, and many joints may from time to time undergo attacks of pain, swelling and stiffness. The adjacent muscles are also implicated and undergo fibrous changes so that they become weak and stiff The repeated distension so relaxes the ligaments that the joint becomes more and more unstable and insecure, and the slightest movement then causes extreme pain Acute exacerbations occur again and again, and may be accompanied by a mild pyrexia. If the disease progresses the affected joints sooner or later become dislocated, and serious deformities result.

(*a*) **The Serous Type (Acute Synovitis).** Acute synovitis is

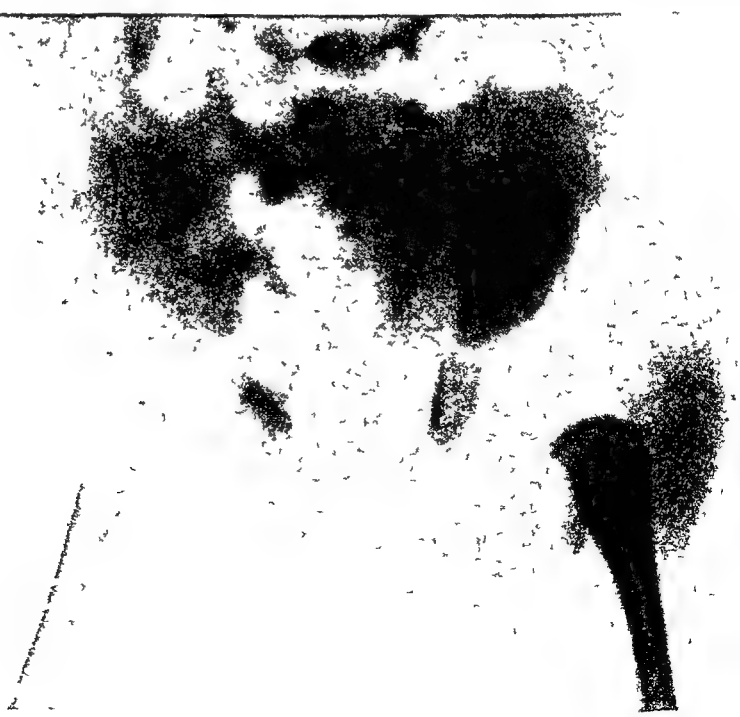

Fig 191 —Acute Arthritis of the Hip Joint

the vessels of the synovial membrane and capsule The effusion may subside gradually without further trouble, or it may subside and later recur, or it may eventually become sero-purulent, or actually purulent.

2. The Sero-fibrinous Arthritis. Here the synovial membrane is not merely congested but actually inflamed, so that the joint aspect is covered with a sero-fibrinous exudate and the cavity filled with a cloudy fluid containing a large number of polymorphs and a few large mononuclear cells Organisms are present in the joint fluid in the early stages. There is usually in addition some peri-articular inflammation, and since adhesions are particularly liable to follow the ultimate degree of function of the joint depends on the amount of scar tissue and the number of adhesions

3. Purulent Arthritis. In the most severe type of acute arthritis the whole joint and its surrounding structures are quickly involved. There is a considerable exudate of pus in the joint cavity, containing large numbers of polymorphs, bacteria, red blood corpuscles and fibrin. The capsule and synovial membrane are infiltrated with leucocytes, and engorged, and there may be small areas of focal necrosis or fatty degeneration The destruction eventually spreads to the articular cartilage. The intra-articular cartilage changes from blue white to yellow and dies. The articular cartilage is ultimately partly destroyed by the tryptic ferments from the phagocytes and destroyed by encroaching granulations from the synovia, it becomes completely detached, to lie free in the joint cavity in a pool of pus The bone is thus exposed, and if the disease is very acute osteomyelitis may arise, with its sequelæ, suppuration, necrosis and sequestration. The intra-articular ligaments may be destroyed as the tension of the exudate rises, and finally the capsule may be perforated, the pus escaping from the joint to form an extra-articular or peri-articular abscess

The end-result depends on the stage at which treatment is instituted, and if treatment has been started early a surprising amount of function may be preserved. In the majority of cases, however, there is gross disorganization of the joint, which is left crippled by adhesions and ankylosis. When there has been great interference with the joint structure, the joint surfaces at a later date are liable to be displaced.

Diagnosis

Pyogenic arthritis usually commences rapidly and without previous warning Malaise and temperature are associated with effusion and pain in the joint At first a small amount of movement does not produce pain but later spasm of muscles occurs. It is of great importance to aspirate and examine some of the synovial fluid as early as possible in the suspected joint. The blood count is of less importance as a leucocytosis is often present in the conditions most likely to be confused with pyogenic arthritis

at this stage, because gram-negative organisms may also be introduced accidentally.

The Sero-fibrinous Type. When the fluid has become slightly turbid, the joint should be aspirated, and penicillin solution, 500 units per c.c , should be injected into the joint, to the amount of half the volume aspirated. If the organism is not penicillin-sensitive, simultaneous aspiration and irrigation can be tried with other chemotherapeutic agents

Purulent Aspirations. When aspiration reveals the presence of frank pus, penicillin replacement may yet be successful , but if the pus is still thick thereafter, on re-aspiration 48 hours later, the joint should be opened and irrigated with penicillin solution. The capsule should then be closed securely round one or two fine rubber catheters leading into the joint, and the skin loosely approximated Penicillin is instilled into the joint, 5–10 c c. twice daily after aspiration, for three days and the tubes then removed By these means a movable joint may be achieved.

If the arthritis is unsuitable for penicillin treatment the joint should be opened and irrigated, the capsule repaired, and a drain inserted as far as the suture line, but not into the joint. In a desperate case open drainage may be necessary, but this almost invariably leads to ankylosis, especially when drains are inserted actually into the joint.

However, where all the components of the joint are infected and the cartilage has already been destroyed, the best that can be hoped for is ankylosis, and therefore the treatment consists of fixation, free drainage, and the prevention of deformity. The joint is immobilized in the position which promises the maximum degree of function In particular, a careful watch is kept for dislocation which is often spontaneous in the hip and knee, and which should be reduced as soon as the acute inflammatory symptoms have subsided

ACUTE INFECTIVE ARTHRITIS OF INFANTS

Acute infective arthritis is not a disease of great frequency in children, but carries with it the possibility of serious consequences to life and to future function of the limb. It appears usually in children under one year and is generally secondary to a neighbouring bone lesion, although less commonly the joint may be infected through the blood-stream Osteomyelitis has a predilection for the metaphysis, and this in many cases is intra-articular, or virtually so, since the articular capsule of the joint includes at least a portion of the metaphysis

Infecting Organisms. By far the greatest number of cases are caused by infection with the staphylococcus aureus or the hæmolytic streptococcus Less commonly, the organism is the influenza bacillus, pneumococcus, colon bacillus, or, in fact, any of the pyogenic organisms

evidenced by a tense painful swelling of the joint. In superficial joints, such as the knee, the bony outline may be completely obliterated. The joint feels hot, and it is usually kept in a position of slight flexion by muscular spasm, and any attempt to move it is attended with severe pain The temperature is raised, and there is usually a high leucocytosis. If the joint is aspirated at this stage, a clear exudate will be obtained, with a low sugar content

(*b*) **The Sero-fibrinous Type.** This is a later stage of the serous type, and is a much more serious condition. The joint is exquisitely tender, fever is high, and night pains occur from loss of muscular control.

(*c*) **The Suppurative Type.** In the early stage of the suppurative type, when the disease is limited to the synovial cavity, the symptoms differ little from those of acute synovitis. The patient, however, is more apprehensive; he feels extremely ill, and the joint is more painful. The limb wastes rapidly, and the temperature is high.

Treatment

When arthritis is suspected, the joint should in each case be aspirated for diagnostic purposes, any fluid withdrawn being submitted to histological and bacteriological examination

Aspiration is not only diagnostic but also therapeutic It relieves the pain and distension of the joint, allows a further outpouring of mildly bactericidal fluid and, if repeated, gives an indication of the progress of the disease

As the majority of infections are penicillin sensitive it is unnecessary to wait for bacteriological examination of the fluid, but an immediate injection of 100,000 units of penicillin is made through the aspirating needle The penicillin should be dissolved in such an amount of sterile water as will, without distending the joint, fill all its recesses Meanwhile a systematic course of penicillin is given to deal with a primary or blood stream infection.

Acute Synovitis. The patient is confined to bed, and the joint immobilized. When the symptoms are very severe, a weight extension is of great value There is less danger in thus immobilizing the joint until the infection has subsided, than in allowing movement, which merely disseminates or prolongs the inflammatory process. During this period careful radiological examination should be carried out to exclude the possibility of osteomyelitis, which is often associated with a reactionary synovitis.

The aspiration is repeated as required, and so long as the fluid remains clear and serous no further treatment is necessary. As the amount of fluid diminishes, gradual movement may be commenced to lessen the formation of adhesions

Penicillin should not be introduced into the joint prophylactically

In infants the diagnosis may be rendered difficult by the feebleness of their general reaction to the infection, since suppurative arthritis may exist without any elevation of temperature or leucocytosis. In such cases only the local signs of arthritis are present, and aspiration of the joint is the only certain means of diagnosis.

It is to be noted that in early purulent arthritis, when the articular cartilage is still unharmed, there is a small range of movement which is entirely free from pain.

Differential Diagnosis

Suppurative joint infections are most frequently confused with *acute rheumatic fever*. In acute infective arthritis there is direct involvement of the joint surface, and so the slightest attempt at active or passive movement of the affected joint is almost impossible, and induces severe pain In acute rheumatism there is often a preceding history of tonsillitis, and the multiplicity of the joints involved together with the comparative mildness of the inflammation, usually indicate the diagnosis.

In one type of mono-articular infection there is occasionally some difficulty. In this group of cases there is a history of a rapidly developing pain in a joint, along with the other signs of arthritis—increased local heat, rigidity, limitation of movement, and effusion Immediately thereafter multiple joint lesions occur in rapid succession, but do not present the definite findings which the original focus demonstrated They are probably toxic in origin, but unless they subside in a short time, leaving the original joint focus active, the condition may be mistaken for acute rheumatism. These cases obviously do not respond to salicylates

Tuberculous arthritis has often to be considered, but in tuberculosis there is no leucocytosis, and the progress is usually very insidious There is also complete limitation of joint movement, except in synovial tuberculosis In children the tuberculin reaction is an aid to diagnosis and there are usually sufficient X-ray evidences to differentiate the two conditions

Traumatic synovitis must also be seriously considered, for after some trauma there may be pain, limitation of movement, effusion, and occasionally elevation of temperature, and it may be difficult to say that the case is actually not one of infection. There is, however, no increase in local temperature or leucocytosis, and no evidence of the systemic reaction. Pain and muscle spasm are relieved by immobilization, while in purulent arthritis these usually persist.

Hæmophilic arthritis, though rare, must be borne in mind. It may arise without known cause or significant trauma, but there may be associated ecchymoses in the skin overlying the joint. The temperature may be slightly elevated The history may be of assistance, because of hereditary transmission, and more than one joint may be involved. If there is any suspicion of hæmophilic arthritis, it is advisable to investi-

Generally speaking, infections produced by the staphylococcus are the most virulent and most destructive, while those produced by the hæmolytic streptococcus are only a little less severe. Seventy per cent. of cases of acute coxitis in infants are due to streptococcal or pneumococcal infection. In later childhood and adolescence, on the other hand, the staphylococcal lesion predominates; while practically all adult cases are due to streptococcal or pneumococcal infection. Cases of staphylococcal coxitis in adults are recurrences of an earlier infection.

The local source from which the general infection develops may be the oro-nasal passages, skin or the umbilicus.

Surgical Pathology

The infection starts in the synovial membrane lining the joint This rapidly becomes inflamed, swollen, and œdematous, and from its surface is poured out synovial fluid, plasma, and leucocytes, filling the joint cavity with a turbid fluid containing large numbers of polymorphonuclear leucocytes and much fibrin. The synovial membrane has very similar powers to the peritoneum in combating infection, and so long as it remains comparatively healthy, and especially so long as the joint tension is not excessive, it may deal successfully with a considerable degree of infection. If the infection is severe or prolonged, the mesothelium lining the synovial membrane is destroyed, and its place taken by a mass of granulation tissue The articular cartilage is less readily involved than the synovial membrane, which is fortunate, since any injury to the cartilage results in greater or less impairment of the function of the joint The cartilage is killed first and most extensively at points of contact between opposing articular surfaces; it is broken down partly by the absorptive action of the granulation tissue, partly by pressure erosion, and partly by the digestive action of proteolytic ferments in the joint exudate

Signs and Symptoms

The signs and symptoms of acute suppurative arthritis in a superficial joint are sufficiently clear to offer no appreciable obstacle to diagnosis. The onset is abrupt and in many cases is preceded by trauma At an appreciable interval after the trauma, usually twelve to twenty-four hours, the joint becomes painful, swollen, and hot. Movement and weight-bearing are painful, and quickly become impossible. The patient begins to show signs of toxæmia and fever and may even at an early stage have one or more rigors. Examination reveals muscle spasm, fluid within the joint capsule, and pain on the slightest movement. The joint is fixed, usually in flexion. The temperature is elevated to between 100° and 103°, and a polymorphonuclear leucocytosis is present. Blood culture often demonstrates a septicæmia Finally, the diagnosis is completed by aspiration of purulent fluid from the joint

necessary As a precaution, a different point of entrance should be used at each aspiration

Even less recognized than the therapeutic value is the diagnostic importance of the aspiration of joint fluids. In slight injuries with a tear in the capsule only blood is found in the effusion. In cases of rupture of the semilunar cartilages of the knee and intra-articular fractures the effusion may contain fat which has been torn from the fat deposits in the joint or from the bone marrow

The differentiation between inflammatory and traumatic effusions is another problem of importance from both a scientific and a practical point of view, especially in compensation and liability cases The presence of blood in the aspirated effusion is of significance only in recent injuries An icteric index higher than 6 is pathognomonic of traumatic effusion. The icteric index increases with the age of the effusion.

Examination of inflammatory effusions makes it possible to differentiate specific from non-specific forms of synovitis and arthritis. Luetic arthritis can be diagnosed most accurately from the Wassermann reaction of the joint fluids. Reschke and others have reported positive Wassermann reactions in joint fluid in cases in which the Wassermann test of the blood was negative In a study of 121 synovial fluids in cases of gonococcal arthritis, Kling and Pinkus found the gonococcal complement-fixation test to be specific and to give stronger and more positive reactions than the blood serum. In tuberculous arthritis the effusion sometimes contains so many organisms that they can be demonstrated in the sediment, but for diagnostic purposes it is usually necessary to resort to animal inoculation of the fluid

The etiology of chronic non-specific arthritis is far from definitely determined In the laboratory of the Hospital for Joint Diseases, New York, about 20 per cent. of the fluids examined developed colonies of streptococci, staphylococci, or diphtheroid bacilli. The study of the cells in the synovial fluid gives some indication of the underlying process Forkner came to the conclusion that a count of over 11,000 leucocytes with 60 per cent. polymorphs in chronic non-specific arthritis is likely to be associated with a positive bacterial infection, and that a cell count under 5,000 leucocytes with fewer than 50 per cent. polymorphs is likely to be associated with negative bacteriological findings.

Methods of Aspiration and Drainage

Before undertaking the treatment of acute arthritis in any joint it is essential to know the method and the site of aspiration, the mode of approach for drainage, and the optimum position should ankylosis supervene

The Hip Joint.

Aspiration The hip joint may be aspirated either through a lateral or an anterior route.

gate the coagulation time of the blood before resorting to any radical measures. It is unduly prolonged.

Treatment

Fraser says, "the ideal of successful treatment is to arrest the condition without having to resort to incision and drainage of the joint, since risks of ankylosis are increased by such an operation." Cotton wisely and tersely remarks that the treatment of a suppurative joint by incision and drainage is an outrage. Immediately the case comes under observation, the joint is splinted in a position of slight flexion, and traction applied Some warm soothing applications may be used, but, where an infant is concerned, must be used with great care to avoid the risk of burning. Abundant fluids are given, and the bowel evacuated by calomel followed by a saline purge As soon as possible aspiration of the joint is carried out, and fluid withdrawn for examination The joint should be emptied as far as possible The type of fluid, and the organism responsible for the condition, are now demonstrated and determine the future treatment of the case. If the organism is penicillin sensitive, which it usually is, then conservative treatment is persisted with, i e continued traction to the joint with repeated aspirations and instillation of penicillin In a successful case successive aspirations become more serous, and after a time function is restored to the part by gentle movement and massage. In some cases it may be that operative measures will ultimately have to be resorted to, and it is unwise to delay too long lest the patient become too debilitated to stand the operation.

Aspiration of Joint Effusions.

The importance of aspirating joint fluids, both traumatic and inflammatory, is not sufficiently recognized The accumulation of fluid expands the capsule, stretches the ligaments of the joint, interferes with the circulation, and irritates the nerve endings, which in turn causes muscular spasm Following trauma blood is absorbed slowly from the joint and produces inflammatory changes of the synovial membrane Fibrin is precipitated and organized and may form a nucleus for the development of loose bodies. The cartilage undergoes degeneration The immobilization of the joints may finally give rise to atrophy of muscles and bone

In traumatic effusions aspiration is carried out twenty-four hours after the injury. The severity and the type of the injury are then determined by examination of the fluid and by clinical methods. In cases of simple traumatic synovitis, non-weight-bearing movement is allowed at once, and weight bearing after a few days if the effusion does not recur

Aspiration is indicated in inflammatory effusions if treatment for one week does not produce a marked decrease in the swelling. Re-aspiration should be done at weekly or bi-weekly intervals as long as

subsequently develop a gonococcal urethritis, are very prone to develop gonococcal arthritis.

Pathology

Acute cases may be divided into four types:

(1) Arthralgia, in which one or more joints may be painful but there are no gross physical signs

(2) An acute infection with effusion in one or more of the larger joints

(3) An acute infection with erosion of cartilage in addition to the effusion

(4) An acute infection involving the synovial membrane and the articular surfaces. The intra-articular exudate becomes purulent, and there is marked ulceration and erosion of all the cartilaginous surfaces. This condition is comparatively rare.

Subacute and *chronic cases* may be divided into two main types.

(1) A synovial type, involving especially the knee joint. The synovial membrane is thickened, and there is a moderate effusion.

(2) A mixed type, involving both the synovial membrane and the articular surfaces, and frequently polyarticular in the smaller joints, in which the serofibrinous exudate is always fibroblastic and leads to adhesions and deformity. Proliferative changes are more evident than destructive ones, and the peri-articular tissues are involved in the fibrosis in almost every case.

Symptoms

The acute joint infections other than arthralgia begin suddenly, and are often ushered in by a chill or a rigor. The temperature is raised, and the joint is painful The pain rapidly becomes excruciating, and is attended by muscular rigidity The skin overlying the joint becomes red and hot, and peri-articular œdema soon manifests itself When the joint effusion becomes purulent, pyrexia is increased, and rigors occur

The acute form may subside into a chronic type, or a sub-acute or chronic infection may arise *de novo*. The symptoms resemble those of the acute phase, but are milder except during the acute exacerbations which are liable to occur. The associated muscles become atrophied, and there is a persistent joint effusion. When there is gross enlargement of one joint—e g. the knee—in the absence of febrile and other symptoms, the condition is known as hydrops, dropsy, or hydroarthrosis. Suppuration is rare in this form.

The tendons, the tendon sheaths, the bursæ and the periosteum may be inflamed, in association with gonococcal arthritis. This is especially so of the tendons of the wrist and ankle and of the retro-calcanean bursa. In severe cases the adjacent bones are rarefied.

(*a*) The needle is entered at a point 2 inches below the anterior inferior iliac spine and pushed upwards, backwards and medially.

(*b*) The needle is inserted from the side just above the upper border of the great trochanter and thrust inwards and slightly upwards in a line almost parallel with the femoral neck.

Method of Drainage. The hip joint should be drained from its posterior aspect. The incision runs parallel to the central axis of the neck of the femur, and extends to the tip of the trochanter. The gluteal fascia is exposed, and divided in the line of the skin incision. The fibres of the underlying gluteus maximus are thus laid bare. These are separated, and the sciatic nerve in the median angle of the wound carefully preserved. The gemellus superior is detached from the tendon of the obturator internus, to enable the capsule to be split longitudinally throughout its entire length. The head, neck and acetabulum are now exposed, and the appropriate treatment carried out

This method provides rapid dependent drainage, and does the minimum of injury to anatomical structures. There is practically no bleeding.

The Optimum Functional Position Should unilateral ankylosis of the hip be anticipated, the joint is placed in a position of slight flexion, very slight abduction and very slight lateral rotation. When both hips are affected, one joint should be immobilized with some degree of flexion, so that the patient can sit with some comfort.

The Knee Joint.

Aspiration. A needle can be introduced into the knee joint at any point along the medial or the lateral border of the patella. The patella should first be grasped, pulled to the opposite side, and the needle passed obliquely between the femur and the patella, while the quadriceps muscle is relaxed.

Method of Drainage The anterior compartments of the knee may be opened on either or both sides of the patella, a short transverse incision being made through the capsule. Except in the grossly infected joints of modern warfare the capsular opening should invariably be closed after the joint has been evacuated and irrigated. Strips of rubber dam may be inserted down to the capsule in order to drain off the leakage of the first few days.

The Optimum Functional Position. The knee joint should be fixed in a few degrees of flexion.

The Ankle Joint.

Aspiration. The ankle joint is entered from the front, between the lateral border of the peroneus tertius and the lateral malleolus, or between the medial border of the tibialis anterior and the medial malleolus. The needle is thrust backwards and slightly downwards, and should gain the interval between the tibia and the talus, which has been previously recognized by palpation The joint may also be

Acute gonococcal arthritis must, in addition, be differentiated from arthritis following on pneumonia, dysentery, cerebro-spinal, typhoid, or scarlet fevers, acute tonsillitis, and tuberculosis.

An acute *tuberculous arthritis* is more insidious in onset, it is rarely polyarticular, the pain is not so severe at first, there is often epiphyseal involvement, and X-ray examination will reveal a definite lesion of the bone.

In *pneumococcal arthritis* the joint fluid almost always contains pneumococci In other cases of *pyogenic arthritis* the typical signs of the primary disease, such as scarlet or typhoid fever, etc, are of the greatest help in accurate diagnosis

In acute joint involvement X-rays are of little assistance except in differentiating it from acute tuberculous disease. In tuberculosis there is often definite evidence of osseous change, especially in the region of the metaphysis, and the changes are destructive and not proliferative and reparative as in gonorrhœa. When the activity of a tuberculous joint has ceased the definition becomes more distinct, but the articular surfaces have a worm-eaten appearance.

It is important to bear in mind Reiter's syndrome, which was first described in 1916, because the triad of urethritis, polyarthritis and conjunctivitis is most suggestive of a gonococcal infection The condition is a form of non-gonococcal urethritis which is probably due to a virus and certain authorities have demonstrated the presence of inclusion bodies.

The Gonococcal Complement Fixation Test may be positive in cases showing local or systemic complications in both sexes but the results as a whole are very disappointing and the test has proved to be of little value other than to suggest the possibility of gonococcal infection as an etiological factor.

Prognosis

The prognosis in the first three groups of gonococcal arthritis—arthralgia, acute and subacute synovitis, and acute and subacute synovitis and arthritis—is invariably good, even when there is involvement of the periarticular structures, if treatment of the original focus of infection, and of the joint, is carried out on correct lines In the fourth group—acute arthritis with suppuration—surgical interference may be required, and there may be considerable loss of function Fortunately this type of acute arthritis is rarely, if ever, encountered nowadays Subacute and chronic cases react well to treatment, but recovery is always slow and the joint condition is apt to recur. In neglected cases the articular cartilage may be destroyed and fibrous ankylosis occur, bony ankylosis is uncommon.

Treatment

This may be described under the following heads

(1) General Treatment. In this, the main essentials are rest, mild purgation, and a non-stimulating diet

Diagnosis

A painful affection of a joint, whether acute, sub-acute, or chronic, and which is associated with peri-articular changes, should prompt tactful inquiries concerning urethral discharge. The latter may be extremely slight—e g. a "morning drop"—or there may be no discharge but a palpable enlargement of the prostate or of the seminal vesicles. The secretion of these organs may be expressed by finger massage and may show gonococci on examination. When no gram-negative, intra-cellular diplococci can be demonstrated in a stained film it is essential to conduct cultural and sugar fermentation tests and, if necessary, the oxydase reaction, on specimens obtained from the most common foci of residual infection, i e. the prostate and cervix.

Even when there is no obvious focus of gonococcal infection, it is always important to exclude this type of joint lesion by repeated examinations, when an acute, subacute or chronic affection of a joint is painful, persistent, and associated with peri-articular changes.

It is important in acute cases to be able to differentiate between acute rheumatism and a gonococcal arthritis :—

	Acute Rheumatism.	Gonococcal Arthritis.
1	No evidence of genito-urinary disease	The genito-urinary signs and symptoms may occasionally be well marked but are more frequently of a slight nature
2.	Marked temperature reaction and more prolonged constitutional upset and prostration	Very moderate temperature reaction, and constitutional upset slight, except in purulent cases
3	Sweating very profuse, with acid odour	Very little sweating except in purulent cases.
4	Pain intense and aggravated by the slightest touch.	Pain less intense
5	Many joints involved, but as pain leaves one it flits to another, and the first affected appears to be free from discomfort	May be limited to one joint, and usually one or two joints only, and pain does not leave a joint rapidly and pass to another.
6	Tendon sheaths and peri-articular tissues rarely involved	Tendon sheaths and peri-articular tissues very frequently the site of disease
7	More common in women.	Less common in women
8	Often some cardiac complication, such as endocarditis or pericarditis, and an active focus of infection in the tonsils	Cardiac complications very rare, and no acute condition in the tonsils
9	Symptoms and temperature react extremely well to the administration of salicylates.	Salicylates have little effect on the pain, the swelling, or the temperature
10.	Complement-fixation test of blood negative	The complement fixation test may be positive but too much reliance should not be placed on this test, which has not attained the same significance or reliance as the Wassermann test in syphilis
11.	Temporo-mandibular joint rarely involved	Temporo-mandibular joint may be involved

Joint Lesions in Acquired (Early) Syphilis.

(1) Arthralgia.
(2) Hydrarthrosis.
(3) Plastic Arthritis (very rare).

Joint Lesions in Acquired (Late) Syphilis.

Gummatous arthritis
(1) The synovial form
(2) The osseous form.
(3) Charcot's joints.

Joint Lesions in Inherited Syphilis

In addition to the two forms that are described below as occurring in inherited syphilis, we meet with others which are exactly analagous to the tertiary syphilitic form met with in adults.

1. Parrot's Syphilitic Osteochondritis. This is an epiphysitis, or a juxta-epiphyseal inflammation, which occurs during the first few months of life in children with inherited syphilis. It affects the upper limbs more frequently than the lower, and consists of a gelatinous change in the cartilage and bone, often associated with an effusion into the adjacent joint. The gelatinous tissue breaks down to form a greenish-yellow fluid from which a strongly positive Wassermann reaction is obtainable Suppuration may or may not occur, but is rare The extremities of the bones at which growth principally takes place—knee, shoulder and wrist—are more frequently involved, the epiphyseal region becoming large and tender. Separation of the epiphysis may occur and give rise to unwillingness to move the joint—syphilitic pseudo-paralysis

The *X-ray changes* are irregularity of the epiphyseal line, cupping of the metaphysis, widening of the articular space, thickening of the periosteum, and decalcification of the neighbouring bone.

Anti-syphilitic treatment may produce complete resolution, but the growth cartilage may be so damaged that, later, shortening or deformity arise

2. Clutton's Joints (Symmetrical Hydrarthrosis). The joint condition commonly known by this name was first described by Clutton in 1886, and consists of symmetrical hydrarthrosis of the knee in children from eight to sixteen years of age. The onset is insidious and there is no fever The joints are painless, and in spite of the effusion the patients are able to walk quite well This condition when associated, as it commonly is, with eye-changes and other stigmata of congenital syphilis, constitutes a striking clinical picture Syphilis is practically the only cause of a bilateral, painless hydrops of the knee in a child.

The condition shows a slow response to treatment and appears to run its own course Spontaneous recovery may take place Relapses are unlikely.

(2) Eradication of the Original Focus of Infection.

(*a*) *Local Measures.* These need not be considered here, but, despite modern systemic remedies, they still play an important part in treatment.

(*b*) *Chemotherapy.* Adequate dosage with the sulphonamides and/or penicillin, preferably in oil-wax suspension (by intra-muscular injection) are the modern methods which alone, or in combination, give most excellent and rapid results.

(3) Treatment of the Infected Joints. Relief of pain is of primary importance and is obtained by rest in a semiflexed position While rest is advisable if the pain is severe it is very important not to continue immobilizing the joint for any period longer than is necessary to relieve the acute pain Early mobilization is one of the greatest assets to the recovery of joint function. Palliative measures comprise Bier's hyperæmia and the application of soothing medicaments to the joint—e g Antiphlogistine, 20 per cent. warm Ichthyol and Glycerine, or lead and opium compresses

Operative treatment has been advocated largely on the Continent, but it is doubtful if more than a few acute or subacute cases require operative interference. Aspiration will undoubtedly relieve the intra-articular pressure The fluid from the joint may be replaced by 10,000 units of penicillin daily for three days.

The response to penicillin is usually excellent and provided treatment is begun early and the organism is not resistant resolution takes place without damage to the joint.

SYPHILIS OF JOINTS

Syphilis as an etiological factor in arthritis is probably commoner than is generally believed because, despite the general effectiveness of the present Venereal Diseases Scheme in this country, there still remains a fair percentage of defaulters from treatment Anti-specific treatment is clearly indicated in all cases of syphilitic arthritis but the response, unless in the early stages of the disease, both in the inherited and acquired forms, is in the main not encouraging Diagnosis is materially assisted by concomitant signs or symptoms of syphilis and blood serological tests (Wassermann and Kahn) The latter are invariably positive in the early stages but are not so reliable in late syphilitic lesions, being positive in only about 50 per cent of these cases It need hardly be stressed that a negative blood serological test does not exclude syphilis as the cause of the arthritis Syphilis of the joints may occur at all stages of the disease and in both the inherited and acquired forms.

Classification of Syphilitic Arthritis.

Joint Lesions in Inherited Syphilis.

(1) (In Infancy) Osteochondritis

(2) (In Childhood) Clutton's joint, Symmetrical hydrarthrosis.

exceptionally, pain may be severe, and the disease simulate tuberculosis. The pathological changes are limited to the outer layers of the capsule, and consist of thickening and perivascular infiltration. The lining endothelium and articular cartilage remain shiny.

The disease can be distinguished from tuberculosis by the fact that there is less muscular wasting, and that even after years of neglect there may be little pain and little restriction of movement, whilst suppuration is practically unknown and no other complications occur. It is therefore wise to exclude syphilis in any doubtful chronic joint infection.

2. The Osseous Form. The whole of one large joint is affected—as a rule the knee The condition resembles osteo-arthritis both pathologically and on X-ray examination Distension of the joint is present, and some increase in the density of the peri-articular soft parts can be detected in the radiogram.

The spine is sometimes affected and the disease then closely simulates tuberculosis, the diagnosis being made only when other signs or symptoms of syphilis are present, blood serological tests assist, and/or the response to suitable anti-syphilitic treatment is satisfactory

Even in well-established gummatous arthritis, timely treatment can produce great improvement, though not so much as in the earlier cases. It is important to institute thorough and prolonged treatment, since if it is delayed gross osteo-arthritic-like changes occur, or else ankylosis The development of fibrous ankylosis is particularly deplorable, because there is a greater risk of non-union in attempting to convert this into a firm bony ankylosis by arthrodesis than there is in a tuberculous case This risk remains even after a thorough prophylactic course of anti-syphilitic treatment

A weight-bearing caliper should be worn throughout the active stage of the disease, but it should be taken off daily so that the joint may be put through its full range of movements without weight-bearing.

There is little pain ; little or no muscular wasting, and the temperature seldom reaches 99° The clinical picture of a painless polyarthritis in a child, without local heat, redness, wasting, pyrexia, night-starting, or response to salicylate treatment, makes up a characteristic picture

There is another form which simulates rheumatoid arthritis, with fusiform swellings of the fingers, sweating, pain, debility, intermittent pyrexia, with exacerbations and remissions

3. Charcot's Joints. (Tabetic Arthropathy) This is considered to be neuro-arthropathic in origin. It usually occurs in acquired syphilis but may very occasionally follow inherited syphilis. The large joints, the knee, ankle, hip or shoulder, are commonly affected, but rarely multiple large or smaller joints may be involved The early stages of rapid exudation into the joint cavity and periarticular structures is rapidly followed by a painless disorganization of the articular and surrounding structures resulting in a painless flail-like joint. Radiological examination shows gross disorganization, disappearance of

Joint Lesions in Acquired Syphilis

1. Arthralgia. The commonest joint manifestation in acquired syphilis is a simple arthralgia, which forms part of the clinical picture in the secondary stage. It may even appear before the early rashes. The pain is never severe and can often be more correctly described as an ache. As in tertiary syphilis, it is chiefly nocturnal It is characteristic of it that movement does not increase the discomfort, an important point in the differential diagnosis from rheumatism. It usually affects one or more of the larger joints; there is little, if any, muscular spasm, and usually at this stage there is no local swelling, heat or tendency to deformity.

The diagnosis is determined by the history and general phenomena and the positive Wassermann reaction.

2. Hydrarthrosis. Later in the secondary stage serous synovitis may occur, and may be acute, sub-acute or chronic. It usually involves two or more joints, especially the knees, and often in a symmetrical manner In the earlier cases the synovitis is of a transient nature, but later it is more persistent Fluid is abundant and the synovial membrane is swollen Pain is moderate, and gentle passive movement does not hurt, although direct pressure on the joint may do so. The condition is usually of a mild type, but in exceptional instances it may be acute and even simulate suppuration, when pain, tenderness, malaise, and pyrexia are present.

3. Plastic Arthritis. A very rare and later type in the secondary stage is a plastic arthritis The synovial membrane is thickened and the joint swollen, though very little fluid is present The fluid, turbid and thick, invariably gives a positive Wassermann reaction. The affection is usually mono-articular, but may be polyarticular in neglected cases Larger joints, such as the knee, are usually affected The response to treatment is slow, but most cases eventually recover The later the institution of treatment, the more chronic the disease will be

Tertiary Syphilitic Arthritis

(Gummatous Arthritis)

Gummatous arthritis may affect a whole joint, or be localized to a part of a joint. Its onset is usually insidious, less commonly acute and sudden, usually the joint has been previously normal, though occasionally it is superimposed on a secondary syphilitic joint lesion such as hydrarthrosis

1. The Synovial Form. This type often follows trauma, and may lead to an erroneous diagnosis of tuberculosis The commonest joints to be affected are the knee, ankle, elbow and shoulder, but smaller ones, such as the inter-phalangeal joints, are occasionally affected. There is considerable but, as a general rule, painless effusion, but,

General health unimpaired in many cases in spite of prolonged joint affection.

Failure to respond to certain specific drugs, e g. salicylates.

Persistence of the condition in spite of treatment that would be successful in other conditions—rheumatism, tuberculosis, etc.

Nocturnal occurrence of pain

Associated evidence of syphilis.

Failure to produce tuberculosis, after injection into a guinea-pig of some of the aspirated joint-fluid, may be of assistance in the differential diagnosis.

HÆMOPHILIC ARTHRITIS

John Otto wrote the first important description of this disease, hæmophilia, in 1803, and in it he postulated Nasse's law that the disease is transmitted as a sex-linked character by females and manifests itself only in males. Sporadic cases are reported, however, so it is not safe to rule out the condition because of an absence of a family history of the disease Hæmophilic arthritis, also known as "bleeder's joint," was first described by Volkman in 1868. Konig in 1892 divided the condition into three stages (1) hæmarthrosis; (2) pan-arthritis, and (3) the regressive stage. He warned against operation under a mistaken diagnosis.

Pathology

It is doubtful where the defect in the clotting time lies in this disease, but it is likely that there is some qualitative alteration which results in delayed activation of thrombin by prothrombin.

The hæmorrhage usually results from injury, and the joint quickly becomes distended with blood which is under considerable pressure and does not clot It gives rise to mechanical disability, and, acting as an irritant, induces hyperplasia of the synovial membrane. Phagocytic macrophages accumulate in the subsynovial tissues, where they die, releasing the blood pigments from phagocytized red blood-cells. With each new hæmorrhage this process is repeated, and the periarticular tissues become saturated with blood pigment In this way a dense layer of fibrous connective tissue is formed, and the size of the joint and the movement at it are steadily diminished in consequence, so that a fibrous ankylosis may result. If the bleeding ceases the synovial membrane may return to normal, but if it does not then the cartilage eventually becomes eroded around its margins through the encroachment of the hyperplastic synovial membrane. There may in addition be some patchy destruction of the cartilage over the articular surface Such areas are irregular and map-like in contour, and not situated at the points of greatest pressure in the joint.

In the bone, the characteristic change consists of cavitation in the intra-articular portion, either at the articular surface or deep in the

cartilage and articular margins, and bony rarefaction. Fragments of bone are commonly found lying free in the joint.

Diagnosis is arrived at by correlating a history of a rapidly progressive and painless disorganization of a joint, without associated muscular atrophy, and with the clinical and serological signs of Locomotor Ataxia (Tabes Dorsalis) Other associated neurotrophic features may be present, such as perforating ulcers affecting the sole of the foot, or one of the toes, and pathological fractures may occur Treatment is most unsatisfactory and very disappointing, but a few cases have recently been described, where splinting was impracticable, that have proved successful after arthrodesis which was preceded by suitable anti-syphilitic treatment consisting chiefly of penicillin and/or Malarial therapy.

General Diagnosis

The family history, that of previous diseases, and of the present condition should be most carefully considered The Wassermann and Kahn tests should be conducted as a routine in every case of chronic arthritis of any degree of severity and, where serological diagnosis presents any doubts or difficulties, it is advisable to repeat quantitative tests, at monthly intervals, over a period of six months, in order to observe their variations. The blood serum and, if obtainable, the joint-fluid should be investigated, for in a number of cases a positive result may be obtained from the fluid when the blood serum gives a negative result Todd says a negative Wassermann reaction cannot be assumed to exclude the possibility of syphilitic arthritis, in cases of late congenital syphilis, at any rate until the effect of a course of anti-syphilitic treatment has been tried. It is important to remember that blood serological tests may also be negative in late cases of acquired syphilis. As a corollary to this it might be added that in all cases of chronic arthritis in which, despite full investigations, the diagnosis is not clear, anti-syphilitic remedies should be exhibited. In order to obviate or minimize the possibility of serious or even fatal sequelæ from Herxheimer phenomena it is most advisable to confine the anti-syphilitic treatment to Bismuth, Mercury or Iodide preparations To give Arsenic or Penicillin as a therapeutic test, without a very thorough examination of the patient, including the electro-cardiogram, is most inadvisable. Finally, one must not forget the possibility of a non-syphilitic arthritis occurring in a person with concomitant positive blood serology.

There are certain clinical features which Todd has pointed out as of diagnostic importance and which should make one think of syphilis:

Painlessness, in spite of profuse hydrops, especially when associated with a free range of movement

Symmetrical synovitis.

cancellous bone Key believes this is due to intra-osseous hæmorrhage in the atrophic bone, followed by aseptic necrosis and absorption. These areas of bone destruction can frequently be visualized by X-ray and when present are characteristic of advanced hæmophilic arthritis. When the patient grows older and bleeding ceases the condition of the joint may simulate that in hypertrophic arthritis. Marked deformity occurs as the disease progresses, and the X-ray and clinical findings may simulate those of any type of arthritis

The Clinical Picture

This varies with the stage of the disease The most dangerous period in the life of a hæmophiliac lies between the age of one year and adolescence. 89 per cent are stated to die before the age of 21. Key recognizes two stages:

(1) **Acute Hæmarthrosis.** The joint disturbances of hæmophilia nearly always begin in childhood, and the child may be seen by the surgeon during the first attack or only after repeated attacks in that or other joints. The hæmarthrosis usually follows a minor injury or strain, and the blood may gather slowly or rapidly; it may be slight in amount, or copious and under considerable pressure. Pain and loss of function may be slight or severe, varying directly with the amount of effusion. There is accompanying muscle spasm. At the superficial joints the skin may be cyanosed, but there is no increase in local heat or redness. The general temperature is slightly elevated, and there is usually a moderate leucocytosis.

(2) **The Chronic Arthritic Stage.** In this stage permanent changes are present in the joint. They may follow the first attack but are more often the sequel to several attacks The joint remains swollen, tender, sore and painful for several weeks or months. The arthritis progresses Repeated attacks of acute pain and swelling occur, with permanent and increasing disability of the joint in the shape of contracture, deformity, and peri-articular thickening. Muscle atrophy also increases after each fresh hæmorrhage The coagulation time of the blood tends to be prolonged to a varying degree.

Treatment

In the acute stage, the patient is put to bed and the joint immobilized by splints or plaster of Paris Aspiration may be definitely dangerous. Further hæmorrhage may be prevented by blood transfusion or by hæmoplastin or horse serum given intramuscularly External bleeding can be arrested by the local application of the venom of Russell's viper applied in 1 · 10,000 dilution When the swelling and the pain subside, function is gradually restored with gentle massage and exercises. Every effort is made to avoid trauma in the future.

In the stage of chronic arthritis any deformities that have been

When the affection follows a slight injury the patient complains of severe pain, excessive tenderness and impaired function of the joint. On examination the joint appears normal, but the skin over it is exquisitely sensitive Stiffness is common and in some cases amounts to absolute rigidity. The joint may be fixed either in flexion or extension, but it is rarely in the exact position of ease assumed in a true joint inflammation, and the position is apt to be changed from day to day and from hour to hour. When the patient's attention is diverted, the pain and stiffness may disappear.

Should the symptoms be unduly prolonged disuse atrophy of the tissues may ensue, while circulatory changes from the same cause, such as undue pallor, temperature changes, and undue perspiration, are not unusual Secondary contractures of the joint set in if the joint is kept rigid for long periods.

Hysterical phenomena at joints are seldom found alone, but are associated with other, possibly latent, stigmata, such as *globus hystericus*, zones of anæsthesia, and convulsions.

Diagnosis

In every case of alleged hysteria, a careful examination must be carried out to eliminate the possibility of a true organic lesion The ordinary clinical examination may be supplemented if necessary by one under anæsthesia, and by X-rays

In examining the case, the observer will usually note that the signs disappear when the attention is diverted; that they are out of all proportion to the local evidences of disease, that there is no sign of joint destruction, and that a light touch may cause more pain than does firm pressure

Differential Diagnosis

Hysterical affections of joints have to be differentiated from those joint disorders which are reflex in nature The hip joint is a common site for such disturbances, and the commonest cause appears to be preputial adhesions, although anal, vaginal and coccygeal lesions are also common ætiological factors

The distal part of the extremity must be inspected for evidences of a septic lesion, as joint stiffness or fixation is frequently associated with infection in the inguinal or popliteal glands secondary to an area of peripheral sepsis.

Treatment

An accurate diagnosis is essential to successful treatment. The general health should be carefully tended, and a nourishing and easily digested diet instituted The local condition should be explained to the patient as due to an abnormal state of the circulation and innervation of the joint It is wise to refrain from saying that nothing is the matter or that it requires only an effort of will to overcome it, for this view will

tissue respiration will be defective. A small defect in tissue respiration may not produce any demonstrable effect on the individual, but if it does, this will be seen in parts of the body where the defect is increased by a slow circulation These parts, owing to mechanical reasons, are the tips of the fingers and toes, and the nose This imperfect oxygenation, or anoxæmia of the parts, produces œdema and later, if long continued, it may be hypertrophy of the connective tissue.

ARTHRITIS OF BRUCELLOSIS

Osteoarthritic manifestations in human and animal brucellosis are important and not infrequent. The osteoarthritic types of brucellosis are (1) arthralgias and ostalgias, (2) fibrositis, (3) hydrarthrosis, (4) acute arthritis; (5) chronic arthritis; and (6) osteitis, osteomyelitis and osteoperiostitis Spondylitis is the most frequent articular lesion and may simulate Potts disease or spondylitis ankylopoietica The microbe may localize in the joints and produce purulent metastatic arthritis in septicæmic cases. In chronic types the articular changes are part of an allergic inflammatory response of mesenchymal tissues The disease should be suspected when a patient shows musculo-articular changes with psychic asthenia, changes of the eighth cranial nerve, autonomic nervous system disturbances with or without fever Additional findings of positive intradermal reaction of Bund, anæmia with anisocytosis, leucopœnia with neutropœnia and lymphocytosis, normal B S R. and absence of signs of other diseases presume the presence of brucellosis

Treatment is by streptomycin 2 gm. intra-muscularly daily, combined with aureomycin or chloramphenicol 2 gm. daily for two weeks This may be combined with protein-shock therapy, e.g, intravenous T A B once or twice in the first week. Methymycin may be used in place of aureomycin. Others have combined cortisone with the antibiotics.

In addition, there is usually well-marked muscular atrophy and general weakness. The former is in part due to the debilitating effect of the original disease and in part produced reflexly by the joint disturbance.

Pathology

The terminal part of the finger is swollen and enlarged. The nail is enlarged so that it overlaps its bed, while it is curved over the end of the fingers producing the so-called parrot's beak effect. It is markedly striated and breaks easily Under the nail there is a vascular turgescence and a hyperplasia of the connective tissue.

The joint lesions are the result of swelling and turgescence of the synovial membrane, which shows an infiltration with granulation tissue and with small round cells. Later there may be erosion of the articular cartilage, with exposure of the underlying bone.

The thickening of the bone is due to the deposit of successive layers of new sub-periosteal bone. The sub-periosteal sheath is loose and friable, and especially marked at the muscular or tendinous insertions In long-standing cases, especially when the individual is confined to bed, there may be marked atrophy of the cancellous tissue of the old bone At other times, it is sclerosed and the medullary cavity may be encroached upon

Etiology

Many theories have been advanced to explain the occurrence of these curious changes. Thus they have been attributed variously to bacterial toxæmia, amyloid disease, tuberculosis and neuropathy. Phemister and others regard two factors as necessary for their production—the first, a toxin from the long-standing intra-thoracic disease; the second, circulatory disturbances from cardiac and pulmonary involvement

Compere and Adams have shown that the diseases which are associated with Marie's syndrome are all productive of dyspnœa, cyanosis and a disturbance of the acid-base-equilibrium of the peripheral blood They point out that a toxic factor is not necessary—and often not present—as in carcinoma of the lung, syphilis, and hepatic disease. These views are supported by two facts. (1) Similar bone changes are occasionally encountered in those who for a long time live at high altitudes, (2) in certain cases they studied, the carbon dioxide content of the blood serum was increased and the oxygen content diminished.

In Campbell's opinion œdema is the primary pathological basis in this disease He believes that the diseased area through which the blood flows prevents proper ventilation and accordingly the oxygen tension of the whole arterial blood will be lowered. The transference of oxygen from the blood to the tissues depends on the difference in tension of the oxygen in the blood and in the tissues It will be clear that if from any cause the arterial oxygen tension be lowered, the

CHAPTER VIII

CHRONIC ARTHRITIS

Chronic arthritis, a disease which probably has more synonyms than any other, is for various reasons one of the most serious of all joint affections Its economic importance is reflected in the recent statement that each year it is responsible for the loss of more than one and a half million weeks of labour in America, and that annually it costs the Approved Societies nearly a million pounds in insurances. Its treatment bulks largely in the work of the orthopædic surgeon, to whom are referred those whose lives have been made a burden through pain or crippling The disease has therefore a profound significance, and there is a vast field for research in the question of its etiology and treatment. Chronic arthritis is as old as man himself; it has affected both man and the lower animals from remote periods in the earth's history, and in the Museum of the College of Surgeons there are ancient Egyptian bones which exhibit all the changes which we have come to regard as typical of the disease.

Nomenclature. The Committee appointed by the British Medical Association in 1931 has adopted the following clinical grouping:

RHEUMATOID ARTHRITIS

Synonyms Chronic polyarthritis (Continental nomenclature).
Atrophic Arthritis (Goldthwaite)
Proliferative Arthritis (Nichols and Richardson) (American nomenclature)

Primary cause unknown, with further knowledge this may merge into

Secondary · associated with focal or general infection

CHRONIC VILLOUS ARTHRITIS

Mainly occurring in women at or about the climacteric.

OSTEO-ARTHRITIS

Synonyms. Hypertrophic Arthritis (Goldthwaite).
Degenerative Arthritis (Nichols and Richardson).

Primary · no definite association with infection

Secondary · associated with infection.

The first group, polyarticular and more common in females, may begin either in childhood, when it is known as Still's disease, or in early adult life—usually before the age of 40—when it is called rheumatoid

body posture which favours and induces mal-position of the thoracic and abdominal viscera. Such mal-positions in turn increase the faulty posture of the body, and so a vicious circle is established.

The Infective Theory. The infective theory is widely held and there is much to be said in its favour. It may be that organisms from some distant focus reach the joint and initiate the series of changes which characterizes the disease, or it may be that the joints have become hypersensitive to the presence in the blood of any circulating toxin which is being fed into the circulation from an obscure infective focus such as a septic tooth-apex The clinical course of the disease—where joint after joint is affected, swells up and becomes red, hot and painful, and then settles down—is certainly much more characteristic of a septicæmic than of a toxic infection

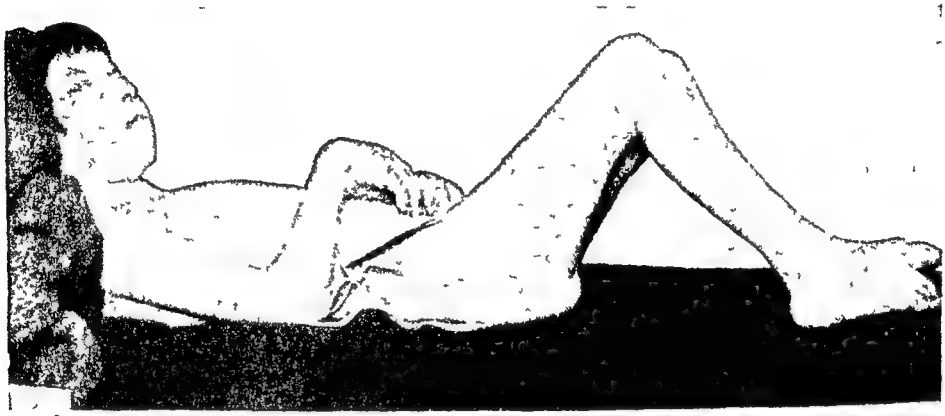

Fig 193.—Rheumatoid Arthritis of Joints

Case showing multiple infection of joints

In spite of persistent lack of evidence that focal sepsis can cause rheumatoid arthritis this theory remains the basis of treatment of a great number of arthritics in this country. Penicillin has been used in a great number of cases in this belief, but even with large doses the results have been disappointingly poor, so it is fair to assume that the condition is not caused by any of the bacteria which are known to be affected by this drug It has to be remembered that the infective type of polyarthritis with a rheumatoid distribution may derive great benefit if the causal organism is penicillin sensitive

It has long been recognized that those with arthritis often suffer from coldness and blueness of the hands and feet Exposure to cold shows that whereas the initial peripheral temperature is lower, the subsequent fall of temperature is also less When the subject returns to room temperature, the rise in the lowered peripheral temperature is also slower and less than in normal individuals. This is due to a condition approaching rigidity of the finer peripheral vessels because it is known that, other things being equal, the temperature in a part is regulated by the blood flow through it Again, direct observation of the capillaries

growth of granulation tissue from the marrow, or by the extension of granulation tissue over its surface.

Changes in the Bones. The bone trabeculæ may be diminished in size and in number, and the density of the bone decreased by the absorption of calcium salts from its matrix.

Changes in the Capsule. The connective tissue of the capsule proliferates and the capsule is therefore thick; it is liable to undergo conversion into dense fibrous tissue, so that movement at the joint may be seriously hindered.

Changes in the Joint. When the articular cartilages are destroyed by granulation tissue, fusion occurs and the resulting ankylosis may be fibrous, cartilaginous, or bony, according to whether synovial, perichondrial or the trabecular proliferation predominates. If the trabecular proliferation is excessive, all traces of the original joint are obliterated, and the compound bones are completely united, often with a single continuous medullary canal. Limitation of joint movement in this form of chronic arthritis is usually due to a degree of ankylosis, in contrast to the osteoarthritic type, where restriction of movement is usually due to the deposit of extra-articular osteophytes Associated with the tendency to ankylosis, there is a tendency for dislocation or subluxation to occur

Etiology

No definite cause has yet been ascribed to this disease. There are, however, two main schools of thought, which regard it as an infective and as a non-infective process, respectively.

Non-infective Theories. The non-infective factors which are held to contribute to the production of rheumatoid arthritis are:

1. A congenital predisposition.
2. Endocrine disturbances
3. Gastro-intestinal derangements

An interesting fact is the marked influence of heredity in the production of arthritis This does not mean that the disease is inherited *per se*, but it does mean that the background upon which the disease is implanted is definitely inherited in about 50 per cent. of all cases.

Little evidence can be adduced in support of the second of these factors, but derangements of the alimentary tract are occasionally found. These might almost be considered as infective factors since they are commonly inflammatory in nature, and often situated in the right iliac fossa.

Pemberton has recognized for many years the relation of gastro-intestinal disturbances, as determined by X-rays, to the arthritic syndrome, and the importance of dietetics in its treatment. The disturbances of the gastro-intestinal tract include dilatation of the bowel, achlorhydria, atony of the gall bladder, and general visceroptosis. In these conditions can be seen the influence of faulty

Diagnosis

Kersley reported a varied onset in a review of 750 cases. In 38 it was so acute as to resemble rheumatic fever and in 10 per cent of the whole there was a history of rheumatic fever Such acute attacks frequently followed a throat infection and this acute onset requires a diagnosis to be made between rheumatic fever, gout, gonococcal arthritis, and septic arthritis. Owing to the monarticular onset occasionally the differential diagnosis from tuberculosis has to be considered Frequently a biopsy is necessary. Another group of cases is distinguished by having an episodic onset and here the differential diagnosis lies between gout, palindromic rheumatism and intermittent hydrarthrosis.

The Arthritis Committee has pointed out the importance of differentiating between rheumatic infection of acute or sub-acute nature and rheumatoid arthritis. A useful table for differentiating the conditions is published in its report and is printed here in a modified form.

	Acute Rheumatism	*Rheumatoid Arthritis*
Incidence .	Chiefly adolescents and young adults of both sexes	Women of child-bearing age (at least in the primary form)
Onset . .	Acute.	Subacute (sometimes the two conditions are practically indistinguishable in the early stage)
Joints affected . .	Flitting from one joint to another, complete recovery of individual joints	Small peripheral joints with bilateral symmetry, persistence of changes after acute stage has passed.
Skin over joints	Red and hot	Shiny, cold
Pain and tenderness	Severe, very tender	Not severe, slight tenderness
Swelling . . .	Due to synovial effusion	Slight, periarticular.
Pyrexia . . .	May be present and is sometimes high	Not marked, occurs initially and/or intermittently thereafter
Cardiac involvement	Common, may be severe and permanent	Frequent tachycardia, but permanent lesions are rare
Spleen and lymph glands	Not enlarged	Not infrequently enlarged.
X-ray . . .	No change	Local or general osteoporosis
Response to salicylates	Satisfactory	Analgesic effects, but only temporary.

Prognosis

The prognosis should be guarded as the cartilage has but little power of regeneration, and even when it proliferates the deformity tends to increase. The outlook in a sense depends upon the elucidation of the cause, and, when a bacterial source has been discovered, upon

under the microscope shows them to be more or less closed, or at least empty, in the arthritic It thus appears that the rheumatoid syndrome is accompanied by a disturbance of peripheral vessels suggestive of vasoconstriction Vasospasm then appears to be a predisposing background for rheumatoid arthritis It is conceivable that without this underlying factor in such patients rheumatoid arthritis might not develop.

This is in keeping with the clinical observations of the frequency with which Raynaud's syndrome is encountered in the rheumatoid case, and fits in well with the long-recognized clinical effect of certain remedial measures used in arthritis, namely heat and massage.

Clinical Features

The disease is usually poly-articular, but may be mono-articular, and any joint, whether large or small, may be affected. It is commonest in early adult life, but may arise at any age.

The onset may be acute, or it may be insidious; the first sign is often stiffness or lameness, which gradually increases Although often mono-articular at first, it may spread to involve practically every joint in the body. The characteristic local changes are swelling and effusion, and the joint capsule becomes thickened. X-ray examination shows increased permeability of the bones in the neighbourhood of the joint, as a result of the loss of lime salts

After an acute attack there is a persistent slight deformity and some limitation of movement in the affected joints. These disabilities increase with each exacerbation until there may be gross distortion or even dislocation of the joints Adhesions form between the opposing articular surfaces, and they may be so dense that the joint cavity is obliterated and movement impossible. Albee has summarized completely the various clinical manifestations that may occur. These are . stiffness, or lameness, localized sweating of the hands and feet; decrease in the surface temperature, deformity, with flexion or subluxation, pain, at first slight, crepitus; limitation of motion, with ultimately apparent ankylosis of varying degree and form; constitutional derangements, lassitude, muscular atrophy, enfeebled circulation; sallow, thick, and dry skin, striated, hypertrophied or exfoliated nails. The facial expression bears eloquent witness to the chronic distress of body and mind.

Henderson and Adson divide rheumatoid arthritis into three groups:

(1) Advanced and accompanied by ankylosis.
(2) Less advanced and pain a pronounced feature.
(3) Vascular disturbances pronounced
    (a) Vaso-spastic phenomena of Raynaud's disease or thromboangiitis obliterans
    (b) Cases where pale, cold, clammy extremities precede or accompany the arthritis

Fig 194 —Rheumatoid Arthritis of the Wrist.

transfusion of fresh blood, are given for the hypochromic anæmia

Diet. No diet has any specific curative action in rheumatoid arthritis, but as patients suffering from it are usually considerably under weight a diet is prescribed to correct this. An adequate supply of proteins is required to build up the wasted muscles, and there is no justification in prohibiting animal protein such as beef, mutton, chicken, etc. The patient should be encouraged to eat liberal amounts of fatty foods because of their high caloric value Milk, cream, butter and bacon are valuable, particularly the first since it is so rich in calcium phosphorus and vitamins A and D. Cod Liver Oil and liver or liver extract are advised. The arthritic individual requires 100 to 200 mg. of Vitamin C daily, i e two to four times that needed by a normal person, and it is probable that an ordinary hospital diet is inadequate in ascorbic acid. Plenty of fresh vegetables and fruit should be taken. Vitamin B is important for the nervous system and the tone of the gastro-intestinal tract and therefore concentrates such as Yeast tablets—ill—t-i-d., or

Fig 195 —Rheumatoid Arthritis of the Hand. The typical appearance of the hand

the individual's reaction towards serum or vaccines. Some of the cases go rapidly down-hill in spite of all treatment, and permanent fixation of the joint may occur, usually as a result of bony ankylosis.

If patients are followed over a long period of time, their ultimate physical fate will fall into one of the following five categories, according to some writers:

1. Bed-ridden, or chair-ridden—10 per cent
2. Deformities or flexion contractures with continuing complaint of joint pain, namely disease still active and progressive—28 per cent
3. Deformities or flexion contractures without pain; i.e., the commonly called "burned-out" cases—12 per cent.
4. Occasional joint pain without deformity or joint contraction and no interference with function—22 per cent.
5. No signs of arthritis—26 per cent.

Further, in regard to the prognosis, it is found that the cases that do well start rather slowly and gradually in the first year. The typical severe symmetrical acute cases do less well.

Treatment

Team work is essential throughout the course of treatment of this condition, the team being composed of at least a physician, orthopædic surgeon, and physiotherapist. Effective treatment should combine the best remedial measures of all three groups.

The first obligation is, of course, to institute a thorough search for any possible infective focus. The mouth, nose, throat and abdomen are carefully overhauled and foci of infection or of suspected infection eradicated or treated. Promises of relief, however, should be as conservative as the removal itself should be radical.

General Treatment. The psychological aspect and its importance have been emphasized by Dunlop *et al.* The physician must secure the intelligent co-operation of the patient by taking her into his confidence, by explaining in simple language the nature of the disease and the principle on which the treatment to be adopted is founded, and by assuming an optimistic attitude regarding the results to be expected. Fresh air, sunshine, cheerful surroundings, good nursing, and nourishing diet are all factors of importance in improving the physical and psychological state of the patient. Since long-continued fatigue is an extremely important factor in initiating the onset of rheumatoid arthritis or in leading to relapse, rest—both physical and mental—is the first object to be achieved. In the acute stage rest must be complete until the active stage is past, but must be considered by the patient as only the first stage in an organized scheme of treatment. Pain is controlled by analgesic drugs in adequate quantities. Aspirin in 15 gr. doses four-hourly is especially useful for the pain, as are also phenozone (5–10 gr.) and amidopyrin (5–10 gr.). For insomnia Potassium Bromide, Chloral Hydrate and Tincture of Opium together are useful. Iron, or even

and of the total given in each course. The drug has its complications, the chief of which are toxic gold rashes, buccal ulceration, albuminuria, diarrhœa, and, less rarely, purpura and jaundice. The employment of excessive doses has been incriminated in the production of agranulocytosis. The initial dose should not exceed 0·02 gm. and the dose should be worked cautiously up to a maximum of 0·1 gm. The doses are given at weekly intervals and a course of 1·0 gm. is given. The onset of complications may interrupt the full course. Arthritic patients are more sensitive to the drug than tuberculous patients and the dosage must be a more cautious one.

Severe reactions are said to be lessened by giving 10 c.c. of a 10 per cent solution of calcium gluconate with the gold solution. A severe reaction is not to be regarded as a contra-indication to continuation of treatment at a later stage as it is said that 70 per cent. of the patients who have reactions in the first course have no further trouble in a later one.

At least four courses of gold must be given in two years to prevent relapse It is important that an interval of not less than six weeks should intervene between each course to allow complete excretion of the metal to take place

Examination of the blood is particularly important for controlling treatment. Decrease in white blood corpuscles and decrease in blood sedimentation rate, particularly the latter, are significant indications for reducing the dose.

The clinical results of gold treatment have amply confirmed the work of Forestier The general condition improves. Patients who were pale and cachectic show normal colour, look stronger and less depressed. The inflammatory condition of the joints improves, and in favourable and recent cases it disappears. In older cases it is usually very much alleviated. There is a very distinct action on pain, shown by the fact that these patients decreased the quantity of aspirin they were taking. Rawl reports marked improvement with almost complete remission in 53 per cent of 100 cases; 21 per cent definitely improved, and 12 per cent. slightly improved Douthwaite found disappearance of signs and symptoms of activity in 70 per cent of 200 cases, but noted relapses in those subjected to only one course of injection

Butazolidin Since J P Currie published his report on the use of this drug much publicity has been given to its effect as an analgesic in gout and various rheumatic conditions Kuzell *et al* studied 140 patients who had the drug by intramuscular injection or in tablet form. The tablets contained 125 or 200 mgm and a daily dose varied from 1 to 6. The injection was reserved for acute cases, the dose varying from 0·69 to 1 09 Gratifying results were reported. It is a valuable analgesic and patients have a feeling of well-being when taking it Some patients, however, derive no benefit; the drug is dangerous and the injections may produce a residual abscess

Cortisone In considering surgical treatment of rheumatoid arthritis

bemax or marmite, one to two drachms daily are included in the diet

Physiotherapy. Prolonged physiotherapy by trained physicians or physiotherapists is beyond the means of the majority of patients. The method is of distinct value, however, and the above disadvantages may be partly overcome by instructing the patient himself to carry out a daily programme of physiotherapeutic treatment, which can be supervised periodically The measures of greatest value are hot and cold compresses, wax baths, contrast baths and showers, simple yet specific exercises, and, if necessary, hot sand or salt bags For the more fortunate or the more desperate patient, a prolonged stay in a warm equable climate is indicated, but that too is usually more palliative than curative.

Medical Treatment. The use of Vitamin D in Rheumatoid arthritis in which atrophic changes and osteoporosis are features is a sound therapeutic measure in moderate doses—400–600 i u daily.

Treatment by Gold Salts. Gold preparations were introduced into the treatment of chronic rheumatism by Forestier of Aix-les-Bains and still have an established place in the long term treatment of rheumatoid arthritis. Snorrason showed in a series of 368 cases that with gold therapy it is possible to arrest the disease in 72 per cent of cases as compared with 23 per cent who did not receive the treatment. As gold is powerful it is contra-indicated in patients with great weakness, intense anæmia, cachexia or lack of reaction

The mode of action of gold, or more precisely the gold-sulphur preparations in use, is problematic They seem to stimulate the immunity organs to the production of antibodies against the infective and toxic elements present in the chronic rheumatic There are grounds for believing that their action takes place through the reticulo-endothelial system Gold injections produce an artificial disease, a gold disease more or less similar to the "rheumatic disease." Their action can thus be explained in the light of modern immunological principles

The most important preparations used are .

Sanocrysin, a thiosulphate of sodium and gold, the preparation originally used by Moellgaard in the treatment of pulmonary tuberculosis ,

Calcium Aurothiomalate This has been found to be 100 times less toxic than the sodium salt

In chronic rheumatism oily preparations have proved best (oleo-sanocrysin, solganal B oleosum), the degree of tolerance of gold being increased by suspension of the metal in oil These preparations can be injected intramuscularly, forming a deposit in the muscle. As a rule absorption is more gradual and the effect more protracted and uniform by this method, and secondary effects are lessened Only intramuscular injections should be given in chronic rheumatism.

Dosage is important, both in the matter of the individual dose,

but is much less harmful The movements must never be carried to the point where they cause pain.

Immobilization. Since rheumatoid arthritis is essentially inflammatory and the disease in the joint consists of a spread of pannus across the cartilage and granulation tissue deep to it, Dr. Vincent Coates believes that the more rest allowed to such a joint the more prospect is there of arresting such a process. On this basis he has suggested that absolute immobilization in plaster of Paris would help to heal such joints

Kindersley states that the effect of the plaster is that locally it relieves pain, allows subsidence of the inflammatory process and absorption of effusions; its general effects are the comfort of the immobilization which produces sleep without sedatives, an improvement in the general health, and a relief of spasm. The coarse tonic spasm of the muscles which goes on night and day is controlled and the muscles are rested and allowed to regenerate. The plaster prevents deformity and in certain cases may be used to improve any deformity present.

It is obviously quite impossible to splint every joint in the body and in practice this is found unnecessary. The joints which give rise to severe pain and are rested with the greatest difficulty are the knees, ankles and wrists. This means applying one long plaster to each leg and a small light plaster to the forearm and wrist.

A skin-tight plaster is applied and from two to twelve days after the application the plaster is bivalved, and as soon as possible the patient is given the usual general treatment, especially deep hot baths. After the physio-therapeutic treatment the patient goes straight back into the splint, and the muscles are massaged on alternate days After two to three deep baths the joint is allowed free for half an hour and then returned to the splint. Heat and swelling, particularly heat, are the indications for prolonged rest in the splint.

In cases where fibrous adhesions have formed, and the joint has become stiff in bad position, it is sometimes possible to restore a certain amount of mobility by skilful manipulation. The adhesions should be gradually stretched each day, the manipulation being carried out with the greatest care lest a recrudescence of the disease be precipitated.

Operative Treatment.

The commonly accepted treatment has been the avoidance of operations during the acute stage of rheumatoid arthritis, and the principle of rest is still the basis of all conservative treatment but there are still these reasonable indications for operation. Though the methods overlap the main indications are —

1 Removal of foci of infection.
2 Relief of pain
3. Restoration of function.
4 Correction of deformity.

we must attempt to clarify our thoughts about the possibility of using cortisone or ACTH—that very important discovery by Hench, Kendall, Slocumb and Polley in 1948 This discovery, although failing to maintain its brilliant promise, has done much in stimulating the medical world in possible therapy for this disease as well as in research. Following a multi-centre trial of the drug by the Empire Rheumatism Council the conclusion was reached that "the only possible generalization on the long-term treatment of rheumatoid arthritis to be drawn from the results of this trial is that either aspirin or cortisone plus a basic regime of general care, including physiotherapy and splints, will produce improvement in patients carefully selected. Similar disappointing results have been got in children"

We have seen how these drugs can relieve muscle and joint stiffness and arrest pain, improve joint movement, with decrease in swelling and effusion, but then limitations weigh heavily against these highly desirable properties Undesired side effects such as sodium retention producing hypertension, cardiac failure and hypo-potassæmia, abnormal fat deposition, sexual endocrine changes, osteoporosis of bone secondary to a negative nitrogen balance, and depression of the protective inflammatory reactions, would be a cheap price to pay if these drugs did produce a cure Unfortunately, the disease process is only suppressed and there is always relapse on withdrawal of the drugs. As yet there is no safe or practical form of long-term administration, nor any means of prolonging the periods of improvement once the drug has been stopped Research is, of course, being carried out to produce new compounds possessing these desirable properties.

The drug, however, has its uses for the surgeon and Kersley has recently given us a very useful guide in the use of these drugs as short courses during this disease

1 To prevent any flare-up if surgery is required during an active phase;

2 In the correction of flexion deformities of the joints, by manipulation, although probably an intra-articular injection of hydrocortisone is to be preferred,

3 To assist rehabilitation to a more important grade of fitness, and

4 In the patient who is deteriorating in spite of all other treatment.

Treatment is directed towards changing the natural course of the disease, and so it is important to have some information on this.

Local Treatment. *Rest* When joint irritation is present, with muscular spasm and pain, rest is necessary. In the acute stage the patient should be placed in bed, with traction applied to the affected limb It is important to bear in mind that there is a strong tendency to early and rapid ankylosis, so that a careful compromise must be made between rest and movement This problem is best solved by allowing the patient non-weight-bearing movement, as regards joint function this is just as useful as weight-bearing motion

which have their ganglia in the spinal cord. Orbelli believes that the relief of pain following sympathetic denervation is due to lowering of the sensitiveness to pain Young suggests that the augmentation of the blood supply might be the chief factor in causing improvement The cases of chronic arthritis selected for ganglionectomy are those in whom the disease is progressive, and who have failed to respond to the accepted types of treatment, such as the removal of foci of infection, immobilization, massage and exercise, and who present the vaso-spastic syndrome that is temporarily relieved by radiant heat, diathermy, and vaccines. Pemberton also believes that ganglionectomy offers a rational method of influencing the circulatory vasoconstrictor disturbances occurring in young persons with soft arteries. He thinks it important that the surgical procedure should be instituted early in the course of the disease, before bony changes have taken place, in order to obtain the maximum results from the operation. F A. Bothe suggests that ganglionectomy is most beneficial in the third group of arthritis—those with prominent vascular disturbances—and though it may help some in type 2, it is of little use in the first group.

Pain in the Shoulder. This is a common site for pain and it is associated with internal rotation and adduction of the arm from spasm and, as Smith-Petersen has pointed out, often a subacromial bursitis. He suggests a removal of the acromion process and the underlying infected bursa. This allows free movement and by relieving muscle spasm modifies the pain. The acromion process is removed through the acromio-clavicular joint and the deltoid sutured to the periosteal attachment of the trapezius muscle In cases where the articular cartilage is grossly affected an arthrodesis in the optimum position and retained in plaster may be necessary and will be a short cut to what will eventually happen and will eliminate months of pain and ensure a reasonable position for function

Pain in the Elbow. Smith-Petersen has shown that the radial head may be drawn upwards to the capitellum by spasm of the biceps. Excision of the head of the radius reduces the consequent pain and improves the forearm and elbow movements Where there is gross destruction of the joint a formal arthroplasty may be carried out. A flail joint is unlikely here because of the fibrosis round the long-inflamed joint. Fascia lata or cellophane is used to form the joint cavity and to prevent undue fixation—always a danger in arthroplasty in this disease.

The Knee Joint. This joint in the rheumatoid patient is the one that most commonly requires surgical treatment. It is the largest joint in the body. Because it is a weight-bearing structure it is frequently attacked. The first signs of impending deformity are pain, swelling and flexion

Atrophy of the muscles and ligaments about the joint appears rapidly Subluxation and rotation of the tibia on the femur may occur as the fluid subsides. The joint space usually becomes narrowed and the patella is often fixed against the femoral condyles, and fusion may

1. The removal of foci of infection. Therapy based on the unproved assertion that the disease is due to any known microbe and that it can be checked by the elimination of focal sepsis is becoming less and less popular since results have become correspondingly more disappointing. Yet it seems reasonable to search for and remove any sepsis since its removal should at least improve the general health and help to modify the course of the disease if only secondarily and not directly. The nose, throat, teeth and the various possible foci in the abdomen, etc, are accordingly investigated and any infective area removed or treated

Synovectomy. Since the synovial membrane may be a secondary storehouse of infection its removal is justified in certain cases, particularly those with local tenderness The operation is also of value in chronic gonococcal arthritis with sub-acute synovial changes. Allison, indeed, says there are few contra-indications to this operation. Pain and discomfort are greatly relieved, the function is improved, and marked improvement occurs in the other joints affected. Age, poor general condition, and hopeless inactivity, therefore, are not contra-indications. Allison has operated on subjects who have been bedridden for years, and found that they tolerated the operation well, improved in every way, and were finally able to walk. The operation is rarely carried out other than in the knee-joint.

Technique. A tourniquet is applied and the joint opened through a parapatellar incision, the patella being dislocated laterally. It may be possible, while the joint is actually being opened, to separate the synovial membrane from the capsule along the line of the incision. The infra-patellar pad of fat is divided, its lateral half seized with heavy clamps and the synovial membrane dissected free from the deep surface of the patellar tendon and the head of the tibia Both menisci are removed The lateral pouch of the joint is stripped of synovial membrane up to the border of the patella and the lateral aspect of the femoral condyle also cleared The supra-patellar pouch is similarly stripped and the separation continued over the medial condyle of the femur to the medial pouch of the joint The space between the femoral condyles and the two cruciate ligaments is now cleared The entire joint cavity is carefully wiped with gauze to remove any loose vestiges of the membrane. The wound is stitched up, a firm dressing is applied, and the tourniquet is removed. The knee is supported in suspensory slings and kept at rest for about forty-eight hours. Thereafter, joint movement is encouraged, and radiant heat, massage, and exercises commenced Functional use of the joint should be encouraged as soon as possible

2. The relief of pain.

Operations on the Sympathetic System. Adson and Rowntree have obtained surprising results in chronic arthritis by the resection of the lumbar sympathetic ganglia. Generally speaking, the muscular tone and calibre of the arterial system is governed chiefly by the sympathetic nerves The sympathetic nervous system also conveys sensory fibres

until the active arthritic process subsides. A flare-up occurs infrequently in a joint that has been manipulated, and in many cases the activity subsides when the joint deformity has been corrected.

There are certain cases where movement is good from a position of about 20 degrees short of full extension to almost full flexion. This limitation of full extension is due to either adhesions of the patella to the front of the femur or capsular shortening behind

Correction of deformity is of no value unless the motor control of the joint can be restored The extensor motor apparatus in the knee of a patient who has had a severe flexion-deformity for years is inefficient, due to the over-stretching of the quadriceps muscles during the years of deformity and the inefficiency of the muscle itself due to atrophy, intramuscular adhesions, and loss of muscle skill and often patello-femoral adhesions Seldom can corrective exercises alone restore the extensor motor apparatus to normal efficiency after a severe flexion deformity has been corrected by posterior capsulotomy and hamstring tendon lengthening. There is too much slack in the extensor quadriceps apparatus when the knee is brought into full extension. Occasionally a patient is able to develop the ability to lock the knee in full extension after months of corrective exercises. But the average patient fails to secure complete active extension and as a result he gradually develops a partial recurrence of deformity in spite of the most painstaking post-operative care.

To correct this situation it has been suggested that the tubercle of the tibia may be moved distally a distance of about an eighth to a quarter of an inch for every 10 degrees of flexion deformity, so that there is tightening up of the extensor apparatus The result is an improvement of efficiency of the apparatus and a decided shortening of the period of post-operative corrective exercises. All such patients develop full active extension of the limb to the previous range of passive extension These patients are kept in hospital until they are able to stand bearing weight upon the operated leg with the knee in extension.

The most common operation for the rheumatoid knee joint is an arthrodesis, and even where both knees are affected an arthrodesis of one, giving a firm, stable, painless, weight-bearing joint is of immense value, and if a synovectomy is done at the same time it seems to have a beneficial effect systemically. The pressure type of arthrodesis is not used since the bone is, in any case, very osteoporotic and would hardly hold the compression pins The capsule behind is shortened and tight, and usually holds the joint surfaces together after they have been excised. For fixation, crossed excision pins are used and the leg is put in a plaster case. There is usually little difficulty in getting a good arthrodesis, and if it is fixed at about 10 or 15 degrees of flexion it gives a very useful limb indeed.

Where both joints are involved the ideal is, of course, an arthroplasty in at least one, and this would be particularly beneficial where there were multiple ankyloses, or stiffness perhaps of both knees and hips.

eventually take place between the two bones. Contracture of the hamstring muscles, joint capsule and periarticular structures can be brought about by placing pillows under the knee joint in the flexed position.

In cases in which muscle spasm is pulling the joints into a position of flexion, a plaster-of-Paris splint should be applied, so as to immobilize them in their best position for a few days. Spasm and pain will be abolished and the B S R lowered by this procedure, and after a few days the splint can be removed and the joint put gently through full movement once daily in order to prevent adhesions forming. Another plaster can then be applied, and it will generally be found that on this second occasion it will be possible to fix the joint in a better position, and possibly, in time, in full extension. After a week this second plaster also should be removed and the posterior portion retained for use as a gutter splint. The affected limb should be bandaged into this for most of the day, being removed only for gentle movement once daily.

Later, further measures will be required to restore active function and stability of the affected joints, these will involve the re-education of the muscles which should control these joints. Premature weight-bearing in the absence of such control must be avoided, since it will lead only to recurrence of pain and effusion, and so to further muscle wasting. This stage of muscle re-education consists in skilfully graduated resisted exercises and physiotherapy, which may lead on to the use of the stationary bicycle or rowing machine before actual walking is allowed, with or without the help of crutches or sticks.

In patients who become severely crippled in spite of adequate medical treatment, certain orthopædic measures may become necessary Skilled surgical intervention need no longer be delayed on account of the disease being in an active stage

In order to maintain function after manipulation with intra-articular hydrocortisone, once the local activity has subsided, several rules must be followed by the physician

1 Restore all movements and strength possible through rest and exercises before manipulation.

2 Use of the proper technique of manipulation—which really means not too forcible and with a short leverage.

3. Splint the manipulated limb in the corrected position, for only a few days until the reaction subsides.

4 Have the patient start muscle contracting in the splint at once, and then passive and active exercises after four to six days, increasing as quickly as is tolerated comfortably

When the complete splints are opened on the fourth or sixth day, the posterior halves are kept as rest shells and are used between exercise periods. Usually in four to eight weeks the patient will be strong enough to stand in good position, balancing only with crutches and without braces, or she may use a walking machine Except for the exceedingly hot or acutely painful joint, manipulation does not need to be postponed

gradually in the convalescent period. Often "revision" operations are called for because of loss of movement and new bone formation. It may be that a removal of head and neck after the manner of Girdlestone is a better procedure than the various forms of arthroplasty even in spite of the fact that this method produces a somewhat unstable joint and may necessitate crutches in the future. It is probably better to carry out the operation, whatever it may be, at an early stage in the disease before the soft tissues have become damaged by disuse and fibrosis.

The Feet. The arthritic patient who possesses a foot under constant strain is more likely to have it attacked by the disease than a normally-shaped foot. Furthermore, if deformities are present at either the hip or the knee, there will be a resulting foot strain. For example, permanent flexion of the knee may produce a sufficient strain on the metatarsal heads to produce acute pain. External rotation of the leg leads to pronation or longitudinal arch strain When a patient has been confined to bed for a long time the muscles and ligaments become relaxed and foot strain appears on weight-bearing In all such instances the feet must be well protected by arch supports and strengthened by exercises. Foot hygiene must be just as carefully carried out in the arthritic as in the diabetic patient

With the onset of arthritis in the ankle or tarsal joints, protective muscle spasm appears and tends to pull the foot into a valgus position. The pull of the gastrocnemius, aided by the force of gravity, and the weight of the bed-clothes, tends to thrust the foot into an equinus position This resultant equino-valgus deformity not only causes the front arch to be depressed during weight-bearing but leads to a dorsiflexion of the toes as well. In time, hammer toe deformities develop.

In the acute phase, when the feet are swollen and painful, weight-bearing is definitely contra-indicated. In such cases a plaster boot that extends from below the knee to just proximal to the metatarsal heads on the plantar surface and to the tips of the toes dorsally, is usually worn with comfort It must be bivalved so that the foot may be removed for daily movement and physiotherapy Foot exercises should be taught to the patient as soon as the foot is pain free

If deformities have taken place, they may be corrected by serial plaster dressings, which should be left on for forty-eight hours A new attempt at correction can then be made in about seventy-two hours

Manipulations under anæsthesia are helpful in gaining better positions, but the corrected position should be held in a splint for four to six days. In the most refractory cases operative measures, such as a fusion or a radical correction of hammer toes, has to be resorted to.

If the foot is in a position of fixed deformity, a triple arthrodesis is carried out It is an easy operation in the rheumatoid case because of the softness of the bones A wedge of bone is removed, and with very little force the foot may be easily manipulated into a good position It soon fuses and results are very satisfactory.

When doing an arthroplasty, fascia lata was used in early cases, but has been very disappointing in that most cases became ankylosed again, or it resulted in only a few degrees of motion which was of no practical value Attempts to use metal as an inlay have raised a number of problems which have not yet been solved, but these problems are being investigated every day and the time may not be far distant when a new acrylic prosthesis for a knee arthroplasty may be available.

At present nylon is being used instead of fascia. Because of nylon's great strength and elasticity, it has been used in the repair of defects in neuro-surgery, as well as for interposition in the carpo-metacarpal joints In planning the operation of arthroplasty of the knee by nylon, it is noted that a functional rather than an anatomical joint is attempted.

Results of this operation are such that we still must endeavour to find a more suitable form of arthroplasty, the main difficulty being, of course, that the stability and function of the knee joint is dependent upon ligaments which have been disrupted by the disease process and are functionless The mechanical problem is therefore great Where the chief trouble is a patello-femoral fusion—bony or adhesive—it is a good procedure to remove the patella.

The Hip Joint Pain referred to the anterior thigh and medial aspect of the knee may be the first symptom of arthritis of the hip. Examination may reveal from a slight permanent flexion deformity and, after exercise, some muscle spasm, to a marked flexion-adduction deformity with rest pain.

To correct the earliest permanent hip flexion the patient should lie prone in bed at least once a day, starting with one or two pillows beneath the abdomen. As the pillows are gradually removed, the hip will assume a neutral position from the stretching of the anterior structures.

A simple device to preserve muscle tone may be arranged by supporting the leg in a padded canvas cuff suspended by an elastic cable from an overhead bed frame. The patient can do so-called bicycle exercises almost as effectively as if he were in a water tank.

If the painful hip deformity is still present after conservative therapeutic measures have been exhausted, or if ankylosis has occurred in a poor position, an arthroplasty may give a painless movable joint. When ankylosis is inevitable and the general condition of the patient does not warrant an operation, the hip should be allowed to fuse in slight flexion, without rotation, and in about 10 degrees of abduction—the neutral position.

Arthroplasty as by Judet's technique, or a pseudarthrosis of Girdlestone or Batchelor may be attempted, especially if other joints are involved Movement at the hip with ankylosis of the knee joint allows the patient to manage some degree of lying or sitting comfortably and therefore should be restored to the patient.

There is little doubt, however, that this disease is the least favourable condition for arthroplasty, as there is a great tendency to stiffen up

possible in addition to 15 degrees of flexion (Fig 196) A wedge osteotomy combined with tenotomy of the adductors may be used similarly for flexion-adduction deformities of the hip When both hip joints are ankylosed, a pseudarthrosis on one side and an osteotomy on the other will often improve the function to a considerable extent.

Girdlestone has suggested an alternative procedure for bilateral ankylosis of the hips He suggests removal of the head and proximal part of the neck, allowing the femur to ride up on the side wall of the pelvis A movable hip results but the result is apt to be unstable especially if done on both sides Smith-Petersen in such cases carried out a cup arthroplasty. He aimed at producing a joint which is painless,

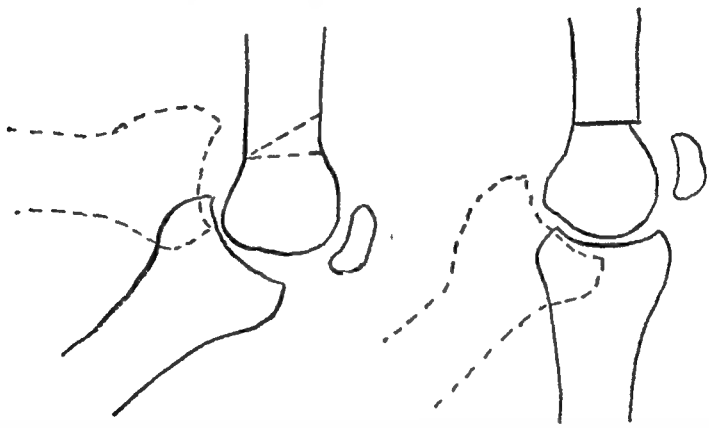

Fig 196.—Wedge Osteotomy of the Femur in Rheumatoid Arthritis.

Where a patient has a few degrees of movement in the middle of the arc of flexion, it is possible by doing a wedge osteotomy of the femur, as above shown, to give him a knee joint which is much more useful After the osteotomy he has full extension and his few degrees of movement are from the fully extended position in the direction of flexion

stable, and capable of bearing weight His form of arthroplasty restores some movement but this is variable in extent and may only be produced after more than one revision operation This usually consists of the removal of more bone The wasting and fibrosis of muscle, an ordinary accompaniment of the disease, is an obstacle to the strength—and often the extent—of the movement.

In performing the operation in rheumatoid arthritis Smith-Petersen removed more bone and made the acetabulum much bigger and deeper, and indeed there remains ultimately little but periosteum on its floor. The joint capsule and the synovial membrane are also removed completely, as is all of the articular cartilage, so allowing free movement between the head and the acetabulum. Where the head is atrophied, small, and soft, the arthroplasty can be done at a more distal level. The trochanter is then displaced down the outer aspect of the shaft and fixed, carrying with it its attached muscles, and the region from which it was detached used to fit into the acetabulum. This is after the manner of a Whitman reconstruction

After these operations the limb is put in traction for 4 to 6 weeks and during this period movement and rehabilitation of muscles are

3. Restoration of Function. Many of the methods already described go a long way towards restoring function The arthroplasty of the hip and elbow, and denervation of the hip, all enable the patient to use his limb to better purpose, and even the arthrodesis, though abolishing the function of the joint, restores the function of the limb

The Wrist Joint This joint usually becomes ankylosed in flexion and in ulnar deviation and is consequently weak and rather useless. A very useful result can be obtained by resecting 2 inches of the lower end of the ulna, or a partial resection of about 1 inch of shaft at the lower end leaving the terminal half-inch—an operation described by Baldwin. This will permit pronation and supination if the proximal radio-ulnar joint is healthy. The wrist itself may be arthrodesed in a position of maximal function—that is dorsiflexion. Such a combination of operations is most useful, too, in abolishing pain.

Fingers The hand is usually affected and the finger joints stiffen up, often in extension and with a characteristic unsightly and crippling ulnar deviation This latter is a postural deformity produced by gravity since it may not be seen in bed-ridden patients. Splints may be worn to prevent this in the acute stage (Bodenham). Arthoplasty of a formal type may be used with hope of considerable improvement.

In the formal type of arthoplasty a joint space of about 1 cm. is obtained mainly at the expense of the proximal phalanx. The metacarpal head is left broad and flat laterally but tapered antero-posteriorly; a fascial flap is interposed. Capsulectomy is advised for joints stiff in extension if the surfaces are intact and cannot be mobilized by physiotherapy and traction. An incision is made on each side of the joint. The extensor expansion is split lateral to the extensor tendon and the collateral ligament completely removed. If the interphalangeal joints extend when the metacarpo-phalangeal is flexed adhesions exist in the extensor tendon and must be corrected The phalanx must glide round the anterior surface of the metacarpal head and not open like a book; this latter movement is due to an adherent anterior capsule and must be corrected by stripping. Full correction is maintained for three weeks after which removable traction is employed for one month

The carpo-metacarpal joint of the thumb is often severely affected and is then painful and rather useless Arthrodesis in a good functional position of apposition produces a useful digit against which the fingers can produce a good grip

4. Correction of Deformity. (*a*) *Osteotomy.* When deformity at the hip or the knee is too great to be corrected by manipulation or by traction, then a wedge osteotomy may be performed In the knee, at certain stages of the disease the patient may have 10 or 15 degrees of movement in the joint, but since the joint is in a position of flexion such a range is inadequate to secure extension, and the function of the joint is bad A wedge osteotomy at the lower end of the femur will so alter the functional position of the joint that full extension will be

carried out intensively It is obvious that a good deal of any success achieved will depend on the patient's will to get well.

In arthritis of the knee the best functional result is got by fusion of the joint but mobility is most desirable where other joints are affected —as they usually are—and so attempts may be made to improve the condition and yet preserve movement. Arthroplasty of the knee is not satisfactory but a debridement as advocated by Magnuson, where the synovial membrane, the menisci, and diseased cartilage are all removed, is attended with some measure of success. In a case with flexion deformity and some luxation, posterior capsulotomy along with division of ligaments gives a good result in many cases. If adhesions are dense subperiosteal stripping of the capsule off the posterior aspect of the femur is an easier method of overcoming the flexion deformity.

Still's Disease

Most observers believe this condition differs from rheumatoid arthritis only in that it develops in childhood. The changes are more confined to the peri-articular tissues, there is little radiological evidence of destruction of the actual joint surface, and the joint swelling and muscular wasting are accompanied by a lymphatic reaction which shows as an enlargement of the lymphatic glands, especially those around the elbow and in the axilla. Often the spleen is enlarged. The glands are tender, discrete and rubbery Often there is a secondary anæmia and quite often patches of light brown pigmentation on the skin

The course of the joint disease is as in rheumatoid arthritis, going on eventually to fibrous ankylosis often with considerable deformity. Twenty-five per cent under 5 die, and complete recovery occurs only in a few cases. Treatment is on the lines of that suggested in rheumatoid arthritis of adults.

There is only a difference of degree of lymphoid reaction to separate Still's disease in infants from the rheumatoid arthritis of adults.

Reiter's Disease

This clinical syndrome may be confused with rheumatoid arthritis or gonococcal arthritis It is characterized by acute polyarthritis, urethritis, and purulent conjunctivitis. The causative organism has not been demonstrated The onset of the arthritis is acute and widespread with an elevated temperature. The joints commonly involved are the knee, ankle, foot, shoulder, elbow and wrist Osteoporosis is the only characteristic X-ray appearance and is visible eight weeks after the onset There is a polymorph leucocytosis with a considerably elevated B S R Joint fluid contains about 10,000 leucocytes per cubic millimetre, with 70 per cent neutrophils The conjunctivitis and urethritis subside in 4 to 6 weeks. The arthritis disappears in 6 to 12 weeks, but recurrences may take place. Neither penicillin nor sulphonamides have any influence on the course of the disease It has been suggested that pleuro-pneumonia-like organisms found in the urethritis may be the

started it automatically continues and becomes progressively worse as a result of this constantly increasing trauma caused by motion and weight-bearing. It is possible that avascular necrosis as a result of the trauma plays some part in the process.

FIG. 197.—Osteo-arthritis.
A dry specimen of an advanced case showing the lipping, formation of osteophytes, and the deformity.

PATHOLOGY

The primary lesion in osteo-arthritis consists of degeneration of the hyaline cartilage. As a result, the cartilage is soft and is easily and rapidly eroded until ultimately the bone-ends are exposed. The erosion of the cartilage is not uniform, so that at first areas of bone are exposed in a patchy fashion and there are intervening islands of normal cartilage. The process gradually becomes more comprehensive, until finally the bone-ends are entirely denuded, but the process is so slow that joint movement is maintained for a considerable time. The perichondrium and the cartilage round the periphery of the joint are stimulated into activity, and, as a result, the non-articular areas of the bones are heaped up and elevated above the remainder of the surface, and project circumferentially to give the appearance known as "lipping." In addition, irregular outgrowths appear in this area, at first cartilaginous, but eventually becoming ossified to form osteophytes.

The synovial membrane is involved in the later stages, and is the seat of an irregular shaggy proliferation. The synovial tags or polypi are insinuated into the joint, and when very exuberant the process is referred to as "lipoma arborescens." Occasionally cartilage formation occurs in these tags, and they are then liable to be broken off into the joint, when they are known as "joint mice." The exposed bone-ends of the articular surface are subjected to considerable friction; in

Treatment

If the symptoms are very acute complete rest and immobilization are indicated. In less severe cases, partial rest and a bandage with perhaps a light posterior splint may be sufficient Diathermy, short wave therapy, radiant heat, and local douching are helpful Any existing deformity of the foot must be corrected, and varicose veins, if present, are treated. General measures include thyroid medication, and agencies for the reduction or prevention of obesity, with sedatives if pain is severe. In severe cases synovectomy may be carried out, usually with good results

OSTEO-ARTHRITIS

This disease is characterized by primary degenerative changes in the articular cartilage and subsequent new bone formation at the articular margins The larger joints are those usually affected, with the hands and feet sometimes affected as well. The disease occurs in the middle-aged and elderly, who, although healthy in other respects, often show evidence of arterial and other degenerations

Etiology

The etiology of this condition may be discussed under the following headings.

(*a*) *Local Causes.*

(1) Previous trauma—fractures, involving the joint; dislocations, occupational strain, altered articular alignment from disease; joint mobility, from relaxation of ligaments

(2) Nutritional bone diseases in infancy—Coxa Vara, Perthes' disease, rickets.

(3) Congenital dislocation of the hip, especially after forcible manipulations.

(4) Errors in local blood supply of the joint as after aseptic necrosis of the head, osteochondritis dissecans.

(5) Subacute infections of the joints in earlier life, as rheumatoid arthritis

(*b*) *General Causes*

(1) Generalized toxæmia from localized foci of infection.

(2) Diseases interfering with the nerve supply of the joint.

It is generally believed that degenerative arthritis is the result of wear and tear of increasing age and repeated trauma which may be caused in a variety of ways and that it is not the result of an inflammatory process, metabolic disturbance or endocrine dysfunction. The trauma is often found in mal-alignment, over-weight or primary injury, and these in some cases may be the sole cause Probably oft-repeated slight trauma is the major cause and after the roughness of the cartilage has

The immediate reaction to degeneration of the cartilage is proliferation of the subchondral blood vessels which is interpreted as an attempt to bring about repair Calcification takes place in the deeper layers of the cartilage and then the blood vessels enter this calcified cartilage and further calcification takes place ahead of them In the non-pressure areas this process continues indefinitely, the vessels spread outwards preceded by a vanguard of calcification capped with a layer of fibro-cartilage, thus gradually increasing the size of the bone This is the way osteophytes are formed. In the vascular zone beneath the pressure area cysts are formed and these cysts always communicate with the joint through small openings The cysts increase in size from the intermittent pressure of the synovial fluid At a later stage the hyperæmic bone, no longer protected by its covering of articular cartilage, decreases in height as a result of successive trabecular fractures.

Capener, on the other hand, says the similarity of changes seen in an example of spontaneous osteo-arthritis of the hip joint compared with those which develop in this joint as a result of avascular changes in the femoral head following injury to the neck of the femur strongly suggests that osteo-arthritis is a disease of defective vascular supply and strengthens the analogy to arterio-sclerosis as a manifestation of an ageing process.

2. Changes in the Capsule. These are slight The fibrous tissue of the capsule becomes more dense and, at its point of attachment to the articular margin, may even be transformed into fibro- or hyaline cartilage In some cases bony nodules appear under the surface of the synovial membrane and project into the joint cavity. These nodules may be sessile, or pedunculated; in the latter event they may be broken off to form joint mice and may then cause the joint to lock, or otherwise interfere with the free mobility of the joint

3. Changes in the Synovial Membrane. The synovial membrane rarely shows any pathological change until the first signs of lipping appear. The membrane then appears thickened, the villi already present are enlarged, and new villi are thrown out. These projecting villi may become the seat of cartilage formation or become infiltrated with adipose tissue.

Clinical Features

The traumatic form of osteo-arthritis is mono-articular and usually, but not invariably, affects one of the large joints; the infective, or toxic, form, on the other hand, may be mono- or poly-articular, and frequently starts in the small joints of the hands and feet

The onset is slow and insidious, and the disease is seldom associated with a rise of temperature or with marked constitutional symptoms. The earliest symptom is stiffness experienced after rest and disappearing on movement. At this stage a soft creaking can be felt and heard

consequence the bone trabeculæ in the immediate neighbourhood are thickened and the marrow spaces obliterated. The change involves only a thin layer abutting on the joint, and when the surface of this layer gradually becomes more and more smooth and polished as a result of the continual rubbing, the process is known as eburnation.

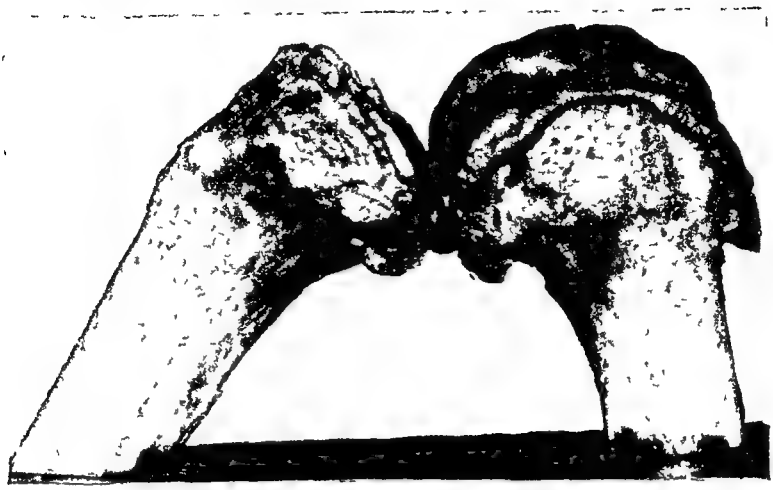

Fig 198 —Osteo-arthritis of the Knee
Dry specimen showing the lipping, deformity, etc

An osteo-arthritic joint rarely if ever becomes completely ankylosed, in contrast to the rheumatoid form in which ankylosis is almost the rule. Nevertheless the gross peripheral proliferation and the presence of osteophytic outgrowths may to a great extent impede the free movement of the joint, and even simulate a degree of fusion which does not in fact exist.

Changes in the Individual Joint Constituents.

1. The Articular Cartilage. The earliest change in osteo-arthritis begins in the hyaline cartilage Harrison *et al.* believe that this is not ordinarily, as was previously supposed (Fisher, etc.), at the summit of the head of the femur, i e., at the main pressure area, but at the non-pressure area of the lower part of the head which is opposite to the part of the acetabulum without an articular lining. They found that every femoral head examined showed degenerative changes in the cartilage These changes in 71 per cent. of femoral heads were in the non-pressure areas ; in 26 per cent in both pressure and non-pressure areas ; whereas in only 3 per cent were the changes restricted to the pressure areas. They argue that use and compression are necessary to maintain the nutrition of the articular cartilage The intermittent pumping action of alternate pressure and rest forces the synovial fluid into the cartilage Hence where pressure is absent, nutrition is likely to be absent and degeneration occurs more readily.

	Primary Rheumatoid Arthritis	Secondary Rheumatoid Arthritis	Chronic Villous Arthritis	Osteo-arthritis
Incidence	Women of child-bearing age	Any age, either sex	Women at menopause	Both sexes in later decades of life
Onset . . .	Generally sub-acute	Sometimes acute	Slow and chronic	Slow and chronic
Infection . .	Not proven	Septic focus	Not proven	Present only in secondary form
Prodromal symptoms	Present	Absent	Absent	Absent
General condition of patient	Ill and emaciated	Affected in later stages only	Florid and healthy	Tending to show signs of senile changes
Joints affected .	Small joints, tendency to spread centripetally	Any joint distribution; tendency to symmetry	Predominantly knees; also 1st carpo-metacarpal joints	Large joints, especially hip
Appearance of joints	Fusiform swelling accentuated by wasting of surrounding tissues	Fusiform swelling accentuated by wasting of surrounding tissues	Pouched swelling of knees	May be swollen more or less symmetrically in large joints; smaller joints tend to be nodular
Movement . .	Much restricted	Much restricted	Not much restricted	May be very restricted in some directions, but free in others
Crepitus . . .	Coarse creaking or absent	Coarse creaking or absent	Fine crepitation	Coarse grating
Muscular wasting .	Marked	Variable	Absent	Marked in late stages only
Skin . . .	Trophic changes	Trophic changes, sweating often marked	Myxœdematous	Senile changes
Pain	May be severe	May be severe	Aching, not severe	May be very severe
Thyroid . . .	Hyperthyroidism common	No constant change	Hypothyroidism	Tending to hypothyroidism
Pulse . .	Rate increased	Rate varies with severity	Not affected	Arteriosclerotic
X-ray	Marked general osteoporosis	Similar, but osteoporosis is often confined to the ends of the bones	No change till late stages, when osteophytes may form	Areas of degeneration and osteophytes
Removal of septic focus	No improvement	Often improvement	No constant improvement	No constant improvement

Pain gradually appears and the joint becomes swollen There is an effusion, not only into the joint, but commonly also into the bursæ which communicate with the joint. After resting for a time, the joint is extremely stiff and painful; this is particularly noticed on rising in the morning. At this stage the joint outline may be more or less spindle-shaped, a feature most readily detectable in the joints of the fingers. The enlargement is roughly symmetrical, and is most apt to affect the metacarpo-phalangeal joints After a variable period, the articular margin may show a greater or less degree of lipping, at first the out-growths are cartilaginous, and may not be apparent on X-ray examination, but a crunching or muffled kind of crepitus can be elicited when the joint is moved. Later, when the central part of the articular cartilage has been eroded, and the bone is exposed, the symptoms become more grave. There is a constant gnawing pain, and the patient feels as if the bones were being ground together, as indeed they are. The peripheral outgrowths have now become ossified, and these osteophytes may actually be palpable Movement of the joint is associated with harsh grating, and there may be unnatural mobility from ligamentous degeneration The whole limb may be short, or other deformities may be present

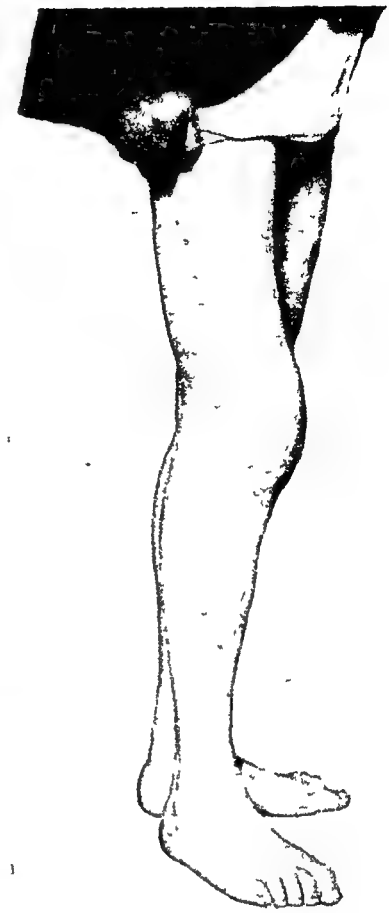

Fig 199 —Osteo-arthritis of the Right Knee.

Osteo-arthritis can be more adequately controlled, and is more amenable to treatment, in its early phases, than rheumatoid arthritis. The influence of trauma is very important and not sufficiently appreciated Injury will serve to determine the onset of arthritis in a joint in individuals who already suffer slightly from generalized arthritis. For example, an injury to the knee or the hip is likely to precipitate a troublesome form of arthritis in the injured joint For this reason joint injuries in arthritic persons assume an unusual importance and should be prevented or efficiently cared for

Diagnosis

The main characteristics of the various varieties of chronic arthritis

Local treatment and acidification of the joint has been advocated by Crow and Waugh but their claims are unconvincing. The rationale of acidification of arthritic joints is based on observations on the pH of synovial fluid in various arthritic conditions; in chronic osteo-arthritis it appeared to be consistently on the alkaline side. Waugh injects

Fig 200 —Osteo-arthritis of the Hand

each week 15 to 20 ml of a solution of lactic acid of a pH of 5 8 together with procaine into and around the joint He followed up 26 of a group of 108 and claims that 50 to 60 per cent of these gained sufficient relief to return to a normal occupation.

Vasodilating drugs such as acetylcholine and priscol are also advocated for injection.

Deep X-ray Treatment. Recently deep X-ray therapy has used in various forms of arthritis, but particularly in osteo-a occurring in middle-aged people who appear to be in good

are well summarized in the Report of the Arthritis Committee of the British Medical Association as in the table on page 448.

Differential Diagnosis

The diagnosis of chronic arthritis is seldom difficult unless pain and swelling are limited to one joint When the onset is acute, gout, rheumatic fever and infective arthritis have first to be considered The diagnosis soon resolves itself by the course of the disease. In those over 50, osteo-arthritis is the probable cause. In younger people it may be impossible for some weeks to distinguish between rheumatoid arthritis, gonococcal arthritis and tuberculosis.

Prognosis

The prognosis in osteo-arthritis is governed by three factors:

(*1*) *The Cause of the Condition.* The correction of recognizable causes, such as flat-foot in osteo-arthritis of the knees, may at an early stage completely arrest the disease Gouty cases, even with thinning of the cartilages, often yield to spa treatment. When associated with arteriosclerosis the disease tends to progress.

(*2*) *The Joint Affected.* Morbus coxæ senilis has a bad prospect, though temporary relief is possible; fixation of the joint, provided a good position is secured, is often the best result obtainable.

(*3*) *The State of the Cartilages.* If parts of these have disappeared, the outlook is not good With merely localized thinning, correct splinting and local treatment may mean at least partial recovery

Treatment

General Treatment.

The general treatment consists essentially of raising the body tone and stimulating the emunctory functions by baths, rubbing and massage. The bowels should be kept open by laxatives, and the kidneys kept active by liberal quantities of water with a low mineral content. There is no object in restricting the diet other than when weight reduction is necessary.

Local Treatment.

The affected joint should be rigidly protected from even the slightest of injuries, and extremes of movement must be prevented, since there is an ever-present danger that one of the peripheral osteophytes or a synovial tag will be broken off into the joint. The joint, however, should not be completely immobilized It is also essential to prevent deformity, as the altered mechanics resulting from deformity throw added strain on related structures, and may even precipitate the development of arthritis in other joints This is particularly important in the hip joint, where a flexion adduction deformity is liable to be followed by painful sacro-iliac strain.

one joint is seriously affected, and there is no general infection, then operation is certainly advisable; on the other hand, when the disease is polyarticular, operation is undertaken only after the infective process has become quiescent The procedures which may be adopted in osteo-arthritis include the following:

1. Excision of the joint.
2. Arthroplasty.
3. Arthrodesis.
4. Osteotomy.
5. Cheilotomy
6. Joint debridement

1. Excision of the Joint. The aim of this operation is to eradicate the disease completely The unhealthy joint surfaces are removed in all cases, but the subsequent procedure depends on the object in view. In the knee it is well to aim at an arthrodesis, but in the other joints and particularly the smaller ones, such as the metacarpo-phalangeal, a pseud-arthrosis may be expected. After excision of the knee, therefore, the bones are fixed together by excision pins, in the elbow, hip, wrist, and the metacarpo-phalangeal joints on the other hand, sufficient bone is removed from each surface of the joint to ensure that the two raw areas will not come together and so become fixed. To make absolutely certain of this, it is advisable—especially in the metacarpo-phalangeal joints—to prevent further apposition of the joint surfaces by some method of traction during the immediate post-operative period.

2. Arthroplasty. Arthroplasty is now being carried out more and more frequently, and no joint in the body can be said to be exempt from the efforts of the enthusiastic surgeon Page holds that in osteo-arthritis the operation is generally undesirable, on the grounds that the new joint may be presumed to undergo the same pathological changes as the original.

3. Arthrodesis. Arthrodesis of a joint consists of the removal of the remnants of the articular cartilage and of the underlying sclerosed bone, with subsequent approximation of the raw ends in good position. The ultimate result, therefore, is an ankylosis. In a good number of cases in which an arthrodesis is attempted bony union does not occur, and then the resultant fibrous ankylosis, with its slight range of painless movement, may be an even better result.

4. Osteotomy. Osteotomy may be required to correct deformity, particularly when the altered mechanical conditions are giving rise to pain It is of particular value in connection with the hip joint

5. Cheilotomy. Cheilotomy consists of the excision of the peripheral osteophytes In many cases these are so prominent that they constitute a bony block which hinders movement In this event their removal, in addition to lessening the pain, may increase the mobility of the joint considerably

6. Joint Debridement of Magnuson. Magnuson believes this

otherwise. It is believed that much of the benefit is derived from the effect of the X-rays on the vegetative nervous system, which plays such an important rôle in any anaphylactic reaction The effect of the X-rays on this system shows two stages In the early stage, there is an exacerbation of symptoms lasting usually about forty-eight hours, but which may last one to two weeks After this uncomfortable period there is the quiescent stage with amelioration of pain,

Fig 201.—Advanced Osteo-arthritis of the Hip Joint.

and improvement in the pain has been noted to last as long as six months after treatment It is the author's experience that in certain of the joints, especially the superficial ones, e.g. the knee, some measure of relief with alleviation of severe symptoms may be expected by X-ray therapy.

Surgical Treatment.

Active surgical measures are necessary in the presence of persistent pain and progressive deformity The decision for or against operation is influenced by the number of joints involved In cases where only

disease progresses they become more and more frequent. Later the most prominent feature is the deformity, at first the result of muscular spasm. The thigh is flexed and adducted, and the resulting shortening causes the patient to limp The deformity has another effect; the sacro-iliac joint is placed at a grave mechanical disadvantage and becomes the seat of a painful, chronic strain As the hip becomes more and more stiff, flexion is progressively limited, and sitting is difficult and uncomfortable With the continued progress of the disease the deformity increases, and stiffness in bad position results In certain cases severe acute exacerbations occur which necessitate confinement to bed

It is not believed that the pain in the osteo-arthritic hip is produced by the movement on each other of the irregular articular surfaces, but is probably from tension in the sensitive articular capsule and in the inflamed synovial membrane Reduction of tension by osteotomy, or of inflammation by an injection of hydrocortisone, usually gives relief from the pain.

Diagnosis

There should be no difficulty in recognizing osteo-arthritis of the hip, from the type of individual, the history of trauma, the characteristic limitation of movement, and the typical radiological appearances.

Prognosis

The disease is a progressive one and little can be done to stay its course Without treatment, ankylosis usually results, often with extreme deformity, and the fixation of the joint is usually followed by relief of symptoms The value of treatment is in placing the joint in a good functional position, even though it be stiff.

Treatment

General Treatment has already been described.

Local Treatment.

If the case is seen in the early stages, when pain is the pronounced feature, *rest and fixation* are the first requirements, not only to alleviate the pain but to prevent progressive flexion and adduction of the limb Therefore while the disease is acute and pain and muscular spasm are present, rest in bed with traction by weight and pulley and fixation are indicated

When the acute stage has passed the patient may benefit greatly by simply using crutches and keeping the weight off the limb by a thickened sole on the shoe on the sound limb. Use within limits, short of irritating the joint, is valuable in maintaining function. If such exercise produces pain which is persistent and lasts for a period after the activity ceases or comes on at night sufficient to interrupt sleep, then it may be assumed that the joint is being used too freely and that additional protection is required. Gentle massage to the

form of arthritis, produced by the wear and tear of life, progresses because of the presence in it of irregularities and roughnesses on the articular surfaces rather than any pathological condition of the synovia. He suggests, therefore, that the spread of the disease may be cut short by removing the roughened surfaces He describes his operation on the knee, although it can be applied to other joints.

The knee joint is approached through a long vertical incision, and the patella displaced outwards All roughened cartilaginous areas are removed with a thin osteotome from the articular surfaces and also adherent synovia and every trace of degenerated hyaline cartilage. This is so thoroughly done that in some parts the underlying bone may be completely uncovered Transverse, though not necessarily longitudinal, ridges are removed The after-treatment consists of traction on the leg of 6 to 8 pounds for one week during which movements are encouraged After ten days the patient is allowed to bear weight on his limb.

Magnuson states that unless the patient is anxious and willing to co-operate in the after-treatment it is better that no operation be done as the result in such circumstances is likely to be unsatisfactory. This note of warning seems to imply some degree of pain in the convalescent stage.

ARTHRITIS IN THE INDIVIDUAL JOINTS

The Hip Joint

The hip joint is frequently the site of osteo-arthritis, and the condition is sometimes spoken of as malum coxæ senilis. It often follows an injury, possibly sustained years before. It is commonest in men past middle age

Pathology

The joint space is diminished, there is irregularity of the two joint surfaces, and lipping at the articular edges The neck of the femur is broad and short, while it appears to have slipped upwards in relation to the head. The head itself is surrounded by a ring of osteophytes and appears to be much broader The acetabular edge is also ringed with osteophytes, and is rough and uneven, so that the acetabular cavity appears to be deeper. In the neighbourhood of the joint the bones show an increased density, and this is particularly noticeable in the weight-bearing areas The sclerosis is not uniform and the X-ray shadow is mottled from the presence of areas of diminished density.

Symptomatology

The usual complaint is of an ache in the hip, particularly in the early morning, and at the same time there is some limitation of movement. These gradually wear off in the course of the day, but as the

is a history of early trouble in the hip region, and the radiological appearance suggests an old trauma to the epiphysis, probably of the nature of a "slipped" epiphysis The femoral head is large and mushroomed, and the femoral neck correspondingly stout and broad.

2 A type in which the spine and the hips become progressively stiff. Here the surgeon is usually called upon to treat a bilateral fibrous ankylosis of the hip joints.

3. The most common type, when the disease is again mono-articular, and the patient is an old man

It is important, from the point of view of treatment, to recognize these clinical types. The first patient, for example, is in good general condition and well able to withstand operative intervention The second group present a special and intricate problem in view of the bilateral ankylosis; they require special consideration. The third type, the old man with unilateral hip disease, must be dealt with on the assumption that he is not able to undergo long and elaborate operations, and on this account many of the usual operative procedures are inadvisable.

The Operations.

1. Drilling of Bone. For cases with much pain Graber-Duvernay has suggested drilling the bone in the neighbourhood of the hip joint with the idea of increasing the circulation within the bone

The operation consists of boring minute channels through the bone to the centre of the head of the femur with the object of profoundly modifying the circulation, relieving pain and arresting the morbid changes responsible for it Re-vascularization is the hope and some benefit may result but it is not usually long continued.

2. Denervation of the Hip. A novel method of treating the pain in osteo-arthritis of the hip is described by Tavernier. The hip joint is supplied with sensation by the three chief nerves of the lower extremity —the obturator, sciatic and femoral The supply from the last is small and of little consequence but it is found that division of the supply from the other two nerves is followed in a large proportion of cases by amelioration and relief of pain The main obturator nerve is divided in the pelvis or its posterior branch in the adductor region, and the supply from the sciatic by an approach through the gluteus maximus.

(*a*) *Obturator branches.* This is carried out just as in the neurectomy done for spastic paralysis (see p 584) The author has usually divided the main nerve to ensure that all the pain fibres are divided. The paralysis of the adductors is useful, too, in correcting the adduction deformity

(*b*) *Sciatic branches.* The posterior branches originate from the sciatic nerve from two sources, on the one hand direct branches, variable and always slender, and on the other hand branches which come from the nerve to the quadratus femoris. This nerve itself is quite large and emerges from the pelvis below the pyramidalis muscle, proceeding

muscles is useful, combined with movements of abduction and extension short of causing pain or muscular spasm, carried out two or three times at each sitting. At the same time faradism and muscle training by non-weight-bearing exercises should be encouraged. Later, to prevent undue trauma to the joint when walking is resumed, a weight-bearing *caliper* splint may be used

When the affection remains painful surgical measures may be indicated If the condition is quiescent and there has not been great damage to the head of the bone, great relief may be obtained by gentle *manipulation* of the joint under general anæsthesia This is particularly so if the condition is an early one with slight changes in the X-ray and the patient complains of inability to perform some particular movement and this limitation can be confirmed on examination. McMurray says that if the pain produced by the movement is of short duration the result of manipulation will be satisfactory, but if the pain disappears only after a considerable time the result will probably be disappointing Under the anæsthetic it is possible to discover whether the adduction and flexion is due to muscular spasm or to actual shortening of the adductor muscles In the latter event tenotomy of the adductor tendons is necessary, followed by traction of the limb in abduction for two weeks and radiant heat, massage and active weight-bearing movements as soon as possible thereafter.

Operative measures on the joint should be undertaken only when severe pain and disability are present

The General Indications

Pain unrelieved by conservative treatment is the predominant indication for operation in osteo-arthritis of the hip *Limitation of movement* seems so much less disturbing to the patient if only one joint is affected though it is a different matter when both are involved in the process and in such a case some form of surgery is usually indicated to prevent complete crippledom The third indication is the mono-articular case where there is *bad flexion-adduction deformity* causing a pelvic tilt and throwing a heavy strain on the lumbar region. In the older patient such a state of affairs will fairly quickly set up a spinal and sacro-iliac arthritis

Contra-indications are mostly those from the general condition and age of the patient This is major surgery and is not a life-saving measure and should only be carried out in collaboration with a physician who perhaps can sum up the whole picture from a possibly less prejudiced viewpoint The cardio-vascular system, the kidneys and the obesity and age of the patient are considered.

The choice of operation will depend to a great extent upon the type, the age, the general condition, and the build of the patient. Clinically, three common types of individuals present themselves for treatment

1. The youthful patient with a unilateral affection. Often there

though the joint is not directly affected by the tubercle bacillus but by its toxin. The clinical picture of this condition was first described by Poncet, of Lyons, in 1897. Poncet treated a suppurating tuberculous hip joint in a young patient who also had pain and swelling of the wrist and interphalangeal joints. Later there was a flare up in the knees and feet which subsided in a few weeks, but was followed by additional attacks of polyarthritis, apparently of the atrophic type. Poncet's reasoning was that since there was no evidence of any other infection in the body, and since the patient had definite tuberculosis of the hip, the likelihood was that all the lesions in the joints were due to the same cause. He was so struck with the relationship between tuberculous disease and many cases of polyarthritis that he is quoted as having stated that in the presence of rheumatism that which one should demonstrate in the very first place is that it is not tuberculous

Poncet described two forms of tuberculous rheumatism: (1) the acute or sub-acute; and (2) the chronic, which included those cases which we would classify as rheumatoid arthritis and osteo-arthritis, and in which the joints usually present no specific evidence of tuberculosis. In such cases there is usually associated visceral tuberculosis, a tuberculous family history, or the presence of a true tuberculous joint in any patient before, associated with, or following a polyarthritis of any type.

Poncet's views, which received wide acceptance in France, have not been confirmed by experimental work, or by the carefully checked clinical findings of workers in this country There seems to be little doubt that a very small percentage of cases of arthritis of a rheumatoid type is of tuberculous origin. These cases occur in patients who have other tuberculous lesions, usually of a quiescent character, and they are in all probability due either to the action of the tubercle toxin on the joints, or, as has been suggested, to the action of an attenuated type of tubercle bacillus. The pathological changes in the joints have in these rare cases been found to be modified tuberculous ones. The whole subject is somewhat confused, but one can say that the condition is far from common, and that it is not possible to distinguish clinically those cases which are of a tuberculous nature

INTRAPELVIC PROTRUSION OF THE ACETABULUM

Intrapelvic protrusion of the acetabulum was originally described by Otto in 1824, and is often known as the "Otto pelvis" Its main characteristic is a bulging of the acetabular floor towards the pelvic basin, so that the socket becomes extremely deep and the head of the femur is deeply embedded in it Otto originally attributed the condition to gout but it is now generally assumed that the deformity is not a specific one but may occur in many and various lesions at the hip joint

rectus is divided at its attachment to the anterior inferior spine and reflected laterally Care is taken to avoid the lateral cutaneous nerve and the motor fibres of the femoral nerve overlying the iliacus muscle. The region of the joint is now visible and access is got by removal of most of the capsule, and part of the anterior rim of the acetabulum, while the sacrifice of the inferior half of the anterior inferior spine improves the access After removal of osteophytes, which may prevent it, the head is dislocated and by means of the special reamers and burrs the acetabulum and the head are shaped. The reaming of the acetabulum is done very completely and, indeed, on its base there may eventually remain only periosteum from the inner aspect of the ilium It is important to enlarge it widely and to have the head very loosely

FIG 203 —Cup Arthroplasty This operation resulted in a movable hip over about 60° of flexion.

fitting A large vitallium cup is inserted and the head replaced and the muscles stitched. Traction is applied with the leg abducted and special care taken to prevent any outward rolling of the leg A plaster shoe with a piece of wood fixed to the heel of it in a transverse direction is useful to prevent rotation. Movement is encouraged within a few days and in four weeks the patient is allowed to sit up It has been found that the opposite surfaces of the joint are covered eventually by a smooth lining of fibro-cartilage or of hyaline cartilage.

It is interesting that in Hungary Zinner *et al.* have been experimenting with a fibrin cup made from blood clot These are of adequate solidity and of adjustable absorption time After the addition of plasticizing substances and heat treatment the cups are stable and may be sterilized in an autoclave The author saw medullary nails of a similar type used in Russia

(*b*) *Removal of the Femoral Neck and Head* Girdlestone has described and shown cases where, in a bilateral ankylosis in a patient of poor

These symptoms may develop gradually or date from an injury. It is likely that the protruding hip is vulnerable to trauma, to prolonged recumbency, and to superimposed infection.

3. *Deformities associated with bilateral arthritis.* Both hips have well marked arthritis. Earlier the patients have complained of unilateral symptoms and in several instances this has ceased to be painful because of osteo-arthritic ankylosis. Later the lumbar spine and even the knees may show signs of osteo-arthritis secondary to the hip condition. It is necessary then to distinguish this condition from a true polyarthritis

The great, or the lesser, trochanter may be made to grate against the side wall of the pelvis when attempts are made to abduct and adduct the limb, while on abdominal palpation a globular swelling projecting into the pelvis may sometimes be felt above Poupart's ligament The protrusion may be palpable on rectal or vaginal examination

The Radiological Appearance. The acetabular deformity is readily recognizable on X-ray examination. In early cases of the non-infective group the floor of the acetabulum is thin and wafer-like and may protrude anything from a few millimetres to five centimetres into the pelvis. The head of the femur is sunk into the socket, and the margins of the acetabulum appear to overhang the femoral neck The articular surfaces are intact though there is often some loss of joint space.

In the infective group the deformity is complicated by the radiological evidence of infective arthritis. Thus the articular cartilages are often eroded, and the bone tissue of the femoral head may be irregularly sclerotic and rarefied. In this group there is often a deposit of new bone on the pelvic surface of the acetabular floor which has the effect of acting as a splint to prevent complete perforation of the acetabulum.

Treatment

In the early stages non-operative treatment in the form of forcible stretching under anæsthesia, or weight traction on an abduction frame will usually suffice to overcome the contractures

In the stage of osteo-arthritis similar treatment may be successful at an early stage with the addition of local heat in the shape of short wave therapy Sometimes a weight-relieving caliper will prevent the ache in the hip in unilateral cases Operation is indicated where the acetabular margin is obstructing hip movements and where palliative measures have been unsuccessful

Acetabuloplasty as recommended by Smith-Petersen is the operation of choice and conversely this condition is the principal indication for acetabuloplasty The operation removes bony contacts, deepens the acetabulum, and removes a large portion of the sensitive joint capsule so increasing the movements and lessening the pain

Gilmour in a recent study suggests that there are two main types:

(1) A primary group whose origin has been the subject of much speculation.

(2) A secondary group resulting from disease of the hip or injury of the acetabular floor.

These can be distinguished on clinical and radiological grounds

(1) *The Primary Protrusion* Gilmour points out that the changes are due to an increased plasticity of the acetabular floor so that it yields to the pressure of the femoral head and that this is due to an acceleration in the rate and an advancement in timing of primary epiphyseal ossification which he terms premature acceleration of primary epiphyseal ossification. Its manifestation in the Y-shaped epiphyses of the innominate bones would convert the normally resistant cartilage of the acetabular socket into young vascular bone—a tissue ill-adapted to resist the stress of the increasing weight of adolescence. He has demonstrated an increase in the rhythm of adolescent development in protrusion cases and has quoted a case where this deformity was present on one side and a slipped femoral epiphysis on the other, indicating that they are both adolescent and show phases of abnormal epiphyseal evolution under certain physiological conditions.

(2) *The Secondary Protrusion* Medial displacement of the acetabular floor may follow gross lesions at the hip Thus fracture, neoplasms, tuberculosis and pyogenic arthritis may be the causal factor While this must be borne in mind in investigating a hip which shows protrusion of the acetabulum, it is certain that such gross and usually obvious lesions play no part in the development of the true Otto pelvis

Clinical Features

Primary Protrusion The deformity according to Gilmour is much commoner in females—in the proportion of 30 to 7 Bilateral and unilateral protrusion are almost equal in numbers For practical purposes three clinical types of deformity may be recognized

1. *Deformities without arthritic changes.* This illustrates the features of an uncomplicated deformity Its recognition is accidental and is due to radiographic examination consequent upon development of pain and stiffness in the hip or because of the occurrence of local trauma, such as falls upon the joint In the early phases therefore the deformity is a painless one and the initial signs arise from the limitation set upon hip movement by the deep insertion of the hip in the acetabulum The signs at this stage are limitation of movement, pelvic tilt from the fixed hip flexion, hyper-lordosis of the lumbar spine from the same cause, stilted gait, and it may be inability to cross the legs or turn the leg inwards

2 *Deformities associated with unilateral arthritis.* This group is characterized by the development of progressive stiffness and pain in the joint with the deeper protrusion, the other still remaining silent.

most commonly affected are the knee, foot and ankle, hip, intervertebral joints, elbow, shoulder and wrist.

Pathology

King has written a very convincing monograph on the pathology and etiology of this condition.

The outstanding feature is the pronounced and rapid destruction of the articular surfaces. The compact bone underlying the cartilage is also destroyed, until eventually the cancellous tissue is laid bare. The bone ends are, therefore, extremely irregular, and owing to the great instability of the joint, liable to become displaced.

The capsule is thickened, and the intra-articular ligaments destroyed. The joint cavity is enlarged, due partly to the destruction of bone, and partly to the recession of the capsule, which gradually acquires more and more peripheral attachments as the articular margins are worn away. Neighbouring joints or bursæ may also become involved and lead to still further deformity. Eventually bones, such as the talus, may come to lie loose in the joint cavity

The joint cavity is lined by a ragged-looking synovial membrane, bearing numerous villous processes and polypoid masses. This membrane may be continued over the bone ends Its structure is fibro-cartilaginous, and the polypoid bodies are also formed of cartilage.

In certain cases there is a remarkable tendency for new bone to be deposited in the form of osteophytes, or of plaques, in the capsule Occasionally a layer of new bone is deposited around the diaphysis for some distance beyond the articulating ends—a condition never met with in osteo-arthritis. Not infrequently bone is also formed in the interfascial planes outside the capsule. To this form of the disease the term "hypertrophic" is applied; when the excessive destruction of bone takes place without any attempt at new bone formation, the condition is described as "atrophic." The atrophic type is said to be more common in France than in England, and to affect particularly the joints of the upper extremity, especially the shoulder and the wrist

Brailsford has produced some suggestive evidence to show that the hypertrophic and atrophic types of the disease are really stages in the same process. He has followed a case by serial radiography, and his findings apparently show that in neuropathy there are three distinct stages·

(i) A stage of *hydroarthrosis*, with distension of the joint by serous effusion

(ii) A stage of *atrophy*—or better, destruction.

(iii) A *hypertrophic stage*, associated with new osseous deposits about the joint

These observations are of some interest in view of King's recent observations on the pathology of the neuropathic joint

Charcot distinguished also between "benign" and "malignant"

The operation is carried out through a Smith-Petersen incision and the anterior half of the roof and the anterior margin of the acetabulum are removed along with the attached segment of capsule which lies in front of the femoral neck. The new margin of the acetabulum now lies to the medial side of the articular border of the head and the plane of the acetabular orifice becomes oblique as in the normal joint. The operation leaves a good functional joint and can be carried out on both sides if necessary The patient is able to be out and about in three weeks

Fig 206.—Asymmetrical protrusion of the Acetabuli.

THE NEUROPATHIC JOINT

(Charcot's Disease of Joints)

This condition, which arises frequently in cases of tabes dorsalis and occasionally in general paralysis of the insane, was long regarded as syphilitic in origin, but is now known to occur in such non-specific conditions as syringomyelia, paraplegia, myelitis, and peripheral nerve lesions A neuropathic ankle was recently described following on division of the sciatic nerve at mid-thigh This case substantiates the theory that the changes are the result of excessive trauma to a joint when there is impairment of the sensory nerve supply This has led to the exclusion of syphilis as an immediately causative influence

The affection occurs in 4–10 per cent of cases of tabes and in about 25 per cent. of cases of syringomyelia It is rare before the age of 40. Mentioned in order of decreasing frequency of involvement, the joints

(2) There was marked cellular activity in many parts, consisting of fibroblastic proliferation, and excessive development of bone and cartilaginous tissue, particularly in relation to pieces of necrotic bone. The bone and cartilage showed a great variety of appearances. In the areas of proliferation, the vessels were well developed, and the completely formed vessel walls suggested neoplastic rather than inflammatory vascular proliferation.

(3) There was no microscopic evidence of syphilis. Old trauma was suggested by the irregular distribution of large numbers of cells containing blood pigment, indicative of hæmorrhage

(4) That the new growth of bone was associated with architectural remodelling was shown by the decalcification of certain areas In some of these, osteoclastic activity was evident, but in others osteoclasts were completely absent, and the mechanism of bone removal in them is apparently by halisteresis

Etiology

The importance of trauma in the production of this condition has been shown by the experimental work of Eloesser. After anæsthetizing a limb by section of the posterior nerve roots typical Charcot's joints were produced only after trauma to the anæsthetic joints. Axhausen and Nageotte have shown that the implantation of a small piece of live bone into such a part as the ear of the rabbit results in a curious reaction of the connective tissue, metaplasia occurring with the formation of bone and cartilage. Leriche produced similar changes in joints by implanting pieces of fresh bone. This results in a remarkable proliferation of the surrounding tissues with thickening of the synovial membrane, formation of polypoidal processes, and osteo-cartilaginous formation in the neighbouring tissues.

These changes, experimentally demonstrated by Leriche, bear a close resemblance to the changes observed by King in neuropathic arthropathy. In both, the mechanism of the process is evidently a reversion of the cells of the capsule—and of the bone—to a primitive mesenchymal state, a rapid proliferation of them, and subsequent redifferentiation as cartilage, bone, and osteoid tissue. King suggests that in Charcot's joints the stimulus inaugurating this process is the presence in the joint of small portions of dying bone These are the result of multiple traumata, only possible in anæsthetic joints

It is interesting to note that King finds a distinct resemblance in neuropathic arthritis to the changes occurring in osteo-arthritis. In the neuropathy the pathology is, of course, more grotesque, but in both there is destruction of articular surfaces and marginal exfoliation after a period of cellular dedifferentiation towards a primitive mesodermal tissue

If, as King suggests, the stimulus to these changes should prove to be the products of dissolution of small segments of dying bone, there is good reason for accepting Brailsford's dictum that the

forms of tabetic arthropathy In his benign cases the disease completely disappeared, or did not proceed to complete disorganization of the joint The malignant group included those in which the bone destruction was advanced, and where absolute disorganization and dislocation of the joint were invariable sequelæ

Pathologists have not yet been able to assign, with any degree of definiteness, the responsibility for maintaining the trophic nutrition of the joints to any one area of the spinal cord. Collier and Pitt have demonstrated a partial atrophy of the right Clarke's columns in the

Fig 207 —Charcot's Disease of the Elbow Joint

lower and mid-dorsal region, along with some changes in the motor-cells of the anterior horn, in a case of Charcot's disease of the left knee.

King has given a complete account of the microscopic anatomy in a typical case He found that while the histological picture varied in different parts of the joint, the following features could be typically observed

(1) In some areas small fragments of dead bone were present, some still attached to the articular surface, others situated in the neighbouring connective tissue The bone around the Haversian canals was necrotic in places; the fibrous tissue was granular and the vessels degenerated

degree of function preserved. Locally some form of splint such as a weight-bearing caliper on the leg or a leather corset for the elbow are used.

In the case of vigorous patients with a life expectancy of several years, operation may be recommended. For the spine, fusion as in tuberculosis is carried out: for the hip, intra-articular and extra-articular arthrodesis. In the knee, resection, with or without bone grafting or arthrodesis, is the method of choice. Such operations are not uniformly successful, but are worth a trial. Soto-Hall recommends

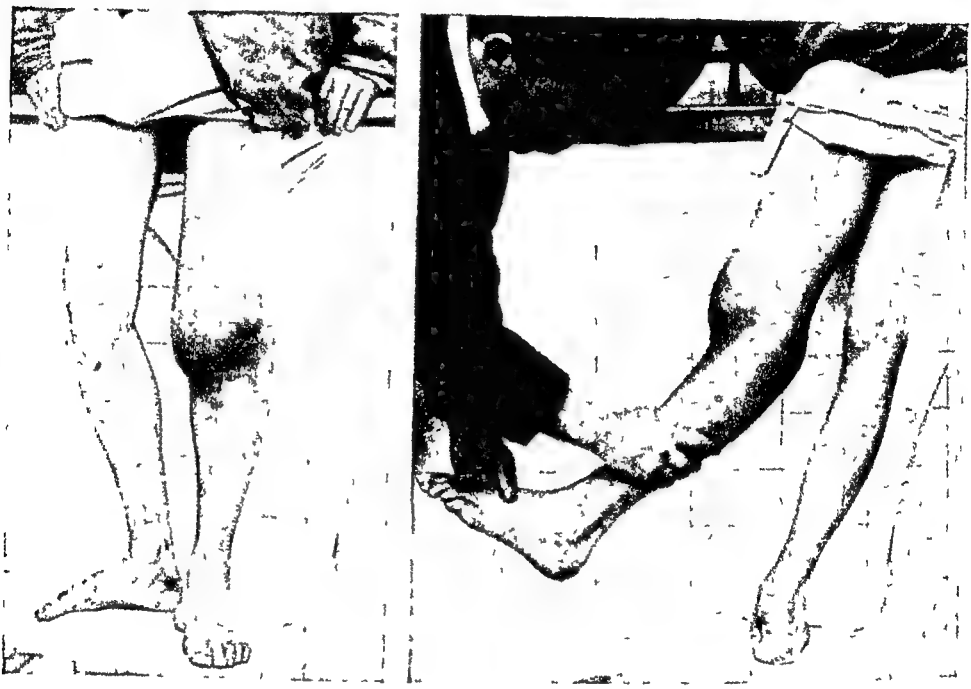

FIG 209—Charcot's Disease of the Knee Joint
The painless and unnatural mobility is being demonstrated

a two-stage operation The first stage is a multiple drilling of the bone ends with a view to influencing their avascular condition—the chief cause of failure of arthrodesis Six weeks later the ordinary arthrodesis is carried out. Good results are reported by the use of compression arthrodesis

When the ankle joint is affected, and especially when the disease is advanced, amputation at the seat of election below the knee should be seriously considered

ALKAPTONURIC ARTHRITIS

Alkaptonuria is a rare inborn error of metabolism in which a defect occurs in the breakdown of the amino-acids phenylalanine and tyroxin Catabolism stops at the stage of homogentisic acid which is excreted

atrophic—i.e. destructive—phase of neuropathic arthritis is only a prelude to the later proliferative stage.

The Clinical Course.

The onset is often sudden and unexpected; premonitory signs are rare. The patient may find on going to bed that one of his joints, usually the knee, has become greatly swollen. The swelling gradually increases, and is eventually associated with a firm diffuse œdema of the leg and foot. The swelling gradually subsides, and the joint is then found to be unduly lax; the bones can be freely moved one upon the other in abnormal directions, and to an unusual extent

Later, deformity arises as a result of the destruction of the bone ends, of subluxation, of a copious effusion into the enlarged cavity, or of the formation of osteophytes Throughout the whole course there is a striking absence of pain. The process may occupy only a few weeks, or months; and by the end of that time the joint is often flail, and the patient completely crippled. The disease then gradually diminishes in seriousness, and may even be completely arrested, so that the subject may live for years without any material change in the disabled joint. Other joints may in the meantime pass through a similar series of changes.

Fig. 208.—Charcot's Disease of the Knee Joint

Not infrequently a diffuse erythematous blush may be found over a neuropathic joint, particularly at the onset of the disease, when the joint is swollen and œdematous

Charcot's joints are more common in females. Though the absence of joint pain is noteworthy, the subject suffers the other evidences of tabes in the shape of lightning pains and sensory phenomena; the Wassermann reaction is usually positive.

Treatment

As soon as the diagnosis is made the joint should be protected so that bone destruction is limited, deformity is prevented, and some

Acute Gout. The first attack is usually sudden and often during the night. There are often a few preliminary symptoms such as dyspepsia, pain in the hands, and the traditional irritability of temper. He is awakened with acute pain, often in the great toe, which increases and is accompanied by throbbing, burning, and a feeling of tension. Mild constitutional symptoms are present with pyrexia to 101° F. or higher. In the morning the toe is swollen, and the whole joint is extremely painful. Usually the acute pain lessens in the day-time but returns with great violence in the night hours. The attacks may last many days or pass away in two days. The great toe joint is tensely swollen, hot, shining, dusky-red, pits on pressure and acutely tender, but suppuration never ensues The ankles, knees, and small joints of the hand and

Fig 210—X-ray of Gout affecting feet (Dr. Whateley Davidson's case)

wrist are affected next, in that order of frequency During the attack there may be a leucocytosis. An attack lasts from two or three days to two or three weeks and is usually followed by improved health, but the intervals between the attacks gradually become shorter The uric acid output, which is low before, is greatly increased for a few days up to 6 mg per 100 c.c Sodium biurate is deposited in the cartilage of the joint and head of the bone, but the swelling and stiffness may eventually disappear completely.

Colchicum is a reliable diagnostic aid since acute gout is the only acute joint disease which responds dramatically to it.

Chronic Gout. After several attacks the joint does not completely recover In chronic gouty arthritis, or stage (iii), the mild and usually constant arthritis symptoms with superimposed acute attacks have all the characteristics of the preceding stage except that joint

in the urine. There it slowly oxidizes, producing the characteristic dark colour.

Almost all alkaptonurics by the time they reach middle life develop ochronosis, a pigmentation of the cartilage and fibrous tissues of the body. Secondary degenerative changes in articular cartilages and intervertebral discs cause a widespread arthritis.

Clinical Features

It is rare for joint symptoms to be noticed before the age of 40. Most cases develop a stiff spine although only half of them have serious pain. Deformity is usually a kyphosis caused by the narrowing of the discs The joints of the shoulder girdle are frequently involved, usually the shoulder but also the sterno-clavicular joint. Knees and hips are affected but the smaller joints rarely so. There is evidence of ochronosis in the small pigmented patches in the whites of the eye. Homogentisic acid is present in the urine.

Radiograms show a characteristic narrowing and calcification of the intervertebral discs The symphysis pubis may be affected, being blurred and sclerosed. In the larger joints the main feature that may distinguish ochronosis from osteoarthritis is peri-articular calcification

GOUT

Gout is a disease in which there is a disturbance of the protein metabolism and an increase of uric acid in the blood It is characterized by recurrent attacks of acute inflammation of the joints with deposition of sodium biurate in and around them.

It is almost confined to men of between 30 and 50 and is often hereditary, the predisposition to it being transmitted mainly through the male line Attacks are more frequent in the changeable weather of spring and autumn. Exciting causes are alcohol, especially port and malt liquors, nitrogenous food in excess, especially sweetbreads, liver and kidneys, and too little exercise and fresh air Trauma plays a part in the production of the acute attack and the common site in the big toe is probably from the trauma of pressure of the boot

Symptoms

The earliest symptom is often a deposition of sodium biurate in the cartilage of the ear This often passes unnoticed but may be accompanied by an intolerable itching or tenderness.

Smyth and Huffman divide the course of gout into—stage (i) asymptomatic hyper-uricemia, stage (ii) acute intermittent gouty arthritis, and stage (iii) chronic gouty arthritis or tophaceous gout. The first stage precedes for some time attacks of acute arthritis and is often found in the relatives of persons with known gout Stage (ii) is acute gout

two or three hours for the first twelve hours and thereafter three or four times a day until the acute symptoms have subsided Heat should be applied to the inflamed joint in the form of a kaolin poultice, and the pressure of the bed clothes avoided by means of a cradle A lacto-vegetarian type of diet is prescribed and purin containing foods reduced to a minimum.

When the acute attack has subsided careful attention is devoted to the patient's general mode of life Uric acid is diminished by means of a low-caloric value, a reduced protein and fat intake, and a low purin intake in his diet In all cases where the gouty tendency is marked all forms of alcohol are forbidden although a little whisky well diluted with water may be taken without harmful results. Where the patient is over-weight this should be reduced

In those cases where the gouty state has become chronic and where the blood uric acid remains persistently high, considerable benefit may be derived from periodic courses of Cincophen prescribed in 7½ gr. doses, thrice daily for a period of three or four days at a time and then stopped for a week The irritating effect of the drug on the stomach is diminished by the simultaneous administration of sodium bicarbonate, 30 gr thrice daily

Benemid (R) has an important place in therapy of gout, preventing attacks and relieving joint pains in patients with tophaceous gout. High fluid intake and alkalinization of urine are advisable during the early stages of treatment Bartels reports on the Benemid (R) maintenance therapy. The serum uric acid level usually falls within 3 to 6 weeks and where the average before treatment was 7 8 mg /100 c c., after it the level was 4·8. The dose required to sustain a normal serum uric acid level was about 1,100 mg per day.

Sufferers from chronic gout derive great benefit from an annual visit to a Spa where general treatment takes the form of vapour hot air and immersion baths, while the Spa waters taken internally have a mild diuretic and laxative effect Local treatment to the joint in the form of mud and peat packs, wax baths and other forms of physiotherapy do much to reduce pain and suffering

manifestations do not subside entirely, response to colchicum is less dramatic, deposits of urate crystals occur, urate stone may develop in the kidney and albuminuria with or without hypertension and premature arteriosclerosis may appear. The joint, therefore, becomes swollen and irregular in shape In the advanced stages the skin over the uratic deposits breaks down and masses of chalky material are extruded and the wounds heal with difficulty. The general health of the patient suffers after several attacks and does not recover completely

Diagnosis

The diagnosis of a case of classical gout with recurring attacks of arthritis in the toe or tarsus is easy, especially if the patient comes of a gouty stock or indulges in much good food and drink The presence of tophi is proof positive that the patient is the subject of gout. The blood should be examined in all cases of doubt and if more than 4 mg per cent. of uric acid are found the case is definitely one of gout, although uric acid in the blood is increased in cases of chronic interstitial nephritis. While it is certain that gout does not occur in the absence of an increase of uric acid in the blood, the presence of an excess of uric acid in the blood does not exclude the presence of other diseases.

The X-ray appearances are striking. The negative shows dark areas where the sodium biurate is deposited in large amounts, and replaces bone or cartilage, since sodium biurate is not opaque like the calcium ion. In the less severe cases there may be lipping at the articular margins, a localized atrophy of bone, or a narrowing of the joint space These latter changes occur in other kinds of arthritis and are in no way characteristic of gouty arthritis

Fig 211 —Gout affecting index finger (Dr. Whateley Davidson's case)

Prognosis

If the patient has once had an attack he will always be liable to have another attack unless he alters his way of living. The frequency and severity of the attacks can be modified by treatment. The prospects of long life depend on the state of the heart, arteries and kidneys.

Treatment

During the acute stage the patient is confined to bed A mixture containing Vin Colchici., Sod Salicyl, and Potass Bicarb. is given every

in each instance we are dealing with an independent disease A list of some of these conditions is.

Primary Centres

Vertebral body (Calvé, 1925)
Carpal scaphoid (Preiser)
Semilunar, adult (Kienbock, 1910)
Patella (Kohler, 1908)
Astragalus (Mouchet, 1928)
Tarsal scaphoid (Kohler, 1908)
Medial cuneiform (Buschke, 1934)

Secondary Centres

Vertebral epiphysis (Scheuermann, 1921)
Sternal end of clavicle (Friedrich, 1924)
Head of humerus (Hass, 1921)
Capitellum of humerus (Pannei, 1927)
Head of radius (Brailsford, 1935)
Ulna, distal (Burns, 1931)
Head of metacarpals (Mauclaire, 1927)
Iliac crest (Buchman, 1925)
Pubic symphysis (Van Neck, 1924)
Ischiopubic junction (Oldberg, 1924)
Head of femur (Legg, 1910)
Trochanter of femur (Monde Felix, 1922)
Patella (Sinding-Larsen, 1921)
Head of tibia (Ritter, 1929)
Tubercle of tibia (Osgood, Schlatter, 1903)
Os calcis (Sever, 1912)
Metatarsals (Freiberg, 1914)

Etiology

The etiology of epiphysitis is a most interesting study Many theories have been put forward to account for it, but so far no clear-cut scientific proof of any one of them exists. The reason for this may be that, since operation is not often indicated in this condition, there have been few opportunities for a comprehensive study of the histology. The only general agreement which exists concerning the etiology of epiphysitis, is that the disease is neither tuberculous, rachitic, nor syphilitic. The theory most favoured at present is that a vascular disturbance, possibly following trauma, causes an avascular necrosis

A Consideration of the Various Theories of Pathogenesis

1. Trauma. It is generally agreed that in most cases a history of preceding injury can be obtained, and some authors consider trauma to be the sole determining etiological factor. Legg describes the sequence of changes as follows

"As a result of injury there is an obliteration of a portion of the vascular supply of the epiphysis, which consequently undergoes the atrophy of anæmia A compensatory hyperæmia of the adjacent portions of the diaphysis is the natural response, and is the starting-point

CHAPTER IX

AFFECTIONS OF THE EPIPHYSES

The epiphysis is the part of a bone concerned with growth in length; in addition, it takes part in the formation of joints and acts as an attachment for muscles and tendons. Parsons describes three types of epiphysis.

1. The pressure epiphysis, which transmits weight from one bone to another
2. The traction epiphysis, situated at the point of attachment of muscles.
3. The atavistic epiphysis, which represents a part of the skeleton that has lost its function.

The epiphysis develops from a secondary centre of ossification and is at first separated from the main bone by an area of unossified cartilage. Later it joins the shaft to make the adult bone. The cartilage lying between the bony tissue of the epiphysis and the diaphysis is known as the epiphyseal cartilage, and it does not ossify nor does the epiphysis become joined to the body of the bone until growth has ceased.

Epiphyseal disturbances may be caused by many factors, of which the chief are circulatory changes, trauma, infection, diet, exercise, and endocrine disturbances.

OSTEOCHONDRITIS, OR EPIPHYSITIS

The term osteochondritis, or epiphysitis, is used to signify a derangement of the normal process of bone growth which is wont to occur at the various ossification centres during the period of their greatest activity. The name osteochondrosis has been applied in the standard nomenclature of disease. No epiphysis in the body is immune to the disease, and there is little doubt that the same underlying pathological process is present, no matter where it occurs, though the particular location modifies its features in certain respects. Cases have been recorded in which almost every epiphysis of the body has been simultaneously the site of this condition, though in each situation there have been essential differences due to the various stresses and strains to which the various epiphyses have been subjected.

Unfortunately in most instances the lesion has come to be known by the name of the original observer. This has the disadvantage of giving no hint as to the pathological process and, further, of implying that

Pathology

The pathological changes in epiphyseal disorders are obscure, because most of these conditions do not warrant operative interference, and few of the cases end fatally Our knowledge is therefore derived from a study of the radiological pathology, and from the examination of tissues obtained experimentally, though the latter often represents a late stage of the lesion. It is to Axhausen that we owe most of our knowledge. He pointed out that it was entirely a subchondral lesion, and that there were roughly four stages in the pathology. There is first a disturbance of nutrition, which is followed by a stage of necrosis; later, under some strain, there is a pathological fracture; and in the last stage of all the necrosed bone is replaced and we get the final condition of a more or less healed fracture

This interpretation has been discounted by many writers, as in some forms of osteochondritis there is a destruction of the epiphyseal cartilage and islands of cartilage are found in the already ossified areas. As the condition advances, hæmorrhage and necrosis, and evidences of trauma become more and more marked.

Undoubtedly these variations can be explained only by the various stages at which the superimposition of trauma occurs

Symptoms

Clinically, there is a marked parallelism in the symptomatology of all the various osteochondritides. The onset is gradual, and there may or may not be a history of injury, commonly slight. As a rule the patient is in good general health, and is practically never acutely ill, although Platt has described cases where the patient was suffering from a mild septicæmia and frequently showed an irregular evening temperature.

The local effects of the disease are somewhat similar to those of early tuberculosis—slight pain, limp in a weight-bearing joint, limitation of movement, and, at times, muscle spasm The term "growing pains" is now held in disrepute, but it is highly probable that congestion of the rapidly growing epiphysis may indeed give rise to such symptoms, so that the term may be re-adopted with some justification.

All these symptoms are mild, indeed, many cases are symptomless, and are discovered only when deformities develop

The affection may be bilateral, or only one side may be affected.

X-ray Appearance. The X-ray appearance is very similar in the various forms of osteochondritis, and is usually out of all proportion to the mildness of the clinical picture.

It has been of the greatest aid in the study of the changing pathological picture in these cases, as by this method it is possible to demonstrate the early evidence of decalcification, the subsequent necrosis, and finally the signs of repair In the earliest stages there are usually small areas of lessened density which increase in extent and intensity under

of these hypertrophic changes which have been noted in the occurrence of broadening."

Bergmann believes that, to explain this group of diseases, an aseptic necrosis, either alone or associated with other pathological conditions, must be assumed. Severe dislocations of the hip joint, and bloodless traumatic epiphyseal separations produced experimentally in rabbits failed to cause epiphyseal necrosis, but after partial section of the synovial membrane, in which the nutrient vessels are carried, more or less extensive areas of necrosis developed in the epiphysis of the head. These lesions were more intense when the ligamentum teres was also severed Bergmann concludes that Perthes' disease is undoubtedly due to an aseptic necrosis, though other factors, congenital or exogenous may play a rôle He thinks a purely traumatic explanation is improbable. Jackson Burrows puts forward the suggestion that although both conditions are due to interference with the blood supply, the changes in aseptic necrosis may be caused by the interference with arterial flow while those of coxa plana may possibly be due to venous obstruction

The supporters of the traumatic theory point to the history of injury, to the greater frequency of the condition in boys, to its more usual location either in weight-bearing joints, such as the hip, or in epiphyses which are subjected to a great strain, as in the tubercle of the tibia. They also instance the case where Perthes' disease developed in a hip the site of a congenital dislocation, which had been reduced the year before, and point out that minor degrees of a similar change are a common radiological finding in old manipulated congenital hips.

The opponents of the theory point to the fact that it is frequently bilateral, and that histological changes of trauma such as are seen in a recent fracture are usually absent They also point to the fact that in many cases the temperature in the early stages is raised.

2. Infection. It has been noticed that the condition often occurs after a general septicæmia, or following some previous infective state In addition, it is notable that the disease may simulate a mild infection. It may, for example, affect more than one epiphysis in the same person, while there is usually a complete resolution, as one sees in mild osteomyelitis Writers on the subject have drawn attention to the frequency with which swelling and tenderness have been observed round the affected area. Kidner and Phemister found staphylococci in some cases, and cases have been described which have followed a mild acute polyarthritis Platt described two cases which passed through a stage of pyrexia, for which no other cause could be found. Phemister had an opportunity to study histologically a portion of the epiphysis removed by curettage of the head of the femur. The tissue gave no microbic growth, but otherwise it was said to be typical of an old infective lesion of bone, probably of pyogenic origin At operation there was evidence of an active synovitis, but the articular surface of the deformed head retained its normal sheen.

when the manifestations are so trivial as to give rise to the belief that recovery has taken place. The stage lasts from about six to eighteen months

Limp. The limp tends to disappear, although it returns for short intervals and may occasionally continue indefinitely. It is a conspicuous feature during the existence of local pain and tenderness, or fixation of the affected joint.

Spasm. The spasm noted during the stage of onset usually disappears quickly, but leaves a residual limitation of mobility The pain and tenderness have usually disappeared before the total abolition of the spasm, and the child may even be limping markedly with a completely fixed and painless hip The usual position of the limb is one of slight flexion combined with adduction, in striking contrast to the abducted position of the early tuberculous hip The attitude, therefore, forms a sign of considerable diagnostic importance in distinguishing between the two lesions.

Mobility of the Hip Joint During the active stage, the affected hip joint invariably shows limitation of abduction, medial rotation, and flexion These movements are diminished, first because of the spasm of the adductor muscles, and, at a later stage, because of the true shortening of these muscles. Still later, the deformation of the femoral head provides actual mechanical conditions which prevent a full degree of movement Perthes noted that abduction was limited even under anæsthesia.

The trochanter on the affected side is much more prominent than normally, and appears to project unduly in the lateral direction. If the trochanter is grasped from before backwards, between the thumb and the fingers, its antero-posterior diameter will be felt to be definitely thickened as compared with the normal side

The *muscles* on the affected side are usually under-developed, but the atrophy is due more to lack of use than to any trophic disturbance such as is so common and constant a feature of the tuberculous hip joint In spite of the considerable deformity of the head of the femur, there is little, if any, shortening

3. The Stage of Recovery. The subjective and objective signs gradually diminish in intensity until, finally, a stage of apparent recovery is reached in which the function of the hip joint is restored so completely that there is little or no difference from the normal Two signs, however, persist through life, viz trochanteric thickening, and limitation of the range of abduction.

X-ray Appearances.

The X-ray appearances are of a very special and interesting type, and usually quite characteristic of the disease.

A. Changes in the Femoral Head. (*i*) *Flattening.* The head at first is slightly reduced in its vertical diameter, but with no appreciable increase in its lateral extent. Later, there is a uniform opacity

observation The epiphysis becomes fissured, fragmented, broadened, and fuzzy in outline, with a ragged appearance Areas of dense necrotic bone are visualized The process may involve both the epiphysis and the metaphysis, and the former may be compressed and flattened. In the stage of regeneration or recovery there is a gradual loss of the osteoporosis with absorption of the dense necrotic bone in the epiphysis This is followed by slowly advancing replacement of the necrotic bone by recalcification, until there is complete bony restitution.

The amount of deformity of the restored bony contour will depend on many factors, including the stage at which it was first recognized and adequate treatment applied The duration of treatment also plays a rôle Some patients refuse to allow the involved part adequate rest after the symptoms have disappeared It should be recognized that there is a definite lag in bony replacement as compared with the disappearance of the symptoms Many patients have a definite sense of well-being at a time when the X-rays still show necrosis and very little evidence of regeneration

OSTEOCHONDRITIS DEFORMANS COXÆ JUVENILIS

Osteochondritis of the hip is also known as Coxa Plana, Quiet Hip Disease, Flat Head, Perthes' Disease, Legg-Calvé-Perthes' Disease, or Pseudo-Coxalgia. It was first described by Legg, of Baltimore.

It is a deforming condition of the femoral head, resulting from a disturbance of growth of the epiphyseal cartilage Atrophy of the epiphysis occurs from absorption of the subchondral bony substance of the femoral head. The condition is essentially a disease of boys, and occurs usually between the ages of 5 and 10 years, but may be any time between 2 and 18. It is bilateral in about 10 per cent. of cases.

Symptomatology and Physical Signs

Platt describes three stages in the symptomatology

1. The Stage of Onset. The most constant early sign is a limp. The limp is usually, but not invariably, accompanied by pain, in fact, the absence of pain in many cases has been commented upon by various reporters Although few observations have been made on the early stages of the disease, pyrexia has been noted by at least two observers, Platt and Sundt Muscular spasm is usually present in the early stages, so that the hip is completely fixed, as it is at the start of a true arthritis.

2. The Active Stage. The stage of onset merges gradually into the stage of activity, without any clear dividing-line. Platt states that the active stage may be said to extend from the time of the appearance of the first subjective or objective phenomena, to the time

Diagnosis

It is not difficult to recognize a fully developed case, especially if radiograms are available. In the early stages, however, there are certain points of similarity to early tuberculosis not yet involving the bone. The distinguishing points between the two are that pseudo coxalgia usually affects males of from 5 to 10 years of age, pain is an inconspicuous feature; extension, and sometimes flexion, are fairly free; and the patient is usually a healthy child otherwise. A von Pirquet tuberculin test is usually negative, but even a positive reaction does not entirely exclude pseudo-coxalgia Tuberculosis may affect either sex, at any age, though often the subject is young; all

Fig. 212 —Osteochondritis of the Capital Epiphysis of the Femur Bilateral disease

the movements of the hip joint are usually limited, the child is obviously unhealthy Frequently other signs of tubercle are present and the von Pirquet test invariably yields a positive result

Prognosis

Pseudo-coxalgia is a self-limiting disease with a strong tendency to spontaneous recovery The immediate good results have in the past tempted surgeons to be unjustifiably optimistic Late results, however, show that the soft head must be preserved from pressure until the softness has gone and healing is well on its way. This softness and plasticity remains for a long period In a résumé of the end-results, Legg showed that the final results could be placed in one

of the bony nucleus, and thereafter signs of irregular calcification appear which denote the commencement of the next phase.

(*ii*) *Flattening plus Fragmentation* There is now apparently some breaking up of the bony nucleus of the epiphysis into a number of pieces with cyst-like spaces between. The pattern is not uniform, and the size and number of these bony islands vary considerably The condensation of lime salts in these fragments produces hyper-calcification of the head as compared with the head on the other side. At the same time the head becomes still more flattened, and, as it expands, it "creeps" out of the acetabulum in the direction of the great trochanter.

(*iii*) *Flattening, with Fusion Changes in the Disorganized Nucleus.* This marks the onset of the healing stage The bony islands coalesce, and the density of the epiphysis diminishes until the shadow becomes not only uniform, but comparable with that of the other side. The head, however, remains flattened

(*iv*) *The Expanded Flattened Head* Even after the disease has healed a deformity of the head still remains, and usually persists throughout life, though possibly in rare cases where there has been no weight-bearing on the joint, the normal contour may be preserved.

B. Changes in the Neck of the Femur. Deformity of the neck can develop very early in the disease even before the head has been deformed The upper part of the neck is expanded and its metaphysial end becomes rounded off At the same time the neck becomes progressively shorter, but it does not usually bend

Platt describes an alteration in calcification which produces an ill-defined spongy zone in the upper part of the neck This occurs at an early stage of the disease, but in the second stage is replaced by a more regular pattern-like arrangement, consisting of areas of condensation.

C. Changes in the Acetabular Cavity. Waldenstrom (1938) of Stockholm described as an early sign an increased distance between the medial pole of the head and the floor of the socket This may reach such a degree that the shadows of the head and the ischial bone no longer overlap but leave a gap between them Whitman found on opening a joint in pseudo-coxalgia that the ligamentum teres was grossly swollen and congested and Korvin believes that it is this congested hyperæmic ligamentum teres that causes Waldenstrom's sign and an excavation of the acetabular roof from its pressure.

D. Changes in the Acetabulum. The acetabular floor is altered, as it adapts itself to the alteration in the shape of the head It does not show the usual contour but is hollowed out abruptly. This excavation occurs later than Waldenstrom's sign but is never seen in the absence of the latter. Korvin says this sign can occasionally be seen in hips with inflammatory lesions such as tubercle Areas of condensation and zones of irregular lime absorption may be seen also, but the appearance is usually ill-defined and difficult both to interpret and to describe.

are better than those untreated. The inference is drawn that the prognosis of Perthes' disease, although good on the whole, is less certainly favourable than has been supposed, but is definitely improved by early treatment by rest with traction, followed by plaster support.

Treatment

A preliminary arthrogram is useful since it will show whether the cartilaginous outline is nearly normal. It is thus of prognostic as well as therapeutic significance.

It is generally agreed that no active measures seem to have been successful in modifying the pathological process. The aim of treatment

Fig 214.—Osteochondritis Deformans Coxæ Juvenilis An early stage in the Right Hip Joint

to-day then is to protect from the pressure of weight-bearing and preserve the normal contour of the femoral head An ambulant method may give the relief from pressure that is so essential

The best method of protection is by traction applied to the limb in order to diminish the inter-articular pressure, and in some cases this traction is continued until healing has occurred In the acute stage he should be confined to bed, with traction applied to the abducted hip. This must be continued until the stage of activity is complete and healing has advanced to a point at which the bone is strong enough to take pressure without being distorted That may mean up to two years of treatment but a sound hip makes it worth while A Thomas's walking caliper is used in the later stages only if there is doubt about the healing success, or a Schynder sling to prevent weight-bearing may

of two categories, and that there were distinct differences between the two types of case.

1 The *mushroom type* does not show marked atrophy or fragmentation of the epiphyseal bone centres. In some cases the epiphysis migrates considerably towards the great trochanter, while in others this displacement is slight. Abduction, and, at times, rotation, is limited when the epiphyses show marked migration, otherwise motion at the hip may be restored to normal in adult life. In this type there is also less shortening

2. The *fragmented type* shows marked variation in X-ray density in the epiphyseal centre and the neck, fragmentation of the epiphyseal bone centre, and shortening and rounding off of the upper end of the neck. Indeed, the epiphyses in some cases seem to be obliterated.

FIG 213 —The effects of Perthes' disease The condition has healed apparently with considerable deformity The child walked with only a very slight limp

The ultimate limitation of movement and the permanent shortening of the leg are generally considerable in this variety.

Schmidt found the end-results were satisfactory in his cases in proportion as the early treatment had been systematic Perfunctory treatment led to poor results Ratliff found that the results in those patients followed into adult life were disappointing He classified his fairly small series as 38 per cent. good; 38 per cent. fair, and 24 per cent poor A high percentage had no pain and good function, but only 40 per cent had a good hip radiologically, while there was evidence of arthritis in 51 per cent The end results of those adequately treated

are better than those untreated The inference is drawn that the prognosis of Perthes' disease, although good on the whole, is less certainly favourable than has been supposed, but is definitely improved by early treatment by rest with traction, followed by plaster support.

Treatment

A preliminary arthrogram is useful since it will show whether the cartilaginous outline is nearly normal. It is thus of prognostic as well as therapeutic significance

It is generally agreed that no active measures seem to have been successful in modifying the pathological process The aim of treatment

Fig 214—Osteochondritis Deformans Coxæ Juvenilis An early stage in the Right Hip Joint

to-day then is to protect from the pressure of weight-bearing and preserve the normal contour of the femoral head An ambulant method may give the relief from pressure that is so essential

The best method of protection is by traction applied to the limb in order to diminish the inter-articular pressure, and in some cases this traction is continued until healing has occurred In the acute stage he should be confined to bed, with traction applied to the abducted hip This must be continued until the stage of activity is complete and healing has advanced to a point at which the bone is strong enough to take pressure without being distorted That may mean up to two years of treatment but a sound hip makes it worth while A Thomas's walking caliper is used in the later stages only if there is doubt about the healing success, or a Schynder sling to prevent weight-bearing may

be sufficient to limit long periods of hospital treatment, which has not been proved to give any better results.

In some cases it is a sound practice to immobilize the hip joint for a short period. In particular, marked spasm, considerable limitation of abduction, or some degree of pain, are very definite indications for immobilization treatment Any adduction deformity should be carefully corrected, either by gentle stretching under an anæsthetic, or by the method described in the treatment of an early case of tuberculous arthritis

Operative Treatment.

Drilling is now being considered in an attempt to improve the vascularization of the head Some enthusiasts suggest scraping out the bone in the head and filling it with cancellous chips of bone

Fig 215 —Typical unilateral Perthes' Disease

Stabilizing operations in the later stages when arthritis has developed are usually needed.

Complications Apart from the general complications of prolonged decubitas there are local complications occurring at a later date

(1) Osteoarthritis due, of course, to some measure of incongruity of surfaces,

(2) Failure of growth of the femoral neck, possibly from premature fusion of the epiphysis in whole or in part, and

(3) Osteochondritis dissecans.

OSGOOD-SCHLATTER DISEASE

In 1903, Osgood reported ten cases of epiphysitis of the upper end of the tibia in boys. Several months later, Schlatter described a similar condition. At first it was thought to be simply a traumatic separation, combined sometimes with an actual fracture of the epiphysis. This, of course, does sometimes occur, but the true Osgood-Schlatter disease shows, in addition, characteristic bony changes which stamp it as a definite disease entity

Fig 216 —Osteochondritis of the anterior part of the Upper Tibial Epiphysis—known also as Osgood-Schlatter's disease

The tibia is developed from four centres—one for the shaft, one for the lower epiphysis, and two for the upper epiphysis The tuberosity usually arises as a tongue-like protrusion from the lower end of the upper epiphysis, but it may have two centres of ossification, one extending down from the epiphysis, and one reaching up from the shaft. While the centre of ossification for the head appears first, it unites with the shaft last There may be earlier points of union in the tuberosity which more easily permit circulation in the fragments.

Partial separation of the tuberosity from trauma, such as violent contraction of the quadriceps muscle, occurs mostly in males between the ages of 16 and 18. There is immediate pain over the affected site, aggravated by any attempt to straighten the knee; the tuberosity is tender and swollen; and radiograms show the detachment of the tongue-like epiphysis

True Osgood-Schlatter disease occurs at an earlier age, usually from 13 to 15, in most cases injury is to some extent an exciting factor, but it does not play the prominent part that it does in the traumatic separation.

The onset of pain and local tenderness is insidious. The patient first complains of some aching in front of the knee after any exercise, or after a long walk. In many cases such over-exertion is the only history of trauma obtained. The pain is increased by full voluntary

be sufficient to limit long periods of hospital treatment, which has not been proved to give any better results

In some cases it is a sound practice to immobilize the hip joint for a short period In particular, marked spasm, considerable limitation of abduction, or some degree of pain, are very definite indications for immobilization treatment Any adduction deformity should be carefully corrected, either by gentle stretching under an anæsthetic, or by the method described in the treatment of an early case of tuberculous arthritis

Operative Treatment.

Drilling is now being considered in an attempt to improve the vascularization of the head Some enthusiasts suggest scraping out the bone in the head and filling it with cancellous chips of bone

FIG 215 —Typical unilateral Perthes' Disease.

Stabilizing operations in the later stages when arthritis has developed are usually needed

Complications Apart from the general complications of prolonged decubitas there are local complications occurring at a later date

(1) Osteoarthritis due, of course, to some measure of incongruity of surfaces;

(2) Failure of growth of the femoral neck, possibly from premature fusion of the epiphysis in whole or in part, and

(3) Osteochondritis dissecans

pain and disability, or return after conservative treatment, and when the child is old enough to justify such a procedure, the patient should be treated by operation. He splits the tendon of the patella and by means of a thin osteotome opens the tubercle by reflecting the cortical bone on each side of a central incision. With a sharp curette fragments and débris are removed from within the tubercle The tendon with cortex and periosteum attached is then allowed to fall back into place and impacted to minimize bulging. Thomson treated forty-one cases in this way. They were from 10 years of age upwards and results were uniformly successful

OSTEOCHONDRITIS OF THE UPPER END OF THE TIBIA

Ritter reported the case of a girl, 7 years of age, who before the age of 4 years was extremely bow-legged. By the age of 4, one leg had become normal in appearance, whereas the other remained extremely bowed Radiograms showed a peculiar condition of the medial half of the upper tibial epiphysis, which, according to Ritter, was similar to the appearance in osteochondritis of the hip joint.

OSTEOCHONDRITIS OF THE LOWER END OF THE TIBIA AND FIBULA

In 1922, Sterne demonstrated a case of osteochondritis of the lower end of the tibia and fibula, while six years later Ritter reported a similar condition in the lower end of the tibia.

KOHLER'S DISEASE OF THE TARSAL NAVICULAR

Unfortunately, two quite different conditions have been named Kohler's disease, one affecting the navicular of the foot, and the other the head of the second metatarsal.

Kohler's disease of the navicular occurs usually in young children, especially between the ages of 3 and 6. It affects boys more commonly than girls

The navicular is the last bone of the foot to ossify, and, as it forms the keystone of the long arch, it must be subjected to a very considerable strain while yet in the cartilaginous state.

The disease is distinctly analogous to the condition known as Kienbock's disease, which will be described later. It is probably an osteochondritis, but its cause has not been definitely established.

The clinical manifestations are often very slight, and consist of pain and swelling in the region of the tarsal navicular. The pain is exaggerated by weight-bearing, and the affected region is sensitive to movement and tender on pressure There may, or may not, be reddish discoloration in addition to swelling The patient limps, and usually

extension of the joint, since the affected epiphysis is then pulled on by the contracted quadriceps muscle. There is also pain on passive complete flexion, as the epiphysis is then dragged on by the stretched quadriceps The epiphysis itself is tender, and in many cases there is some localized œdema

The radiographic appearance is characteristic. The texture of the bone nucleus of the epiphysis is altered; it is irregular in contour, or even fragmented. There may be localized haziness in the adjacent tibial metaphysis

Occasionally a similar condition may affect the lower pole of the patella and this may occur together with the Osgood-Schlatter condition described. The patellar epiphysitis is sometimes referred to as a "reversed Osgood-Schlatter" and was first described in 1921 by Larsen He presumed an accessory ossifying centre here

Diagnosis

Osgood-Schlatter disease has to be differentiated from osteomyelitis, sarcoma of the head of the tibia, bone cysts, and infra-patellar bursitis.

The first three occasion little difficulty, but an infra-patellar bursitis may be difficult to distinguish unless fluctuation is present. Aspiration of the bursal fluid usually indicates the source of the trouble.

Treatment

The condition is treated very much like an epiphyseal separation. First, a plaster case is applied, followed later by a Jones's knee cage with a stop joint to prevent undue flexion, last of all physiotherapy is employed In contradistinction to the treatment of fractured patella, weight-bearing is permitted from the start, but if there is great tenderness, rest in bed, or the use of crutches, may be insisted on Flexion of the knee joint is not allowed for at least five weeks, and violent exercises are prohibited for about four months

Complete restitution of the tuberosity to normal is usual. The condition, however, is apt to recur, and the cure is never really complete until the epiphysis joins up with the tibia

Stirling has described two interesting late complications of the condition The epiphysis may be pulled upwards, indicating some separation The consequence of this may be that the proximally displaced patella from its more irregular contact with the lower end of the femur is apt to develop osteoarthritis This is diagnosed by taking lateral radiograms of both knees with the quadriceps muscle fully contracted If there is displacement it may be advisable to correct this by operation The second complication is that the abnormal epiphysis of the tubercle may cause an early fusion of the anterior part of the upper tibial epiphysis With continuing growth of the posterior part a genu recurvatum is a possibility

Thomson believes that when the patient has repeated attacks of

the medial half of the heel prolonged forwards towards the sole, and sponge rubber pads inserted to relieve the strain on the longitudinal arch, and especially on the navicular.

It is advisable to investigate any possible focus of infection, especially the tonsils. If such a source is found, it should be eliminated. Later, flat-foot exercises, gentle massage, and contrast baths are prescribed.

EPIPHYSITIS OF THE CALCANEUS

The posterior part of the calcaneus has a separate secondary centre of ossification, which fits on the back of the main portion of the

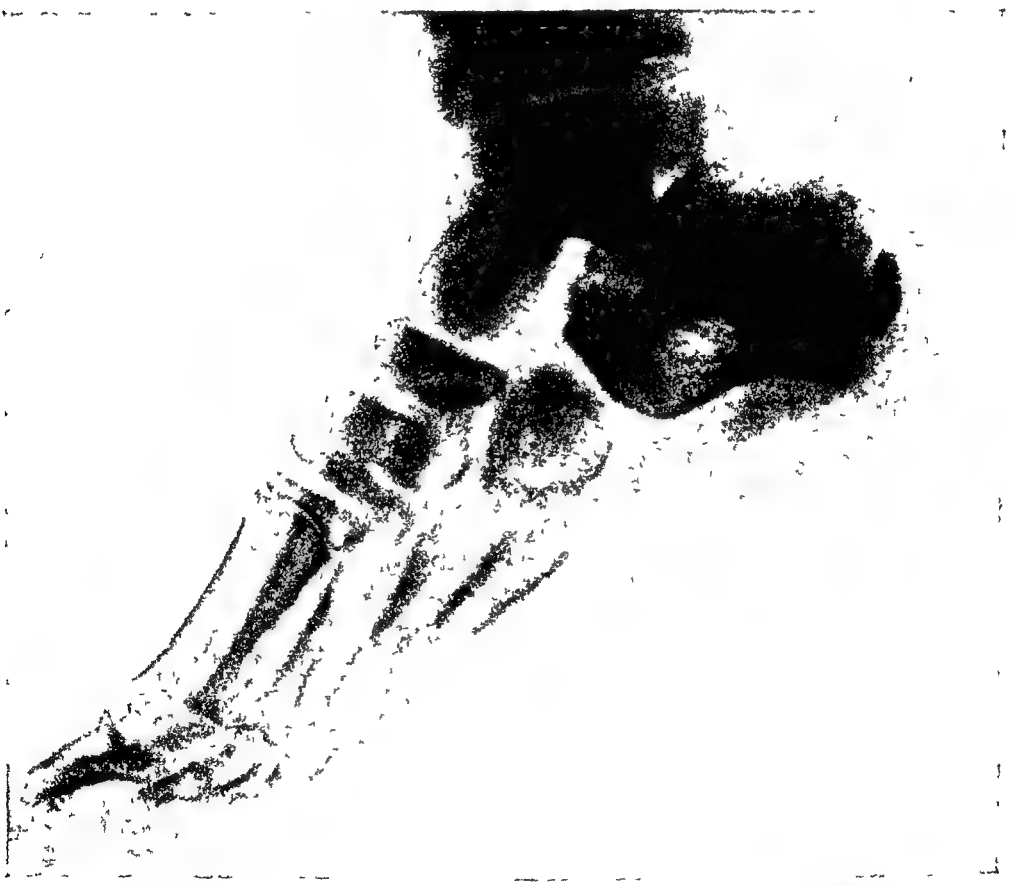

FIG. 218.—Osteochondritis of the Epiphysis of the Calcaneus.

bone like a cap It appears at the age of 8 and fuses with the parent bone about the age of 14. A pathological process affecting this epiphysis was first described by Sever, and various writers in recent years have since drawn attention to it

There is frequently a history of antecedent injury, which is often slight in nature and may even consist of nothing more than running about on hard roads in soft shoes

The onset is gradual and insidious The first symptom is usually

walks and bears weight on the lateral border of the foot, to relieve the affected side.

The condition is usually detected from the physical examination in conjunction with the history, and is confirmed by the radiograms which reveal definite changes in the bone These changes consist of a narrowing of the bone in its antero-posterior diameter, along with a condensation of the bony structure so that, from the lateral view, the navicular may look like a sixpence seen on edge There is no

Fig 217.—Osteochondritis of the Tarsal Navicular—known also as Kohler's disease.

fragmentation of the bony nucleus. The joint spaces remain clear, and the neighbouring tarsal and metatarsal bones are normal in appearance.

Treatment

The treatment of this condition is comparatively simple, symptomatic recovery usually occurring in a few months A plaster case should be applied to hold the foot in a slight varus position, and weight-bearing prevented by the use of crutches After a few weeks the plaster is removed and adhesive strapping used to support the ankle and the mid-tarsal region. The boot is fitted with a Thomas's heel, i e. with

COXA VARA

In the adult femur the neck is set on the shaft at an angle which varies from 120 degrees to 140 degrees A decrease in this normal neck-shaft angle is known as coxa vara, while if the angle is over 140 degrees, coxa valga is said to be present

Coxa vara consists, therefore, of a depression of the neck, and is a feature of many different conditions, although at one time it was thought to be due invariably to active softening and bending of the bone. The depression of the neck results in certain obvious mechanical disadvantages. The normal apposition between the joint surfaces is lost, since the head of the femur no longer accurately fits the acetabulum. The trochanter is displaced upwards, and hence, during abduction, is liable to impinge on the side of the pelvis. The marked shortening of the limb leads to a waddling gait, not unlike that of a congenital dislocation of the hip As coxa vara is a symptom of many diseases, it is usually classified according to the condition which causes it The following classification is substantially that of Key.



Fig 219—Coxa Vara from old Perthes' Disease

A. Congenital Coxa Vara.

Coxa vara may be a primary congenital deformity, occurring alone, or in association with other congenital defects, especially defective growth of the femur. It may also be a secondary congenital error, when it is associated with some intra-uterine affection of bone, such as achondroplasia

Congenital coxa vara, also described sometimes as cervical or infantile coxa vara, is characterized, according to Fairbank, by the presence in a radiogram of a triangular piece of the neck adjacent to the head being separate from the rest of the bone. The condition is often bilateral and often symptoms are evident as soon as the child walks, but they may be delayed for some years.

The patient is usually small in stature and limps, and, in bilateral cases, rather resembles a congenital dislocation Often there is pain and stiffness. On examination the great trochanter is on a level higher than the normal with consequent shortening of the limb Rotation and abduction are limited, while there may be a flexion contracture present.

Zadek reports the histological findings in four of his own cases. These all show abnormality of bone trabeculation with alteration of pattern and direction as well as abnormal islands of disintegrating cartilage cells but he adds "The histology was not sufficiently characteristic to permit a definite diagnosis as to the cause of the bone change."

a limp which may, or may not, be accompanied by pain situated over the affected epiphysis. The pain is aggravated by wearing shoes with no heels, as this considerably increases the traction exerted on the epiphysis by the calf muscles It is also increased by the pressure of the shoe, and, as swelling is usually present, the discomfort is considerable if the patient wears his usual size of shoe. Tenderness can usually be elicited over the insertion of the tendo-calcaneus, and the patient shows a marked disinclination to make a full step as this entails dorsiflexion, and consequent stretching of the tendon.

X-ray Appearances. A lateral view, and an antero-posterior one, with the foot in full dorsiflexion, should be taken Marked irregularity of the epiphysis and diffuse thickening can be seen. The epiphyseal line is cloudy and partially obliterated, while the epiphysis itself is not uncommonly fragmented.

Diagnosis

In the differential diagnosis the following conditions have to be considered: calcanean bursitis; tuberculous and pyogenic infection of the calcaneus; and teno-synovitis of the tendo-calcaneus

Prognosis

The duration of the acute condition is short, varying from a few weeks to a few months. Under appropriate treatment, the prognosis is excellent, but recurrences are possible until the parent bone and the epiphysis are solidly united.

Treatment

The objects of treatment are to relieve the strain on the tendo-calcaneus and to prevent weight-bearing on the calcaneus. In cases of unusual severity it is sometimes necessary to apply a plaster case to the affected leg from the toes to just above the knee, to hold the foot in a slight equinus position and relax the pull on the tendo-calcaneus. The plaster should remain on for about three weeks, and at the end of that time adhesive strapping should be applied round the epiphysis

After the plaster is removed, physiotherapy, in particular massage, radiant heat, and diathermy, are beneficial in relieving the acute symptoms. A sponge rubber heel should be worn inside the shoe, and ordinary rubber heels fitted and used during the period of convalescence. Full weight-bearing is allowed at the end of two months from the start of treatment

Vertebral Epiphysitis or osteochondritis juvenilis dorsi has also been described. For a full discussion of this disease, the reader is referred to the section on deformities of the spine.

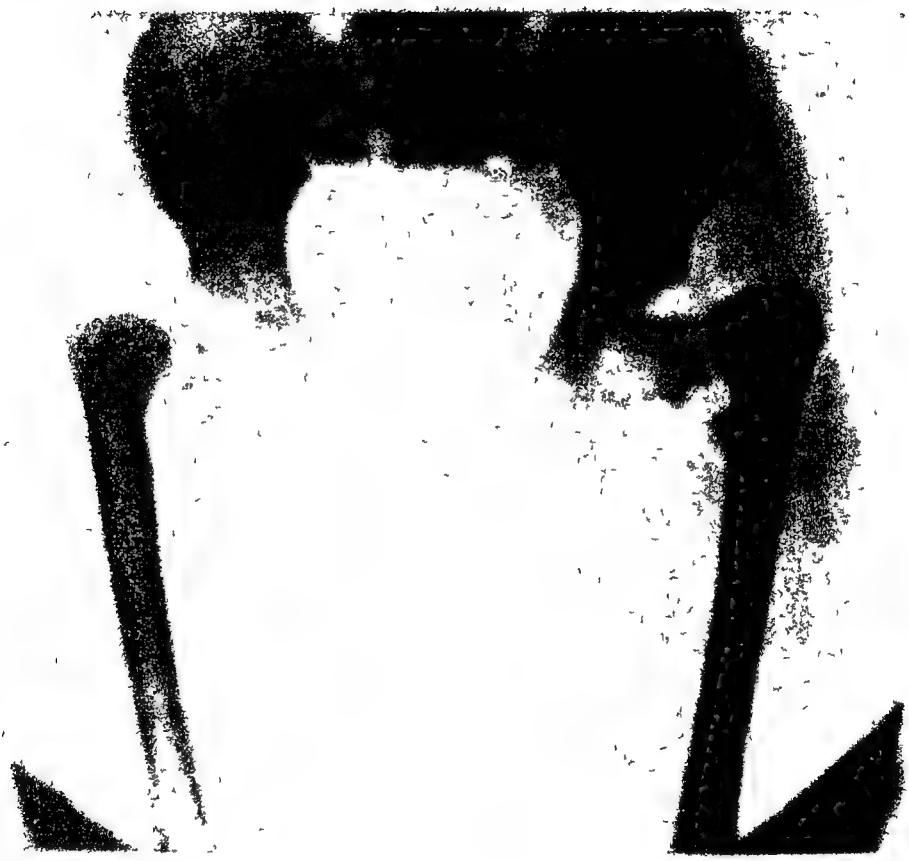

A typical case shows interesting radiographic features which are tabulated as follows although all may not be present in one case.

(1) The angle of the neck is reduced to something below a right angle.

(2) The neck varies in length but is short and may even be non-existent, and may be fragmented through incomplete ossification. Often the neck shows a prolonged lower extremity which forms a down-hanging lip.

(3) The head is unusually translucent, situated low in the acetabulum, and may be fluffy in outline.

(4) There is a fragment of bone, triangular in shape, occupying the lower part of the neck close to the head. This is bounded by two clear bands traversing the neck and forming an inverted "V." The inner band is the epiphyseal line, while the other is part of the epiphysis as the two lines usually disappear at the same time

(5) There is some deformity of the acetabulum due to the malposition of the head.

(6) In extreme cases the great trochanter curves inwards, is beaked, and may articulate with the ilium above the acetabulum.

Treatment. The only method that offers any real hope is, according to Fairbank, an osteotomy. This should preferably be carried out between the ages of 6 and 8. In choosing the position afterwards the deformity is corrected to an extreme degree so that a coxa valga is produced. The bone division is carried out a considerable distance below the trochanters. It has to be remembered that the upper fragment is mobile and is liable to flex. The osteotomy is done obliquely from above and outside, downwards and inwards, so providing a sharp end to the lower fragment to impact into the cancellous tissue of the upper.

B. Acquired Coxa Vara.

This group is classified on an anatomical basis, according to whether the primary error is situated in the head of the femur, the epiphysis, the neck, or the trochanteric region The following table indicates the respective causes of each type:

(*i*) *Capital Coxa Vara.*
- (*a*) Perthes' Disease.
- (*b*) Destructive Arthritis (pyogenic, tuberculous, Charcot, etc.).

(*ii*) *Epiphyseal Coxa Vara.*
- (*a*) Idiopathic
- (*b*) Traumatic.

(*iii*) *Cervical Coxa Vara.*
- (*a*) Developmental or constitutional disease—(rickets, osteitis deformans, etc.).
- (*b*) Destructive disease—(tuberculosis, osteomyelitis, etc.).
- (*c*) Fracture with mal-union.

that this spur provides a natural ledge on which the epiphysis rests. Occasionally the spur ossifies from a separate secondary centre which may remain isolated from the rest of the metaphysis by a strip of cartilage till puberty. This increase in the amount of cartilage weakens the neck in proportion to the body-weight, while the inadequacy of

FIG 221 —Congenital Coxa Vara A late case Note the inward curve of the great trochanter

the spur, increased occasionally by fragmentation of its centre, allows the epiphysis to slide gradually downwards.

SYMPTOMATOLOGY

Epiphyseal coxa vara may be idiopathic (non-traumatic), or traumatic.

Pathology

The only abnormality in the early stages is in the epiphyseal cartilage. This is immature and forms fibrous tissue instead of bone. This abnormality appears to be the primary factor in the histological picture and it proceeds toward the fragmentation and disappearance of the epiphyseal plate

Etiology

The deformity results from a weakening of the union between the epiphysis and the femoral neck and the effect of the normal shearing strain at this site.

1. Hormonal Theory. Although the softening is due to a failure of maturation of cartilage into bone the reason for this failure remains obscure The analysis of the evidence seems to suggest that it is the result of a hormone imbalance. "Ecchondial ossification is largely dependent upon the function of the sex glands and hypophysis for many cases point to a disorder of these glands" (Scott, 1937). The hormones principally concerned with normal development are those of the pituitary, thyroid and the sex glands An excess of the one or a decrease of the other might account for the decreased shearing strength of the body's epiphyses

2. The Traumatic Theory. Many writers consider the condition to be a purely traumatic separation of a normal femoral epiphysis. The epiphyseal line is said to be the weakest part of the normal adolescent bone

There is no doubt that trauma and static influences are both important factors in the development of epiphyseal coxa vara, but it is probable that they must act upon a femur in which the epiphysis is less firmly attached than normally. The pathological conditions which cause the loosening of the epiphysis are not definitely known, but Key points out that they may be neither in the bone nor in the epiphyseal cartilage, but in the periosteum of the femoral neck. In childhood this periosteum is thick, and thrown into folds or ridges known as the retinacula of Weitbrecht, actually it is the chief factor in holding the head in place. In adolescence this periosteum begins to atrophy, and to approach the adult type, thus tending to produce a point of weakness at the epiphyseal line He also points out that most cases of coxa vara give a history of very rapid growth previous to the epiphyseal displacement, and he thinks that during this period the periosteum crossing the epiphyseal line is stretched and thinned, and consequently weakened, thus permitting the epiphysis to be easily separated.

Fairbank describes a form to which he gives the name *infantile coxa vara* He points out that the epiphysis is set obliquely on the neck and faces upwards and medially. This setting, somewhat insecure as a means of supporting the body-weight, is strengthened by a spur projecting from the lower half of the metaphysis Walmsley has shown

the pain is so severe that it prevents the patient from being able to walk.

Physical Signs

During its early stages, the condition is associated with considerable pain, but by the time the patient is seen, the disease is usually

Fig 223 —(*a*) Idiopathic Coxa Vara—early stage 4 1 48.
Complaining of a little pain but walking The normal angle between the head and the neck has disappeared on the left side but reported as "no abnormality"

Fig 223 —(*b*) Same case admitted 29 3 48.
Showing the condition the day after a slight trauma but pain more severe and unable to walk

(*a*) **The Idiopathic Type.** Many children with this condition are over-weight and some have a typical adreno-genital syndrome. There is seldom any history of preceding illness or constitutional disturbance. The onset is gradual, and in many cases the earliest symptom is that the patient gets easily tired after walking or standing. He may then complain of pain, which may be confined to the hip, but usually radiates down to the lower thigh and knee. There may be slight limitation of abduction. These symptoms are evanescent and disappear for a time, only to reappear with increased severity. In the early stages the pain is relieved by rest, and the patient is not troubled at night.

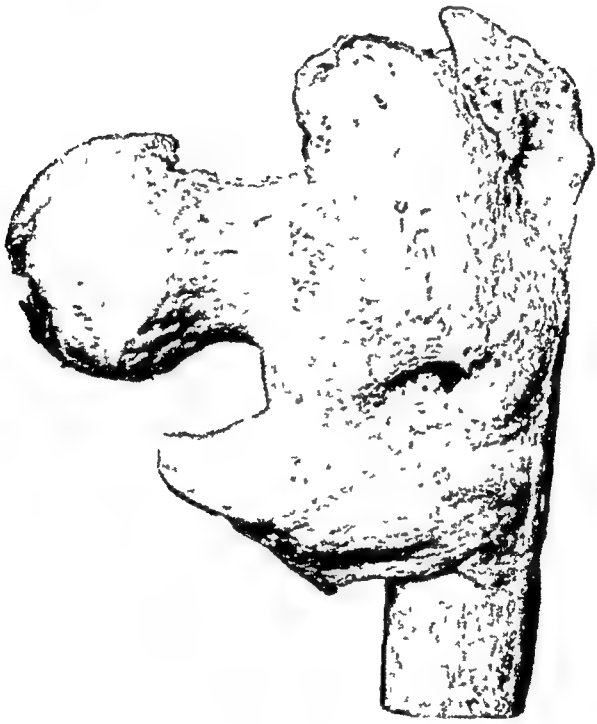

FIG. 222.—Coxa Vara following fracture of the base of the Neck and implicating the Trochanter.

The pain is accompanied by a limp, and, as the error progresses, the limp may be present even when the pain is absent. The affected leg gradually becomes shorter and smaller than its neighbour, and tends to turn laterally, while its movements are restricted.

(*b*) **The Traumatic Type.** In this type the patient has usually had a fall, or received a blow on the hip, some time before In many cases, however, the trauma is very trivial, and not infrequently the history is elicited that the patient had some disturbance in the affected hip even before the injury. It is unlikely that trauma can displace a normal epiphysis. Following on the trauma, there is usually a dull ache, associated with a little disability in the hip, although occasionally

MEDICAL CO

of the neck is buried in the concave cervical surface of the epiphysis, and appears to be shortened. In the angle between the lower border of the neck and the under-hanging head, new bone is formed.

(3) *Advanced Type.* The femoral head is atrophic, especially in its projecting lower half, and it has now become so rotated and displaced that only a small anterior portion is actually in the acetabulum. The articular surface is thus directed medially, backwards, and downwards. The projecting lower edge of the head is now curved laterally and upwards, and in contact with the lower border of the neck. The neck is thick and short, and its lower border sharply bowed

Fig 224 —Coxa Vara

This is the cervical or congenital type

upwards The neck-shaft angle appears to be decreased to about 90 degrees The joint space is clear and there is usually no evidence of arthritis

In cases where trauma has been severe, the head is often completely separated from the neck, and lies loose in the acetabulum. Except for this displacement, the contour of the bones is normal, but the joint margins and the joint space may be hazy from the extravasation of blood

Diagnosis

Harris has drawn attention to the importance of early diagnosis and has described a characteristic symptom-complex—a limp of spontaneous onset and pain referred to the knee in an obese adolescent.

Diagnosis is further suggested by the adducted, laterally rotated

well developed, and the painful acute stage is passed. He walks with a waddling gait, the body swaying over to the affected side. The pelvis on the sound side tends to drop when weight is borne on the affected extremity.

The patient stands with the leg rotated laterally and slightly adducted, while inspection shows the pelvis to be tilted down on the affected side A slight scoliosis towards the affected side is present in the lumbar region, and towards the sound side in the thoracic The buttock is atrophied, and the gluteal fold lower than on the normal side.

On palpation of the groin, a hard mass can often be felt, which moves with the femur, it is the thickened head and neck.

Measurement shows the trochanter to be higher than on the sound side, the tip being usually situated about ½ inch above Nelaton's line.

Movement on the affected side is limited. With the patient recumbent on his back, the position of the leg is one of lateral rotation and slight adduction Flexion is limited to about 80 degrees or 90 degrees and, as the thigh is flexed, it rotates laterally. Adduction and lateral rotation are free, but abduction, medial rotation and hyper-extension are greatly restricted.

In a recent complete separation, the signs resemble those of recent fracture of the neck of the femur, and it may be possible to elicit a soft muffled crepitus

X-ray Appearance.

The condition is progressive and the X-ray appearance varies with the stage. Both hips should be X-rayed in such a way that they are shown in exactly comparable positions in both antero-posterior and lateral views on the same film

(1) *The Pre-slipping Stage.* In early cases the X-ray shows: (1) A minimal slipping indicated by the absence of the normal "shoulder" on the upper aspect of the neck and head, (2) the head is more or less sickle-shaped instead of hemispherical, its height is diminished; (3) the epiphyseal plate is thickened, rarefaction or even streaks of sclerosis may be seen underneath it, and (4) the lateral view shows the slightest downward displacement better than in the antero-posterior view. Those features should be sought for in children suffering from discomfort or pain in the hip joint Their recognition demands measures to prevent slipping

(2) *Early Stage.* The head of the femur lies in the acetabulum but is rotated so that its lower and posterior borders are displaced downwards and laterally. The head is slightly displaced in relation to the neck, its lower border projecting as a beak-like process below the lower margin of the neck The upper margin of the head is thinned out and separated by a short distance from the prominence made by the upper angle of the metaphysis. The femoral neck bears its normal relation to the shaft, but its upper border is lengthened and roughly convex upwards, while its lower border is shortened and also appears to be more sharply curved upwards than normally. The lower border

major displacement gently examined under an anæsthetic and with X-rays to determine mobility of the epiphysis as soon as possible. A major fixed deformity is a problem to be considered and often not easily solved

For purposes of treatment, epiphyseal coxa vara may be grouped into four common clinical types:

1 The early case with minimal displacement.
2 The early displaced case
3. Healed cases in young adults
4. Older cases with arthritis.

1. The Early Case with Minimal Slip. Such cases unless immobilized and fixed are apt to continue slipping and pass into the second category Wilson's criterion of the degree of displacement which could safely be accepted as compatible with normal subsequent function except for slight limitation of internal rotation was that clinically there should be free abduction and not more than 10 degrees of fixed external rotation, that the antero-posterior X-ray should show the upper border of the epiphysis well above the surface of the neck, and that in the lateral view the epiphysis should not be displaced posteriorly more than one-third of the diameter of the neck

No attempt is made to alter this position in such cases and they are pinned by means of the Moore type of fixation pins These are only 2 5 mm in diameter and are less traumatizing than a Smith-Petersen pin and, equally important, they do not tend to push the epiphysis away from the metaphysis. In two weeks they are allowed up on crutches but weight-bearing is not permitted for three months The pins are removed in 12 months by which time the epiphysis is usually fused.

2. Cases with Displacement.

The early case Where the disability has occurred suddenly and acutely the case is treated as an emergency and treatment instituted forthwith since each day that passes makes a successful result less probable At the earliest convenience an anæsthetic is given and the hip gently moved under radiological control to ascertain any mobility of the epiphysis If the epiphysis is mobile it may be reduced possibly by gentle movement or by skeletal traction using a 10-lb long pull on the limb and a derotating pull of about 4 lb

Manipulation must be gentle and, if successful, pinning is carried out at the same sitting Foley recommends the Leadbetter method of manipulation and finds that in early cases the reduction may take place surprisingly easily and completely with slight crepitus. The reduction is checked by X-rays and if satisfactory the limb is fixed and the pinning carried out

If X-ray shows the epiphysis to be immobile and the degree of slip slight the deformity is accepted and pins inserted.

If the epiphysis is immobile and the degree of slip severe the patient is returned to bed because no immediate treatment is indicated and it can only be corrected by open operation.

position of the limb. In addition, the radiographic appearance is characteristic.

Differential Diagnosis

Coxa vara is to be distinguished from tuberculosis of the hip, osteochondritis, and congenital dislocation.

The *tuberculous hip* is adducted and medially rotated, with movement limited in all directions. The atrophy is greater, and the hip is more sensitive and painful even while at rest.

In *osteochondritis*, the history, the limitation of movement, the slight atrophy, and the shortening are identical with those of a mild coxa vara The chief points of difference are the age of the patient, and the X-ray appearance. Osteochondritis rarely begins after the tenth year, while epiphyseal coxa vara seldom begins before it In osteochondritis the head is not displaced but actually deformed, and may in the mushroomed type "overflow" on to the upper border of the neck.

In *congenital dislocation of the hip*, there is a history of lameness from birth In addition, the head of the femur may be palpated outside the acetabulum, and telescopic movement can be elicited in the majority of cases.

Brailsford believes that *renal rickets* may produce a disorganization of the metaphysis very like early cases of a slipping epiphysis. Renal rickets, therefore, should be excluded before any operative procedures are undertaken in these cases, the urine being examined for albumin on several occasions.

Prognosis

In making a prognosis, the fact must be considered that in a proportion of cases—about 1 in 60—the second hip becomes affected.

The end-result depends to a certain extent upon the degree of displacement of the head, but it is only in the early cases where there is minimal slipping that the end result is completely satisfactory.

A review of the end-results from various sources forces the conclusion that, save in the exceptional case, manipulation is apt to do more harm than good This impression is reinforced by operative findings. The appearance of the usual type of slipped epiphysis at operation is such as to convince the surgeon that if manipulation had been attempted, the strength required to reduce the displaced head would have done irreparable damage to the cartilaginous joint surfaces.

Most patients with a displaced epiphysis develop arthritic changes during adult life.

Treatment

Adolescent coxa vara should be treated as a surgical emergency no matter the degree of slip or the mildness of the symptoms. A slight slip should be fixed, an acute displacement reduced and fixed, and a

the deformity and allow the gap in the neck to be closed Avascular necrosis is the complication to be feared also in this operation but it is a risk in all degrees of slipping The preferable operation is the former, especially in reasonably early cases.

(3) *Subtrochanteric osteotomy.* This is safe but not ideal. The hip left as it is with a severe degree of slip gives a marked limp, permanent disability and the likelihood of early arthritic change. It does, however, compensate to some extent for the deformity and may in the early stages considerably improve the gait and relieve symptoms.

(a) (b) (c)

FIG 226—Slipped epiphysis treated by open reduction and retained by a Smith-Petersen nail

The patient danced in the chorus of a pantomime 18 months after.

3. The Treatment of the Healed Case in Young Adults. In this type the head is markedly deformed, the neck is thickened, and its upper surface rests against the upper portion of the acetabulum. No line of demarcation is present between the epiphysis and the neck.

It should be realized at the outset that even an approximately normal joint is unlikely to result, and this being so the choice of operation will be an arthroplasty by the cup or metallic prosthesis method or a McMurray osteotomy, and indeed it may now be looked on as a severe arthritic condition but with the obvious advantage that the patient is young. It is therefore a suitable case for a cup arthroplasty and the results of this are good, in selected cases with marked pain

4. The Treatment of Older Cases with Arthritis. The treatment of this type too is practically that of osteo-arthritis and, since operative treatment is a serious matter, it should not be lightly undertaken. Where the patient is a poor operative risk, it is better to be content with palliative measures, such as physiotherapy, rest, and possibly a walking caliper If these measures fail to give relief, operation may be unavoidable, or even demanded. In such a case, the simplest and quickest measure should be adopted, and the operation attended with the slightest degree of shock is the displacement osteotomy of McMurray, already described.

The operative treatment of this type is controversial. There are three possibilities

(1) *Open anatomical reduction.* With the joint opened and the neck and epiphysis exposed, the epiphysis is freed by dissection through the metaphysis. The neck is then, by abduction and internal rotation



(*a*) (*b*)

FIG 225 —(*a*) Coxa Vara from a slipped Epiphysis of some months' duration. Open reduction is the appropriate treatment (*b*) After reduction.

of the limb, manipulated into its correct relationship with the epiphysis. Sufficient bone has to be removed from the metaphysis to make reduction possible without any great force

(2) *Osteotomy of the femoral neck* By this means the deformity is corrected by removal of a wedge of the base of the neck. The base of the wedge is antero-lateral and sufficiently large to compensate for

Etiology

There is usually a history of injury sustained while the hand is dorsiflexed, but the trauma may be a very insignificant one, and in some cases no history of injury can be obtained

The condition usually begins with a primary total or partial, acute or chronic fracture which becomes pseudarthrotic and is accompanied

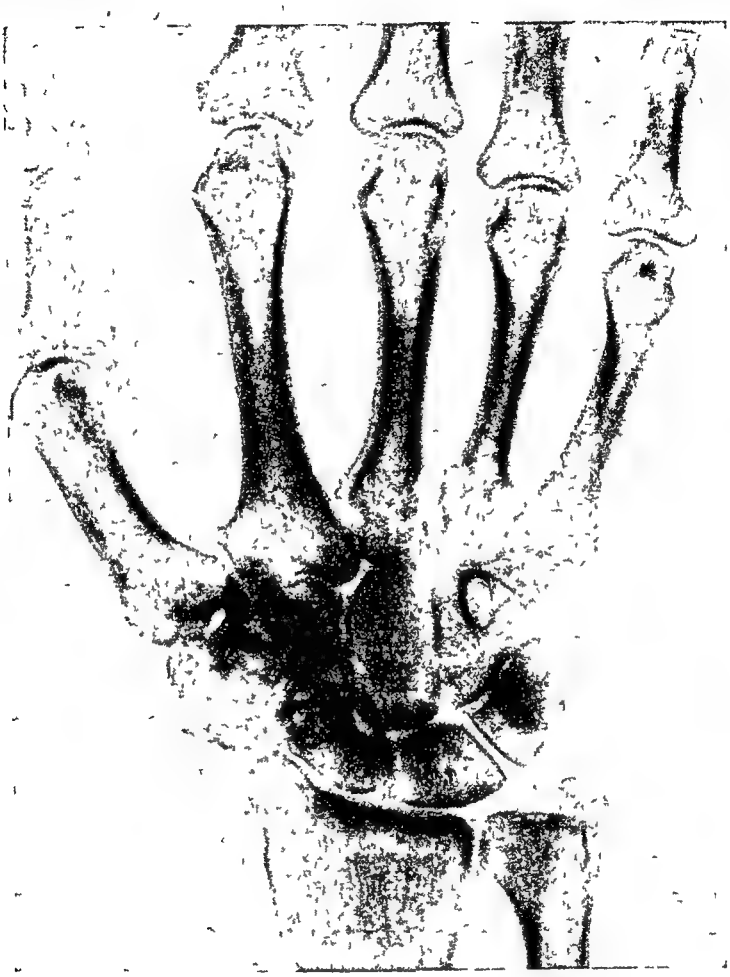

Fig 227.—Osteoporosis of the Os Trapezium.

by secondary changes in the spongiosa and the joint cartilage. Protracted use of the hand leads to further fragmentation These characteristic secondary fractures are promoted by the peri-fractural osteolysis and osteosclerosis and develop into further pseudarthroses There is a labile equilibrium between traumatic damage and restoration with predominance of osteolysis. Complete recovery is possible with rest from the first but continued use leads to progressive atrophy of the semilunar bone The aseptic necrosis of the bone is secondary and due to fractures

Although the condition is usually compared with the various osteochondritides previously described, it differs very materially from them

This gives a strong painless weight-bearing limb whose function is extraordinarily good

AVULSION OF THE LESSER TROCHANTER OF THE FEMUR

The lesser trochanter of the femur is the comparatively weak structure into which the ilio-psoas tendon is inserted. Its ossification centre appears about the twelfth year and unites with the shaft at the eighteenth, so that, during the intervening years, it is liable to be avulsed by undue traction exerted by the ilio-psoas.

The cause is usually traumatic and the condition, therefore, more often occurs in boys, who are more subject to injury.

Symptoms

One of the functions of the ilio-psoas tendon is to flex the hip joint and, therefore, where the trochanter has been avulsed, the patient is unable to perform this movement In consequence a limp develops, and, at the same time, attempts to carry out the movement are painful

On examination, tenderness is elicited in the region of the lesser trochanter, and when the patient lies on his back on the examination couch, he is unable to raise his thigh. He is also unable to mount stairs unless he drags the affected limb after the sound one. He cannot bend from the hip, and fails to pick up an object from the floor.

An X-ray examination reveals the separation of the epiphysis

The prognosis is good.

Treatment

Complete immobilization is unnecessary; it is usually sufficient to put the patient to bed in a sitting-up position, i e the Fowler position At the same time a means of preventing some abduction of the affected side should be adopted. The patient uses a back rest while sleeping Union usually takes place in about six weeks.

OSTEOPOROSIS OF THE CARPAL BONES

This rare condition was first described by Kienbock in 1910, as an affection of the carpal lunate bone. Since that time a considerable volume of literature has accumulated, and many hypotheses have been advanced to explain its occurrence. It may affect many of the carpal bones in addition to the lunate—Buchmann, for example, states that it may also occur in the navicular, the trapezium, and the hamate So many of Buchmann's cases gave a definite history of injury that he has named it traumatic osteoporosis of the carpus When it affects the lunate, however, the condition is usually called Kienbock's disease (also lunato-malacia), and, when the navicular is involved, Preiser's disease.

become fragmented, and areas may even disappear Changes of an osteo-arthritic character may also occur, so that the articular surface of the radius may show osteoporosis, and the points of insertion of the ligaments may become roughened.

It is a matter of doubt whether any line of fracture can be seen

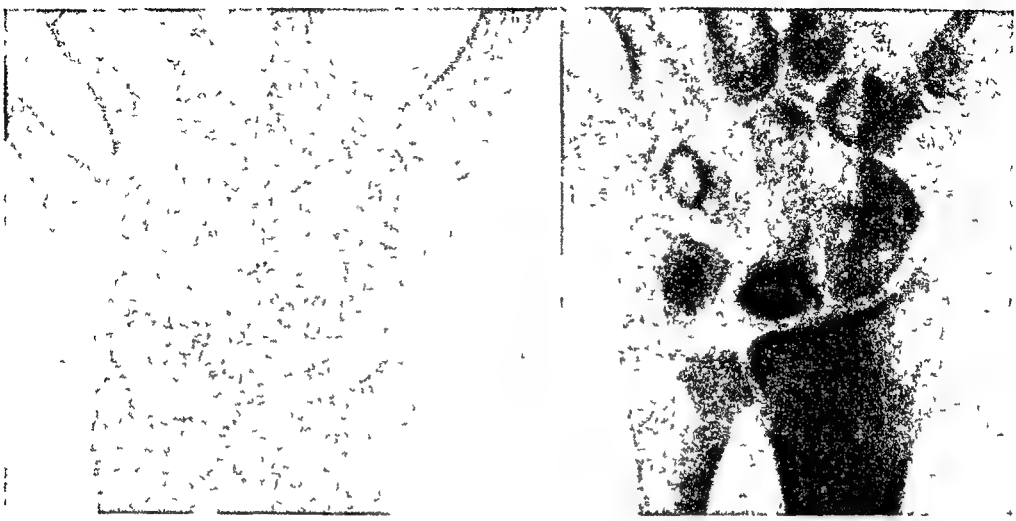

(a) (b)

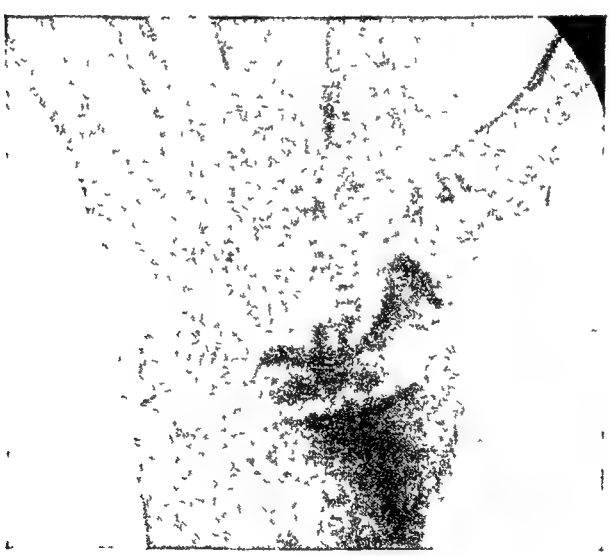

(c)

FIG. 228.—Kienbock's disease The X-ray appearance at various stages. (a) 1 11 47, (b) 27.1 48, (c) 2 3 48

in the early stages Some authors believe that it is present but invisible, because of the superimposition of bone, or because of the thickness of the bone Kienbock, however. believes that it is not present at first, but that it occurs secondarily, and is pathological in nature. The first radiological evidence of the condition may be one

It affects, for example, only fully formed tissue, in which growth has been completed. It is, perhaps, more correct to compare it with Kummel's disease of the spine, and with the absorption occasionally seen in certain fractures of the neck of the femur. These two conditions probably belong to the same group.

Clinical Course

The course of the disease can be divided into three stages:

1. An acute stage, following the injury.
2. A period of freedom, sometimes lasting as long as two months.
3. A period of the actual disease, the symptoms of which may perhaps persist for years.

The acute stage follows the injury, and lasts some weeks. The trauma is not uncommonly a mild one, so that the patient is often not disabled It may be a simple strain, accompanied by swelling, pain and tenderness over the lunate, with limitation of the extremes of motion

The painful period is followed by an interval of freedom from symptoms, which may last months or even years. The period of active disease then sets in. It is characterized by increasing disability, by swelling and tenderness over the lunate In the early stages the pain is aching, present only on extreme exertion, and aggravated by excessive use of the wrist, but it gradually becomes more persistent, until, in the final stages, it is permanent and disabling.

When the condition is well advanced, and destruction considerable, clenching of the hand fails to show the normal prominence of the head of the third metacarpal. This bone may even recede, because of shortening in the vertical axis of the affected lunate This sign is known as Finsterer's sign and is said to be pathognomonic of Kienbock's disease. Percussion over the head of the third metacarpal also elicits tenderness, and, while pushing with the hand is painful, pulling actions are said to be accomplished without any discomfort. The depression normally situated just below the distal end of the radius is obliterated occasionally from the antero-posterior thickening of the lunate.

When the disease affects the navicular, the symptoms and signs are very similar Pain is at first slight, and felt only on exertion, but it gradually becomes more and more severe and is finally present even when the hand is at rest. It may even become so excruciating that the patient is unable to sleep. Movement, especially dorsiflexion, is limited There is usually slight swelling and tenderness over the navicular, and the "anatomical snuff-box" may be obliterated.

X-ray Appearance. In early cases there are no characteristic X-ray appearances, but later, areas of rarefaction and of increased calcification may be seen The affected bone is denser than the others and is also wider in its antero-posterior axis, but thinned out in its short vertical axis In the later stages, the proximal aspect may

The disease is sometimes associated with hypoglycæmia, and it has lately been shown that the creatinine metabolism is disturbed.

Treatment

Scientifically planned exercises retard the muscular lesion. Massage and friction may be employed to supplement these, but are of minor importance compared with the exercises Tinne treated his cases by pineal substance, 1/10th of a grain three times a day for three weeks out of five, then thyroid and pituitary, and, as the patient grows older, testicular extract Lewin, in view of the hypoglycæmia, gives suprarenal extract, 3/200 of a grain by the mouth three times a day.

In view of the abnormality in the creatin metabolism, glycin has recently been given with very marked clinical improvement

2. The Juvenile Type of Erb

In this type the sexes are more equally affected than in pseudo-hypertrophic paralysis. It usually begins in the second decade of life, and the muscles of the upper arm and thigh, together with certain muscles of the shoulder and pelvic girdles, are affected; those of the forearm and leg are generally spared. There is, therefore, a striking contrast between the size of the arm and forearm, and of the thigh and leg, in a typical case.

The biceps, triceps and brachio-radialis are the first muscles to show any change. Subsequently the latissimus dorsi, the lower part of the pectoralis major, the trapezius, the serratus anterior and the rhomboids are involved The deltoid and the spinati usually escape. The atrophy of the serrati leads to bilateral winging of the scapulæ Later in the disease the glutei, the flexors of the hip and the muscles of the thigh, especially the quadriceps extensor, become wasted and weak. The gait and the manner of rising from the ground may be the same as in the pseudo-hypertrophic form.

3. The Facio-Scapulo-Humeral Type of Landouzy and Dejerine

This is a type in which weakness of the facial muscles begins to develop in infancy, or is present at birth, and is followed by wasting of the scapulo-humeral muscles. In other respects the distribution of the atrophy resembles that of the juvenile form, and the two diseases are in all probability of the same nature

The hereditary nature of this type is sometimes shown by its presence in successive generations. In many cases, however, no other members of the family have been affected.

The characteristic feature is the early and marked involvement of the facial muscles. The orbicularis oris and orbicularis palpebrarum are prominently affected, the patient being unable to close the eyes completely, or to whistle or blow A sphinx-like facies develops: the lips are everted, the lower lip projects and the mouth has, not inaptly,

or more small circular or oval areas of absorption or rarefaction in the centre of the bone These soon fuse into a large area of decreased density, and through this area the fracture occurs.

The histological findings in excised specimens vary with the extent and duration of the disease, but in general there is absorption of the bone lamellæ with replacement by granulation tissue which goes on to form fibrous tissue instead of becoming calcified. This is a slow process and the deformity may be aggravated by fresh injuries.

Prognosis

The prognosis depends upon the treatment. Poor results follow unrecognized fractures of the lunate bone just as they follow unrecognized fractures of the carpal navicular.

Under conservative measures many cases recover completely, both clinically and radiographically It is usual, however, to find evidences of osteo-arthritis, with severe disability, some time after the condition has cleared up Other cases have periods of either complete or comparative relief from symptoms, while others again become continuously incapacitated.

Treatment

Treatment may be either conservative or operative, and good results have been reported from both.

Conservative treatment should be tried first, the wrist being put up in a plaster-of-Paris cock-up splint, as for a fractured navicular, for two or three months This gives good results in early cases.

If, after that period, the condition persists in spite of these measures, it is tempting to remove the abnormal bone, but the truth is that this rarely cures the pain since arthritis has usually started and will progress in spite of the removal of its cause. In cases with arthritis arthrodesis should be considered and carried out if the symptoms are sufficiently incapacitating. The symptoms disappear after a successful arthrodesis and the loss of palmar flexion is no disability

touches the forearm and the dorsum of the foot the front of the tibia. The hands and feet are often long.

The children never learn to walk but adopt some strange method of getting about, by rolling over and over or by assuming a squatting attitude, so that the name "frog-child" or "the limp floppy baby" may be given to them

Contractures are apt to occur in the course of time, and the knee and hip may be flexed.

The muscles show a lowered excitability to faradism—indeed, when the amyotonia is severe the current must be very powerful to obtain any response. The strong current is borne without complaint, despite the fact that no loss of sensibility to any other form of stimulation can be detected.

The superficial reflexes are normal; the deep are lost, but may return in cases in which improvement takes place. The sphincters are never affected. The mental condition is normal and the child learns to talk at the ordinary age. The growth of the bones and the general bodily development are not interfered with

The course of the disease is one of slow and progressive improvement which may be hastened by the persevering use of massage and passive movements, although complete recovery has never been recorded.

(c) Infantile polyneuritis is comparatively rare but it shows all the clinical features of amyotonia congenita including congenital onset and tendency to improvement In these cases muscle biopsies show no abnormality or, at most, an appearance of immaturity. In this condition an elevated protein content in the cerebro-spinal fluid may be sufficient to make the diagnosis clear.

6. Myotonia Atrophica

This is a very rare condition characterized by the association of muscular atrophy with a slow relaxation of the muscles of the extremities after voluntary contraction. This myotonic condition is very limited in its distribution It is most conspicuous in the flexor muscles of the hands, so that the patient finds it impossible to relax his grasp suddenly.

The atrophic weakness affects the facial muscles, the sterno-mastoids, the vasti, and the dorsiflexors of the ankle, and occasionally the forearm muscles, the masseters and the temporals

The disease is a familial one and affects the males rather than the females Its manifestations usually appear between the ages of twenty and thirty Its course is slow and progressive, and in many cases muscular wasting is present for several years before the myotonic state appears.

Diagnosis of the Myopathies

Well marked types are easy to recognize, but there are many aberrant forms in which it may be difficult to decide whether the

been compared to that of a tapir. The smile is often peculiar, for the mouth forms a straight line, and the angles of the mouth are not drawn upwards and outwards

After the facial atrophy develops, the muscles of the shoulders and the arms are implicated and subsequently the muscles of the back, hip and thigh

4. The Distal Type

The characteristic feature of this type is atrophy of the distal muscles of the limbs, especially the extensors of the wrists and fingers, and of the toes and ankles. The proximal muscles are not affected, though occasionally the face is The condition may be noticed in infancy, or not till adult life.

Clinically the disease closely resembles the peroneal type of muscular atrophy. In the latter, however, sensory changes in the legs are often present and the facial muscles are never affected.

5. Infantile Hypotonia

(*a*) Muscular weakness and hypotonia in infancy and early childhood are important physical signs, often difficult to understand and interpret

Werding and Hoffman described infantile spinal muscular atrophy. This is one in which the child appears normal during the first few months of its life but then develops a rapidly progressive flaccid paralysis of the limbs and trunk, progressing inexorably to death. It commonly affects more than one member of a sibship.

(*b*) *Amyotonia Congenita* This is a rare infantile malady characterized by smallness and extreme flaccidity of the voluntary muscles, by loss of the deep reflexes and by a tendency to gradual improvement.

Oppenheim described Amyotonia Congenita and suggested that the condition was present at birth and in contrast to the Werding-Hoffman disease tended to improve slowly but steadily, and, unlike the other, was not familial

The condition is usually congenital and is noticed at birth or shortly afterwards In a few cases it has developed in a previously healthy infant, apparently as a result of diarrhœa or acute bronchitis. There is no evidence of either hereditary or familial tendency, so that it is not certain whether this disorder should be included among the myopathies or not The health of the parents, including that of the mother during pregnancy, has usually been good.

The limbs, especially the lower ones, are the most severely affected; the trunk is often involved, the face but rarely. There is general weakness of the limb, but no actual paralysis, voluntary power in individual muscles, although feeble, being retained. The distribution of the muscular flaccidity is symmetrical The limbs are flail-like at all their joints, and may assume the most curious positions. Thus the wrist and the ankle may be so over-extended that the metacarpus

touches the forearm and the dorsum of the foot the front of the tibia. The hands and feet are often long

The children never learn to walk but adopt some strange method of getting about, by rolling over and over or by assuming a squatting attitude, so that the name "frog-child" or "the limp floppy baby" may be given to them

Contractures are apt to occur in the course of time, and the knee and hip may be flexed.

The muscles show a lowered excitability to faradism—indeed, when the amyotonia is severe the current must be very powerful to obtain any response. The strong current is borne without complaint, despite the fact that no loss of sensibility to any other form of stimulation can be detected.

The superficial reflexes are normal; the deep are lost, but may return in cases in which improvement takes place The sphincters are never affected The mental condition is normal and the child learns to talk at the ordinary age The growth of the bones and the general bodily development are not interfered with.

The course of the disease is one of slow and progressive improvement which may be hastened by the persevering use of massage and passive movements, although complete recovery has never been recorded

(*c*) Infantile polyneuritis is comparatively rare but it shows all the clinical features of amyotonia congenita including congenital onset and tendency to improvement In these cases muscle biopsies show no abnormality or, at most, an appearance of immaturity. In this condition an elevated protein content in the cerebro-spinal fluid may be sufficient to make the diagnosis clear.

6. Myotonia Atrophica

This is a very rare condition characterized by the association of muscular atrophy with a slow relaxation of the muscles of the extremities after voluntary contraction This myotonic condition is very limited in its distribution It is most conspicuous in the flexor muscles of the hands, so that the patient finds it impossible to relax his grasp suddenly

The atrophic weakness affects the facial muscles, the sterno-mastoids, the vasti, and the dorsiflexors of the ankle, and occasionally the forearm muscles, the masseters and the temporals.

The disease is a familial one and affects the males rather than the females. Its manifestations usually appear between the ages of twenty and thirty Its course is slow and progressive, and in many cases muscular wasting is present for several years before the myotonic state appears.

Diagnosis of the Myopathies

Well marked types are easy to recognize, but there are many aberrant forms in which it may be difficult to decide whether the

muscular atrophy depends on an abnormal condition of muscular tissue or on disease of the spinal cord. In favour of a myopathy would be .

1. The onset of the atrophy at an early age.
2 Its occurrence in more than one member of the family.
3 Its distribution. Progressive wasting of the muscles does not correspond to destruction of a definite group of cells in the spinal cord.
4. The absence of fibrillary twitchings and of a definite reaction of degeneration.
5. The condition of the tendon reflexes, which are never exaggerated and disappear as the muscular wasting progresses.

FRIEDREICH'S ATAXIA

This is a developmental disease in which there is an ataxic paraplegia as a result of sclerosis of the postero-lateral columns of the spinal cord. The symptoms usually appear during adolescence, and consist of inco-ordination and weakness of the legs, clumsy speech, nystagmus, scoliosis and pes cavus. The deep reflexes are absent but the plantar reflex is of the extensor type. In the later stages there is a profound loss of joint sense in the lower limb, and often diminished tactile sense, although sensibility to pain and temperature remain unimpaired to the end.

The characteristic claw foot deformity of the well-marked case occasionally develops at an early stage, even before the characteristic ataxia. For this reason a neurological examination should be made in cases of adolescent claw foot before operative correction is undertaken.

The disease is progressive and little can be done to arrest it.

PROGRESSIVE MUSCULAR ATROPHY

The progressive atrophic paralysis which characterizes this disease depends on a gradual destruction of the ganglionic cells in the anterior horn of the spinal cord as a result of chronic inflammatory or degenerative changes

Symptoms

Usually the initial feature is weakness or wasting of some of the small muscles of the hand, especially those of the thenar eminence and the interossei The atrophy gradually increases in extent until paralysis supervenes A characteristic deformity is soon produced by the weakness of the interossei, for the flexor muscles of the fingers flex the interphalangeal, whilst the long extensor muscle hyper-extends the metacarpo-phalangeal joints; hence the claw-hand or *main en griffe* appearance results Weakness and wasting now spread to the arms, one limb being affected in advance of the other. In the forearm the flexors are first affected, and in consequence the claw-shaped

muscular atrophy depends on an abnormal condition of muscular tissue or on disease of the spinal cord. In favour of a myopathy would be:

1. The onset of the atrophy at an early age.
2. Its occurrence in more than one member of the family.
3. Its distribution. Progressive wasting of the muscles does not correspond to destruction of a definite group of cells in the spinal cord.
4. The absence of fibrillary twitchings and of a definite reaction of degeneration.
5. The condition of the tendon reflexes, which are never exaggerated and disappear as the muscular wasting progresses.

FRIEDREICH'S ATAXIA

This is a developmental disease in which there is an ataxic paraplegia as a result of sclerosis of the postero-lateral columns of the spinal cord The symptoms usually appear during adolescence, and consist of inco-ordination and weakness of the legs, clumsy speech, nystagmus, scoliosis and pes cavus. The deep reflexes are absent but the plantar reflex is of the extensor type In the later stages there is a profound loss of joint sense in the lower limb, and often diminished tactile sense, although sensibility to pain and temperature remain unimpaired to the end

The characteristic claw foot deformity of the well-marked case occasionally develops at an early stage, even before the characteristic ataxia. For this reason a neurological examination should be made in cases of adolescent claw foot before operative correction is undertaken.

The disease is progressive and little can be done to arrest it.

PROGRESSIVE MUSCULAR ATROPHY

The progressive atrophic paralysis which characterizes this disease depends on a gradual destruction of the ganglionic cells in the anterior horn of the spinal cord as a result of chronic inflammatory or degenerative changes

Symptoms

Usually the initial feature is weakness or wasting of some of the small muscles of the hand, especially those of the thenar eminence and the interossei The atrophy gradually increases in extent until paralysis supervenes A characteristic deformity is soon produced by the weakness of the interossei, for the flexor muscles of the fingers flex the interphalangeal, whilst the long extensor muscle hyper-extends the metacarpo-phalangeal joints, hence the claw-hand or *main en griffe* appearance results Weakness and wasting now spread to the arms, one limb being affected in advance of the other. In the forearm the flexors are first affected, and in consequence the claw-shaped

considerable degree of rarefaction. Shortening invariably occurs in paralytic limbs, the exact cause is not known but reduction of the musculo-osseus blood supply from paralysed muscles is probably an important factor. Joint capsules and ligaments when not protected by healthy muscles become stretched, the joints become unduly mobile and occasionally may dislocate if not protected. The skin circulation of the paralysed limb is affected and responds more readily to local temperatures. In cold conditions the cyanotic leg with recurring chilblains may be a source of discomfort to the patient.

Clinical Features and Course of Disease

Exposure of the susceptible individual to poliomyelitis produces a wide variety of response to infection. In epidemic poliomyelitis it is known that the virus is present in the fæces of "healthy carriers" and most probably also in the pharynx at the time of infection. In these cases either the virus has not extended beyond the alimentary tract or else the disease has been asymptomatic. "Silent infection" is probably very common during epidemics and while of no clinical significance it is obviously an important factor in the spread of disease.

The incubation period is difficult to define in many cases. It varies from three days to several weeks with a probable average of 10 days. Direct questioning of intimate contacts of paralytic patients frequently brings to light minor symptoms such as brief headache, back pain or sore throat.

Poliomyelitis usually presents as an acute illness with symptoms of meningitis followed by paralysis. Different forms of the disease are described but they refer merely to variations in symptomatology, depending on the differences in the intensity and location of lesions within the central nervous system. See Table I.

The clinical course of paralytic poliomyelitis passes from the acute stage to the convalescent or recovery stage and finally to the chronic or residual stage when no further significant recovery in muscle power can be expected.

Table I

Stages in Development of Poliomyelitis		*Clinical Forms of Disease*
(Minor Illness) Prodromal Stage		Abortive poliomyelitis
(Major Illness) Preparalytic Stage	→	Non-paralytic poliomyelitis
Paralytic Stage	→	Paralytic poliomyelitis { Bulbar type / Spinal type

N B Recovery at Prodromal Stage = Abortive poliomyelitis
Recovery at Preparalytic Stage = Non-paralytic poliomyelitis.

Clinical Course of Paralytic Poliomyelitis

Acute Stage = Major Illness
Convalescent Stage = Stage of Recovery
Chronic or Residual Stage = No further significant recovery.

moment whether the blood-stream invasion is incidental to or precedes the invasion of the central nervous system.

The presence of the virus in the central nervous system is usually associated with the onset of meningitic symptoms but its effect may vary from the slight paresis found clinically without any history of a previous illness to the severe meningitic case which recovers without any demonstrable muscle weakness

The factors governing the degree of destruction of the motor cells are not fully understood but clinical observations indicate that certain conditions influence not only the incidence but also the localization of paralysis. Ritchie Russel (1947) drew attention to the fact that physical activity during the preparalytic stage increased the incidence and severity of paralysis. Injections or trauma to the limbs may precipitate paralysis which is often localized to the affected limbs while recent tonsillectomy appears to increase the frequency of bulbar poliomyelitis.

Pathogenesis

The poliomyelitis virus once established in the central nervous system has a special affinity for the anterior horn cell of the spinal cord and for certain motor nuclei in the brain stem

The pathological changes which take place in the spinal cord motoneurones have been clarified by Bodian and are based on evidence obtained both from human autopsies and from experimental work with monkeys.

The earliest visible change is chromatolysis of the Nissl substance in the cytoplasm of the nerve cell and this is followed by inflammatory infiltrations of polymorphonuclear and mononuclear cells at first in the perivascular regions and then diffusely in the grey matter.

Interference with function of a motor cell in poliomyelitis may be reversible or irreversible and early recovery of some muscle groups is often a striking feature in the early weeks of the disease It was previously considered that œdema was responsible for temporary paralysis but Bodian's experimental work does not support this view. Bodian considers that nerve cells are either destroyed during the early days of the illness or undergo slow recovery leading to morphological recovery within about a month

In the irreversible case chromatolysis progresses, the cell nucleus shrinks and the necrotic cell is removed by neuronophagia.

Changes in the Chronic Stage of Poliomyelitis. As a result of the destruction of the nerve cells in the anterior horn, the peripheral nerve degenerates and the muscles supplied by it atrophy The extent of muscular degeneration depends on the amount of nerve involved. The atrophied muscle fibres are recognized by their yellowish-white colour In some cases complete degeneration is shown by the fatty deposit around the atrophied muscle Tendons atrophy from disuse and lose their normal glistening appearance Bones are also involved in the pathological process—they are more slender than normal with a

Paralytic poliomyelitis presents either as the spinal or bulbar form of the disease Fortunately combination of the two forms in the same patient is rare

The Spinal form is the more usual type Partial or complete paralysis affects the muscles of the neck, trunk and extremities. The paralysis is of the flaccid lower motor neurone type with loss of tendon reflexes. The lower limbs are affected at least twice as frequently as the upper limbs and there appears to be a certain predilection for muscles such as the Tibialis Anterior and Posterior, Quadriceps, Glutei and Deltoid. The bladder is affected in a small percentage of cases and retention of urine may require catheterization.

Paralysis of the diaphragm and intercostal muscles is manifest by rapid shallow respirations. The patient becomes restless, apprehensive and fatigued The appearance of cyanosis of the lips indicates the need for mechanical respiration.

The Bulbar form of poliomyelitis though less common than the spinal form is nevertheless of extreme importance as it accounts for a high proportion of deaths attributable to poliomyelitis. The initial symptoms indicating involvement of the cranial nuclei are nasal intonation, difficulty in swallowing and accumulation of saliva in the pharynx. Cyanosis in these cases is an indication of obstruction to the airway. Prompt recognition and treatment will relieve obstruction to the airway but in severe bulbar cases progressive involvement of the vital centres may rapidly prove fatal.

Muscle Spasm.

The term muscle spasm is so frequently associated with the early stages of poliomyelitis that consideration of its definition and etiology is warranted.

Definition of "Muscle Spasm" In the acute and early recovery stages of poliomyelitis passive movement is sometimes limited by pain or resisted by muscle contraction A clinical study of poliomyelitis patients suggests that the muscle contraction usually described as muscle spasm is an involuntary contraction to prevent a potentially painful movement and resembles the muscle spasm associated with certain fractures

Pain is a common symptom in the early stage of the illness

In the acute febrile stage sustained painful spasm of the posterior spinal muscles is a characteristic feature and resembles the protective spasm of other inflammatory meningitic conditions. This sustained tone disappears but spasm of the back muscles can be elicited by spinal flexion for a variable period in the recovery stage

Pain in the limbs not necessarily associated with movement may present as a feature of the preparalytic and paralytic stages This type of pain is probably referred from lesions which have been described by Bodian (1948) in the spinal ganglia.

When the patient has recovered from the acute stage passive move-

Minor Illness In approximately one-third of patients admitted to hospital with poliomyelitis there is a definite history of a short prodromal stage with symptoms of slight headache, malaise, fever and sore throat. This minor illness lasts only for 48 hours. The symptoms while not specific for poliomyelitis warrant close observation of the patient during localized outbreaks of the disease.

The illness may not proceed beyond the prodromal stage and an abortive form of poliomyelitis is recognized In less fortunate patients the minor illness is followed by four or five days of well-being before the onset of the major illness This apparent recovery frequently encourages the patient to resume work or strenuous holiday activity which may have some bearing on the eventual severity of the paralysis.

Acute Stage (Major Illness) This stage describes the main febrile phase of the disease and is regarded as the most dangerous phase of invasion of the motor nerve cell. The major illness which lasts from four to seven days occurs in all typical cases of poliomyelitis and includes both the preparalytic and paralytic stages

Preparalytic Stage The preparalytic stage is characterized in the majority of cases by an abrupt onset of meningeal symptoms accompanied by headache, fever, malaise, nausea or vomiting The temperature rises to 101–103° F, neck stiffness becomes more marked, the patient is often irritable and complains of pain in the trunk or limbs

The patient does not wish to sit up. On examination there is definite stiffness of the back and neck and in severe cases retraction of the head and arching of the back are maintained by spasm of the posterior spinal muscles

It should be recognized that the preparalytic stage may be less dramatic and patients are sometimes seen in whom muscle weakness is the only available evidence of poliomyelitis

The term non-paralytic poliomyelitis describes the case in which the symptoms and signs of the preparalytic stage subside without clinical evidence of paralysis.

Paralytic Stage. Paralysis supervenes usually on the third or fourth day but may appear at any time during the major illness. The onset of paralysis is not marked by any particular change in the signs and symptoms of the preparalytic stage, although diminution or loss of deep reflexes may precede paralysis in the affected muscle groups

The degree of meningeal symptoms and signs is variable and is not related directly to the severity of the paralysis. The patient complains of headache and pain in the back. Photophobia is marked in some cases while in others pain and tenderness of the limbs is a prominent feature.

Spasm of the posterior spinal muscles with neck retraction and a positive Kernig sign are found in the majority of patients but true muscle spasm in the extremities is not a feature of poliomyelitis in this country.

e.g , Lasegue and Kernig (Mitchell, 1952). The response simulates that found in irritation of the sciatic roots by certain intervertebral disc protusions (Fig. 229). The limitation of straight leg raising is equal on both sides irrespective of the degree of paralysis. When muscle resistance is ineffective, the straight leg raising may be limited by pain alone

(a)

(b)

Fig 230 —Protective Spasm in Biceps Limiting Extension, produced by Contralateral Neck Flexion and also by Traction on Upper Limb.

Schlesinger (1951) found that limitation and pain persisted even with muscles rendered atonic with intravenous mephenesin.

Muscle spasm is less common in the upper limbs and appears usually as a resistance to full abduction of the shoulder or as a temporary limitation of elbow extension In the author's experience only approximately 2 per cent of paralytic cases show a significant degree of muscle spasm in the upper limbs. In such patients the muscle spasm is also

ment of the limbs may be limited by pain or painful muscle contractions which, if treatment is neglected, encourage faulty positioning with possible joint stiffness and deformity.

Passive movement of the limbs in the early stages of poliomyelitis is limited by spasm only when the muscles are active and by pain alone when muscles are paralysed The term muscle resistance to stretch



(a)

(b)

FIG. 229 —Limitation of Straight Leg Raising in Early Weeks of Poliomyelitis Limitation increased by Dorsiflexion of Foot

is a more accurate description of this guarding action of muscles but the term muscle spasm is more convenient for clinical description

Etiology of Muscle Spasm. Muscle spasm or muscle resistance to stretch is more frequently manifest as a contraction of the hamstring group which limits straight leg raising to an angle of 30 degrees in a high proportion of patients with lower limb involvement. The muscle spasm in these patients can be aggravated by nerve traction tests,

evidence of early recovery or the initial paralysis will have been incomplete

Muscle recovery is most marked in the first three to six months but continues to improve up to eighteen months to two years (Fig. 231) (Green, 1949)

Residual Stage Significant increase in reliable muscle chart recordings seldom occurs later than two years after the onset of poliomyelitis but functional improvement may continue for several years especially in young children This can be attributed to improved co-ordination and will power assisted by general body development.

Diagnosis

Diagnosis of the prodromal illness (minor illness) can only be presumed during localized outbreaks of poliomyelitis as the clinical features are not specific A brief febrile illness may be associated with headache, malaise, nausea, vomiting or sore throat. If contact with poliomyelitis is suspected, these patients should be confined to complete rest at home for about a week.

In the major illness the subjective symptoms are more intense. Headache, nausea and vomiting are common together with pain in the neck, back or limbs The most important objective finding is nuchal and spinal rigidity The patient is unable to kiss the knees and when asked to sit up he frequently supports the stiff spine by placing his hands behind him on the bed—tripod sign. Kernig's sign is positive in a high proportion of cases.

Diminished or absent tendon reflexes may precede actual muscle weakness by 24 hours Detailed muscle testing is not justified during the acute stage Main muscle groups can be examined by active movement against the slight resistance of the clinician's hand In the infant, a paralysed limb does not participate in the general rhythm of body movement and offers no resistance when handled The tone of the abdominal muscles is evident in crying

Lumbar Puncture Examination of the cerebrospinal fluid is, however, of the greatest importance in the differential diagnosis of pyogenic and bacterial meningitis and lumbar puncture should be carried out immediately if there is any doubt as to the diagnosis

In poliomyelitis the cerebrospinal fluid is variable but rarely normal During the acute stage the cell count is usually only slightly raised to around 20 per c mm but higher counts of 100—200 per c mm are not infrequently found In the early stage of poliomyelitis the protein is initially normal or only slightly elevated, but as the paralysis develops, the cell increase subsides whereas the protein tends to increase, reaching a level of 100–300 mg per 100 c cm within three weeks of the onset.

aggravated by tests which exert a traction effect on the nerve roots, e.g., upper arm traction and contra-lateral neck flexion (Fig 230) (Mitchell, 1951)

The muscle contraction at first sight appears to resemble true spasticity but there is no true evidence of an upper motor neurone type of lesion and the increased tone subsides rapidly on sedation

From these observations it is concluded that muscle spasm or muscle resistance to stretch is a protective muscle contraction to prevent painful movement of sensitised nerve roots The painful stimuli probably arise from the residual inflammatory changes which have been found at autopsy in the region of the posterior nerve roots and meninges

Convalescent Stage (Stage of Recovery). The convalescent stage or stage of recovery is defined as that period of the disease which starts immediately after the acute stage or major illness and ends when no further significant recovery in muscle power is anticipated.

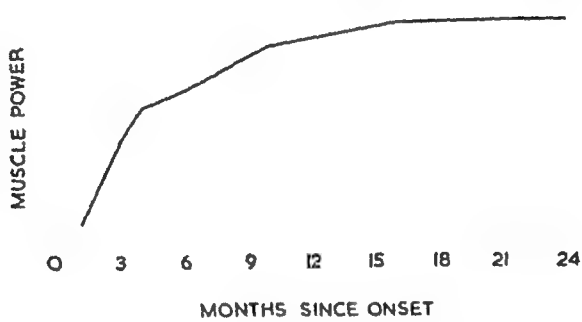

Fig 231 —Muscle Recovery Chart (Green 1949), Showing Rise in Total Muscle Power during First Two Years after onset

Recovery of muscle power depends on the distribution of the destructive lesions in the grey matter of the cord and on the proportion of recoverable to irrecoverable lesions

According to Bodian (1949) the affected motor cells are either rapidly destroyed during the acute paralytic stage of the disease or undergo gradual recovery changes leading to complete morphological recovery within a month While Bodian's deductions are based mainly on experimental work with rhesus monkeys, clinical evidence suggests that in human poliomyelitis the fate of the motor cell is decided in the early weeks of the disease.

Several factors must be considered in attempting to estimate prognosis in the early stage of the illness. Pain, muscle spasm of antagonistic groups, inadequate early treatment and lack of co-ordination in younger children all tend to delay or mask muscle recovery.

In the absence of these factors, complete paralysis of a muscle persisting beyond the third month indicates severe motor-cell destruction and a poor prognosis as regards useful recovery. Where worthwhile return of function is to be anticipated, the muscle will either show

and the necessary facilities must be available to deal adequately with the different problems of respiratory complications which are such an important feature of the acute stage

No specific treatment is indicated during the acute stage. Detailed recording of muscle power at this stage is both unnecessary and harmful ; an approximate estimation of the extent of paralysis can be obtained by gentle handling of the limbs

The patient should be nursed in a quiet cubicle and is allowed to assume whatever position is most comfortable The position of severely paralysed patients should be changed for nursing purposes and to ease back pain which is often marked Retention of urine may require catheterization which should be intermittent and carried out with the strictest asceptic precautions , normal micturition is usually restored early if infection is avoided

Treatment of Respiratory Difficulty.

Prompt recognition and accurate clinical analysis of the functional defect is necessary for successful treatment of respiratory difficulty In some cases, however, extensive destruction of the brain stem with its vital centres renders a fatal outcome inevitable. The two main types of respiratory complications are (I) Intercostal and diaphragmatic paralysis of the spinal form of poliomyelitis and (II) Pharyngeal paralysis of the bulbar form

(*I*) *Intercostal and diaphragmatic paralysis.* The signs of progressive respiratory involvement in order of likely sequence as described by Wilson, 1953, are

Increased Respiratory Effort

1. Increased rate of breathing
2. Dilation of nostrils
3. Interruption of speech
4. Use of accessory muscles of respiration.

Effort and/or Failure

5. Anxiety
6. Restlessness or sleeplessness
7. Disorientation

Respiratory Failure

8. Coma
9. Cyanosis
10. Convulsions

Intercostal and diaphragmatic paralysis of a degree which prevents the maintenance of normal alveolar ventilation, requires the use of artificial aids to respiration. The mechanical respirator of the tank type is the most commonly used

(*II*) *Pharyngeal Paralysis* Pharyngeal paralysis is the most important of the bulbar forms, causing respiratory failure on account of its frequency and the effectiveness of prompt treatment.

The danger in pharyngeal paralysis lies in the constant risk of aspiration of unswallowed secretions Effective coughing may be impossible and obstruction of the airway causes irregular respiration and fatigue. If the obstruction is not relieved, inadequate respiration or aspira-

Differential Diagnosis

i. Meningitis.

(*a*) Meningo encephalitis due to antigenically unrelated viruses, e g , mumps, coxsackie virus. (*b*) Tuberculous meningitis (*c*) Pyogenic meningitis. Important where clinical picture has been modified by chemotherapy prior to admission

ii. Infective Polyneuritis (Guillain-Barré Syndrome) May closely simulate poliomyelitis but the paralysis is symmetrical and sensory changes can usually be demonstrated The cell count is within normal limits and the protein is elevated to over 300 mg. per 100 c.cm. in the C.S.F.

iii. Pseudo-paresis. Hysteria, rheumatic fever, osteomyelitis and injury may be referred as suspected poliomyelitis during epidemics.

Prophylaxis of Acute Poliomyelitis

Trials of poliomyelitis vaccine in the U S A. in 1954 showed that a formalin vaccine could protect against paralytic poliomyelitis and other countries have confirmed the value of vaccination against this disease In 1957 in the U.S.A a protection rate of about 90 per cent. in children receiving three doses of vaccine was achieved. The problem to-day is to determine the most effective way of maintaining immunity The mechanism of immunity is not fully understood. Although resistance is closely associated with the presence of circulating antibody, precise information on whether any particular level of antibody is necessary for protection is lacking.

A better antibody response in infants and young children is obtained with three doses of vaccine rather than with two or one Salk recommends two primary doses, four to six weeks apart, followed by a third dose seven months later There is a considerable decline in the antibody level (especially in types 1 and 3) after immunization with two doses of the vaccine, but a substantial antibody response is obtained after the third or " booster " dose.

Treatment

The treatment of poliomyelitis is conveniently divided into three stages · the acute stage, the convalescent or recovery stage, and the residual stage

In this country the acute stage of poliomyelitis is usually treated in isolation hospitals and the orthopædic surgeon is principally concerned with recovery of function during the convalescent stage and with the treatment of residual disability when recovery has ceased

Treatment of the Acute Stage.

Poliomyelitis patients should initially be admitted to isolation units where the medical and nursing staff are experienced in the differential diagnosis and treatment of acute febrile illnesses Trained personnel

The psychological aspect of treatment is important and the patient should be as relaxed and confident as possible under the circumstances. Pain is alleviated by codeine and sedation with small doses of phenobarbitone assists relaxation and allays apprehension. The treatment of muscle spasm presents no major problem except in severe respiratory cases. Since the muscular contraction is purely protective no vigorous stretching is necessary Spasm likely to interfere with subsequent joint mobility will respond readily to rest, heat and regular gently passive movement.

Hot Packs Hot, moist packs relieve pain and "muscle spasm" during the early days of treatment but should only be used where indicated,

Fig 232 —Tightening of Ilio-tibial Band in Untreated Case

as their over-zealous application can be tiring to the patient. Packs retain heat longer if covered by a rubber hot-water bottle and may be reapplied according to the benefit obtained They have no specific effect on the actual recovery of nerve cell lesions

Passive Movements. All joints are moved through a passive range twice daily When movement is restricted by pain or muscle spasm, treatment is increased to four times a day but restricted to the pain-free range The patient should be turned regularly to relieve pain and stiffness, and at least one period a day is spent in the prone position.

Certain patients show a tendency to loss of elasticity of fascial structures which may lead to contraction if not detected in the early stage Particular attention must be paid to the ilio-tibial band and

tion of accumulated secretions leads to anoxia, coma and ultimately death.

Early signs of bulbar involvement include nasal intonation and difficulty in swallowing. Ritchie Russel (1952), emphasizes the importance of a rattling sound with breathing due to respiration bubbling past mucus. This rarely occurs in a conscious patient except with pharyngeal paralysis; it is therefore an important sign which can be recognized by listening to the patient's breathing.

The essentials of treatment in pharyngeal paralysis are prompt diagnosis, immediate postural drainage and aspiration of the throat. Tracheotomy should seldom be necessary unless bilateral abductor paralysis of the vocal cords develops

Correct positioning of the patient is important The patient is nursed in the semi-prone position and turned to the other side every few hours. The foot of the bed should be elevated at least 18 inches

Treatment in Convalescent or Recovery Stage.

This stage begins with the subsidence of the acute symptoms and continues up to the time when no further significant recovery in individual muscle groups is to be expected, i e, approximately 18 months The average patient with lower limb paralysis may spend six months in hospital before he is allowed home with suitable apparatus, while severe spinal paralysis patients may spend one year in the orthopædic hospital.

The aim of treatment in the early stages is to eliminate deforming tendencies, restore joint mobility and to train the co-ordination of recovering muscles. In the later stages the residual muscle power is built up with resistance exercises and the patient is fitted with suitable apparatus to enable treatment to be continued as an outpatient.

Specific treatment is not indicated during the acute stage but may commence 48 hours after the temperature has subsided. Treatment must be delayed when encephalitic signs persist and should be subordinated to the care of acute respiratory complications when necessary.

An approximate estimation of paralysis is recorded and any limitation of passive movement is noted and particularly any tendency to "muscle spasm" A comprehensive examination must not be attempted in the early days as it proves exhausting and depressing for patients with severe paralysis. Muscle charts can be completed at subsequent examinations.

The method of muscle strength recordings as advocated by the M.R C. has certain disadvantages but is sufficiently accurate for treatment purposes

Grade 0 = Complete paralysis
,, 1 = Flicker of contraction
,, 2 = Movement with gravity eliminated, e g, in pool
,, 3 = Movement against gravity
,, 4 = Movement against resistance
,, 5 = Normal muscle power

the resistance to the muscle is increased depending on the degree of recovery. Movement against gravity is increased to movement against resistance either by the hand or by pulleys and weights

In the later recovery stages maximum resistance can be applied to the muscle. With maximum resistance the muscle groups should be exercised in rotation to give a rest interval between contractions.

In the orthopædic hospital two sessions of treatment daily are sufficient. One should be carried out in the physiotherapy department and the other one in the pool This gives variety of surroundings, allows the patient to meet others and maintains his interest in treatment

Physiotherapists should use the Guthrie-Smith suspension sling apparatus This is best constructed by erecting a heavy gauge wire mesh overhead screen from which are suspended canvas slings to support the limbs during exercise periods

Pool Therapy. In the orthopædic hospital the swimming pool is an invaluable aid to treatment The small tank is useful in the early weeks of recovery but more freedom is required during the later stages. Walking is commenced in the large pool and swimming is excellent exercise to improve the overall body tone. Poliomyelitis patients should always be treated in hospitals equipped with a suitable pool.

Apparatus used in Convalescent and Residual Stages.

During the ambulatory stage apparatus may be necessary to protect a weak muscle, prevent deformity or to support the patient. The apparatus may be permanent in severe cases while in others it may be discarded when the patient gains more control or when stabilization of the part is achieved by surgical means

1 Abduction Shoulder Splint The abduction splint for paralysis of the deltoid muscle is seldom indicated. When worn for long periods it may actually delay the recovery of the deltoid and throw an unnecessary strain on the spine Adequate support for the shoulder during the ambulatory recovery stage is obtained by wearing a sling supporting the elbow This allows the patient to use the forearm and hand while protecting the shoulder from the effects of gravity When it is evident that no significant recovery of the deltoid is likely, complete freedom should be encouraged and exercises concentrated on the development of the scapulo-thoracic muscles which will later carry the arthrodesed shoulder

2. "Cock up" Wrist Splint. Light splints to support the wrist are necessary when the extensors are paralysed. "Lively" splints, as advocated by Capener, leave the palm relatively free; individual finger extensions can be incorporated if necessary.

3. Weight-bearing Caliper. In severe paralysis of the hip muscles the body weight may be taken on a padded metal ring and transmitted down the metal side bars to the shoe into which the ends of the appliance fit Stability of the hip through the ischii on the caliper ring will

plantar fascia Regular stretching of tight fascial structures in the early stage is essential if serious contractures are to be eliminated (Fig. 232)

Positioning. Limbs and spine are so positioned as to prevent the stretching of paralysed muscles and the development of any overacting tendency in active muscles.

Spine · Children are nursed on a firm mattress Heavy adults with severe spinal paralysis are more comfortable on a 4-inch Dunlopillo mattress supported by fracture boards Periods in the prone position are important in maintaining tone of the posterior spinal muscles and gluteı

Lowei Limbs · The knees are maintained in slight flexion on a pillow or by a wooden pole placed under the mattress to prevent the tendency to genu recurvation sometimes induced by cot mattresses. The feet are supported by a foot board but felt-padded plaster splints may be applied when indicated to control leg rotation, foot imbalance or to prevent tightness of the plantar structures developing in the cavus type of foot. In severe paralysis of the calf the foot should be placed in slight equinus and stretching of the calf avoided as overstretching of a paralysed calf accentuates calcaneus deformity of the foot

Uppei Limbs · If there is any tendency to muscle spasm when shoulder and arm are involved, position may be maintained by a felt sling under the elbow suspended from an overhead beam. This method is comfortable for the patient, maintains a satisfactory position of all joints and allows passive movement to be carried out with the minimal disturbance. Felt slings are also suitable in the later stages when the patient is allowed to sit up for periods—gentle active movement is possible with the support of slings Felt opponens splints maintain the thumb in opposition and are comfortable for the patient—they are not practical, however, in infants. In maintaining splintage it is emphasized that they should be padded with felt and that regular passive movements of the joints are carried out. Splintage is only used when satisfactory position cannot be achieved or maintained by simpler methods.

Muscle Re-education. The re-education of a muscle establishes better co-ordination between the remaining nerve fibres and enables the patient to obtain the maximum possible contraction When pain and tenderness have subsided the patient concentrates his attention on the attempt to accomplish the desired movement while it is performed passively. It helps co-ordination to get him to perform the same action on the healthy limb. When the muscle becomes capable of spontaneous action it is allowed to contract with gravity eliminated—this is best accomplished in a warm water tank. Underwater therapy is a useful aid to treatment even in the early recovery stage Residual pain and muscle spasm is relieved and back stiffness is more easily overcome. The patient appreciates the greater mobility of water immersion and benefits both psychologically and physically

In the early recovery stage muscle fatigue should be avoided. Later

TREATMENT OF SOFT TISSUE CONTRACTURE

1. Dislocation of the Hip

Paralytic dislocation of the hip is particularly common in infantile paralysis. It follows flexion-deformity, especially that associated with adduction. The relaxation of the joint capsule facilitates dislocation. The dislocation may be incomplete, giving rise to what is known as a "snapping hip." The diagnosis is not difficult, as the head of the femur slips from the socket whenever the leg is adducted The condition causes great lameness, and occasionally much irritability of the joint.

Probably the most important factor in the treatment of these cases is prevention Flexion and adduction should be prevented by conservative methods and these patients should acquire the habit of sitting and sleeping with their knees separated—the abduction being more important than extension in the prevention The best splint is made from two half cuffs of metal joined together by a metal rod, about 12 inches to 18 inches long, attached to the middle of their convex surfaces This is bandaged on nightly to the patient's legs just above the knees In addition to the steps taken to reinforce the paralysed muscles—usually the gluteı—two methods are employed in the treatment of the actual dislocation

(*a*) **Shelving Operation.** If there is any difficulty in reducing the hip, the contracture is relieved by fasciotomy. Thereafter the hip is reduced Through a Smith-Petersen approach a shelf is turned down from the side of the ilium The shelf should be accurately placed on the upper and posterior part of the acetabulum and be of a more massive type than in the operation for congenital dislocation. The actual method is described under the treatment of a congenital dislocation of the hip in Chapter II (page 44).

(*b*) **Arthrodesis.** Arthrodesis may be indicated if it appears certain that a stiff hip will assist locomotion Many of these patients have other deformities and paralyses which would annul the possibility of this benefit, so that careful consideration must be given to each case before an arthrodesis is recommended. In some cases, however, it may be justifiable. The usual method of arthrodesing the hip is carried out as described later.

2. Hip Flexion Contracture

This results from contraction of the tensor fasciæ latæ, the iliopsoas, the sartorius, and the rectus femoris It rarely occurs alone, being frequently associated with adduction of the hip, flexion deformity of the knee, and talipes equinus of the foot. It may be obviated to a certain extent by placing the patient in the prone position for some hours daily during the earlier stages of the disease. Once the deformity has developed, it may be treated in one of two ways—either

enable the patient to bear weight and avoid undue strain on the hip which might otherwise lead to paralytic dislocation.

4. *Below-knee Appliances.* These are used to control mobile foot deformities which result from muscle imbalance.

In infants the foot is best controlled by double below-knee irons with flat sockets inserted into the heel.

In children the irons should have round sockets inserted into the heel. Permanent appliances for adults are made with ankle-joint hinges

Equinus deformity is prevented by adding a toe-raising spring or drop-foot stops to the heel. Anterior check-stops are used for calcaneus deformity.

A valgus foot due to paralysis of the invertors is corrected by an outside iron and an inside "T" strap attached to the shoe. An inverted foot due to peroneal paralysis is corrected by an inside iron and an outside "T" strap (Fig. 233)

5. *Spinal Brace* Adequate support for severe spinal paralysis is difficult to achieve. Paralysis of the abdominal muscles is controlled by an abdominal corset. Mild trunk weakness is treated by a corset into which may be incorporated a light posterior metal frame of the Goldthwaite type.

More extensive trunk weakness with spinal instability or early scoliosis should be supported by a moulded leather jacket constructed from a plaster cast taken with the patient standing under slight traction from a head sling

Advancing scoliosis, particularly in the upper thoracic region, merits the application of a "Milwaukee" distraction brace, provided the paralysis is not otherwise so extensive as to render the wearing of the appliance intolerable or to prevent the patient from walking

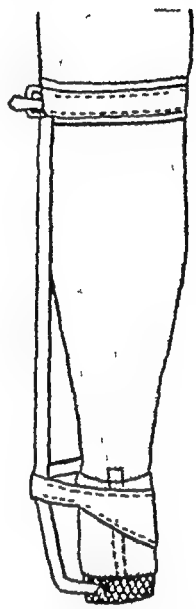

Fig 233. — Poliomyelitis. Medial iron and lateral T strap for use in peroneal paralysis. The strap and iron may be transposed for use in other deformities

Treatment of the Residual Stage.

Treatment of the residual or chronic stage includes regular out-patient supervision of the physical, social and economic problems arising from the disability. Experienced advice is invaluable to the rehabilitation of the patient in suitable employment and in his social environment.

Although recovery of individual muscle power may not show significant increase after 18 months or so, some functional improvement may continue in children as the general musculature and co-ordination improve with growth.

Orthopædic procedures in the residual stage are indicated (*a*) to correct soft tissue contracture, (*b*) to improve function and to prevent deformity by tendon transfer and stabilization procedures, (*c*) to correct inequality of leg length.

fasciæ latæ for about 4 inches The fascia is exposed and divided in a line from the greater trochanter to a point near to the anterior superior spine The muscles are then stripped from the spine subperiosteally by an elevator. The separation extends backwards on both sides of the crest for about 1½ inches, and downwards on the anterior surface of the ilium as far as the anterior inferior spine. The thighs are then extended In most cases the deformity is in this way



Fig 235 —The Schwartz Frame in use in correction of severe Hip Flexion Deformity following Poliomyelitis

completely corrected In more severe cases it may be necessary in addition to divide the ilio-psoas muscle This can be reached in the depth of the wound by following the neck of the femur down to the lesser trochanter after retracting the sartorius medially, and the tensor fasciæ latæ laterally. In still more severe cases, it may be necessary to divide the anterior portion of the capsule of the hip joint. The anterior superior spine and part of the crest of the ilium, left bare in the wound when the thigh is extended, are now cut off flush with the surface and the wound closed

After-Treatment

The patient is placed either on a Schwartz frame or in a plaster spica with the hips hyperextended for two or three weeks until the wound is healed and the muscles have become united to their new attachments

In the early recovery stage deforming tendencies should be noted and corrected by regular stretching supplemented when necessary by padded plaster splints. Early contraction of the ilio-tibial band and plantar fascia of the foot respond to treatment at this stage

When treatment in the convalescent stage has been inadequate, patients may present with established soft tissue contractures which must be overcome before joint mobility can be regained and the remain-

by stretching the paralysed tissues or by division of these structures by open operation. Each method has its advantages and its advocates Stretching is said to be unreliable because of the nervous irritation produced, and because of the local pain. Further it damages other tissues, and may interfere with the circulation. On the other hand, division of a shortened muscle or erasion of its normal origin leaves it very much weakened. The author uses the gradual stretching method in mild contractures, in severe cases and in cases which resist stretching he performs the Soutter type of operation

(*a*) **Gradual Stretching by the Agnes Hunt Method.** In correcting a flexion deformity of the hip by stretching, the compensatory spinal lordosis induced by previous treatment must be overcome. This is effected by the following method:—any lordosis is corrected by flexion of both hips; the spine and unaffected hip and leg are then immobilized in plaster of Paris The affected limb is now fixed in a

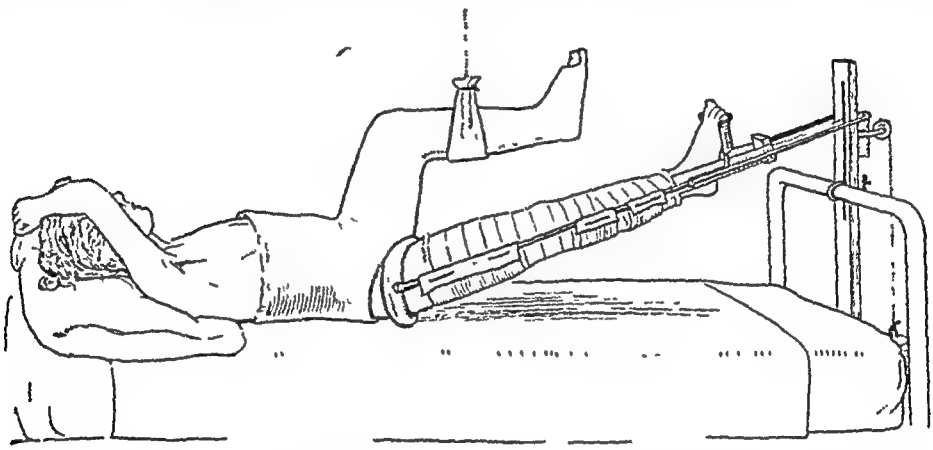

FIG 234 —Poliomyelitis. The Agnes Hunt Plaster Method of correcting Flexion Deformity of the Hip

Thomas's knee splint and traction made on it, the splint being gradually lowered as the tight structures yield to the extension. When the limb has been brought down to the extended position, the plaster is removed. If both hips are contracted, the spine and the corrected limb are then put in plaster and the same corrective measures carried out on the other leg.

(*b*) **Open Division and Fasciotomy.** In certain cases where the above method has failed, it may be necessary to divide the tensor fasciæ latæ. This is followed by manipulation, repeated if necessary, and is frequently attended with very good results.

(*c*) **Soutter's Operation.** By this method, the flexors of the hip are stripped sub-periosteally from their original position, and allowed to slip down the side of the pelvis. This permits of full extension of the hip.

Technique A vertical incision is made from 2 inches above the anterior superior spine downwards along the anterior edge of the tensor

patient is placed on a hinged frame with the hips extended and traction on both legs. Regular stretching of the hip is carried out daily by physiotherapists and this is probably the most important part of the procedure

3. Deformities of the Knee

(*a*) **Flexion Deformity.** This occurs where there is paresis of the anterior thigh muscles with over-action of the posterior group. The deformity can be prevented by the use of a Thomas's knee splint; and frequently this splint may be used also to correct the condition when applied along with plaster traction on the side of the leg.

METHODS OF REDUCTION OF THE ESTABLISHED DEFORMITY

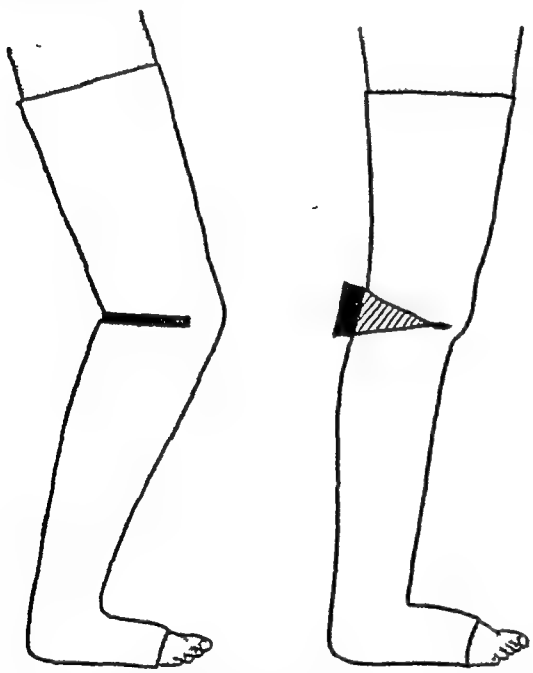

FIG 236 —Poliomyelitis The method of Correcting a Flexion Deformity of the Knee by Wedge Plasters

(*1*) *Wedge Plaster Method.* A circular plaster is applied to the leg from the toes up to the groin in the position of the deformity and allowed to harden A transverse slit is then made through the posterior three-quarters of the plaster at the level of the knee joint. Thin pieces of wood are now inserted into this slit to force it open, the leverage being so favourable that the knee may be straightened out quite quickly An instrument devised on the lines of a rib-spreader is used by the author to force open the divided plaster

(*2*) *Operation — Tendon Lengthening.* This operation may be carried out by a single longitudinal and medial incision in the popliteal space, or by two separate lateral incisions. The semimembranosus, semi-tendinosus, gracilis, and sartorius muscles are lengthened on the medial aspect, and the biceps and tensor fasciæ latæ on the lateral Directly in the line of the incision in the fascia of the popliteal space are the popliteal artery and the common peroneal nerve, at a deeper level is the popliteal vein These structures must be carefully avoided Each of the tendons is lengthened in the usual Z-shaped fashion, and after closing the wound the leg is put up in a straight back splint.

Wilson has recently shown that many of the cases which resist correction by other means can be treated satisfactorily by a capsulo-

ing muscles re-educated. In such cases where conservative methods fail, the deformity must be corrected by operation.

Contracture of the Ilio-tibial Band.

Attention has been drawn to the deforming influences of the ilio-tibial band by Yount (1926) and Irwin (1947). Contractures of this structure are responsible for flexion abduction deformity of the hip and also for obliquity of the pelvis. Bilateral contraction will produce increased lumbar lordosis.

Established contractures of the ilio-tibial band will not respond to conservative measures. Early contractures may be satisfactorily corrected by division of the ilio-tibial band distally as suggested by Yount In flexion abduction contracture of the hip of long standing, division of the ilio-tibial band may be supplemented by Campbell's transference of the crest of the ilium.

(*a*) *Division of the Ilio-tibial Band and Lateral Intermuscular Septum* (Yount) Prior to operation a close-fitting single-hip spica is applied to the sound leg under traction This leaves the affected leg in abduction until the tight ilio-tibial band has been divided—traction is then applied to the affected leg which is stretched daily to maintain the operative correction The fascia lata is exposed through a longitudinal incision The ilio-tibial band is divided between the biceps tendon and the anterior surface of the thigh at a level 1 inch proximal to the patella A 2-inch section is excised from the ilio-tibial band and from the lateral intermuscular septum at this level.

(*b*) *Campbell's Transference of the Crest of the Ilium.* Campbell's modification of Soutter's fasciotomy is a major operation if complete correction of the hip-flexion deformity is to be obtained.

The operation is carried out through a Smith-Petersen incision. The superficial and deep fasciæ are incised over the crest of the ilium to the anterior superior spine. The latter is detached with an osteotome along with a part of the outer table of the crest of the ilium. Along with this piece of bone the entire muscle mass is separated subperiostially until the rim of the acetabulum is reached. The iliacus muscle is detached subperiostially from the inner table of the ilium and the anterior border of the ilium is denuded down to the anterior inferior spinous process. The attachment of the rectus femoris is freed and the reflected head severed along the anterior margin of the acetabulum. If necessary the contracted capsule of the hip joint is divided and in severe cases the iliopsoas muscle is released from the lesser trochanter by tenotomy. Finally the transferred iliac crest is approximated to a prepared tract of bone on the wing of the ilium below the former crest. The deep fascia of the upper edge of the wound is sutured to that of the lower flap bringing the skin incision 1 inch below the edge of the ilium to avoid pressure.

After treatment—a double-plaster hip spica is applied with the hips extended for three weeks, when the plaster is removed and the

anterior half is detached from its insertion into the calcaneus, while at the upper end a transverse incision is made through the posterior half of the tendon. In this way two broad flaps are secured which form broad surfaces for co-aptation after the deformity is corrected. The tendon flaps are sutured with chromic catgut and the foot immobilized in plaster of Paris for six weeks. Before deciding on operative lengthening of the tendo-calcaneus it should be remembered that patients with quadriceps insufficiency may depend on a tight heel cord in the absence of active gastrocnemius contraction to enable the hamstring muscles to lock the knee on a stable foot.

Contracture of the Plantar Fascia.

Persistent contracture of the plantar fascia produces a cavus or cavo-adducted foot. In this type of foot Steindler's stripping operation gives a satisfactory result, although in some cases the operation may have to be repeated in later years.

Steindler's Procedure A horizontal incision 1½ inches long is made over the inner aspect of the calcaneus. The under surface of the plantar fascia is separated from the subcutaneous fatty tissue and is divided close to its origin from the calcaneus. The short muscles of the foot are stripped from the periosteum of the calcaneus and dissection is continued to the calcaneo-cuboid joint to include the ligaments which extend from the calcaneus to the cuboid. Dissection should be carried out under vision and by keeping close to the bone the plantar vessels and nerves will escape injury.

The foot is manipulated and immobilized in plaster for two weeks. Further manipulation is carried out and a second plaster applied for four weeks After-care consists of wearing a plaster night splint and ensuring that regular stretching of the foot is carried out at home.

Tendon Transfer for Regional Deformities.

Tendon transfer to improve muscle balance is most successful in the wrist and hand. In the foot it is more commonly used in conjunction with stabilization operations on the bones.

Certain points in the technique of tendon transfer are of importance :

1. The deformity must be corrected before transplantation is performed. There must be a free range of passive movement in the joints to be activated by the transplanted muscle.
2. The muscle to be transferred must be sufficiently strong to substitute for the paralysed muscle.
3. The transferred tendon must pass in a direct line through subcutaneous fat or through a tendon sheath to avoid friction.
4. The tendon should be inserted into bone through drill holes or subperiostially if possible. In the wrist, however, the flexor tendons are transferred directly into the extensors.
5. The tendon should be attached under moderate tension.
6. Muscles which have similar or related actions give better results.

plasty of the posterior part of the capsule of the knee joint. This tends to be very short in flexion contracture

(*b*) **Knock-knee.** This deformity is often seen as a result of paralysis of the quadriceps and may be due to the stronger pull of the hamstring muscles, and particularly that of the tensor fasciæ latæ. Prophylactic measures should be adopted in cases in which the deformity is likely to develop. In these cases the application of a plaster case may help

Mild cases may be overcome by manipulation and traction, recurrence being prevented by the application of a caliper splint fitted with a knock-knee strap to secure leverage. If knock-knee is greater than 8 degrees, an osteotomy is indicated, and should yield very satisfactory results.

(*c*) **Genu Recurvatum.** This develops in cases of paralysis of the quadriceps, when the patient, fearing that the knee will give way, attempts to make the leg stable by locking the joint in hyperextension before bearing his weight on it. The posterior part of the capsule and the posterior muscles become stretched The prognosis is not good in these cases, but a caliper with a posterior knee strap is a satisfactory form of support, sometimes in addition a Jones's knee brace may be used

Campbell's Operation for Genu Recurvatum. Campbell recently described a bone-check operation in which the patella is used to prevent the occurrence of the deformity. A U-shaped incision round the patella is made with the transverse bar of the U just below the attachment of the ligamentum patellæ The flap is reflected upwards and the patellar ligament and patella exposed. The ligament is completely excised and a raw surface made on the lower end of the patella. A further raw area is similarly prepared on the anterior aspect of the upper end of the tibia, and united to that on the patella, the knee being flexed at 160 degrees After closing the wound the limb is encased in a plaster of Paris spica When satisfactory union has occurred between the patella and the tibia, it will be found that the patella forms a complete check to any hyperextension at the knee joint.

Arthrodesis Cure of the deformity can be effected by this operation, but it is rarely necessary to resort to it.

Contracture of Heel Cord.

Shortening of the tendo-calcaneus may occur from overaction of the calf muscles unopposed by paralysed extensors. In neglected cases the heel cord may require stretching by manipulation followed by wedging plasters In severe cases the tendo-calcaneus may have to be lengthened by open operation and the posterior capsule of the ankle joint divided if contracted The tendon is divided into anterior and posterior halves by a long, lateral, vertical splitting incision. At the lower end the

of the peroneus longus with cocking of the big toe, the tendon of extensor hallucis longus can be transplanted to the first metatarsal and the interphalangeal joint of the hallux is fused

In long-standing deformities in the older patient where passive correction of the subtaloid joint is not possible—triple arthrodesis is the method of choice

Talipes Varus, which is less common, is due to paralysis of the peroneal muscles, the foot becoming inverted by the action of the tibialis anterior and posterior This is a difficult deformity to control by a caliper during the growing years While the foot is still mobile correction may be obtained by a strut graft inserted into the sinus tarsi from the inner side, supplemented by transplantation of the tibialis anterior to the cuboid

Even lateral transplant of the tibialis anterior alone will allow the foot to be more easily controlled by an inside iron and outside " T " strap

Talipes Calcaneus is an inevitable deformity in isolated paralysis of the gastrocnemius. Active dorsiflexors plus active peronei and tibialis posterior muscles produce a progressive calcaneo cavus deformity despite caliper protection.

In the young child the deformity may be minimized by transplantation of the tibialis posterior and peroneal tendons into the heel cord, followed by protection with a caliper.

In the older child transplantation of tendons into the heel cord should be accompanied by triple arthrodesis.

Talipes Equinus Paralytic drop foot is satisfactorily controlled by a caliper with a toe-raising spring or a dorsiflexion spring at the ankle joint. Lambrinudi foot fusion with transplantation of over-acting peronei to the dorsum of the foot is reserved for the older patient.

Clawtoe Deformity of the Hallux Clawtoe is frequently found in paralytic feet The hypertension deformity of the first metatarso-phalangeal joint, which occurs on attempted dorsiflexion of the foot, is caused by unco-ordinated contraction of the extensor hallucis when the tibialis anterior is paralysed The clawing of the hallux increases the depression of the first metatarsal head produced by unopposed action of the peroneus longus

Clawtoe deformity occurring in a foot with adequate dorsiflexion power is satisfactorily treated by interphalangeal fusion of the hallux

Transference of the extensor hallucis tendon to the neck of the first metatarsal accompanied by interphalangeal fusion of the hallux is a satisfactory procedure when the power of dorsiflexion of the foot is only slightly impaired

Transplantation of the extensor hallucis by itself is not satisfactory when dorsiflexion of the foot is weak or where there is a fixed cavus deformity

Knee Joint.

The quadriceps is commonly affected in lower limb paralysis but these patients walk well provided there is adequate power in the hamstrings

7. The tendon should be protected by splinting in the relaxed position for three weeks Careful re-education of the transplanted muscle is essential

Deformities of the Foot.

Transfer of tendons for paralytic foot deformities are usually used in conjunction with stabilizing operations on the bones. Opposing muscle groups must be balanced so that recurrence of deformity can be avoided.

Imbalance between invertors and evertors should always be corrected by tendon transplantation following any stabilization procedure Tendon transplantation alone is not satisfactory.

The opposing action of tibialis anterior and peroneus longus should be kept in mind Tibialis anterior elevates the head of the first metatarsal and supinates the forefoot, while peroneus longus depresses the head of the first metatarsal and pronates the foot

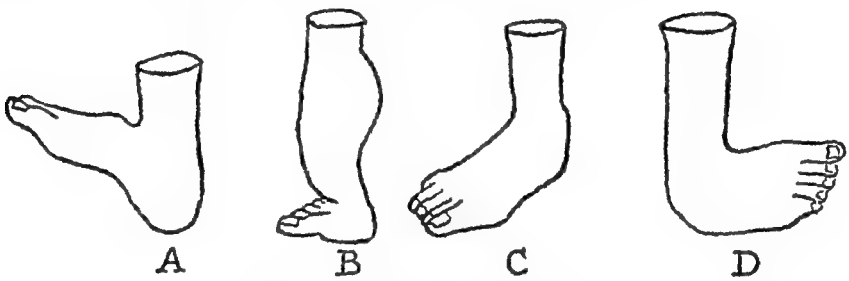

Fig. 237 —Types of Foot Deformity
(A) Talipes calcaneus (C) Talipes valgus
(B) Talipes equinus (D) Talipes varus

Standard procedures involving arthrodesis of both the subtaloid and midtarsal joints should be postponed till the age of 10 or 12 years in order to secure sound fusion and avoid growth disturbance During this period the foot should be protected by a caliper. Marked foot imbalance, however, cannot be completely controlled by a caliper and some structural deformity of the foot is inevitable. While this can be corrected at the definite procedure it will usually entail some loss of shape and height of the foot following bone resection.

The strut graft operation described by Grice has therefore proved of great value in stabilizing the subtaloid joint in young children with paralytic flat foot This procedure, combined with tendon transplantation, will maintain the arch of the foot during the growing years.

Talipes Valgus This results from paralysis of the tibial muscles The calcaneum everts and no longer supports the head of the talus which inclines medially and downwards with depression of the longitudinal arch In children over the age of four the deformity can be corrected by strut-graft stabilization of the talo-calcaneal joint in the corrected position. If the peronei are active the peroneus brevis should be transplanted into the medial cuneiform. In the presence of overaction

spine of the ilium, exposing the fascia over the muscles in this region The fascia is incised longitudinally near the spinous processes and cleared from the muscles The lateral half of the sacro-spinalis, with its aponeurosis, is separated from the medial half and from the muscles lateral to it, the incisions being carried down to the lower end of the skin incision. This portion is then freed from the crest of the ilium, from the sacrum, and from the transverse processes in such a way that a free flap of muscle about 5 inches long, 1 inch wide and $\frac{3}{4}$ inch thick, is obtained An incision is next made on the lateral aspect of the thigh from the tip of the greater trochanter to 1 inch above the level of the patella, exposing the fascia lata and its tensor. The tensor is freed, and parallel incisions made in the fascia to the level of the skin incision

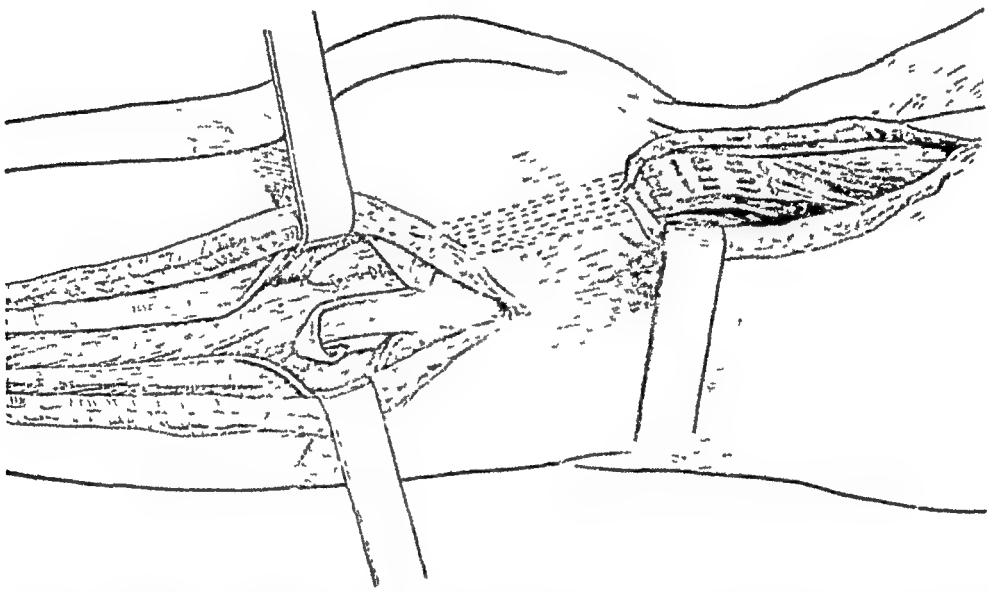

Fig. 238 —Ober's Operation. The active erector spinæ muscle is used to take the place of the paralysed gluteus maximus by transplantation of a strip of fascia latæ.

in order to form a long flap of fascia 1 inch wide. A hole is drilled through the femur at the level of the gluteus maximus tendon just below the neck, and the long flap of fascia is drawn through the bone from before backwards. At that point, the edges of the fascia are sutured to the gluteus maximus tendon The free end of the fascial flap is then drawn up under the gluteal fascia to the lower end of the first incision, care being taken to keep the gliding surface of the fascia next to the iliac bone. The superficial surface of the fascial flap is scarified and then overlapped for 2 or 3 inches by the free flap of the sacro-spinalis. The edges of the fascial flap and the aponeurosis of the sacro-spinalis muscle are then sutured together under moderate tension, so that the extension of the hip is obtained by the sacro-spinalis muscle acting on the femur. A plaster cast is applied with the limb in abduction and full extension for a period of four to six weeks, after which walking exercises may be permitted.

Dickson's Operation. The origin of the tensor fasciæ latæ is transplanted with a piece of its bony attachment to a groove on the crest of the ilium near the posterior superior spine, the muscle thus being changed from an abductor and flexor to an abductor and extensor. Post-operatively the limb is maintained in abduction in a plaster cast which is bivalved at three weeks to commence muscle training.

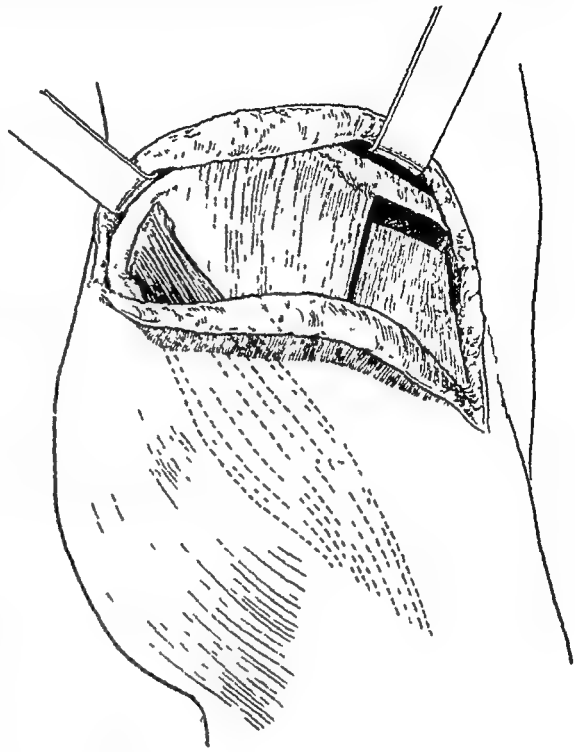

FIG. 239.—Dickson's Operation showing the Method of Transplantation.

(2) Paralysis of the Gluteus Medius Muscle.

The gluteus medius is frequently affected in infantile paralysis. Its function is to abduct the limb, and when the weight is borne on one side to raise the opposite side of the pelvis When the muscle is paralysed, the resulting gait is characteristic When in walking the weight is borne by the affected side, the patient lurches over to that side, with consequent upset of balance. The limp is often indistinguishable from that produced by a short leg, and it cannot be compensated for by any apparatus or by any building up of the sole of the boot. It can, however, be eliminated to a great extent if the patient carries a weight of about 12–14 lb. in the hand of the affected side This changes the centre of gravity and compensates for the weakness of the muscle

Treatment by Legg's Operation The insertion of the tensor fasciæ latæ is transferred to the posterior surface of the femur. An incision is made from the anterior superior spine backwards and downwards over the greater trochanter to a point 3 inches below it. The fascia lata is thus exposed in the anterior part of the wound throughout the full extent of the incision Along this line it is incised and from the lowest point a cross-incision is made backwards for $1\frac{1}{2}$ inches. The posterior border of the tensor fasciæ is then defined, and the entire tendon mobilized. The lateral and posterior surface of the femur is then exposed $2\frac{1}{2}$ inches below the trochanter by dividing the fibres of the vastus lateralis At this point a periosteal flap is turned down from the bone and a groove made Into this groove the free end of the fascia lata bearing the tensor is sutured and the periosteal flap replaced and closed over the groove, the thigh being fixed at 30 degrees abduction. The hip is thereafter retained in a plaster-of-Paris spica

in 30 degrees abduction for about two months. An abduction splint is worn for about six months.

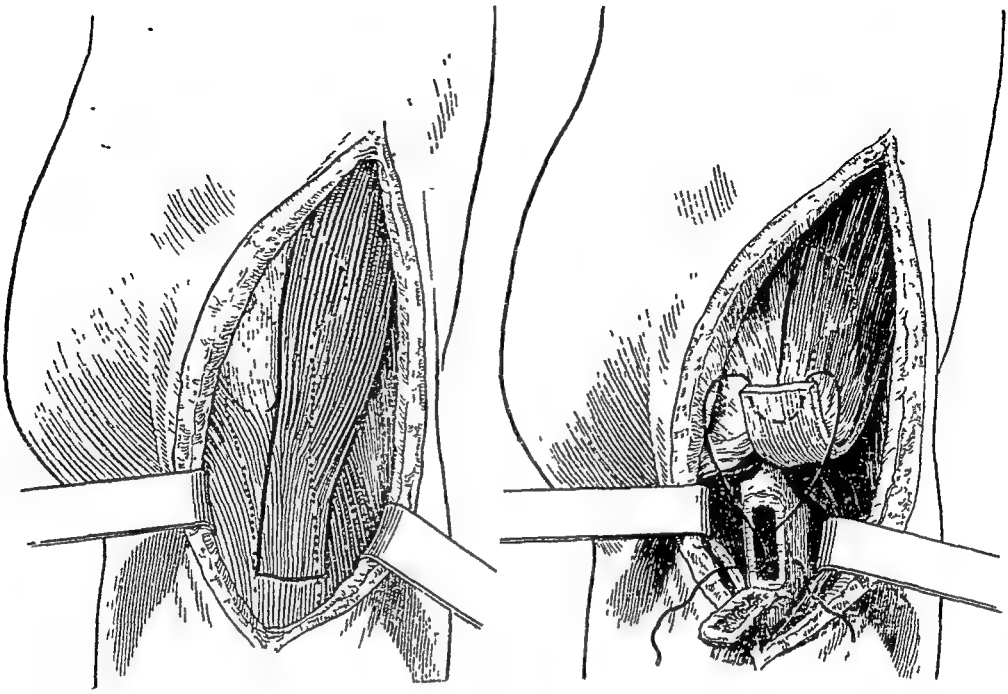

(A) (B)

FIG 240 —Legg's Operation for Gluteal Paralysis (A) The line of division of the tensor fasciæ lata (B) The fixation of the tendon into the femur

The operations should not be performed when there is, in addition, marked involvement of the gluteus maximus

Shoulder.

Paralysis of the deltoid with adequate power in the scapulo-thoracic muscles should be treated by arthrodesis of the shoulder joint after the upper humeral epiphysis has closed. In the interval unrestricted use of the arm is encouraged to maintain tone in the scapular muscles.

Tendon transference to improve abductor power in childhood has been suggested by Mayer using the trapezium muscle and by Ober using the biceps and triceps muscles The results do not justify surgery at an early age and the patient should wait until shoulder fusion can be carried out

Elbow.

Surgery should be confined to restoring flexion at the elbow provided function of the hand is satisfactory Gravity will extend the elbow once flexion is restored , transposition for paralysis of triceps is unlikely to give sufficient power to enable the patient to push up from a chair or to improve crutch walking materially.

Dickson's Operation. The origin of the tensor fasciæ latæ is transplanted with a piece of its bony attachment to a groove on the crest of the ilium near the posterior superior spine, the muscle thus being changed from an abductor and flexor to an abductor and extensor. Post-operatively the limb is maintained in abduction in a plaster cast which is bivalved at three weeks to commence muscle training.

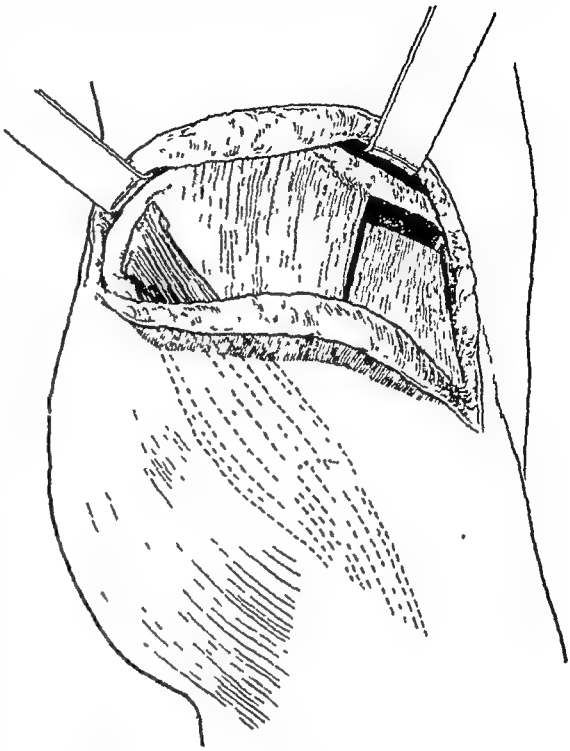

FIG. 239 —Dickson's Operation showing the Method of Transplantation

(2) Paralysis of the Gluteus Medius Muscle.

The gluteus medius is frequently affected in infantile paralysis Its function is to abduct the limb, and when the weight is borne on one side to raise the opposite side of the pelvis When the muscle is paralysed, the resulting gait is characteristic When in walking the weight is borne by the affected side, the patient lurches over to that side, with consequent upset of balance The limp is often indistinguishable from that produced by a short leg, and it cannot be compensated for by any apparatus or by any building up of the sole of the boot It can, however, be eliminated to a great extent if the patient carries a weight of about 12–14 lb in the hand of the affected side This changes the centre of gravity and compensates for the weakness of the muscle

Treatment by Legg's Operation. The insertion of the tensor fasciæ latæ is transferred to the posterior surface of the femur. An incision is made from the anterior superior spine backwards and downwards over the greater trochanter to a point 3 inches below it. The fascia lata is thus exposed in the anterior part of the wound throughout the full extent of the incision Along this line it is incised and from the lowest point a cross-incision is made backwards for $1\frac{1}{2}$ inches. The posterior border of the tensor fasciæ is then defined, and the entire tendon mobilized. The lateral and posterior surface of the femur is then exposed $2\frac{1}{2}$ inches below the trochanter by dividing the fibres of the vastus lateralis. At this point a periosteal flap is turned down from the bone and a groove made Into this groove the free end of the fascia lata bearing the tensor is sutured and the periosteal flap replaced and closed over the groove, the thigh being fixed at 30 degrees abduction The hip is thereafter retained in a plaster-of-Paris spica

The position of the arm is maintained in a dorsal slab which is removed after three weeks but a sling is retained for a further three weeks while the re-education of the muscle is started. At first flexion of the elbow is accompanied by contraction of the undisturbed part of the pectoralis major, but after a variable period independence of the transplant is achieved and a good range of supination may also result.

Forearm.

Loss of pronation of the forearm may be improved by transposing the tendon of flexor carpi ulnaris across the anterior aspect of the forearm to the radial aspect of the distal radius.

Restoration of some degree of supination may be expected if biceps activity is restored as in Clark's transplantation of pectoralis major. Supination may also be improved by transposing the tendon of flexor carpi ulnaris around the ulna and inserting it into the radius just proximal to the wrist.

Wrist and Hand.

The most successful results in tendon transplantation are obtained when the wrist flexors are transferred to the finger extensors, since they normally have a synergic action If care is taken to ensure that the wrist will be balanced after transplantation, supplementary arthrodesis to ensure wrist stability will only occasionally be necessary.

The operations described in the chapter on Injuries of the Peripheral Nerves may be modified to suit the type of paralysis met with in poliomyelitis. It is to be noted that the extensors do not act well when transplanted into the flexors of the forearm.

(*a*) In complete flexor paralysis extensor carpi radialis longus and extensor carpi ulnaris may be transplanted to the tendon of flexor pollicis longus and to the deep flexor tendons of the fingers.

(*b*) In extensor paralysis the operation described by Sir Harold Stiles may be modified to suit individual requirements. The pronator teres is transplanted into the extensor carpi radialis longus and brevis The flexor carpi radialis is inserted into the abductor pollicis longus and the extensor pollicis brevis The palmaris longus is transplanted to extensor pollicis longus The tendon of flexor carpi ulnaris is inserted into the extensor digitorum tendons.

(*c*) Loss of active opposition of the thumb is a common and disabling feature in poliomyelitis The grasp is weakened and the useful pinch action between thumb and index finger is lost. Restoration of opposition is an important step in the recovery of hand function in poliomyelitis. Satisfactory results from tendon transplantation are only possible when full passive movement of the thumb has been maintained, any tendency to web contracture should be overcome before operation

Several methods are described to restore opposition Royle (1938) withdraws the flexor sublimis of the ring finger just distal to the flexor

Steindler's operation of proximal transposition of the common flexor origin from the medial epicondyle gives satisfactory results if normal power is present in the flexors of the wrist and fingers. As brachioradialis is normally a supplementary flexor of the elbow, proximal transposition of the extensor origin may also be carried out when the flexor group is below normal strength.

When biceps, brachialis and brachioradialis are completely paralysed, but good power is present in the pectoralis major, Clark advocates transposition of the pectoralis major to the biceps tendon

Flexor Transposition at the Elbow (Steindler, 1923). The best results are obtained when the brachioradialis is still functioning. Some loss of full extension of the elbow may occur after successful transplants and this should be explained to the patient before operation

An incision is made over the medial aspect of the humerus running distally from 3 inches above the medial epicondyle, passing behind the epicondyle and then forwards over the pronator teres. The ulnar nerve is identified behind the epicondyle and retracted The common flexor origin is detached close to the bone in one mass These muscles are the superficial head of the pronator teres, the flexor carpi radialis, the palmaris longus and the flexor carpi ulnaris They are mobilized downwards for a distance of 1½ inches to the point of entrance of its nerve supply from the median nerve and transplanted to the periosteum of the humerus 2 inches above the epicondyle The muscle mass may be more firmly secured by sutures passing through drill holes in the bone The arm, acutely flexed, is immobilized in plaster midway between pronation and supination for three weeks, after which a back splint is worn in acute flexion for a further three weeks to allow muscle training.

Transposition of Pectoralis Major (Clark, 1946) An incision is made extending from the level of the apex of the axilla distally along the axillary border of pectoralis major to the seventh rib.

The lower third of pectoralis major is separated from the remainder of the muscle and from its origin together with a portion of the sheath of rectus abdominis in continuity with the distal end of the transplant to serve as a tendon.

The transplant is stripped proximally off the ribs and the medial anterior thoracic nerve and its accompanying blood vessels are exposed.

An L-shaped incision is made on the lateral aspect of the lower third of the arm with the horizontal limb across the front of the elbow joint

A space is opened up beneath the deep fascia for the reception of the transplant with a wide diameter for the proximal part of the tunnel to accommodate a considerable mass of muscle without jeopardizing the blood supply

The elbow is flexed to 30 degrees above the right angle and placed in full supination and the aponeurotic extension of the transplant is sutured to the biceps tendon

and secured by the insertion of a Smith-Petersen pin after excision of the articular surfaces Excessive abduction should be avoided, otherwise symptoms may arise from scapular contact or shoulder drag, particularly when the trapezius has been slightly affected Fusion at 60 degrees abduction gives a useful shoulder with strong scapulo-thoracic muscles· fusion between 45 and 60 degrees should be accepted if these muscles are below normal. The shoulder should be fused with

Fig 241 —Result of Shoulder Fusion for Paralysed Deltoid.

the elbow joint on the same plane as the anterior surface of the body and with the forearm slightly above the horizontal, corresponding to slight lateral rotation of the humerus

The plaster may be changed in one month's time and a fresh plaster applied until there is radiographic evidence of fusion It is wiser to retain plaster protection for at least four months as X-rays are difficult to interpret When considered fused the shoulder should be protected by an abduction splint during the initial mobilization.

Stabilizing Operations on the Foot.

Various stabilizing operations are carried out with success on the foot It has already been mentioned that tendon transplantation alone is seldom satisfactory but when combined with one or other of the stabilizing procedures greatly improved function can be anticipated

Triple arthrodesis, i e operations involving the talo-calcanean, talo-navicular and calcaneo-cuboid joints, ensures lateral stability and with modifications will correct varus, valgus and calcaneo-cavus deformities The Lambrinudi triple arthrodesis is designed to limit plantar flexion

retinaculum and re-directs the tendon across the palm to be inserted into the base of the proximal phalanx of the thumb.

Bunnel (1938) uses flexor sublimis but passes the tendon round a pulley at the pisiform. Bunnel emphasizes two principles · (1) the tendon must pass from its insertion into the thumb subcutaneously in a direct line to the pisiform bone so that the thumb may be angulated forwards and towards the ulna, (2) the tendon must be attached to the dorsi ulnar aspect of the base of the proximal phalanx of the thumb to restore pronation.

Technique—Bunnel. An L-shaped incision is made along the distal flexor crease at the wrist to the pisiform bone and continued proximally in line with the flexor carpi ulnaris for 3 inches.

Through a small incision in the metacarpo phalangeal crease of the ring finger, the slips of sublimis tendon are divided and the proximal portion withdrawn from the wrist incision.

A pulley is constructed at the pisiform bone using half the thickness of flexor carpi ulnaris which is sutured to the pisiform bone The motor sublimis tendon is passed round flexor carpi ulnaris before passing through the pulley, thus utilizing flexor carpi ulnaris to aid the motor tendon.

An incision is made over the metacarpo phalangeal joint of the thumb, the motor tendon is passed through a subcutaneous tunnel across the thenar eminence and secured to the ulnar border of the base of the proximal phalanx.

The tendon is sutured under moderate tension with the wrist flexed and the thumb in full abduction. This position is maintained by a plaster splint for three weeks, when muscle re-education is commenced.

OPERATIONS TO INCREASE STABILITY OF A JOINT

Arthrodesis is frequently carried out to improve function of the shoulder and foot in poliomyelitis. Satisfactory results are obtained when the correct technique is observed in suitable cases

Arthrodesis of the elbow, hip and knee are seldom indicated. Arthrodesis of the wrist is occasionally required to supplement tendon transplantation.

Arthrodesis of the Shoulder.

Shoulder fusion is indicated in deltoid paralysis when the trapezius and serratus anterior are sufficiently strong to rotate the scapula and thereby abduct the arm. Operation should be postponed until closure of the upper humeral epiphysis.

The technique of the operation is described in Chapter XIX but intra-articular fixation is preferred because the joint is often underdeveloped and fixation maintains the desired abduction during the healing phase

The precise angle of abduction should be determined before operation

surgeon has gained experience of this procedure, it is safer to cut the grafts slightly longer than is indicated by the osteotome as they can then be removed and trimmed until a perfect fit is obtained Correct tension of the grafts prevents displacement and accelerates healing

After operation the foot is immobilized in a long leg plaster In three months the grafts are soundly healed but tendon transplantation

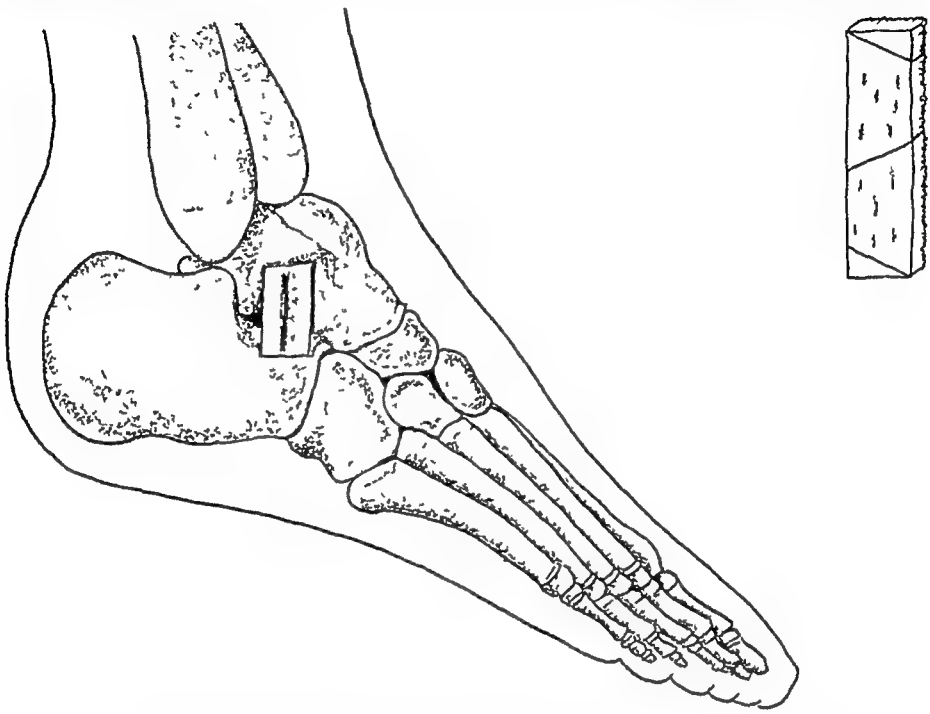

Fig 242 —The Grice Extra-articular Operation (After Grice)

may be carried out at six weeks if the indications are clear. Either peroneus longus or peroneus brevis can be transplanted to the inner side of the foot In doubtful cases tendon transplantation can be postponed until the foot is fully mobilized and a more accurate assessment of function is possible. Residual tightness of the heel cord sometimes gives an awkward gait in the early mobilization phase, if significant, this should be corrected by equinus wedging plasters.

Should the grafts displace after operation, fresh grafts should be inserted one month later.

Triple Arthrodesis.

Fusion of the subtalar and midtarsal joints is indicated when deformity or instability of the foot is accompanied by lateral stability of the talus in the ankle mortise Varus and valgus deformities are corrected by excising appropriate wedges of bone from the midtarsal and subtalar joints. A varus heel must be avoided, a slightly valgus heel gives a satisfactory result. At the time of operation the foot should be aligned in relation to the ankle joint Deformities such as knock-knee and tibial torsion should be corrected at the site of deformity.

If the foot is flail it is desirable to move the fulcrum of the ankle

Foot fusion operations should be postponed till the age of 10–12 years. Fusion at an earlier age may be necessary if deformities are severe but where possible should be delayed to avoid disturbance of growth and ensure more certain fusion and lasting correction.

Extra-articular arthrodesis has been suggested by Grice (1952) to stabilize the talo-calcaneal joint in paralytic flat foot in children. It has proved of great value and is successfully carried out in young children where it preserves the architectural shape of the foot throughout the growing years

Extra-articular Arthrodesis of the Subtaloid Joint (Grice).

Grice points out that in paralytic flat foot the calcaneus is everted and displaced laterally and posteriorly in relation to the talus. As a consequence there is loss of normal support beneath the head of the talus which drops into equinus and deviates medially in relation to the abducted forefoot. If the deformity persists, secondary adaptive changes take place in the joint capsules, tendo-achillis and in the osseus structure.

It is desirable to correct this deformity in the young child before it has become fixed and the operative technique should not therefore interfere with the subsequent growth of the foot.

Surgical correction entails the reduction and maintenance of the calcaneus in normal relationship to the talus by means of strut bone grafts placed in the sinus tarsi. Muscle balance is restored by tendon transplantation to avoid recurrence

Operative technique A short curved incision is made over the lateral aspect of the subtalar joint. The short toe extensors are reflected forwards, the cruciate ligament divided and the sinus tarsi dissected free of adipose tissue and ligamentous structures With the foot in equinus the calcaneus can usually be replaced under the talus by inverting the foot It may sometimes be necessary to divide the posterior capsule of the subtalar joint or to remove a small amount of bone from the under aspect of the head of the talus to restore correct alignment.

An osteotome of suitable width is inserted into the sinus tarsi to test stability and to determine the size of the grafts and the most suitable site for their insertion The sinus tarsi is prepared for the grafts by removal of a thin layer of cortical bone but a rim of intact cortex should be left at the lateral surfaces to hold the notched portions of the grafts when they are counter-sunk

Grafts approximately 2 to 2 5 cm long and 1 5 cm wide are cut from one piece of cortical bone obtained from the bone bank or the patient's tibia These grafts are fashioned to a wedge shape and the corners of the base rongeured away to allow counter-sinking. (See Fig. 242)

The grafts are inserted while the foot is over-corrected so that in the corrected position the grafts are firmly held under tension and the foot is stable. An inverted position of the heel must be avoided. Until the

The foot is displaced backwards at the sub-taloid joint so that the head of the talus will rest in a cup-shaped depression prepared for it by the removal of bone from the dorsal surface of the cuneiform bones In some cases a transplantation of tendons or a tenodesis is now carried out The extensor digitorum brevis is replaced and fixed by catgut stitches and the peroneal tendons sutured if previously divided The opposing bone surfaces should be broken up by an osteotome and any spaces packed with cancellous chips. A more secure fixation may be obtained by a stainless steel staple across the calcaneo-cuboid joint With the foot held in a good weight-bearing position, and with the raw bone surfaces adequately apposed, the whole is fixed in plaster of Paris Gauze applied over the wound should not encircle the foot as this might subsequently constrict the circulation The plaster should be split and the foot elevated for 48 hours during

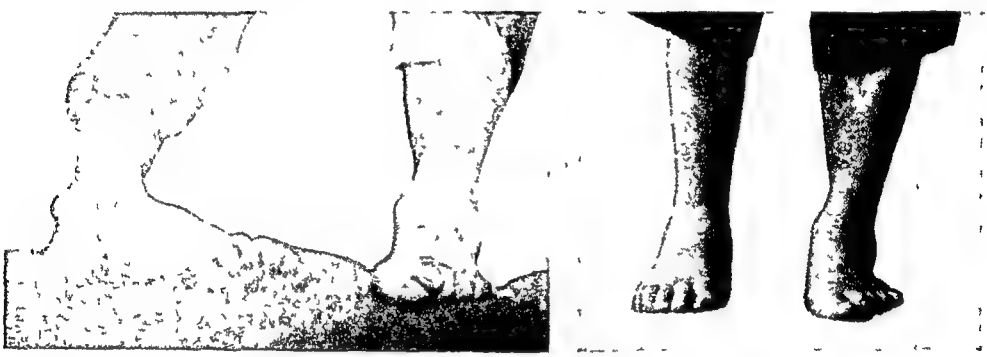

(A) (B)

FIG 244 —Poliomyelitis (A) Talipes equino-varus with callosities on the lateral surface where weight is borne (B) The result of a Naughton Dunn operation in the same case

which period a close watch is maintained for circulatory insufficiency. The position of fixation of the foot is of great importance. The talus and calcaneus are directly centred under the bones of the leg The relation of the forepart of the foot to the posterior segment allows restoration of the normal arch and weight-bearing with both the first and fifth metatarsal heads The plaster is changed three weeks after the operation when the alignment is changed if necessary Weight-bearing should be avoided during the first two months and then a walking plaster is used for a further two months During the early months of mobilization the foot should be protected by a below-knee caliper.

Lambrinudi's Operation. The special indications of this operation according to Fitzgerald and Seddon are paralysis of the foot dorsiflexors and peroneı, but with some muscular control of the knee and preferably with active calf muscles The aim of the operation is to use the anterior process of the talus to prevent dropping of the foot The plane of bone section is carefully planned before the operation

nearer the centre of the foot. This can be accomplished by the technique of Dunn where the foot is moved backwards at the subtalar joint after removal of the navicular.

In paralytic drop-foot, the Lambrinudi fusion corrects the equinus at the subtalar joint by part excision of the talus and stabilization of the foot in a functional position Paralytic drop-foot may also be corrected by the Campbell posterior bone block and foot fusion.

A two-stage fusion at the midtarsal and subtalar joints with transplantation of the peronei and tibialis posterior tendons into the heel (Elmslie, 1934) is a satisfactory procedure and gives a stable foot with some increase in the power of push off.

The Naughton Dunn Operation. In those deformities of the foot in which, because of severe static deficiencies, it is desirable to secure forward displacement of the talus on the calcaneus the operation of Naughton Dunn is indicated. This operation combines with a subtaloid arthrodesis a reconstructive shortening of the forefoot. A degree of symmetry between the two halves of the longitudinal arch is thus established, so that the static condition of the foot is improved

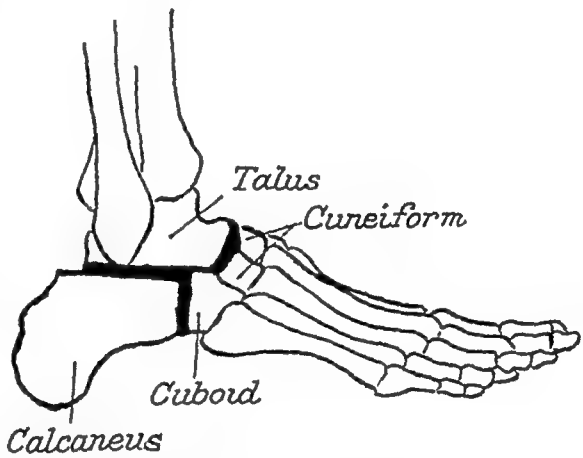

Fig 243.—Naughton Dunn's Operation for stabilization of the flail foot

Technique A straight incision is made extending from above and behind the lateral malleolus, down to the lateral aspect of the head of the fifth metatarsal bone. After reflexion of the edges the origin of the extensor digitorum brevis is detached from the dorsal aspect of the calcaneus and reflected with the soft structures to the dorsum, so exposing the tarsal bones. The calcaneo-cuboid joint is now exposed by retracting or dividing the peroneal tendons The articular surfaces of the calcaneus and cuboid are now removed by means of a sharp osteotome. The amount of bone removed depends upon the deformity to be corrected The head of the talus is now divided behind its articular cartilage, and this, along with the proximal surfaces of the cuneiform bones, is removed together with the whole, or a portion, of the navicular. The strong interosseous ligament between the talus and the calcaneus and the lateral ligaments of the ankle are divided, and the foot dislocated medially at the sub-taloid and mid-tarsal joints. This exposes the sub-taloid joint, the cartilaginous opposing surfaces of which are removed by an osteotome.

Naughton Dunn points out that the foot is now in three sections and that the removal of bone will allow correction of the deformity.

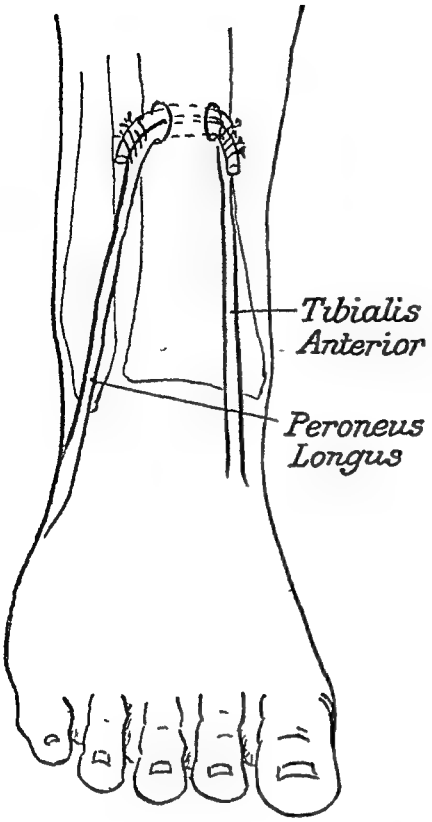

FIG 246 —Paralysis of the Foot Extensors Operation of tendon fixation

The peroneus longus is transposed in front of the lateral malleolus and along with the tibialis anterior slings the foot up to the front of the tibia

Campbell's Operation for Drop-foot. This procedure checks the foot drop by a posterior bone block and is usually combined with a sub-talar arthrodesis. The results of bone block operation are uncertain and often fail owing to absorption or hypertrophy of the bone block.

TECHNIQUE. An incision is made over the antero-lateral surface of the ankle from a point 1 inch above the joint and over the dorsum of the foot to the lateral cuneiform The bones are exposed by reflecting the tendons medially and laterally, good access being gained thus to the entire tarsal region. A small portion of the head of the talus, the whole of the navicular, and the articular cartilages from the posterior surfaces of the cuneiform are resected. A second incision is now made over the tendo-calcaneus, which is divided into anterior and posterior flaps. These are retracted upwards and downwards. The space between the tendon and the tibia is now freed from loose tissue and, with a large periosteal elevator, the posterior surface of the tibia and the upper surface of the calcaneus are cleared The foot is now dorsiflexed and the posterior edge of the body of the talus removed. A wedge-shaped cavity is now chiselled out of the calcaneus, just below the posterior extremity of the talus, and into this cavity the denuded navicular and the small pieces of bone obtained in the first part of the operation are placed and piled into a pyramidal mass which rises well above the posterior edge of the tibia The tendo-calcaneus is

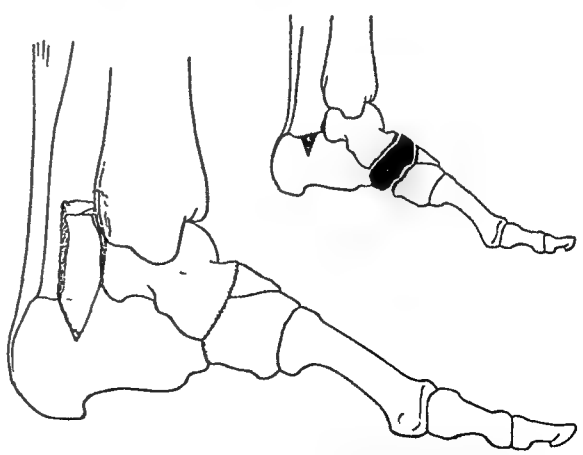

FIG. 247 —Poliomyelitis Campbell's wedge block stabilizing Operation for Dropfoot

The tarsus is approached through a lateral incision and the foot is dislocated medially below the talus. The talus is then cut by a saw in the desired plane as shown in the line drawing The upper surface of the calcaneus and the calcaneo-cuboid joint are cut with a sharp osteotome. The navicular is cut so as to make a postero-inferior notch The bones are now apposed and the beak in the talus fitted into the notch in the navicular, and held in place while the incision is closed and a leg plaster applied The foot and leg are, of course, elevated after the operation, and in two weeks the plaster is removed and a new closely fitting one applied for five months

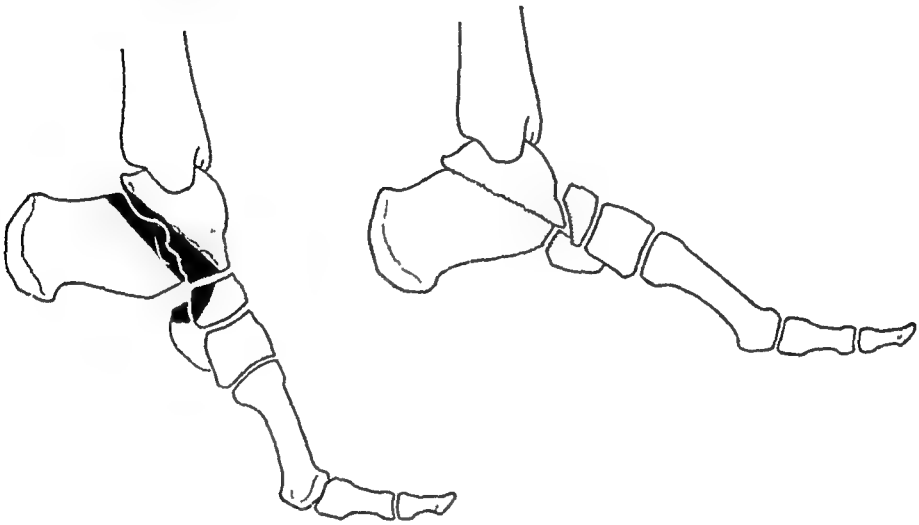

FIG 245 —Lambrinudi's Operation for Drop-foot

In estimating the exact line of section of the bones, the surgeon can make paper tracings from the X-rays before operation The tracing is divided into three components which are then fitted together to give a plantigrade foot The overlap of the tracings indicate the precise amount of bone to be excised at operation

The early results of the Lambrinudi operation are very satisfactory but unfortunately the foot tends to drop further in later years. The author therefore prefers to postpone this procedure until the patient is over 18 years of age as the foot can be adequately controlled by an appliance during the earlier years The foot should be fused in only a few degrees of equinus

To counteract the subsequent dropping of the foot, Barr (1949) advocates tenodesis of the tibialis anterior and peroneus longus to the tibia. The peroneus longus tendon is divided about 3 inches above the lateral malleolus, the free end of the tendon is drawn downwards into the incision through which the triple arthrodesis is done and re-directed upward in the anterior compartment to be attached to the tibia along with the anterior tibial tendon in such a way that the two tendons act as a sling for the foot

Second Stage. A vertical incision is made along the inner border of the tendo-achilles The peroneal tendons and the tendon of tibialis posterior are divided on the lateral and medial aspects of the foot and withdrawn through the posterior wound. The long flexors of the toes are also used if they are sufficiently powerful. A wedge of bone is removed from the subtalar joint in order to correct the calcaneus deformity. With the deformity corrected and the foot in equinus the tendons are transplanted into the tendo-achilles and where possible they are continued through the tendon to be inserted into a large drill hole in the calcaneus. The foot is immobilized in plantar flexion for three to four months

It may assist the surgeon if paper tracings are made from the pre-operative radiographs These are cut into the three components and thus the correct size of the bony wedges to be removed can be ascertained

Inequality of Length of the Lower Extremities.

Significant muscle paralysis in the lower limb is almost always accompanied by some degree of shortening The degree of paralysis bears some relationship to the final amount of shortening in that those with severe paralysis are likely to have greater shortening than those with slight paralysis. It is impossible, however, to give an accurate prognosis of the final shortening to be expected in any one patient

While routine clinical measurement by the same surgeon gives a reasonable idea of the progress of shortening, periodic radiographic measurement is essential for an accurate recording or when contemplating leg equalization procedures.

The following observations are made from radiographic analysis of patients with paralysis confined to one limb (Ratliff, 1957). The greatest shortening is to be expected in patients affected at about the age of three years The maximum shortening is unlikely to exceed 3½ inches Both the tibia and the femur are usually involved and the disparity appears soon after the illness. In general the shortening in the more severe group tends to be progressive but in the milder group the shortening may progress to 1 inch or 1½ inches over a few years and then remain constant Reduction of discrepancy is not to be expected.

Leg Equalization.

Equalization of the lower extremities may be achieved either by lengthening the affected limb or by shortening the sound limb

Leg lengthening has the advantage that surgery is confined to the affected limb There are, however, certain contra-indications to leg lengthening and the procedure is not advised unless the surgeon has personal experience of the operative technique and after-care

Leg shortening has the disadvantage of subjecting the sound leg to surgery and of reducing the patient's height when the discrepancy is marked. It is, however, a simpler and safer procedure and for this

united and the wound closed. The foot is now immobilized at a right angle or in slight plantar flexion in a plaster-of-Paris case and remains in this for at least three months. At the end of that time a strong boot with a lengthened upper should be worn.

Two-stage Fusion for Calcaneo Cavus Deformity.

First Stage Tight structures are released from the heel by a Steindler's stripping. Through a longitudinal incision on the dorsum

(*a*)

(*b*)

FIG. 248 —Calcaneo Cavus Deformity of the Foot treated by Mid-tarsal and Subtalar Correction, supplemented by Transplanting the Tibialis Posterior and the Peroneal to the Os Calcis

of the foot a wedge is excised from the midtarsal joint and the alignment of the forefoot corrected on the hind foot The foot is then immobilized in plaster in maximum dorsiflexion for one month.

joint and the osteotomy cut carried through into the tibia. Fibular fragments are inserted across the gap to promote union of fibula to tibia (Fig. 249)

If there is marked equinus of the foot due to tightness of the tendo-achillis the heel cord should be lengthened and the posterior capsule of the ankle joint divided at the first-stage procedure.

The second stage may be carried out approximately two months later. Two pairs of tibial transfixion pins are inserted into the tibia with the aid of a guide at intervals corresponding to the apertures in

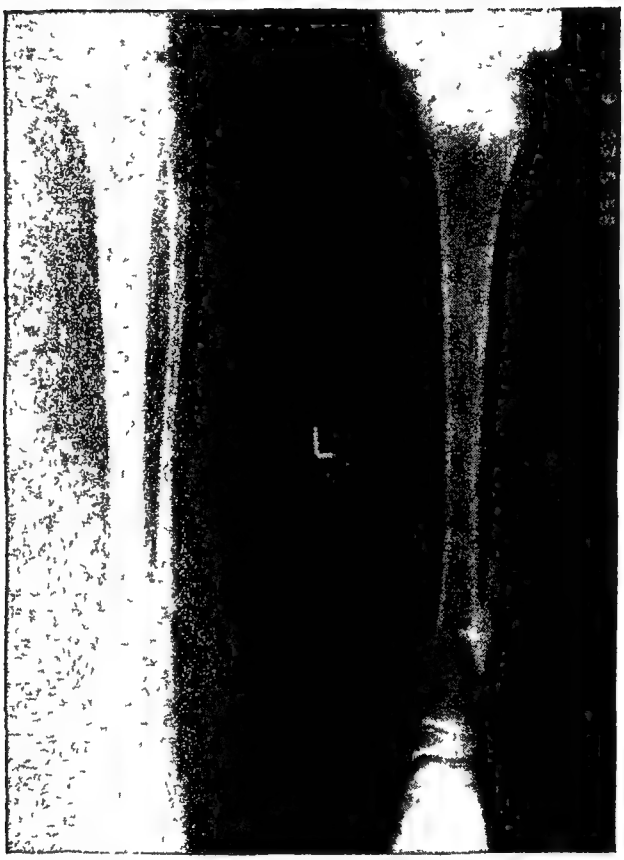

Fig 249 —First-stage Leg Lengthening. Fusion of the Lower Fibula to Tibia

the pin-holding blocks of the lengthening apparatus The apparatus is then fitted to the transfixion pins and the nuts tightened, keeping the side bars of the apparatus parallel and the transverse connecting bar in correct rotation A longitudinal incision is made over the subcutaneous border of the tibia and carried down to bone with reflection of the periosteum which is divided completely around the circumference of the tibia in the upper third of the wound. The tibia is divided longitudinally by a motor saw into anterior and posterior sections approximately 3 inches long A "Z" division is completed by dividing the upper posterior tibial cortex with a Gigli saw and the lower anterior cortex with the motor saw. The fibula is divided at the second-stage

reason is more widely practised. Leg shortening is achieved either by bone resection after growth has ceased or by epiphyseal arrest in childhood

The choice of the most suitable procedure in any given case will be influenced by the surgeon's personal experience but will also depend on various factors related to the shortening.

Leg Lengthening.

Leg lengthening is a procedure which should not be undertaken lightly. The potential complications due to faulty selection of cases or failures in the technique are considerable. There is, however, a definite place for lengthening of the affected limb in suitably chosen cases The technique described has been evolved at the Princess Margaret Rose Hospital over the past 25 years and is modified from the original work of L C. Abbott in 1927

Selection of Cases. Patients with 2 inches or more of shortening may be considered for leg lengthening if the leg is flail or the foot already unbalanced. Each case is considered individually and the choice of lengthening the affected limb or shortening the sound limb fully discussed with the parents Female patients in particular are grateful for discarding a cumbersome and unsightly high boot even if they still have to wear a caliper.

Leg lengthening should be proceeded with as early as possible; the younger the patient the easier the procedure and the better the results. Lengthening should preferably be carried out between the ages of 10–14 years and not over 18 years. The writer limits tibial lengthening to 2 inches in order to reduce the risk of complications but recognizes that greater lengthening can be achieved When lengthening is to be limited to 2 inches, the operation can be carried out whenever that disparity is evident rather than waiting for the final growth period

If shortening exceeds 3 inches, the affected leg may be lengthened by 2 inches and the sound leg subsequently shortened so that a shoe raise can be abolished without serious loss of the patient's height.

A definite contra-indication to tibial lengthening is the patient with a balanced foot despite involvement of the leg muscles Tibial lengthening in such cases will upset the muscle balance and produce a foot deformity which will require stabilization Shortening accompanied by a balanced foot should therefore be compensated by shortening the sound limb.

Technique. Lengthening of the tibia is preferred to femoral lengthening which is a more difficult procedure and liable to cause arthritic changes in the knee joint Tibial lengthening is carried out in two stages. At the first stage the lower fibula is united to the tibia so that when the leg is lengthened at the second stage, the ankle mortise will remain stable—the lateral malleolus moving down with the lower tibia. The fibula is divided through a lateral approach just above the ankle

progress of lengthening can be measured. The lengthening apparatus is suspended from an overhead beam with the foot supported by an upright foot piece (Figs 250, 251).

POST-OPERATIVE TREATMENT. Lengthening should not be continued until approximately the fourth post-operative day. Lengthening should then never exceed $\frac{1}{16}$ inch in the one day. The threads of the apparatus must be constructed so that one whole turn of the adjusting nuts will equal an advance of $\frac{1}{16}$ inch. Lengthening is achieved by turning the adjusting nuts by one half-turn twice a day which equals progress of $\frac{1}{16}$ inch per day—to exceed this speed is to invite complications If the lengthening has to be temporarily slowed down for any reason, e.g. pain or suspected nerve stretch, that delay must never be made up subsequently by exceeding the $\frac{1}{16}$ inch on any one day.

FIG 252 —Tibial Lengthening of 2¼ inches, showing Union five months after operation First stage lower fibula fused to tibia Second stage "Z" section of tibia and transverse section of fibula

Lengthening will be achieved in approximately five to six weeks. The exact length achieved is measured on the apparatus and checked on the X-ray, e g , 2 inches equals 32 screw threads. The apparatus is left in position until there is radiographic evidence of ossifying callus at the distraction sites The apparatus is then removed, leaving the tibial transfixion pins *in situ* and the leg immobilized in a long leg plaster which incorporates the pins

The leg plaster, which is usually applied two to three months after operation, is changed in about six weeks when the tibial transfixion pins are removed and a fresh plaster applied. Weight-bearing is encouraged in a close-fitting plaster and continued until both clinical and radiographic union are established When the leg is firmly united the patient is admitted to hospital for non-weight-bearing exercises to loosen the foot and restore the synovial circulation to articular cartilage before full weight is borne.

COMPLICATIONS.

(1) Nerve complications are always due to too rapid stretching If the recommended routine is followed, lengthening will usually proceed without such a complication. Occasionally, however, the patient may complain of pain in the leg or a slight sensation of numbness over the dorsum of the foot In such cases, the lengthening is temporarily stopped or slowed down with relief of symptoms. Every patient should

operation either through the wound used for section of the tibia or through a separate lateral incision. The adjusting nuts of the lengthening apparatus are now turned to produce an initial distraction of just



Fig 250 —Pin Transfixion Guide for Leg-lengthening Apparatus



(a)

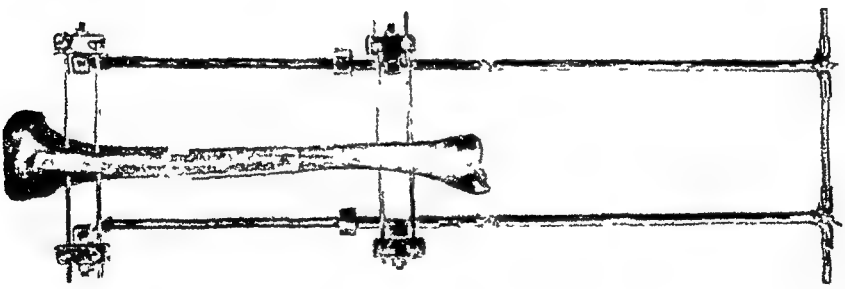

(b)

Fig 251 —Tibial Lengthening Apparatus

under $\frac{1}{4}$ inch. The periosteum is sutured, the skin wound closed by interrupted sutures and the leg bandaged over layers of cotton wool. A strip of adhesive strapping round the threads of the lengthening apparatus marks the original position of the adjusting nuts so that the

be regularly examined for any slight sensory disturbance and due attention paid to any complaint.

(2) Disturbance of circulation is not a complication of a careful lengthening technique Swelling of the leg may require protection with elastic stockings during the early mobilization phase but is not permanent.

(3) Infection of the main wound should not occur but some infection around the transfixion pin tracks does occur but this remains localized and clears after removal of the pins

(4) Protrusion of the anterior tibial fragment through the wound has been listed as a complication but does not occur with a careful technique. In the lengthening apparatus illustrated the transfixation-pin holding blocks can be rotated to correct tilting of the tibial fragments

(5) Deformities of the foot occur during the lengthening process. Some equinus plus varus or valgus depending on the muscle imbalance is inevitable. These deformities are gradually corrected when the plaster is changed by manipulation or wedging of the plaster Residual foot deformity is corrected by the appropriate stabilization procedures. Again it is emphasized that leg lengthening is contra-indicated in a poliomyelitis patient when the foot is balanced

(6) Arthritis of the ankle joint from pressure during lengthening should be avoided (*a*) if lengthening is confined to 2 inches, (*b*) elongation of the tendo-achillis is carried out for marked tightness, and (*c*) when an adequate period of non-weight-bearing mobilization is allowed to restore free-ankle joint movement

Leg Shortening.

Shortening may be achieved by epiphyseal arrest or by resection of bone from the tibia or femur The indications for leg shortening are . (1) Discrepancy of leg length insufficient to justify the lengthening procedure, e.g $\frac{3}{4}$ to $1\frac{3}{4}$ inches approximately. (2) Discrepancy of 2 inches or more when the patient is over 18 years of age or when the foot on the paralysed side is balanced (3) Personal objection to lengthening procedure by the surgeon or parents. (4) As a supplement to leg lengthening when shortening is of the order of 3 inches or more

The writer's preference is for leg shortening by bone resection at the end of the growth phase Shortening by bone resection should not exceed $2\frac{1}{2}$ inches in the femur and $1\frac{1}{2}$ inches in the tibia No difficulty is experienced in regaining muscle tone with the aid of adequate physiotherapy. This enables accurate correction of the discrepancy and avoids any growth disturbances due to unequal epiphyseal arrest. It must be stated, however, that epiphyseal arrest is a well-recognized procedure in which complications can be avoided by a careful technique

Arrest of Epiphyseal Growth. Estimation of the probable effect of epiphyseal arrest at the upper tibial and lower femoral epiphysis may be judged from the tables prepared by Green, Anderson (1947) This information should be supplemented by the height for age of the

The value of this classification is increased if the extent of the involvement is specified, e.g., hemiplegia, triplegia, etc, and if, when possible, the cause is indicated

The spastic child is a stiff child because of the marked increase in muscle tone produced by an upper motor neuron lesion rendering every movement one of extreme effort. A lesion of the motor system at any point between the cerebral motor cortex and the anterior horn cells will produce these features and the related exaggeration of the deep reflexes, the presence of an ankle and patellar clonus and, most important of all, a stretch reflex. Phelps claims that this latter is the clinical sign *par excellence* of the spastic.

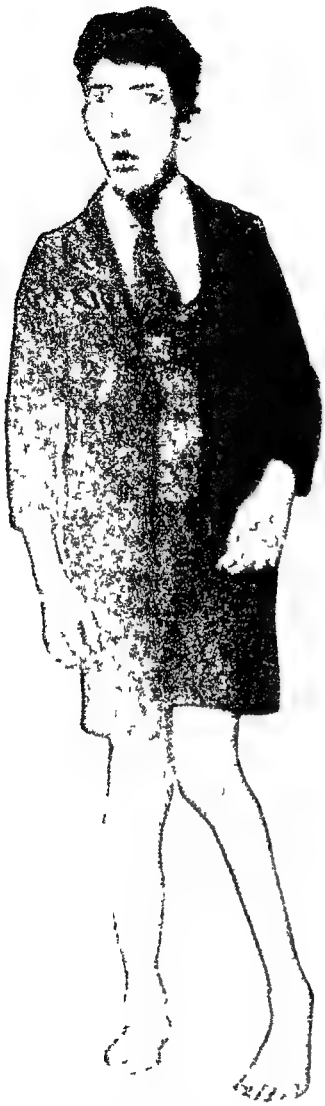

Fig. 253 — Cerebral Palsy The typical gait and expression of a case of moderate degree

It is frequently stated that the spastic child is an introvert and that he is most conscious of, and hypersensitive in regard to, his disabilities While this may be so, one other popular impression is definitely false that he is anti-social. All cerebral palsied children crave affection and for the most part return it abundantly. If the spastic child is less demonstrative it is because excitement and emotional stimulation tend to increase muscle tone, and any sudden excess in response to an affectionate gesture may provoke mass spasm and give rise to pain. It is for this reason, and to avoid painful muscle spasm, that he may appear stand-offish.

Athetosis is the term applied to the incoordinate, involuntary, and largely uncontrollable movements which occur in the fingers and toes of certain cerebral palsied children Where these movements spread to the upper and lower limbs choreoathetosis is the term used to describe the clinical state of mobile spasm, and when the body is affected also so that the child postures or assumes rapidly changing attitudes. American workers describe the state as dystonic, i.e, like the torsion spasm of dystonia musculorum deformans.

The movements in the fingers may be slow or fast, gross or fine, and always become more obvious when an attempt is made to perform some purposeful digital activity.

When limbs flail about in an erratic purposeless movement, the con-

The shaft of the femur is exposed through a lateral approach and the periosteum incised and retracted over the middle third of the bone Drill holes are made through the shaft of the femur in the proposed line of bone section which should run obliquely down the shaft from an anterior to a posterior direction to allow a generous overlap after shortening. The drill holes are connected by osteotome and oblique section of the femur completed. The estimated length of bone is removed from the upper and lower fragments which are then secured by three screws. A plaster spica is applied for initial protection but this should be changed at six weeks to a thermos splint with skin extensions and a Pearson's knee piece to allow muscle re-education and knee movement.

CEREBRAL PALSY

by George Pollock

Cerebral palsy is not one single well-defined condition, but a group of neuromuscular disorders which vary, one from the other, as the clinical signs of spasticity, inco-ordinate movements, ataxia, tremors, rigidity or atony predominate. Most cases present a clear picture of spasticity or of the inco-ordinate and uncontrollable movements of the athetoid, but in not a few both features may co-exist or be combined with ataxia or tremors, etc. These "mixed" cases may give rise to considerable difficulty in diagnosis and classification The clinical picture is frequently complicated further by associated defects of sight, of speech, of hearing, of intelligence, and of emotional control. Epilepsy may be present also, occurring in the spastic child more commonly than in the athetoid.

Classification and Clinical Features

There is as yet no universally accepted classification of cerebral palsy and that adopted recently by the American Academy of Cerebral Palsy is not in its final form. Yet it serves as a simple and easily understood method of clinical analysis. Balf and Ingram have advocated that this disease should be classified on a neurological basis, but until the neuro-pathological background is more definitely defined it is probably simpler to classify these cases on the clinical findings:

Spastic

Athetoid
- Tension
- Non-tension
- Tremor
- Dystonic

Ataxia
Rigidity
Tremors
Atonic
Mixed

dition was described by Phelps as non-tension athetosis. When, as a result of the patient's own voluntary effort at control of this activity, a degree of tension developed in the muscles, which can be appreciated by the examiner as he attempts to move the patient's limbs passively, Phelps described the state as tension athetosis It is a condition which suggests, superficially at least, the spastic or rigidity case. There are no clinical signs of pyramidal tract involvement in this group of cases.

Ataxia is characterized by a drunken, staggering, wide-based gait, by diminished muscle tone, lost muscle-joint sense, and disturbance of speech and eye movements. The deep reflexes may be normal, depressed, or even absent, or, in the case of the knee-jerk, may show a pendulum characteristic

Rigidity although infrequently diagnosed is nevertheless a very definite clinical entity. It resembles the spastic state most closely but differs from it in showing no evidence of pyramidal tract involvement or of the stretch reflex. The complete absence of involuntary movement excludes the only other condition to which rigidity may bear a superficial resemblance tension athetosis A diagnosis is made by recognizing the peculiar plastic tone of the affected muscles as they are stretched by slow, passive movements of the limb If the knee or elbow joints are extended or flexed slowly and passively, a characteristic sensation is conveyed to the hands of the examiner as the joints give way either in a cog-wheel-like manner or relax slowly, much in the way a lead pipe might bend or straighten under firm pressure. So distinctive is the "feel" that "cog-wheel" and "lead pipe" rigidity are acceptable clinical descriptions. A few cases may give rise to more difficulty in diagnosis due to the variability of tone in the affected muscles. At one examination the presence of an increased plastic tone in the muscles is obvious, at another it may be absent—thus a third type of rigidity, intermittent rigidity, is recognized

Tremors take the form of flexion-extension movements of the fingers and toes but may extend to involve the limbs and, more rarely, the entire body may appear to quiver. The movements may be fast or slow, coarse or fine, and they are aggravated by voluntary efforts. Falconer has described a somewhat similar condition in rats which have suffered brain damage. The condition in man is very rare

The Atonic form of cerebral palsy is also rare but conforms to the clinical description in presenting a state of almost complete muscle flaccidity There is no true paralysis but muscle tone and power is exceedingly poor, and in the few cases which have been examined by the author the determination or will of the patient to co-operate in his treatment is on a par with the strength of his skeletal musculature. Speech may be absent or phonation so weak that while the lips may move, little sound emerges A well-developed eloquence of the eyes secured for one patient all the attention and help she required She appeared to understand everything that was said to her but she neither spoke

of several exceptions to this rule. Accurate information is being acquired slowly to show that cerebral palsy is associated with developmental defects such as absence of the cerebellum or of the basal ganglia, and polymicrogyria

Josephy believes that developmental malformations are responsible for those cases which show symmetrical involvement of the body although two or more destructive lesions could produce similar symptoms. Asymmetrical or unilateral involvement, such as a monoplegia or a hemiplegia, are, however, the result of destructive lesions, infective, inflammatory or vascular, alone.

Incidence

Winthrop Phelps, from an unrivalled personal experience of cerebral palsy, was the first to recognize the scope and scale of this condition as a crippling agent, and computed that in a population of 100,000 seven cases of cerebral palsy occurred each year, of which perhaps only one case succumbed before the age of eight. Expressed differently, in a township of 100,000 there would be found 120 cases of cerebral palsy under the age of 21 In Britain most surveys have been based on the school age population (5–15 years) and the figures have varied widely from 1 2 per thousand (Keddie): 1·6 (Holorian); to 2 5 as the result of a careful study carried out by Ingram.

Diagnosis

It is accepted generally that the earlier the diagnosis and the sooner treatment is begun, the better are the prospects of habilitation. While this is true in the main, it must be remembered that progress, physical or mental in the cerebrally palsied child, as with the normal, occurs *pari passu* with maturation or in the common phrase, "You must creep before you run"

To-day the experienced physician should be capable of establishing a diagnosis in almost every case within the first year of life, and in most within the first six months.

It is most important that an accurate history be obtained of the family and, in particular, of the mother's pregnancy and confinement; a prolonged labour, even if it ends spontaneously, may be of significance. The need for resuscitation and the measures adopted must be recorded fully, and the presence of post-natal irritability or undue "quietness," a bulging anterior fontanelle, or muscle twitching, and the presence or absence of jaundice whether due to Rhesus incompatibilities or not are very significant facts which must be noted also, and be available for later reference, even if an apparent recovery to normal takes place before the child is discharged from hospital No child who has shown two or more of the above features should be considered normal until repeated investigations by experienced physicians (at regular intervals) over 18 months have proved this to be the case beyond any shadow of doubt. Observance of these necessary precautions will prevent some

of the tragedies of adoption, and the heartache of foster parents on [illegible] that their baby suffers from cerebral palsy

[illegible]

stic

[illegible] the
tional
ental
cent.
to be
50 or
ormal

support by means of which balance and independent walking are gained. By cutting down the "overflow" movements in the spastic and controlling the inco-ordinate movements of the athetoid, bracing alone may provide an increasing "carry-over" period of muscle relaxation of which the physical, occupational and speech therapists can make good training use. Early bracing can prevent deformity as well as correct it in many cases when it is already present Adductor spasm, flexion contracture of the hips and knees and an equinus deformity will respond to bracing or to wedging of plaster casts in all except the most severe forms.

Operative Treatment.

It is unwise to operate on children suffering from cerebral palsy below the age of 5 years as they are too young to co-operate or to follow accurately or with regularity, the physiotherapeutic regime which is essential to improvement in the post-operative phase.

Surgery has nevertheless a worth-while contribution to make to the treatment of the cerebrally palsied individual but it can do so only when combined with expert and prolonged post-operative care

The operations that are carried out for the relief of a patient suffering from cerebral palsy may be divided into three groups

(1) Operations on the nervous system.
(2) Operations on muscles and tendons
(3) Operations on bones and joints.

(1) *Operations on the Nervous System* Sympathectomy, as elaborated by Royle and Hunter, posterior rhizotomy (Foerster), or Stoffels' operations are less popular to-day than they were some years ago due to the large number of rather disappointing end results

Anterior rhizotomy has still a place in the treatment of the athetoid, whose life has become unbearable because of the violence of the involuntary jerking movements of the upper limb. As a result of division of the anterior roots of the third cervical to the first thoracic nerves all active movements in the limb are abolished, but proprioceptive sensation remains unchanged It is a destructive operation and can be justified only where all other forms of therapy have failed to control the excessive movements of the shoulder and arm

In recent years hemispherectomy (Krynauw and Cairns) has been used successfully in cases of spastic hemiplegia complicated by severe epilepsy, particularly if the patient has shown himself to be emotionally unstable and difficult in his social relationships The operation is destructive and while it may not completely eliminate the epileptiform seizures, it does reduce the frequency and the severity of the attacks, and may convert a difficult and intractible individual into one who is both docile and trainable.

The operation of cordotomy gained an initial degree of popularity in the treatment of athetosis, but this has not been maintained in

recent years. A personal experience of one successful case is insufficient to justify a firm advocacy.

The success which has followed coagulation of the Globus Pallidus in some cases of Parkinson's Disease has led to the use of this form of therapy in severe choreo-athetosis. The early results are said to be encouraging.

It is probably fair to state, however, that up to the present there is no neuro-surgical cure for cerebral palsy.

(2) *Operations on Muscles and Tendons* The usual operations performed to-day on the muscles and tendons of the cerebrally palsied child include

(*a*) Tenotomy, tendon lengthening, and tendon transplantations.
(*b*) Myotomy and muscle transposition procedures.

Simple tenotomies and myotomies are among the oldest methods of surgical treatment and still retain their value when the cases are carefully selected. Subcutaneous tenotomy of the adductor longus origin to correct an adduction contracture of the hip, or of the tendo-Achilles to cure an equinus deformity of the foot, are still popular although most surgeons prefer the "open" to the "subcutaneous" method.

Lengthening of the hamstring tendons to correct a simple uncomplicated flexion contracture of the knee is an accepted procedure. Where there is a co-existing flexion of the hip or an equinus deformity of the ankle, superior results will be obtained if, instead of lengthening the tendons, these are detached at their insertions and transplanted into the lower end of the femur. The operation corrects not only the knee flexion, but by reinforcing the action of the glutei increases the strength of hip extension. Not infrequently it is found that when the plaster immobilization is discontinued after 6–8 weeks the equinus deformity has improved also.

As a result of the gradual stretching of the patellar ligament the patella will be seen to "ride high" in many cases of cerebral palsy who show a paraplegic or quadriplegic degree of involvement In consequence the last few degrees of full extension of the knees are lost and the stage is set for a flexion deformity of the knee to develop. Division of the patellar retinaculæ (Eggers) alone or combined with distal reattachment of the patellar insertion into the tibia will give more satisfactory functional results than those which follow hamstring reinforcement of the quadricep.

(3) *Operations on Bones and Joints.* Under this heading are included

(*a*) Bone-lengthening or bone-shortening procedures as a means of leg equalization in the spastic hemiplegic.
(*b*) Osteotomies
  (i) To correct gross knock-knee deformities.
  (ii) As a varus osteotomy of the femoral neck in the treatment of dislocation or subluxation of the hip.

(iii) Derotational osteotomies combined with (ii) in subluxation and dislocation of the hip, etc.

(c) Arthrodesis of the wrist, hip or foot, to correct deformity; provide stability and, in many, to improve function also.

Of all the operations recommended in the treatment of cerebral palsy, none have given results superior to those performed on the bones and joints.

The Treatment of Deformities in Various Regions

1. Deformity of the Arm.

There are three common deformities of the upper limb caused by cerebral palsy.

(1) The most arresting in appearance is the flexion deformity of the fingers, wrist and elbow which characterizes the spastic group in general and the spastic hemiplegic in particular.

(2) Limitation of supination of the forearm usually associated with (1).

(3) The writhing, flaying and uncontrollable movements of the hand and arm of the choreo-athetoid.

(1) Flexion deformities of the fingers, wrist or elbow of minor degree respond satisfactorily to treatment by wedging plaster casts, followed by muscle education and a prolonged period of splinting or bracing, i.e., until growth ceases Initially splinting should be worn at night as well as during the day—even although muscle relaxation does occur to a marked degree during sleep. Later, day splinting is reduced progressively so that active use of the limb can be encouraged in bimanual activities.

Arthrodesis of the wrist is the most satisfactory operation in the upper limb of the cerebrally palsied child. The wrist should be fused, in slight dorsiflexion and ulnar deviation, by means of a cortical bone graft supplemented by abundant cancellous bone chips A metal staple uniting the carpus to the lower end of the radius provides better immobilization than a plaster cast alone.

A wedge resection or a carpectomy will permit of correction of even a severe fixed flexion deformity of the wrist. The carpectomy by shortening the distance between the radius and the fingertips relatively lengthens the tight wrist and finger flexors, thereby permitting the recreation of a normally appearing hand.

The operation is indicated whether recovery of finger function is possible or not A "helping hand" with satisfactory function frequently results, but even if there is no recovery of finger movement, the operation is still well worth while cosmetically and psychologically for the boost it can give to morale.

(2) The Stoffel operation, as a method of correcting wrist and finger flexion, or as a means of obtaining an increased range of supination in a pronated arm, has not impressed the author favourably. As prona-

tion of the hand and forearm is the attitude assumed by the cerebral palsy hand, and since this is the position of function of the helping as opposed to the leading hand, why should we attempt to change it by operation? When the affected hand retains its "leading" role either because of the mildness of the handicap or because of the potent influence of heredity, operation may be justified. Even under these conditions careful thought should be given to all aspects for it must be admitted that the end results of surgery for the correction of this particular disability are not outstanding.

(3) The excessive involuntary movements of the upper limbs of some patients who suffer from choreo-athetosis may be so severe as to preclude all occupational or social pursuits. In some the pain from muscle spasm—sometimes likened to electric shocks—may be so great that treatment, even by so destructive a procedure as an anterior rhizotomy, must be considered seriously. The anterior roots of the third cervical to the first thoracic on the affected side are divided to produce a complete motor paralysis of the limb, but happily sensory and proprioceptive functions are not affected. With loss of all involuntary movement, pain disappears and the emotional and psychological picture is immediately improved.

Deformities of the Hip Region.

(1) *Adduction Deformity.* (*a*) Conservative treatment. When adductor spasm is not severe a satisfactory correction can be obtained by the application, under general anæsthesia, of a guarding plaster to each leg extending from the groin to the ankle. The legs are then widely separated and the casts united to each other by means of a cross bar of wood and the cast left in position for three to four weeks. A similar result can be achieved by attaching two turnbuckles to both plaster casts, one above and one below the knee. By regular daily turns the legs can be gradually separated and the adductors stretched — without anæsthesia. The injection of 20–30 c.c. ½ per cent Novocain into the muscle bellies may facilitate the separation and render it less uncomfortable during the first day or two. When the spasm is more severe, abdominal obturator neurectomy alone or combined with division of the adductors in the thigh is frequently recommended.

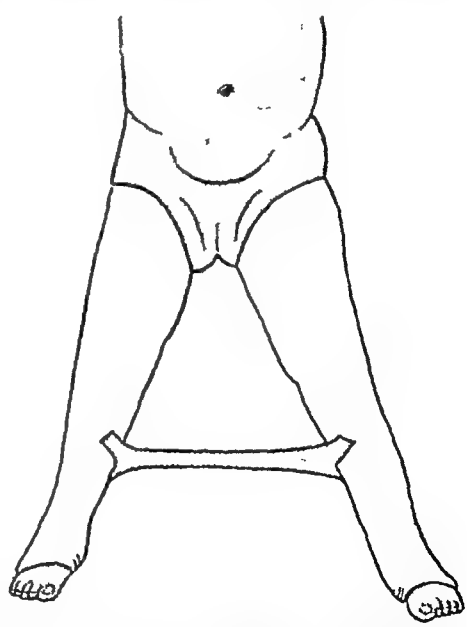

Fig. 256.—Cerebral Palsy. Plaster applied in a case of adduction deformity.

(*b*) By operation.

(i) *Abdominal Obturator Neurectomy* A median supra-pubic skin incision is made and the recti muscles separated. Care is taken to avoid damage to the bladder as the peritoneum is sponged upwards off the bladder and then medially and downwards to expose the inner wall of the pelvis. The obturator nerve can be identified as a white cord running along the side of the pelvis to disappear through the obturator foramen. It is in close relation to its accompanying vessel and veins which should be carefully separated from it Some surgeons remove a complete segment of about 1 inch in length from the nerve, but most remove only the upper and inner two-thirds over a distance of 1 inch, as by so doing some muscle function is retained. Both nerves can be dealt with at the one operation The operation is a satisfactory one from the surgical point of view but is not always followed by a permanent correction of the adduction deformity.

(ii) *Adductor tenotomy.* An incision about 3 inches long is made from the pubic spine downwards along the line of the tendon of the adductor longus. The tendon is identified and divided and the muscle fibres sponged downwards until the anterior branch of the obturator nerve is exposed in the intermuscular fascia behind. The nerve supplies the gracilis, adductor longus and a portion of the adductor brevis A section 1 inch in length is removed from the anterior division and at the same time it may be advisable in cases of severe spasm to identify the posterior branch by dividing the adductor brevis fibres which cover it. The posterior branch of the nerve is then clamped between pressure forceps (Barnett) This ensures maximum immediate weakening of the adductor muscles but without permanently weakening the whole adductor group, since recovery takes place in the posterior branch of the obturator nerve in the ensuing months. Fixation of the legs in an abduction plaster cast is advisable for two to three weeks until the wounds are soundly healed

(2) *Medial Rotation of the Thigh* This deformity develops slowly as a result of the characteristic manner in which the cerebrally palsied child gains a sitting balance The hips are flexed to a right angle, internally rotated and abducted so that they are separated one from the other by an angle of approximately 90 degrees The knees are also flexed to about a right angle and the inner side of the foot and leg rests on the floor This gives a satisfactory wide base and facilitates the acquisition of an independent sitting balance. The habitual assumption of this attitude causes a rotational deformity of the femur. A derotational osteotomy of the femur is the logical and satisfactory procedure for correction.

(3) *Flexion of the Thigh* Many cases of flexion deformity of the thigh can be corrected, easily and permanently, by Soutter's operation, as described under the treatment of infantile paralysis The two muscles which cause the flexion are the tensor fasciæ latæ and the ilio-psoas but the deformity may be fixed by contracture of these muscles as well as

of the reflected head of the rectus femoris and of the ilio-femoral ligament of Bigelow Where stripping of the muscles, as described by Soutter, does not permit of full correction, division of the capsule of the hip joint and of the ilio-femoral ligament in particular and of the ilio-psoas tendon also may be necessary before correction occurs In one case division of the ilio-femoral ligament led to a dramatic correction for, as the ligament was cut, the internally rotated leg rolled outwards.

Subluxation or frank dislocation of the hip is not uncommon in the cerebrally palsied child and is a cause of delay in the development of standing and independent walking. Treatment by a varus osteotomy of the base of the femoral neck will permit of correction of the valgus as well as of the ante-version of the femoral neck when this is required. Not infrequently the articular surfaces of the hip joint are badly eroded or so undermined by atrophy that the cartilage strips off easily. Under conditions such as these it is wiser to deepen the acetabulum, denude the femoral head, and perform a formal arthrodesis of the joint.

Deformities of the Knee.

Flexion deformity at the knee may be due to:

(1) Spasm or contraction of the hamstrings.
(2) Talipes equinus
(3) Flexion deformity at the hip.

The surgeon must decide first whether the muscular contraction is one that can be abolished by stretching or whether it is permanent. When knee flexion is due to muscle spasm alone and can be corrected by steady pressure, conservative treatment by wedging plaster casts may be sufficient to correct this deformity.

Under general anæsthesia the knees are stretched manually, and the degree of correction obtained held by the application of a well-padded plaster cast which must include the foot if an equinus deformity is also present Full thickness saddler's felt pads are placed at all three pressure points, under the heel, over the kneecap, and under the upper posterior thigh. Every fourth day a wedge is removed from the cast just over the patella and the edges approximated and fixed by a fresh plaster bandage Three or four wedgings are sufficient to each cast and no cast should be left in position longer than two to three weeks Pain occurring at the pressure points calls for inspection of the skin at these situations if sores are to be prevented. If there is no associated equinus deformity, a guarding cast extending from above the ankle to the upper thigh is all that is required

When the flexion deformity is permanent, lengthening of the hamstring tendons at the knee alone or combined with division of the heads of the gastrocnemius muscles is usually sufficient to allow the knee to be fully extended.

A Stoffel type of operation on the sciatic nerve in the thigh in which the twigs of supply to the long head of the biceps, the semi-membranosis,

soleus muscle deeply which, at this point, is covered by glistening fascia The fascial attachment is divided by a sawing motion distally. The foot is now fully dorsiflexed and the gastrocnemius fascia reattached to the soleus at a higher level—using a strip of the gastrocnemius fascia or the plantaris tendon itself as suture material. The advantages are threefold

(1) The shape of the calf is altered to a minor degree only.
(2) The strength of the tendo-Achilles is not weakened.
(3) A calcaneo deformity never occurs

Scaglietti and Silfverskiold detach the heads of the gastrocnemius muscle from the femoral condyles and after excising about 1 inch allow them to slip down below the joint level This procedure may be combined with the Stoffel operation

Lateral Deformities of the Foot.

Varus deformity, as an entity in itself, is uncommon in cerebral palsy, but as a component of talipes equino varus, it is relatively frequent in the hemiplegic state

Surgical lengthening of the tendo-Achilles before adaptive bone changes have taken place, followed by an adequate period of post-operative physiotherapeutic training, will correct the condition. Where bone changes have occurred, however, nothing short of a triple arthrodesis—preferably of the Lambrinudi type—is effective.

Talipes valgus alone or as part and parcel of a calcaneo-valgus deformity is both common and crippling It is a deformity of the athetoid as well as of the child suffering from an atonic diplegia, for which treatment by tenotomy of the peronei or by operations upon the nerves have been more than disappointing.

Talo-calcaneal arthrodesis by means of a Grice strut graft is satisfactory in its immediate results, but the number of operations performed and the length of time which has elapsed since are as yet insufficient to permit of unqualified praise.

When the deformity is well established, a triple arthrodesis is still the most satisfactory means of obtaining a weight-bearing foot upon which the child may be encouraged, perhaps for the first time, to try to develop an independent standing and walking balance

CHAPTER XI

AFFECTIONS OF NERVES

LESIONS OF THE PERIPHERAL NERVES

The great frequency of peripheral nerve lesions during and after the World Wars afforded an invaluable opportunity and provided a strong stimulus for the study of such injuries in all their phases and complexities Consequently, many previous gaps in our knowledge have now been filled, and while long-accepted views have in some cases been strengthened, in other cases old beliefs and practices have had to be modified or even wholly rejected. Nerve injuries occur, however, not only in warfare but also in civil life, so that their recognition and effective management are still of great economic and industrial importance. Their mode of origin must therefore be thoroughly understood, in order that they may be recognized or, in many cases, prevented; the appropriate treatment must also be understood in order that nothing should be done to aggravate the already existing damage.

Etiology

A peripheral nerve may be injured by direct or indirect means.

(a) **Direct Injuries.** The nerve may be wounded by a stab from a knife, by a bullet wound, or by the ragged ends of a fractured bone. In these cases it may be either completely severed, or only partially divided. In addition, however, it may be directly compressed by hæmorrhage or œdema following the reception of a wound Nerves may also be involved by direct vascular ischæmia as seen in Volkmann's contracture of the forearm. Another type of direct injury is when violent traction applied to a limb results in stretching or rupture of the nerve trunks, as in obstetrical paralysis or in motor-cycle injuries. Chemical injury may also be produced by the injection of drugs into or near a nerve.

(b) **Indirect Injuries.** Although it may escape injury at the time of accident, the peripheral nerve may be surrounded by callus or enclosed by cicatricial fibrous tissue some considerable time after an injury to a bone or to the soft tissues in its neighbourhood.

Pathology

When it is wounded, changes ensue not only in the nerve itself but also in its coverings, and in the surrounding tissues There is thickening of the neurolemma, and cicatricial fibrosis of the neigh-

bouring connective and muscular tissues which have been coincidently injured. In this way a mass of fibrous tissue is formed about the nerve and it is often difficult to recognize or to isolate the nerve.

In the absence of suture the divided nerve itself is usually the site either of a more or less bulky neuroma or of a pseudo-neuroma. A neuroma is a bulbous swelling resulting from the local proliferation and entanglement of regenerating nerve fibrils, and it forms round the central end It usually blocks the growing fibrils eventually

The pseudo-neuroma arises as a result of the proliferation of the neuroglial elements in cases of partial division. It gives rise to a swelling situated on the course of the nerve, and, since it contains no nerve fibrils, is really a glioma It may follow a simple contusion or compression, but is also found on the peripheral end of a completely divided nerve.

Changes in the Nerve Fibril

Degeneration. It is an accepted principle that the peripheral segment of an interrupted nerve fibre undergoes centrifugal degeneration whether immediate suture is undertaken or not To this phenomenon the term Wallerian degeneration is applied. It is due to the separation of the nerve from its trophic centres, which, in the case of the motor fibres, are the anterior horn cells, and in the case of the sensory, the posterior root ganglia The individual components of the fibre undergo specific changes The axis cylinder first becomes fibrillated, then gradually attenuates, and finally disappears The myelin sheath swells up in places and becomes irregular, while the myelin loses its special characteristics and comes to resemble the ordinary fat globules. Finally, it completely disappears, having been partly absorbed and partly eliminated by leucocytes. The cells of the sheath of Schwann show active nuclear division and they share with the leucocytes the task of eliminating the myelin.

The interrupted nerve fibre now consists merely of an empty protoplasmic frame surrounded by the proliferated cells of the sheath of Schwann This state is arrived at about two weeks after the injury, and is followed by progressive shrinkage of the peripheral Schwann sheaths

In the central end degeneration advances proximally only to a slight extent Indeed this retrograde degeneration is practically confined to the immediate neighbourhood of the lesion.

Regeneration. When a nerve is divided its recovery depends on the outgrowth of new nerve fibres from the central stump. When the ends are approximated rapid union takes place by proliferation of the cells of the sheath of Schwann, but this is temporary and not regeneration It has been shown by Abercrombie and Johnson that in the rabbit, the greatest activity of these cells is seen about three weeks after the injury The peculiar attraction which the empty sheath exerts on the growing axis cylinders is known as neurotropism. The cells of the sheath of

Schwann in both stumps multiply, and in the peripheral stump they form the Schwann bands, or bands of Burgner, down which pass the young out-growing axons. It is believed that these Schwann bands may even bridge a gap of some length by forming broad strands of tissue or a fan of tissue There may be some accelerating, and perhaps attracting, influence exerted by the central stump on the Schwann tissue growing from the peripheral stump—a reversed neurotropism as it were. The peripheral outgrowth may take place fanwise, and it has been noted that one arm of the fan may proceed distally until it joins with the central stump as though its growth were accelerated by this central stump. Regeneration across such bridges may be impaired if the new fibres are not guided into proper paths, as they might be by a true peripheral stump, but after all, as Cairns and Young point out, it is probable that the arrival of new fibres at appropriate end organs is always a matter of chance. About the fourth day after injury, the axis cylinders of the central end divide into fine fibrils which slowly advance right down to the level of the actual section, having traversed the small zone of retrograde central degeneration. They then proceed to bridge the gap, attracted and guided by the proliferating neuroglial cells; next they scatter about, seeking the empty sheath of the peripheral segment, which they ultimately penetrate. Thereafter they continue to grow until the nerve trunk is completely restored. At the same time the myelin sheath is re-acquired, and resumes its normal structure.

The length of time between the nerve suture and the complete return of function is variable and depends on many circumstances, but no matter how favourable the circumstances may be, regeneration is essentially a long and a gradual process. An axis cylinder is reckoned to grow at the rate of about 1 mm per day and, even after it has apparently had time to cover the full distance, there may be a considerable interval before there is anything like a return of function. Even in the most favourable cases, it is unlikely that all the functions —motor, sensory, and trophic—will be restored completely to their former perfection.

Changes in Dependent Structures

Complete division of a mixed nerve has the following effects · the muscles supplied by it are immediately paralysed, and begin to atrophy, they also show the reaction of degeneration, the area which derives its entire sensory supply from the nerve is rendered insensitive, while the structures over which it exercises trophic control—e g bones and joints—begin to atrophy.

CLINICAL EXAMINATION OF THE PATIENT

The efficient investigation of the condition of a nerve demands a perfect knowledge of its anatomy and physiology, i e. its course, its

branches, the muscles it supplies, and the cutaneous territory to which it is distributed

The examination of the nerve should be repeated frequently, say at intervals of several weeks, in order to note the evolution, the progress of the symptoms and signs of regeneration as they appear. Otherwise operative interference might be undertaken too soon.

The importance of examining the patient under proper physical conditions cannot be over-estimated, and one would particularly emphasize the unreliability of electrical and sensory tests when the limb is cold.

The investigation should commence with a carefully taken history of the injury, or the onset of the trouble. The symptoms and physical signs should next be elicited; and finally the actual clinical examination carried out.

While the history of the case is usually not important, it may sometimes be of value to know exactly how the injury was received—e.g. in the case of a bullet wound, to know the direction in which the bullet proceeded and the exact position of the limb at the time. It is also well to know whether or not suppuration occurred in the wound.

The clinical examination of the case is then proceeded with

1. Attitude. Lesions of the various nerves usually result in a characteristic attitude. Ulnar injuries lead to a typical extension of the metacarpo-phalangeal joints of the fourth and fifth fingers, with flexion of the distal joints, median injuries to the characteristic flat hand; radial to a dropped wrist, and lateral popliteal to dropped foot.

2. Voluntary Power. This may be estimated by asking the patient to carry out in turn the movements performed by each individual muscle, a chart being made of the result R B Zachary has developed a method which was adopted by the M R C. nerve-injury centres In this the motor power of a particular muscle is calibrated from 0 to 5, i e, from no contraction to full contraction against resistance In cases where the muscle is very weak, it is useful, for purposes of comparison, to carry out the same action on the opposite side, and also to test the muscle in the position in which least strain is imposed upon it and therefore not against the force of gravity In examining the deltoid, for example, the patient may be placed on his back and then asked to contract the muscle; while in testing the function of certain muscles, a polished surface may be inserted underneath the part to eliminate friction In the case of radial nerve paralysis, the hand is laid on its ulnar side before the patient attempts to dorsiflex. In this way the slightest trace of voluntary contraction can be detected

3. Reflexes. Paralysis of a muscle is attended by disappearance of its reflexes. In paralysis of the muscles dependent on the sciatic nerve, for example, the calcaneus jerk is lost, in triceps lesions the olecranon reflex disappears. It is to be noted, however, that if the

skin is anæsthetic over the area of excitation, the reflex will be abolished, independently of any motor paralysis, so that loss of the reflexes is not pathognomonic of division of a mixed nerve, or of the paralysis of a muscle.

4. The Muscles. A paralysed muscle shows certain characteristics:

(*a*) It atrophies slowly and progressively until eventually it is nothing more than a fibrosed cord.

(*b*) The muscular tone is completely abolished.

"Tone" is the state of latent and permanent contraction which persists even when a normal muscle is at rest; its total disappearance is recognized by the complete flaccidity of the muscular bellies on palpation. It is also evidenced by the attitude of the limb, the lifeless paralytic attitude becoming even more pronounced

(*c*) The paralysed muscle is painless when compressed, except in cases of nerve irritation alone. This complete insusceptibility to pressure is one of the clearest signs of complete interruption, and, conversely, if the muscle bellies are very sensitive, nerve irritation may safely be assumed to be present.

5. The Skin. In a case of complete paralysis, examination of the integument is important The skin is most commonly glazed, the cutaneous folds disappear, and the papillary crests are smoothed out, giving a flat, polished appearance to the finger-prints. There may be excessive sweating, although this is more usual in cases of slight neuritis. The skin is much more frequently dry and sometimes a fine desquamation occurs.

Certain vaso-motor disturbances may be present, giving characteristic appearances. Pallor is common, but cyanosis and redness are only slightly less frequent in their occurrence. Œdema may be found in cases of nerve interruption, although it may be due only to abnormal posture or to disuse.

Ulceration may be present in areas where the nerve has many sensory fibres—e.g a typical trophic ulcer commonly develops over the heads of the first and fifth metatarsals in sciatic lesions There may also be a diminution or elevation of the local temperature, while hypertrichosis is common in all nerve lesions. In a case of nerve division a simple transverse groove is seen across the nail, while in irritative lesions the nail may be striated, split, curved, or otherwise deformed. Frequently, too, the nails atrophy, and this, in association with the wasting of the subcutaneous tissue and the atrophy, gives a tapering, conical appearance to the finger-tips

6. Sensation. The most practical method of testing sensation is by means of a wisp of cotton-wool, and by an ordinary pin. It is not really important to investigate the finer grades of sensibility, or of thermo-sensibility.

When testing with a pin, in cases of nerve lesion, four zones can

usually be differentiated. In the first, or central zone, the patient feels absolutely nothing. In the second zone, he feels the pin-prick, not as a painful stimulus, but as a touch In the third zone, which is beginning to derive a portion of its nerve supply from neighbouring nerves, he feels a vague pricking and for the first time can clearly distinguish a piece of cotton-wool. In the fourth, or most peripheral zone, the pricking is felt acutely, as the adjacent nerve is intact. Not infrequently there is slight hyper-æsthesia at the margins where the areas supplied by adjacent nerves overlap the affected one. The varying degrees of loss of sensation may also be graded from complete loss of all sensation to loss of deep cutaneous pain sensibility, to loss of superficial cutaneous pain sensibility, to loss of two-point discrimination, to normal sensation, i e, from 0 to 4 (after R. B. Zachary).

Testing for temperature sensation may also be of diagnostic value.

7. The Nerve itself. In examining the nerve, the first feature investigated should be its tenderness to pressure. Tenderness is present along its whole course when the nerve is subject to irritation, and, if elicited, it naturally indicates an incomplete lesion

An attempt should next be made to elicit formication, or what is usually known as Tinel's sign This is evidence of the presence of young axis cylinders, and therefore of an attempt at regeneration. It is particularly seen after the nerve has been repaired If the nerve is gently compressed or percussed an inch below the level of suture after about a month, a sensation of "pins and needles" can be elicited in the area supplied by the nerve. This "formication" can gradually be elicited by more and more distal pressure as the regeneration proceeds We are thus able to trace the furthest point of regeneration and so determine the rate at which the nerve is regenerating

Lastly, a neuroma is sought for along the course of the nerve. This may take the form of a simple fusiform thickening, or of a large bulky tumour, or both. The presence of two neuromata indicates a complete lesion, but frequently the divided ends are so embedded in a mass of fibrous tissue that the swellings cannot be palpated

8. Electrical Examination. The investigation is completed by testing the electrical response of the muscles. Using the bi-polar method, the faradic or intermittent current is first employed, with one pole over the nerve and the other on the muscle belly. In cases of complete division, no contraction is obtained. The galvanic, or continuous, current is then used, with a similar arrangement of the poles Here a weak and sluggish response is obtained as compared with the normal rapid sudden contraction. There is also an alteration in the polar reactions, as contraction is stronger when the muscle is stimulated with the anode. In addition a greater intensity of current is necessary to produce the minimal contraction. These findings —the absence of faradic response, the weak galvanic response with a sluggish contraction, and a reversal of the polar formula—are collectively known as the "Reaction of Degeneration"

Ritchie (1944) developed a method of evaluating the strength-duration excitability of muscles. In this, electrical stimuli of variable strength and duration are applied to the muscle, under test, through electrodes and its response is compared with that of the normal muscle in the normal limb. Information can be obtained to show that re-innervation is occurring, and to differentiate lesions of continuity from those of frank division.

Another recent method of electrical investigation is electromyography. In this the electrical potentials are measured through electrodes within needles inserted into the muscles and during re-innervation, for example, action potentials can be demonstrated.

DIAGNOSIS

The diagnosis of a nerve injury should not be difficult, but only by a careful examination of the various functions of the nerve can certain confusing conditions be excluded These are.

(1) Central paralyses, such as monoplegias and cord lesions.

(2) Peripheral polyneuritis due to some form of toxic poisoning.

(3) Functional paralyses. Some of these are hysterical or mimetic paralyses, and correspond to no definite anatomical distribution. They do not affect so much the movement, as the function, or use of the part. Atrophy and loss of tone such as occur in peripheral nerve lesions are absent, and the area of anæsthesia corresponds to no anatomical nerve distribution, but is oftener of the glove or stocking type

(4) Pseudo-paralyses from muscular contractures or tendon adhesions.

(5) Ischæmic paralyses, which arise from venous obstruction and result in fibrous contracture, tendon adhesions, and postural deformity

By far the most important and difficult problem to solve in cases of peripheral paralysis, however, is that of the nature of the lesion. In this connection, four clinical syndromes are described and are considered to be fairly typical, and clearly characterized. They are·

1 The syndrome of interruption.
2. The syndrome of compression.
3. The syndrome of irritation.
4. The syndrome of regeneration.

It is all-important, from the point of view of treatment, that each case be assigned to its appropriate group.

1. Syndrome of Interruption. When a nerve is completely divided, when it is called Neurotmesis (Seddon), there is an immediate and complete paralysis of muscles, with rapid diminution in tone and progressive atrophy in three weeks a typical reaction of degeneration is present Anæsthesia follows immediately after the nerve is divided. Formication is absent below the lesion and there are no trophic disturbances

Seddon points out that in the syndrome of interruption, in addition to the above "complete anatomical division" there may be two other phases:

(*a*) A "lesion in continuity," called Axonotmesis, in which some of the supporting structure is preserved but there is always disturbance of the nerve fibres so that true Wallerian degeneration occurs peripherally.

(*b*) "Transient block," called Neuropraxia—a minimal lesion producing paralysis usually incomplete, and quite transient; there is no peripheral degeneration.

A "lesion in continuity" is often seen after injuries which fail to divide a nerve completely. Fusiform neuromatous enlargement may appear at the site of injury, and there may be a thickening of the epineurium and perineural adhesions. The clinical effects are much the same as those which follow complete anatomical division, but according to Seddon there are three possible ways of distinguishing the two lesions: (i) The nature of the injury: thus, an open gunshot wound of the arm followed by radial palsy usually means a trans-section of the nerve while a closed fracture of the humerus with paralysis of the same nerve probably means a lesion in continuity. (ii) Spontaneous regeneration does not occur after anatomical division of a nerve. (iii) Exploration will reveal the nature of the lesion. This operation, which in competent hands does no harm, should not be postponed.

A "transient block" of a nerve typically follows violence which is not severe (e.g. the pressure palsies). The characteristics of the clinical effects are: (i) the syndrome is predominantly motor. (ii) There is little wasting and no change in the electrical reactions. (iii) Dyæsthesiæ (subjective sensory complaints) are common. (iv) Objective sensory changes are minimal and incomplete. (v) Loss of postural sensibility and vibration sense are common. (vi) Loss of sweating is unusual. Recovery generally begins within a fortnight and may be complete within two months. The progress of recovery is irregular, and is eventually complete.

2. Syndrome of Compression. Here the paralysis may be as complete as in the syndrome of interruption, but frequently it is only partial, a few ill-defined movements being possible. The muscle atrophy is far more rapid, but less severe than in complete interruption. There is also some preservation of muscle tone, and the reaction of degeneration is always incomplete. The anæsthesia is variable both in extent and in degree. Pain is absent at the level of the lesion and also along the course of the nerve and on pressure of the muscle belly. There is no formication or trophic disturbance.

3. Syndrome of Irritation. This group presents a variable picture, since there are varying grades of nerve irritation.

In the mild type there is spontaneous pain, exquisite tenderness along the nerve trunk, and certain trophic phenomena.

In the more severe types, a condition known as causalgia develops. The patient suffers constant pain, with even more acute exacerbations,

(1) Primary Operations. These are carried out in the presence of an external wound. While the primary excision, or the "débridement," of the wound is being carried out a nerve may be found divided Seddon believes that primary nerve suture should be done only in the rare event of a nerve being cleanly divided accidentally at an operation. The principal reason is that the agent severing the nerve often produces more damage than is apparent In three weeks the sheath thickens and makes suture more easy. Early secondary suture is proved to be superior in its results. At the primary operation the nerve ends are tacked together to prevent retraction and rotation.

(2) Secondary Operations. These are employed after the external wound has thoroughly healed, the indications for these operations are derived from the clinical examination of the individual case and the interpretation placed on the clinical syndrome.

(*a*) *Complete Divisions.* When it is evident that there has been a complete interruption of the nerve, it is unwise to delay operative exploration. A fracture of the humerus, with complete radial paralysis, for instance, should be explored as soon as the skin and general condition of the patient admit of operation.

(*b*) *Syndrome of Incomplete Interruption.* If no definite improvement occurs in three months in cases of this type, exploration should be carried out.

(*c*) *Syndrome of Irritation.* In this type, and particularly in causalgia, operation should be resorted to as soon as possible

(*d*) *Nerve lesions presenting some time after injury.* In this very difficult group, some even presenting with a degree of neurological recovery, decision to re-explore must be made. The factors to be considered are the conditions found at the first operation—state of the lesion, the level, the interval since injury and the gap still present to be closed. Learmonth (1944) has suggested re-exploration in healed wounds after long sepsis, and in which there had been severe bleeding at the original operation; in closed injuries following a crush; in cases with involvement of more than one nerve and when pain or excessive sweating persists

Preparations for Operation. The most essential part of the preparation is the thorough sterilization of the skin of the patient, by iodine or "Cetavolon" solutions, in order to reduce to a minimum the possibility of sepsis. If any septic spots are present on the limb the operation should be postponed until they are soundly healed. One of the most common sources of post-operative sepsis, especially after a fracture, is the presence of desquamating skin in the vicinity of the incision. About a fortnight after the fracture, just at the time when the exploration of the nerve could be justifiably undertaken, the œdema subsides and the skin begins to desquamate. It is of the utmost importance, therefore, that all the dead skin should be thoroughly removed during the preparation, which should involve the whole limb. If the approximation of the nerve-ends is likely to require flexion of a

the affected muscles. Without this, recovery is slow, and may be very incomplete. The splint varies with the anatomical site of the lesion—for deltoid paralysis, an abduction splint; for radial paralysis, a cock-up splint; for a lateral popliteal paralysis, a drop-foot splint The most important object in this treatment is to preserve the mobility of the whole limb and every part of it. Splintage has to be carefully used, therefore, and at least once every day every joint has to be put through its full range of movement. One must carefully avoid over-splintage of the hand at all stages of treatment, and carefully flex and extend the small finger joints regularly.

Physiotherapeutic treatment is also essential The limb is massaged to preserve the tone of the muscles, while the muscles themselves are passively exercised. Electrical treatment is also of considerable value. Denervated muscles which have received galvanic stimulation frequently are less atrophied, less fibrosed, show better excitability and contractility, and stronger reflex activity. Either the continuous galvanic, or the interrupted faradic, current may be used according to the reaction of the muscle

By far the most important part of this conservative treatment, however, is muscular re-education. The patient is taught to use the individual muscles, and so gradually restore them to normal In the case of children, this type of treatment may be camouflaged by the use of toys and musical instruments, which bring into action the desired muscles.

When the nerve is regenerating, the level on the nerve trunk at which formication can be elicited gradually creeps down the limb, inch by inch, and month by month, and, when the growth of the axis cylinders has proceeded as far as the muscle bellies, the patient may begin to complain of a little tenderness when these are palpated. Later, the anæsthetic area becomes hyperæsthetic, and finally there may be a little twitching in the muscles as voluntary power returns. While these signs are showing themselves, the electrical reactions are found to be gradually improving, but the faradic response does not usually return until the patient is able to move his muscles voluntarily.

It is impossible to assign any definite time-limit to the process of regeneration, as many circumstances may alter the case and lead to delay.

When nerve suture is carried out soon after the original lesion, we may expect the nerve to regenerate at about the rate of 1 inch per month, but even after the nerve has reached the extremity of the limb there is a lapse of some considerable time before voluntary power returns The more distal the injury, the quicker and more complete is the recovery, but following a lesion in the upper limb it is rare to find a complete restoration of all the small muscles of the hand

Operative Treatment

Indications for Operation. Peripheral nerves may be operated on at the time of the original injury or at a later date.

cut ends is all that is required. Fine tantalum wire suture or human hair material is frequently used now. After stitching, the affected portion of the nerve is buried in healthy tissue and the wound closed. When necessary, the flexion of joints must be rigidly maintained by splints, to prevent disruption of the suture line.

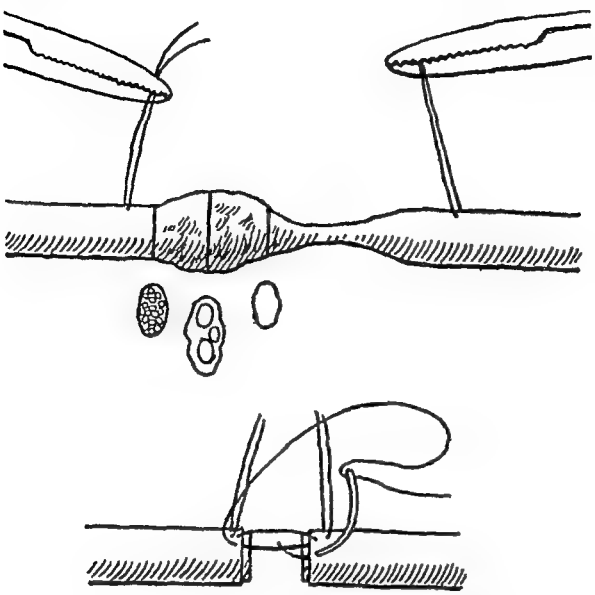

Fig. 257.—Suture of Peripheral Nerve

The suture penetrates the sheath only. The nerve is sectioned first until healthy fibres are evident. In the transverse sections will be seen homogeneous fibrous tissue, swollen fibrils, and healthy nerve, from right to left.

Young and Medawar have devised experimentally a method by which nerve-ends may be held together with concentrated coagulated blood plasma. They say this reduces the difficulty of nerve suture and minimizes the disorganization of fibres by sutures. The method consists in holding the cut stumps together and pouring round them plasma which has just been mixed with a little tissue-extract. This plasma clots to a firm jelly in about 2 minutes and holds the stumps together. It is freely permeable and during subsequent days dissolves, though remaining long enough to allow a firm union to be established. It is said that the new fibres grow across the junction rather more quickly than across a suture line.

Method of obtaining End-to-End Suture. In many cases, the loss of nerve tissue will have been so great that end-to-end suture can be obtained, if at all, only with great difficulty. There are various methods by which the approximation of the ends may be facilitated.

(*i*) *Extensive Mobilization of the Nerve.* A gain of about 1 inch in the arm, or 2 inches in the leg, may be obtained by a wide mobilization of the nerve trunk on either side of the lesion. This feature depends on the inherent elasticity of the nerve tissue.

(*ii*) *Relaxation of the Nerve,* by the temporary fixation of joints in favourable positions. Flexion of the elbow will occasionally facilitate suture of the nerves which pass in front of it; even when there is a gap of 2 inches. Flexion of the wrist to about 45 degrees similarly gives an extra inch to the median and ulnar nerves; while adduction of the arm at the shoulder gives an extra inch to the nerves crossing the axilla. After fixation for six weeks, joint movements are commenced, and the range of these will be found to increase rapidly without separating the sutured nerve-ends.

joint, the joint should be prepared for this beforehand and any necessary manipulation carried out Splints and plaster cases likely to be required after operation should be devised, made, and placed in readiness beforehand.

The Operation.

The incision should be long and, as a rule, in the anatomical line of the nerve Immediately after the skin incision is made, the knife should be discarded, and sterile towels at once clipped to the wound edges.

The nerve itself is then exposed above and below the lesion. If that is done, and the nerve trunk encircled with and picked up by Lane's forceps on either side of the lesion, there is usually no difficulty in freeing the nerve from the surrounding scar tissue. The dissection is performed delicately and carefully with a sharp knife. After the affected segment has been elevated from its bed, the physiological activity of the nerve is tested by faradic stimulation with a fine sterile needle electrode. Where the faradic response is absent or where it is obvious that there is no intervening nerve tissue between the proximal and distal stumps, then the operation of nerve suture must be carried out. If the response in the muscle supplied by the nerve is brisk, however, then there is no need for complete suture and neurolysis may be carried out. In some cases the lesion will prove to be only a partial one, several fibres being intact. In this event the intact fibres are left alone, and resection and suture of the injured segments alone carried out.

(*a*) **Neurolysis.** This term is applied to the operation in which the nerve is freed from enveloping scar tissue. In many cases it may also be incised or sliced in a longitudinal direction, to relieve the pressure of the contracting fibrous tissue on the nerve fibrils. Thereafter, the affected part of the nerve is buried in healthy muscular tissue, away from its previous bed of scar tissue

(*b*) **Nerve Suture.** The first step in this operation is to mobilize and thoroughly relax the nerve by wide dissection of the proximal and distal ends In the majority of cases this procedure, along with flexion of the appropriate joints, will enable the ends to be approximated When co-aptation has been secured, a stitch is put into the healthy nerve segments below and above the lesion to prevent axial rotation of the nerve during the insertion of the later sutures. The nerve is now trimmed, i e it is cut through at the level of the lesion, and the cross-section examined Successive slices are removed until normal fibrils are evident to the naked eye, indicating that the part is sufficiently healthy to be sutured. This procedure is carried out at both ends of the nerve, and, when both present normal fibrils, the ends are ready for stitching. A series of interrupted linen stitches are passed through the nerve sheath, since the mere approximation of the

sign. but the flexor pollicis brevis may occasionally remain intact owing to its deriving an anomalous supply from the ulnar nerve.

FIG 258 —The Median Nerve

The typical conical index finger whose flexion is limited or non-existent

The sensory loss involves the thumb, index and middle fingers, and half the ring finger Injuries of the median nerve are notable for the frequency with which irritative syndromes of all grades develop. Trophic disturbances are best seen in the wasting of the terminal phalanx of the first finger, which is usually thin. pointed and conical.

DIAGNOSIS

The characteristic attitude of a hand deprived of its median nerve supply is one of flattening, the thenar eminence being entirely wasted and the thumb rolled laterally from paralysis of the opponens pollicis

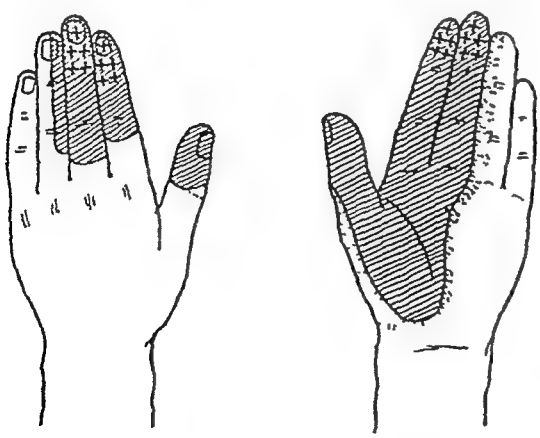

FIG. 259 —Sensory loss in division of Median Nerve

The dotted area is that insensitive to pain the shaded area is that insensitive to pin-pricks and cotton-wool the crosses indicate the region insensitive to deep pressure

The first finger almost entirely loses its power of flexion, and when an attempt is made to close the fist, the thumb and the index finger remain extended Also, when the palm of the hand is laid on a table, the patient is unable to flex the first finger with the other fingers remaining flat on the table.

A good clinical test for the loss of median sensation is to ask the patient to button his coat; this manœuvre cannot be carried out unless the movements are directed by vision

(*iii*) *Alteration in the Course of the Nerve.* The ulnar nerve may be brought in front of the medial epicondyle; the radial nerve may be brought to the front of the arm; and the median brought in front of the flexor muscles of the forearm.

(*iv*) *Stripping up of Branches* Where the branches anchor the nerve ends and prevent their mobilization and approximation they may be gently stripped up from the parent nerve.

(*v*) *Sacrifice of Branches.* When suture is prevented by the tension of distal branches, it may be better, since the branches are already functionless, to suture the rest of the nerve at their expense, particularly in a nerve such as the median where the return of sensation is a matter of great importance.

(*vi*) *The Two-stage Operation.* This method may be used where it is absolutely impossible to secure direct suture, the principle being to bring the untrimmed ends of the nerve into contact, or as near as possible to each other, by the methods of relaxation described above and then anchor them by strong sutures. In two or three weeks the joints are gradually extended and the nerves thus coincidently stretched. As soon as the full range of joint movement has been restored, the nerve is again explored, and, by repeating the process of mobilization, the nerve-ends will in the majority of cases be capable of approximation.

(*vii*) *Autogenous nerve grafting* to fill up long gaps in a destroyed nerve is attended with some degree of success, as was shown by the work of Ballance and Duel on the facial nerves. Brooks has reported his results in 93 cases of nerve grafting where the graft was used to restore continuity of a nerve All patients with pedicle nerve grafts made excellent recoveries. Results of sciatic grafting were poor and those of digital nerve grafting uncertain; all other forms gave useful recovery in 50 per cent of the patients. He points out that the most important single factor contributing to the success of a nerve graft is adequate vascularization of the graft. Early operation is advocated and as there may be extensive collagenization of the peripheral stump resection of this should lie on the side of generosity Grafts are taken from the medial cutaneous nerve of the forearm, the sural, the superficial radial proximal to the wrist, or the saphenous in the thigh. Several strands may be used to bridge a gap in the larger nerves. All grafts shrink, so they are cut to be 15 per cent. longer than the gap to be repaired Scar tissue should be completely removed to ensure a good bed for vascularization of the graft. The actual suture must be done with extreme care and be technically perfect. Concentrated plasma is often used for the actual attachment of the nerve ends.

In closing the wound, great care should be taken to secure absolute hæmostasis. The muscular tissues are united over the nerve and as thick a covering as possible obtained by this means. An accurate skin apposition is made easy if transverse scratches have been made across the line of the proposed incision before the skin was actually divided

After-Treatment The after-treatment of nerve injuries is of

flexor carpi ulnaris. Accordingly this tendon is identified and split longitudinally and one of the halves severed at its insertion A subcutaneous tunnel is now made from the distal end of the first incision to the distal end of the second and the tendon of the extensor brevis pollicis threaded through it The first incision is now stitched up. With the thumb fully rotated into the opposed position the proximal end of the divided thumb tendon is stitched to the distal end of the divided part of the flexor carpi ulnaris under a fair amount of tension. After stitching the wound the thumb is retained in this position for about four weeks in plaster of Paris

In similar cases where paralysis has produced a flat hand with a non-apposable thumb an inter-metacarpal fusion may be carried out between the first and second metacarpals. They are approached through separate one-inch long incisions. The bones are exposed and a tunnel formed through the soft tissues between them. Smillie uses a section of fibula of appropriate length and fixes it in position with a fine pin or thick Kirschner wire, which is driven through the two metacarpals and their covering skin to lock them in position The pin is removed in eight weeks. Because of the varus deformity which sometimes occurs in the metacarpo-phalangeal joint following this "strut" graft operation, it is preferable in the young hand to attempt an opponens tendon transfer. In this the flexor sublimus tendon to the ring finger is divided and re-routed around the insertion of flexor carpi ulnaris and attached to the base of the proximal phalanx of the thumb or to the short flexor tendon of the thumb.

The Carpal Tunnel Syndrome

The median nerve is not infrequently the object of pressure under the transverse carpal ligament. Usually the earliest symptom is numbness, tingling, or painful burning of the fingers coming on during sleep. Rubbing the fingers, dangling the hand over the side of the bed, or just holding the wrist straight often brings relief in a few minutes With the pain there is often a feeling of swelling or paralysis of the affected fingers which are held in semi-flexion. The paræsthesia is in the median area Within a few months persistent numbness or lack of feeling sometimes appears in one or two finger pads with weakness of the thenar muscles. Sensory loss may be prominent. The syndrome affects middle-aged women predominantly. The condition is often bilateral Symptoms can often be reproduced by pressure over the transverse carpal ligament by applying a tourniquet with occlusion of the brachial artery.

Treatment. Complete relief can be obtained by dividing the transverse ligament through an incision extending along the skin crease at the base of the thumb to the transverse skin crease at the wrist which is also traversed towards the pisiform bone.

The Ulnar Nerve

The ulnar nerve is most commonly injured in incised wounds of the forearm, or in fractures of the lower end of the humerus, particularly those affecting the medial epicondyle. Occasionally it is contused by crutch pressure in the axilla, and it is frequently implicated in osteo-arthritic outgrowths about the elbow joint

Occasionally also the nerve is anchored so insecurely in the post-condylar groove that it can slip backwards and forwards with each movement of flexion and extension This instability often results in neuritis, with pain, and weakness of the fingers.

Clinical Features

In lesions above the post-condylar groove, the paralysis affects the flexor carpi ulnaris and the medial half of the flexor digitorum profundus, the hypothenar muscles, the interossei, the medial two lumbricals, the adductor of the thumb, and sometimes the deep head of the flexor pollicis brevis Abduction and adduction movements of the fingers are lost, and also adduction of the thumb, so that the patient is unable to grasp a pencil placed crosswise between the thumb and the index finger In paralysis of the dorsal interossei, abduction of the fingers can be carried out by the extensor digitorum communis but this produces also hyper-extension of the metacarpo-phalangeal joints.

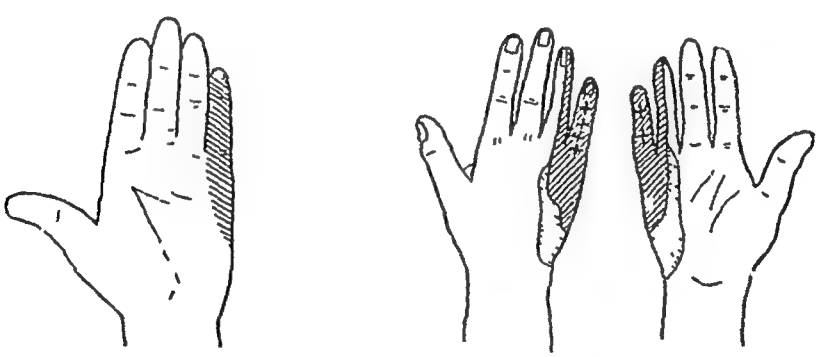

Fig 260.—Anæsthesia in Ulnar Nerve Injuries

In the left-hand figure is shown the typical extent of the absolute sensory loss In the right-hand figure the dotted area is insensitive to light touch (epicritic) and the shaded area is insensitive to pain (protopathic)

The muscular atrophy gives the familiar flattening of the hypothenar eminence, the depressed interosseous spaces, and the prominence of the metacarpal heads in the palm A claw hand deformity, most marked in the ring and little fingers, develops later The proximal phalanges are then extended, and the distal and middle phalanges flexed, while the little finger is usually abducted As time goes on this contracture becomes more and more marked, and the fourth and fifth fingers gradually flex down into the palm and become rigidly fixed in this attitude.

Sensation is lost over the ulnar border of the hand, the entire little finger and ulnar half of the ring finger, on both extensor and flexor surfaces.

If the lesion is below the origin of the large dorsal cutaneous branch, sensation is retained on the dorsum of the hand and the area of analgesia is exceedingly small.

Diagnosis

The functional disability following division of the ulnar nerve is slight; indeed many such cases of complete ulnar paralysis were able to return to full duty before the end of the last War.

Prognosis

Results of suture are disappointing as, although the long muscles may recover and even in quite a proportion of cases sensibility to pinprick, one rarely sees an effective recovery of voluntary movement in the ulnar intrinsic muscles of the hand.

Traumatic Ulnar Neuritis

Certain types of ulnar nerve lesion, of the nature of friction neurites, result from some alteration in the normal relations between the nerve and its post-condylar bed of the ulna Platt states that three distinct groups of these may be recognized

1 Lesions associated with recent fractures of the lower end of the humerus, e g fractures of the medial epicondyle

2. Late ulnar palsy, following fractures of the lateral condyle sustained usually in early childhood. In this type of lesion, three stages can be characteristically recognized

(a) The fracture in early life

(b) A latent period, rarely less than ten years

(c) The development of the lesion.

Fig. 261 —Post-traumatic Ulnar Neuritis

A fracture of the lateral condyle of the humerus resulting in cubitus valgus and the later development of ulnar neuritis

The neuritis is here due to friction or tension, and is a sequel to the gross valgus deformity resulting from the fracture The nerve trunk, compelled to take a longer course, becomes overstretched in the abnormally shallow post-condylar groove.

3. Recurring dislocation of the nerve

In these injuries, the clinical picture is one of a mild irritative lesion. The nerve trunk becomes exquisitely tender and thickened, and later a definite nerve spindle or neuroma may develop.

Traumatic neuritis of the ulnar nerve may be caused by compression of the nerve by a ganglion originating in a carpal joint. Cases have been described by Seddon where the ganglion projects anteriorly at the level of the pisiform bone and comes through the flexor retinaculum to compress the main nerve. The deep branch may be compressed similarly by a ganglion at the level of the hook of the hamate, to produce a syndrome in which all the intrinsic muscles of the hand are wasted, but the hypothenar group of muscles are normal since they are supplied by the superficial branch of this nerve Removal of these ganglia is followed by prompt recovery.

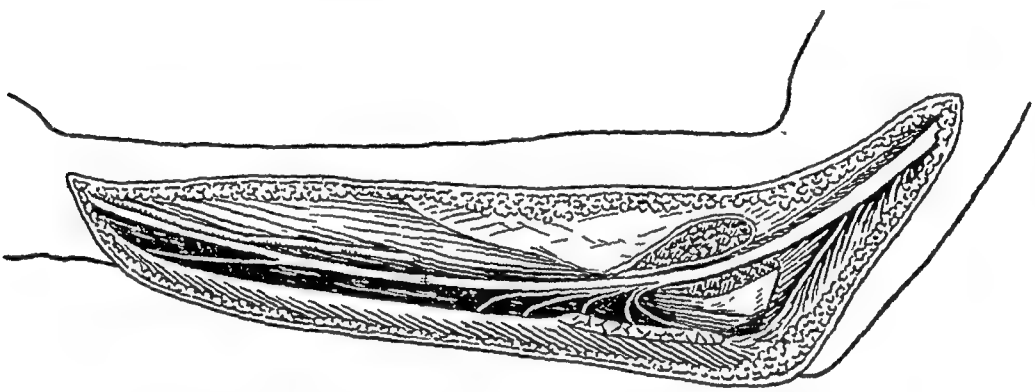

Fig 262.—Diagram showing the method of transposing the Ulnar Nerve to obtain end-to-end Suture after considerable loss of Nerve Length.

Osborne has pointed out how another form of spontaneous ulnar nerve paresis may occur The ulnar nerve at the distal end of the posterior-condylar groove passes into the forearm beneath a tendinous arch, bridging the two heads of the flexor carpi ulnaris muscle. This fibrous or aponeurotic arch is fixed above to the medial condyle and below to the olecranon The effect of flexion of the elbow is to separate these attachments and thus to tighten the band across the superficial surface of the ulnar nerve. In certain cases the capacity of the tunnel created by the band superficially and the joint beneath reaches a critical volume with flexion of the elbow causing compression of the ulnar nerve which, if prolonged, results in an ulnar paresis Osborne believes transposition of the nerve is rarely necessary but in persistent cases simple division of the band should be effective.

Treatment

Lesions of the ulnar nerve are treated on the lines already laid down. In addition, however, anterior transposition of the nerve has a wide application

This operation is indicated in all extensive injuries, where there is a considerable gap to be bridged, in all lesions of the nerve in the region of the post-condylar groove, and in recurring dislocation of the nerve. The incision follows the course of the nerve in the upper third of the forearm and the lower third of the arm, midway between the medial condyle and the olecranon. The trunk is exposed in the whole extent of the incision and mobilized from its bed behind the epicondyle. The articular branch is sacrificed, but the motor branches are stripped up as far as possible so that the nerve trunk can be displaced easily to the front.



Fig. 263.—Lesion of the Median and Ulnar Nerves.

A new bed is then constructed in front of the epicondyle, by division of the aponeurosis covering the common origin of the flexor muscles, and the superficial muscular fibres themselves. The nerve is now laid in its new bed. It will be seen, however, that as it runs forwards, it crosses the tense bridge formed by the medial intermuscular septum and it is necessary to resect a portion of the septum large enough to accommodate the nerve trunk. The divided muscle fibres and fascia are then sutured over the nerve.

Fig. 264.—Lesion of the Median and Ulnar Nerves from Gun-shot Wound.

The Radial Nerve

The radial nerve is one of the most frequently injured of all nerves. Its intimate relation to the humerus explains its common association with lesions, especially fractures, of that bone. If it escapes injury when the actual fracture is sustained, it may later become involved in the scar contracture of the soft tissues or in callus formation at the site of the fracture. The nerve may be injured also by the pressure of a crutch in the axilla, while it may be contused when the arm is left hanging over the back of a chair for a long period, as in a drunken sleep.

Clinical Features

The paralysis affects the extensor group of muscles—the brachioradialis, the radial and ulnar carpal extensors, and the extensors of the thumb and fingers—so that there at once results a characteristic drop

wrist. Paralysis of the triceps muscle is very rare, as all the branches supplying it arise before or just as the main trunk enters the radial groove.

The sensory signs are trivial. When the lesion is in the upper third of the arm there is a small, ill-defined, triangular zone of anæsthesia on the dorsum of the hand over the first interosseous space. In lesions below the origin of the lowest lateral cutaneous branch there is little sensory loss at all, while trophic changes are also absent.

Diagnosis

The diagnosis is rarely in doubt. The wrist drop of lead palsy is usually bilateral, and the paralysis incomplete, the brachio-radialis remaining unaffected. It should be remembered that the inter-phalangeal joints of the fingers are extended by the interossei and lumbricals, and that it is the metacarpo-phalangeal joint that is extended by the muscles supplied by the radial nerve, though the lumbricals have an unopposed action on the metacarpo-phalangeal joint in radial lesions as flexors. The grip is very materially weakened in radial paralysis, because the flexors of the fingers are placed at a mechanical disadvantage

Fig 265 —Compound Fracture of the Humerus with Involvement of the Radial Nerve and Wrist Drop

Prognosis

The results of suture of this nerve may be better than others and one can usually anticipate some recovery in all the muscles after a long delay Every effort should be made to secure an end to end union.

Treatment

Since the nerve is almost wholly a motor one, and the amount of sensory recovery unimportant, the results of suture should be good. Lesions of the nerve are treated on the lines already laid down, but in extensive lesions, where there is a considerable gap in the nerve tissue, the defect can sometimes be diminished by transposing the nerve

Transposition of the Radial Nerve. The nerve between the lesion and the axilla is exposed by an incision on the medial side of

the arm, care being taken to avoid injuring the motor branches which come off opposite the insertion of the latissimus dorsi The nerve is traced to the site of the lesion, which is usually in the upper part of the radial groove Through a separate incision overlying it, the nerve is then exposed at the junction of the middle and lower thirds of the arm, and again traced upwards to the site of injury. The two dissections can usually be made to meet without actually joining the skin incisions, and without cutting the lateral head of the triceps. The affected portion of the nerve is excised and an oblique tunnel made in an upward direction along the front of the humerus through the deepest part of the brachialis muscle. Forceps are passed down the tunnel, and the lower end of the nerve grasped and pulled upwards until it emerges near the upper end. At this point, it is sutured to the upper stump.

If the lesion is situated at the lower end of the groove, the upper stump is pulled from above downward through the tunnel and united to the lower stump at the lower end of the groove. After the operation, the elbow is maintained in a position of full flexion, with the forearm pronated. By this procedure, a full inch may be gained; that is to say, ends which would have remained an inch apart without transposition can, by employing this method, be sutured together.

After all operations on the radial nerve, a special splint is necessary to maintain the hand and wrist in dorsiflexion. The fingers should be kept a little short of full extension, while the thumb should be kept extended in the position it takes up when grasping a tumbler It should be noted that in division and repair of the radial nerve about the mid-humeral level, recovery may not be observed for at least 120 days

Where the lesion of the radial nerve is so extensive that even after transposition the divided ends cannot be brought together, the motor paralysis can be dealt with most satisfactorily by tendon transplantation Most gratifying results are obtained by this operation when the patient is suitable, i.e where he has the necessary intelligence to take full advantage of the new muscular movements

Tendon Transplantation for Complete Radial Paralysis. With the forearm pronated, a dorsal mid-line incision is made from the back of the wrist joint, to the middle of the forearm; from there it deviates to the radial side for about 2 inches, in order that the insertion of the pronator teres may be freed easily from the middle of the radius. The interval between the bellies of the extensor communis and the extensor carpi radialis brevis is defined and opened up, and the insertion of the pronator detached from the radius with a periosteal elevator. The tendon is flat and broad, so that care must be taken to obtain it long enough and strong enough for suture. When the tendon has been detached it is pulled on, and the belly freed by blunt dissection from the flexor carpi radialis, with which it is intimately associated The radial carpal extensors are freed by opening the deep fascia over them and the two muscles retracted.

Anastomosis forceps are now placed on the free pronator, and the dissection of the extensor tendons continued down to the wrist joint. The common extensor sheath is opened just above the dorsal carpal ligament, and each tendon isolated so that individually it pulls freely

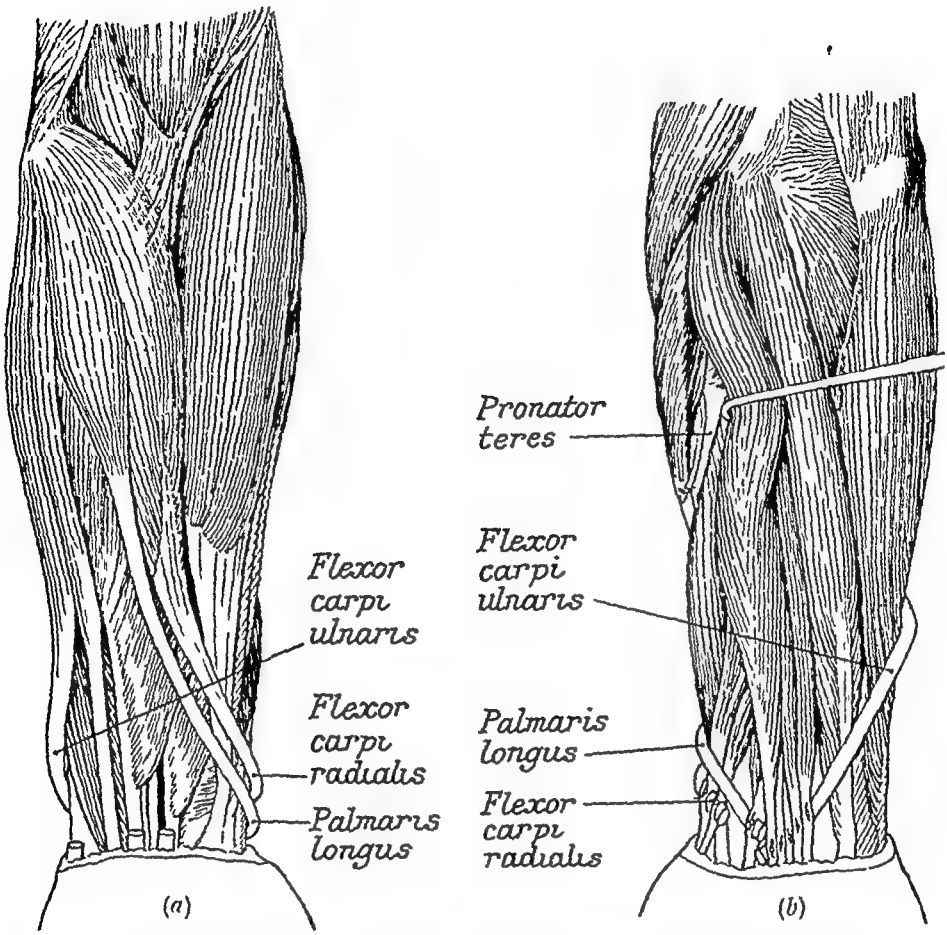

FIG. 266 —Method of Tendon Transplantation for Radial Paralysis.

(a) Anterior view showing the 3 tendons divided and transposed round the lateral and medial aspects of the lower forearm

(b) Posterior view showing the transplantation of the 3 long tendons at the wrist, and of the pronator teres higher up

to its insertion. The common extensors are then retracted medially, and the extensor longus pollicis picked up, with the extensor indicis proprius lying along its ulnar aspect The skin edges of the dorsum are now held together with Lane's forceps, while incisions are made on the front of the forearm.

An incision is next made along the radial border of the flexor carpi ulnaris tendon which is dissected free from its muscular fibres up to the middle of the forearm, and divided opposite the wrist joint. The skin between the volar and the dorsal wounds is next undermined, so that communicating tunnels are formed between the front and back of the forearm The flexor carpi ulnaris is passed through the tunnel and clipped with anastomosis forceps to the dorsal incision.

A third incision is made along the radial border of the flexor carpi radialis tendon in the lower two-thirds of the forearm. The tendon is isolated, divided at the level of the wrist joint, and freed up to the level of its fleshy belly. If the palmaris longus be present it is similarly freed and detached, but, when absent, the tendon of the flexor carpi radialis may be slit longitudinally and so divided into two separate portions

A tunnel is now made round the radial border of the limb to the back of the forearm, and the palmaris longus and the flexor carpi radialis threaded through it and clipped in the dorsal incision. The anterior wounds are now closed

For the rest of the operation the wrist, fingers, and thumb are kept in the fully dorsiflexed position by a second assistant. The pronator teres is now threaded through the two radial extensors after the latter have been pierced by a tenotomy knife. The tendons are held taut, the pronator being pulled distally and the extensors proximally, until thread stitches are inserted.

The tendons of the abductor pollicis longus and extensor pollicis brevis are exposed above the wrist joint. Their tendon sheath is opened, and the muscles freed; into them the flexor carpi radialis is now transplanted. A slit, half an inch long, is made in the two paralysed tendons by a tenotome, and through it the flexor carpi radialis is pulled. The tendons are then pulled taut, and with the thumb in extension they are stitched with No 60 linen thread From this point to the end of the operation, the thumb must be kept fully extended at both its joints

The palmaris longus is transplanted into the extensor pollicis longus, and the flexor carpi ulnaris to the extensor digiti quinti proprius, the

Tendon Transplantation for Radial Paralysis

Active Muscles	Paralysed Muscles
Pronator radii teres (Median)	Extensor carpi radialis longus Extensor carpi radialis brevis
Palmaris longus (Median)	Extensor pollicis longus
Flexor carpi radialis (Median)	Extensor pollicis brevis Abductor pollicis longus
Flexor carpi ulnaris (Ulnar)	Extensor communis Extensor indicis Extensor minimi digiti

If the palmaris longus is absent the tendon of the flexor carpi radialis is split into two halves and one used in place of the absent muscle.

tendons of the extensor digitorum communis, and the extensor indicis proprius.

After the wound has been sutured, liberal dressings are applied, and the limb put in a cock-up splint so that the fingers, thumb, and wrist are kept rigidly dorsiflexed. The dressings are left on for several days—in fact, they need not be removed, unless there is some special indication, until the time for the removal of the stitches, i e. in about ten days

There is considerable pain for about forty-eight hours, but this can be controlled satisfactorily by the use of morphia, provided the dressings have not been applied too tightly. The tips of the patient's fingers should be left exposed so that the condition of the circulation can be watched.

Summary of the Transplantation. 1 The pronator teres is transplanted into the extensor carpi radialis longus and brevis.

2. The flexor carpi radialis is inserted into the abductor pollicis longus and the extensor pollicis brevis.

3. The palmaris longus, if present, is transplanted to the extensor pollicis longus.

4. The tendinous portion of the flexor carpi ulnaris is inserted into the extensor digitorum communis, extensor indicis proprius, and extensor digiti quinti proprius.

The Circumflex Nerve

This nerve may be injured in dislocations of the shoulder, and in fractures of the neck of the humerus. Cases are also on record in which the nerve has been inadvertently divided in exposing the shoulder joint.

Clinical Features

The nerve supplies the deltoid, and teres minor muscles, as well as the shoulder joint and the skin over the deltoid Paralysis of the deltoid is therefore the main result of a lesion of the nerve The patient is unable to abduct the arm at the shoulder joint, while there is diminution in the power of flexion and extension, these movements being to a considerable extent initiated by the deltoid.

Sensation is decreased in the skin over the middle of the deltoid; the loss is seldom complete, there being only hypoæsthesia of the lateral surface of the shoulder

Treatment

The nerve may be exposed in the axilla or at the level of the surgical neck of the humerus

(*i*) *In the Axilla.* With the arm abducted and laterally rotated, an incision about 7 inches long is made in the line of the great vessels, with its mid-point over the proximal border of the latissimus dorsi tendon. The pectoralis major is retracted upwards, but if it obstructs

(*b*) *Sensory Signs.* There is a wide zone of anæsthesia involving the hand, forearm, and part of the arm.

(*c*) *Vaso-motor and Trophic Signs.* If the lesion is complete, these symptoms are slight. More commonly, from irritation by scar tissue, gross fibrosis and degenerative changes are manifest in the tissues of the hand.

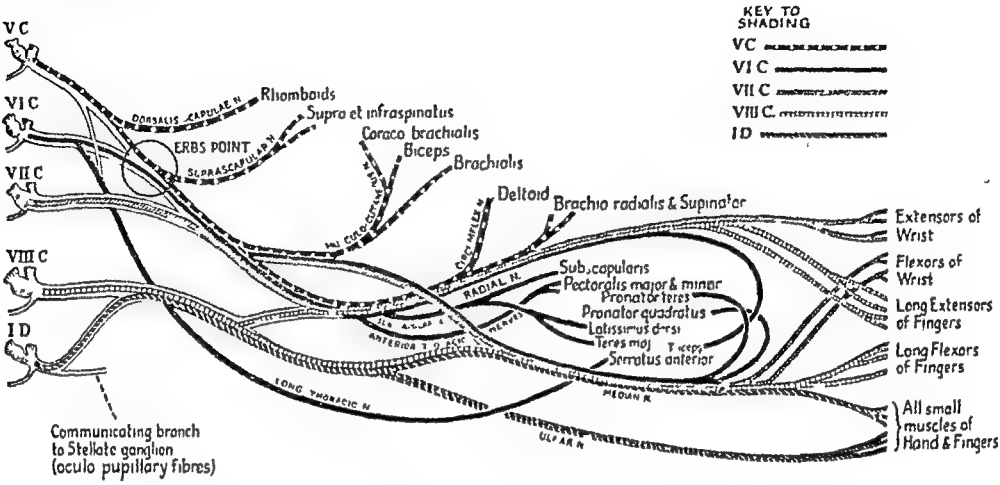

FIG 267 —Obstetrical Paralysis (Upper Arm Type)

Schematic diagram illustrating the distribution of the brachial plexus The ring indicates the common situation of injury (after Quervain)

(*d*) *Sympathetic Signs* When the eighth cervical and first thoracic nerves are injured close to the intervertebral foramina, the oculo-pupillary and other sympathetic fibres which run with them are implicated The pupil is contracted, and fails to react to light

2. Upper Arm Syndrome. (Erb-Duchenne type)

This syndrome is evidence of a combined lesion of the fifth and sixth cervical nerves, either below their junction or at Erb's point, that is to say, proximal to the origin of the suprascapular but distal to the origin of the long thoracic and dorso-scapular nerves; the serratus anterior and the rhomboids are unaffected.

(*a*) *Motor Signs.* There is paralysis of the deltoid, teres minor, supraspinatus, infraspinatus, and the clavicular head of pectoralis major The arm is therefore rotated internally by the latissimus dorsi and sternal head of pectoralis major. The biceps and brachioradialis are paralysed and the brachialis weakened; the elbow is extended by the triceps The supinators of the forearm are affected and the forearm is pronated by the pronator quadratus (pronator teres being supplied by C6) alone The radial extensors of the wrist are paralysed, resulting in ulnar deviation of the hand.

(*b*) Sensory signs are absent if the lesion is confined to the anterior primary ramus of C5, but if C6 is affected there is some loss of sensation on the lateral aspects of the arm and forearm. Vasomotor and sympathetic signs are absent.

The Root Supply of the Plexus. Many of the large muscles are innervated from several segments, but usually isolated injuries of the plexus bear very heavily on certain muscles. The following table gives the commonest effects of section of the individual roots in terms of paralysis:

C 5 Rhomboids, deltoid, spinati, biceps, brachialis, clavicular head of the pectoralis major.
C 6 Sternal head of pectoralis major and triceps
C.7. Extensors of wrist and fingers
C.8 Flexors of wrist and fingers
T.1. Intrinsic muscles of hand (and cervical sympathetic).

The lowest root of the plexus carries in it for a short distance some of the sympathetic fibres which have left the cord in the anterior roots of the first and second thoracic segments Rupture of the former root will therefore be accompanied by Horner's syndrome as well as by paralysis of the small muscles of the hand The lesion must be close to the spine to affect the sympathetic fibres, as these leave the nerve after a very short course.

Injury may affect the nerve roots proper, their anterior primary divisions, the primary plexus trunks, the cords, or the branches of distribution, either separately or in combination. The injuries are more commonly grouped on a topographical basis as supra-clavicular and infra-clavicular lesions.

Supra-clavicular Lesions.

These are caused by·

(*a*) Traction lesions from over-stretching, as in the familiar obstetrical palsy.

(*b*) Penetrating wounds.

(*c*) Friction or compression lesions associated with rudimentary cervical rib.

Infra-clavicular Lesions.

These are produced by:

(*a*) Contusion or compression lesions, associated with shoulder-joint dislocation.

(*b*) Penetrating injuries

These lesions are divided into three groups, according to their clinical features—the lesion of the complete plexus, the upper arm syndrome, and the lower arm syndrome

1. The Complete Plexus Syndrome.

(*a*) *Motor Signs* There is a complete paralysis of all the muscles of the hand, forearm, and upper arm The rhomboids and the serratus anterior remain unaffected, however, unless the injury is at the level of the cervical transverse processes.

OBSTETRICAL PARALYSIS

Paralysis of one or both upper extremities occasionally follows the birth of a child. This is more common when the labour is complicated by obstetrical difficulties which necessitate forcible manipulation or traction on the arm. the condition is accordingly known as "obstetrical paralysis."

Etiology

The paralysis is the sequel to a lesion of the cords of the brachial plexus whereby they are stretched, and not due to the results of a dislocation of the shoulder.

Sever pointed out that traction on the arm in adduction puts the upper cords of the plexus, which arise from the fifth and sixth cervical roots, under the greatest amount of tension, and causes them to stand out like bow-strings. If the tension is aggravated, the cords are liable to be injured.

Thomas thinks that the paralysis is due to the inclusion of branches of the brachial plexus in the axillary inflammation which follows upon the joint injury.

Steindler holds that neither of these theories can be accepted to the entire exclusion of the other, and there seems to be no reason why gross lesions of the shoulder joint should not be combined in a number of cases with injuries to the nerve roots.

Varieties. There are three varieties of obstetrical paralysis.

(*i*) *The upper arm type*, or the Erb-Duchenne paralysis, which results, according to the supporters of the neurogenetic theory, from downward traction exerted on the arm. The shoulder is forcibly separated from the neck, beyond its normal limits, and the fifth and sixth cervical roots are consequently over-stretched.

(*ii*) *The lower arm*, or the Klumpke type, which is said to result when the arm is pulled upwards above the head and the eighth cervical and first thoracic roots over-stretched.

(*iii*) *The whole arm type*, where the exciting cause has been one of unusual severity, and all the cords of the plexus have been to some extent involved Sever found that in his series of cases the incidence of the three types was as follows: upper arm, 400; whole arm, 64; and mixed arm type, 9.

Clinical Features

Upper Arm Type. Soon after birth the affected arm is seen to hang loosely at the side of the body; the forearm is pronated and the elbow slightly flexed, while the child is unable to abduct the arm. For the first few days after birth some swelling or tenderness may be observed in the region of the deltoid, but this usually subsides, leaving a paralysis of the deltoid, supra-spinatus, biceps, coraco-brachialis,

3. The Lower Arm Syndrome. (Aran-Duchenne.)

This is most commonly seen in obstetrical paralysis. The lesion usually affects the first thoracic nerve but may involve the whole lower trunk (C8 and T1).

(*a*) *Motor Signs.* The intrinsic muscles of the hand are paralysed and a claw-hand deformity results, the interphalangeal joints being flexed and the metacarpo-phalangeal joints hyperextended. Paralysis of the flexors and extensors of the fingers may follow lesions of the entire lower trunk.

(*b*) *Sensory Signs* The zone of anæsthesia includes the ulnar side of the hand and forearm, and a narrow strip of the arm.

When the first thoracic nerve is injured proximal to the point of origin of its white ramus communicans oculo-pupillary symptoms are a characteristic feature and the paralysis is known as Klumpke's paralysis.

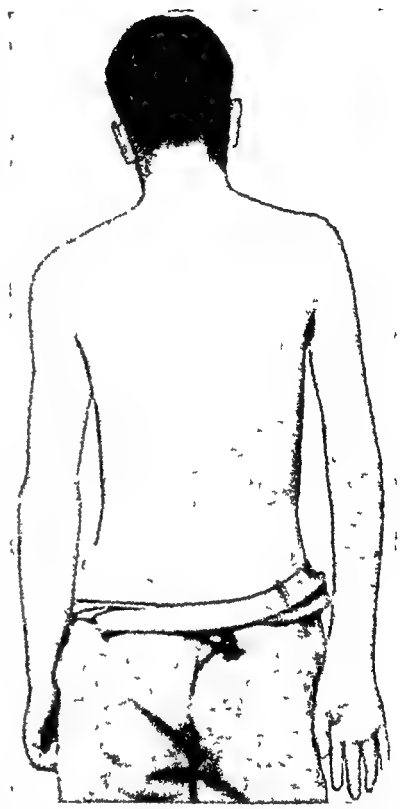

Fig 268 —Lesion of the Brachial Plexus

The arm and hand are completely paralysed and wasted and held in the characteristic attitude

The Cervical Sympathetic

The sympathetic trunk may be injured by penetrating wounds in the lower part of the neck, or in the course of operation in the deep triangle. The oculo-pupillary fibres which leave the spinal cord through the anterior roots of the first and second thoracic nerves are also occasionally injured in lesions of the brachial plexus

Signs of paralysis of the cervical sympathetic (Horner's Syndrome) are obvious on inspection, and are due to interference with the conduction.

(1) Drooping of the upper lid
(2) Narrowing of the palpebral fissure.
(3) Retrogression of the eyeball.
(4) Contraction of the pupil.
(5) Loss of the cilio-spinal reflex. Normally the pupil dilates when the skin of the neck is pinched, but when the sympathetic is paralysed this reflex is lost.
(6) Absence of sweating in the whole of the upper limb, the upper part of the chest, neck, and half of the face, the area being accurately delimited by the middle line.

When the sympathetic trunk is irritated, as by the presence of scar tissue, an exactly opposite train of symptoms arises.

lesion at an earlier date. In all cases of the upper arm type, the prognosis is good, but in the lower arm and whole arm forms the restoration of function is unlikely.

Treatment

Treatment should be instituted at the earliest possible moment, as in the milder cases considerable improvement may be expected from conservative treatment alone.

When there is no hope of recovery it may be possible, by reconstructive operations, to make the limb less of an encumbrance, and even an asset It has always been most difficult, even at exploration, to decide whether any further recovery can be hoped for or whether reconstructive surgery should be carried out However, Bonney (1954) has described a test in which the vasodilation response to an intradermal injection of histamine in the finger-tips is observed. A positive response suggests a preganglionic lesion close to the cord with a very poor prognosis for recovery and therefore reconstructive procedures should be carried out early Hendry says that even when the limb is almost flail, a forearm which can project forwards by the construction of a bone block behind the elbow, with arthrodesis of the shoulder when necessary; a hand with fingers in the form of a claw and a thumb which opposes them; and a wrist which may perhaps be arthrodesed, but which, still better, can flex or extend when the forearm is pronated or supinated; together with the wise use of such muscles as are likely to gain function, may enable a patient to do very much more than he can with an artificial limb.

If contracture is present in these earlier cases, it will usually yield to simple stretching, with or without anæsthesia Thereafter the extremity is securely immobilized on a type of abduction splint, with the arm abducted and rotated laterally, the elbow flexed to a right angle, the forearm supinated, and the wrist dorsiflexed The splint should be worn night and day, and be removed only for purposes of massage and passive exercise. It is retained for at least six months, after which the arm may be carried in a sling, except that in lower arm types the wrist should still be kept in the dorsiflexed position by means of a cock-up splint The child, as soon as he is old enough, should be taught to play with toys or perform simple games so as to encourage voluntary movements of the affected muscles

Cases with adduction contracture, which will not yield to manipulation, require an open operation for the relief of the deformity.

Sever's Operation. An incision is made from the acromion process downwards over the anterior aspect of the shoulder. The interval between the deltoid and the pectoralis major muscle is defined, and these muscles retracted to either side. The upper part of the pectoral muscle is then divided, at or near its tendinous insertion, in order to give better access to the head of the humerus. The subscapularis tendon is then located as it swings across the head of the

and brachio-radialis. Contractures soon develop from the unopposed action of the adductors and medial rotators of the shoulder.

In many cases the paralysis of the deltoid and supra-spinatus is only temporary, and with the repair of the injured nerve these muscles begin to function again. In the early stages, therefore, the greatest care must be taken to prevent the formation of adduction contractures The cases in which the nerve lesion fails to heal, and in which the muscle paralysis is permanent, form a small minority The typical course consists of a temporary paralysis, followed by a permanent contracture In some cases the contracture may even be complicated by subluxation or dislocation of the shoulder joint.

The Whole Arm Type. In a small proportion of cases, the lesion involves all the cords, so that not only are the muscles of the shoulder affected, but also those of the arm, the forearm, and the hand. In these cases the paralysis of the intrinsic muscles of the hand, together with that of the muscles of the shoulder, is liable to persist The lesion involves especially the fifth and sixth cervical roots, and the ulnar and median nerves, which are derived from the eighth cervical and first thoracic roots

The Lower Arm Type. In this type there may be at first paralysis of the whole arm, followed by a quick recovery of the muscles of the upper arm, those supplied by the lower segment of the plexus remaining more or less permanently paralysed The resulting paralysis is then of the inferior radicular group or Klumpke type

In the whole arm and the lower arm types, sensory disturbances are present The anæsthesia is usually complete in the forearm and on the lateral side of the arm, but the medial aspect of the arm is unaffected, owing to the distribution of the inter-costo-brachial nerve. Frequently, also, in the inferior radicular type, there are oculo-pupillary signs—miosis, pupillary contraction, and recession of the eyeball

Sometimes associated are injuries in the region of the shoulder joint: fracture of the clavicle, separation of the upper humeral epiphysis, and dislocation of the head of the humerus Fracture of the clavicle greatly facilitates a rupture or tear of the plexus, especially of the lower cords The dislocation of the humerus is usually a posterior one, although the anterior form has also been described.

The injury to the nerve roots is usually limited to the sheath, but in some cases the roots may be completely torn across When the sheath is injured, the paralysis in the early stages is due to the resultant hæmorrhage and the œdema, but later the formation of scar tissue may also play a part The exact situation of the lesion is generally close to the point of exit of the roots from the vertebral column, but in some cases the lesion is stated to have been actually within the canal

Prognosis

A minority of cases recover completely in three months, and it is therefore impossible to determine clinically the exact extent of the

exposure of the injured nerve roots would be indicated. Attempts to repair the lesion, however, have been unrewarding and even exploration has been decried because it yields little information of value and some which may mislead

The Exploratory Operation. An incision is made from the sterno-clavicular joint upward and outwards; the deep fascia is divided, exposing the omohyoid and the transverse cervical vessels. These vessels are ligated, along with the transverse scapular artery, and the thickened and adherent fascia divided to expose the plexus. The lesion is generally found at the junction of the fifth and sixth roots, which are usually enveloped in scar tissue. The scar tissue is carefully excised with a sharp knife, and the nerve-ends, if completely divided, should be brought together by sutures of fine linen thread which pass through only their sheaths. After the wound is closed, a plaster-of-Paris splint is applied which keeps the head and shoulders approximated to each other.

In extensive lesions it may be necessary, in order to secure coaptation, to divide the clavicle and the subclavian muscle. If, after this, the shoulder is elevated and the head flexed towards the affected side, a gap of as much as 3 cms can be bridged.

The Sciatic Nerve

The sciatic nerve may be injured in deep wounds of the thigh, especially gunshot wounds, while its lateral popliteal branch may be implicated in comminuted fractures of the head of the fibula Since the nerve is very superficial at this point, it may also suffer in association with incised wounds of the same region.

Clinical Features

In a complete lesion of the sciatic nerve there is usually paralysis of all the muscles below the knee, but the hamstrings rarely suffer. In partial injuries, it is common to find the common peroneal motor syndrome predominating Sensation is abolished in the foot over a zone conveniently termed the "slipper" area Ulceration frequently occurs from loss of trophic influences, the ulcers being usually under the fifth metatarsal head, on the sole of the foot, or the terminal phalanx of the great toe Such ulcers are very intractable—they perforate deeply, and infection and necrosis of bone often follow. In partial lesions, the sensory phenomena are those of the irritation syndrome, and after gunshot wounds a true causalgia frequently develops.

The Lateral Popliteal Nerve

The lateral popliteal nerve supplies the tibialis anterior, the extensor digitorum longus, the extensor hallucis longus, the extensor digitorum brevis, and the long and short peroneal muscles Paresis of these muscles results in plantar flexion and inversion of the foot, along with a certain

humerus to the lesser tuberosity. A blunt director is passed deep to it, between it and the capsule, and the tendon severed. The arm can now be completely laterally rotated. The muscles are allowed to fall together, the wound is closed, and the arm is put up in plaster in abduction and lateral rotation for two weeks, after which a splint is applied as previously described

Some authorities advocate osteotomy of the humerus, with subsequent lateral rotation of the lower fragment In severe cases the coraco-humeral ligament close to the biceps, the short head of the biceps, and, if necessary, the coraco-brachialis should be divided.

The Repair of the Lesion. The possibility of repairing the injured nerve roots is a matter of considerable uncertainty. Theoretically, exploration is indicated when there is no spontaneous return of muscle function, but it is difficult to decide how long one is justified in waiting. If, however, there is no improvement in 3 to 6 months,

Nerve and Roots	Muscles Supplied	If Paralysed	Deformity Produced
Femoral L2, 3, and 4	Quadriceps Sartorius Pectineus	Inability to extend lower leg Absence of knee reflex. Paralysis of ilio-psoas evidenced by inability to flex hip.	Gait disturbed Patient stepping carefully, avoiding flexion of knee
Obturator L2, 3 and 4	Adductor longus. Adductor brevis. Adductor magnus Gracilis. Obturator externus	Adduction and to a slight extent external and internal rotation impaired	
Inferior gluteal L5, S1 and 2	Gluteus maximus.	Abduction and particularly extension at hip joint hampered	In walking, leg swings too far inwards, also excessive lifting and sinking and forward tilting of pelvis
Superior gluteal L4, 5, S1, 2	Gluteus medius Gluteus minimus Tensor fasciæ femoris.	Loss of abduction and circumduction of thigh	
Medial popliteal L4, 5, S1, 2	Gastrocnemius Soleus Tibialis posticus. Flexor communis digitorum. Flexor longus hallucis	Loss of plantar flexion of foot and toes Patient unable to lift himself upon tips of his toes. Walking difficult.	Claw position of toe (pied en griffe), pes calcaneus or valgus.
Lateral popliteal. L4, 5, S1, 2	Tibialis anticus. Extensor proprius hallucis Extensor longus digitorum. Peronei. Extensor brevis digitorum.	Foot falls from its own weight, and cannot be raised, nor can first phalanx be extended Walking difficult, toes scrape the floor	"Foot-drop" Foot remains in equino-varus position.

the limb can be obtained R B. Zachary (1954) has emphasized that poor neurological recovery is not an indication to amputate. Amputation has, in most cases, been carried out for poor function arising from deformity and ulceration, and these are preventable to some degree by care of the skin of the foot and reconstructive procedures.

FIG 269 —The Sciatic Nerve The effects of a perforating ulcer of the foot developed as a result of a trophic disturbance in a case of sciatic paralysis

The ulcer has penetrated to the fifth and fourth metatarsals, parts of which have been eroded

The Medial Popliteal Nerve

This branch of the sciatic supplies the posterior muscles of the leg, and all the plantar muscles, so that, when divided, there is a complete inability both to plantar flex the foot, and to flex the toes Walking is not grossly interfered with by this paralysis, and it may therefore easily pass unnoticed. The patient puts his foot down flat and does not lift the heel from the ground. He walks with a splay foot, without spring or elasticity. The anæsthesia affects the sole and the dorsal surface of the lateral four toes, and this lesion is, more frequently than the peroneal, followed by trophic disturbances—cyanosis of the foot, hyperæsthesia, and especially ulceration

The healing of a trophic ulcer is often prevented by hard thickened skin around it This obstructs the circulation so must be removed to allow the formation of granulation tissue. Accordingly excision is the best form of treatment.

Causalgia.

The term Causalgia is used to describe a bizarre syndrome resulting from injury to peripheral nerves Its cardinal features are the subjective complaint of intense burning pain in association with trophic and vasomotor changes in the injured extremity Its cause is unknown and, indeed, there is some confusion as to what constitutes a case of this

degree of flattening of the long arch, which is normally maintained to some extent by the tibialis anterior and the peroneus longus. The patient walks with a high stepping gait, the foot being elevated to allow the dropped toes to clear the ground

Anæsthesia is noted only over a small triangular area opposite the first metatarsal space.

Gairland and Moorhouse (1952) have described common compressive lesions affecting the lateral popliteal nerve as it lies superficially against the head and neck of the fibula This can result from simply sitting and crossing one leg over the other, or kneeling, or wearing knee-pads or bandages This may produce complete motor paralysis with little sensory loss

Treatment consists of active exercises and the wearing of a foot-drop appliance if necessary.

The Anterior Tibial Syndrome

A syndrome occurring in fit young men and consisting of ischæmic necrosis of the muscles of the anterior tibial compartment of the leg with a lesion of the lateral popliteal nerve, is not uncommon. The symptoms usually follow exertion involving strenuous use of the leg muscles.

Clinically there is pain in front of the leg followed by signs of inflammation of the pre-tibial muscles and paresis of the dorsiflexors of the foot and toes. The peroneal muscles are not involved and the foot-drop is minimal because of contracture of the ischæmic muscles. Barham Carter *et al*, discussing the pathogenesis of the syndrome, consider that the sequence of events is . unaccustomed exercise—muscle trauma—increased pressure within the anterior tibial compartment—impaired blood supply to the affected muscles—ischæmic necrosis. Spasm of the anterior tibial artery is believed by Hughes to be the most likely cause The nerve is involved either by compression (in which case it recovers rapidly) or by ischæmia (in which case the loss of function is permanent) Barham Carter believes the condition can be prevented by graduated physical training If the syndrome is recognized early, rest alone may prevent irreversible damage to the muscles; but if paralysis has developed surgical decompression of the anterior tibial compartment as an emergency measure is advocated.

The lateral popliteal nerve is occasionally the site of a myxoma. This produces a local swelling, usually in the region of the fibular neck, followed by paresis of the nerve This greyish gelatinous material is encountered at operation and this may track down the leg for some distance. A complete cure may necessitate the resection of a considerable length of the nerve.

Prognosis

Although suture of the sciatic nerve can be carried out satisfactorily, neurological recovery is never complete. Even so, good function of

of success have been reported with drugs and physiotherapy. Interruption of the sympathetic chain has consistently been the most efficacious procedure and the results of pre-ganglionic section are superior to those of post-ganglionic sympathectomy. Interruption of the appropriate sympathetic chain by the appropriate block, sometimes repeated several times, is followed by dramatic relief. It is instantaneous and absolute, and is maintained for intervals of from one to three hours, after which the pain returns. This is a definite indication for permanent division by sympathectomy, and, in the case of the leg, the second, third and fourth lumbar ganglia are removed and usually the patient is free of pain on waking and remains so. Similarly, in arm cases an appropriate pre-ganglionic resection is followed by dramatic relief. The operation should be done early to prevent the crippling deformity of the joints which follows prolonged voluntary immobilization of the painful limb. Slessor (1951) considers that the result is obtained by its interrupting the efferent impulses as well as by preventing cross-stimulation of the pain-bearing fibres at the level of the injury.

In cases of phantom limb the futility of repeated amputation is becoming widely realized. If simple retrimming fails to relieve the pain, sympathetic block with local anæsthetic should be tried. One or more injections of the local anæsthetic or an appropriate sympathectomy may be successful, but if such fail the contralateral spinothalamic tract should be divided well above the level at which the plexus from the limb joins the cord. This cordotomy should not be unduly delayed in cases in which the symptoms are severe lest pain fixation becomes a cerebral condition for which such procedures as post-central cortical ablation or frontal leucotomy may have to be considered. Success with such measures have been reported. Doupe and his co-workers put forward the suggestion that the underlying cause of such conditions is a cross union or fusion of the efferent sympathetic fibres with sensory axones. They believe this may either occur at the site of injury to the nerve or at a point distal to it as the result of a breakdown of insulation. They found, too, that temporary sympathetic block gave immediate relief from pain even in patients demoralized by long-standing severe pain, and sympathectomy gave permanent relief.

condition, since some include Sudeck's atrophy, painful phantom limb, and the so-called minor causalgias.

The distribution is usually that of the median or sciatic nerve and the nerve lesion in most cases is usually of an incomplete nature

The pain is usually in the distal part of an extremity, either the palm of the hand or the dorsum of the foot, but not confined to the autonomous zone of the injured nerve. Some patients have warm skin and others cold, but whichever it is, it is usually glossy and shiny and there is loss of hair from the trophic effect The burning pain usually comes on within a few hours of the moment of injury. It is of an intense burning nature and the intensity varies with emotional stimuli such as anxiety, anger or fear. Noises such as the scraping of a chair, tearing of a paper, or loud music cause intense suffering Lighting the room without warning often provokes a severe paroxysm of pain Hydromania is sometimes marked—that is, the patient wishes to keep not only the affected limb but also other parts of the body wet. The patients usually exercise great care to prevent the part being touched, particularly by rough objects In severe cases the patients are poorly nourished, due to low food intake, are irritable, show no interest in their family or friends, prefer to be alone in a dark room, and are unduly critical of attendants. This severe type of causalgia is rarely seen now and the common type, although still very infrequent, occasionally results from injury to a digital branch of the median nerve

The history seems to suggest that the disorder might be entirely psychogenic in character. The motor and sensory loss are difficult to determine for usually the patient refuses to move the part or permit it to be touched In addition there is usually marked stiffness of the joint due to disuse.

In some cases the skin is cold, thin and glistening The superficial layers are denuded and sweating is profuse With this there is loss of hair, tapering of the digits, and a tendency for the nails to curl In other cases the skin of the painful part is warmer than that of the opposite number and the hair long and coarse The skin is relatively dry in these cases and at times actually scaly. Some are helped by warm water and some by cold. Oscillometric examination shows marked vasoconstriction in the first type of case, and vasodilation in the second The severity of the trophic changes increases with the duration of symptoms, yet the types remain unchanged X-ray shows spotty osteoporosis of the small bones of the hands and feet in cases with vasodilation The cases with vasoconstriction show demineralization of the painful part but it is not spotty.

Treatment

Success has been reported with many forms of treatment. Direct surgical attack on the nerve trunk above, below and at the level of the injury is reported to relieve the syndrome at times Varying degrees

CHAPTER XII

CIRCULATORY DISTURBANCES OF THE EXTREMITIES

Lesions of the peripheral vessels are an important and interesting cause of pain and fatigue in both the upper and lower extremities, and frequently require the attention of the orthopædic surgeon. Recent advances in our knowledge of the structure and function of the autonomic nervous system, largely based on the results of surgical procedures in human subjects, have resulted in a clearer understanding of the mechanisms underlying many of the disturbances of the peripheral circulation.

The Circulation of the Extremities. Since Claude Bernard first postulated the preservation of the "milieu interieure" as the determining factor in the freedom and independence of warm-blooded animals, evidence has accumulated regarding the important part played by the peripheral circulation in the maintenance of the necessary constancy of internal conditions. The circulation of the extremities subserves such purely local functions as the transport of the metabolic requirements and products of the tissues, the production of an inflammatory defence in response to injury, and the maintenance of local temperature at a suitable level In addition it plays an important part in the regulation of body temperature. The surface area of the extremities is about 65 per cent of that of the whole body and as the limbs are usually lightly clad a large proportion of heat loss occurs from the skin of the limbs. The capacity of the vascular bed is greater than the total volume of blood contained therein, and therefore at all times active vaso-constriction must be present in a large part of the circulatory system to ensure that vital organs receive an adequate blood supply. Unusual demands for blood in one organ are met by local vaso-dilatation or constriction in other parts of the body. The most common vaso-constrictor stimulus is cold Other factors which produce intense constriction in the extremities are fear, pain, anger, asphyxia, hæmorrhage or dehydration. Such constriction may be so intense that the cutaneous circulation may temporarily cease Vasomotor reactions are most intense in the extremities The hand, wrist, foot and ankle are the regions most commonly affected by the factors listed above, and are also the parts most exposed to trauma and the influence of environmental changes Constriction is most marked in the arterioles but also occurs in the capillaries and veins. The venous dilatation observed after sympathectomy is due at least in part to cessation of vaso-constriction.

The peripheral vessels are controlled by the autonomic nervous

(A.) THE PRIMARY VASO-MOTOR LESIONS

(1) *Vaso-constrictor Disturbances*

Raynaud's Disease

There is a tendency at present to discourage the use of the term "Raynaud's disease" on the grounds that it lacks specificity and includes a number of ill-defined and different conditions It is proposed to retain the term in this discussion, however, but to restrict it to a form of peripheral vascular disturbance usually affecting symmetrical areas of the hands and feet, characterized by intermittent pallor or cyanosis of the extremities and precipitated by exposure to cold or emotional disturbance. The smaller terminal arteries are constricted but the main vessels pulsate normally and, in the early stages, no pathological change occurs in the wall of the vessels

Raynaud's disease is ten times more common in women than in men and usually occurs after puberty and before the menopause. Its effects are most marked in the exposed parts of the limbs It is often symmetrical in distribution and may affect upper or lower, or all four extremities. Of the many individuals, mostly young emotional females, who suffer from "poor circulation," unusually cold moist hands and numbness of the fingers and toes on exposure to cold, the condition of the majority improves as they grow older, but in some it progresses and may ultimately take the form of typical attacks of Raynaud's disease. Such an attack may be initiated by exposure to cold, by excitement or embarrassment The first sign is pallor of the tips of the affected fingers, which may be followed by transient greyness as the remaining blood gives up its oxygen. In the early stages the pallor may be patchy and even intermittent but if the initiating factor continues to act spasm increases and the fingers appear more and more pallid, waxen and numb, and no fine movements can be carried out. Following relaxation of the spasm, the circulation slowly returns to the fingers, their colour becomes bright red and capillary pulsation may be noticed. The fingers swell and tingle, and there may be an intense sensation of "pins and needles" or severe pain after a prolonged attack. These symptoms of returning circulation are most marked after rapid warming following a prolonged attack.

If these attacks continue their character changes. They are more readily provoked, and, starting in the tips of the fingers or toes, affect the whole of one or more digits and may continue into the palm or sole, even as high as the wrist or ankle The colour is at first blush, becoming slaty, and finally waxen if the spasm persists, patchy colour changes indicate incomplete or intermittent spasm, the colour variations being due to influx of fresh blood Recovery occurs only following prolonged warming. As these more severe attacks become more frequent secondary changes appear in the digits; the pulp of the finger atrophies, its skin becomes smooth and glistening, and the finger tapers towards the tip

appears about the eighth day after denervation and occurs only after post-ganglionic section. Following pre-ganglionic section there is a reduction in the sensitivity of the effector cells.

Knowledge of the vaso-dilator mechanism is less complete. The inability of the peripheral arteries of a limb to dilate further after sympathectomy may be evidence of the presence of sympathetic dilator fibres in the rami divided. It is believed that other dilator fibres exist in the posterior roots of the spinal nerves, having cell beds in the root ganglion, and that these fibres are part of an axon reflex and are stimulated by an impulse through the spinal sensory fibres.

Sudomotor and pilomotor fibres are associated with those of vaso-constriction. In the hands and feet there are numerous arterio-venous anastomoses—the digital glomal system of Popoff—by means of which in response to nerve impulses, the blood flow through the part, and hence the rate and amount of heat lost, may be varied very rapidly. For this reason amongst others, vaso-spasm is more evident in the hands and feet than in other parts of the body. Vaso-constriction results in pallor and coldness and is associated with sweating. Vaso-dilatation is followed by heat, redness, and dryness of the part.

The Importance of the Capillary Area. The capillary area of the peripheral circulation is the site of the main physiological activity of the circulatory system. Interchange of oxygen and carbon dioxide, and of nutritive and waste material, between the blood and the tissues takes place through the delicate endothelium of the capillary tubes. Interference with the blood flow in this area is likely, therefore, to lead to profound changes in local tissue metabolism, temperature, and health.

Classification of the Vascular Disturbances

An arbitrary division may be made between the disturbances which are chiefly of function, the anatomy of the vessels remaining relatively normal, and those in which there are early organic changes. It must be remembered that anatomical changes will be found in the late stages of the former and that often vasospasm is an important factor in the latter group.

(*A*) *Primary Vaso-motor Lesions.*

(1) Vasoconstrictor disturbances—Raynaud's disease.
(2) Vasodilator disturbances—Acrocyanosis; Erythromelalgia.
(3) Peripheral vasoneuropathy after chilling—Immersion Foot and Immersion Hand

(*B*) *Primary Obliterative Lesions*

(1) Mechanical—Embolism and thrombosis.
(2) Inflammatory—Thrombo-angiitis obliterans.
(3) Degenerative—Arteriosclerosis

and the finer adjustments of co-ordinated movements are sluggish and awkward. A peculiar hypoæsthesia seems characteristic. This diminished sensibility does not appear to be of a hysterical nature, although evidences of a general neurotic disposition are present. The cyanosis is often bilateral and in such cases roughly symmetrical, although there may be slight differences in the intensity of the colour. As the attack passes off the part becomes warm and red, and burning pain associated with œdematous swelling is experienced. These features gradually disappear and the part returns to normal. The condition is usually most severe in the hands, probably because as a rule the feet are more adequately protected against low temperature.

Acrocyanosis resembles Raynaud's disease in its location, but there is an absence of the blanching and other features of what is known as "syncope." The absence of pain in acrocyanosis, the fact that the attacks are progressive rather than paroxysmal, and the increasing development of cyanosis, are the usual distinguishing criteria.

Pathology

It has been pointed out by Lewis that the clinical picture of acrocyanosis resembles the changes which appear when the normal hand is subjected to a low temperature. He has suggested that the condition represents a peculiar sensitivity to the effects of cold on the cutaneous arterioles of those individuals who suffer from the disease Thus a stimulus which would have little or no effect in the ordinary subject causes slowing of the cutaneous circulation due to arteriolar dilatation. This leads to anoxia, capillary dilatation, increased plasma outflow, and therefore local swelling. The dilated capillaries packed with red corpuscles impart a deep red colour which becomes blue as the oxyhæmoglobin becomes reduced, the intensity of the colour depends on the quantity of blood contained in the part.

(b) Erythromelalgia

This condition was first described in 1878 by Weir Mitchell who believed it to be a rare vaso-motor neurosis involving the extremities It is characterized by redness, burning pain, and swelling of the hands and feet brought on by heat, exercise, or the dependent position During an attack the hands and feet become intensely cold and the skin acquires a bright red colour. When the parts are warmed a feeling of swelling, fullness and throbbing is experienced Burning pain may be induced by cold, friction, tension, or elevation of the temperature of the limb to a certain critical temperature which varies with each individual Pain is brought on by such a rise of temperature irrespective of whether the rise is due to the application of external heat or to increase in blood supply produced by other means. There may be great disability, the patient being unable to tolerate any covering or pressure on the affected part. The vessels are widely dilated and capillary pulsation is present Lewis states that this condition is not

over which the nail curves Small areas of thickened skin appear on the finger-tips, especially under the nails, these plaques separate leaving small painful areas which heal very slowly Ulceration, infection, or frank dry gangrene are uncommon, but the pain may be so intense that the finger or even the hand becomes useless. These changes are usually more marked in the fingers than in the toes.

Pathology

According to Lewis there is an intermittent leakage of blood through the constricted arterioles during the stage of pallid asphyxia. The colour depends on the rate and amount of blood flow into the part and the temperature of the environment. The rate of dissociation of oxyhæmoglobin and tissue metabolism are markedly reduced at temperatures below 60 degrees Fahrenheit Thus hands dipped in ice-cold water may remain pink, while at a higher temperature there may be marked vascular spasm combined with ready dissociation of oxyhæmoglobin resulting in cyanosis. Rapid warming by plunging the hand into warm water may result in abolition of spasm with an inrush of blood into anoxic tissues, where increased metabolism and rapid dissociation of oxyhæmoglobin lead to deep cyanosis and the part "turns black" These changes are often accompanied or followed by severe pain and patients soon learn not to use such methods.

It may be that the initial fault is in the autonomic nervous system when one considers that the disease is commonest in young emotional females, is so frequently accompanied by excessive sweating, and that changes in the vessel walls are the result of prolonged vasomotor disturbances. Lewis claimed that the disorder was entirely due to an intermittent spasm of the digital arteries due to a local hypersensitivity to cold and this opinion is widely held in this country.

The late stages of Raynaud's disease are commonly associated with secondary changes, particularly in the skin and subcutaneous tissues, giving rise to the condition of scleroderma or sclerodactyly. At first the digits are swollen and firm and the skin is smooth (stage of œdema). Later they become stony hard and tense, and the skin is glistening and fixed and may appear varnished (stage of induration) Finally there is wasting and the skin becomes thinned and there may be brownish pigmentation (stage of atrophy) These changes have been recorded in the ears and nose. There is often associated ulceration and reduced growth of nails and hair.

(2) *Vaso-dilator Disturbances*

(a) Acrocyanosis

This condition most commonly affects the female sex and takes the form of a slow development of cyanosis or asphyxia of the hands and feet, generally as a result of exposure to a low temperature. The fingers and the toes become cold, the movements of the part are impaired,

"algid state," may occur during the latter part of the hyperæmic stage; both are probably due to partial interference with sympathetic innervation with sensitization to adrenaline.

The lesions have been classified by Ungley into four grades according to their severity. Those with *minimal lesions* without interference with nerve function have swollen feet for a few days and transient tingling, but symptoms subside within a week. *Mild cases with reversible nerve lesions* have symptoms for from three to six weeks with slight weakness of the intrinsic muscles of the feet; later there may be excessive sweating or cold sensitivity. Of *moderately severe cases with severe (degenerative) nerve lesions* 50 per cent. have blistering and a few superficial gangrene, anæsthesia extends nearly to the ankle joint, and muscle wasting is more marked. Symptoms may last for three months and functional return be delayed for six months *Very severe cases with irreversible (degenerative) nerve lesions, usually with gangrene,* have loss of sensation above the ankle, gangrene of the toes or distal half of the foot, infection may occur and amputation be necessary. Symptoms may last six months or more and late complications are frequent.

Early treatment follows the principle of cooling the affected limbs while warming the rest of the body; the affected areas must on no account be rubbed or heated. The limbs should be elevated and precautions taken with chemotherapy against secondary infection of raw or gangrenous areas. The patient should remain in bed until all swelling has subsided and walking is painless The late complications may be susceptible to sympathectomy.

(B.) THE PRIMARY OBLITERATIVE DISTURBANCES

General Effects The general clinical manifestations of occlusion of limb arteries are the same whatever the ætiological factor involved, and depend upon—

(1) The size of the artery involved;
(2) Rate of occlusion—sudden or gradual;
(3) Availability of a collateral blood supply;
(4) Metabolic demands upon the tissues distal to the block.

Sudden occlusion of a large peripheral artery, due to ligation, embolism or injury, is followed by pallor of the skin distal to the block and motor and sensory paralysis of varying degree Interruption of blood flow in a main vessel may be followed by generalized spasm of all the vessels distal to the obstruction and if the collateral circulation is insufficient for the needs of the limb, gangrene will follow.

If the arterial occlusion is gradual, or if the limb has survived a sudden major occlusion, the blood supply while sufficient to maintain the nutrition of the skin may not be sufficient to allow the increase necessary for exercise, and the patient may present himself with the complaint of cramp-like pain in muscles on exercise (intermittent claudication) which is quickly relieved by rest. In the leg the calf is that most

of vaso-motor origin since in normal subjects an equal degree of vaso-dilatation is not accompanied by pain. He believes that this disorder is due to a hypersensitivity of the pain fibres to heat or tension. Telford and Simmons have suggested sympathectomy in the treatment of this condition, arguing that the vessels of a sympathectomized limb are incapable of dilatation as well as of constriction. Following such operation pain is abolished and the circulation returns to normal.

(3) *Peripheral Vasoneuropathy after chilling*

Immersion Foot and Immersion Hand.

These disturbances, for which Ungley has suggested the alternative term of "peripheral vasoneuropathy after chilling," result from prolonged exposure to cold which is not so severe as to cause frost-bite. Most subjects have been the survivors of shipwreck, but the condition has followed exposure without immersion. When due to exposure in open lifeboats the most important causal factors are the duration of exposure and the temperature of the water; sea-water at temperatures of 5° to 8° C. may produce nerve damage in 22 hours (Ungley) Any factors which impair the circulation, such as constricting boots, socks, or other clothing, immobility, chilling of the trunk, starvation or sea-sickness, will increase the severity of the disturbance. Distinction should be made from frost-bite in which the superficial tissues are frozen and the œdema without nerve lesions which follows prolonged immersion in sea-water at higher temperatures (8° to 20° C.).

There are three clinical stages. At first in the pre-hyperæmic stage the cold swollen limbs are pale, mottled or blue in colour, numb and anæsthetic, and pulsation is absent in the main vessels After several hours the picture changes suddenly to that of the hyperæmic stage with pain, heat, redness, increased swelling and full arterial pulsation. The normal skin temperature gradient of the limb is abolished and procaine block produces slight, if any, rise in temperature. When the limb is horizontal the foot or hand is red, if dependent the colour becomes a deep purple and blanching rapidly follows elevation. In the more severe cases blisters appear after about three days, especially in areas which are to become gangrenous Healing of blistered areas may take from one to six months. Pain, tingling, "pins and needles" or burning appear early, may be very severe, and are made worse by warmth, cold, dependency and exercise. There is weakness and wasting of the muscles in the affected areas leading to later disturbances such as flat feet Sweating, at first absent, later returns rapidly and may ultimately be excessive The hyperæmic stage may last from a few hours or days up to three months In the posthyperæmic stage inflammation subsides, vascular tone and skin temperature return to normal, but a state of "cold sensitivity" may develop in which, after cooling the limb, there are attacks of Raynaud's phenomenon or delay in warming in spite of attempts at reflex vasodilatation A similar disturbance, the so-called

commonly affected, but Leriche pointed out that in cases of aortic thrombosis and/or thrombosis of the common iliac or internal iliac arteries, the initial complaint may be of pain in the hip or buttock or of general tiredness of the limb on exercise and relieved by rest In some of these cases where the block is short and the collateral circulation good, the peripheral pulses may be present but may disappear on exercise and this condition may occasionally be confused with pain due to arthritis in the hip (Leriche syndrome).

(1) *Mechanical—*

Embolism and Thrombosis

When large peripheral vessels are occluded suddenly by injury or ligation there is a marked danger of the subsequent onset of gangrene, particularly in the leg where the collateral circulation is poorer than in the arm. Interruption of blood flow in a main vessel may be followed by generalized spasm of all the vessels distal to the obstruction, and if the collateral circulation is insufficient for the needs of the limb, gangrene will follow Diffuse spasm can be abolished and the collateral circulation improved by the interruption of the constrictor impulses, as by paravertebral alcohol injection Kinnimonth has shown that if the artery in spasm is bathed in 2·5 per cent papaverine it will relieve the spasm. 2 ml of this solution in 8 ml. of Xylocaine is used In addition heparin is of value in cases of embolism or thrombosis

(2) *Inflammatory*

Thrombo-angiitis Obliterans

The classical description of this disease was made by Buerger in 1908, and his name is still associated with the condition. Its incidence is high in the Jewish race, and it has been claimed that there is an association between it and excessive smoking The disease affects males almost exclusively, most commonly those above the age of 30 This constitutes an important difference from Raynaud's disease with which it is liable to be confused in the early stages.

The symptoms usually begin with pain and cramp in the foot brought on by exercise and relieved by rest though the earliest sign may be migratory phlebitis These are succeeded by colour changes in the feet, redness or cyanosis, particularly when the limbs are dependent. Such colour changes are often associated with severe pain When the limb is elevated it becomes pale and waxy These are other features which are not found in Raynaud's disease Trophic changes ultimately appear in the form of a localized superficial ulcer which will not heal; later dry gangrene may follow In the severe late forms of the condition there is intense pain which is unrelieved by rest and may be so severe as to cause the patient to commit suicide.

involvement may be patchy in the early stages, as it is in Buerger's disease, but later tends to be diffuse, so that when occlusion becomes manifest there are no entirely healthy alternative channels which can dilate to maintain the circulation. The margin of safety is therefore small The process is slow and the duration of symptoms from the onset to the development of serious surgical situations necessitating amputation is very long except when occlusion is accelerated by infection or thrombosis. Apart from these accidents, proper care may postpone the necessity for amputation by 5 or 10 years.

The process is predominantly degenerative rather than inflammatory or neuro-circulatory. In the muscular arteries of the extremities it begins as an increase in the mucinous metachromatic ground substance of the media, for it is the media which carries the burden of functional strain in these vessels As the mucin increases the elastic and muscle tissue of the media decrease, fat is deposited, and hyalin fibrosis sets in. This is soon followed by calcification which is found in 69 per cent. of males and 21 per cent. of females. The intima is involved, first by fat deposit, then by proliferative changes. The patients generally do not have a high blood pressure. Those with a high blood pressure can usually keep on driving an adequate amount of blood through their thickened vessels, until one of the hypertensive accidents occurs.

Leriche syndrome. Pain in the hip on exercise may be a sign of aortic, common iliac, or internal iliac artery occlusion In the two latter the peripheral pulse may be present and the condition may simulate or be confused with arthritis of the hip—or both may be present.

There is no significant difference between the lesions produced in the diabetic and non-diabetic subjects There is doubt as to whether vascular spasm is the initial factor giving rise to changes in the arterial wall, or whether spasm results from these changes. A significant degree of spasm is found in a proportion of patients, especially in the earlier stages. Pain is a prominent symptom, largely because of the severe degree of circulatory insufficiency, and alone may be sufficient indication for amputation. The blood supply may be worse in a painful though non-gangrenous leg than when gangrene is actually present.

Methods of Investigation.

According to White and Smithwick the three fundamental essentials for the investigation of disorders of the peripheral circulation are a room the temperature of which can be maintained constant within 2 degrees Fahrenheit for two hours at any season of the year, an accurate apparatus for the measurement of skin temperature, and a familiarity with methods of producing temporary inhibition of sympathetic activity.

Slight fluctuations in room temperature exert a significant effect on peripheral surface temperature; humidity changes are of less importance. An operating theatre is suitable provided that the temperature

line of the affected artery. The pain subsides gradually and has usually disappeared in from 24 to 72 hours

Superficial phlebitis occurs frequently, the most common site being the main trunk of the internal saphenous vein below the knee, although the branches may also be affected Inflammatory signs rarely persist for longer than 4 weeks in any one site, but when the condition spreads upwards along the vein the illness may last longer.

Œdema from arterial disease is rare in the upper extremity but is common in the leg and foot, particularly when the clinical course is rapid and when severe pain is felt during rest

Vaso-motor disturbances are often so marked as to mask the primary disease. The hands are more commonly affected than the feet, and the most striking change is complete pallor, producing the so-called dead finger ; less striking are minor grades of pallor ; cyanosis may also occur

"*Rest-pain*" varies greatly in severity, but is constant in its situation, being almost confined to the toes but occasionally affecting the dorsum of the foot or ankle. It precedes obvious trophic changes, but is greatly accentuated by them when they appear.

The disease, then, is essentially slow in its progress. Characteristically, it affects relatively young individuals who at the start have an ample capacity for the development of a collateral circulation which permits recanalization of the thrombus At its onset, the disease is limited to a small segment of the vessels, so that the amount of recanalization demanded is small. As the attack subsides circulatory efficiency is re-established, but there is a slight reduction in the available collateral supply. With each attack more and more of the main channels are occluded, and more and more of the collateral channels are utilized, so that with each attack the margin of safety shrinks Finally the total inflow of blood is barely enough to maintain life in the part, the demand for additional blood flow during exercise cannot be met, and ischæmic cramp (claudication) results ; the hyperæmia required for the healing of even minor wounds cannot be supplied, and indolent sores develop The disease may take a more rapid course, attacks following so closely upon one another that healing practically never occurs When it starts in older individuals, or is complicated by arterio-sclerosis, little or no collateral circulation develops, and much slighter degrees of thrombo-angiitis may lead to gangrene. This disease is nearly always bilateral. Even when manifest in one leg only it is almost certain to be latent in the other, and sooner or later will give rise to signs and symptoms, and this feature must always be remembered when a prognosis and decision regarding treatment are being made

(3) *Degenerative*—

Arteriosclerosis

Arteriosclerotic vascular occlusion is an accompaniment of old age, and the patients are usually in poor general condition The vascular

used: the most convenient is peripheral nerve block. In addition the presence or absence of sweating may be demonstrated by the starch-iodine test of Victor Minor 10 c c. of castor oil are added to 90 c.c of 1·5 per cent. tincture of iodine and the mixture is painted on to the skin and allowed to dry Starch powder is then insufflated on to the skin and adheres to the castor oil. Wherever moisture appears a deep blue-black colour develops Instead of the starch-iodine method Quinizarin Compound may be used in powder form which is dusted on to the skin, a purple colour appearing in the areas in which sweating occurs Dry skin is a poor conductor of electricity and after sympathectomy the resistance of the skin to passage of a small electric current is therefore increased and can be measured

TREATMENT OF PERIPHERAL VASCULAR DISEASE

The treatment to be adopted in any individual case of peripheral vascular disease forms one of the most difficult of surgical problems The therapeutic measures available are:

(1) Local and general measures to improve the circulation
(2) Sympathetic denervation
(3) Thrombo-endarterectomy
(4) Arterial graft
(5) Neurectomy or tenotomy of the tendo Achillis.
(6) Peripheral nerve section
(7) Amputation.

1. Local and General Measures to improve the Peripheral Circulation

The broad principles of the treatment of early peripheral vascular disturbances may be stated shortly as the prevention or abolition of vaso-spasm where this is present, combined with the protection of areas with an impoverished blood supply from trauma of all kinds. In the later stages, palliative procedures designed to relieve pain, and amputation may be necessary

Such patients present a dual problem in treatment—that of improving their general condition and the treatment of the local disorder. Each patient requires careful investigation and treatment as an individual Attention should first be directed towards the improvement of their general condition before passing to the more radical procedures designed to correct local disturbances

A period of complete rest in bed is always beneficial but should not be prolonged as this may result in undue loss of mobility in elderly subjects Draughts should be carefully excluded The value of adequate sound sleep is very great and this should be ensured by suitable sedatives Vaso-dilatation is marked during sleep and persists for some time after waking if the extremities are kept warm For this reason many of these patients immerse their unaffected extremities

and humidity can be accurately controlled. In making observations for comparison such a room is essential and the tests should be carried out at similar hours of the day and under basal conditions. Tests are of no value if done on very hot days, in the presence of fever, or of cachexia due to advanced malignant disease. The temperatures at comparable points on opposite limbs of a subject with normal arteries do not commonly differ by more than 2 degrees and it is thus possible to use one side as a control when testing the other side In normal

DIFFERENTIAL DIAGNOSIS OF VASCULAR DISEASE AFFECTING THE EXTREMITIES.

	Thrombo-angiitis obliterans	*Arterio-Sclerotic Disease*	*Raynaud's Disease and Similar Conditions*	*Primary Erythro-melalgia*	*Acrocya-nosis*
Pulsation of arteries	Pulseless 50 per cent Diminished 45 per cent. Normal 5 per cent	Pulseless 50 per cent Diminished 45 per cent Normal 5 per cent	Normal	Normal	Normal
Excessive rubor with dependency	Present	Present	Absent	Present	Absent
Excessive pallor with elevation	Present	Present	Absent	Absent	Absent
Claudication	Usually present	Usually present	Absent	Absent	Absent
Gangrene	Common	Common	Rare	Never	Never
Rest pain. .	Usually very severe	Usually mild	Usually absent	Usually mild	Absent
Type of rest pain	Sharp stinging	Aching	Absent	Burning	Absent
Appearance of gangrenous ulcers	Moist, inflamed; discharging	Usually dry	Small punched-out areas	None	None
Superficial phlebitis	30 per cent of cases	Absent	Absent	Absent	Absent
Age .	Mostly between 25 and 45 years	Mostly between 55 and 85 years	Mostly between 18 and 30 years	Mostly between 30 and 50 years	Mostly between 30 and 50 years
Sex .	Males 99 per cent	Males 90 per cent	Females 95 per cent	Females 70 per cent	Females 70 per cent
Colour changes following exposure to cold	30 per cent.	15–20 per cent	Always	Always	Always
Œdema . .	Frequent	Infrequent	Absent	Absent	Present during attacks

blood vessels and causing a re-active hyperæmia. It works in a mechanical way rather than a pharmacological according to Ratschow. The method is effective and of Ratschow's 150 patients 60 per cent. showed marked improvement. The technique is to inject 20–40 c c of sterile oxygen gas on between 20 and 40 occasions into the femoral artery. The obvious theoretical complication of thrombosis of the artery at the site of needle puncture has not yet been reported

2. Sympathetic Denervation in Vascular Lesions of the Extremities

In the treatment of vascular disturbances of the extremities sympathetic denervation is of value only where vaso-spasm can be demonstrated by one of the methods already described The beneficial effect of such denervation will be in direct proportion to the amount of spasm present provided that a suitable complete pre-ganglionic denervation be carried out In addition such denervation is of undoubted value in an attempt to improve the circulation in a limb affected by obliterative vascular disease when spasm is present

It is generally believed that *thrombo-angiitis obliterans* tends to run a chronic course for a varying period, after which the progress of the disease is arrested and healing occurs If gangrene and amputation can be avoided during the active stage an adequate collateral circulation may develop and function may be restored This process may be greatly assisted by the removal of reflex vaso-spasm by a suitable sympathetic denervation

Vaso-spasm is a common accompaniment of *arterio-sclerotic occlusion* of the vessels of elderly subjects and is frequently the factor which precipitates gangrene The extent of such gangrene may be limited and collateral channels more widely opened by removal of vascular spasm by denervation In the same way it is often possible to delay amputation in one or more limbs for a considerable period. The circulation to the skin and subcutaneous tissue and muscle may be improved, and claudication may be reduced or abolished, by sympathectomy In the majority of cases improvement should first be demonstrated by a suitable test, in a minority it has been shown that operation is of value in spite of the absence of a favourable response to testing

The discoloration and coldness of the legs associated with *anterior poliomyelitis* are usually due to vaso-spasm and if a suitable response be obtained to diagnostic spinal block, improvement will follow lumbar ganglionectomy, ulcers may heal and the skin temperature rise.

There is general agreement that periarterial sympathectomy as advocated by Leriche is of little value in the treatment of disorders of the peripheral vessels The procedures in common use are diagnostic and therapeutic paravertebral injection of sympathetic rami and ganglia, and thoracic and lumbar sympathectomy.

Paravertebral Injection. Blockage of the sympathetic trunks

in hot water on rising which produces a lasting vaso-dilatation, especially if combined with warm gloves and socks There is no doubt that excessive smoking has an adverse effect on peripheral vascular disturbances, and in many subjects even slight indulgence is followed by an evident increase of spasm It seems wise to cut down smoking as much as possible Alcohol, by producing vaso-dilatation, is of benefit but subsequent excessive cooling may result in intense spasm, and alcoholic drinks should be consumed only in warm surroundings or before going to bed Such measures as active and passive exercises, dry heat and hot baths may be employed to improve collateral circulation. In Buerger's exercises the patient lies on his back and raises the limb to an angle of 60 degrees with the horizontal for 3 minutes, then lowers it to hang in a vertical position for 3 minutes and finally it is raised to the horizontal for 5 minutes. The cycle is then repeated. Long-term anti-coagulants are useful to prevent the spread of thrombosis Syphilis, diabetes, or bad teeth should be treated by suitable measures and any infections controlled by suitable chemotherapeutic agents

General Directions for Patients suffering from Vascular Disturbances of the Feet. In addition to the above, great care must be taken of the affected part and the following rules will be found invaluable. The feet should be washed each night with warm water and soap and dried with a soft towel. Methylated spirit should be applied and allowed to dry, after which the skin may be anointed gently with hydrous lanolin to keep the skin soft, supple and free from scales The feet should always be kept warm Woollen socks or wool-lined shoes in the winter and cotton socks in warm weather are satisfactory, and where possible a fresh pair of socks should be used each day Loose-fitting bed socks should be used in preference to hot-water bottles or other mechanical heating devices Walking shoes should be loosely fitting and of soft leather Very great care should be exercised when the toe nails, corns or callous skin are being cut. and if the nails are dry and brittle they should be softened in warm water nightly and lanoline generously applied on, about and under the nail. Circular garters and strong antiseptic drugs should both be avoided The appearance of blisters on the feet should be the signal for careful treatment. The blisters should be snipped, the skin removed, and a dry dressing applied. Regular exercises, short of fatigue, should be prescribed The extremities should be carefully protected from trauma since mild abrasions frequently initiate gangrene. The patient should be warned of the danger of injury to his extremities and the reasons for the precautions enjoined should be explained to him in order to secure his co-operation

Treatment of Ischæmia by Insufflation of Oxygen Gas. Recent writers have studied the mechanism of the improvement in the peripheral blood flow which follows the insufflation of oxygen gas It is concluded that the oxygen gas bubbles work by blocking the small

turn and aspirated. Procaine is then injected through each needle and sympathetic paralysis is shown by warmth and dryness of the foot and leg of the same side.

Thoracic Sympathectomy.

(*a*) *Posterior approach* Prior to operation the spinous process of the second thoracic vertebra is identified under the fluoroscopic screen, and is marked by scratching the skin. The patient lies in the prone position with the chest supported on a pillow so that the shoulders and arms fall forwards, and the head is supported on a small pillow so that the neck is slightly flexed. Intratracheal nitrous oxide-oxygen ether anæsthesia is employed. An incision is made, four inches in length, two inches from the mid-line centred on the second thoracic

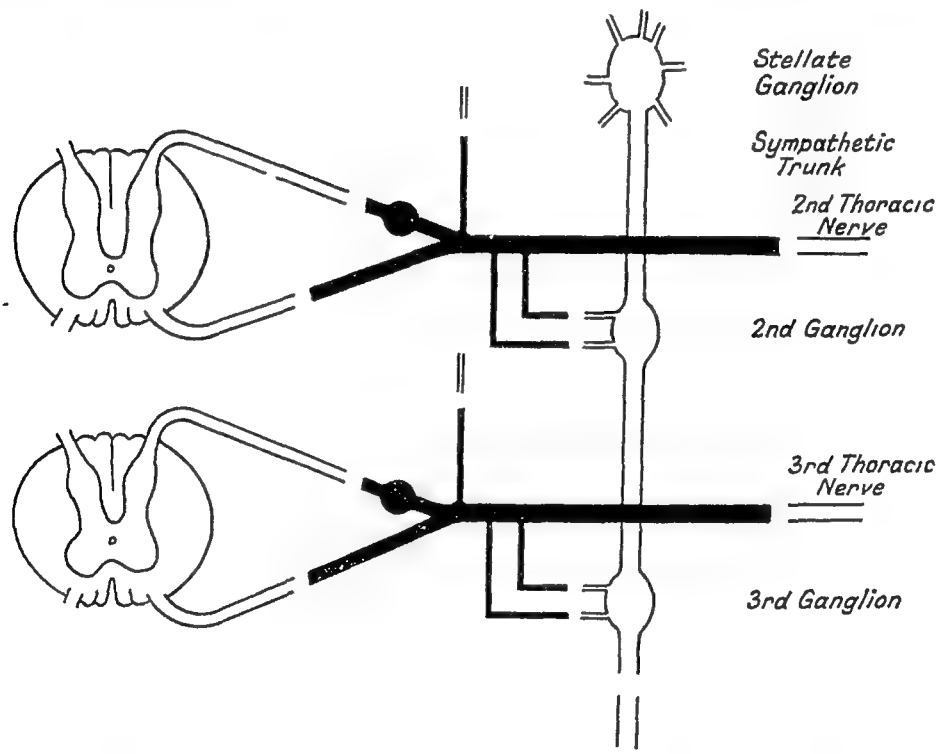

Fig 271 —Diagram to show sites of section for upper-limb sympathectomy (intraspinal section). Black indicates tissue excised.

spinous process The fibres of the trapezius are divided in the line of the skin incision, the fibres of the rhomboid muscle are split, its deep surface is separated from the underlying structures and the third rib is identified This rib is exposed by dividing and elevating the paravertebral muscles and the inner two inches of the rib and the distal inch of the vertebral transverse process are excised subperiosteally The pleura is separated by blunt dissection to the mid-line and upwards and downwards for two inches, exposing the second and third intercostal nerves and the sympathetic trunk. One of three procedures may now be carried out (Smithwick)—

and ganglia by the paravertebral injection of anæsthetic drugs is a procedure of great value, since by this means it is possible to obtain an accurate estimate of the effect on the peripheral circulation of removal or destruction of these ganglia. The therapeutic value of this method is no less great in properly selected cases. A single injection of local anæsthetic may produce much relief in conditions such as arthritis or causalgia. Alcohol injection is of value in producing sympathetic denervation in subjects unfit for operation but it must not be used as a substitute for operation in subjects fit for this. Accurate injection is difficult and may be followed by traumatic neuritis of intercostal nerves. General anæsthesia cannot be employed during paravertebral injection but phenobarbitone, or morphine and hyoscine, should be administered to allay anxiety The spinous processes of the thoracic vertebræ are opposite the transverse process of the vertebra below. Under local anæsthesia long needles (spinal puncture needles are suitable) are inserted, 4 cm from the midline at the level of the upper three ribs, until the needle hits the rib. The needle is manipulated until it passes below the lower border of the rib, then rotated laterally through 20 degrees and pushed in for a further 3 cm Contact should be made with the side of the vertebral body at this point. If it is missed the needle should be directed more towards the midline. If contact is made sooner the needle should be reinserted at a slightly less angle A test aspiration should now be made to ensure that the needle has not entered the lung through the pleural space or the subarachnoid space, or a blood vessel This latter is common in the case of the upper two ribs When all the needles are in position 5 c c of 1 per cent procaine solution is injected slowly through each needle. Signs of sympathetic paralysis should develop within ten minutes; the arm, hand, face and neck should become hot and dry, but there should be no anæsthesia in these areas If this does not happen within ten minutes the needles should be withdrawn and a further attempt made later. If a satisfactory paralysis develops and it is desired to inject alcohol, 5 c c. of 95 per cent alcohol is injected slowly through each needle. Pain should be abolished by the preliminary injection of procaine, but if it develops the injection should be stopped until it passes off. The site of injection can be marked by injecting a few drops of lipiodol into each needle after the alcohol The needles are then withdrawn and the patient is turned on his back to lie quietly in that position for at least half an hour He may then return to bed for 24 hours.

In the case of the lumbar ganglated chain the needles are inserted 3 cm. lateral to the upper border of the spinous processes of the third, fourth and fifth lumbar vertebræ. Each needle is pushed in 3 to 4 cm. at which point contact is made with the transverse process The needle is passed over the upper edge of the transverse process and the tip turned slightly medially and thrust through the psoas muscle until it hits the vertebral body. The syringe is fitted to each needle in

also draws away the carotid sheath and internal jugular vein A dissector is passed beneath the scalenus anterior which is now divided

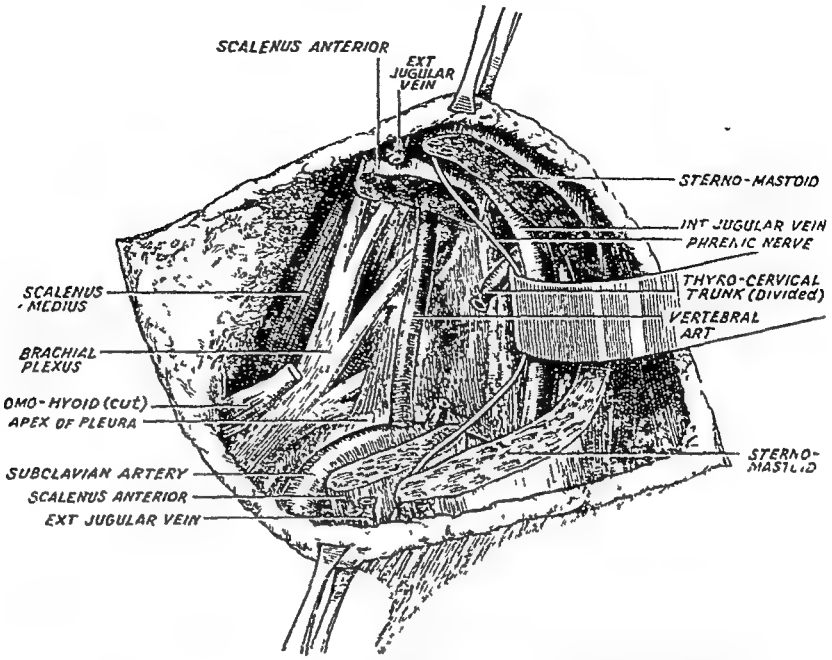

FIG 273 —The anterior approach to the Stellate Ganglion

The anatomical area shown is wider than that actually seen at operation but gives in this way better orientation for the operator

close to its insertion to expose the subclavian artery The vertebral artery and thyro-cervical trunk are defined and the latter is divided

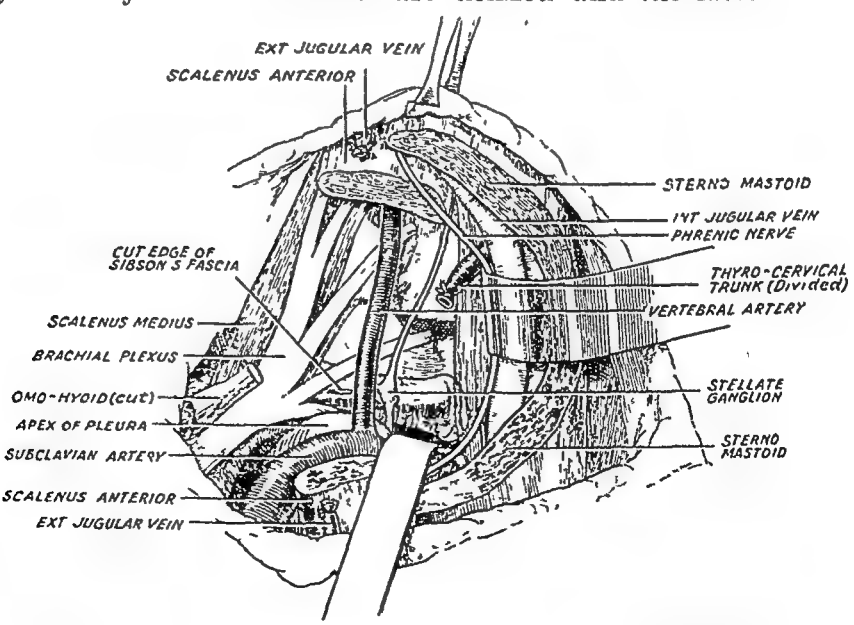

FIG 274 —The anterior approach to the Stellate Ganglion.

Sibson's fascia has been divided from the first rib and the ganglion exposed after retraction of the apex of the pleura

between ligatures. On the left side the thoracic duct may now be exposed and should be gently retracted medially. The subclavian

(1) Intraspinal Root Section. The third intercostal nerve is divided at the lateral margin of the incision, the proximal end raised from its bed and its rami communicantes and dorsal branch are cut The anterior and posterior roots are then exposed and separated and the posterior root divided just proximal to its ganglion. The meninges are pushed medially along the anterior root until the glistening intradural part is seen, the root is divided at that point, the proximal end retracting within the arachnoid.

(2) Extraspinal Root Section. The roots of the nerve are divided just proximal to the posterior root ganglion and the rami communicantes are cut as above.

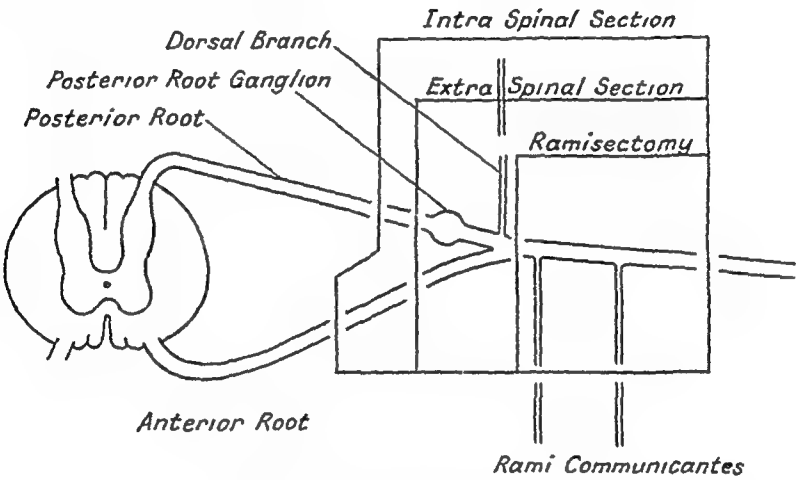

Fig 272 —Types of Nerve Section

(3) Ramisectomy The intercostal nerve is divided lateral to the posterior root ganglion; the rami communicantes are cut as above.

Ramisectomy is the easiest and intraspinal section the most certain of the three methods. The second nerve is similarly dealt with and the sympathetic trunk is divided below the third thoracic ganglion and the upper end of the trunk is brought out of the thorax, ligated and sutured into the paravertebral muscles Smithwick advises that the upper end of the trunk be enclosed in a silk cylinder in order to prevent regeneration The wound is closed in layers with interrupted sutures without drainage

(*b*) *Anterior approach* The patient lies on his back with a firm sand pillow behind his shoulders to extend the cervico-thoracic spine and his head is rotated towards the opposite side Intratracheal nitrous-oxide-oxygen ether anæsthesia is employed. A transverse incision is made a finger's breadth above the clavicle, passing laterally for three inches from the inner border of the sterno-mastoid muscle The external jugular vein is divided between ligatures, and the clavicular head of the sterno-mastoid is divided to expose the scalenus anterior muscle. The phrenic nerve is raised from the anterior surface of this muscle, freed and retracted medially with a small blunt copper spatula, which

blunt dissection with small wool pledgets on forceps, and as its rami are found they are cut with scissors until the chain has been freed to a point above the second lumbar ganglion where it is again cut across.

Right Side The peritoneal incision is made just lateral to the inferior vena cava and is carried downwards over the right iliac vein The ureter and cæcum are retracted laterally and the veins are retracted medially with a blunt copper spatula. The chain lies more behind the vena cava on the right side than the aorta on the left side, and passes beneath the common iliac vein below.

The dissection of the trunk is more difficult on the right side because of the thinness of the vena cava and the presence of the lumbar veins which may pass either superficial or deep to the trunk and if torn give rise to troublesome bleeding. On the left side there may be similar difficulty at the lower end of the chain. Such bleeding is best controlled with Cushing's clips. The peritoneal incisions are closed with catgut before the packs are removed and the abdomen is closed

(*b*) *Retroperitoneal approach* Spinal block is the anæsthetic of choice The patient is placed on his side with a sand-bag under the loin. The lower limb is flexed to a right angle at the hip and the upper to half this extent. A pillow is placed between the thighs and the patient is tilted slightly towards the operator and this position is maintained by sand-bags behind the thighs An incision is made from the angle between the twelfth rib and the sacro-spinalis muscle downwards and forwards parallel to the rib, and continued until it reaches a point above and about one inch from the anterior superior iliac spine The posterior fibres of the external oblique muscle are divided in the line of the skin incision to expose the internal oblique muscle and its attachment to the lumbo-dorsal fascia. These structures are divided in a line parallel to the twelfth rib from the border of the sacro-spinalis behind to the origin of the transversus in front, care being taken to avoid the subcostal and ilio-inguinal nerves which lie respectively above and below the line of this incision. By blunt dissection the peritoneum is mobilized forwards from the quadratus lumborum and psoas muscles, from the lower pole of the kidney downwards. The ureter is mobilized with the peritoneum The sympathetic trunk may be palpated on the anterolateral aspect of the vertebral bodies at the medial border of the psoas muscle The peritoneum and ureter are retracted forwards with a large curved illuminated retractor and the trunk and its second and third rami are now easily exposed The lower end of the trunk is cut across below the third ganglion and lifted up and the rami to the second and third ganglia are divided and the trunk again cut across above the second ganglion Bleeding may occur from the lumbar veins during the dissection of the trunk, especially on the right side where the vena cava is in close relationship to the trunk and must be retracted gently to facilitate exposure of the

artery is drawn forwards and downwards and the costal attachment of Sibson's fascia is incised along the inner border of the first rib. The apical pleura is thereby exposed and may be stripped forwards and downwards by blunt dissection to the level of the third rib and held by a flat illuminated retractor The cervico-thoracic (stellate) ganglion can now readily be seen lying on the head of the first rib, with the trunk running downwards from its lower pole and a number of fine rami passing out from its upper pole. The trunk is followed down to the third ganglion below which it is hooked up and divided. The upper cut end is then grasped in fine forceps and drawn upwards, the white and gray rami communicantes of the second and third ganglia being divided During the exposure and definition of the trunk troublesome bleeding may occur from the branches of the superior intercostal vein and artery This may be controlled by the application of Cushing's clips. The upper cut end of the trunk should be drawn into the wound and sutured to muscle to prevent regeneration. The stump may also be enclosed in a silk cylinder as advocated by Smithwick. This procedure interrupts all vaso-constrictor and sudo-motor fibres to the arm and head but does not affect the oculo-pupillary fibres. The wound is closed in layers without drainage, the cut edges of the sterno-mastoid and platysma being sutured

Lumbar Ganglionectomy.

The lumbar gangliated chain may be exposed by the trans-peritoneal or extra-peritoneal routes The trans-peritoneal route has certain advantages when it is desired to deal with both sides at one operation When operating on one side only, or on both sides on different occasions, the extra-peritoneal route is preferable since by this method excellent access is obtained with little disturbance to the patient. Both approaches will be described.

(*a*) *Trans-peritoneal approach* High spinal block is the anæsthetic of choice and the patient is placed in a modified Trendelenburg position. The abdomen is opened through a lower paramedian or mid-line incision and the intestines are packed into the upper abdomen

Left Side The parietal peritoneum is incised lateral to the pelvic and descending parts of the colon, which are mobilized medially by blunt dissection The ureter adheres to the colon and peritoneum and is mobilized with them The colon is held away by a retractor and the aorta and left common iliac artery are exposed. The genito-femoral nerve is seen running down the surface of the psoas muscle The sympathetic chain lies rather deeply in the groove between the aorta and the bodies of the lumbar vertebræ medially and the psoas muscle laterally and may be embedded in fat and surrounded by lymphatic glands which make its identification difficult The chain is most easily identified at its lower end where it passes behind the left common iliac artery and is divided above the fourth lumbar ganglion which usually lies behind that artery. The chain is now defined by

section and immediate suture of the nerves. Smithwick and White have found the simpler procedure of crushing the nerves equally effective. In order to ensure good healing accurate anatomical exposure with a minimum of trauma is essential and the skin only should be loosely sutured Regeneration of the nerve takes from three to six months Scrupulous care should be taken of the anæsthetic areas which should be protected from trauma If sufficient improvement results from this operation it may be possible to carry out local treatment of ulcerated or gangrenous areas, and lumbar ganglionectomy should be considered as an additional measure to delay amputation.

7. Amputation

Amputation is most commonly called for in obliterative disturbances affecting the legs The digits are supplied by end-arteries and their collateral circulation is poor. Conservative treatment should always be tried when gangrene is localized to one toe and there is a good line of demarcation, absence of lymphangitis, cellulitis, and osteomyelitis, and no generalized toxæmia. Early amputation of a single toe is dangerous and often results in a further spread of gangrene, and healing is usually delayed The patient is put to bed with the affected part covered with a light, dry gauze dressing and protected by a simple wire cage. A thermostatically controlled heated cradle is placed over one of the other extremities, and prophylactic doses of gas gangrene and tetanus antitoxic sera are injected intramuscularly In the presence of mild local infection a localized debridement of the gangrenous area should be carried out as a preliminary step to lessen toxæmia and lower the temperature and pulse rate. In such cases it may be permissible to wait for local healing where the first step has been a limited procedure, but if it has been at all extensive amputation should be carried out as soon as the patient's condition permits In diabetic gangrene inability to control glycosuria even with large doses of insulin is an indication for immediate amputation, following which control of the diabetes is usually readily effected When a limb is useless, intractably painful, or endangering life, amputation is indicated. Amputations through the foot or ankle regions are seldom successful but recently transmetatarsal amputation has been suggested in certain cases with success, but the indications are not easy to define. Pedersen carried out the operation in 23 cases in thrombo-angiitis obliterans, arterio-sclerosis, and diabetes with primary healing in 8 and by granulation in 9 The first group were walking in three weeks—a great advantage in old people. The poorer the circulation, of course, the less the chance of success. Absence of pulsation below the femoral artery is not a contra-indication and provided the skin of the dorsum of the foot is warm and well nourished and free from discoloration success can be anticipated. Infection must be assumed in all cases and must be controlled before operation The level of amputation is just proximal to the metatarsal heads and with a long plantar flap. If it is doubtful whether a good

trunk. The wound is closed in layers with catgut sutures without drainage.

The level of these operations is planned to fit the level of the arterial occlusion. For popliteal occlusions excision of the second and third lumbar ganglia is adequate, but the first should be dealt with for mid-thigh blocks, and up to the tenth dorsal ganglia for high occlusions such as the common iliac arteries After sympathectomy amputations should be as conservative as possible

3 Thrombo-endarterectomy

This new concept in the surgery of peripheral arterial disease is based upon the finding that the thrombosis of arterio-sclerosis often involves a localized segment of a major artery and that it is technically possible to restore normal arterial flow through the segment by surgical resection of the diseased intima. It is often called " dis-obliteration."

The criteria for the selection of suitable cases for operation include

(1) the presence of disabling symptoms ,
(2) the radiographic demonstration of segmental occlusion of a large artery , and
(3) a relatively good physical status.

The contra-indications to operation are

(1) debility of advanced age ,
(2) the presence of serious concomitant disease in other organic systems , and
(3) the arteriographic demonstration of the diffuse form of arterio-sclerosis

At the operation the artery is clamped off with Pott's clamps, as are the branches if necessary. The diseased artery is then incised longitudinally along the entire length of the thrombosed segment The distal incised arterial wall is then opened out to lie flat between the operator's thumb and forefinger. A circumferential incision is made into the intima below the lower limit of gross arterio-sclerotic change, so as to gain the dissection plane within the media Care is taken to prevent separation of the intima from the media distal to the circumferential incision. The dissection is carried proximally until a relatively normal proximal arterial lumen is reached The intimal section is cut off abruptly with no attempt to bevel the end. Closure of the incised arterial segment is accomplished by the use of a continuous over and over suture of 00000 Deknatel through all the layers. The clamps are released momentarily before the closure is complete to assure a free flow. Clots may have to be removed. During the closure the lumen is continually irrigated with dilute heparin solution (10 mg heparin per 100 c c saline solution) to prevent the local accumulation of clotted blood.

In addition to their use during the operation anti-coagulants are used as a long-term measure in patients with obliterative vascular

this test depends the decision as to whether sympathetic denervation will be of value. Unless marked improvement results from rest in bed, abstinence from tobacco, and a diet containing a high content of calcium and little potassium, sympathetic denervation should be advised when the patient is under 40 years of age, there is a good dilator response to heating, and no evidence of involvement of vessels other than those supplying the limbs. This operation should be urged upon those patients who have already lost one or more limbs or parts of a limb, or who have no pulsation in their main vessels at the level of the wrist or ankle, since following operation mobility and the use of the fingers are greatly increased. The disease can and does progress following operation, and conservative treatment must be continued. Passive vascular exercises are then of greater value since hyperæmia may be more readily induced. Subsequent thrombosis is not followed by a massive constrictor response as the reflex arc is interrupted by the operation Where there is no reflex response to heating the operation is of little permanent value Peripheral nerve crushing should be carried out to relieve intractable pain Later amputation may be necessary

Arterio-sclerosis may be associated with a sufficient degree of vasospasm to justify sympathetic denervation. Where this is so operation is often followed by an improvement in the nutrition of the skin and subcutaneous tissues. Intermittent claudication is not much benefited by sympathectomy The arteries to the muscles are only to a slight extent under sympathetic vasomotor control, their calibre being controlled almost entirely by the metabolites of the contracting muscle. Attempts have been made to diminish the blood requirement of some of the calf muscles by paralysing parts of each muscle after the manner of Stoeffel This is sometimes of benefit in intermittent claudication.

below-knee stump five to six inches in length can be obtained, amputation through the lower third of the thigh should be carried out.

Summary of Treatment.

It is important to recognize that a disturbance such as Raynaud's phenomenon may result from several combinations of the same factors. It is essential in the case of a particular patient to assess the relative importance of the factors concerned before it is possible to decide the most suitable form of treatment. For each individual there is a critical temperature below which vaso-spasm occurs The higher the temperature the more severe and disabling is the disease . recovery from an attack is correspondingly slower and changes in the vessel walls are usually more marked. In most cases some improvement will follow the wearing of warm woollen socks and gloves and the avoidance of extreme cold. In the early stages where there are no detectable changes in the vessels or soft tissues and full vaso-dilatation follows heating, the results of pre-ganglionic sympathetic denervation are excellent Where there are slight changes in the digits and reflex vaso-dilatation is slow and incomplete, the progress of the disease may be arrested and the frequency and severity of the attacks reduced by pre-ganglionic denervation. Where the disease is in an advanced stage and there is little local reflex response to heating other parts of the body, pre-ganglionic denervation is useless since any response is slight and usually transitory. If a lower limb is affected the second and third lumbar ganglia and intervening trunk are removed (in females the first may also be included) In the case of the upper limb the trunk is divided below the third thoracic ganglia and all the rami to and from the second and third ganglia are divided. In acrocyanosis and erythromelalgia similar treatment to that detailed above for Raynaud's disease is indicated.

In the obliterative disturbances, thrombo-angiitis and arteriosclerosis, the problem is rather more complicated. General treatment is of great importance, but in addition it is essential to estimate the degree of vascular efficiency of the affected limbs and the part played by vaso-spasm The site and extent of arterial occlusion and the potential and actual collateral compensation must also be assessed. Age is important in considering the potential collateral circulation, which diminishes with increasing age and in the obliterative disease The colour, temperature, and the state of nutrition are valuable criteria. In the presence of gangrene a sharp line of demarcation indicates good collateral circulation in the unaffected part, provided infection is not present. Skin temperatures taken at intervals along the length of the limb may show an abrupt fall beyond the site of vascular occlusion. Simple palpation of the main vessels, where these are accessible, provides a certain amount of information, but more accurate knowledge may be gained from oscillometry The reflex vascular response to heating another extremity must be estimated, and on the result of

CHAPTER XIII

AFFECTIONS OF THE SPINE

LOW BACK PAIN

The variable character of low back pain, its multiplicity of causes, and the difficulties in its treatment, render this affection one of the most perplexing, as also one of the most frequent, problems that confront an orthopædic surgeon Moreover, the condition has important industrial and economic aspects, and in this connection the advice of the surgeon is often sought. Many individuals habitually assume, at work or otherwise, positions of great mechanical disability, and sooner or later under the stress and strain the body tissues rebel and backache results Industry, both heavy and light, therefore, suffers a severe drain on its man-power from this type of affection, since slight traumata may throw on the disabled list for very long periods those whose bodies have been repeatedly insulted by postural errors, and the consequent mechanical strain Because it is in only a small proportion of the patients so afflicted that any pathological basis can be found, aetiology is largely speculative, treatment is empirical, and a systematic approach to either is full of puzzles

In dealing with cases of low backache, it is essential to have a comprehensive method of investigation. A systematic and routine examination must include all possibilities, otherwise little progress can be made either in the diagnosis or the treatment The orthopædic surgeon should have, for each patient, a blank questionnaire, which should be carefully and methodically completed.

The Complaint. Low back pain may take the form of a dull, heavy sensation, which annoys and depresses the patient, or it may be a sharp, agonizing pain from which only sedatives give any relief In addition to the pain, there may be stiffness in the back. There is nothing particularly characteristic in either of the two complaints, but the pain and its salient features must be thoroughly investigated.

The Pain.

(*a*) *The Situation* The situation of the pain is a fairly good index of the site of the causative lesion.

(*b*) *The Reference* The pain may be referred to a variety of regions. In lumbo-sacral strain, it is usually reflected to the calf and the foot In sacro-iliac cases it may be experienced in the posterior aspect of the thigh, and may also be referred to the sciatic notch, and to other parts of the leg.

(*c*) *The Duration.* It is important to know how long the pain has been present, and so determine whether the condition is acute or chronic.

and sacro-iliac regions, in the posterior, inferior and superior spines, the ilio lumbar ligaments, the lumbo-sacral joint, and the spines and transverse processes of the lumbar vertebræ. The presence of tender fibrositic nodules may be of importance in arriving at the final diagnosis.

The effect of *lateral compression of the iliac crest* is observed. *Rectal* and *prostatic* examinations are made.

Special tests are of great value in the differential diagnosis and location of low back pain. Forcible compression of the iliac crests often elicits pain in the sprained sacro-iliac joint, but usually has no effect on the lumbo-sacral sprain. Laguere's sign, which consists of forcing the leg in flexion, abduction and lateral rotation, causes pain in the affected sacro-iliac joint. As a rule, this manœuvre does not cause pain in a painful lumbo-sacral area. Goldthwaite's and Gaenslen's signs similarly produce pain in the affected sacro-iliac articulation with slight effect upon the lumbo-sacral. In the former sign, the thigh is strongly flexed with the knee extended. The tension of the hamstring muscles produces a rotatory force upon the painful sacro-iliac joint. In the latter sign, the thigh and the knee on the affected side are flexed so that the extremity is pressed against the abdomen then upon hyperextension of the opposite hip, pain is felt in the affected sacro-iliac joint. It is often very difficult to fix the spine so as to relieve it of stress when exerting force upon the sacro-iliac joints, or to fix the sacro-iliac regions in a position of relief while placing stress upon the lumbo-sacral junction. This is especially so when the sprain is acute and has associated spastic limitation of motion.

Lasegue's sign (straight leg bending test) is carried out with the patient prone on a couch. The straight leg is flexed at the hip and usually it can be lifted to 90 degrees or more, the distance depending on the tautness of the hamstrings Limitation of movement and pain are usually present in low back pain and sciatica When the leg is flexed, dorsiflexion of the foot increases the pull on the sciatic nerve without altering the tension of the hamstrings and this increases sciatic pain but not pain from other causes.

The X-ray Examination. An antero-posterior and lateral view of the spine, extending well above and well below the suspected site, should be taken In many cases, a stereoscopic view of the lumbo-sacral and sacro-iliac regions should also be obtained, as many conditions, and especially those of the lumbo-sacral articular facets, cannot be properly appreciated except by this particular method. Roberts has emphasized the necessity in cases of doubt of taking an oblique view in order to get a view of the pars interarticularis.

Laboratory Examination. Examination of the urine, blood, and cerebro-spinal fluid, and a Wassermann test, complete the investigation.

cological examination made if any suggestive symptom is discovered. Pain which is increased during menstruation suggests a chronic ligamentous strain, as the ligaments of the pelvis are congested at that time

(*e*) *Neurosis* The mental balance of the patient, and, in the wage-earning classes particularly, their attitude towards work and compensation, must be carefully assessed.

(*f*) *History of other Diseases* Osteomyelitis, arthritis, gonorrhœa, typhoid fever, tuberculosis, syphilis, and any possibility of neoplasm, should be excluded

(*g*) *Constipation.* Sir T. R. Fraser has shown how frequently low back pain may be associated with a loaded colon, so that a careful history of the bowel action should be taken

Examination of the Patient

The patient is stripped and examined in both the erect and recumbent positions

1. Standing. The general posture, weight, muscular development and tone are noted Careful observation is necessary for some minor abnormality of posture which the patient adopts for instance a slight degree of flexion at the hip and knee which relaxes the hamstrings may be due to chronic sacro-iliac strain on the side concerned.

The spinal curves are examined and any deviation from the normal noted. A slight tilt of the pelvis which has resulted from the shortening of one limb and which has caused a compensatory scoliosis may be the error of posture responsible for the symptoms

The movements of flexion, extension and lateral flexion are carried out and abnormalities such as rigidity, muscle spasm or the production of pain noted

And has emphasized a test for spinal movements much used in medical tribunals to diagnose a case of hysterical limitation of movement or even plain malingering Flexion of the spine is first examined with the patient standing and thereafter on the examination couch. On the couch he is invited to sit up and bend forward while a show is made of palpating his spine from behind. It is sometimes quite remarkable how differently the spine flexes in the two methods.

2. Sitting. *Movements of the spine,* both active and passive, are investigated in the manner indicated above

The reflexes are tested, the possibility of active *focal sepsis* in the teeth and tonsils considered, the condition of the *circulation* observed, and *blood pressure* readings recorded

3. Lying. *Measurement* of the length and girth of the limbs is carried out

Joints of the Legs. The contour and range of movement of the joints of the legs are observed

Abdominal palpation is carried out.

Points of tenderness are sought particularly in the coccygeal, sacral,

Sometimes two vertebral bodies may be fused together, but this condition is usually symptomless

The Articular Processes. The articular facets of the lumbo-sacral joints show great variations in shape, and in the plane of their surfaces Normally the articular processes are vertical, and the facets lie in the sagittal plane, but on one or both sides, the processes may show the characteristics of the thoracic region, where the facets face forwards and backwards respectively : in other cases, one facet may be directed backwards and the other medially.

When the facets are thus asymmetrical, abnormal movements may occur Brailsford found that the articular facets of the fifth lumbar vertebra were directed in various ways : 57 per cent backwards ; 12 per cent medially, and 31 per cent mixed, the directions on the two sides being different.

(b) The Neural Arch.

The principal anomaly occurring in this region is a lack of fusion between the two halves of the arch. The condition occurs either in the fifth lumbar or in the first sacral vertebra, and the defect is situated in the mid-line, thus constituting a spina bifida occulta. The only evidence of such an error may be a small lipoma, a tuft of hair, or a dimple in the skin of the lumbo-sacral region. There may be no symptoms, although frequently there are co-existing deformities of the lower limb, e g pes cavus. Instability in the lumbo-sacral region, and low back pain are common accompaniments.

In addition to this central defect, there may be anomalies in the attachment of the laminæ to the body on one or both sides These may be found along with the commoner central defect All varieties of congenital error in this situation are more common in males.

Spondylolisthesis, the name given to that deformity of the lumbo-sacral region produced by the gradual gliding or slipping forward of the lumbar spine on the sacrum, first attracted the attention of obstetricians in 1853 when Kilian recognized it as a definite clinical entity, and considered it to be chiefly a disorder of women It has, however, been shown since to affect men more often than women. The condition is thought by some to be due to an important variation in the ossification of the fifth lumbar vertebra where, instead of one primary centre for each half of the vertebral arch, there are two primary centres in each half, the two parts being united by a plate of cartilage set obliquely between the superior and inferior articular processes. Willis points out that as the artery divides at this point. either before or after entering the bone, into ascending and descending branches, bone development may progress in a similar way and, fanning out in both directions, be defective centrally In such a case the posterior part of the arch of the vertebra, consisting of the spine, laminæ, and inferior articular processes, is occasionally separated from the rest of the bone, union being effected by hyaline cartilage only. A similar

THE COMMON CAUSES OF LOW BACK PAIN

1. Low Back Pain associated with Congenital Errors

(a) The Vertebral Body.

The bodies of the vertebræ ossify from two separate centres which may be alongside each other, be superimposed, or even be one behind the other A variety of anomalous radiological shadows is therefore met with When the two centres of ossification do not develop properly, or fail to fuse, the X-ray appearance is that of a split body, and there is often some separation between the two halves. Care should be taken not to confuse a true failure of fusion between the centres with the apparent splitting of the vertebral body occasionally seen in children and young adolescents In the latter case, there is an apparent separation between the upper and lower halves of the body, but the cleft is anterior to and extends only as far as the centre of the body. The appearance has no clinical significance, and is thought to be due to delayed union of the notocordal segments A split body does not give rise to deformity, but if one of the true centres actually fails to appear, a hemivertebra is produced and leads to a spinal curvature, usually a scoliosis. The balance of the erect posture is then altered and compensating secondary lateral curvatures arise.

Fig 276—Congenital abnormality of the first lumbar vertebra producing a kyphus in the lumbar region

It is sometimes associated with other congenital abnormalities, such as limitation of other joint movements, cloudy cornea, etc Note also the indentation in front of some of the vertebræ This is a delayed fusion of the primitive notocordal segments (Mr Armstrong's case)

the upper and posterior borders of the sacrum (Fig. 279). The apex of the wedge is formed by the articular facet of the sacrum and splits the fifth lumbar vertebra into two portions at the site of the congenital non-union Thus is initiated spondylolisthesis.

The apposition of the inferior articular processes of the fifth lumbar vertebra with the articular processes of the sacrum checks any forward displacement of this vertebra, but, if there is any solution of continuity between the superior and inferior articular processes of the fifth lumbar vertebra, displacement may occur at the joint owing to the superincumbent body weight acting as a shearing strain overcoming the resistance of the weaker ligamentous structures. This slipping takes place slowly and gradually, probably over a matter of years.

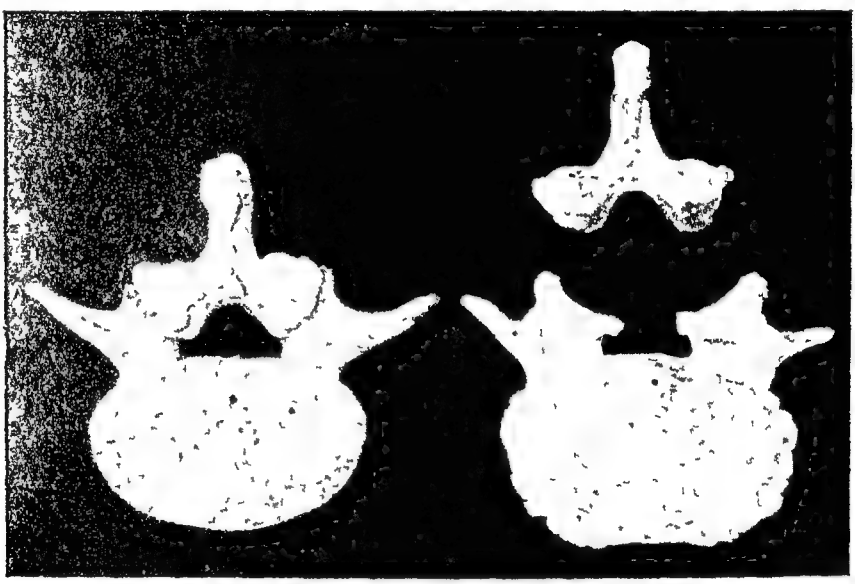

Fig 278 —Specimen of the Fifth Lumbar Vertebra showing Congenital Non-fusion of the Posterior half

In those cases where a snap is felt in the back it is believed by Neugebauer that secondary infraction of the interarticular portions of the arch takes place and gives the patient the sensation of a snap The posterior part of the arch remains in place. The body, with the anterior part of each of the lateral masses, slips downwards and forwards, carrying with it the superincumbent vertebral column

Newman in a study of some 200 cases believed that they could be placed in five groups which he described briefly by the salient features.

(1) Luxation at the lumbo-sacral junction due to congenital sacral defect including the articular facets with attenuation of the neural arch Occasionally a secondary break of the neural arch results

(2) Luxation of the anterior part of the vertebra due to attenuation or a break in the pars interarticularis, or a combination of both, the facets remaining intact.

condition may be seen in the fourth, and occasionally in the third lumbar vertebra, so that the deformity may lie between the third and fourth or between the fourth and fifth, or at the lumbo-sacral junction. Roberts believes that this bone defect of the pars interarticularis is not a defect of ossification of that part but rather a linear de-ossification

FIG. 277 —Spina Bifida of the first Sacral Vertebra.

due to overstrain from the upright posture with consequent changes similar to those occurring in so-called fatigue or strain fractures. He describes a softening with downward and forward sagging of the arch with the X-ray appearance of a translucent striation across it. The pars interarticularis being at the pivotal centre of the neural arch and of a delicate structure in the human body is liable to suffer from extra strain.

Newman was of the opinion that spondylolisthesis is due to lumbar instability caused by

(1) Congenital absence of the sacral ridge associated with deficiency of the median raphe of the lumbo-sacral fascia and other posterior spinal ligaments.
(2) Congenital or acquired facet deficiency
(3) Acquired deficiency of the lumbo-dorsal fascia, other posterior spinal ligaments and the intervertebral disc.

He said the characteristic lesion of the pars interarticularis is not always present It is secondary to instability and caused by attenuation or fatigue or a combination of both and is not the cause of spondylolisthesis, but its presence may permit an additional degree of slip Capener has pointed out the importance of the wedge-like influence provided by

the smaller, becomes larger and appears different in shape from the normal.

The slipping of the vertebra produces an angulation rather than a curve, so differentiating the condition from an aggravated normal lordosis. The antero-posterior pelvic diameter is diminished and the anterior superior spines are rotated backwards through a considerable arc. Tchirkin has described a physical sign which he maintains is pathognomonic of acute spondylolisthesis He says that the lordosis of spondylolisthesis is associated with a compensatory forward bend of the spine in the region between the flexible lumbar and immobile thoracic vertebræ, producing a slight kyphosis of the first lumbar spinous process.

The presence of spondylolisthesis may be suggested to obstetricians by asymmetry of Michaelis's rhomboid—the rhomboid figure formed by the lines joining the dimple over the tip of the fifth lumbar spine to the posterior superior spines above, and the convergence of the buttocks below.

A slight degree of scoliosis is frequently present owing to the unequal slipping forward of the vertebræ and the consequent rotation Flexion of the spine is restricted, while lateral movements are free. There may be a limitation in hip extension, but in most cases the patient can touch his toes in the straight leg bending exercise. On abdominal palpation a prominence of the fifth lumbar vertebra may be present, and may be confirmed by vaginal examination

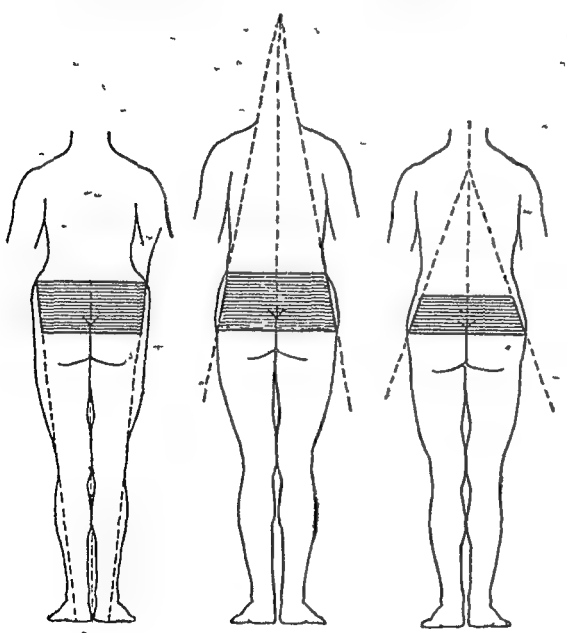

FIG 280 —Diagram to illustrate the differences in the Bi-iliac and Bi-trochanteric Measurements in various conditions

(a) Spondylolisthesis The forward rotation of the pelvis increases the bi-iliac diameter
(b) Normal
(c) Congenital dislocation of both hips increases the bi-trochanteric measurement

X-ray Appearance. The diagnosis is confirmed by X-rays taken antero-posteriorly, laterally, obliquely (45 degrees), and stereoscopically. In early cases a zigzag hair line translucency may be seen in the pars interarticularis In the later cases in the antero-posterior radiographs a characteristic arc or bow is seen, which is the shadow of the anterior border of the transverse process continuing on to the anterior border of the body This appearance is produced by the X-rays penetrating the fifth lumbar vertebra from

(3) Slipping due to instability caused by an acute fracture of the neural arch
(4) Luxation due to degenerative joint changes causing facet deficiency in later life
(5) Instability or luxation due to bone disease

The average age of patients who suffer from symptoms from this deformity is about 40 years, although cases have been reported as old as 80 and as young as 5.

The Clinical Picture

The patient complains of low back ache and pain in the lower extremities, but in the majority of the younger individuals such symptoms are entirely absent. The symptoms may be summed up briefly as follows—sometimes without previous injury but generally after a single or repeated trauma a deformity of the spine develops gradually, accompanied by pain referred to the lumbar region and radiating down into both lower extremities. The pain is relieved by rest and aggravated by hard work. It is of a dull aching character. Weakness and stiffness of the spinal column are usual, although only a few of the patients notice deformity Occasionally shortening of the torso and decrease in height have occurred Some of the patients have a slight waddling gait and some a marked limp

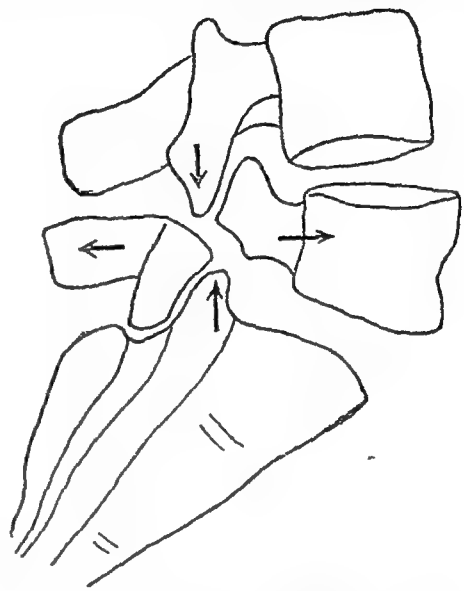

Fig 279 —Diagram showing the wedge-like influence of the upper and posterior part of the Sacrum further splitting the unfused segments of the Lumbar Vertebra (Capener)

Physical Signs

In the fully developed case the trunk is shortened, and transverse furrows are seen encircling the body between the ribs and the iliac crest. There is a diminution of the space between the ribs and the crest of the ilium, and between the xiphoid cartilage and the pubis The sacrum is prominent, and there is a still greater prominence of the fifth lumbar spine with a depression above. The shortening of the trunk gives an appearance as though the spine had been telescoped into the pelvis This makes the iliac crests appear to rise, whereas in congenital dislocation of the hip the shortening of the trunk is due to the descent of the pelvis. The latter condition exaggerates the bitrochanteric diameter in relation to the bi-iliac, which is lessened. In spondylolisthesis, on the other hand, the bi-iliac diameter, normally

process of the fourth lumbar vertebra may rest on the sacrum. In extreme cases the inferior surface of the fifth lumbar body is shown



FIGS 283 and 284 —X-ray showing the Gap in the "Terrier's" Neck in a case of Spondylolisthesis of the Fifth Lumbar Vertebra.

in close apposition to the anterior surface of the first sacral body with which it may be ankylosed, or it may glide still lower and reach even the third sacral vertebra.

TREATMENT

Many cases of spondylolisthesis have comparatively few symptoms and accordingly in these cases no treatment is indicated By the time the patient presents himself there is no possibility of reducing the displacement, as the soft structures have by this time become firmly fixed and shortened, and in any case there is no method of getting sufficient leverage to produce a reduction. Where the symptoms are slight the treatment is based on the assumption that it is the result of mechanical strain consequent upon the upright posture The first objective therefore, is reduction of this strain by flexing and balancing the lumbar curve, and the restoration of tone to the muscles that maintain it. Temporary support, exercises, and occasionally

above instead of from the front The lateral radiograph furnishes absolute proof of the presence of any anterior slipping of the fifth lumbar body on the sacrum. Normally when a straight edge is placed along the shadow of the anterior border of the first sacral body it will project upwards and forwards well to the front of the shadow of the fifth lumbar body, but in spondylolisthesis the straight edge will cut into the body of the fifth lumbar vertebra This is known as Ullman's sign

FIG 281 —Antero-Posterior Radiograph to show the characteristic bow appearance Scoliosis can also be observed from unequal slipping forward of the body

FIG 282 —Lateral Radiograph to show slipping forward of the body of the Fifth Lumbar Vertebra on the Sacrum

Spondylolisthesis is best shown, however, by an oblique view as this enables the pars interarticularis to be easily visualized An outline of a " Scots terrier " can easily be seen in this view with the neck formed by the pars interarticularis When there is a break or a separation here the terrier is decapitated and the lesion in the pars seen

One of the most characteristic features is a break in the laminæ This may appear as a gap continuing the clear space of the lumbo-sacral joint backwards above the spinous process of the fifth lumbar vertebra.

As evidence of spontaneous arrest, bony buttress formation may be seen attached to the anterior surface of the sacrum under the projecting portion of the fifth lumbar vertebra, and the lower articular

is produced between the sacrum and the displaced vertebra, extending backwards for about $\frac{3}{4}$ inch This gap is produced by removal of $\frac{1}{4}$ to 1 inch of the contiguous margins of the lumbar vertebra and sacrum and the intervening intervertebral disc. Autogenous bone grafts are now taken from the crest of the ilium to wedge into the gap. These are accurately fitted and punched home into the gap

Fig 286 —Spondylolisthesis
A very typical case showing the transverse skin creases

An accurately fitting block of bone is better here than chip grafts since the latter may produce pressure behind if punched home too enthusiastically The patient should be kept recumbent in a shell (in which, indeed, the operation is performed) for at least three months. A successful solid fusion gives complete relief in 90 per cent of cases

(c) The Spinous Processes.

If the laminæ fail to fuse, the epiphyses for the spinous process may remain separate and give rise to a distinct bone which can occasionally be seen in radiographs of the lumbo-sacral region In other cases, the spinous process may unite to the neural arch on one side only.

Kissing Spines. Normally between the spinous processes a distinct interval exists In certain cases, especially those with an increased lumbar curve, this interval is diminished, and the spines may be brought into contact, or even overlap In the X-rays a condensation of the bone may be detected on the margin of each spine where it is in contact with the other. A supernumerary joint is thus formed, and instead of two lateral joints on which the vertebræ swing forward and backward as on a hinge, the patient has three, arranged as a triangle. Any one or all of these may be sprained, giving rise to pain Some specimens of spinous processes show cartilage on the margin of the spine, and that the spines are actually in contact can be demonstrated at operation A joint in this situation is exposed to constant strain.

This is a very real, although comparatively rare, cause of backache The physical signs are not clear-cut In spite of the pain, mobility except in extension is not usually restricted. A list of the trunk may be present The diagnosis is made from the radiographs but may easily be overlooked unless the possibility be kept in mind

manipulation to free adhesions are used The results are often excellent, though for men doing heavy labour it is usually found necessary to change to a lighter occupation

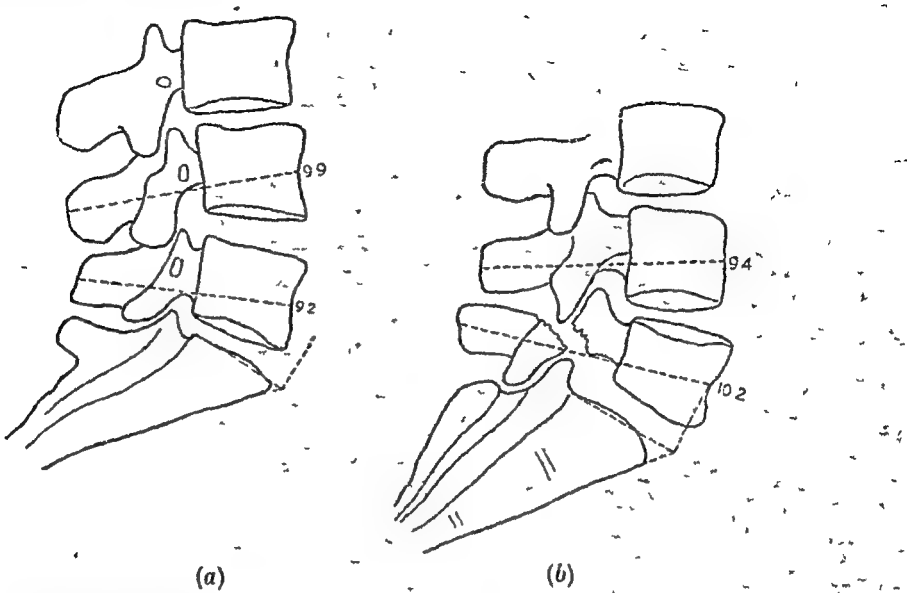

FIG. 285.—Diagram illustrating Diagnostic Signs on the Radiograph.

(a) The normal appearance
(b) i In spondylolisthesis the abnormal vertebra measures more than the one above it from the lip of the spinous process to the front of the body
ii Ullman's sign The body of the fifth lumbar vertebra projects in front of a perpendicular line drawn up from the front of the sacrum (after Capener)

Where the symptoms are extreme some operative method should be considered, and the method is usually one whereby the affected area is fused by grafting of bone. Many believe that before the fusion is carried out there should be complete removal of the loose lamina and its attached inferior facets together with the ligamentum subflavium above and below The nerve roots also may have to be relieved from adhesions on the osteophytic edge of the vertebra. Occasionally also the disc nucleus may be removed by curettage

The fusion may be carried out by one of the following methods.

1 *Posterior Arthrodesis* An arthrodesis of this part of the spine may be carried out after the method of Albee or Hibbs, fixing the spinous processes above and below as is done in a tuberculous spine This method helps to fix the slighter cases, but if there is any tendency for the deformity to increase a shearing strain is put upon the graft which may bend or break and fail to limit the increase in deformity

2 *The Author's Method.* The author's method may be used in some cases and has the advantage of fusing the bodies of the vertebræ together and is probably more effective in preventing further displacement The approach is made through a supra-pubic abdominal incision and the gap between the sacrum and the slipping vertebra is dissected free of the overlying soft tissue By means of an osteotome a rectangular gap

cervical vertebra. Nichol compares the ventral portions of the lateral parts of the sacrum with rudimentary ribs.

Ossification of the sacral vertebræ proceeds from three centres of ossification, one in the body and one in each of the two lateral processes, but in the first, second and third sacral vertebræ there appears, ventral to the centre of ossification in the lateral process, an extra centre of ossification analogous to the costal element which is the important factor in the production of a cervical rib.

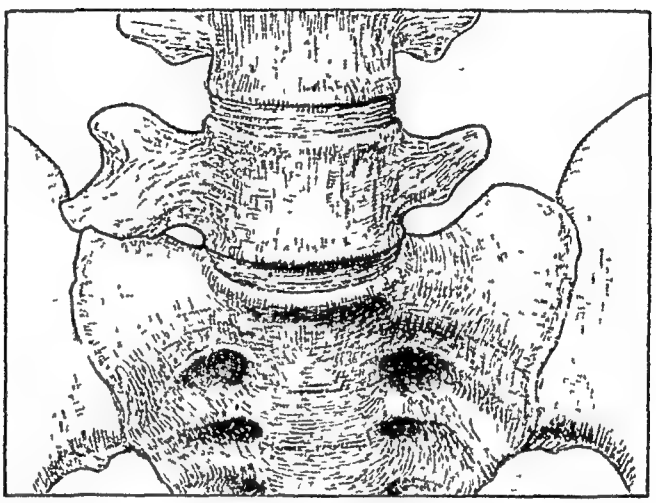

Fig 287—Sacralization of the Transverse Process of the Fifth Lumbar Vertebra.

The Clinical Picture

The patient, either a male or a female, usually begins to complain of symptoms about the age of 18 to 20. There is pain on the affected side low down in the back. Often there is a history of some trauma, a strain or a twist of the back, from which the symptoms date. Thereafter the pain becomes almost continuous and is accompanied by a general feeling of tiredness. There are acute exacerbations when the pain may shoot down to the back of the leg. The patient is unable to sit comfortably on the buttock of the affected side. The pain is worse after exercise or when tired, but is improved by the wearing of tight corsets and by lying in bed on the back or in the ventral position.

On examination it will be seen that the patient walks somewhat stiffly but without a definite limp. He is able to bend forward well but the back is kept stiff. Hopping on the leg of the affected side increases the pain. He rises from the stooping position slowly and with pain

On inspection it will be seen that there is a certain amount of flattening of the lumbar curve The spinous processes of the lumbar vertebræ appear to be slightly displaced to the affected side so that there is a lumbar scoliosis with convexity to the affected side. This remains even in the sitting posture The sacro-spinalis is tense on

TREATMENT

The reduction of movement in the lumbar spine by means of a lumbo-sacral brace may produce some alleviation of symptoms The rational treatment is operative. An ankylosing operation may be performed on the two vertebræ, the spines of which impinge, but better and far simpler is the resection of one or both spines close to their origin from the neural arches

Sprung Back. Newman has described what is the opposite of Kissing Spine in an article on *The Sprung Back* This condition occurs more commonly in the female and between the ages of 15 and 35. There is pain across the lumbo-sacral area radiating to the buttocks or further. It is a dull ache or a discomfort with acute exacerbations. The onset may be associated with a fall or blow on the back or a strain when lifting, or there may be no history of trauma On examination of the spine in relaxed flexion tenderness may be found in the mid-line between the fourth and fifth lumbar or fifth lumbar and first sacral spinal processes Frequently a depression is felt The pain is caused by rupture of the posterior ligaments of the spine, including sometimes the posterior longitudinal ligament and the annular fibrosus These ligaments may be torn by the same injury that produces a crush fracture of the upper lumbar vertebræ.

Though Newman says nothing about treatment it would appear that a short fusion of the implicated region would be the rational method of approach.

(*d*) Transverse Processes of the Fifth Lumbar Vertebra.

Most of the anomalies of transverse processes concern the fifth lumbar vertebra of which they comprise by far the most variable components. Variation in the size and shape of the transverse processes of the remaining vertebræ, such as may be seen in the third lumbar vertebra especially in women, is of little clinical significance.

Sacralization of the Transverse Processes of the Fifth Lumbar Vertebra. Sacralization is a developmental anomaly in which one or both transverse processes of the vertebra become abnormally large and strong They may become so large that they form a more or less intimate connection with the base of the sacrum or ilium, and by this union a foramen forms between the lower margin of the transverse process and the upper free edge of the sacrum instead of the normal broad and irregular cleft In such cases the transverse process often has the appearance of a butterfly's wing

PATHOLOGY

The so-called transitional vertebræ are vertebræ which by transition from one segment of the vertebral column to another have acquired the characteristics of both segments Instances of this are seen in the so-called cervical rib which is really a dorsalization of the seventh

and free at the other, the natural result is that the growth of both sacrum and fifth lumbar vertebra will be somewhat greater on the free side.

The form of the intervertebral cartilages and the fifth lumbar vertebra depends on the secondary lumbar curve. These become wedge-shaped, with the base situated anteriorly, while the remaining lumbar vertebræ have the same height anteriorly as posteriorly, so that according to the degree of wedge-shape taken by the fifth lumbar vertebra during the growth period, and to the amount of forward displacement of the vertebra, there is a greater or less degree of lumbar lordosis. When the fifth lumbar vertebra is fixed posteriorly by a broad unilateral or bilateral sacralization it cannot participate in the formation of the secondary lumbar curve by moving forward, the curve therefore does not develop and instead of the normal lordosis a flat back results. This appears to be the explanation of the flat back and the scoliosis in these cases

Various theories have been put forward for the local pain It has been suggested that it might be due to compression of muscle or fibrous tissue between the process and the sacrum or ilium, irritation of a bursa, or arthritis of the new joint, while many have suggested that it was due to compression or stretching of nerve fibres where they leave the column. The fourth lumbar nerve is said to be occasionally stretched over the large transverse process. The posterior branch of the fifth lumbar nerve comes out in front of the transverse process of the fifth lumbar vertebra which, even in its worst form, appears to leave sufficient room for the branches of this nerve. Most of the X-rays of sacralization show an ample interval between the body and the transverse process of the fifth lumbar vertebra, and the lateral part of the sacrum, while in none of the cases reported is there definite evidence of clinical symptoms arising from a nerve compression

The probable cause of the pain, which is situated in the region of the sacro-iliac joint, is a distraction of this joint produced by the leverage of the abnormal process in lateral movement of the spine The process impinges on the ilium and strains the ligaments of the joint.

Treatment

The removal of the offending process would appear to be the rational form of treatment though an arthrodesis of the sacro-iliac joint has also been suggested

Posterior Route This is probably the route of choice Bonniot has described the anatomy and though the process is situated deeply, a comparatively easy removal can be achieved if a large triangular segment of the ilium is freed by an osteotomy and turned downwards. A preliminary X-ray picture with a mark on the skin is helpful in locating the abnormal process The area is approached through a curved incision like that used by Smith Petersen for his sacro-iliac

the affected side The lower limbs are normal in movement and musculature, as are the sensation and reflexes There is marked tenderness over the sacro-iliac joint on the affected side, and to a less extent down the sciatic nerve.

On X-ray examination the degree of sacralization of the transverse process may be seen. The body of the fifth lumbar vertebra is slightly displaced laterally towards the abnormal process There is a scoliosis with the convexity towards the affected side. The enlargement of the transverse process will be noted and it is important to determine by means of stereoscopic X-rays, whether or not the free end of the process is impinging on the ilium. Between the body of the vertebra, and the sacrum and the transverse process, a well-marked intervertebral foramen will be noticed.

Although this anatomical anomaly has been present since childhood it usually does not produce symptoms before the age of 20. This discrepancy is connected with the ossification of the vertebral column, and it is only when the column has acquired its final stiffness that the asymmetrical fixation of the fifth lumbar vertebra to the pelvis may produce symptoms Up till then the natural resilience of the relatively soft bone does not cause sufficient pressure to give rise to symptoms, nor does it fix the spine so firmly.

For the explanation of the flattening of the spine and the scoliosis, one must turn for a moment to the development of the spinal curves. The normal curves of the adult spine are only partially present at birth They develop later under the influence of the upright carriage. Early in the life of the embryo the so-called primary curves in the thoracic and sacral regions with the concavity forwards can be demonstrated, while the so-called secondary or compensatory curves in the cervical and lumbar regions develop during the first few years of life —the cervical curve when the child can hold the head erect, and the lumbar curve when the child can walk, i e between one and two years of age The transverse process of the fifth lumbar vertebra in the normal fully grown skeleton lies more than one centimetre anterior to the posterior superior iliac spine, so that during the development of the secondary lumbar curve the fifth lumbar vertebra slips forward a little in relation to the ilium and sacrum With these portions of the skeleton it does not make bony union, but is united only by means of its articulation and ligaments When a sacralization is present, the transverse process has grown towards the lateral mass of the sacrum or the ilium in its posterior part as well and has become fixed to either or both. This fixation of the lumbar vertebra to the pelvis is, of course, abnormal In the normal development of the secondary lumbar curve the fifth lumbar vertebra remains with its one transverse process fixed posteriorly by its union with the sacrum or ilium In this way originates a scoliosis with its convexity towards the sacralized side. This abnormal fixation likewise explains how the fifth lumbar vertebra is drawn over towards the sacralized side, since, being fixed at one side

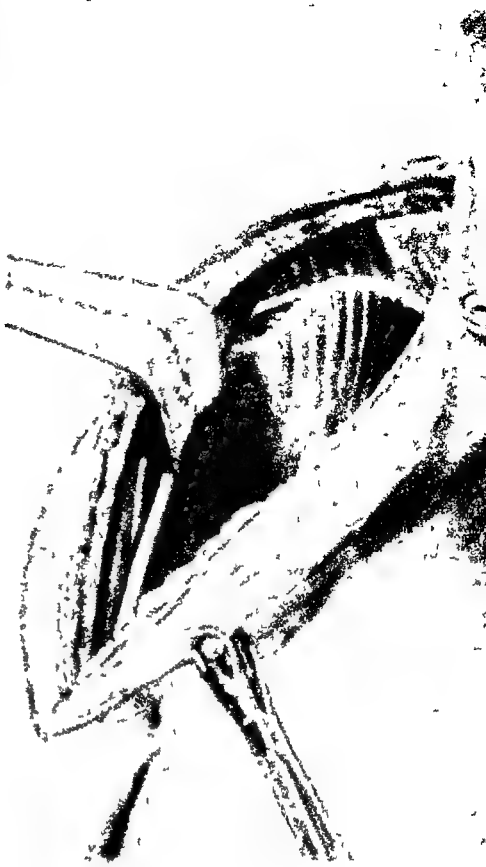

(h)

operation A good view of the process is got and it is freed by curved elevators which are left in to protect its anterior aspect while severing it The triangular segment of ilium is replaced and heals quickly

Anterior Route. With the patient on his back and with the hips flexed to relax the psoas, a long incision is made as though exposing the lower end of the ureter It extends from the costal margin down into the right iliac fossa, in the line of the fibres of the external oblique. This muscle is split in its length right up into its muscle belly. The internal oblique and the transversalis are then cut across in the line of the skin incision and the peritoneum exposed. The peritoneum is swept medially by means of gauze dissection and packed there with a gauze swab, and the whole operation carried out extra-peritoneally The ureter is carried medially with the peritoneum. The iliacus muscle, with the lateral cutaneous nerve of the thigh running across it, and the psoas muscle, are thus exposed (Fig. 288 *a*) and a finger is inserted to localize the posterior part of the iliac crest. This is located and the examining finger pushed along it until the abnormal process is felt, and it is felt quite easily. The femoral nerve is seen at the lateral border of the psoas, and, along with the genito-femoral nerve, and the obturator in the muscle at this part, is retracted medially and anteriorly (Fig. 288 *b*). The iliacus muscle is now incised at its medial part where it is attached to the posterior part of the iliac crest and the fibres of the anterior sacro-iliac ligament, and turned downwards (Fig. 288 *c*) Lying behind the muscle and in front of the abnormal process there is a mass of adipose tissue, and in it, at the base of the process, are three branches of the fourth lumbar nerve, one to the sacro-spinalis, one to the obturator, and one to the femoral. A descending branch of the fourth artery and vein may be found passing over the transverse process at its base. These may lie in the substance of the psoas but in any case give rise to no operative difficulty The parent trunks to the fourth lumbar vessels lie a variable distance above the upper border of the fifth transverse process Occasionally they are in actual contact with the process and might require ligation With a blunt periosteal elevator the fatty tissue is elevated medially to expose the abnormal process A very good view of the process is now obtained and by means of an osteotome the part articulating with the ilium is cut off (Fig. 288 *d*) There is usually no bleeding. It is easy to remove the greater part of the process The wound is stitched up in layers and a small rubber drain inserted for 24 hours

2. Low Back Pain following Trauma

(a) Sacro-iliac Strain

Etiology

There is a small but measurable range of movement at the sacro-iliac joints.

position Although the pain begins over one sacro-iliac joint it may extend to the opposite side, round the pelvis and down the whole course of one or even both sciatic nerves Occasionally pain is complained of inside the pelvis Coughing or sneezing produces pain.

Attitude In standing the body is usually inclined away from the side of the affected joint, and the shoulder on the affected side is often lower than on the good side. At rest the knee and hip will be noted to be slightly flexed on the affected side—an attitude which decreases the strain on the joint In rising, the spine is usually held rigid and the hands frequently used to obtain additional support. In stooping, flexion of the trunk is avoided When the condition is acute, long steps in walking are impossible because of the co-existing spasm of the hamstrings

Limitation of movement Movements of the body on the thighs, or of the thighs on the body, are limited. Forward bending of the trunk with the knees held straight is restricted if the lesion is of any magnitude To determine whether the limitation is the result of spinal disease or of sacro-iliac disease, the tension of the hamstring muscles should be released by allowing the patient to sit Similar movements are now attempted; when the spine is involved the limitation will be found to persist, but in lesions of the sacro-iliac joint flexion can now be carried out easily and without pain

When attempts are made to flex the hip with the knee fully extended, marked limitation is present in sacro-iliac lesions and attempts to increase the range of movement cause pain referred directly to the sacro-iliac joint involved This phenomenon is known as Goldthwaite's sign Often pain in the affected joint is elicited by flexion of the opposite leg.

Albee states that the following symptom complex is almost pathognomonic of sacro-iliac disturbance

(*a*) Pain in the region of the joint on turning over from the recumbent position.

(*b*) Discomfort while lying on the back.

(*c*) Pain while sitting on a hard chair, relieved by sitting on the opposite buttock

(*d*) Pain in the affected joint on forward bending.

(*e*) Pain on deep pressure over the affected joint.

(*f*) Listing of the whole spine to the opposite side.

(*g*) Positive Goldthwaite's sign

McBride has described a "toe-to-mouth" test for sacro-iliac pain The patient stands on one leg and draws the toes of the opposite foot towards his mouth, bending his head forcibly forward. The test is positive if there is pain in the sacro-iliac joint opposite the leg that is being lifted The theory of this test is that all the weight is suspended on the opposite sacro-iliac joint and motion will occur in the joint and cause pain if pathology is present

The opposing sacral and iliac surfaces of the joint are irregular, but so arranged that the opposing irregularities fit together accurately The opposing surfaces are smoother in the female joint and thus the range of movement is greater in the female, attaining its maximum range in pregnancy due, it is said, to a special hormone of the corpus luteum called relaxin of which there is an over-secretion at this time This smoothness and range of movement makes the female joint weaker The condition to which the term "sacro-iliac strain" is applied occurs when the joint becomes locked at one or other of the extremes of range of movement It may frequently be demonstrated in spare subjects that the ilium is displaced in relation to the sacrum by palpation of the posterior superior spines, or even by inspection, when it will be noted that the spine on the affected side is more prominent than the spine on the normal side The locking may occur as a result of the stress incurred while lifting a heavy weight, of the strain of increasing obesity, or during pregnancy, when the shearing strain due to the increase of lumbar lordosis in addition to the laxity of the sacro-iliac ligaments makes displacement of the joint a matter of common occurrence. It may occur however, without injury, is often bilateral and is more common in the female sex.

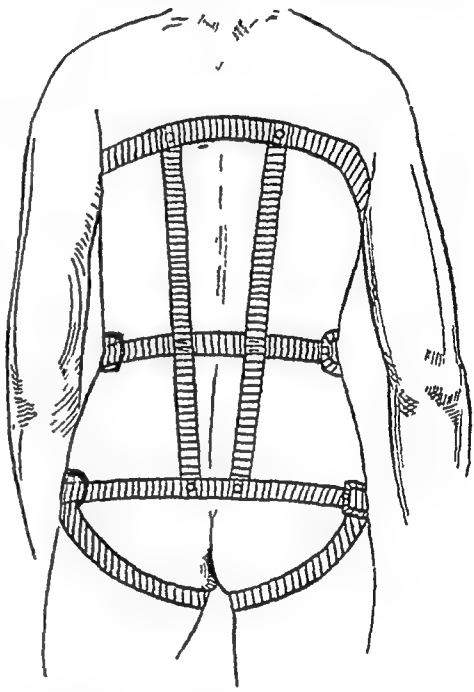

Fig 289—Low Back Pain Type of appliance useful in cases of strained back, especially of the lumbo-sacral joint.

Symptoms and Signs

The symptoms accompanying sacro-iliac strain vary considerably, but certain features are constantly present.

Pain. Pain is experienced over the posterior aspect of the joint or the sacro-spinalis over it and may be elicited by digital pressure in that area. It is increased by movements which put added strain on the joint. It is constantly more severe at night because the recumbent position obliterates the normal lumbar lordosis and throws more strain on the joint. Exacerbations also occur at the menstrual periods as the increased congestion at that time causes softening of the joint ligaments and increased joint mobility. Standing or sitting for long periods also leads to an aggravation of the pain Lateral distraction or compression of the iliac crests may or may not produce pain in the joint There is pain on forward pressure of the sacrum with the patient in the prone

Radiographic Appearances. There are no characteristic radiological changes in acute sacro-iliac strain and often no abnormality is seen. In cases of long standing, however, the joint undergoes arthritic change, the radiological appearances of which are:

(*a*) Increased density along the margins of the joint.
(*b*) Proliferative changes at the inferior margin of the joint.

The real reason for X-raying the joint is to exclude other abnormalities.

Differential Diagnosis

Sacro-iliac arthritis must be differentiated from the following conditions:

(1) *Lumbo-sacral strain* Here the tenderness is over the fourth and fifth lumbar spines and lumbar movements are restricted in all directions, while straight leg bending shows limitation in extremes on both sides

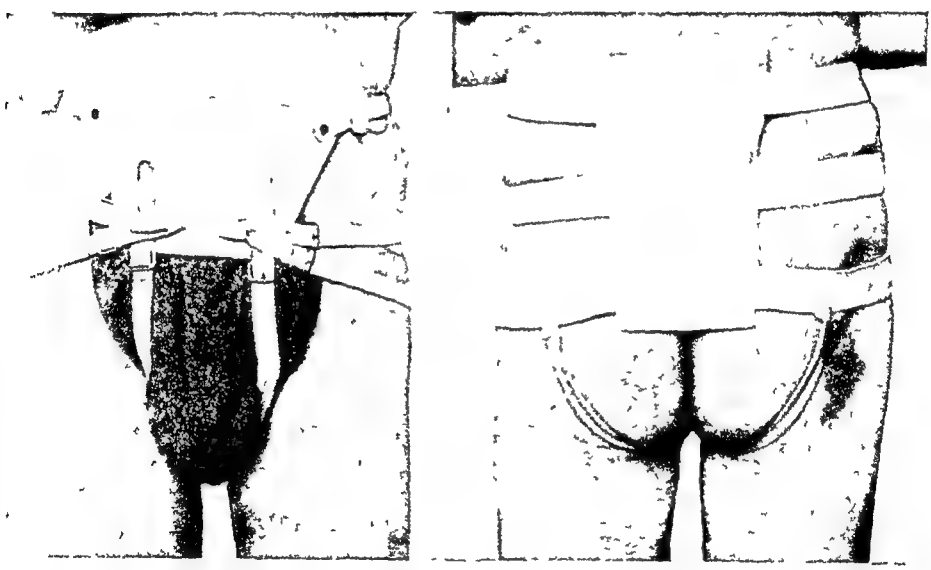

Figs 290, 291 —A supporting Sacro-iliac Belt, useful in cases of strain of this joint

(2) *Lumbar back strain* This is a localized rupture of the deeper fibres of the sacro-spinalis. There is muscular spasm of this muscle and a definite localized point of tenderness on one side and fairly general hyperæsthesia

(3) *Lumbago* The pain is much higher, is stabbing in nature, and affects the lumbar muscles on both sides Goldthwaite's sign is absent

Treatment

The treatment of both the acute and chronic varieties is essentially by manipulation designed to correct the displacement and to restore mobility in the joint, together with physio-therapeutic measures and spinal exercises to increase muscle tone and correct faulty posture No manipulative treatment is undertaken until the possibility of

are common. In addition to the great variations in the angle, this region is unstable for the following reasons

(1) It is the junction of a mobile and a fixed part of the spinal column

(2) It is developmentally designed for the four-footed position and hence is at a disadvantage in the upright position.

(3) It is the site of a rotatory action which is often asymmetrical.

(4) It is the site of great shearing strain.

Structural abnormalities in the lumbo-sacral region render this part of the spine more vulnerable to mechanical stress and strain than is normal. This does not imply that all individuals with anomalies in this area have symptoms in consequence, but it does mean that if an individual with symptoms referable to the lower part of the back is found to have some anatomical variation in the lumbo-sacral region, this anomaly may well be held responsible for the symptoms until or unless another cause can be demonstrated.

Lumbo-sacral strain occurs in both acute and chronic forms. The acute form may be caused by a sudden blow forcing the joint into positions beyond the normal range of movement, by an effort to prevent a heavy article falling, or by a sudden body movement while attempting to regain lost balance. The spinal muscles are caught off guard and thus the ligaments sustain the full force of the injury.

The chronic form is usually insidious in onset but may follow an acute strain which has been unrecognized or untreated. It occurs in the long weak type of back with poor musculature and an increase of the normal lumbar lordosis or in a type of patient, usually a woman, whose increase of weight in recent years takes the form of a pendulous abdomen The maintenance of body balance necessitates an exaggeration of lumbar lordosis with consequent increase of the shearing strain at the lumbo-sacral angle In certain cases narrowing of the intervertebral disc space is noted as a result of traumatic arthritis. As the bodies approximate there may be encroachment on the intervertebral foramen with root pressure.

Symptomatology. In acute cases with a history of recent trauma the pain and tenderness are situated at the lumbo-sacral junction and the movements of the spine are restricted in all directions. A lumbo-sacral case will bend forward freely, however, whether sitting or standing, because he holds the lumbo-sacral region rigid and flexes chiefly at the hip-joints

In chronic cases the symptoms vary, some patients merely complaining of a "weak back" which tires easily, while others suffer very acute pain and real disability Often there is a history of intervening periods of comfort lasting several years, between attacks of pain, but gradually the attacks become more and more frequent or the pain may become constant as age advances Sciatic pain and sciatic scoliosis may be present if there is root pressure

cavity. The rectangular block removed from the ilium is then denuded of cartilage on its sacro-iliac surface and replaced and counter-sunk so that its cancellous surface makes contact with the cancellous bone

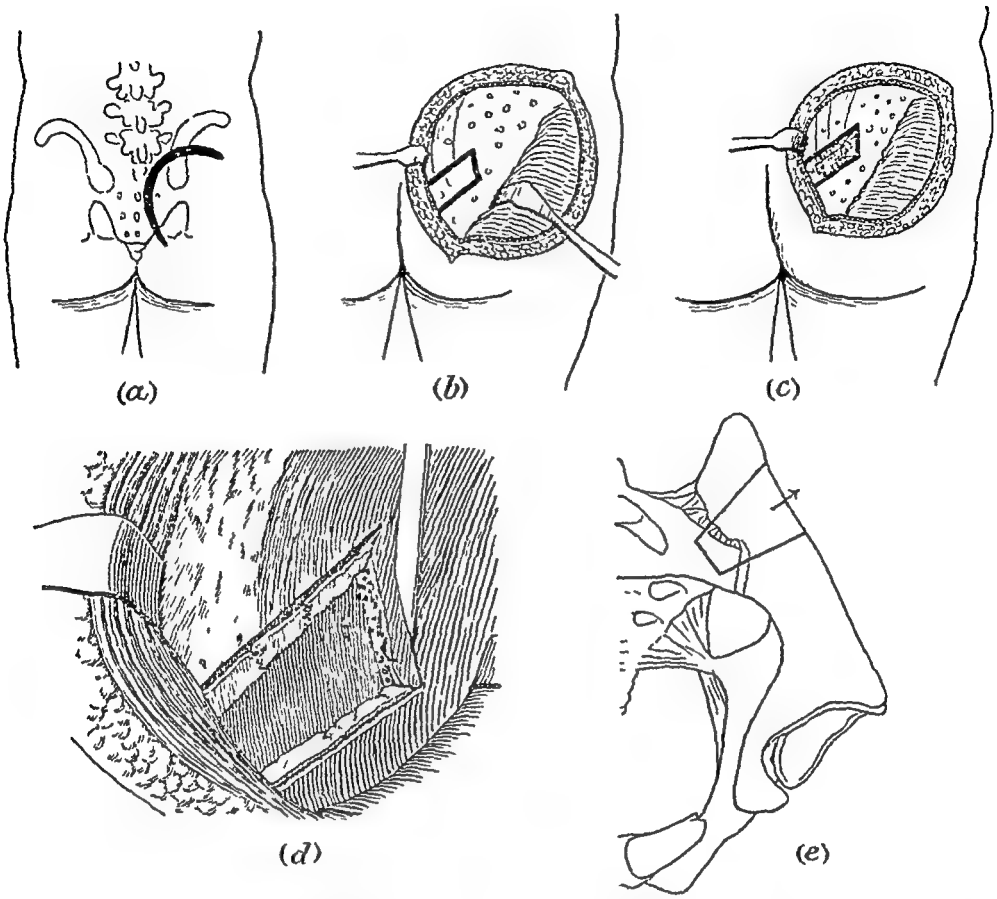

FIG 292 —The Smith-Petersen operation for Arthrodesis of the sacro-iliac joint (a) The incision (b) The bone cut outlined (c) Removal of bone segment (d) Bone reshaped and inserted and edge broken over it (e) The bone removal on section (After Smith Petersen)

of the sacrum To secure the closest contact and to promote osteogenesis the edges of the defect in the ilium may be broken in over the block At the completion of the operation the patient is immobilized in a previously prepared posterior plaster shell for a period of two to three months by which time arthrodesis is complete In many cases it is necessary to arthrodese both joints.

(b) Lumbo-Sacral Strain

Etiology

In the embryo of 9 weeks the sacrum is nearly straight and forms a direct continuation of the lumbar region. From this time onwards the sacrum alters its direction and the lumbo-sacral angle begins to form In the adult the average angle is 120 degrees, but variations

factors as increase of weight causing an exaggeration of the lumbar curve, active toxic foci and constipation must receive attention. Thereafter exercises designed to flatten the lumbar curve, increase muscle tone and improve posture form the essential local treatment. The fitting of a back brace is rarely necessary or desirable, but those patients with pendulous abdomens frequently benefit from the support of a lumbo-sacral belt or strong corset.

Manipulation as an isolated measure can only produce transient improvement in chronic lumbo-sacral strain but, in long standing cases, especially where there is evidence of initial trauma, is of extreme value in mobilizing joints and breaking down adhesions prior to back and postural exercises (see Chapter XVIII)

In severe cases of long standing which have failed to react to conservative treatment, the joint may be arthrodesed in a similar manner to that used for tuberculous disease of the spine (see p 329) Where there is root pressure an operation will be directed to its relief and this may require a facetectomy

(c) Injuries of Intervertebral Joints, Ligaments and Muscles.

These injuries are produced by such external violence as overstretching of the spinal column and are thus common in the mobile areas of the cervical and lumbar regions.

The pain is sudden, and although increased by certain movements, it is constantly present during the acute stage and is only partly relieved by rest

In addition to severe pain, muscular and ligamentous sprains and injuries of the intervertebral joints are frequently associated with limping and with muscular spasm and lumbar rigidity, and often a side list of the spine The patient walks with a very slow and painful gait. It is often difficult to determine the exact site of the lesion, but when the muscle alone is affected, the symptoms are intensified when the muscle contracts and when it is put on the stretch The common sites of muscle strain are either the origin of the sacro-spinalis from the back of the sacrum (the so-called multifidus triangle syndrome), or the origin of the gluteus maximus from the posterior superior iliac spine and the sacro-tuberous ligament The underlying pathology is simply the rupture of some fibres with consequent exudation and swelling. Steindler's novocaine test is carried out by injecting into the tender area 5–10 c c. of 1 per cent. novocaine Three postulates must be met before the diagnosis is proved (1) Contact of the needle aggravates the local pain and the frequent radiation pain down the leg, (2) Novocaine injection abolishes the local pain and the radiating pain; (3) Novocaine injection restores normal straight leg raising. Healing takes place through the medium of fibrous tissue but it is the object of treatment to avoid the excessive production of fibrous tissue with resulting adhesion formation or fascial contracture.

In ligamentous injuries the pain is deep-seated and can be elicited

Differential Diagnosis

Lumbo-sacral strain is distinguished from a sacro-iliac lesion by a consideration of the history and the examination of the case Smith Petersen has summarized the differential diagnosis in convenient tabular form (see below).

Treatment

In the acute stage rest in bed for a period of 2 to 6 weeks is essential. The patient should lie in a bed fitted with fracture boards, and pillows are placed beneath the knees. When the acute symptoms have subsided, massage, radiant heat and diathermy are of assistance, and as improvement takes place graduated spinal and postural exercises are instituted. Chronic lumbo-sacral strain presents a more complex problem and dramatic results are not to be expected. It is necessary to seek the underlying cause before local treatment is commenced Such

	Lumbo-sacral	*Sacro-iliac*
History—trauma	Leverage from above with spine in flexion.	Leverage—unilateral via lower limb.
Pain—		
1 Referred to	Fifth lumbar, First sacral areas	Fourth and fifth lumbar areas First and second sacral areas
2 Distribution .	Lateral side leg Dorsum foot Sole of foot	Especially posterior aspect of thigh, and adductor regions
Points of tenderness	The ilio-lumbar ligaments, spinous processes of fourth and fifth lumbar, and first sacral vertebræ	Inferior sacro-iliac ligaments Greater sciatic notch
Movements of spine .		
(*a*) Standing	All lumbo-sacral motion is restricted	All free except unilateral side bending, forward bending in extremes
(*b*) Sitting .	All restricted as in standing position	Forward bending free with hamstrings relaxed
(*c*) Lying . .	All restricted	Free
Special tests		
(*a*) Straight leg raising	Limited, in extremes, on both sides equally.	Unilateral limitation at small range
(*b*) Compression of pelvis	Nil	Occasional pain in sacro-iliac joint

spine" or traumatic neurosis—is especially serious from this point of view When it is suspected that the patient is exaggerating his disability, or that a frank neurosis has developed, the services of a neurological expert should be enlisted, as the treatment of the mental condition is of more importance than that of the back.

3. Low Back Pain associated with Pathological Changes

(a) Osteo-arthritis of the Spine (Spondylosis Deformans). According to some authorities—Shore and Fletcher—there are several varieties of this condition:

(*a*) Polyspondylitis marginalis osteophytica
(*b*) Osteo-arthritis of the spinal apophyseal joints
(*c*) Spondylosis ossificans ligamentosa

(*a*) *Marginal Polyspondylitis* is the condition usually referred to as osteo-arthritis of the spine and is characterized clinically by pain in the back for which other causes have been excluded, and radiographically by lipping of the vertebral bodies at or near the site complained of Osteophytes appear on the lateral and anterior aspects of the vertebral bodies and not from the spinal aspect They are broad at the base, taper off, and do not spread over the cartilaginous surfaces of the bodies but may span an intervertebral interval. It is unusual to have them formed on a single vertebra The osteophytes arise from the short deep fibres of the anterior common ligament where they are firmly attached to the edges of the body They lie, therefore, a little below the outer edge of the epiphyseal ring and proliferate so as to overlap the intervertebral space until eventually osteophytes from neighbouring vertebræ may fuse together. The osteophytes arise principally at the junction points of the antero-posterior curves of the spinal column, that is about the fourth cervical, eighth to ninth dorsal, and fourth to fifth lumbar region. At these points the vertebræ are prone to slide and rotate on one another, while at other parts the bodies are held firmly in place by the direct strain which they take Degeneration of the discs and loss of turgescence in the nucleus pulposus are often precursors of polyspondylitis and this forms a typical feature of this form of the disease

(*b*) *Osteo-arthritis of the apophyseal articulations* The dorsal arch of each vertebra provides a superior and an inferior articular process. These form movable synovial joints and are frequently the seat of osteo-arthritis This occurs where the joint balance is upset, as in scoliosis on the concave side, and also following the collapse of a vertebral body from disease or injury. Shore concludes that osteo-arthritis might be held here, as elsewhere, to represent an effect of wear and tear The sites of lesions in this type of disease are the seventh cervical to first thoracic, second to fifth thoracic, and in the second, third and fourth lumbar vertebræ

(*c*) *Spondylosis Ossificans Ligamentosa* Fletcher describes this lesion as characterized clinically by pain in the back with local ossifica-

both by movement of the spine and by pressure with the finger. In contrast to muscle injuries, active and passive movements in the same direction both produce pain.

Muscle or ligament strains if of long standing are frequently complicated by a referred sciatica and may be associated with mild infective attacks of the nature of acute fibrositis, during which the pain becomes more diffuse and tenderness can be elicited over a wider area.

The most common minor injury of an intervertebral joint results from an unexpected movement or sudden strain which causes the joint to lock at the extreme limit of its range of movement This lesion, which occurs most frequently in the cervical region but is also encountered in the lumbar spine, causes extreme pain and associated muscle spasm. It may be diagnosed from sprains of muscle and ligament from the history of the type of injury, the localized tenderness and muscle spasm and the fixation of the area of the spine affected so that rotatory movement is almost entirely lost

Treatment

In all severe acute traumatic cases the patient is treated by rest in a bed fitted with fracture boards The back is supported by firm bandaging, adhesive strapping, a lumbar belt, or even a plaster jacket may be necessary. Physiotherapy is contra-indicated in the early acute stage as it merely increases local hyperæmia and exudation but when the acute phase has passed radiant heat followed by graduated active exercise is of service. In many cases instant relief can be obtained by infiltrating the carefully located area with 20–50 c c 's of ½ per cent novocaine This procedure may be repeated every second or third day and is often of considerable value in accelerating recovery.

In early cases of sprain of muscle or ligament passive stretching or manipulation merely increases exudation and scar tissue formation and is therefore contra-indicated In chronic cases manipulation is of value in breaking down the adhesions which have resulted from excessive fibrous tissue formation. Adhesions and contractures may result from these soft tissue strains and are most marked in the gluteal fascia below the posterior superior spine or anteriorly in the region of the tensor fasciæ latæ and ilio-tibial band.

When the injury can be localized to an intervertebral joint, assumed to be "locked," instant relief is obtained from manipulating the area concerned through its full range of rotation in both directions under nitrous oxide and oxygen anæsthesia

In many cases, particularly those who apply for treatment only at a late stage, the symptoms will persist or even become worse. It should be borne in mind that in this type of case, the patient, consciously or unconsciously, exaggerates his symptoms Indeed, injury to the back more than any other lesion is liable to be followed by evidences of a serious and demoralizing neurosis The spinal symptoms which occasionally follow railway accidents—the so-called "railway

breast, are quite common. Often at the original operation the breast tumour was found to be small and apparently benign, and yet an X-ray film shows evidence of secondary deposits in the vertebræ Other neoplasms are rare but should be considered.

(c) **Fibrositis (Lumbago).** Fibrositis refers to cases of low backache where one or more tender nodules may be found lying fairly superficially in the erector spinæ or its attachments, or in the region of the muscular attachments to the crest of the ilium. In the lumbar region it is called lumbago. It has been divided into primary and secondary types, but it appears doubtful whether there really is a primary form and, indeed, this is denied by pathologists. Tender nodules are found in the buttocks in sciatic backache in muscles innervated by an affected root. Pressure on these aggravates the pain and novocaine injection relieves it Elliot believes that these tender areas are due to a local muscular spasm arising from irritation of the nerve root. This has been confirmed by pathological investigation and electromyographs. Cyriax believes that if the case is thoroughly investigated it will be found that the cases ascribed to rheumatic fibrositis, that is the cases coming on without apparent reason, are in fact the result of articular lesions Local fibrositic inflammatory nodules and another explanation, herniation of fat-lobules, have not been found on pathological examination Lumbago is probably caused by some internal derangement at a low lumbar intervertebral joint.

Fig 294 —Spinal Support used in cases of osteo-arthritis and injuries to the back.

The pain comes on suddenly while the patient bends his back and is so severe that he is at once immobilized in his lumbar region by muscular spasm. After this acute phase examination shows that lumbar extension is impossible Cyriax believes that the syndrome is caused by posterior displacement of part of the cartilaginous disc in this small joint. This may show the signs of sciatica—lumbar deviation and limitation of trunk flexion. Recurrences are common and the condition may become chronic. The pain is usually central, becoming unilateral later, though the reverse may occur. When neurological signs are present it is probable, of course, that a disc has been protruded.

Treatment The principle is to secure reduction of the displacement causing the symptoms. Recovery of more than half the cases occurs with a complete manipulation of the lower lumbar region. Rest in bed will alleviate the symptoms in most cases if the time can be spared

tion of ligaments as shown by X-ray films Local movement may or may not be limited. This type is rarer than the others. The patients are nearly always of the age of 40 years and upwards and rather more females than males are affected. The condition is found in the cervical and thoracic vertebræ principally.

Symptomatology. The commonest complaint is pain in some portion of the back and most commonly in the lumbar region The pain in a few cases radiates and is then fairly severe. In the cervical region it tends to go down the arms, the thoracic pain round the thorax, and the lumbar pain down the legs In lumbar cases sciatic pain may occur but it is unusual. It is felt more often on the front of the thighs and on their lateral aspect. Pain in this region is unusual in

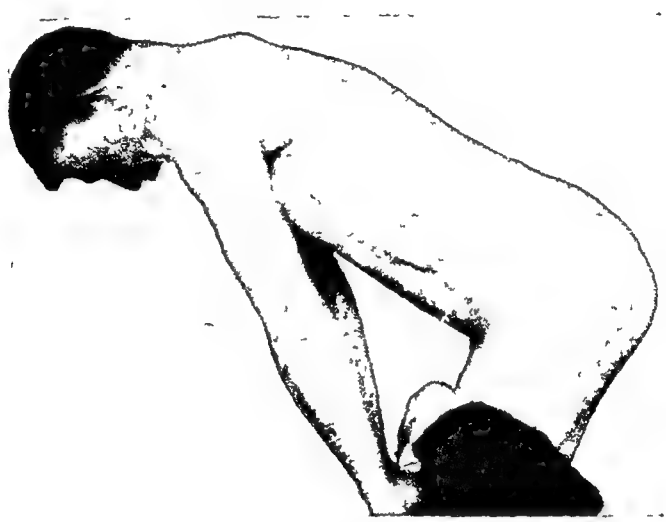

Fig 293 —"Poker Back" appearance on Spinal Flexion

other conditions but neuritis of the lateral cutaneous nerve of the thigh, osteo-arthritis of the hip, a renal origin, and infiltration in and around the inguinal ligament must be considered

X-ray pictures are helpful in diagnosis and if taken at suitable angles the posterior joints of the spine can be visualized The appearance of osteo-arthritis of these joints differs from the same condition in limb joints in that sclerosis is very severe, the joint space becomes lost, osteophytes are infrequent, and loose bodies are never seen.

Treatment is by no means easy. In early stages manipulation of the spine often results in a considerable amelioration of the pain Deep X-ray therapy is disappointing Immobilization by means of a Goldthwaite brace for the thoracic or lumbar region may be helpful and if the lesion is sufficiently localized and the general condition of the patient permits a posterior fusion of the area will cure the pain.

(*b*) **Other Pathological Errors of the Spine.** Specific infections of the spine, e g tuberculosis, syphilis, and osteomyelitis, are considered in other chapters Cases of spinal metastases, from carcinoma of the

In the early stages there is an ulcerative lesion with a tendency to spread to adjacent segments because of the fact that the vertebral bodies lack a compact bony layer, thus allowing the intervertebral discs to become involved and rapidly destroyed by the proteolytic enzymes of the pyogenic exudate. In tuberculous infection the disc substance is not so readily destroyed and the route of spread to attack adjacent segments is under the anterior common ligament Martin points out that these changes are of value in the differential diagnosis, as in pyogenic osteomyelitis early narrowing or disappearance of the intervertebral space is evident. Although narrowing of the space is seen in tuberculous disease it is neither so early nor so marked a feature as in the pyogenic form. The abundant blood supply with the local excess of calcium results in early massive new bone formation, giving rise at first to beaking of the lower and upper margins of adjacent vertebral bodies, and later to a fusion of adjacent vertebræ by means of these bony outgrowths The free blood supply and the cancellous nature of the bone make the formation of sequestra unlikely

This early subperiosteal new bone formation is an important point in the diagnosis In pyogenic osteomyelitis collapse of the bodies and gibbus formation are not common as the severity of the symptoms, particularly the pain, leads to the patient taking to his bed at an early stage Suppuration is common and abscess formation often occurs, and often of a large size These enlarge, usually forwards, and are

Fig 295 —Osteomyelitis of Vertebræ showing Characteristic New Bone Formation Lateral View

Fig 296 —Antero-posterior View of the Same Case

Secondary Fibrositis. Cyriax describes four categories of this condition

1. *Traumatic fibrositis* occurs from tearing of a muscular insertion. As a result of the torn edges beginning to heal and then being pulled apart each time the muscle is used excess scar tissue is laid down. In a week or two there is pain from the development of chronic traumatic fibrositis

2 *Rheumatic fibrositis* Nodular perineuritis and polymyositis complicate rheumatoid arthritis Cyriax points out that rheumatoid arthritis is a generalized disease of the fibrous tissues of the body in which the chief and most obvious incidence is on the capsule of the joint But in addition to the joint lesion the tendon sheaths thicken, the tendons become rough and nodular and bursæ swell and fill with fluid.

3 *Infectious fibrositis* An infectious disease called Bornholm's disease is an epidemic myalgia and is caused by a virus. It is characterized by fever, severe pain in the abdominal and thoracic muscles, and a quick recovery.

4 *Parasitic fibrositis* occurs following infestation with Trichina spiralis.

Rheumatoid arthritis is the only condition to which the term generalized fibrositis properly applies

Pyogenic Osteomyelitis of the Spine.

When osteomyelitis of the spine forms a part of a generalized bacteræmia it has been almost a uniformly fatal disease, but this statement may be modified now that we have in penicillin such a potent factor in the treatment of such conditions In the acute and fulminating types, however, diagnosis is not often made of the osteomyelitis since it is only an incident in the course of the general disease , but in the less acute conditions, where the condition is limited to an affection of a region of the spine, the mortality rate is very considerably lower. Peter Martin, in a recent excellent article on the subject, suggests that many cases of tuberculosis of the spine which do well with early firm bony fusion are in reality cases of pyogenic osteomyelitis.

The disease is three times more common in the male than in the female and the age of onset is predominantly in the third decade, that is after the vertebræ are fully formed, thereby being different from osteomyelitis occurring in long bones This is ascribed to the presence of a cellular bone marrow with a sluggish blood flow which encourages embolism and thrombosis in pyæmic states.

The lumbar region is most frequently involved, and the bodies of the vertebræ are generally affected, usually as a metastatic phenomenon, the primary focus being recognizable in about half the cases as a typical infection, such as boil, whitlow, septic wound, or a tooth infection As in other types of osteomyelitis the causative organism is the staphylococcus aureus

	Pyogenic Osteomyelitis	*Tuberculosis*
Site of Disease .	Body usually, often appendages	Body almost invariably.
Primary focus	Typical pyogenic infection 50 per cent	Often T.B distant foci
Onset .	Usually sudden, sometimes gradual	Gradual
Pyrexia	Often marked	Seldom marked
Pain .	Intense.	Aching.
Leucocytosis .	May be marked	Not a feature
Vertebral collapse .	None	Usual
X-ray .	Increased density New bone Spread through disc.	Decreased density. No new bone Spread under anterior common ligament
Cord involvement . .	Rare and acute onset	Common and gradual onset
Course .	Short to bone fusion	Prolonged to recalcification ? fibrous fusion

The TREATMENT of the condition consists in immobilization of the spine in a plaster shell until the disease process is over and bony fusion is complete Abscesses are evacuated and penicillin both locally and systemically plays an important part in the treatment. Fusion is quite unnecessary as bony ankylosis is an early constant feature

Brucella Spondylitis The incidence of bone and joint complications of brucellosis is said to be about 30 to 40 per cent Back pain may be the presenting symptom or it may accompany or follow a febrile illness This may be associated with loss of weight, feverishness and sweating at night for several weeks Abscess formation in the shape of an ill-defined swelling in the iliac fossa may be palpable. Spinal movements may be full and painless when the spine is involved. X-ray examination of the spine may show marginal erosion of the body,

guided in their course by normal cleavage planes—forming psoas, perinephric, pelvic, or pelvi-rectal abscesses. An epidural abscess may form with compression meningitis or vascular disturbances in the cord The onset of spinal symptoms is sudden and dramatic compared with the more usual slow and gradual appearance in tuberculous disease.

SYMPTOMS The onset is usually acute but in some cases it may be more insidious. In the more acute type of case toxæmia and general disturbance may completely override the local signs. There is always a spontaneous intense lumbar pain which is usually severe enough to confine the patient to bed and may leave him helpless and unable to move Spasm of the erector spinæ is present and all movements of the spine are limited and painful. At a later date there is a localized tenderness over the affected area, and where the posterior processes are involved œdema and tenderness of the area may be present, to be followed by abscess formation

In the early stages a blood culture may be positive Pyrexia and leucocytosis are present in varying degrees, but signs of an acute and severe systemic upset may not be prominent An increasing leucocytosis count indicates the progress to abscess formation In all cases of obscure deep-seated pus, pyogenic osteomyelitis of the spine should be considered The progress of the disease is rapidly limited in most cases and in two or three months after the onset an X-ray will show firm bony union

DIAGNOSIS The radiological findings are of great importance but in acute fulminating cases there is probably a fatal outcome before these have had time to develop. It has also to be remembered that in some cases bone focus is minimal so that there may never be evidence When the disease attacks the body it may be a month or two before changes are seen on X-ray examination. There is a marked narrowing of the disc space and a moth-eaten irregularity of the bodies bounding it The affected vertebræ show an increased density with some areas of mottled rarefaction. This is in marked contra-distinction to the decalcification of tubercle At about the same time subperiosteal new bone is formed at the margins of contiguous vertebræ leading to "beaking" This increases in time and eventually the beaks on neighbouring vertebræ fuse The diagnosis rests, therefore, in the early cases, on severe backache, pyrexia and leucocytosis, with possibly rigors in the history There is often a primary focus in the way of boils, etc. The diagnosis may not be complete until a later stage when X-ray changes are evident

The distinction between pyogenic osteomyelitis and tuberculosis presents difficulties and Martin points out that the points shown in the table on page 694 are helpful In doubtful cases it is worth measuring the staphylococcal anti-toxin level of the patient's serum It is often not necessary to estimate the titre more than once and the staphylococcal infection may be diagnosed from the tuberculous lesion on the basis of a much raised blood titre.

backache produced by bending over one's work can be relieved almost immediately by placing a stool under one foot. The elevation of the one foot tends to straighten out the lumbar region, and so relieve the strain

One of the common causes of chronic strain in the lower back is a sagging or protuberant abdomen, which by its weight and its downward and forward pull, tires out the muscles and leads to increased tension on the ligaments supporting the lumbar spine.

The obvious treatment of such a condition is reduction of weight and of the size of the abdomen by dietetic methods combined with active exercises designed to increase the tone and control of the abdominal muscles. Failing this, the strain may to some extent be relieved by supporting the abdomen. In fitting abdominal supports, it should be borne in mind that the strain is not diminished if the belt is of equal width at the back and at the front To be of real benefit, the support should extend well above and well below the lumbar spine

Many cases of chronic back strain are caused by deformities of the feet or the knee The feet, therefore, should be carefully examined and abnormalities such as flat foot or valgoid deformity corrected

5. Low Back Pain referred from Other Regions

Under this heading, Osgood discusses four types of error which may cause backache ·

(*i*) General debility, and mental or physical fatigue

(*ii*) Gynæcological and genito-urinary lesions. At one time the tendency was to look on disorders of the pelvic viscera as supplying the key to all these problems Inflammation of the ovaries and tubes, and displacements of the uterus, were considered the common, if not the sole cause of low back pain in women The perfection of the X-ray apparatus, together with the realization that low back pain is as common in men as in women, has proved how fallacious was the old assumption of the visceral origin of these symptoms.

Renal calculus may give rise to acute lumbar pain without showing the characteristic radiation of renal colic. The writer recently treated such a case of renal stone, accompanied by periodic attacks of backache The main complaint was pain in the back, there was no indication of any abnormality in the urinary tract, in fact, the attacks usually came on after hunting The X-ray examination disclosed a very small stone in the left kidney, the removal of which completely relieved the backache.

(*iii*) *Neurological Lesions—Spinal Cord Tumours* Osgood points out that there is a small, but definite, group of cases where the symptoms are suggestive of an organic lesion, which is liable to be overlooked. Lumbar puncture, in combination with puncture of the cisterna magna, may reveal a complete spinal block, or the fluid obtained may show definite change either in tension or in constitution

narrowing of the disc space, and bulging of the psoas shadow. Blood segmentation rate is increased from 25 to 79 in one hour (Westergreen)

Brucellosis should be considered as a possible etiological factor in chronic spinal lesions. Brucella agglutinations are raised significantly, viz Brucella abortus 1 3840, and Brucella melitensis 1 3960. A blood culture may grow the organism after two to three weeks The organism is sensitive to penicillin, streptomycin, chloramphenicol or aureomycin. Tuberculosis can be excluded by repeatedly negative cultures and guinea-pig inoculations, by the absence of tuberculous changes in the sinus biopsy, and by repeated negative Mantoux tests

Persistent local pain is the main symptom accompanied by local tenderness and muscle spasm.

Treatment should be conservative in the absence of abscess formation Complete rest in bed is beneficial. Abscess formation may be treated by aspiration initially and if necessary later by surgery Antibiotic treatment should be started as early as possible and be prolonged for four to six weeks or, if there are bone complications, for even longer

4. Low Back Pain associated with Static or Postural Errors

Postural errors, assumed either from habit, in the course of some occupation, or from the presence of such abnormalities as weak feet or a protuberant abdomen, form a large proportion of the cases of low backache seen by the orthopædic surgeon Unfortunately, too, they are by far the most difficult conditions he is called upon to treat.

Hunter lays great stress on the two distinct functions of muscle, viz that of postural tone, and that of movement The former, controlled, according to Hunter, by the autonomic nervous system, maintains correct posture without effort or fatigue When it fails, either as a result of some general disease, or of neurasthenia, posture must be preserved by the exercise of the second, or voluntary, function. The muscles require to contract actively to do this, and fatigue and pain speedily result If this conception is correct, it explains practically all the cases of backache which occur in nervous people.

Certain types of individual are peculiarly liable to such postural strains. The slender type, whose posture is bad and who habitually hyperextend the lumbar region, throw a severe strain on the lumbosacral region generally, and on the sacro-iliac joint particularly When the lumbar lordosis is increased, the body-weight is transferred to the sacrum, not through the body of the vertebra but behind that by way of the spinal arch The long, slender type of back is unable to withstand this strain for any length of time, and at least one large industrial company refuses to employ for hard labour any man over 5 feet 10 inches in height, but tries to obtain men of about 5 feet 8 inches high, with a square, stocky back

Postural strain is precipitated by certain occupations. Surgeons and dentists who have to bend over their work for long periods are especially liable It is useful to remember in this connection that the

frequency with which weak feet and varicose veins accompany the neuralgias is regarded as further proof of the presence of physical strain.

The chief symptom is pain, either sudden or gradual in onset. It is gnawing or burning and may be continually present or may occur in paroxysms It is often extremely severe, especially at night. It is worse in any position that causes pressure on the nerve, such as sitting The patient in bed lies on his side with the hip and the knee bent and the ankle plantar flexed. The pain begins in the lumbar region or in the hip joint and tends to spread downwards It may never reach below the knee and is generally worse at the back of the hip and thigh, but it may involve any or all branches of the nerve in its course. Special points of tenderness, known as Vallaix's points, are found on the nerve and its branches : between the ischial tuberosity and the great trochanter, at the centre of the posterior aspect of the thigh, just lateral to the middle of the popliteal space, the middle of the calf, and lastly just behind the medial malleolus.

Lasègue's sign is present in all cases. If the knee is kept in full extension and the foot dorsiflexed, the hip cannot be flexed to any extent without causing great pain, this being brought about by the direct stretching of the nerve

To avoid stretching the nerve, the patient in a severe case walks on the toes of the foot of the affected side with a plantar flexed ankle, the hip and knee being kept flexed The knee jerk may be diminished or absent. Scoliosis is often produced and there may also be paræsthesia or hyperæsthesia Gluteal atrophy is often present, and X-ray frequently reveals arthritic changes.

Diagnosis

In all forms of sciatic pain a full investigation should be carried out. Where a tumour is exerting direct pressure on to the nerve cord, etc , i e. in the spinal canal, a bilateral sciatica may develop This is exceedingly rare in other circumstances. Secondary carcinoma subsequent to a breast or thyroid gland operation has a special predilection for this site and inquiries should always be made with regard to previous operations. Diseased kidneys or prostate gland, ovarian or fibroid tumours, or infected sacro-iliac joints and lumbar spondylitis may not infrequently give rise to a form of sciatica to be diagnosed only by a thorough examination, including rectal and X-ray examinations It is wise also to exclude the lightning pains of tabes and transverse myelitis before embarking on treatment.

Treatment

If any specific cause can be discovered the primary treatment will naturally be directed towards this Palliative treatment, however, in such a case is not to be despised The bowels should be well cleared out, while Pemberton recommends a restricted diet giving a minimal caloric intake from the outset Rest, however, must be the basis of

(*iv*) *Imperfect Mechanical Conditions in the Lower Limbs*, especially faulty posture of the feet. This has been referred to under the static or postural type of backache It is a common contributory, and occasionally a primary, cause of back pain.

6. Low Back Pain from a Combination of Causes

This is probably the most important feature in difficult and persistent cases. Numerous combinations occur, as for example, postural strains in susceptible bodily form, with or without anatomical abnormalities on which fibrositis is so commonly superimposed, or postural and traumatic strains superimposed on a pre-existing arthritis Such a combination of errors demands a combination of methods of treatment.

Summary

The essence of the diagnosis of low back pain lies in a careful history and in a painstaking examination. The decision can be accurate and the treatment intelligent only if we have, in addition, an accurate anatomical knowledge of the part involved Judgement and ability are also necessary in estimating the extent to which static or anatomical factors are responsible for the symptoms

Good X-ray films are the most valuable confirmatory evidence Their interpretation should be undertaken only by one familiar with the clinical picture

Sciatica

Sciatica as expressed in the modern attitude signifies sciatic pain without connoting any particular pathogenesis It is a symptom not a disease Essential sciatica, or sciatic neuralgia, should be differentiated from a sciatic neuritis or a true inflammation of the nerve.

An inflammation of the sciatic nerve may be either primary or secondary Primary sciatic neuritis is due to a generalized toxæmia, as from alcoholism or lead or arsenic poisoning, or it may be the result of systemic disease, such as diabetes or syphilis. The secondary form is likewise a peripheral neuritis, but it is due to pressure on the nerve, usually before it leaves the pelvis, as from a spinal cord tumour that exerts pressure within the canal, or metastatic tumours that press on the root, plexus or trunk. Pelvic tumours may give unilateral pain from pressure on the plexus or nerve.

The reflex neuralgias, however, are of much more frequent occurrence than those two groups combined Before a reflex sciatica can be diagnosed, sciatic neuritis must be excluded Unlike the latter the neurological manifestations in reflex sciatica are normal Sciatica is usually preceded by symptoms of muscular insufficiency in the lumbar and sacro-iliac regions—intermittent ache and tiredness, stiffness and soreness, boring pain over the lumbo-sacral or sacro-iliac joints Muscle spasm in the lumbar area and a protective list may be present. The

capsule under considerable tension—it amounts to 30 pounds in the lumbar region in a supine position, being, naturally, very much higher during spinal movements. The turgor of the disc is dependent on high osmotic pressure of the nucleus pulposus, drawing fluid from the spongiosa of the vertebræ, the nucleus being non-compressible, transmits the pressure against the cartilage plate and annulus fibrosus, the latter with other ligamentous structures of the spine being responsible for the resilience and flexibility of the vertebral column. The diurnal variations in height—a man being taller in the morning up to $\frac{3}{4}$ inch, a woman $\frac{1}{2}$ inch, than in the evening—are mostly due to alterations in water content of the nucleus as the annulus fibrosus is only very slightly elastic.

The nucleus is entirely avascular. Roofe has shown the presence, although he did not trace the origin, of fine unmyelinated nerve fibres in the posterior longitudinal ligaments and in lesser number in the annulus fibrosus The ligamentous and articular structures of the vertebral column have sensory innervation from the nervus sinuvertebralis (von Luschka)—a recurrent branch arising just distally to the ganglion of the posterior nerve root.

Pathology. Intervertebral discs are one of the most "hard-worked" structures in the organism, particularly in the lower lumbar region, and the majority begin to show evidence of senescence in the third decade. The function of the disc may be disturbed principally in a twofold manner—either by alteration of the water content of the nucleus pulposus or "wear and tear" changes in the annulus fibrosus leading to partial or complete extrusion of its interior

The water equilibrium may be destroyed by changes in the cartilage plate with escape of disc material into the spongiosa of the vertebræ with subsequent formation of granulation tissue and vascularization. Desiccation of the nucleus may occur through fissural tears in the annulus fibrosus—degenerative or traumatic Due to these changes, the disc space becomes diminished, bulging of the annulus occurs—in any direction—followed by proliferation of collagenous tissue, and its calcification at the edges of the vertebræ may occur resulting in so-called osteophyte formation If bulging occurs anteriorly or laterally it does not give rise *per se* to any appreciable symptoms

The fibres in the lamellæ of the annulus fibrosus may give way gradually, usually the internal layers first, thus the attenuated annulus may protrude more or less prominently either due to turgor of not entirely degenerated nucleus or simply due to mechanical pressure in weight-bearing position The name protrusion, herniation, prolapse, is generally given to the lesion in which some form of capsule still limits the nucleus pulposus The protrusion may eventually rupture completely and extruded material lies free in the epidural space. This lesion is termed a ruptured disc. Probably in the earlier stages the nucleus is capable of being displaced inwards from

treatment in sciatica as in all other cases of acute inflammation. Local treatment in the form of dry or moist heat is the next indication.

Counter-irritation in the form of tincture of iodine, turpentine, or A.B C liniment, is useful, but if not powerful enough Thermogene wool which has been dampened with either water or ether may be used as a second line of attack, but being very irritant should not be applied for long Electrical treatment is often disappointing. Diathermy sometimes benefits, but often exacerbates the condition. Ionization may be of help in the more acute forms Massage is contra-indicated in the acute stages; later it is valuable, especially if the condition is fibrositic in origin Aspirin takes pride of place, as in all other rheumatic conditions, as an analgesic Amongst substitutes may be mentioned pyramidon, novalgin, phenacetin and veganin In the later stages, iron and arsenic or strychnine is desirable as sciatica wears the patient to a surprising degree. At the same time, and especially in those cases showing muscular insufficiency, graduated exercises are prescribed.

In recent cases secondary to an acute attack of fibrositis a dramatic relief of pain may follow the accurate injection of the fibrositic nodules (see Fibrositis, p. 690)

Although stretching of the nerve is contra-indicated in acute sciatica, old standing cases of neuritis associated with chronic fibrositis frequently benefit from manipulation of the back and thorough stretching of the sciatic nerve under anæsthesia followed by progressive active exercises.

Prolapsed Intervertebral Disc

Anatomy of the Disc. The intervertebral disc consists of three histologically different components the cartilage plate, annulus fibrosus, and nucleus pulposus The cartilage plate is a thin layer of hyaline cartilage adherent to the trabeculæ of cancellous bone of the vertebral body through a thin layer of calcified cartilage at the junction —thus the plate comes into contact with marrow between trabeculæ from which it receives its nutrition The vascular channels are said to be present in cartilage plate extending from marrow but disappear before the third decade The cartilage plate peripherally fades into the annulus fibrosus The latter structure consists of dense fibrous tissue in concentrically arranged lamellæ—the outer attached to the epiphyseal ring by Sharpey's fibres, the inner derived from cartilage plate surrounding and merging into the nucleus pulposus. The nucleus pulposus which lies a little posteriorly to the central axis of the vertebræ, is composed of whitish, glistening, semi-fluid material Microscopically it reveals fine fibrillar structure, with clear stroma, resembling connective tissue, mucin, and fibroblastic, cartilage and notochordal cells The borders of the nucleus are not distinct as they gradually merge into the annulus fibrosus. The nucleus pulposus is enclosed in its fibro-cartilage

white, glistening attenuated annulus fibrosus, with soft elastic summit Less often there is rupture of the capsule with the extruded degenerated material lying in the epidural space embedded in dense fibrous tissue. Occasionally the herniation extends right across the vertebral canal in the form of a firm ridge. An important variety of protrusion which occurs, though infrequently, is the "intermittent herniation" of Falconer, or the "concealed disc" of Dandy. This herniation is not obvious from the position of flexion on the operating table, but the abnormality may be betrayed by softness and thinness of the annulus fibrosus and the bulging can be reproduced by hyper-extension of the spine.

Apart from the type of protrusion, its situation in relation to nerve root, and/or thecal sac is of great importance both clinically and operatively The protrusion may be central, paramedian, or lateral, the commonest site being lateral to the posterior longitudinal ligament which means usually under the nerve root (see Fig 297) and, depending on its size, the root may be compressed backwards and medially (see Fig. 298 *b*) or the protrusion may displace the root laterally and present itself in the angle between the theca and root (see Fig 298 *a*). The medial displacement of the nerve root may be suspected on clinical examination by the presence of a tilt of the trunk away from the affected side; this is most likely a protective mechanism to avoid stretching of the root over the protrusion, but when the root is displaced laterally, the tilt is towards the affected side This paramedian type of protrusion quite often affects two nerve roots, one in its extra dural course, the other intra-durally. The laterally situated herniation may affect two nerve roots, both *extra*-durally.

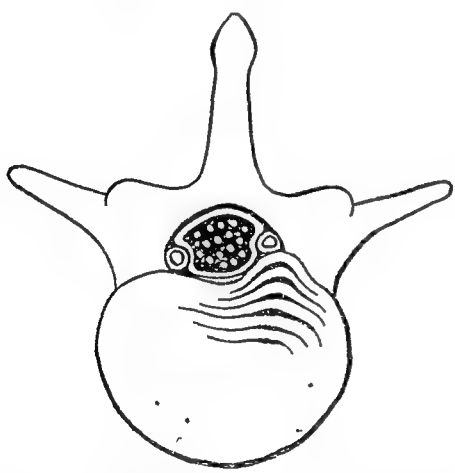

Fig. 297 —Diagrammatic Representation of the Common Type and Site of Disc Protrusion displacing the Nerve Root posteriorly

Clinical Features

(*a*) History. A careful and detailed history is essential in the diagnosis of a protruded intervertebral disc and often it may be our only guide to the localization of the lesion since the other signs may not be conclusive. The dominant feature of the syndrome is pain; the secondary effect of the disturbed mechanism of the intervertebral disc is, *per se*, not evident. The so-called orthopædic signs are as a rule acquired as a protective mechanism against pain, certainly at least in the early phases of the affliction

A typical syndrome consists of low backache followed by referred sciatic pain. This sequence occurs in half of the cases, about a third

a posterior herniation by alteration of the spinal curve or may protrude more, for instance in hyper-extension of the spine.

From these remarks it is evident that the degenerative changes in the discs are physiological at a relatively young age, being chiefly due to strain and stresses of daily life, but do not necessarily lead to appreciable symptoms as every-day experience shows This factor of ordinary stress as well as some hereditary tendency to early senescence of the disc is the predisposing cause of its posterior herniation Apart from the minor repeated trauma, an injury such as a fall, lifting heavy weights, etc , is the precipitating factor in over half of the cases It is possible that only excessively severe trauma may produce acute herniation of a normal disc Penetration of the disc with a lumbar puncture needle has resulted in a herniation in a few reported cases

The disturbance of disc function leads to some derangement of interdependent structures of the spine, e g articular facets and ligaments The secondary changes of strains or arthritis may be the source of some of the backache in disc herniations Males are twice as frequently affected as females The age of incidence is fairly evenly distributed in the three decades between the ages of 20 and 50

Sites Strain and stress being obviously important factors in degenerative change of the disc and its frequent outcome—posterior herniation or rupture—it is natural to find it most commonly in segments of the spine most liable to chronic or acute trauma : lower lumbar and lower cervical spine. Multiple protrusions frequently occur

Mechanism of production of symptoms. The common site for a posterior herniation of a disc is just lateral to the posterior longitudinal ligament , it may start more or less gradually and it is probable that at this stage it may be a source of backache even before there is any demonstrable disturbance of spinal mechanics. With or without undue stress the herniation may enlarge and impinge on a neighbouring nerve root thus producing symptoms and signs similar to any other space-occupying lesion in this area Whatever is the ultimate explanation—irritation of the root due to compression, stretching, friction, occlusion of vasa nervorum, degeneration of nerve fibres, or a combination of any or all of these factors—the result is the same—interference with its function The compressed nerve root becomes œdematous, enlarged, and often adherent to the protrusion. The extruded material from a ruptured disc appears to be more prone to irritate the tissue and set up granulomatous-like reaction The extradural veins become engorged due to obstruction, often having the appearance of extensive varices and undoubtedly add to irritation of the root This state of affairs is almost invariably seen at operation during an acute attack. In the chronic phase of sciatica the root is usually seen embedded and fixed in fibrous tissue and stretched over a protrusion

Types and sites of protrusions. The commonest type of protrusion is fairly well circumscribed bulging of the disc, yellowish or

the nerve root, subsidence of central excitatory state, etc., have been offered as possible causes of retrogression of symptoms.

The pain is usually described as a dull ache, or "like toothache," "dragging," "ache with stabbing jars," "shooting pain," etc. The lower lumbar region is usually indicated as the site of pain and though not well defined, it is generally in the midline. The pain may be referred to the sacro-iliac joint on one or both sides, to the buttock, and further distally to the lower limb. The radiation of pain may descend, gradually affecting the lower levels of the extremity successively—buttock, thigh, etc., or it may be referred to any one part of the leg leaving the proximal parts apparently unaffected. The residual pain distally is a frequent complaint after an acute attack of sciatica. The reverse order of occurrence of sciatic reference—centripetal, is relatively seldom encountered. The pain is referred to the dermatome of the involved nerve root—therefore detailed note of it should be taken. The aggravating factors are as a rule straightening up from a stooping position far more than bending down, lifting weights, coughing, sneezing, straining at defæcation. Amelioration of pain is usually brought about by recumbency, the position of greatest ease varying with each patient

Paræsthesia, most often described as "pins and needles," is present at one time or another in the majority of cases; they fairly often are better localized by the patient, thereby assisting in the identification of the nerve root involved.

Sensation Clinical experience shows that in well over half of the cases with verified protruded intervertebral disc affecting a single nerve root, there is a sensory depression in a given dermatome, most easily demonstrable by testing with the aid of a pin. The loss is rarely complete and not often in the entire dermatome; usually the distal parts —leg and foot—show the greatest depression. Some patients are aware of numbness, subjectively, in others the deficit is found only on objective and careful examination. Loss of other modalities—cold and warmth—although often demonstrable, is technically somewhat cumbersome to apply and the borders of depression are difficult to define

Some degree of wasting in muscle groups innervated chiefly by the affected nerve root is quite frequently observed, but the diminution of motor power is not always demonstrable clinically, especially in the flexor group, since the muscles of the lower limbs are very powerful and minor degrees of weakness are difficult to appreciate The complaint, however, of muscular weakness, is very often heard Occasionally various degrees of drop foot are present. Rarely flaccid paraplegia is encountered

The tendon reflexes—knee or ankle jerks—may be depressed depending on the root and the severity of the compression Occasionally, the ankle jerk may be totally absent but even a slight reduction in the response of the threshold stimulus may be of significance

Sphincteric disturbance—in the form of urinary retention—is found

of patients give a history of sciatica preceding backache; in the remainder both sciatica and backache ensue simultaneously It is debatable how often a herniated disc is the cause of low backache only.

The onset may be acute, following a trauma, e.g a fall in a sitting position, lifting weights in a stooping position, etc. Not infrequently there is a latent period of hours, days or weeks between the trauma and the beginning of pain, and in these cases also the onset may be less sudden —subacute Still further in others, especially in patients subjected to habitual backstrain, the onset may be chronic—patients complaining of intermittent, gradually increasing backache, starting as lumbar "tiredness" or "aching stiffness"

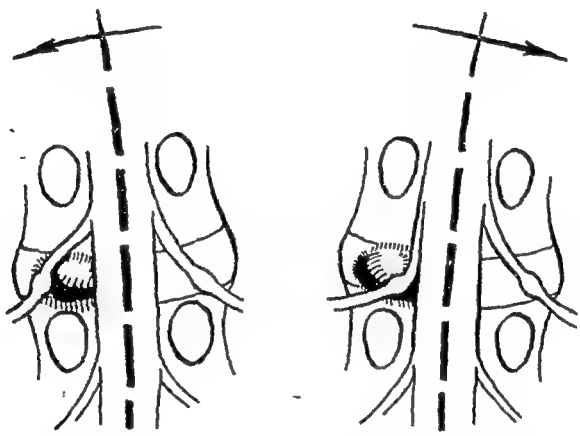

(a) (b)

FIG 298 —Diagram illustrating the Direction of Tilt depending on relation of Nerve Root to Protrusion

(a) nerve root displaced laterally
(b) nerve root displaced medially

A characteristic feature of a disc syndrome is the intermittency (or fluctuation) of symptoms The backache or sciatica comes on in the form of attacks—lasting days or months Even the cases with apparently constant pain, on closer questioning confirm the presence of more or less distinct attacks, as a rule induced by exertion The attacks commence usually fairly rapidly and may incapacitate the victim totally in the course of a few days—the slightest movement in bed may cause excruciating pain; then gradually in a few weeks the pain fades away In some, the first attack may be the most severe one starting a series of perhaps minor but annoying exacerbations, or any subsequent one may become the most acute The remissions may be complete but more often there is either slight ache remaining or a sense of "back awareness." The explanation of spontaneous remissions is not clearly understood. Regression of herniation probably may occur only in the very early stages Degeneration of compressed nerve fibres, adjustment of the nerve root into its displaced situation, diminution of the swelling of the herniation, disappearance of the œdema of

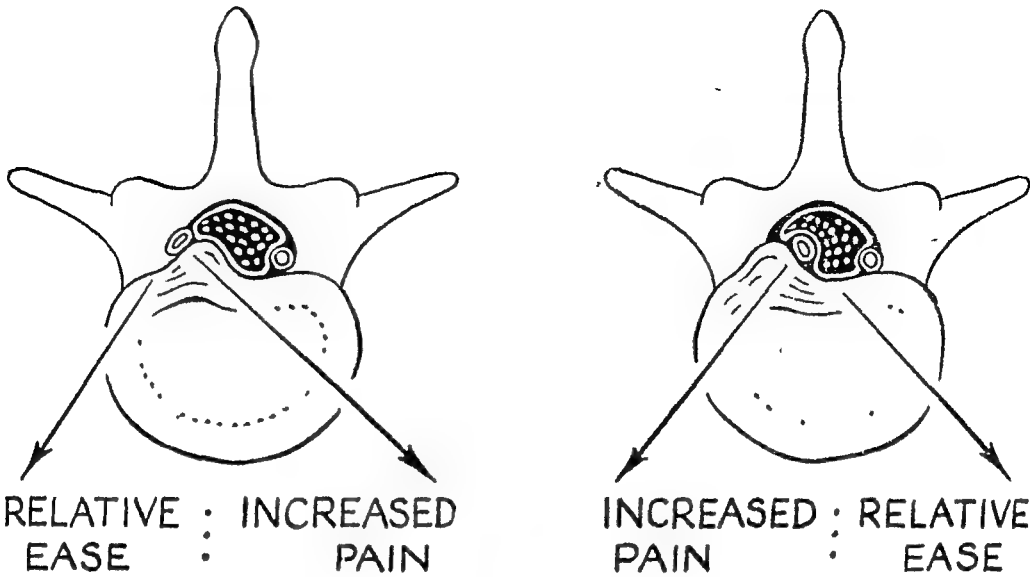

FIG. 299.—Circumduction Test.

Forward flexion of spine (arrows) or circumduction away from the affected side may produce increased pain This suggests lateral displacement of the nerve root Flexion towards affected side does not stretch the root and is a movement of relative ease The reverse results from medial displacement of the root A root stretched over the summit of the protrusion would give pain on flexion straight forwards The more lateral the angle of flexion which causes pain, the more reliably the test indicates sideways displacement of the root.

improves with the patient in a sitting position The pain is the limiting factor of spinal movements, the stiffness found in a sense, is a voluntary effort, and to some extent a "reflex" mechanism. The tenderness of muscles may be a referred phenomenon from the affected root or due to localized muscle spasm brought about by irritation of the root, or any source of irritation, e.g over-activity.

Examination of Spine. The back and lower limbs are examined with the patient completely undressed The spinal curvatures, the presence of a tilt, and the posture, are observed, the range of spinal mobility standing or sitting is estimated. The limitation of forward flexion is probably best measured by the distance of the fingers from the floor on attempts to reach it. Palpation of the spine is then carried out Local tenderness over the interspinous ligament or just laterally to the spinous process over the interspace is found in a great majority of cases and if on pressure with the examiner's thumb over the suspected level, pain is referred to the buttock, thigh, or more distally, a diagnosis of herniated disc may be made with considerable confidence. The sacro-iliac joints and the hip joints should be examined

Lower Limbs. Muscular wasting is observed and the circumference of calves and thighs is measured. Differences, unless more than ½ inch, are probably within the normal limits. Wasting, however, of the foot dorsiflexors may be quite pronounced and of significance, though it will rarely be obvious on measurements

The motor power of the two sides is compared In testing dorsi-

only in cases with paraplegia. In milder degrees of compression there is sometimes a difficulty in initiation of voiding or incomplete emptying of the bladder.

The symptoms due to mechanical derangement of the vertebral column, secondary to a disc lesion, probably play only a small part in the syndrome

The postural deformities of the lumbar spine seen in each case of herniated disc are mostly of a functional, but not organic nature The alteration of the spinal curves, limitation of movement, rigidity (spasm) of spinal muscles are a part of the protective mechanism adopted subconsciously to prevent or ameliorate, or abolish pain This mechanism, if prolonged, by itself may be a source of additional pain, and the altered posture may lead to more permanent changes, yet if the primary cause, herniation, is adequately and early dealt with, these secondary postural abnormalities usually recover completely

The commonest change in the lumbar spine is flattening of the lumbar curve, quite frequently noticeable even in relatively mild cases or during remissions Very rarely there may be an increase of lumbar lordosis.

The tilt of the trunk is very often observed, either towards or away from the affected side. At times it may be present only on bending forwards, in others only in the upright position. In severe attacks some patients may be almost literally "doubled up." The term "tilt" is preferred to scoliosis, as the latter in the lower lumbar region is not always clearly discernible, commonly being missed owing to the presence of a more evident compensatory scoliotic curve higher up in the vertebral column The direction of the tilt of the trunk appears to depend on the relation of the nerve root to the protrusion as mentioned above.

When the tilt is absent or indefinite, the relationship between the nerve root and protrusion may at times be ascertained by a circumduction test Standing firmly, the patient performs half of a circle movement of the trunk in flexion—e g bending to the left side then carrying on circumduction with the spine flexed in the lumbar region forward and then to the right side. Alternatively the patient may do a series of flexions of the trunk—to the left, left and forwards, forward, right and forward, and right side, avoiding rotation of the spine on the vertical axis. If in any particular direction a referred pain may be induced or there is distinct exacerbation of the present sciatic pain in some of the sectors, the test is positive and it is helpful in defining the position of the affected nerve root in relation to the protrusion (see Fig 298)

Some degree of restriction of mobility of the spine is another frequent sign in disc syndrome; indeed, in a recent review 100 per cent. of the protrusions had reduced spinal mobility Limitation of forward flexion is usually complained of, hyperextension of the spine, relatively speaking, may be more affected but this movement is seldom called for and being of limited range, difficult to judge. The flexion of the spine

of L4–5 space, or even it being equal in width to L3–4 disc, can be accurately estimated and it may have a diagnostic value. Recognition of pathological narrowing of the lumbo-sacral disc is less certain and in only about one-third of the cases of herniation at this level are X-rays considered positive. Various developmental errors in the lumbo-sacral skeleton are frequently discovered on routine radiography; some of them, like spina bifida occulta, generally are of no practical importance and have no bearing on the disc syndrome The presence of a transitional vertebra may lead to diagnostic errors of localization and is probably responsible for some "negative" explorations There are relatively frequent variations in the number of lumbar vertebræ. If the number is increased it may be either due to the absence of the twelfth rib or complete lumbarization of the first sacral piece This condition may be misinterpreted or overlooked, as frequently, for economic reasons, one plate is used for the X-ray of the sacrum and lumbar spine, and the latter is not fully shown In cases of lumbarization of sacral vertebra, if overlooked, the exploration will be carried out at a too low level. If six lower vertebræ are present and it is due to the absence of the twelfth rib, the twelfth thoracic vertebra is counted as the first lumbar; consequently, the exploration will be undertaken cephalad to the lesion. Whenever there is any suspicion of an abnormality an X-ray of the entire spinal column should be taken, and the vertebræ counted downwards from the first cervical to settle the issue.

(2) *Myelography* Visualization of disc herniations as a diagnostic method by radio-opaque media—lipiodol, pantopaque, myodil—has many advocates, particularly in America. 3–5 c.c. of the solution is injected slowly into the spinal subarachnoid space followed by X-ray screening on a tilting table. In positive films shadow defects of the lipiodol column in the thecal sac are seen. Deflection or abolition of small subarachnoid pouches at and below the origin of the nerve root are also of diagnostic significance The modern opaque media are said to be innocuous and absorbed almost completely if not wholly in a few years. Nevertheless, it is a foreign body and its removal at operation or by lumbar puncture aspiration is advisable. The method is recommended in disc cases when diagnosis is in doubt especially if differentiation from a tumour of cauda equina is necessary or possibly in some obscure cases of backache Tourney *et al.* have shown that certain cauda equina tumours are clinically indistinguishable from disc lesions. In their series tumours represented 4·3 per cent of all surgically treated low back lesions. Those who do disc surgery without myelography must accept a small but definite risk of missing a tumour It should probably, at any rate, be used in atypical cases and in particular when a neoplasm is suspected It also may be of value in some cases of multiple disc protrusion. It should be stressed, however, that negative myelography does not rule out the presence of disc protrusion and more recent reports indicate up to 25 per cent errors of myelography.

(3) *Cerebro-spinal fluid.* Lumbar puncture, to test the dynamics

flexion of the ankle, minor differences may not be appreciated, so it is worth comparing the strength of dorsiflexion of the toes, where the difference may be more obvious The patient is asked to maintain his weight for a time on either forefoot and definite weakness of plantar flexion on the affected side may then be noticed, or reported.

Tendon reflexes are tested, if necessary with reinforcement. Attention is paid not only to their absence or presence, but also to differences in the threshold stimulus Ankle jerks are most reliably tested with the patient in the knee-hands position and feet overhanging the edge of the couch. Examination for the presence of any pathological reflexes such as clonus, Babinski, Rossolimo, etc , should be made.

Testing for deficient pain perception is, usually, sufficient for our purposes, other modalities being estimated whenever any other neurological condition is suspected Hypalgesia, not analgesia, being far commoner, it should always be explained to the patient that slight " blunting " or " sharpening " of the pin-prick should also be reported It is better to start testing from the suspected area of hypalgesia towards the normal one, and the borders of the depressed area marked Sensory impairment on the sole and outer margin of the foot (first sacral dermatome), with absence of the ankle jerk, points to a lumbo-sacral protrusion, sensory impairment on the dorsum of the foot (fifth lumbar dermatome), without alteration in the ankle jerk, suggests a protrusion of the L4–5 disc , and impaired sensibility extending from the patella along the antero-medial surface of the lower leg, with reduction of the knee jerk, points to a protrusion of one of the upper lumbar discs (L2–3 or L3–4) Elevating the limb and maintaining it for a minute or two at the angle just short of the threshold for increased pain makes the existence of sensory deficit more evident.

The straight leg raising test produces an aggravation of pain or reference to the extremity, due to the stretch of the sciatic nerve The greater the restriction of straight leg raising, the larger the protrusion By the same mechanism dorsiflexion of the foot in this position (Bragard's sign) often causes increase of pain and possibly more distal reference—e g to some of the toes, thus identifying the nerve root involved The test, however, has no differential value as it is merely indicative of lumbo-sacral radiculitis from whatever cause

Additional examination.

(1) *X-ray* Plain films, antero-posterior and lateral views, of the whole lumbar spine and sacrum should be taken routinely The radiograms have chiefly a twofold value—the possibility of the presence of bone pathology, having a bearing on the given case, may be revealed , and secondly they may have disc diagnostic significance The lumbar disc spaces, as is evident in true lateral radiograms, normally show progressive widening in caudal directions, L 2–3 disc space being wider than the one above, etc , except the lumbo-sacral interspace which as a rule is narrower than the higher one Therefore, slight narrowing

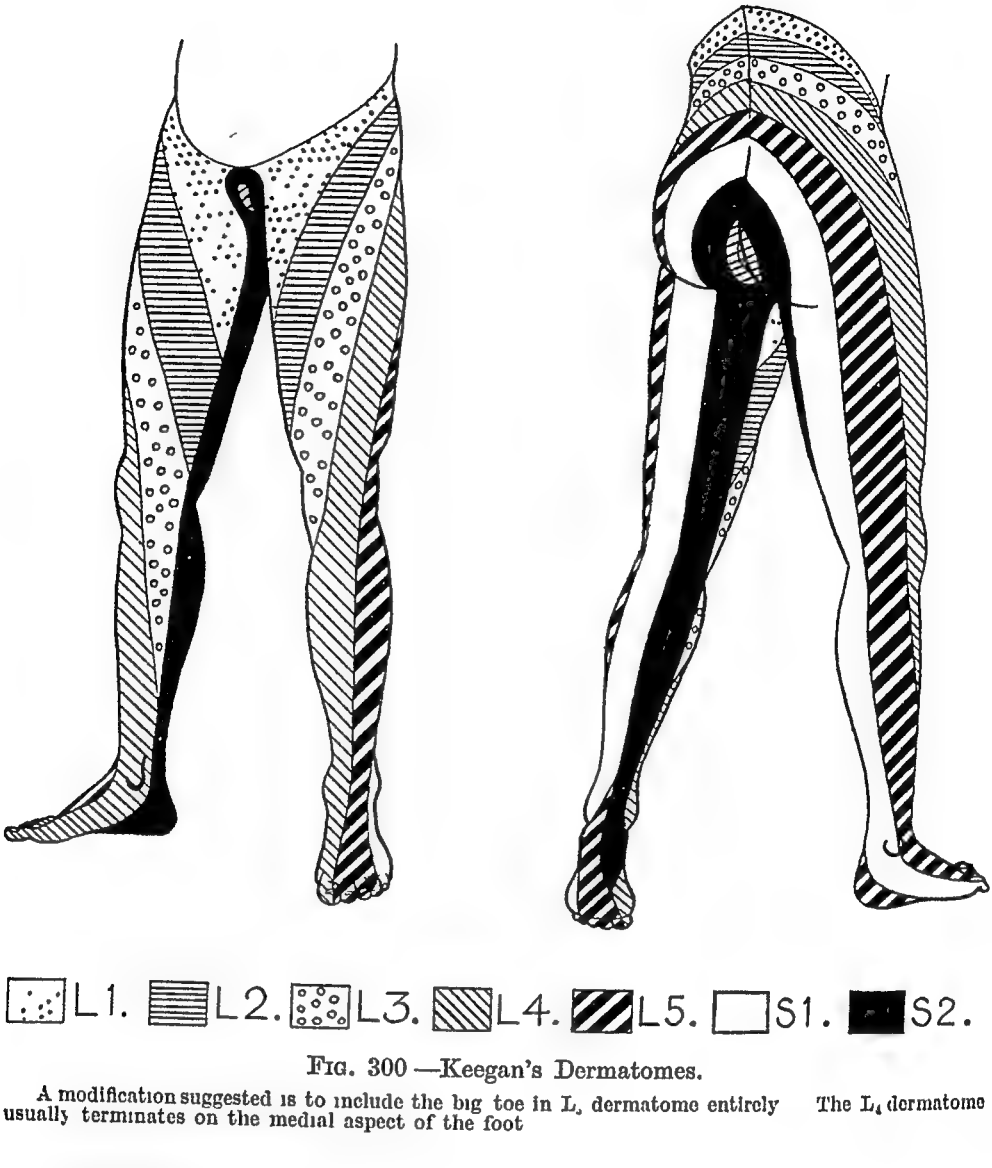

FIG. 300 —Keegan's Dermatomes.

A modification suggested is to include the big toe in L_5 dermatome entirely The L_4 dermatome usually terminates on the medial aspect of the foot

Multiple Protrusions. About half of the cases seen show involvement of more than one nerve root. In these polyradicular unilateral syndromes, differentiation between single protrusion affecting two nerve roots, and two protrusions—one from each disc also involving two nerve roots—is more difficult There are no certain distinguishing points. Generally speaking, a single protrusion simulating multiple herniations shows preponderance of symptoms and signs from one of the nerve roots, and if we manage to deduce its relation to the protrusion (e g. by tilt) it is possible to infer whether the other nerve roots are irritated by the same prolapsed disc or not With multiple unilateral herniations, the objective signs from the compressed roots are apt to be more definite and the course of illness more protracted, though by no means invariably so. Perhaps in some of these cases there is a field for contrast myelography, though once the possibility of multiple

of the C S F as well as its contents, should be performed in all cases with prolapsed disc. Cytology, protein, and serological tests are carried out routinely Cell counts should be normal Total protein content is normal (20–40 mg per cent) in about half of the cases ; in the majority of others it is usually ranging between 40 and 60 mg per cent , though as much as 200 mg. per cent. is found in rare, isolated cases. With these unusually high readings again we should exercise extra caution in diagnosing protrusion of the intervertebral disc. Colloidal gold curve and the Wasserman test should be normal. Only in the rare cases of massive disc herniation giving rise to compression of cauda equina, is partial or complete block found.

Diagnosis

In the great majority of cases with backache and sciatica, or sciatica alone, a herniated disc is by far the commonest cause In cases with low backache alone, the differential diagnosis is more complicated and often quite difficult. A high degree of accuracy of diagnosis may be achieved by detailed history and careful examination—neurological and orthopædic—supplemented by X-ray and C.S F findings, although no sign, *per se*, is pathognomonic for prolapsed intervertebral disc.

Localizing diagnosis. Contrary to the opinion of many writers on the subject, neurological diagnosis of the level of the herniation even without myelography can be highly reliable. Since it is possible in most cases as well as desirable, an attempt should always be made to localize the lesion accurately. The recognition of the level of protrusion usually is not difficult, the greatest assistance being rendered by assessment of which nerve root or roots are affected.

Compression of the fourth lumbar nerve root may result in weakness of the quadriceps muscle, and diminution of knee jerk. The dermatome extends along the antero-lateral aspect of the thigh, front of the knee, medial aspect of the ankle joint, and the medial aspect of the foot, not reaching the great toe (see Fig. 300).

The fifth lumbar nerve root involvement leads to some wasting of the glutei and dorsi-flexors of the foot Inversion and dorsiflexion of foot and toes is weakened Knee and ankle jerks are normal. The fifth lumbar dermatome traverses the lateral aspect of the thigh, antero-lateral aspect of the leg, and dorsum of the foot, and covers the big toe and one or more adjacent toes—never the little toe.

The first sacral root affection shows wasting of the glutei, hamstrings, and calf muscles ; weakness of eversion and plantar flexors of the foot and toes is found. The ankle jerk is reduced or absent. The first sacral dermatome occupies the postero-lateral aspect of the thigh, lateral or postero-lateral aspect of the leg, lateral border of the foot and little toe , two adjacent toes may also be included—never the big toe

Naturally, not all symptoms are necessarily present in every case Furthermore, in polyradicular syndromes, the symptoms or signs referable to one root may differ from that of the other

content of C.S F. settles the diagnosis. Myelography is often necessary for the exact localization.

(2) *Spondylolisthesis.* This interesting condition may closely resemble prolapsed disc syndrome. The sciatic pain may be unilateral or bilateral and is apt to be less affected by postural changes; backache, which not infrequently is a less prominent feature than one would anticipate, is relieved by rest Forward flexion of the spine is often surprisingly good. Major degrees of slipping of the vertebræ are obvious on clinical inspection. X-ray settles the diagnosis. The sciatic symptoms are commonly produced by stretching of the nerve roots over the upper posterior margin of the prominent lower vertebral body. At the level of the actual displacement posteriorly, few remnants of the disc have been seen producing symptoms. Independently herniations of a disc may occur immediately above the level of spondylolisthesis, and be wholly responsible for any symptoms present, the latter being entirely symptomless.

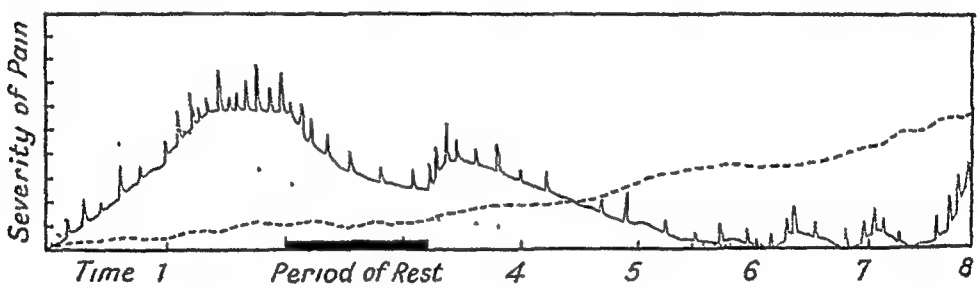

FIG. 301.—Pain Chart

Continuous line—diagrammatic representation of behaviour of pain in an attack of backache and sciatica due to prolapsed intervertebral disc The "spikes" represent the "shooting" pains induced by movements, lifting weights, cough, etc Note the decrease in severity of pain during a period of strict rest Time may be read in terms of days, weeks or even months *Interrupted line*—behaviour of pain in case of a neoplasm Note slowly progressive course and absence of remission on rest Root pains may occur even in early stages but are not mechanically conditioned Time should be read in months *Dotted line*—curve of pain in some inflammatory lesions, e g primary radiculitis Observe rapid onset, and slow disappearance Time can be read in terms of weeks

(3) *Radiculitis (Primary).* Diagnosis of this condition is difficult to make and usually is arrived at by exclusion, since radiculitis is commonly secondary to some other lesion in the vicinity of the roots The etiology of primary radiculitis is unknown but virus infection is generally accepted A history of preceding generalized or local infection may be present. The disease may affect one or several roots of cauda equina, sacral ones being most affected, consequently sphincteric disturbance of the bladder and rectum as a rule is present The disease begins with sudden acute pains in the lower extremities; paræsthesiæ, sensory deficit and increasing muscular weakness soon follow. Unlike the disc syndrome there is distinct tenderness of muscles and rest in bed for a week or two does not appear to have effect on the pain. C.S F. in some cases shows slight lymphocytic pleocytosis There is no history of previous recurrent attacks. Very rarely exploration may be necessary to establish the diagnosis as differentiation from massive disc protrusion or tumour compressing cauda equina is obviously difficult.

lesion is raised, exploration of both or more suspected discs is the best remedy.

Differentiation between single central or occasionally paramedian herniation and bilateral herniations in cases with symptoms and signs referred to both lower limbs, again cannot be very definite, though easier than in unilateral multiple lesions The majority of cases with bilateral protrusions, contrary to expectation, complain of alternating attacks of sciatica—initially the attack may be bilateral with one side predominant symptomatically, followed by attacks referred perhaps repeatedly to one side only, then switching unexpectedly to the opposite side. In these alternating attacks, one side is usually constantly worse If, apart from the history, on examination objective signs are found in both lower extremities, bilateral herniation may be suspected with a fair degree of confidence

Attacks of bilateral sciatica occurring simultaneously are usually due to a single large paramedian protrusion. Usually on one side sciatica is always worse than on the other, even though the pain is referred to both limbs. In others the sciatica affects one side for some time, and only when at its worst the pain may also be referred to the so-far unaffected extremity. Apart from positive straight-leg raising test, objective signs are rarely found on the less complained of side.

The syndrome consisting of alternating and simultaneous attacks of sciatica is present in the midline type of herniation, though sometimes found in the types described in the preceding paragraphs The strictly central type of protrusion is very rarely found as it usually, sooner or later, shows a bias towards either side

Differential Diagnosis

Among many pathological conditions which theoretically could come into differential diagnosis, there are only a few which may resemble closely prolapsed disc syndrome and which from a practical point of view need be considered.

(1) *Tumours of cauda equina*, like ependymoma of filum terminale or conus medullaris, meningioma, or neurinoma, are common in this region The latter is most likely to simulate prolapsed intervertebral disc. Arising from any of the nerve roots, it may attain a very large size before it begins to give rise to other than monoradicular symptoms. Pain may be agonizingly severe especially on coughing or sneezing—the increased pressure of C S.F displacing the tumour distally like a piston with a sudden drag on the nerve root There is no such conditioning of pain on spinal movements as there is in a disc syndrome Sooner or later bilateral and progressively worse symptoms occur. Bladder disturbance may occur early. Paraplegia of flaccid type, with marked muscular wasting, and trophic and sensory changes, supervenes The course is slowly progressive without remissions X-rays may show increase in interpediculate measurements. Manometry and protein

offending disc and question of spinal fusion after removal of the protrusion.

The original method of formal laminectomy and transdural approach was soon modified and an extradural route was generally accepted The laminectomy exposure became less extensive, and this method was then improved by an interlaminar approach with excision of the lig flavum and little, if any, of parts of the adjacent laminæ—the so-called "fenestration" operation. Not all surgeons adopted this technique, some reverted to laminectomy and today many surgeons favour the extensive laminectomy routinely for exposure of disc herniation. It is advocated mainly by those who place little if any reliance on neurological and orthopædic pre-operative localization of the disc protrusion and by extensive exposure wish to avoid missing the lesion Although laminectomy does not really jeopardize the stability of the spine, it is unnecessary to employ the major procedure if the minor interlaminar exposure proves adequate, if need be it may easily be enlarged into hemi-laminectomy

Fig. 302.—Bosworth's Method of Posterior Spinal Grafting

H-shaped graft cut out from iliac crest, about two-thirds of its thickness, is wedged between spinous processes appropriately prepared The L5 spinous process may be removed or inserted into a window in the middle of the graft In spondylolisthesis the L5 lamina is removed Cancellous bone chips from the ilium are packed into the angle (space) between the graft and laminæ

In the early operations only the protruding and compressing part of the disc was removed On theoretical and clinical grounds the inadequacy of this limited procedure was rapidly established The need for clearance of the whole nucleus pulposus is now agreed upon by most surgeons.

Intrathecal division of the sensory nerve root has been practised by some operators together with the removal of the herniation of the disc as an extra security against return of the pain but it is rarely advocated now.

While the operation of removal of the protruded intervertebral disc was solely in the hands of neurosurgeons, the problem of immediate spinal fusion was seldom raised In recent years, some, chiefly orthopædic surgeons in America, being concerned with the mechanical aspects of the spinal column, take for granted that disabilities due to disc removal, if not apparent at once, are to be anticipated sooner or later, and therefore recommend immediate spinal fusion in every case operated on for herniated intervertebral disc

Other conditions, like granulomatous lesions, sacro-iliac strain (p 677), gynæcological or genito-urinary conditions, etc , should not prove difficult to differentiate if sufficient attention is paid to detailed history and careful examination

Treatment

With few exceptions, conservative treatment is recommended initially in all cases of prolapsed intervertebral disc. In a proportion of these cases this may effect a complete and permanent relief

The cardinal point in conservative treatment is rest of the lumbar spine Strict recumbency for a few weeks brings about some measure of relief even in the most acute cases This really can be enforced only under hospital régime. The rest at home in the majority of female cases is seldom complete or simply not feasible due to the domestic duties of an average housewife. Immobilization in a plaster-of-Paris jacket, applied as for a compression fracture of the spine, is frequently recommended, either instead of bed rest or to follow it, depending on the severity of the sciatica A plaster-of-Paris jacket extending from immediately above the pubis to the nipples, after correction of scoliosis (or without it, on the assumption that abnormal curvatures of the spine express optimal position for relief of pain), is applied and is usually followed by prompt alleviation of sciatica. We prefer strict rest in bed to any other conservative method Epidural injections are usually of little value. Whatever method of treatment is employed we would like to emphasize the necessity for adequate, and it may mean heavy, sedation with simple analgesics or morphia if need be, during the acute phase of sciatica Heat is a valuable adjuvant.

Spinal manipulation in cases with prolapsed disc is contra-indicated, and indeed unfortunate results may follow manipulation

Surgical Treatment

(1) *Indications* With the exception of rare cases of paraplegia due to massive herniations compressing cauda equina, which constitute a surgical emergency, surgery of the prolapsed intervertebral disc is essentially a surgery of pain. The severity of pain, its duration and the resulting disability in the economic sense are the chief considerations for surgical intervention. If a trial of conservative treatment fails, after three to six months or so, and the patient is still handicapped in his earning capacity, operation is usually advisable. In some circumstances, e g the patient is unable to afford prolonged conservative measures, or cannot risk repeated interruptions of his work, etc , surgery may be considered even in less severe cases The neurotic type of patient requires, probably, more prompt attention than the average individual in similar circumstances, since surgery in time may prevent complete deterioration of his mental make-up.

(2) *Operations* In surgery of the herniated disc there is no uniformity of opinion regarding exposure, manner of dealing with the

now inserted. The spinous processes and the laminæ adjacent to the suspected space are exposed. Frequently the lower border of the higher lamina, partly overlapping the ligamentum flavum, is nibbled away with a bone rongeur. The ligamentum flavum is then incised longitudinally near the midline. A pledget of wool is inserted underneath it for the protection of the theca and roots, and the excision of the ligamentum flavum is completed. Care should be taken while excising it laterally, as not infrequently the nerve root is displaced right up against it. The small square window usually needs enlargement by nibbling with angled punches, as a rule in an upward (cephalad) direction, since it is preferred to identify the root above the disc, as there is less danger of injury to it, also in order to retract it medially it is necessary to define its lateral border, which can be easily done nearer its commencement from the thecal sac Alternatively, a satisfactory exposure without removal of any bone may sometimes be achieved by division of the interspinous ligament and ligamentum flavum and wide retraction (spreading) of the spinous processes. The enlarging of the "window" laterally, if necessary, should be done carefully to avoid injury to the nerve root and also to avoid damage to the interarticular joint The latter is sometimes inevitable for better exposure but no disability results postoperatively.

The theca and nerve root may be immediately evident on opening of the epidural space, or may be hidden under a layer of epidural fat traversed by numerous veins. These should be coagulated and divided, one by one, and with the fat swept aside The nerve root being fully exposed, vessels coagulated and divided, its position in relation to the protrusion is verified, it is gently mobilized by blunt dissection if adherent to the protrusion, and retracted medially with Love's root retractor. If the protrusion lies medially to the root, and the latter cannot be "slipped" over the summit medially without undue stretching, the protrusion should be partly removed and then the root retracted medially as this is the safest and most convenient position during removal of the disc The acute angle between theca and root contains as a rule a rich network of vessels which bleed easily when disturbed and are difficult to control The protrusion usually is evident as a white or yellowish glistening bulge with the root stretched over it, its abnormal consistency is obvious on pressure with the tip of the forceps—it may be described as that of soft rubber used by draughtsmen, that of a normal disc is like ink rubber used by typists. Having the protrusion exposed and the root safely guarded with the retractor, a circular incision is made with a pointed knife in the capsule of the herniation The extruding material is removed, the opening, if necessary, being enlarged further, and the space is first cleared with alligator-action punches, then with angled narrow dental chisels scraping the annulus fibrosus from inside Particular attention in clearing the space is paid to the opposite posterior "corner" of the disc space and then on the same side under the annulus towards the intervertebral foramen If complete evacuation could not

The objection to spinal fusion, such as prolonged recumbency, economic loss, and "loss" of bed, is claimed to be met by Bosworth's method of a "clothes-pin" type of graft, and plaster-of-Paris jacket, the patient being ambulant two to three weeks after operation. This method is recommended also by Barr, Steindler, and others (see Fig. 302)

Bosworth's **H** graft is certainly a useful method for fusing this area of the spine. A graft is cut from the superficial cortex of the posterior part of the ilium and so notched at either end that it may receive the spinous process above and below. The area to be fused is stripped of its cortical bone and the intervening two spinous processes cut flush with the lamina The graft is inserted with the patient in flexion and the spinous processes separated The lumbar spine is then put in extension and this grips and fixes the graft, and at the same time produces a certain amount of distraction, enlarging by this means the intervertebral foramina. The fusion is further reinforced with separate iliac strips The rigidity of fixation resulting from the method of implantation of the main graft has held the iliac strips placed underneath in excellent contact with the posterior elements of the vertebræ

It appears advisable to reserve spinal grafting for unrelieved, persistent cases with backache following removal of the herniated disc Recurrence of the protrusion on the same or different level should, however, first be excluded before fusion is considered Hyndman, Love, and others, do not think that routine bone grafting is justified in their experience up to the present Falconer abandoned grafting his alternate cases after removal of disc herniations.

(3) *Operative technique* The importance of good lighting—preferably head-lamp, suction and diathermy—cannot be over-emphasized —they are indispensable To the usual instrumentarium, alligator-action rongeur (E N T), punch rongeurs, and angled narrow chisels (dental) should be added.

General anæsthetic cyclopropane, nitrous oxide, etc , is used supplemented by local novocaine infiltration.

In the cases with fixed spinal deformity, manipulation is carried out under the anæsthetic immediately before the commencement of the operation.

The patient is placed in a face-down position on the operating table with the spine moderately flexed by the aid of a bridge or pillows. The weight should be taken by the iliac spines as compression of the abdomen, apart from its interference with respiration, tends to produce an engorgement of the epidural veins

A midline incision, centred over the affected interspace, is used A length of 8–10 cm is usually adequate, but with practice it may be reduced even to 4 cm., though it is better to err on a too long incision than on a too short one The lumbo-dorsal fascia is divided in the midline and the muscles are separated with diathermy close to the bone on one or both sides. Self-retaining curved (Mollison's) retractors are

is the rule On the fifth day exercises in bed are commenced and the patient is allowed up on the tenth day, though many surgeons advocate two to three weeks in bed before allowing ambulation. Stitches are removed on the tenth and twelfth days.

Rehabilitation by physiotherapy and occupational therapy is an important part of treatment, and should be controlled by experienced physiotherapists under hospital conditions. Graded exercises of the spinal muscles and lower limbs, etc , should restore the patient's confidence as well as his spinal mobility. Male patients are usually discharged in seven to eight weeks , females in five to six weeks ; ability to touch the floor with the fingers on forward flexion of the spine being one of the " passing " tests In some cases the convalescence is more protracted, and the relief from pain is a slow process. These are the cases with the persistent marked postural deformities due to prolonged disability prior to operation Even though the primary cause has been removed, the weak muscles perpetuate bad posture, faulty posture causes pain, spasm and so on. If the pain is still acute, longer rest in bed is necessary, and thereafter energetic physiotherapy should be insisted upon. In some cases infiltration of tender muscles with a weak novocaine solution may hasten the progress.

Patients returning to a sedentary type of work may be allowed to do so in six weeks ; those in more active types of work, in three months Patients whose work involves heavy back strain should be employed at a light type of work for at least six months from the date of operation prior to the return to their normal employment

(5) *Complications.* Wound infection very occasionally occurs and as a rule is superficial.

Very rarely, a C S F leaking from the nick in the dura may find its way into the subcutaneous tissues. Aspiration should be carried out followed by a compression bandage. Repeated aspiration, with rigid aseptic precautions, will cure the condition.

Occasionally weakness such as drop foot may be accentuated by surgical interference. The weakness is as a rule temporary, though it may take months to recover A drop foot appliance should be recommended

Results

Mortality. The mortality risk associated with the operation of herniated intervertebral disc is low compared with other similar major surgical procedures Deaths reported are usually attributable to complications inherent in any surgery, the commonest cause being anæsthetic complications The percentage is estimated at 0 25 or less.

Operation results and prognosis. The surgical treatment of backache and sciatica due to protruded intervertebral disc fulfils its purpose—the abolition or relief of pain—in the vast majority of cases. The more recently published statistics contain cures, although sometimes markedly below the early enthusiastic reports, and are sufficiently high

be accomplished by unilateral approach, there should be no hesitation to expose the disc from the opposite side in a similar manner and the clearing of the interior of the disc completed Hæmostasis must be very carefully attended to, as a hæmatoma in the epidural space is probably one of the causes of poorer results Before closure of the wound, a résumé of the findings and whether they are compatible with the clinical picture, should be made. If in doubt the next space should be explored. The muscles may or may not be approximated with a stitch or two The lumbo-dorsal fascia is securely stitched to the interspinous ligament, and its opposite side by interrupted silk stitches (No 3) The skin is closed in two layers of interrupted silk stitches Elastoplast dressing is applied.

If the herniation is not evident on opening the epidural space, the level of exposure should again be verified and the consistency of the disc tested. Mobility of the nerve root should be gently ascertained—with a little experience it is possible to tell if it is free or fixed by a herniation outside the exposed area. A bent wire probe is passed along the root into the intervertebral foramen and diameters of its lumen ascertained, a probe or Gravil-McDonald's dissector is passed under the theca medially in search of a central or paramedian protrusion. A search should also be made over the vertebral bodies adjacent to the disc, as sometimes the nucleus pulposus may "dissect" upwards under the capsule, or a loose fragment of ruptured disc may become displaced. In the latter case, an opening in the annulus fibrosus is found only in recent ruptures

Hyperextension of the spine may reveal the intermittent protrusion of a disc (Falconer) If no herniation is found, the next space should be opened either by making a separate interlaminar opening, or extending the already made exposure by removing the remaining bridge of lamina and so converting it into a hemi-laminectomy exposure. If the search is entirely negative, the dura (especially if the C S F findings were abnormal) may be opened longitudinally on its dorso-lateral aspect exposed by the hemi-laminectomy and the cauda equina roots inspected. If normal, a soft catheter may be passed upwards to the level of the conus in search of obstruction

The accidental opening of the theca during operation should be closed with a stitch, taking care not to include a floating root of the cauda equina in the stitch Partial cut of the nerve root also should be repaired by a stitch or two approximating the dural coverings. Undue stretching of the root during retraction ought to be particularly avoided Profuse hæmorrhage may be controlled by gentle pressure of wool-packs, lowering of the bridge, tilt of the table, small muscle graft ("muscle stamp"), or, best of all, fibrin foam

(4) *Post-operative management.* The patient is nursed lying on his side, and the position is changed 4-hourly For the first day or two the majority require catheterization of the bladder due to operative interference with the nerve roots, but restoration of normal function

O'Connel (1951) published the results of operation in 443 patients, most of whom had had their operation three years or more previously. 46 per cent. had no symptoms referable to the disc lesion. 77·6 per cent. had no lower limb pain and 60 per cent no backache The subjective results stated that 60 7 per cent. were cured and 31 6 per cent. greatly improved. 92·8 per cent had full capacity for work. Dott found that of the cases on the waiting-list for operation, in 10 per cent. the decision to undergo operation is altered after about three months or so of waiting for admission, though some of these eventually do come for operation Of cases with milder symptoms, in whom operation was not considered primarily, about 50 per cent. return within a year demanding surgical treatment. It should be added that Dott's cases are already "selected" by general practitioners.

Even though surgical treatment of chronic backache and sciatica is not ideal, nevertheless, if undertaken in appropriately selected cases, it is the best available. It should be remembered that operative treatment of a disc syndrome is essentially a surgery of pain The opinion of patients who have experienced both conservative and surgical treatment matters most in the end—the vast majority are immensely grateful for complete or even partial relief brought about by surgery.

Kümmel's Disease

This condition was described by Kummel in 1921 as a definite entity characterized by a crumbling collapse of a vertebral body following on injury. It is now generally believed to be the result of an unrecognized fracture. It is probable that a poor lateral X-ray does not show the fissured fractures that are present and so, being unrecognized, the fracture is untreated and the superincumbent body weight causes a collapse of the vertebra It is suggested, therefore, that when an accident produces pain of a persistent nature in the back more than one lateral view should be insisted upon.

Vertebra Plana

This condition of the vertebral body was first described by Calvé in 1924 when he showed two cases at the meeting of the British Orthopædic Association It was considered to be of the nature of Perthes disease of the hip and a very definite entity although by no means common

It is usually diagnosed at first as a tuberculous lesion. The condition is usually in the dorsal region and occurs at an early age. Calvé's original two cases were in children of 2½ and 7 years of age. The onset is insidious, though there may be a history of slight injury. There may be pain, local or referred, occurring spontaneously or only during exercise A small gibbus may be present and local tenderness may be elicited by percussion over the affected region. Spinal rigidity is usually present in the early stages and night cries may be present Apart from a possible negative tuberculous reaction the clinical picture may well be

—60 per cent on an average—to show the value of the operation As a rule sciatic pain is abolished or improved in a much greater proportion of cases than is the backache When the improvement in the severity of symptoms brought about by an operation is taken into account, about 80 per cent or more cases show benefit derived from surgery. A relatively reliable criterion of successful surgery is the percentage of patients returning to previous occupation unrestrictedly Dott, in the first group of 500 cases, with at least three years follow-up, found that 85 per cent were able for equivalent work and the same hobbies as before the illness Residual disabilities in the remaining 15 per cent of cases necessitated some modification of employment

The factors responsible for existence of the group of "not improved" cases, and even the group "improved, but not cured," is worth mentioning as some, being avoidable, may increase the percentage of "cures" The recurrence of protruded intervertebral disc on the same level, reported by various authors as being from 2 to 5 per cent. and commonly due to inadequate disc clearance, is responsible for some of the poor results Persistence of symptoms after removal of herniation is often due to a missed protrusion in cases of multiple prolapsed discs. A fresh protrusion arising on a different level after removal of the first lesion sometimes occurs Faults in operative technique, like excessive retraction of the nerve roots, inadequate hæmostasis, etc , may lead to undesirable sequelæ of the operation Disturbed mechanics of the spinal column due to narrowing of the disc space may be the cause of residual backache in some cases This factor is probably not so important as one would infer on theoretical grounds—no abolition of lumbar pain after disc removal could occur which is contrary to experience in a high proportion of cases . furthermore, the percentage of complete cures is only modestly raised (if at all) when removal of the disc is followed by spinal fusion Perpetuation of symptoms post-operatively is not infrequently encountered among industrial workers—the motive being a compensation claim There is yet another group of incompletely relieved patients in whom the cause of surgical failure still remains obscure

Whenever there is persistence of symptoms after operation, one should not hesitate to follow Falconer's advice of readier recourse to re-exploration Myelography in these circumstances may be very useful.

The problem of conservative versus surgical treatment of persistent disc syndrome is settled in favour of the latter according to surgeons engaged in disc surgery, but, according to the majority of others, is unsolved. Cases of protruded intervertebral discs were (and are) frequently diagnosed as lumbago, fibrositis, spondylitis, etc , and the "life" history of the disability as an entity, treated conservatively, has not been studied on the same scale and with the same thoroughness as have been the post-operative results Consequently, statistical reports are very scanty and not strictly comparable.

of vertebral rotation is present in all cases of structural scoliosis Structural scoliosis implies that irreversible changes have taken place in the vertebræ and adjacent soft tissues. In view of the combination of lateral deviation with rotation, rotatory lateral curvature is a definition which describes the essential features.

In adolescence there is a form of scoliosis called postural or functional scoliosis, in which no vertebral rotation may be present. Such cases are not common and when they are encountered do not give rise to any anxiety as they invariably recover without treatment or with simple postural corrective measures.

Structural scoliosis assumes varying characteristics according to the age at onset, the situation in the spinal column and the aetiology Some cases are relatively benign in their course, whereas others are vicious, progressing to extreme deformity Until comparatively recently treatment has been unrewarding. This is explained by the lack of understanding of the different curve patterns and their prognoses as well as the almost inevitable relapse following conservative treatment and late deterioration even after spinal fusion

Etiology

Scoliosis may be a manifestation of many well-recognized pathological conditions, and yet knowledge about the cause is extremely scanty One can understand the appearance of scoliosis in a case of congenital hemivertebræ and also the development of postural scoliosis compensatory to a short limb, but it is not possible to go much further All that can be said beyond this at present is that scoliosis may develop in cases of muscle imbalance be it of myopathic, neuropathic or idiopathic origin. Anterior poliomyelitis and certain central nervous system disorders may be the obvious etiological factors, but in the largest group—idiopathic scoliosis—it has been impossible to establish any direct relationship between muscle abnormality and curvature of the spinal column The view that many cases of idiopathic scoliosis are due to sub-clinical or mild attacks of anterior poliomyelitis has never been proved The fact that idiopathic scoliosis is more common in girls and also the recognition of certain characteristic patterns of curve make it unlikely that poliomyelitis is a causal factor Discussion of etiology, therefore, resolves itself to consideration of the many predisposing conditions which have been well classified by John Cobb (1938)

(1) *Postural*
(2) *Structural*
  (a) *Myopathic*
    Muscular dystropies
  (b) *Neuropathic*
    Poliomyelitis
    Neuro-fibromatosis
    Syringomyelia

that of an early spinal caries. The progress is, however, uncomplicated by abscess formation or paraplegia and no gross deformity ever occurs. The prognosis is good

In recent years a new conception of the condition has arisen and whereas at first it was thought that the lesion affected only one vertebra, and that usually a dorsal one, cases have now been published where several vertebræ, including those in the cervical and lumbar region, have been affected. In 1954 Compere *et al* advanced the concept that this so-called Calvé's disease was due to eosinophilic granuloma of the vertebral body. Four cases were then presented with characteristic vertebral changes in each of which the diagnosis of eosinophilic granuloma had been proved by biopsy Since then other cases have been described.

Fig 303 —Calvé's Disease of the Third Lumbar Vertebra (Dr Fawcitt's case)

On X-ray examination the body of the vertebra is reduced to a thin disc of increased density, very like a Kohler's disease of the tarsal scaphoid. In one case published six vertebræ were affected, each of them collapsed uniformly to a thin lamella. There were in addition osteolytic lesions in the pelvis and femora The picture of the biopsy was typical of the cholesterol histiocytes.

In coming to a diagnosis it is obvious that the limb bones and other parts of the spine and the pelvis should be X-rayed Dale points out that it is not to be confused with what he calls lamellar tuberculosis, where two flattened and fused tuberculous bodies may simulate Calvé's disease. This fusion is easily recognized by the presence of two neural arches attached posteriorly to the fused mass

Treatment is by radiation therapy. In the early stages immobilization in a plaster shell may be wise , later supporting braces or calipers are fitted where necessary Regeneration occurs to a considerable degree although the vertebral body never resumes its normal size or shape

Scoliosis

by Douglas Savill

Scoliosis is a lateral curvature of the spinal column The deviation may be situated in the cervical, thoracic or lumbar regions and frequently is found at the junction areas producing cervico-thoracic and thoraco-lumbar curvatures. In addition to lateral deviation a marked degree

remain fairly mobile, even after long-standing deformity. The rigidity of the primary curve enables its identification. If the patient is asked to bend forward, the fixed rotation of the primary curve is easily seen. Sometimes two primary curves exist in the same patient, usually thoracic and lumbar combination. Fixed rotation of each in forward flexion permits recognition

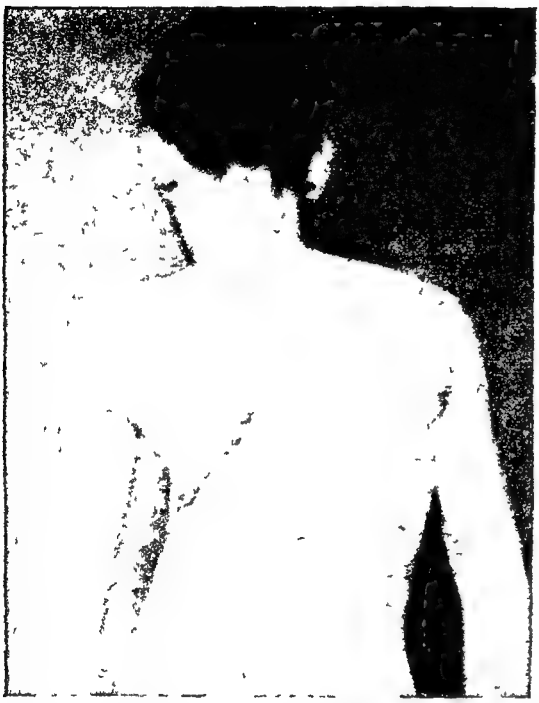

Fig 306.—Scoliosis Lateral Curvature produced by an old empyema scar.

Fig 307.—Functional Scoliosis A total C-curve to the left

Postural Scoliosis. Postural scoliosis, also referred to as functional scoliosis, is one that can be corrected voluntarily by the patient or can be assumed by the normal spine. It occurs characteristically in adolescent girls and is generally believed to be an expression of weak musculature It may, therefore, be associated with other postural defects such as round shoulders, prominent abdomen and pronated feet. Most cases of postural scoliosis are convex to the left and involve the whole of the dorsal and lumbar spine. Viewed from behind, the curve has been likened to the capital letter C and is, therefore, sometimes called a C curve Other clinical features are a raised left shoulder and a prominent right hip. Postural scoliosis may be secondary to a short leg. In such cases, if limb equalization is not carried out or if equality is not restored by raising the shoe, structural changes may develop in the lower lumbar vertebræ There is no evidence that untreated postural scoliosis of adolescence will result in the development of structural change

Postural scoliosis can be effectively dealt with in the Physiotherapy Department. Causes of ill-health should be investigated and treated.

(c) *Osteopathic*
Congenital vertebral anomalies
Thoragenic following empyema and thoracoplasty
Bone dystrophies.
(d) *Idiopathic*

TERMINOLOGY

The curvature in scoliosis is described as right or left according to the side of its convexity It is further named according to the anatomical region involved A curve with convexity to the right in the thoracic region is called a right thoracic curve A curve to the left

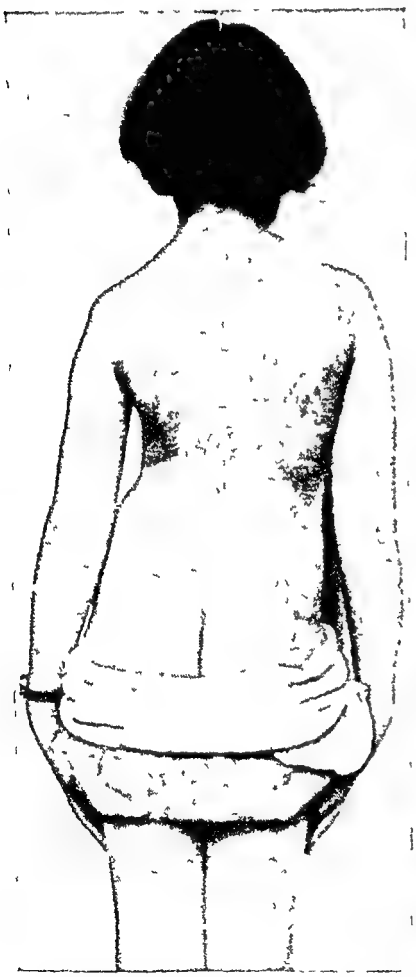

FIG 304 —Scoliosis A mild degree following Poliomyelitis

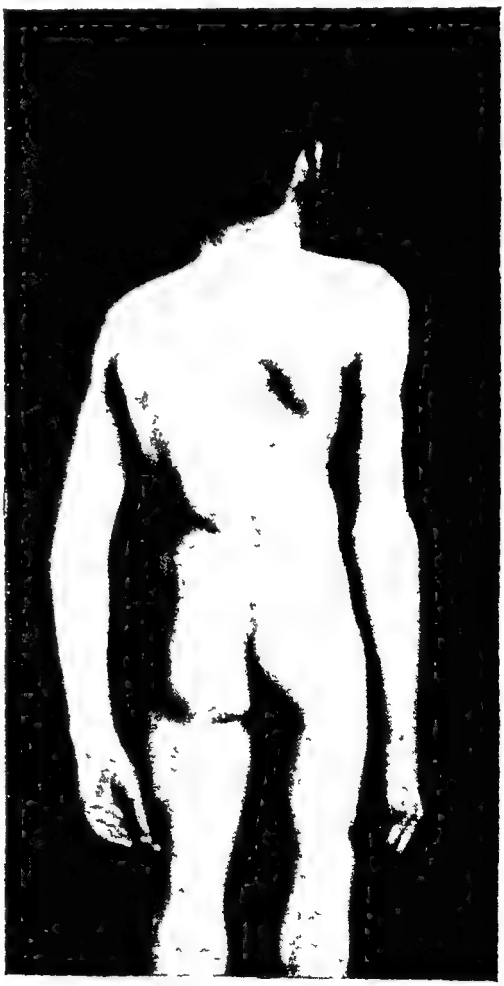

FIG 305 —Scoliosis A severe degree of the deformity following Poliomyelitis

at the juncture of the thoracic with the lumbar spine is called a left thoraco-lumbar curve, and so on If the spine is to remain in balance a curve must be compensated by two curves to the other side, one above and one below the primary curve The main or primary curve is always the most rigid curve The compensatory curves usually

usually able to attend school, and their physical development is nearly equal to that of a normal child

Advice is usually sought because of some outstanding feature, such as a high shoulder, high hip, prominent shoulder-blades or a sunken waistline Often the dressmaker is the first to notice some inequality of the hips: occasionally the observant parent notices the spinal curvature and seeks advice for that reason In all cases the deformity is usually well established before treatment is sought

Older children may complain of pain, but this is rare under the age of 10 It usually takes the form of a mild backache, which is increased on exertion. After the child has started to work he often complains of great exhaustion at the end of the day.

In severe cases, when the chest has become greatly deformed and sunk towards the pelvis, severe pain may arise from the pressure of the lower ribs against the iliac crests. Occasionally, too, referred or root pains are experienced in the limbs, chest or abdomen. In these cases the pressure on the nerve roots results from the distortions of the intervertebral foramina. Painful symptoms of this nature are more commonly encountered in the paralytic forms of scoliosis.

If the abdominal organs have been crowded down by the ribs, symptoms referable to gastro-intestinal disturbances may arise and, if the chest capacity is much reduced, there may be dyspnœa and tachycardia, especially on exertion.

Although many of the patients are able to go through life with little or no trouble, it can generally be predicted that a curve of moderate severity will become progressively more troublesome in later adult life As senile changes develop in the intervertebral discs the scoliosis angle increases, and osteo-arthritic changes may develop in the posterior articulations As already mentioned, this is more likely to occur in lumbar curvatures

Investigation of Case of Structural Scoliosis

It is generally agreed that approximately 90 per cent of cases of scoliosis are of the idiopathic type. The next largest group is encountered in anterior poliomyelitis Most of what follows deals with idiopathic structural scoliosis Towards the end reference will be made to the particular problems presented by the paralytic curve of anterior poliomyelitis Examination of the patient should always follow a standard routine.

(1) Clinical Examination.

(*a*) (i) Adequate exposure of the patient Preferably the child should be examined completely naked The maximum clothing should consist of a triangle

(ii) Note the general state of development Look for evidence of ill-health, such as cyanosis, breathlessness, etc.

(iii) Observe the natural standing position

Structural Scoliosis. The development of scoliosis in a growing spine must necessarily result in changes in the shape of the vertebræ. In the thoracic spine the rib cage shares in the deformity. The vertebral bodies become compressed on one side, the degree of deformity depending upon the position in the curve The vertebra at the apex of the curve, that is, the central vertebra, is always the most deformed The vertebral canal becomes triangular in shape due to the misshapen pedicles and articular processes

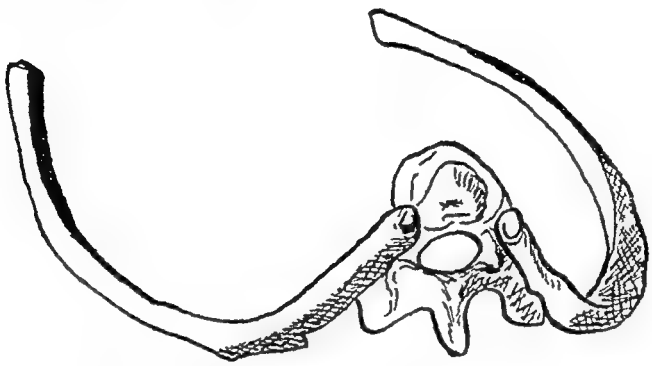

Fig. 308 —Scoliosis The chest deformity.

The vertebral bodies always rotate towards the convexity of the curve

Thoracic curvatures differ from those that occur in the lumbar spine. *In the thoracic spine* the articular facets lie on a circle the centre of which is within or just in front of the intervertebral disc. It is a circle of small radius, and this accounts for the free rotation normally present in the dorsal spine It probably also explains the extreme degree of rotation that is present in cases of primary thoracic scoliosis. The articulating ribs undergo secondary changes. On the concave side they are rotated forward, producing prominence of the chest, while on the convex side they turn backward, producing a posterior rib hump, which in extreme degrees of rotation is aptly described as a "razor back." Eventually the ribs on the convex side may lie hard up against the sides of the vertebral bodies. *In the lumbar spine* the articular facets lie on a circle whose centre is posterior to the facets This circle is of greater radius than that of the dorsal spine. As a result normal rotation in the lumbar spine is of small range Excessive rotation in lumbar scoliosis can only take place by subluxation of one vertebra on the next, associated with subluxation and moulding of the articular processes This is possibly the explanation for pain, which not uncommonly is associated with lumbar scoliosis. Patients with dorsal scoliosis seldom complain of pain.

General Symptoms

Unless there is some co-existing condition, patients with scoliosis are of good colour, feel well, and suffer little inconvenience. They are

Fig. 311.

Fig. 312.

Fig 313.

Fig 311.—Scoliosis Congenital abnormality of lower thoracic spine. Fig 312 —Scoliosis. Congenital abnormality of the cervical vertebræ.
Fig 313 —Scoliosis An advanced degree of adolescent scoliosis

(iv) Look for signs of asymmetry, i e raised shoulder, position of scapulæ, tilting of the head, prominent hip, position of lumbar creases, position of popliteal creases

(*b*) Estimate degree of curvature by marking the skin over the spinous processes with a blue pencil. With the normal patient standing erect there should be no deviation of the spinous processes from the mid-line

(*c*) Estimate the balance of the spine The shoulders should be square over the pelvis, which should be square over the feet A plumb line dropped from the seventh cervical spinous process should pass through the natal cleft If this line deviates away from the natal cleft the spine is out of balance, and the primary curve is uncompensated

(*d*) Estimate the degree of rotation Look down on the shoulder girdle from above for signs of chest asymmetry. Ask the patient to bend forward and look for a thoracic hump or prominence of the lumbar transverse processes on one side

(*e*) Estimate spinal flexibility First observe active movements when walking Ask the patient to flex the spine to one side and then the other Finally have the patient lifted by the armpits and note the effect of superincumbent weight on the curve

(*f*) Clinical photograph. Every case seen for the first time should be photographed This should be done in a proper photographic department Standard views are taken from in front and from behind The prints are stored in the case records and are available for future comparison.

(2) X-ray Examination.

The most valuable information in a case of scoliosis is obtained from the X-ray plates

(*a*) The Major or Primary Curve Clinically the primary curve is demonstrated by fixed rotation on forward flexion. On the radiographs it is usually the largest curve, and its immobility can be shown by taking

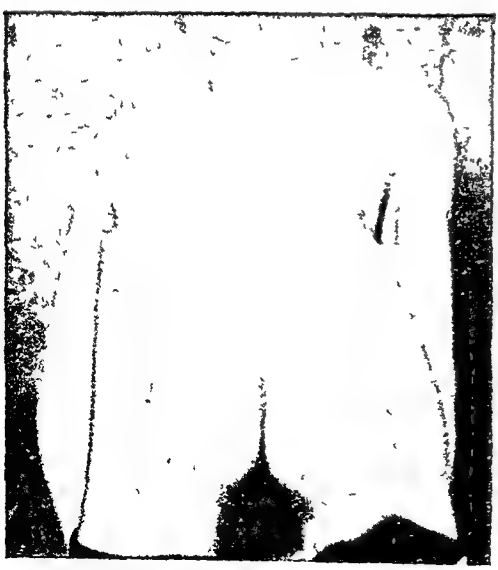

FIG 309 —Scoliosis Severe degree of "razor back" Note Fixed rotation on forward flexion

FIG 310 —Scoliosis Mild degree of "razor back" Note Fixed rotation on forward flexion

of intersection formed by these perpendiculars is the angle of the curve The topmost vertebra is identified because the disc below it is of greater depth on the convex side or deeper on the concave side of the primary curve. The lowermost vertebra is identified similarly but in reverse. The value of the compensatory curves above and below can be estimated in the same way The addition of the proximal and distal compensatory curve angles should equal the angle of the primary curve if the spine is in balance. Measurements are only of value when the X-ray plate is taken with the patient in the erect position.

Tilt Film Before proceeding with reduction of a primary curve prior to fixation by bone grafting it is advisable to estimate the flexibility of the primary and secondary curves. Most cases of idiopathic scoliosis, even of severe degree, remain in balance with the sum of the compensatory curve angles equalling the primary angle It is possible to correct the primary curve through an angle that the rigidity of the secondary curves cannot compensate If that is done, a patient may end up with an off-balance spine after a year or more of trying and exacting hospital treatment. The flexibility of all three curves can be estimated by taking antero-posterior plates of the spine with a 2-inch block under the foot on the side of the primary curve and then on the concave side. The patient stretches as erect as possible during the procedure, and measurements of the curves will demonstrate the degree of correction that is possible by voluntary muscle power against gravity. From this we can work out the amount of correction of the primary curve that is permissible In practice the danger of over-correction has probably been exaggerated If some degree of over-correction is obtained in a corrective plaster jacket, it is usually lost post-operatively because the full degree of initial reduction of the curve is never maintained However, it is a point to be borne in mind by those who are responsible for the highly specialized treatment of children suffering from scoliosis

Prognosis in Idiopathic Scoliosis treated Conservatively

Ponseti and Friedman gave a valuable contribution to our knowledge when in 1950 they grouped their cases of idiopathic scoliosis according to the situation of the curves They were able to identify certain characteristic curve patterns and to determine the prognosis for each They found that most of the characteristics of the curves are present from the onset of the deformity and do not change throughout its entire course apart from the occasional addition of one or two vertebræ to the curve in the later stages In recent years James has carried out an exhaustive investigation into idiopathic scoliosis He has confirmed much of what Ponseti and Friedman have said and has also drawn attention to certain curve patterns, some of which are of good and others of bad prognosis. It is largely on the work of Ponseti and Friedman and of James that the modern approach to treatment has been established It must, however, be borne in mind that the etiology of this form of scoliosis is not understood Until we understand the cause it is unlikely that we can do much more than identify a curve pattern and take the appropriate steps to prevent deterioration.

antero-posterior plates in lateral flexion to left and right. The exact extent and situation of the curve is noted

(*b*) The Extent and Mobility of the Secondary or Compensatory Curves · The radiographs should always be taken with the patient standing to show the effect of the weight of the trunk on the curve, and the patient should be carefully positioned with the transverse axis of the body parallel to the cassette Furthermore, the largest X-ray plates should be used, and every exposure should show the first piece of the sacrum and the iliac crests to enable an accurate estimation of spinal balance to be made.

(3) Measurement of Curves.

Accurate estimation of the degree of curvature can be made from the X-ray plates Measurements at regular intervals, usually every three months, will demonstrate the effect of conservative treatment and the degree of viciousness of the curve

Methods of Measurement

(i) Ferguson The value of the primary curve is the angle formed by the intersection of lines drawn through the centre points of the apical and of each end vertebra

(ii) Lippmann-Cobb This is the method most commonly employed. On the antero-posterior radiograph of the spine a line is drawn along the upper surface of the topmost vertebra of the curve, and a similar line is drawn along the lower surface of the lowermost vertebra of the same curve These lines are extended allowing perpendiculars to be dropped from the upper and raised from the lower The angle

FIG 314 —Measurement of Angle of Primary Curve Lippman-Cobb Method The angle of the curve makes it unnecessary to drop perpendiculars

(3) *Thoracic Curve.*

(*a*) Incidence:
22 per cent of all idiopathic curves (Ponseti and Friedman).

(*b*) Sex
62 females 25 males (Ponseti and Friedman).

(*c*) Site
Apex at eighth or ninth thoracic vertebra (Ponseti and Friedman).
Apex at sixth to 10th thoracic vertebra (James)

(*d*) Side
Ponseti and Friedman found the curves to be predominantly right sided
James found the curve to be right sided in 90 per cent. of adolescents

(*e*) Age at Onset:
James has made a particular study of this curve and has subdivided his cases into three groups

(i) Infantile.	Onset under age of 3 years	52
(ii) Juvenile	Onset from 5 to 8 years	16
(iii) Adolescent	Onset from 10 until end of growth	66

In the Infantile group boys predominated, and most curves were to the left side The prognosis was found to be bad. By the age of 10 every child had a curve measuring 70 degrees or more James decided that there are few orthopædic conditions able to produce so hideous a deformity as this pattern of scoliosis

In the Juvenile group the prognosis is also bad. Of 16 cases 9 had to be corrected and fused, and three were inoperable.

In the Adolescent group 59 per cent. of curves are of severe degree Out of 66 cases James operated upon 19.

(4) *Combined Thoracic and Lumbar Curves.*

(*a*) Incidence:
37 per cent of all idiopathic curves according to Ponseti and Friedman

(*b*) Sex
135 females 11 males (Ponseti and Friedman)

(*c*) Site
Apices at seventh or eighth thoracic and second lumbar vertebræ.

(*d*) Side:
Mainly right thoracic and left lumbar combinations.

(*e*) Age at onset and final stabilization
Average age at onset—12 years 4 months
Average age at stabilization—15 years 5 months (Ponseti and Friedman)

The prognosis on the whole is good Both curves usually balance each other so that the cosmetic effect need not be bad The trunk is considerably shortened. It has been found that the earlier the age of onset the worse the prognosis

The following is a summary of the characteristics of the main curve patterns as described by Ponseti and Friedman and by James ·

(1) *Main Lumbar Curve.*

(*a*) Incidence
According to Ponseti and Friedman this contributes 23 6 per cent. of all idiopathic curves

(*b*) Sex ·
80 females 13 males (Ponseti and Friedman).
70 females 9 males (James).

(*c*) Site .
Apex of curve at first or second lumbar vertebra. Occasionally at third lumbar vertebra

(*d*) Side ·
70 per cent convex to left (Ponseti and Friedman)
Proportion about equal (James).

(*e*) Age at onset and final stabilization :
Average age at onset—13 years 4 months.
Average age at stabilization—14 years 10 months (Ponseti and Friedman).
James found that the age at onset is equally scattered from 10 until the end of growth.

The lumbar curve is the most benign of all types of idiopathic curve. The degree of curvature remains small, no ribs are involved in the rotation, and the shoulders remain level. From a cosmetic point of view it is an innocent curve, but in later life it may give rise to backache, probably due to osteo-arthritic degeneration in the posterior intervertebral joints.

(2) *Dorso-Lumbar Curve*

(*a*) Incidence .
Ponseti and Friedman found that this curve comprises 16 per cent. of all idiopathic curves.

(*b*) Sex
49 females 14 males (Ponseti and Friedman).
20 females 6 males (James)

(*c*) Site ·
Apex of curve at eleventh or twelfth thoracic vertebra according to Ponseti, Friedman and James

(*d*) Side
Mostly right curves (Ponseti and Friedman).

(*e*) Age at onset and final stabilization ·
Average age at onset 14 years.
Average age at stabilization 16 years (Ponseti and Friedman).

Dorso-lumbar curves are not very deforming. The prognosis is worse than in lumbar idiopathic scoliosis but not as bad as in thoracic idiopathic scoliosis Out of 26 cases James found it necessary to correct and fuse only two

Treatment of Structural Scoliosis

The objects of treatment are:

(1) To obtain full correction of the curve. This is seldom, if ever, achieved.

(2) To prevent deterioration by conservative measures.

(3) To correct and fuse the severe curve.

As a result of the work of Ponseti and Friedman and of James we are now in a position to give a working prognosis in scoliosis, based upon the curve pattern and the age at onset. The curve of bad prognosis can be fused before extreme deformity has taken place It is essential to carry out complete clinical and radiological examinations at three-monthly intervals during periods of active growth to determine the rate at which deterioration is taking place A table of curve measurements at regular intervals is of the greatest value in arriving at a decision regarding surgical intervention.

Conservative Measures of Treatment.

There are three lines of attack:

(1) Postural Exercises.

(2) Recumbency.

(3) Relief of pressure by supporting apparatus.

(1) *Postural Exercises* It is doubtful if postural exercises even if long continued have any effect whatever on the primary curve No form of conservative treatment will stop a vicious curve from deteriorating, but that does not imply that remedial exercises are of no value Unilateral or asymmetrical exercises used to be the fashion, it being hoped that by them the weak muscles on the convex side of the curve could be developed. These have been abandoned in favour of bilateral exercises, the object of which is to establish the best posture under the circumstances and also to maintain as much mobility in the spine as possible. Some say that no attempt should be made to mobilize the primary curve and that it should be allowed to stabilize Postural exercises should be prescribed for all scoliotic cases, whether they be infants, juveniles or adolescents

(2) *Recumbency:* During active periods of growth there is a tendency for an idiopathic curve to deteriorate rapidly. With regular examination which includes radiography, it should be possible to discover this before gross deformity has taken place. Superincumbent body weight exerts a powerful deforming influence on the primary curve of a rapidly growing spine John Cobb is of opinion that bed rest is the only satisfactory conservative measure in these cases, and he is prepared to keep his patients horizontal for twenty-three hours a day for several years if necessary Such a strict regime may be essential in a child who is too young for spinal fusion, that is, below the age of 12 Corrective beds can be usefully employed. They are designed to open the curve

(5) *Cervico-Thoracic Curves*

Ponseti and Friedman found five cases in all The apex was at the third thoracic vertebra, and four to six vertebræ were included in the curve Deformity consists of an elevated shoulder at the convexity of the curve

Treatment of Functional or Postural Scoliosis

As the essential cause of postural scoliosis is faulty posture treatment should be directed to the removal of any possible cause. In this respect the effect of improperly adjusted clothing which pulls unevenly on the shoulders, of improper school furniture, or habits such as the carrying of books on one side, of long periods of reading in bad attitudes, and of physical defects such as poor vision or dull hearing must all be carefully considered and their effects minimized.

If the child is pale and weak, mental and physical fatigue are avoided, and an adequate amount of fresh air and sleep insisted upon. Treatment should be directed to both mind and body. Psychological treatment should be indirect, and the less said about the curve to the patient the better

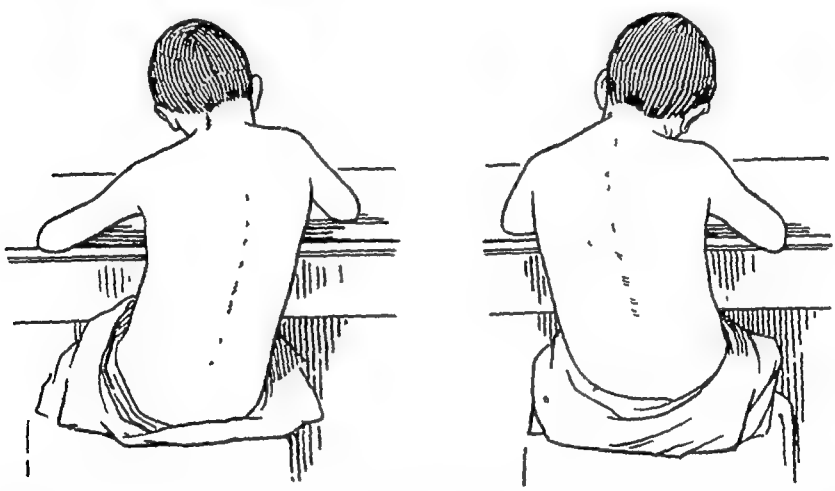

Fig 315.—The effect of a lazy attitude in the acquisition of a Postural Scoliosis

The corrective part of the treatment consists in the employment of gymnastic exercises which will develop the muscles of the body. The aim of the exercises is to improve the general tone and resistance of the patient by increasing the tone and strength of the muscles. They should give confidence and improve the bodily poise, and it is essential that they should be enjoyable Particular attention is paid to the re-education of those special muscle groups which hold the body erect and in its normal symmetrical attitude The type, vigour and duration of the exercises are regulated according to the patient's ability to complete them without fatigue They should be carried out from three to six times a week for periods varying from half an hour to one and a half hours In certain cases, in addition to active muscular contraction, passive stretching may be carried out to augment the flexibility of the spine.

on the concave side and by releasing pressure to encourage growth. They are of particular value in cases of infantile idiopathic scoliosis

(3) *Supporting Apparatus.* Many ingenious spinal supports have been devised in the past to prevent deterioration in the scoliotic spine. In practice, however, they have proved to be ineffective. The curves deteriorate in spite of them, and they have been largely discarded. Occasionally a plaster or celluloid jacket may be effective in controlling a long paralytic curve, but they are quite useless in cases of idiopathic scoliosis. Most surgeons who have to treat scoliosis are agreed that the only support of undoubted value in controlling an idiopathic curve is the Milwaukee brace designed by Blount and Schmidt It is effective because it relieves superincumbent body weight from the primary curve. A plaster case is made of the pelvis, and to the positive is moulded a leather pelvic girdle. Extensible bars pass upwards to chin and occiput supports. The object is to combine distraction with lateral pressure on the convex side of the curve through a hump pad. Many surgeons have simplified the brace, discarding the hump pad and turnbuckle There is good evidence that the brace well fitted to the pelvis and adjustable in length can control a deteriorating curve. The distraction should be of such a degree that the patient can lift the chin or occiput from the support individually but not at the same time A good splint maker can fit a child of only 5 years. It is an effective substitute for long recumbency in a deteriorating curve and is of value when weight bearing is resumed after spinal fusion.

Operative Treatment.

The indications for operation are:

(1) A rapidly increasing curve, with curve pattern of poor prognosis
(2) Spinal instability (uncompensated curve)
(3) Pain.

Except in severe cases of anterior poliomyelitis, with gross curvature, fusion for pain is seldom necessary before adult life, when fixation of a painful lumbar curve may be indicated

Fusion for spinal instability is usually only necessary in cases of anterior poliomyelitis.

It has been said that 5 per cent. of idiopathic curves eventually require correction and fusion, whereas over 30 per cent of curves due to anterior poliomyelitis come to operation In idiopathic scoliosis correction and fusion are mainly carried out for thoracic and thoraco-lumbar curves It is unwise to allow a curve in these areas to progress beyond 90 degrees but a curve of considerably lesser degree should be fused if the curve pattern is bad and rapid deterioration is occurring Many more idiopathic curves are now being fused early in the light of a working prognosis The figure of 5 per cent can probably be more than doubled Risser has shown that the iliac apophysis usually gains attachment to the posterior part of the ilium when vertical growth

Figs 316 and 317 —The Corrective Influence on the Primary Curve of a Milwaukee brace

is removed from the articulations, and the laminæ and spinous processes are thoroughly decorticated Adjacent surfaces of the transverse processes may be similarly treated A large quantity of cancellous bone from the bone bank is packed along the rawed surfaces In extensive curves the patient may not be able to stand a full bilateral fusion. In such circumstances the concave side should be grafted first, followed by the convex side four weeks later.

Another method in the extensive case is to do the upper half first and then the lower half but the upper half is grafted 2 inches further down on one side and at the second operation the grafting is continued for the 2 inches on the opposite side. Such a method prevents a weak area which might fail to unite or fuse.

Fig 319.—Left Dorsal Scoliosis prior to Correction

Post-operative Care

Fusion is usually quite solid in four to six months from the time of operation It is the practice of the writer to explore the grafted area at four to five months The muscles strip easily, and the operation can be completed in ten minutes Any weak areas can be given supplementary cancellous grafts Once satisfied that fusion is complete the patient is taken out of plaster and allowed freedom in the horizontal position As a soundly fused spine may show signs of deterioration following return to the erect position the writer fits every patient with a Milwaukee brace, which is worn for a year though removed at bed time. There is no doubt that post-operative relapse of the curve is much less common when this precaution is taken

of the spine comes to an end. This is a useful observation in arriving at a prognosis

Correction is carried out using the Risser turnbuckle plaster A well-padded plaster is applied to the recumbent patient The thigh on the convex side of the curve is included in the plaster, and the shoulder and upper arm on the concave side In high thoracic curves correction is difficult, and the head has to be included in the plaster Some days later, when the plaster is dry, it is transected horizontally at the level of the apical vertebra of the primary curve Hinges in front and behind are then incorporated over the hump eccentrically so as to allow a degree of distraction when the turnbuckle is brought into use The turnbuckle

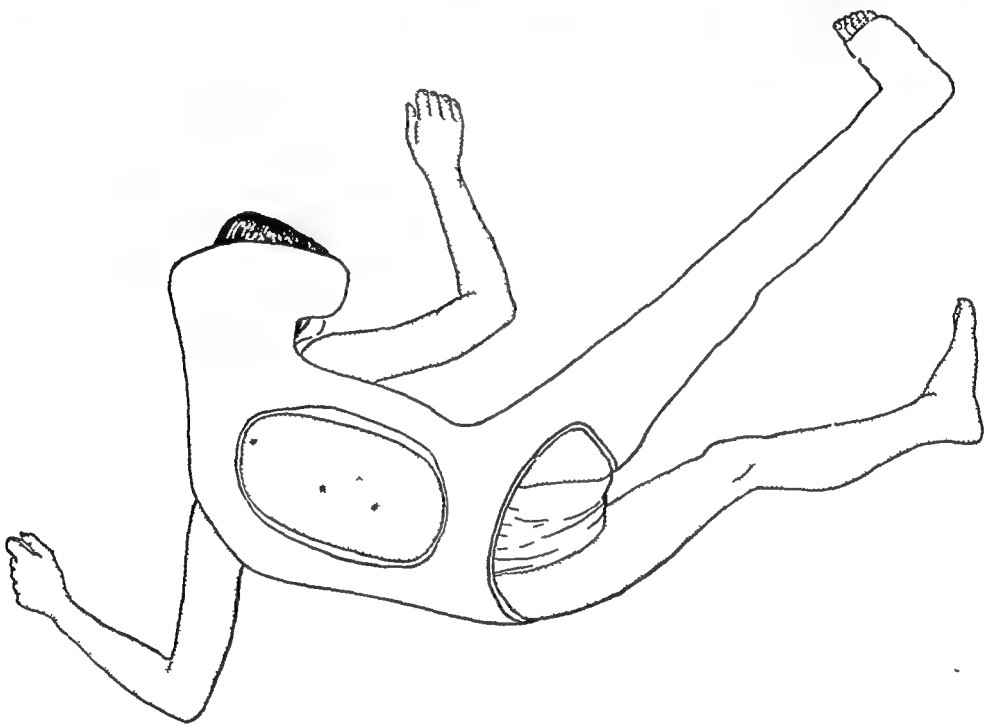

Fig 318 —The Plaster Casing with the opening for performance of Fusion Operation

is fitted to the plaster on the concave side of the curve One complete turn of the turnbuckle is carried out daily until the desired correction is obtained, as determined by radiographic examination Watch must be kept for traction lesions of the brachial plexus and also for pressure sores Considerable experience is required in the application of the plaster if the patient is to remain comfortable and free from complications. Once the corrective phase is completed the gap between the two segments of the plaster is filled in with plaster, and the hinges and turnbuckle can be removed Operation is carried out through a window in the plaster permitting access to the whole of the primary curve.

Operation

The spinous processes, laminæ and posterior articulations are cleared of soft tissues along the whole length of the primary curve. Cartilage

Wedge Resection Roaf claims that the rational surgical approach is to excise a wedge of bone from the apex of the curve The convex side of the curve is approached by resecting the medial 3 inches of two ribs, taking care not to damage the intercostal nerves. The pedicles and laminæ of the vertebræ corresponding to the resected ribs are removed, exposing the dura and the vertebral bodies. The intervertebral disc is removed, and using a small gouge and nibbling forceps adjacent wedges are taken from the vertebral bodies. Finally a plaster jacket is applied incorporating the arm and leg on the concave side of the curve When the plaster is dry it is wedged open by stages until maximum correction is obtained This procedure is in the experimental stage It is a major undertaking and should not be performed by other than one very experienced in spinal surgery. Pseudo-arthrosis sometimes follows fusion, but this does not necessarily result in any serious increase of the curve. The pseudo-arthrosis may only be of hair-line magnitude, and it is difficult to credit that such a defect could have any serious significance Absorption of graft affecting a wider area can be discovered at the exploratory operation at four or five months. Late pseudo-arthrosis occurs sometimes. It is much more common when grafting is performed using large cortical strips of bone Cancellous grafting is now universally performed.

Control by Epiphyseal Stapling. Theoretically stapling of the convex side of the curve by slowing growth should have a favourable effect on a case of scoliosis. Curves have been induced in experimental dogs by Nachlas and Borden, but the method has not been applied to the correction of scoliosis in human subjects.

Excision of Hemivertebra. This has been carried out in cases of congenital scoliosis, but serious post-operative complications have developed

Internal Jack Method of Correction. Allan has designed a jack made of inert metal which he places across the concavity of the curve The ends of the limbs are inserted between the transverse processes of the vertebræ at the top and bottom of the major curve. The limbs are corrected with a threaded sleeve, the stems having right- and left-hand threads permitting extension with a tommy bar. The sleeve is turned slowly with short pauses over a period of fifteen to twenty minutes until the resistance to further turning suggests that the limit of safe correction has been reached. The curve is then grafted in the usual way. No form of external fixation is necessary after operation This method has the advantages of shortening the duration of treatment and allowing correction of high thoracic curves, but there is the disadvantage that it is not applicable to curves other than of very severe degree.

Rib Resection Occasionally this may be indicated for cosmetic reasons when a severe hump is present It should not be done if the rotated vertebral bodies are closely applied to the rib cage If the costal margins cause pain by impingement on the iliac crests, resection of the involved ribs may be advisable.

Fig 320 —Eighteen months after fusion of the Primary Curve following reduction in a Risser Jacket

Fig 321 —Five years after Fusion The same case as Figs 319 and 320 Demonstrates maintenance of correction Milwaukee brace worn for one year after return to ambulation

discs, normal spinal curvature depends to some extent on the long spinal muscles and on the ligaments binding the individual bony segments together

Alterations in the normal antero-posterior curvatures of the spinal column are frequently met with in the young and the old, and many erroneous ideas as to their mechanism and cause have sprung up. In general it may be said that deformed antero-posterior posture of the spine must follow interference in one of the factors producing the normal curves, viz.:

1. *The bones*—this form is seen in tuberculosis, rickets, Kummel's disease, etc.
2. *The discs.*
3. *The long spinal muscles*—the type commonly seen in debilitated children with flabby muscles.

The Importance of the Intervertebral Discs.

The importance of the discs is not merely academic Schmorl has clearly established the fact that they have a profound significance in spinal disease, and indeed the realization of their importance has provided us with a new conception of spinal pathology. The German workers have shown that the discs are liable to many abnormalities, and while a full consideration of these is beyond the scope of this work certain features may be noted.

The spine is unique in function and in structure; as Beadle says, it, more than any other part of the skeleton, is exposed to the daily wear and tear of functional activity, and this functional trauma, never in abeyance, can continue to work the most far-reaching damage to its structure.

The main incidence of such trauma is undoubtedly borne by the intervertebral discs, which thus reflect, like the arterial walls, the age and tone of the body tissues With increasing age the nuclei pulposi lose their elasticity and fluidity, and the annular fibres their definition These changes are very marked in those whose occupations involve strong bodily work, but they may be observed to a greater or less extent in all ageing spines. While changes in the fibrous portion of the disc are undoubtedly important, any alteration in the cartilaginous plates is fraught with even greater significance, since these plates are responsible for the maintenance of the integrity of the discs. If they are intact, the disc may perform its work with a fair degree of efficiency, even though its substance has undergone considerable degeneration.

The Pathology of the Discs.

1. Developmental and Degenerative Changes. The common changes in the cartilage range from localized bulgings towards the spongy tissue of the vertebral body, to complete collapse and rupture. In old spines such changes are the result of senile degeneration of

Scoliosis due to Anterior Poliomyelitis.

Scoliosis is a common complication of anterior poliomyelitis It may develop early before the patient has been allowed up, but it may appear several years after the acute attack, emphasizing the importance of an adequate after-care service. The situation of the curve and its severity depends upon the location of the paralysed muscles and their degree of weakness James has shown that paralytic scoliosis is due to intercostal, erector spinæ and abdominal muscle weakness or paralysis and is not related to involvement of the limbs Once started, the curve tends to progress rapidly, and gross deformity may result. It differs from the idiopathic curve in four ways

(1) It is more rapidly progressive.
(2) More vertebræ are involved in the primary curve.
(3) It more often results in an unbalanced spine.
(4) It is more mobile and more easily correctible

Very severe deformities may occur in extensive muscle involvement Cervico-thoracic curves are accompanied by dropping of the head to the shoulder level, the neck disappears and the appearance of the child is very distressing. The whole spinal column may be involved, and the patient is unable to sit up. Extensive bone grafting may be necessary in such cases if only to permit sitting When the lower limbs are involved in the paralysis the decision to carry out a lumbar fusion must be carefully made. The quadratus lumborum may be the muscle in producing pelvic lift and ambulation. If it is sacrificed by lumbar fusion the patient may not be able to walk at all.

Antero-posterior Curvature of the Spine

(including Adolescent Round Back, Senile Kyphosis, Spondylitis Deformans)

The fœtal vertebral column possesses two *primary curves*, both convex dorsally The upper of these extends from the head to the pelvis, the lower affects the sacral region.

After birth two *secondary curves* develop. As soon as the child begins to hold the head erect a cervical curve appears, its concavity directed backwards, and on the assumption of the erect attitude a lumbar curve appears which is also concave backwards. The object of these secondary curves is to bring the centre of gravity directly above the stance of the body.

The primary curvatures are dependent on the shape of the vertebral bodies; the secondary curves, on the other hand, are the result of the special shapes of the intervertebral discs, which are wider in front than posteriorly in the cervical and lumbar regions It is interesting to note that if the intervertebral discs are removed, the spine tends to resume its fœtal or infantile form—an effect commonly seen in "senile round back"

In addition to the shapes of the bodies and of the intervertebral

the mechanical shocks transmitted from segment to segment of the spine during arduous work are no longer absorbed or distributed evenly over the surface of the vertebral bodies, for they now impinge on the almost bare and unprotected bone. In this way serious changes arise and permanent deformity becomes established.

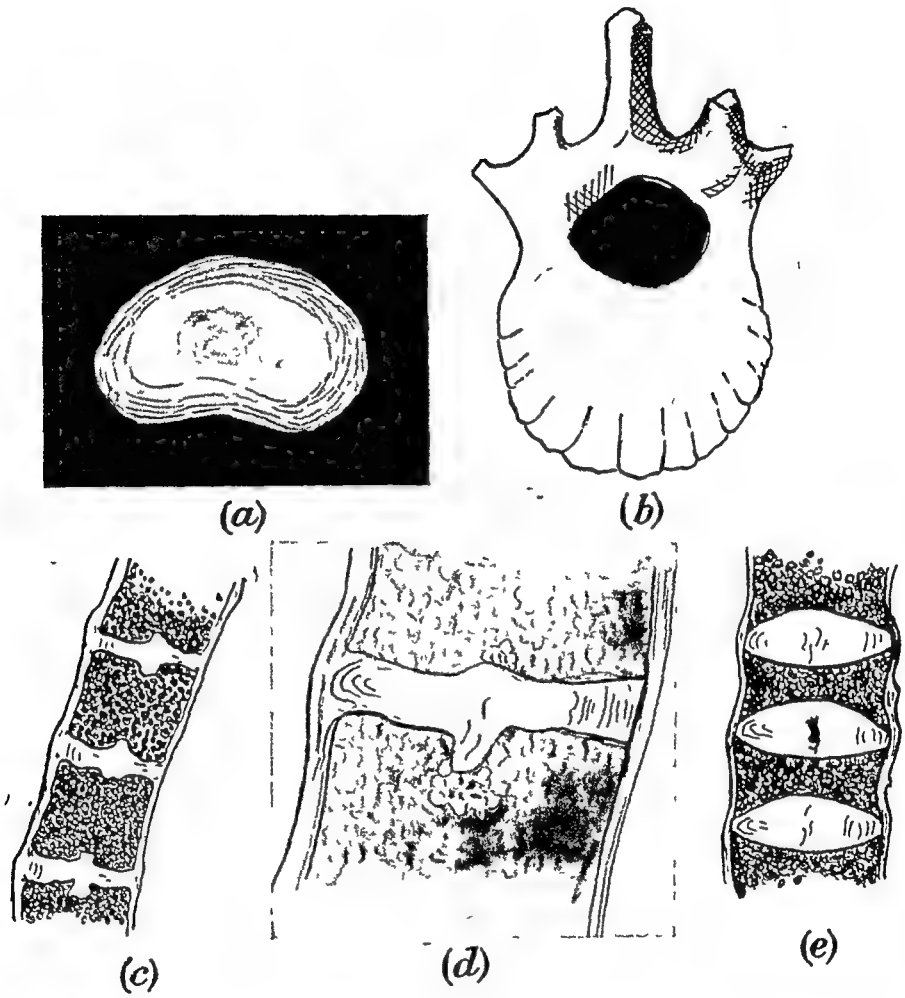

FIG. 322

(a) Section of an intervertebral disc, showing the central nucleus and the laminated annulus
(b) Surface of a vertebra showing clearly the furrow formation
(c) Section of a spine, showing series of nuclear expansions
(d) Typical nuclear prolapse The branching nodule consists of cartilage
(e) Osteoporosis of the vertebral bodies The inherent turgor of the discs has caused a certain amount of collapse, making the vertebræ not unlike those of a fish

Kyphosis in Adolescence

(Juvenile Round Back Round Shoulders.)

Kyphosis in adolescence may be due to:

A. Muscular (or postural) causes

B. Bony deformity

C. Disc lesions—the type often called "Adolescent Kyphosis," or vertebral epiphysitis.

the cartilage itself, or of the deprivation of support that follows senile osteoporotic processes in the body of the vertebra. The generalized collapse is seen in the increased biconvexity assumed by the disc at the expense of the bone, and the stretching of the cartilage accelerates the degenerative processes It is probable that some slight shock is the cause of the final rupture or fracture

Schmorl has drawn attention to the frequency of congenital errors in the intervertebral discs. These are of great importance in predisposing to pathological errors in the young. Perhaps the commonest of these developmental anomalies is the presence of localized herniations in the nuclear regions of the discs—the so-called "nuclear expansions." They occur mostly in the lower thoracic and lumbar regions, and consist of small hemispherical protrusions of disc tissue into the substance of the vertebral spongy tissue The cartilage over these expansions is very much weaker and thinner, and represents an area of diminished resistance where even the slight trauma of incessant functional activity is likely to lead to rupture or fracture of the cartilage.

2. Fracture of the Cartilage Plates: Prolapse of the Disc. Apart from the developmental and degenerative changes described above, Schmorl has shown that the cartilaginous plate is extraordinarily resistant to severe trauma and to those diseases which affect the vertebral body

The predisposing causes of rupture are.

(1) Nuclear expansion of the disc—a developmental error
(2) Senile degeneration of the cartilage
(3) Loss of support to the cartilage through osteoporosis of the vertebral body.

The result of rupture is the prolapse or protrusion of the disc tissue into the spongiosa—a phenomenon the recognition of which we owe to Schmorl and the Dresden school of spinal pathologists The frequency of the condition may be gauged from the fact that these observers found it in 30 per cent of all spines examined, and in all cases of juvenile and senile antero-posterior spinal curvatures.

The presence of the disc tissue in the spongy bone of the vertebral body calls forth a series of reactive changes which are designed to resist the process In youth the reaction is by the proliferation of cartilage and bone, which leads to the limitation of the prolapse In the aged the healing process is a different one, with granulations from the spongy tissue invading the disc and converting it into a shrivelled-up nodule of fibrous tissue

In youth, the loss of disc substance into the prolapse interferes with the function of the discs, while the alterations in shape and size give rise to important spinal deformities. In older individuals, where healing is by granulation, the destruction of disc tissue hinders the normal reaction to the changing demands of functional activity. In both,

If the spine can by this means be rendered flexible, further treatment by developmental exercises should be carried out.

(*b*) The Osseous Type.

This occurs as a secondary deformity to disease or accident affecting the body of the vertebra, and is associated with appropriate symptoms; e g. tuberculosis, rickets. It must be carefully excluded from the other types when estimating the cause of the kyphosis.

(*c*) True Adolescent Kyphosis (Scheuermann's disease: Vertebral Epiphysitis).

This condition occurs in boys between the ages of 12 and 17 and gives rise to a marked kyphosis which is usually painless and which affects chiefly the middle and lower parts of the thoracic spine.

Clinical Features

The area affected extends over three to five neighbouring vertebræ and shows marked rigidity, and increase of the normal antero-posterior curve. The neck is usually flexed, the shoulders appear to droop, the chest is narrow and flat and the scapula prominent. Aching is frequently present but definite pain is uncommon It is usually possible to improve the deformity only in the very earliest stages of the disease and it tends to increase slowly up to the age of 20 to 21 years

Radiological Appearances

These are characteristic. Edelstein points out that the disease shows three characteristic radiological stages, viz .

(*1*) *Florid stage*—in which the vertebral body appears wedged with its apex to the front. There is some mottling of the upper and lower ring epiphyses, and the upper and lower surfaces of the vertebral body appear fuzzy and uneven The intervertebral space is diminished.

(*2*) *Destructive stage*—in which the epiphyses now appear fragmented, and there is often disappearance of the upper and lower outer corners of the body.

(*3*) *Reparative stage*—in which density returns to the epiphyses, and definition to the upper and lower aspects of the body. The body, however, still retains its wedged appearance, which is permanent

In many cases there are also obvious *nuclear prolapses* affecting a series of vertebral bodies

Etiology

The disease is generally regarded as a sequel to disproportion between the *capacity* of the spine and the *load* it has to bear, but there is no clear agreement as to the factors bringing about this disproportion. The various theories may be conveniently considered thus:

(*a*) Factors diminishing the Capacity of the Spine.

(*1*) *Circulatory disturbance* Axhausen suggested that the condi-

(*a*) The Muscular Type.

This affliction is usually seen in children of poor physical development, or who have recently had a severe illness. The shoulders fall forwards and downwards and the head is pushed forwards In the early stages the movements of the spine are normal, but as the deformity continues so is mobility lost and complete correction eventually becomes impossible

Kyphotic children are usually of a special type and are dull and uninteresting looking, slow in their movements, flat-footed and clumsy in their movements, and poor at games. The condition is usually painless and the child is brought because of the deformity. Occasionally, however, there is aching in the spine, feet and legs, from the strain on the ligaments and muscles.

The physiological antero-posterior curvature of the spine is subject to so many variations, even under normal conditions, that it is difficult to say when the border-line has been crossed Lovett recognizes four clinical types of error:

(*1*) *Round Back* Here the spine has resumed its infantile form; the whole column presents a gradual thoracic kyphotic curvature, and the cervical and lumbar lordoses are absent

(*2*) *Hollow Round Back* The thoracic kyphosis is increased and there is a compensatory increase in the lumbar lordosis

(*3*) *Upper Round Back* There is an aggravation of the curvature in the upper part of the thoracic region, and the head and neck are thrust forward

(*4*) *The Flat Back* The spine is unusually straight and the thoracic and lumbar curves absent, but the shoulders are carried in a forward position.

Treatment

When the treatment is started at an early stage the outlook is good and correction can be accomplished without difficulty. Obvious errors of posture such as bad sitting habits should be corrected. The movements of swimming are particularly useful, and deep-breathing exercises are important. It is unwise in prescribing exercises to subject the children to unnecessarily severe muscular exertion Braces are not advisable The child's own muscular effort is better and more permanent

The Flexible Case. When the deformity can be reduced, either actively or passively, treatment should take the form of mild stretching, and of supervised exercises designed to develop the spinal and abdominal muscles.

The Resistant Case In this type the vertebral column must be thoroughly mobilized by stretching, which is best done by stretching the shoulders over a padded roll When the scapulæ are thus forced back they tend to stretch the contracted soft tissues, in particular the pectoral muscles.

tion was akin to Perthes' disease and was due to diminution in the blood supply to the epiphyses

(2) *Early disc degeneration.* With increasing age changes take place in the nucleus pulposus The nucleus is invaded by fibro-cartilage starting at an early stage of fœtal development and continuing through life, so that by middle life its elasticity is lost and the cellular elements disappear The water content becomes progressively less and so the disc is less able to fulfil its function of distributing stresses evenly over the bodies of the vertebræ. The buffering action of the nucleus may be reduced even during adolescence and some change is universal by middle life

The reaction of the vertebræ to increased and ill-distributed pressure varies with the condition of the bone at the time and in adolescents, where development is not complete, the increased pressure on the front of the bodies retards growth and causes them to become wedge-shaped This is a typical feature of adolescent kyphosis.

(*b*) Factors causing increase in the Spinal Load.

(*1*) Increase in the body weight.

(*2*) Multiple minor traumata

(*3*) Shortening of the hamstring tendons Lambrinudi has shown that when the hamstrings are shortened, the effect is to cause increased flexion at the thoraco-lumbar junction on stooping. As a result of this, aided by minor trauma (e.g. leapfrog and gymnastic exercises), hæmorrhage occurs beneath the cartilage plates. The cartilage is apt to fissure or crack, and the disc tissue to prolapse.

Schmorl attributes the condition of adolescent kyphosis to a primary disturbance of the discs, while Lambrinudi attributes it to trauma and secondary lesions of the discs. The truth probably lies somewhere between, and it is probable that adolescent kyphosis is due to either congenital nuclear hernia or secondary nuclear hernia following trauma.

Differential Diagnosis

The condition has to be distinguished from tuberculosis, which is also associated with a kyphotic deformity The absence of pain and the nature of the radiological appearance render this easy

Treatment

In this form of kyphosis the spinal error is progressive if allowed to go untreated, but if the patient comes under treatment during the early phases there is some hope that the condition may be arrested. Treatment should be on similar lines to that of early tuberculosis of the spine, viz , absolute recumbency on a Whitman frame, with traction applied to the head or legs, or both, for a period of 3 to 6 months. Towards the end of this period hyperextension and general spinal exercises are instituted and weight bearing gradually resumed. If, in spite of exercises, the tendency to deformity persists, a light plaster

process The hip joints are unusually painful and they tend to fuse completely. The sterno-manubrial joint is usually affected.

In the early stages the diagnosis is made by X-ray of the sacro-iliac joints which show blurring and gradual obliteration of outline, perhaps at first unilateral but quickly becoming bilateral. Later sclerosis and ankylosis of the sacro-iliac joints takes place and ossification appears in the ligaments of the spine—particularly the anterior common ligament—until eventually the whole spine may be fused into a solid bony column Even if the patient should first complain of shoulder and neck pain with little or no backache, the sacro-iliac joints are usually radiologically affected. It is probable that spondylitis ankylopoietica and rheumatoid arthritis are the same disease and that the difference consists only of the pattern and the order of the joints affected It has been stated that rheumatoid arthritis gives essentially a centripetal distribution, starting in the small joints of the hand and spreading centrally, without the hips and spine being spared, while ankylosing spondylitis is of a centrifugal origin and order of spread.

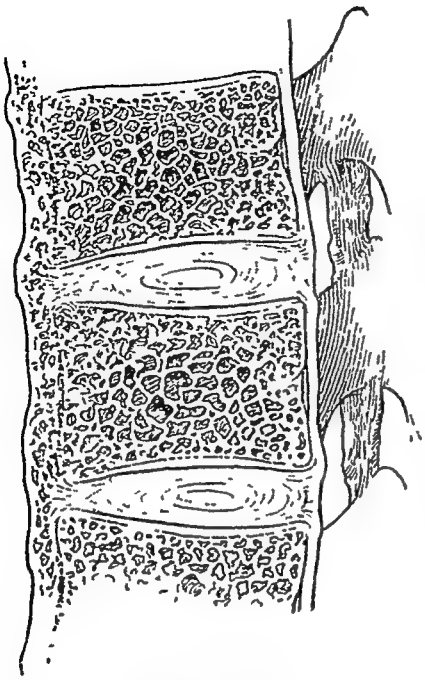

Fig 323.—Spondylitis Ankylopoietica

Diagram showing the ossification of the anterior longitudinal ligament

The cause is still obscure Everything points to its being a systemic disease and not an infectious one in the ordinary sense. The literature on the subject is bewildering and new experience is eagerly awaited in the endocrin domain

Prognosis

Ankylosing spondylitis is a chronic disease which may undergo remissions and exacerbations over years until ultimately it ankyloses the whole spine. The course in some cases is acute and rapid, while in others the progress is slow and takes many years.

Treatment

It is the aim of treatment to eradicate any obvious toxic focus, to control the pain and shape the progress of the disease by means of X-ray therapy, and to secure at the same time the optimum position for ankylosis by gradual reduction of the deformity

In the active stages the patient is rested in the best possible surroundings, with abundance of sunshine, fresh air and good nourishment. High doses of vitamins A, C and D and fresh yeast are given, as well

strangely enough, usually without the appearance of any local symptoms in the region.

The early symptoms are diffuse, in the form of attacks of pain of myalgic or radicular type The pain may move from one region to another, with pain-free intervals The diagnosis, accordingly, may be delayed for it may be many months In all their irregularity, however, the symptoms are yet in some way characteristic. Scott even bases the diagnosis solely on the history, though X-ray changes may be absent in this joint He goes as far as to say that spinal symptoms first appear when arthritis of the sacro-iliac-joints has reached the stage of ankylosis. The disease is overlooked owing to there having been no local symptoms in the sacro-iliac joint. A reliable diagnosis in cases of obscure spinal and root symptoms can often be made by an X-ray picture of the joints Often however by the time an orthopædic opinion is sought the patient's general condition has deteriorated, he has lost weight, has a worried expression, complains of low back pain of considerable duration, and of increasing stiffness and deformity of the spine Girdle pain is common and important. The pain has one almost pathognomonic feature in that it tends to be worse at night Stiffness is the other common symptom but it is often passed unnoticed by the patient One group of patients develop the symptoms insidiously, complaining of the back in the lumbar region and stiffness of the spine, with often girdle pains. A rarer type starts with prolonged fever and joint pains strongly suggesting rheumatic fever. Loss of weight, anæmia, prolonged periods of low-grade pyrexia, and tachycardia are common. The disease progresses from the sacro-iliac joints to the small joints of the spinal column where it brings about secondarily and additionally calcification of the ligaments, but the disease can terminate before that final stage affecting the spine.

It is unusual to be able to prove pain by means of the various methods to test the sacro-iliac joint when the joint is the seat of spondylitis ankylopoietica This is considered to be typical of the disease and distinguishes it from other pathologic processes in the same joint, as, for instance, tuberculosis and septic arthritis which are painful and, moreover, appear as a rule unilaterally. As the condition develops the costo-vertebral joints fuse and chest expansion is diminished considerably This loss of chest mobility renders the patient more liable to infection of the respiratory tract

In the early cases the erythrocyte sedimentation rate is usually raised, a fact of some diagnostic value Conclusions drawn from the sedimentation rate about the activity of the disease are, however, apparently unreliable. In the majority the S R is increased, even if the spondyloarthritis is apparently healed On the other hand, one may have an unaltered S.R in the presence of symptoms In most cases the disease is confined to the spinal articulations. Any tendency to spread is to the most adjacent joints, that is to the shoulder and the hips, and it is rare for more distal joints to be affected in the ankylosing

attachments from the spinous process and laminæ. The spinous processes are then divided with a thin osteotome and excised at their bases. This allows further reflection of the periosteum from the superior and inferior articular processes, exposing the intervertebral notch as well as the articular facets. The ligamentum flavum is then detached from the inferior margin of the lamina. The elevator is then advanced anterior to the lamina and inferior articular process until it appears in the lateral intervertebral notch just above the articular facet, so serving as a guide to the osteotomy. An oblique osteotomy through the superior articular process of the vertebra below and the inferior of the one above is performed at one, two, or three different levels, depending upon the amount of new bone which has been developed in relation to the facets and intervertebral disc. Upon completion of the osteotomy leverage of the body in the direction of extension is given by raising slowly the head and foot of the operating table. In closing the wound care is taken to bridge the gap in the laminæ by the insertion of bone lamellæ obtained from the spinous processes. These grafts bridge the open gap and consequently secure bony union in the corrected position.

This operation is an extensive procedure accompanied by a considerable risk and should be undertaken only after a careful consideration of all the problems involved

Bechterew's type. Von Bechterew described what he considered to be a new neurological disease characterized by stiffness of part or all of the spine, kyphosis with involvement mainly of the upper dorsal spine, paresis of the muscles of the back, neck and extremities, atrophy of the muscles of the back and shoulder girdle, diminished skin sensitivity over the area supplied by the cervical and other spinal nerves, and prominent symptoms of root irritation This is still known as Bechterew's disease and is a form of spondylitis ankylopoietica.

(*b*) Spondylosis Osteo-arthritica.

This includes several disease entities:

1. True Senile Kyphosis.

Morbid Anatomy

The whole spine appears remarkably well preserved, but the vertebral bodies are somewhat wedge-shaped. In their major portion the discs appear relatively normal, but there are constant changes at their anterior edges, varying from patches of necrosis or fibrosis to total disappearance. In the latter event, the adjacent vertebral bodies may be joined at their anterior edges by bands of spongy bone The changes are most marked in the upper and middle thoracic regions

The Explanation of the Changes

Schmorl has demonstrated beyond doubt that the earliest phenomenon is the necrosis of the anterior part of the disc. He

as iron Gradual reduction of the deformity by pillows on a bed fitted with a fracture board is instituted He is encouraged to lie on his back for increasing periods each day so that in a short time the improvement in the back deformity becomes obvious even to the patient Measurement of the distance between the occiput and the mattress on which he lies allows a measurement of his progress and is encouraging to the patient Because of the occasional spread to the hips and shoulders one should be on guard to see that these joints retain their full range of mobility Where the neck movement is limited a Glisson sling with traction by wedge and pulley from the head of the bed helps greatly Sometimes it is useful in reducing the deformity to suspend the body by a series of transverse slings hung on horizontal bars at either side of the bed

The various orthopædic measures are accompanied by deep X-ray therapy The prognosis in this disease has been materially improved by modern developments in radiotherapeutic technique and with proper management it is possible to arrest progress and relieve pain, and often to restore some movement to stiffening joints Radiotherapy is most effective when commenced early in the course of the disease The present scheme is to arrange the therapy on five consecutive days in a week, the first course generally lasting three weeks The treatment may be repeated at intervals of from two to three months In the interim suitable exercises are given, sometimes preceded by some form of heat such as radiant heat or diathermy Breathing exercises are important and are done in various positions. After all treatment is completed the patients are encouraged to return to work

The results seem reasonably good for, following supervision of the treatment for about a year, it is rare to have them report unless it is to report that they are proceeding satisfactorily

If the patient is seen only when both hip joints are ankylosed removal of the head and neck of the femur will provide a pseudarthrosis which will allow the patient greater freedom of movement and the ability to sit in a chair

Osteotomy of the Spine. For the flexion deformity of the spine produced by spondylitis ankylopoietica and also in rheumatoid arthritis Smith-Petersen evolved an operation of osteotomy of the spine to correct the serious deformity. The operation is confined to the laminæ and articular facets and does not involve the vertebral bodies The operation is not undertaken until all conservative measures have failed It is performed in the lumbar region at levels showing the minimum of bone bridging Such bony bridging may be expected to yield after osteotomy of the articular facets The thoracic region commonly presents ankylosed costo-vertebral joints which make correction difficult if not impossible

A mid-line incision is made over the selected level and at least three spinous processes are exposed The supraspinous and interspinous ligaments are removed, followed by the subperiosteal reflection of muscle

the spondylitic process Rather it is the result of a co-existing senile kyphosis.

THE SEQUENCE OF EVENTS

These changes have been carefully worked out by Schmorl, and are well described by Beadle. Formerly, this condition was referred to as osteo-arthritis, or as spondylitis deformans Since the bulk of the changes affect the discs and the vertebral bodies, where there are no joints in the true sense of the word, the former term should be discarded In the absence of evidence of an inflammatory process, the term spondylitis should also be avoided, and hence Schmorl has coined the term "spondylosis"

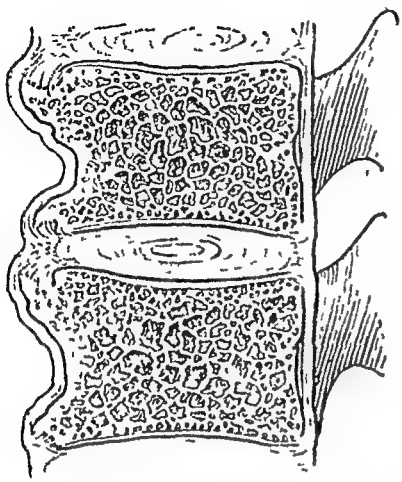

FIG. 325 —Spondylosis Deformans.

Diagram showing some flattening at the epiphyseal discs and osteophytic outgrowths in front of the bodies a little distance from the upper and lower edges

The essential factor in the process is obviously the degeneration in the discs As these waste, there results an increased mobility of the vertebræ one on the other, and the consequent continuous tugging on the fibres of the anterior longitudinal ligaments, which are closely attached to the front and sides of the vertebræ, leads to the production of bony exostoses or osteophytes The looser attachment of the posterior ligament prevents the gross changes seen anteriorly, but occasionally small osteophytes are found on the posterior surface of the vertebral bodies as well.

The occasional absence of kyphotic deformity is due to the fact that, the disc degeneration being diffuse and the posterior intervertebral articulations looser than in youth, the bodies of the vertebræ sink together more or less squarely. Nevertheless kyphosis is a frequent accompaniment, and is due to a greater, or earlier, degree of degeneration in the anterior edges of the discs, together with the habitual assumption of postures which throw severe strains on the front parts of the vertebral bodies.

3. Senile Osteoporosis of the Spine.

MORBID ANATOMY

In this form of "senile spine," an osteoporosis of marked degree is evenly distributed throughout the spine The bone trabeculæ are largely absorbed and replaced by marrow The discs are usually in a state of excellent preservation and bulge markedly into the atrophied spongy tissue of the vertebral body Viewed as a whole, the spine is grossly deformed, owing to the softened vertebral bodies being

suggests that it is a natural response to the greater degree of strain exerted on this area of the disc, especially in those whose occupation is heavy and demands continual stooping The necrosis leads to tears in the annulus, and finally to the complete dissipation of the disc, as a result of which the anterior ends of the two opposing bony surfaces are forced into contact. Long-continued pressure of this kind leads to bone absorption, and the body of the vertebra gradually assumes a wedge-shape. If the anterior ends of the cartilage plates are at the same time destroyed, the adjacent bodies may become ankylosed by bridges of new bone

The significant features of the disease, therefore, are: (1) Kyphosis, due to

(*a*) Necrosis of the anterior parts of the disc.

(*b*) Bone absorption at the anterior edges of the vertebral body

(2) Relative health of the main mass of disc substance

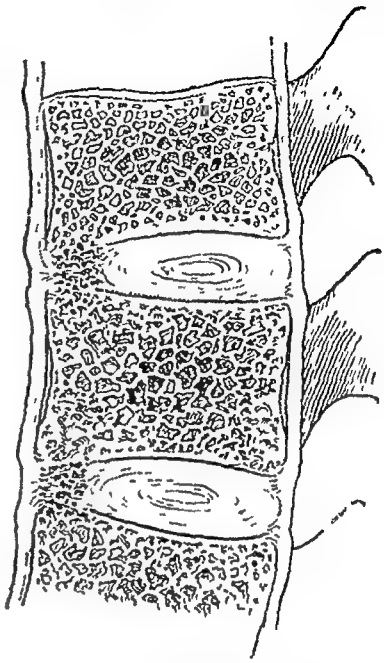

FIG 324 —Senile Kyphosis

Diagram showing the bodies joined to their anterior edges by spongy bone

2. Spondylosis Deformans.

MORBID ANATOMY

The most typical feature of this form of disease is the generalized degeneration of the intervertebral discs These degenerative changes may take the form of brown degeneration, or necrosis. In many cases the disc is prolapsed and invaded by granulation tissue, so that it is present only as an inert fibrous nodule.

The shape of the actual vertebral body is usually unchanged, but the epiphyseal rings may be flattened out Characteristically there are osteophytes of varying size on the anterior and lateral edges of the vertebral body These lie a little below the outer edge of the epiphyseal ring, and proliferate so as to overlap the intervertebral space until eventually osteophytes from adjacent vertebræ may fuse together. These osteophytes tend to be arranged in rows, and adjacent nodules are usually connected by raised bony ridges on the antero-lateral surface of the body It seems clear that this marginal bone proliferation is the result of abnormal tensions on the fibres of the anterior longitudinal ligament, and the bony ridges actually reproduce with faithful accuracy the direction of the ligamentous strands. The condition therefore has been called poly-spondylitis marginalis.

As a whole, the spine may or may not show a kyphotic deformity, usually it does, but the kyphosis must not be considered a part of

Clinical Features

The clinical features of spondylosis deformans, the so-called osteo-arthritis of the spine, being a common condition of adult males must be considered in some detail It occurs in the lumbar spine, an area which is mobile and therefore most liable to the trauma of over-exertion, and is thus seen most commonly in patients whose occupation, such as coal-mining and dock-labouring, have incurred strain over a period of many years.

It is frequently demonstrated radiologically that considerable arthritic change may be present in the lumbar spine and the patient remain symptomless Some factor such as a recent minor injury, increase in weight or the presence of an active toxic focus is usually responsible for the onset of symptoms

In the earliest phase the patient is conscious of his back and has difficulty in carrying out certain movements. There is frequently a history of attacks of "lumbago." At a later stage the pain never completely disappears, one attack merging into another. With each successive attack, the spinal symptoms become more marked and movements more limited. Pain is present particularly in the morning when he straightens up after bending Thus, he often notices that he has difficulty in putting on his boots The pain and stiffness progress, with remissions, until eventually the whole spine is involved

Sensory symptoms become prominent later, and are due to pressure on the nerve roots as they leave the spinal foramina. They may occur before any radiological evidence of the disease is apparent Motor root symptoms are uncommon

When osteophytes are present the X-ray picture is characteristic. In the degenerative form the vertebræ are atrophied and the vertebral shadow uneven In the more advanced cases a mottling or stippling of the vertebral shadow is evident.

The remaining forms of senile kyphosis are evidenced by a change in the figure The individual loses in stature, and carries himself with a pronounced stoop with the head and shoulders apparently thrust forward.

Diagnosis

In addition to distinguishing between the different members of this series, senile kyphosis must be distinguished from those diseases of the vertebral body which result in deformity These are mainly tuberculosis—rare at this age—Paget's disease, Kummel's disease and secondary malignant deposits The differential diagnosis presents no difficulties if full account is taken of the clinical history in conjunction with the radiological features.

Treatment.

The treatment of spondylosis may be considered under two headings :

unable to withstand the superincumbent weight.

The Explanation of the Process

It seems that this type of spinal deformity is common in those who, through the light nature of their work or profession, or through the inherent strength of their constitution, escape the common stresses of advancing age, namely degeneration of the discs or senile kyphosis Schmorl believes the absorptive process is analogous to an atrophy of disuse See also p. 107.

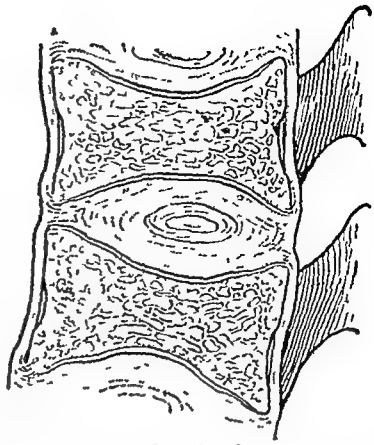

Fig 326 —Senile Osteoporosis. Diagram showing the fish tailing and porosis of the vertebra and the bulging of the discs

Summary of Kyphosis in Adults and the Aged

The continual strain on the individual components of the spine inevitably leads to a series of degenerative changes as age advances These vary according to certain inherent tendencies, and the nature of the individual's employment or exercise Other things being equal, the changes fall naturally into three groups:

1 Degeneration in the anterior parts of the discs, with kyphosis.

2 Degeneration in the entire disc, with new bone formation, with or without kyphosis

3 Degeneration in the vertebral body, with marked deformity

The trend of modern opinion is to regard the spinal changes discussed above as the inevitable sequelæ of advancing years. In many cases the condition has little beyond a pathological interest, and treatment is impossible or useless. The main interest of Schmorl's work up to the present is, therefore, concerned with accurate diagnosis rather than treatment

An accurate knowledge of the underlying pathology will lead to the elucidation of many previously obscure radiological appearances. Thus, it is now known that increased biconvexity of the intervertebral discs is evidence of a senile osteoporotic change in the vertebral body, and the condition can be differentiated with certainty from spondylosis deformans, which is associated with loss of the intervertebral space and the lavish production of marginal osteophytes. Prolapse of the disc reveals itself as an area of increased density in the substance of the vertebral body. In the senile kyphotic spine the radiological appearance is distinctive; the widespread curvature, the loss of the intervertebral space at the anterior aspect of the body, and the atrophic change at the antero-superior and antero-inferior angles of the body, are characteristic

the fusion extends up and down. When this fusion fails there is a gap in the vertebral arch constituting the spina bifida.

The term spina bifida is applied to this congenital gap in the vertebral column through which the contents of the spinal canal may

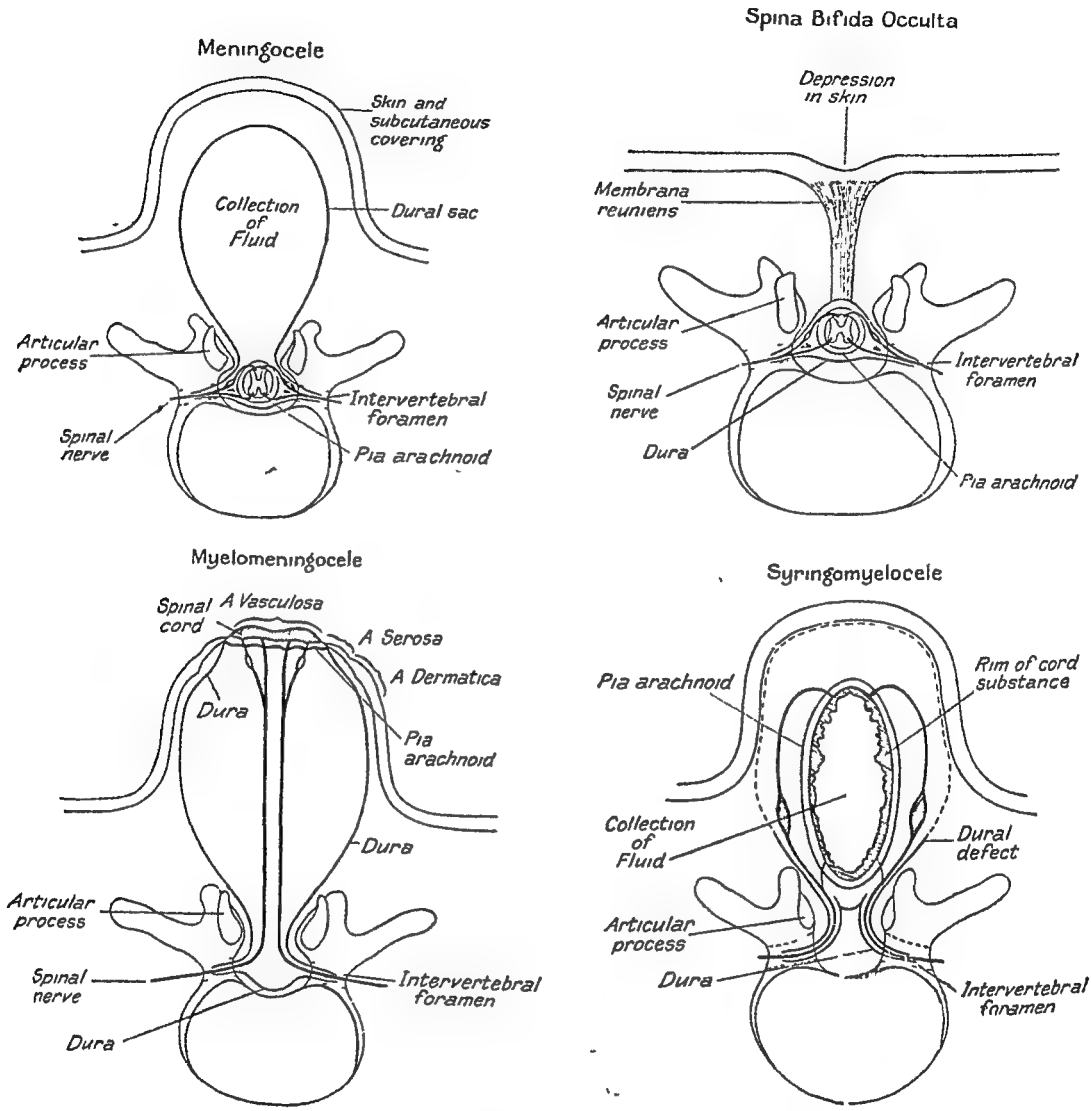

FIG. 327 —Diagrammatic representation of the anatomical relations of the various types of Spina Bifida (After Fraser)

be protruded. It is a distressing and a grave deformity, and is said to occur about once in every thousand births But, though grave, recent authors deprecate undue pessimism, 30 per cent. of patients affected by spina bifida may expect to lead a relatively normal life, assuming that operation has been carried out.

MORBID ANATOMY

Six varieties of spina bifida are recognized:

1. **Meningocele.** Through a congenital defect in the posterior

(1) *General*

(*a*) The eradication of toxic foci in the teeth, tonsils, genito-urinary and gastro-intestinal tracts

(*b*) Correction of postural defects

(*c*) Reduction of weight

(*d*) The possibility of a change to a less arduous occupation should be considered.

Some of the malacic diseases of bone are being treated by aluminium salts on the hypothesis put forward by Helfet for the treatment of fibro-cystic diseases of bone. According to this hypothesis the secretory activity of the parathyroid gland is stimulated by the phosphate of the blood and the bone lesions are the result of chronic hyperparathyroidism, caused by chronic hypophosphatæmia. The aluminium salts precipitate a part of the phosphate of the bowel and so prevent its absorption This has been used in other diseases, such as Paget's, and is also used in osteoporosis of the spine with some degree of clinical improvement Either the aluminium acetate or gluconate is used and at the same time calcium, vitamin D, and abundant milk are prescribed

(2) *Local.*

The common physio-therapeutic measures of massage, radiant heat and diathermy are all of service in relieving pain and accompanying muscle spasm. When the acute phase has passed, to these methods of producing local heat are added graduated exercises to maintain the maximum range of mobility

In the absence of gross osteophytic formation or active toxic focus considerable relief of symptoms may result from gentle manipulation of the lumbar spine. In more advanced cases recumbency on a Whitman frame or firm bed may be necessary to reduce the deformity prior to the fitting of a spinal support

The remaining conditions in this series are seldom amenable to active treatment, but if pain is a prominent feature the use of a spinal brace will afford a considerable measure of relief.

Spina Bifida

Development of the Spinal Cord. In the early days of intra-uterine existence a dorsal groove appears on the dorsal surface—the neural groove. This gradually becomes closed off, forming the neural canal, which goes to form the whole central nervous system. Its lumen persists as the central spinal canal. This neural canal eventually becomes separated from the extra-dermal covering of the body by an ingrowth of mesoderm Anterior to the neural canal there is a solid rod of cells —the notocord—and round this the vertebral bodies themselves develop. From each of the bodies there extend backwards two projections which grow round the neural canal to form the vertebral arch The two halves of the arch fuse behind first in the thoracic region From there

a localized overgrowth of hair. The membrana reuniens, according to Fraser, does not increase in size in proportion to the growth of the spinal cord so that sometimes, about the tenth or twelfth year, it may prove to be too short, and so lead to compression of the cord by traction. Various paralyses may then result.

FIG 329—Lumbar Spina Bifida of the Myelo-meningocele Type.
The right leg shows the talipes deformity which so often accompanies the spinal error

6. Anterior Spina Bifida. This differs from all those mentioned in that the protrusion is to the front It is probably due to a defect in the development of the bodies since at an early stage they consist of two lateral halves and these may have failed to fuse. It may occur in the cervical region or in the lower lumbar region.

THE CLINICAL PICTURE

The clinical features may be discussed in three groups.

1. The tumour.
2. The nervous symptoms.
3. The associated deformity.

1. The Tumour. The tumour is situated in the mid-line and is most frequently found in the lumbar or lumbo-sacral region It is of variable size and is increased by expiratory acts such as crying. It is yielding and fluctuating, and often transparent on trans-illumination. The hiatus of the spinal column is demonstrable in the radiograph

2. The Nervous Symptoms. These vary with the degree of the spinal defect and may be absent in a meningocele or spina bifida occulta, but very marked in the other varieties The motor tracts suffer most severely, and there may be complete paraplegia with muscular wasting and contractures. Sensory disturbances are usually extensive, but limited to the lower limbs, while trophic disturbances are common, particularly perforating ulcers of the foot

3. Associated Deformities. In many cases of spina bifida other deformities are present, affecting the spine itself or the lower limbs, e.g malformation of the vertebræ, congenital dislocation of the hip,

wall of the spinal column there is a sacular protrusion of the membranes —pia and arachnoid The dura stops at the margin of the bony defect. It contains cerebro-spinal fluid, but no nerve tissue

2. The Myelo-meningocele. There is usually a large gap in the posterior wall of the spinal column, through which protrudes a sac which is more often sessile than pedunculated The cord protrudes as well as the membranes and it contains both spinal fluid and nerve tissue, the latter varying with the level of the defect Von Recklinhausen recognizes three areas on the surface of the sac of a myelo-meningocele

(*a*) The central area — the medulla vasculosa — which is recognized by an overlying area of granulation tissue.

(*b*) Surrounding it, the zona epithelio-serosa, covered by a thin pellicle of serous membrane

(*c*) The zona dermatosa—a covering of skin which is often thickened and hairy. The sac contains cerebro-spinal fluid and nerve tissue, the latter being attached to the medulla vasculosa of the sac

Fig 328 —Spina Bifida Specimen showing the nerves leaving the spinal canal

3. The Syringo-myelocele. In this type the spinal cord itself forms the actual lining of the sac and is thinned out into a cyst by distension of its central canal. The skin covering the sac is well formed and uniform, but is often pigmented and covered with a thick growth of hair

4. Myelocele. This deformity occurs most commonly in the lumbar region, where normal closure is longest delayed The defect appears as an elongated fissure, with edges scarred and irregular and covered with telangiectases, or surrounded by hair. Cerebro-spinal fluid escapes from the sinus, which is in direct communication with the central canal of the spinal cord The condition is rarely compatible with life and is never amenable to surgical treatment.

5. Spina Bifida Occulta. Here the development of the canal has gone on to a further degree and is fairly complete, but a defect exists in the vertebral laminæ Though there is no actual hernial protrusion of the dura, the membrane is often connected to the skin by a fibrous band which passes through the bony hiatus and is known as the membrana reuniens. Tumours such as lipomata or angiomata are sometimes present, either outside or inside the vertebral canal The skin overlying a spina bifida occulta shows in many cases

or remove the contents, and to repair the defect by a strong covering of skin and muscle.

The child is placed on an angled Whitman frame with the head down. This position is maintained throughout the operation and for at least 6 days afterwards. If the defect is in the lumbar region, rubber dam is glued above the buttocks to prevent contamination. A transverse elliptical incision is made to encircle the tumour, and the meningeal sac freed down to the gap in the spine. The sac is opened and the contents dealt with according to the type and distribution of the nerve structures. In a meningocele the sac is completely excised and the gap closed by sutures In a myelo-meningocele the vascular area contains nerve cells from which nerve roots may take origin, and it should therefore be carefully preserved The termination of the cord and the nerve roots should be freed from the sac wall and returned to the vertebral canal. In a syringo-myelocele the whole cyst should be replaced after its size has been reduced by tapping.

The edges of the dura are carefully repaired by a continuous suture of fine silk or linen thread The gap in the vertebral column is closed by musculo-fascial flaps. Restoration of the bony canal lengthens the operation, increases the shock and is unnecessary.

If leakage occurs after the operation a fistula persists and infection and meningitis are almost inevitable. This is often precipitated by a rising cerebro-spinal fluid pressure, a development which often is consequent upon the operation To counteract this tendency spinal fluid drainage may be instituted at a point proximal to the operation site and continued until the pressure is stabilized at a physiological level and the wound healed 200 to 300 c c of fluid drain in the 24 hours

In spina bifida occulta, operation is indicated only if signs of cord compression develop in later childhood. The operation consists in the removal of the fibrous band which unites the dura to the skin, or of the extra-dural lipoma if such exists. The track formerly occupied by the fibrous band is then carefully obliterated.

contracted knees, claw foot, etc. Hydrocephalus is often associated with the condition.

It is usual to consider three syndromes associated with a spina bifida occulta:

(1) Foot deformities, especially claw foot,
(2) Nocturnal enuresis;
(3) Low backache and weakness

Fig 330.—Spina Bifida of the Occult Type.

Fig 331.—Spina Bifida of Cervical Vertebræ.

Diagnosis

The nature of the error is usually obvious, but a spina bifida occulta may only be recognized by radioscopy. In the diagnosis of the type of spina bifida, a radiograph taken after an injection of oxygen into the sac gives valuable help, as it shows the distribution of any nerve structures within the sac

Treatment

After birth the part should be carefully protected and the skin treated each day with spirit and antiseptic dusting powder.

The only kind of active treatment to be considered is operation and this is carried out as soon after birth as possible, preferably when the infant is seven to 10 days old Leakage from the sac, ulceration of the surface, co-existing paralysis of the limbs, a patulous anus, absence of the anal reflex or constant dribbling of urine, poor general health and the presence of hydrocephalus are all contra-indications to operation.

The meningocele is the most suitable, the myelocele quite unsuitable, for operative interference The aim is to excise the sac, to reduce

rests against the under surface of the acromion. Further abduction takes place mainly by the lateral rotation of the scapula on the chest wall, but in addition Martin has shown that there occurs a lateral rotation of the humerus at the glenohumeral joint. This serves to roll the greater tuberosity backwards out of contact with the acromion, and permits the last few degrees of abduction to be carried out.

It is a noteworthy feature of shoulder injuries that even after trivial trauma, abduction of the shoulder appears to be limited. In many cases it will be found that in point of fact pure abduction is not restricted, but that loss of the all-important external rotation may create this impression by abolishing the terminal part of the movement Two important deductions may be drawn from this:

1. It is important in severe joint injuries necessitating immobilization to keep the arm laterally rotated.

2 In manipulating a stiff shoulder, it is important to restore the lateral rotation before full abduction is attempted.

A detailed description of the anatomy of the shoulder joint would be out of place here, but attention may be called to the wide range of movement in the joint, and the fact that the attachment of the arm to the body is effected principally by muscles The importance of carefully applying the principles of muscle balance when treating injured shoulders is thus apparent. The location of the sub-deltoid bursa, and the relationship of the circumflex nerve to the surgical neck of the humerus, in which situation it is peculiarly exposed to injury, should also be borne in mind.

Injury to the shoulder is constantly followed by pain, limitation of movement, and muscular atrophy. Pain in this region, however, may be produced by lesions elsewhere than in the shoulder itself. Various cervical, thoracic and abdominal lesions may be responsible, and it is important to realize that such referred pain may in time lead to actual limitation of movement and stiffness of the joint. The pain is referred through the phrenic nerve, and Cope has attempted to localize the causal lesions by mapping out the exact site of the referred shoulder pain. Thus pain in the clavicular area, i.e. over the front of the shoulder, is referred from a lesion in the anterior part of the diaphragm. Pain over the supraspinatus muscle follows a lesion of the posterior part of the diaphragm In lesions affecting the dome of the diaphragm the area of reference is over the acromio-clavicular joint. When both shoulders are painful the lesion is usually situated in the central tendon of the diaphragm.

In a recent study of 56 cases in which the chief complaint was shoulder pain, 14 were apparently produced by lesions without the shoulder. These cases included 2 of cervical rib, 3 of cervical arthritis, 1 axillary abscess, 3 of pleurisy, 1 of tuberculous pleurisy, and 4 with gastric disorders

CHAPTER XIV

AFFECTIONS OF THE SHOULDER JOINT

Injuries in the region of the shoulder are common, and the effects of trauma are demonstrable in all the components of the shoulder. The joint itself is frequently dislocated and fractures in this situation are numerous. These major injuries are usually described in general text-books and will not be discussed here.

The minor injuries, however, are of great importance. Damage to the soft tissues, to the joint surfaces in the absence of dislocation, and to the bony components in the absence of actual fracture, have all to be considered. They assume increased importance from the fact that, although apparently trivial, they frequently lead, especially in older persons, to functional disability even after prolonged and painstaking treatment. Watkins, from a consideration of the comparative anatomy of the joint, suggests that the slow or incomplete return of function can be explained by its recently acquired capabilities He points out that despite the gradual evolution of orthograde man, there has been no development of new muscles Those which were adapted to plantigrade action, i.e with the body held horizontally, have merely had orthograde functions superimposed on them Man's ability to raise and maintain his arm above his head is thus a late acquisition in the evolution of his muscular apparatus and is therefore correspondingly unstable. It follows that whenever the limb is disabled, this most recent function is the first to be affected and the last to recover. Probably the most important of the movements of the shoulder, at least in its relation to trauma, is that of abduction, and a clear conception of this is essential, not only for appreciation of the effect of shoulder injuries but of the nerve lesions in this situation as well.

Abduction from the hanging position is begun by the contraction of the deltoid, but to permit of this the head of the humerus must be held firmly against the glenoid by the contracting supraspinatus, and its associated transverse muscles. During abduction of the arm by the deltoid, the head of the humerus tends to slip upwards over the glenoid fossa. The supraspinatus, pulling transversely, holds the articular surfaces firmly together and in this way supplies a fulcrum against which the deltoid works. When the supraspinatus is paralysed or torn, therefore, abduction is considerably interfered with, particularly in its initial stages. The deltoid carries the arm practically to the horizontal position, and in this position the greater tuberosity

movement, and when it is passively stretched. The pain is the site of the strain, and if any of the fibres have ruptured there be acute pain on pressure at this particular spot. When a sup muscle, like the biceps, has been completely torn through, a prc is visible at the site of rupture when the muscle contracts.

(*a*) *The Deltoid.* The deltoid abducts the arm only when the of the humerus is fixed against the glenoid by the supras Otherwise, its first effect is to draw the head of the humerus up against the under surface of the acromion Loss of abduction, fore, must not be attributed to deltoid insufficiency until a c investigation has been carried out. When the deltoid muscle is stra active abduction is either greatly restricted or painful. Passive ab tion is easily carried out, but if the patient is asked to hold the in the abducted position acute pain is felt and the arm falls to the side.

Gross rupture of the muscle is unusual; the more common consists of rupture of a localized group of muscle fibres.

(*b*) *The Supraspinatus.* Injury of this muscle is important, a special section is devoted to it (page 770).

(*c*) *The Biceps.* The main function of the biceps is to the forearm, and to flex the arm at the shoulder joint. Flexi the elbow is a secondary effect.

Bicipital lesions not infrequently take the form of a complete di of one of the muscle bellies, which is usually easily recognized. the muscle actively contracts a tumour appears at the site of rup and disappears when the muscle is relaxed. When the tendo injured, pain is experienced at the shoulder joint when the fore actively supinated, and there is tenderness over the tendon as it in the bicipital groove.

(*d*) *Rupture of the Long Head of the Biceps* is a rare but occasi lesion. In most cases there is a history of injury, which may take form of lifting heavy weights, or violent extension of the forearm flexion is being carried out, while in some cases the rupture appea have been spontaneous, during the performance of normal movem The latter eventuality has been supposed due to gradual attrition of muscle as a result of its constant playing over an irregularity of the b in the region of the surgical neck, a sequel to a former fracture Occa ally the tendon shows a degenerative change due to pre-existing or peri-arthritis.

The clinical features are characteristic. The muscle belly sho bulbous enlargement in its lateral half, and is situated at a lower than on the opposite side. There is often some discoloration in region of the medial margin of the biceps at its upper part. Fle and extension of the elbow produce pain

Treatment should be by operation, the results of this being factory. The rupture is exposed by an antero-lateral incision over upper end of the biceps belly, and the ends identified The bicip

A CONSIDERATION OF THE VARIOUS LESIONS

Sprain of the Shoulder Joint

A sprain results when the shoulder joint is wrenched and the normal limits of its movement are exceeded. Owing to the shallowness of the glenoid cavity two abnormal movements may be produced at this joint, namely forward and backward movement of the humeral head in the glenoid cavity These displacements may be produced by falls on the back or front of the shoulder, or upon the elbow or hand when directed backwards or forwards The capsule, the synovial membrane, or the ligaments may be stretched or torn, either alone or in combination There is usually an extravasation of blood into the periarticular tissues, and occasionally the effusion may involve the tendon sheaths, so that sprains of the shoulder are likely to be followed by periarticular fibrosis or adhesions The shoulder region is swollen and painful, the pain being most intense when the patient attempts to move the joint in the direction which produced the injury. In nervous patients, exaggerated symptoms may follow slight strains or even excessive use of muscles In such cases extreme pain is felt not only over the shoulder but also down the arm, so that neuritis is sometimes diagnosed. There is no tenderness over the nerve trunk, however, and sensory changes are absent

In arriving at a diagnosis, radiography should be employed to exclude bone damage. Sprains of the shoulder may be incidental to some other more serious injury, such as a Colles's fracture, and may pass unnoticed at the time.

Treatment

In the treatment of shoulder sprain, the complication to be most feared is the formation of adhesions from prolonged immobilization. Accordingly from the earliest stage the shoulder should be moved both actively and passively, after the application of some form of heat therapy. To ensure a good functional result the arm should be retained at an early stage in full abduction with a certain degree of lateral rotation, by means of an abduction or platform splint In later cases accompanied by marked limitation of movement, it may be necessary to manipulate the joint under an anæsthetic and apply an abduction splint thereafter Diathermy, massage, and the re-education of muscles constitute in all cases the subsequent treatment. The injection of 50–60 c c of normal saline under the acromion is often beneficial.

Muscular Strains in the Shoulder Region

The muscles in this region which are most commonly injured are the deltoid, the biceps, the medial rotators, and, more rarely, the lateral rotators. Muscular lesions are distinguished by the fact that the muscle is painful when it is actively moved, when resistance is offered to its

acromion process in movements of abduction and rotation of t shoulder. The peripheral portions of the bursa are loose and redunda and this permits the floor of the bursa to glide under the roof movement. The layers of the bursa are normally approximated b enough fluid is secreted to keep them moist and lubricated.

Inflammation of the bursa occurs practically always as a conseque of a lesion involving neighbouring structures. Codman says that describe sub-acromial bursitis as an entity would be equivalent describing peritonitis as an entity. It is not a structure where dise starts, so much as a structure which limits disease in the adjac structures by temporary adhesions causing fixation of the parts. In bursa the source of most of the pathological changes is the struct forming the larger part of its floor, particularly the supraspinatus eleme of that structure. Owing to the peculiar mechanics of the shoulder j the avascular and inert supraspinatus tendon is the most vulnera part of the joint. Inflammation in it may be painless until the adjac bursa is involved which, being abundantly supplied with vessels nerves, produces the symptoms of which the patient complains Th relatively unstable architectural arrangement of the shoulder joint wit its large humeral head and small glenoid cavity throws much strain o the tendo-muscular cuff which is thus exposed to the injuries of repeate minor insults in daily use.

When the bursa is involved a fairly constant clinical picture presented The main features are Pain in the shoulder on abductio and internal rotation of the humerus; severe aching at night, tenderness on the point of the shoulder. Pain on movement may b of all grades of intensity. It is usually felt near the insertion of th deltoid muscle rather than in the joint itself, although it may radiat widely. The aching at night is often the patient's chief complaint Usually there is a point of tenderness on the greater tuberosity w disappears under the acromion on abduction (Dawbarn's sign) This tenderness may be absent or it may be widespread over the deltoid region In some cases the patient gives a history of an injury to the shoulder This usually takes the form of a fall on the outstretched arm or the point of the shoulder (stubbed shoulder) When the pain follows an injury there is usually an interval of a few days before it manifests itself. There are cases, however, where loose bodies can be felt, or can be shown by X-ray examination; in these cases there is a localized swelling, and pain confined to the region of the bursa on abduction of the shoulder joint X-rays may also show calcareous deposits in the supraspinatus tendons

(*b*) **Sub-Coracoid Bursitis.** The sub-coracoid bursa is situated between the tip of the coracoid process and the capsule of the shoulder joint, it extends up to and even over the lesser tuberosity of the humerus Normally the humerus and the coracoid are closely applied to each other, the tip of the latter resting against, or being opposite the lesser tuberosity of the humerus. This contact is much closer

fascia covering the tendon in the bicipital groove may need to be divided if it has not already been ruptured along with the tendon. The suture is carried out with the elbow flexed (See also description in Chapter XX)

Recurrent dislocation of the long head of the biceps may follow tearing of the bicipital fascia (See page 784.)

(*e*) *The Medial Rotators* The muscles which produce medial rotation of the humerus are the pectoralis major and the subscapularis. The former is palpable in its whole extent and injury can be readily detected, but the subscapularis, attached as it is to the capsular ligament and to the lesser tuberosity, is more deeply situated. In strain of these muscles pain is experienced during active medial rotation, particularly if this movement be resisted. Inflammation of the bursa separating the anterior part of the shoulder capsule and the base of the coracoid process is also associated with pain on medial rotation.

(*f*) *The Lateral Rotators* The infra-spinatus and the teres minor produce lateral rotation Strain of these muscles is uncommon. It may result indirectly from traction on the muscles, or from direct injury.

Acute Synovitis of the Shoulder Joint

Synovitis is less common in the shoulder than in the knee, but when present it is painful and difficult to treat. It may be caused by injury or may be due to a local infection as in so-called rheumatism, and it is found in association with inflammatory conditions of the neighbouring bursæ or tendons. In the early stages of tuberculosis and arthritis deformans there is also a certain degree of synovitis.

The joint is swollen, and movements are painful, particularly when the arm is allowed to hang supported only by muscles and capsule. The synovial effusion is most obvious in the delto-pectoral groove where the joint may be aspirated should the diagnosis be in doubt. Diagnostic aspiration may also be performed between the acromion and the head of the humerus, inserting the needle horizontally and then downwards and backwards An effusion into the sub-acromial bursa is best evacuated from the lateral aspect, the needle being inserted just below the middle of the posterior edge of the acromion.

Synovitis of the shoulder is treated in a position of abduction on the lines laid down in Chapter VII.

Bursitis

(*a*) **Sub-Deltoid, or Sub-Acromial, Bursitis.** The sub-acromial bursa lies under the upper part of the deltoid muscle, and extends upwards underneath the acromion process It separates the greater tuberosity of the humerus from the deltoid muscle and the acromion process. This bursa serves to remove friction and to permit the greater tuberosity of the humerus to rotate inwards under the

Subcoracoid Bursitis. The essential point in the treatment of this condition is the prevention of friction between the two bony points. These patients stand with their bodies relaxed and their shoulders drooping forward, so that to begin with the patient should be made to lie in the recumbent position with a narrow pillow between the shoulders. Hot fomentations will diminish the inflammation, and thereafter postural exercises may be started In persistent cases it may be necessary to excise the bursa. In such cases it is wise also to remove the lateral half of the coracoid process and so prevent recurrence

Subacromial Bursitis. Mild cases of bursitis respond to conservative treatment, consisting of rest with the arm abducted on a splint. Diathermy and massage are helpful in alleviating the inflammation and preventing muscle atrophy respectively. Injection of 10–20 c.c. of ½ per cent. novocaine into the area of the bursa is often permanently helpful. The injection is often very painful and the patient should be lying down while having it In cases which do not respond to this form of treatment, especially if an X-ray picture shows any calcareous deposit, operation is indicated.

A vertical incision is made downwards from the acromion process, and the deltoid exposed lying under its fascia. After division of the latter, the muscle is penetrated by blunt dissection and the bursa opened. Associated lime deposits in the supraspinatus tendon are curetted and removed. The walls of the bursa are removed as thoroughly as possible, and the wound closed. The arm is put up in an abduction splint and conservative treatment continued.

LESIONS OF THE SUPRASPINATUS TENDON

The superior and the posterior portions of the capsule of the shoulder joint are strengthened by the incorporation of the flat expanded tendons of the supraspinatus, the infraspinatus and the teres minor. These tendons form a thick continuous fibrous sheet fused with the underlying capsule of the shoulder joint and separated from the deltoid and the acromion process by the subdeltoid bursa.

The supraspinatus lies superiorly, and forms the roof of the joint, as well as the floor of the subacromial bursa. Complete rupture of its tendon occurs usually in close proximity to the greater tuberosity. The muscle then retracts, leaving a direct communication between the bursa and the joint. The gap between the edges varies from ½ to 2½ inches, but is most commonly about 1½ inches. There are, as a rule, degenerative changes in the intact portion of the supraspinatus, and in the infraspinatus tendon.

In addition to such extensive ruptures it is probable that smaller tears may occur, involving only a few of the tendon fibres These small tears may result in the deposit of calcified nodules in the tendon.

when the shoulder is allowed to droop, the humerus being in consequence moved forwards, medially and downwards. It follows that though this bursa is not particularly exposed to external violence, it is yet distinctly liable to suffer derangement through irritation from the pressure of the lesser tuberosity against the coracoid when the arm is used a great deal. It is not surprising, therefore, to find that persons with round shoulders frequently suffer from shoulder pain.

The patient complains of pain in the region of the coracoid, and there is definite tenderness over the interval between the two bones Late cases, in which adhesions are present, have marked limitation of lateral rotation and abduction. In recent cases relief is obtained when the arm is laterally rotated, and there is a corresponding increase of pain when the humerus is pressed towards the coracoid. A diagnostic injection of 5 c c. of 1 per cent. novocaine into this area may be of considerable help.

The Diagnosis of Shoulder Disabilities

The diagnosis of shoulder disabilities may present great difficulty, and accuracy may be obtained only after the expenditure of considerable time and care It is important to eliminate preconceived impressions and it should be constantly borne in mind that severe disease processes, no matter where they originate, sooner or later involve all the related structures of the joint While it is true that from the point of view of treatment—which does not materially differ in the various lesions—accurate diagnosis is not essential, nevertheless the amount, the nature and the order of treatment are certain to have speedier and more lasting effects if based on a correct conception of the pathology.

The patient's history should be carefully elicited, and too much attention should not be paid to the occurrence of minor traumata, as most persons can recall some previous injury to any affected portion of the body

Every investigation of shoulder symptoms should conclude with a radiological examination of both shoulders, in a position of lateral rotation In this way lesions such as myositis ossificans, loose bodies, and small fractures involving the articular surfaces, will be revealed. But it is also important to X-ray the cervical spine as it is a notable feature that in arthritis of this area the main symptom may be pain in the shoulder region.

The Treatment of Shoulder Conditions

While the treatment will of necessity vary with the cause of the condition, there are several principles which are applicable to almost all shoulder lesions Most of them are improved by being placed in the optimum functional position—i e 75° abduction, with a small amount of lateral rotation It is important to insist on a very gradual return to activity, and in the severer lesions supports should be maintained for four or six weeks.

Etiology

With every abduction movement of the shoulder there is friction and contact of the supraspinatus tendon against the acromion process The subdeltoid bursa from its position minimizes this friction As age advances, however, especially in hard-working labourers, the bursal protection becomes inadequate and degenerative changes occur from the constantly repeated trauma The fibres become worn and a tendinitis occurs As the tendon is avascular calcareous deposits may occur and produce calcification of the supraspinatus. When either of these conditions occurs it is not surprising that a partial or complete rupture may easily occur. A third sequel of the tendinitis is the onset of peri-arthritis resulting from a simple strain plus probably some toxic focus.

(*a*) Tendinitis of the Supraspinatus Tendon.

This symptom complex often follows a history of a minor sprain and the patient comes complaining of pain in the outer aspect of the shoulder and over the deltoid insertion. Occasionally it radiates down the arm to the fingers There is tenderness over the greater tuberosity at the insertion of the supraspinatus tendon Movements are usually not limited but there is an area in the arc of abduction, between 60 and 120 degrees, which is acutely painful, and apparently is at the point where the tender area impinges against the margin of the acromion There is again sharp pain through the same arc from 120 to 60 on adduction from the abducted position There is no abnormality on X-ray. The pain in the middle range of abduction movement is diagnostic of lesions of the supraspinatus In artiritis the pain continues throughout the movement, while in adhesions the pain starts at 75 degrees of abduction and continues to the limit of abduction.

Treatment In the early stages physiotherapy consisting of local heat, massage and pendulum exercises are used If night pain is severe the arm is immobilized with a sling or a circular body bandage while the patient is in bed During the day active use of the arm is encouraged but motoring, lifting, etc., are prohibited. In acute cases recumbent treatment with the arm suspended in abduction is useful

Good results in some cases follow the injection of 10 c.c of 2 per cent novocaine into the painful area Good results are also got from an injection consisting of 50 mg of hydrocortisone in a 2-ml. suspension with the addition of 1,000 units of hyaluronidase to ensure maximum dispersion and contact This may be used along with the novocaine solution The pain is relieved for two hours but recurs usually for a period of four or five hours and then gradually dies away It may be pretty acute when it comes on again and morphia may be necessary If the symptoms are slow in disappearing after this injection short-wave therapy and radiant heat are often helpful

The deposits are probably the result of degenerative changes in the dense avascular fibrous tissue from preceding tendinitis and not unlike that seen in arteriosclerosis. The deposit of lime produces a secondary hyperæmia which may cause absorption of the deposit and also cure the underlying tendinitis.

Treatment

In acute cases, immobilization in an abduction splint for a period of two to three months is associated with disappearance of the deposit and the subsidence of the inflammatory process At the same time massage and short-wave therapy and radiant heat are of considerable benefit. Active exercises are encouraged as soon as possible. Any resulting stiffness of the shoulder may be cured by manipulation.

Removal, complete or partial, or even simple decompression by aspiration and irrigation with normal saline has been used with considerable success Two needles are used, one inserted from the anterior aspect and the other from the lateral aspect They are directed directly into the deposit and salt solution is forced in by syringe through one needle and allowed to escape through the other. No claim is made for the complete removal of the deposit but pain is relieved and function restored in a few days, and absorption of the calcareous material follows within a few weeks Radiotherapy also benefits by relieving pain

The results of surgical excision of the deposits are definite and the relief conferred upon patients with the acute type of symptoms is so immediate and great that there is much to recommend it.

The mass may be too thick to be removed by aspiration though this may be tried first The tendon is exposed by an anterior incision, and the deposit removed by a sharp spoon. The underlying tuberosity should be incised, and the cheesy deposit contained in it evacuated, the walls of the resulting cavity being broken to facilitate the filling up of the dead space There is immediate and quick relief from the pain and full active exercise can be practised at once. In severe cases with a large deposit of calcium acromionectomy has been carried out. In this way compression of the calcium mass is prevented and abduction of the shoulder

(c) Incomplete Rupture of the Supraspinatus Tendon.

An incomplete rupture of the tendon is a common sequel to tendinitis, though often not diagnosed. It is said to occur in no less than 30 per cent of all cadavers.

Pain is complained of over the shoulder and this radiates down the circumflex nerve to the deltoid insertion. Tenderness is present over the insertion of the tendon Abduction is usually possible though there is pain at a certain stage when the torn fibres impinge under the acromion. This is usually at 90 or 100 degrees Abduction can easily be prevented by resistance. With a greater degree of tearing abduction may become impossible. Scapulo-humeral abduction is reversed in

that the scapula abducts on the chest wall before shoulder movement commences

Immobilization in an abduction splint is tried in the early stages and continued for some six to eight weeks. If no improvement is produced the tendon is exposed by operation and the tear dealt with as in the complete rupture. If there is little evidence of a tear the subdeltoid bursa is fully explored and any hyperæmic fringes and the bursal wall removed. If nothing more than tendinitis is found the tendon is scarified to produce revascularization, and this usually relieves the symptoms.

(*d*) Rupture of the Supraspinatus Tendon.

The actual tear may be associated with only slight pain, but there is immediate weakness of the arm and the patient is unable to abduct the shoulder. Occasionally a definite "crack" in the shoulder accompanies the pain at the moment of injury. Localized tenderness can be elicited over the tip of the greater tuberosity, or just medial to it, but it disappears when the arm is abducted, since the tuberosity then passes beneath the acromion. Attempts at active movement may be accompanied by coarse crepitation in the region of the bursa, and by a characteristic "abduction" syndrome. The supraspinatus initiates abduction by fixing the head of the humerus against the glenoid cavity. Thereafter the deltoid assumes control and completes the movement. After complete rupture, the patient cannot voluntarily perform the first fifteen degrees of abduction, but can complete the movement if the first stage is performed for him. When the tear is slight and incomplete full abduction may be possible, though the early phase is attended by considerable weakness. The initial attempts are painful, but the pain, like the tenderness, disappears when the tuberosity is carried beneath the acromion, only to reappear as the arm is brought down from the abducted position

When the patient is inspected as he stands with his arms at the sides and elbows pulled backwards, the tuberosity of the humerus may appear unduly prominent on the injured side and a sulcus may be seen proximal to the tuberosity where the tendon should be In the sulcus there is usually a tender spot which rotates with the humerus and disappears under the acromion when the humerus is abducted.

Diagnostic signs are produced as the arm descends from the upright position. Lowering to a right angle is painless, since it occurs between the scapula and the chest The rest of the movement—at the shoulder joint proper—causes acute pain, and, the shoulder muscles suddenly relaxing, the arm drops to the side, the patient wincing with pain.

Another sign is evident when both arms are elevated—a change in contour of the deltoid region on the affected side due to an alteration in the folds of the skin between the shoulder and the neck, caused by joint fluid being driven into the subdeltoid region owing to the tenseness of the lower portion of the capsule.

Diagnosis

The diagnostic sign is a greater limitation of active than of passive abduction in the presence of a normally contracting deltoid Abduction cannot be carried out by the deltoid alone; the supraspinatus is an essential synergist If the supraspinatus is inactive strong contraction of the deltoid pushes the humeral head up towards the acromion and holds it there while the scapula rotates Scapular movement accounts for some 50 degrees of abduction, but there is no true abduction at the shoulder joint The deltoid can be felt strongly contracting thus excluding circumflex paralysis, and since passive movement is possible adhesions cannot be the cause. The wince of pain at 90 or 100 degrees abduction as the limb is raised or lowered passively, and the tenderness on pressure over the insertion of the supraspinatus clinch the diagnosis

Codman describes certain conditions, symptoms and signs which indicate complete rupture of the supraspinatus tendon and which should be present within twenty-four hours after the accident—

(1) Occupation—labour.
(2) Age—over 40
(3) No symptoms in shoulder prior to accident.
(4) Adequate injury—usually a fall.
(5) Immediate sharp, brief pain
(6) Severe pain on following night.
(7) Loss of power in elevation of the arm.
(8) Negative X-ray
(9) Little, if any, restriction when stooping.
(10) Faulty scapulo-humeral rhythm.
(11) A tender point,
(12) a sulcus, and
(13) an eminence
(14) at the insertion of the supraspinatus,
(15) which cause a jog,
(16) a wince and
(17) soft crepitus as the tuberosity
(18) disappears under the acromion when the arm is elevated, and usually also as it reappears during descent of the arm.

Treatment.

Codman says if the above syndrome is present he feels that "not only is exploration indicated but that it should be strongly urged, *for immediate suture should be a simple and successful operation Delay means retraction of the tendon and a much more serious problem.*"

The ruptured tendon should be repaired by operation unless the tear is too small to disturb the function of the joint or the general condition of the patient is such as to render an anæsthetic dangerous

The arm is in such cases immobilized in an abduction frame with

the arm abducted 90 degrees and laterally rotated 60 degrees for about four to six weeks

The Operation. The bursa and tendon are explored through a 5-inch incision which extends downwards from the acromio-clavicular joint and separates the deltoid fibres.

In view of the herring-bone connection of the fibres of the deltoid it is easier to approach the shoulder joint between the deltoid and the pectoralis major, elevating part of the deltoid from the acromion to get access. After the bursal cavity is entered, the under surface of the acromion may be inspected if the wound edges are strongly retracted and the arm pulled down. By rotating the arm the tuberosities with their attached tendons can now be examined. When the tendon is ruptured, a gap is present in the capsule through which the articular cartilage of the head of the humerus is visible. The humerus is abducted to approximate the torn fibres and several mattress sutures of very strong chromic gut or silk are used. The broad band of supraspinatus tendon is stitched to the tuberosity itself through which the heavy needle employed is passed after six or seven drill holes have been made in its outer furrow so that cutting out from the short distal fibres is avoided. An abduction splint is worn for four to six weeks until the patient can lift and hold the arm.

Peri-articular Adhesions.

This condition, usually called a frozen shoulder, accounts for more cases of shoulder disability than does supraspinatus tendinitis in the proportion of three to two It affects males usually and at a slightly older age than the tendinitis The symptomatology is so characteristic that there is no doubt that this is a separate disease entity.

The patient is usually not seen until the condition is well established. He generally gives a history of having noticed a slight painful catch in the region of the shoulder and upper arm for several months Gradually he has become aware of an inability to perform certain tasks or to participate in certain sports because of stiffness of the arm. Night pain, often wakening him after he has fallen asleep, is a common complaint. Frequently it radiates down the arm to the hand but without being localized to any nerve distribution. Stiffness of the shoulder increases until all movement may be lost. The course of the disease is variable and while in many the symptoms may abate within two years, in many it continues indefinitely

On examination there is a generalized sensitiveness about the shoulder and marked restriction of abduction and rotation, with pain if force is used. The X-ray examination is negative.

This is one of the least understood syndromes causing pain in the shoulder De Palma has recently thrown new light on the condition and considers that bicipital tenosynovitis plays an important part This tenosynovitis has long been known—usually following a strain injury—and it responds usually to conservative treatment. De Palma

Diagnosis

The diagnostic sign is a greater limitation of active than of passive abduction in the presence of a normally contracting deltoid. Abduction cannot be carried out by the deltoid alone; the supraspinatus is an essential synergist. If the supraspinatus is inactive strong contraction of the deltoid pushes the humeral head up towards the acromion and holds it there while the scapula rotates Scapular movement accounts for some 50 degrees of abduction, but there is no true abduction at the shoulder joint. The deltoid can be felt strongly contracting thus excluding circumflex paralysis, and since passive movement is possible adhesions cannot be the cause. The wince of pain at 90 or 100 degrees abduction as the limb is raised or lowered passively, and the tenderness on pressure over the insertion of the supraspinatus clinch the diagnosis

Codman describes certain conditions, symptoms and signs which indicate complete rupture of the supraspinatus tendon and which should be present within twenty-four hours after the accident—

(1) Occupation—labour.
(2) Age—over 40.
(3) No symptoms in shoulder prior to accident.
(4) Adequate injury—usually a fall
(5) Immediate sharp, brief pain
(6) Severe pain on following night
(7) Loss of power in elevation of the arm.
(8) Negative X-ray
(9) Little, if any, restriction when stooping.
(10) Faulty scapulo-humeral rhythm
(11) A tender point,
(12) a sulcus, and
(13) an eminence
(14) at the insertion of the supraspinatus,
(15) which cause a jog,
(16) a wince and
(17) soft crepitus as the tuberosity
(18) disappears under the acromion when the arm is elevated, and usually also as it reappears during descent of the arm

Treatment.

Codman says if the above syndrome is present he feels that "not only is exploration indicated but that it should be strongly urged, *for immediate suture should be a simple and successful operation Delay means retraction of the tendon and a much more serious problem*"

The ruptured tendon should be repaired by operation unless the tear is too small to disturb the function of the joint or the general condition of the patient is such as to render an anæsthetic dangerous

The arm is in such cases immobilized in an abduction frame with

the patient is able to restore it himself. The recurrences may eventually occur at intervals of a few weeks, and may be accompanied by relatively few symptoms Nevertheless, the ever-present danger from falls, and the disabling effect of the dislocation on work and play, call for active treatment. The derangement occurs most frequently in athletes and in epileptics, between the ages of 20 and 30 years.

In the great majority of cases the initial injury produces a detachment of the glenoid labrum and the capsule from the anterior aspect of the glenoid and the displaced head thereafter strips the periosteum from the front of the neck of the scapula. Thereafter, with recurrences of the displacement of the head, a defect is produced in the postero-lateral aspect of the articular surface of the head of the humerus. This is of the nature of an impaction fracture produced on the head by its contact with the anterior margin of the glenoid. This is visible on an X-ray taken with the arm in internal rotation of about 50–60 degrees. It has then the appearance of a groove or depression at the upper and outer margin of the shadow of the humeral head. The detachment of the glenoid capsule and periosteum is said to occur in over 80 per cent. of cases while the bone defect is slightly less common. Some authorities believe that the bone defect is the cause of the recurrent dislocation without any soft tissue detachment. It is likely that whatever the ultimate lesion one of the principal factors in the production of a recurrent dislocation is imperfect immobilization of the original injury after its reduction. After reduction of the initial injury the shoulder should be completely immobilized in the position of full internal rotation and adduction for not less than four weeks. There is no reason to suppose that the actual injury in the recurrent case is any different from that in the one which afterwards remains stable.

Symptoms

The dislocation eventually becomes almost painless, but many of the patients acquire a morbid, exaggerated dread of recurrence. Considerable muscular atrophy may be detected, particularly in the brachialis, the triceps, the deltoid and the supra- and infraspinatus.

Treatment

After recurrence it is unlikely that any treatment other than operative will suffice If operation is contra-indicated or refused, an appliance consisting of a chest belt and an upper arm band, fixed together by a small leather strap, may give relief. This prevents abduction, which is the primary cause of the dislocation, and it should be worn day and night At night it may be more comfortable to stitch the sleeve of the pyjama coat to the body portion.

Operative Treatment.

Treatment by operation is advisable once the condition has become established.

believes that it occurs more commonly than is thought and, as he has operated on 42 cases, it must be at least not uncommon

The clinical picture which De Palma describes resembles what is commonly known as subacromial bursitis, or even peri-arthritis of the shoulder The onset may be insidious but sometimes it is precipitated by strenuous activity Pain starts at the front of the shoulder and usually radiates to the deltoid insertion. There is tenderness over the groove containing the tendon. Most of the cases are cured by a period of rest but a number of the older patients, however, are not so fortunate De Palma operated on 42 such patients and found in each case that every tissue around the shoulder was implicated in a low-grade inflammatory process. This inflammatory process was of varying intensity and involved the gliding mechanism of the tendon The adhesions within the sheath ranged from filmy, frail hæmorrhagic adhesions to firm, dense bands of fibrous tissue binding the tendon firmly to the bicipital groove and to the under surface of the rotator cuff. He considered that the most significant of these findings was the involvement of the gliding mechanism of the biceps tendon and that this involvement was the agent responsible in a large measure for the pain This conclusion was reached because pain was most prominent when the adhesions were loose and friable In such cases there was dramatic relief when the gliding mechanism of the tendon was obliterated at operation. Pain also is relieved when the tendon becomes firmly attached to bone by strong fibrous adhesions It is suggested also that in these cases where there is a sudden cessation of symptoms this occurs because the tendon ruptures

Treatment No manipulation or forcible passive exercise is permitted in the early stages but active exercises are practised under supervision. Massage, radiant heat, and short-wave therapy are helpful, but much less important than active exercises, which should be practised frequently throughout the day These are best carried out in recumbency or in the stooping position.

De Palma treats those patients who fail to respond to conservative treatment by operation He transplants the tendon from its normal insertion to the coracoid process The operation is followed by relief of pain and, with exercises subsequently, movement gradually returns to the shoulder The relief of pain allows movement and muscular activity so that the blood supply is increased and the inflammatory lesion allowed or encouraged to subside

RECURRENT DISLOCATION OF THE SHOULDER JOINT

A patient who periodically dislocates the shoulder joint is considerably handicapped. The limb loses much of its power and efficiency, and each recurrence is so disturbing that the individual lives in constant dread With each dislocation less and less force is required, and whereas at first reduction necessitates the aid of a surgeon, later on

Three of the types of operation commonly in use are described here.

(1) The Bankart Operation. Bankart believes that since the dislocation is due to the wide detachment of the glenoid ligament from the anterior margin of the glenoid cavity the operation should be directed to the repair of this defect

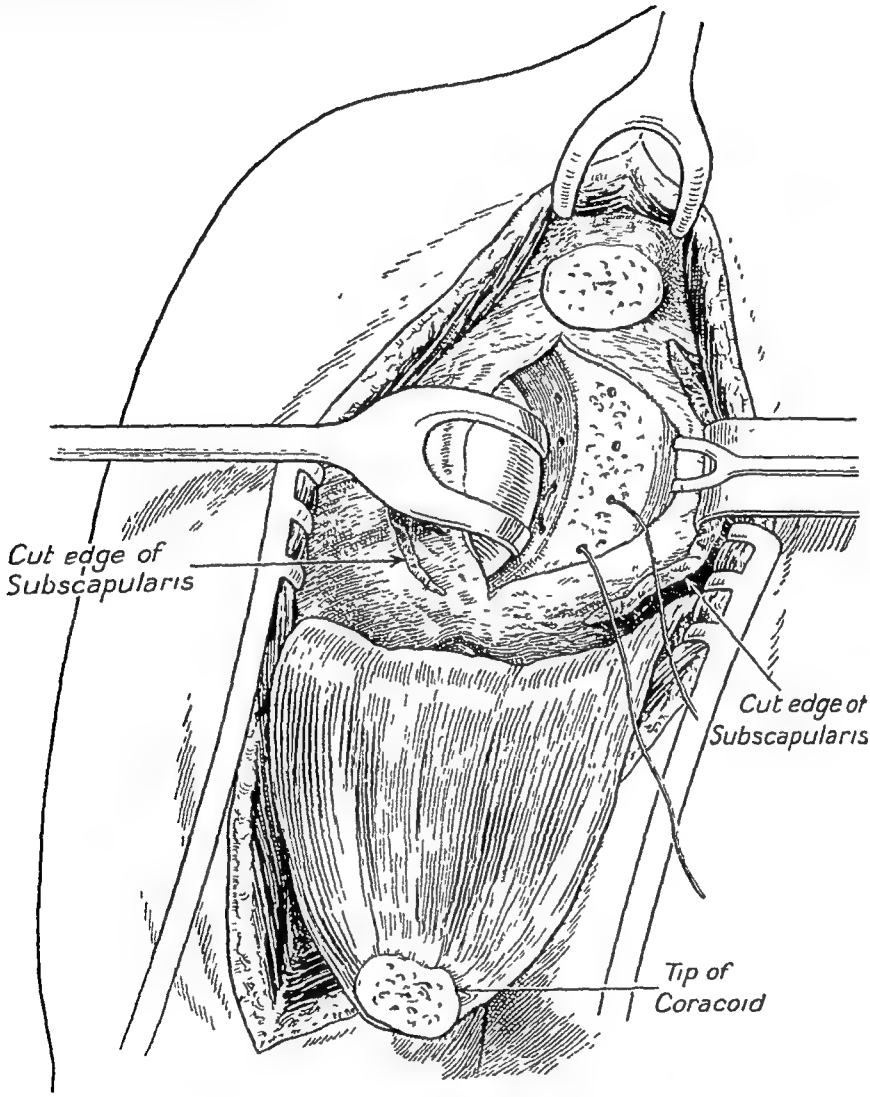

FIG 332 —The Bankart Operation.

The incision is made from the clavicle above the coracoid and extends for 5 inches down the anterior border of the deltoid muscle This muscle is separated from the pectoralis major, avoiding the cephalic vein and exposing by retraction the coracoid and the muscles inserted into it. The coracoid process is now divided with an osteotome in a downward direction and its tip and the attached muscles displaced downwards. On lateral rotation of the humerus the subscapularis is exposed and its tendon divided about $\frac{3}{4}$ inch from its insertion into the lesser tuberosity Not infrequently this incision divides the capsule too. The

was passed under the flexed elbow and tied over a pad placed on the acromio-clavicular joint

If these immediate measures are unsuccessful, and the dislocation recurs, operative treatment should be considered. It is rather doubtful if the operation is worth the patient's time and trouble, for even with a permanently dislocated acromio-clavicular joint the eventual disability is not very great. If operation is undertaken it is necessary to fix the clavicle to the coracoid process, for it cannot be fixed to the acromion sufficiently strongly. The ideal material for binding these bones is fascia, as it is a natural binding agent, hypertrophies under conditions of normal tension, allows normal motion in the joint, and "lives" as long as the patient.

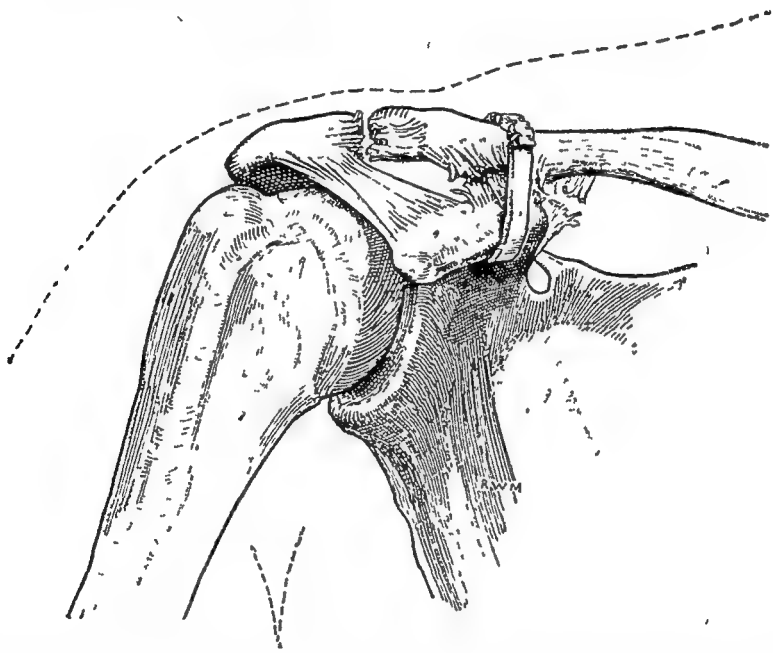

FIG 333 —Stabilizing Operation for Acromio-Clavicular Dislocation Fascia is used and after insertion is tightened and the two ends sutured together

The joint is exposed by a semi-lunar incision, with its convexity forward The coraco-clavicular ligaments are now reconstructed by means of fascia lata The upper surface of the clavicle immediately above the coracoid is denuded of periosteum and the coracoid exposed sufficiently to allow a loop of fascia to be passed round it. One end of the loop goes behind the clavicle, the other in front The dislocation is now reduced by pushing the arm upwards, i e pushing the coracoid up towards the clavicle, and while the reduction is maintained by means of braided silk round the coracoid and clavicle, the loops of fascia are united by means of braided silk. In this manner the clavicle is held firmly in position A plaster-of-Paris cast is now applied while the involved shoulder is held as high as possible to relieve the strain on the repaired ligament The cast extends from the iliac crest up to the axilla

in the same way as in Bankart's operation. The glenoid and the anterior joint capsule are inspected from within. A subperiosteal pocket is made with a raspatory just medial to the glenoid and an osteotome is used to make a small trench to receive a bone graft. The osteotome is introduced just medial to the glenoid and in such a direction that the graft will project in a direction to deepen the glenoid socket It is therefore directed backwards and inwards. A triangular graft $\frac{3}{4}$ inch broad and $\frac{3}{4}$ inch deep is cut from the inner aspect of the iliac crest This is punched home till it is firm and the wound closed in the usual way. Similar post-operative treatment is carried out.

Choice of Operation. The author usually does the Bankart type of operation unless the defect leaves the labrum attached to the glenoid, in which case a simple re-attachment operation is used In carrying out the Bankart reconstruction the distal end of the subscapularis is stitched along with the capsule to the glenoid rim and the proximal muscular belly is overlapped as in the capsulorrhaphy In the subluxable—often voluntarily so—type of case occurring in young adolescents a bone block is carried out.

RECURRENT DISLOCATION OF THE ACROMIO-CLAVICULAR JOINT

The clavicle may be dislocated either upwards or downwards at the acromio-clavicular joint, the upward dislocation being more common on account of the slope of the joint surfaces The displacement results from a blow on the back of the acromion, or from a fall on the tip of the shoulder It is thus a common football injury, but since it is as a rule incomplete, it rarely requires treatment, as spontaneous reduction usually occurs. When the upward dislocation is complete, the acromio-clavicular ligament and the conoid and trapezoid ligaments which hold the clavicle down to the coracoid, are ruptured and the lateral end of the clavicle slides upwards and projects As a result there is considerable deformity, some difficulty in lifting the arm, and limitation of certain of the shoulder movements The condition is recognized by the nature of the causative injury, by the well-marked projection in the region of the joint, by the localized tenderness over the joint, by the pain elicited in the same situation when the shoulder is moved, and by an X-ray picture.

If reduction has not occurred spontaneously, it can be secured easily by raising the arm and by manipulating the joint The reduction, however, though easily obtained, may be difficult to preserve, especially if coraco-clavicular ligaments are ruptured The best immediate measure is by means of a brachio-clavicular sling Broad strips of adhesive plaster are passed round the elbow and over the top of the shoulder, medial to the acromio-clavicular joint, the strips being joined by a piece of strong elastic tubing The wrist is supported by a separate bandage sling This method is really a modification of an old one whereby a sling

bones are exposed. A flake of bone about half an inch long is raised by a periosteum elevator from in front of both bones and turned downwards After the insertion of the sterno-mastoid is freed the posterior aspect of the joint is exposed by blunt dissection and protected by a broad spatula while two holes are drilled in an antero-posterior direction through both bones. A strip of fascia lata is now threaded through the

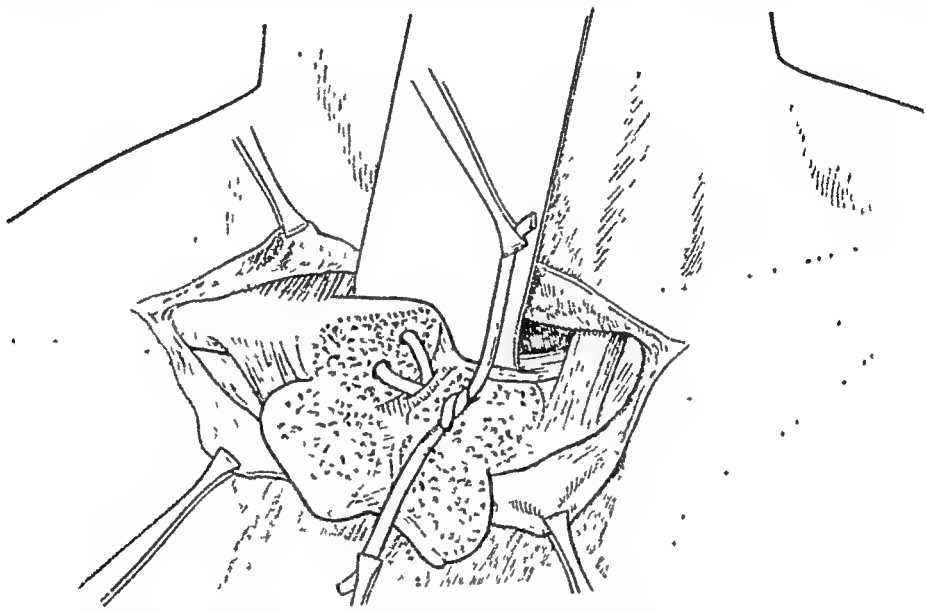

Fig 334 —The Bankart Operation for Recurrent Dislocation of the Sterno-clavicular Joint.

clavicular holes from behind, leaving the two loose ends in front. These ends are now taken through the joint in a backward direction and brought through the sternal holes from back to front. The dislocation is now reduced and the fascia pulled tight, tied in a single knot stitched with linen thread and then the reef knot in the fascia completed. By further linen sutures and replacement of the bone flakes a secure fixation is obtained. The arm is kept bandaged to the side for one month.

DISLOCATION OF THE BICEPS BRACHII

This condition has been recognized since the time of Hippocrates. The tendon is retained in position mainly by the attachment of the articular capsule in the region proximal to the lesser tuberosity and by the medial ridge of the bicipital sulcus which is often very deep. Meyer does not believe that the transverse ligament is important in retaining position. The capsule of the joint may stretch and allow the tendon over the lesser tuberosity and, since the tuberosity is rough, wear of the tendon and even rupture may occur. A localized osteitis reduces the volume of the lesser tuberosity and favours luxation. It is probable that violent muscular action may dislocate the tendon. When the tendon slips over the lesser tuberosity the tension of the

on both sides and includes the arm and forearm on the affected side It is removed in six weeks and full function should be restored in three months Watson-Jones suggests screwing the clavicle and the coracoid together with a vitallium screw This is probably most effective in the recent injury In the old painful unreduced case excision of the outer end of the clavicle relieves the pain, especially if there is any secondary arthritis

DISLOCATIONS OF THE MEDIAL END OF THE CLAVICLE

Dislocations of the medial end of the clavicle are rare, as the bone breaks easily and the ligaments supporting the articulation are strong. In particular, the rhomboid ligament (costo-clavicular ligament) stretching from the clavicle to the front of the costal cartilage is very strong, and resists the tendency of the clavicle to slip upwards, medially and forwards, in the line of slope of the joint cavity. The dislocation is usually an anterior and medial one on this account, and when complete there must be rupture of the costo-clavicular ligament Subluxation may occur if the capsule and ligaments stretch without completely breaking

Posterior dislocation may be caused by direct violence, but is fortunately rare, as the displaced clavicle in this case may injure the large vessels in the superior mediastinum

Subluxation can usually be reduced by direct pressure over the clavicle, while the shoulder is simultaneously pulled upwards and outwards It is difficult to maintain the reduction, but it may be retained with a figure-of-eight bandage round the shoulder and large axillary pads to act as a fulcrum for the weight of the arm to produce distraction. This treatment, in the case of a complete dislocation, should be kept up for four to six weeks to allow the avascular ligament to heal

In the posterior dislocation manipulation is usually ineffective, and the reduction must be made by open operation, the clavicle being replaced by the use of some form of lever. In this case some means of fixing the clavicle must be employed Thin metal or fascial sutures may be used, or the meniscus may be stitched to the front of the capsule, or the clavicle to the first costal cartilage The author favours the use of fascia lata employed as a mattress suture after parallel tunnels have been drilled in the sternum and the clavicle.

If a recurrent anterior dislocation causes severe symptoms, which is unusual, a similar type of operation may be employed, or the clavicle may be sutured to the first costal cartilage by a loop of fascia lata in a similar way to that employed in recurring acromio-clavicular dislocation. In this method the fascial suture replaces the ruptured costo-clavicular ligament

Bankart has described an operation which he states has been very successful in his experience By means of a four-inch incision along the inner end of the clavicle and over the sternum the dislocated

these fibres to ride over the lesser tuberosity. Removal of a part of this muscle, which apparently corresponds to the rotator humeri of lower mammals, was followed by a cure. The two subluxating cases were cured by a bone-block operation as done for the recurrent type of dislocation. In the cases due to a muscular error the tendency is for the symptoms to diminish and be ultimately abolished.

SNAPPING SCAPULA

Scapular grating or snapping, the expression of some anomalous condition between the ribs and the under surface of the scapula, is a tactile-acoustic phenomenon which has been observed in varying intensity in different persons. In some there may be a loud snap, while in others there is only a fine grating barely perceptible to the touch. It appears that the causes of these sounds may be divided into three main groups:

(*a*) those due to changes in the bony structure of the under surface of the scapula or of the wall of the chest,

(*b*) those due to changes in the musculature intervening between the scapula and the wall of the chest;

(*c*) those due to changes in bursæ normally or abnormally present between the scapula and the wall of the chest

A. Bone Causes. In the category of cases due to changes in the bony structure of the scapula or the chest, a number of sub-groups has been denoted:

1. The tubercle of Luschka—a small bony or fibro-cartilaginous elevation located in the anterior aspect of the superior angle of the scapula, at its largest the size of a pea, usually covered by a bursa, was first described by Luschka. It appears to be a matter of doubt whether this is ever a cause of scapular snapping.

2. Abnormal curvature of the superior angle of the scapula This is apparently of congenital origin

3. Scapular snapping has been noted in the presence of exostoses on the ribs or on the under surface of the scapula The exostoses may be found either at the superior or inferior angle of the scapula, and may vary in size from osteo-cartilaginous nodules to relatively large mushroom-shaped masses.

4. Tumours of the ribs or scapula, fracture of either, angulation or buckling of the ribs, are all possible causes in the osseous group

B. Muscular Causes. The second main group is that associated with changes in the muscles lying between the scapula and the ribs. Voelcker suggested that a lesion in the muscles similar to tendonitis crepitans might be responsible for this type of snapping

C. Bursal Causes. The third main group is that in which scapular snapping has been attributed to the presence of normal or adventitious bursæ. Normally two are present beneath the scapula; one at the

muscle is immediately lessened and the classical bicipital syndrome results

The symptoms in most cases are similar to those of a ruptured biceps tendon and the onset is acute. There is pain in the region of the bicipital groove which may radiate down the muscle. The pain is increased on external rotation and overhead extension while weakness in the arm is marked and function impaired The muscle belly is flabby and lower than the normal position. It is unusual to be able to palpate the empty groove, but a change in direction of the tendon is more easily detected. If the onset has been gradual or the slip is only slight the symptoms and signs are not very striking

Diagnosis is not always easy, but in any disability of the shoulder brought on by a sudden movement or by movement of external rotation and overhead extension, and continued over a long time, the possibility should be considered. The patient can often produce the dislocation by bringing his extended arm to overhead extension and external rotation holding a 5 lb weight in each hand The observer puts his finger on the tendon and may feel the snap and often hear it. It is like a taut violin string that snaps as it slips into the groove of the bridge

To reduce a dislocated tendon Gilchrist suggests that the extremity, with the elbow bent and the forearm supinated in order to relax the tendon, should be abducted passively and gently in the correct plane to 90 degrees or more, brought forward, and simultaneously rotated internally. He says the surgical repair varies with the findings If possible the structures round the groove should be repaired and the groove deepened An easier procedure and a satisfactory one, he says, is to repair the tear in the structures round the groove after severing the tendon of the long head as high in the joint as possible and then to suture this tendon to the coracoid process and to the tendon of the short head

SNAPPING SHOULDER

An audible click or snap may be produced by certain movements of the shoulder joint It may be the result of a voluntary subluxation of the shoulder joint, or be due to a tendon slipping over a bony prominence, e g the short tendon of biceps over the lesser tuberosity. The sound occurs usually when the joint is voluntarily brought to an abnormal position and in two recent cases the head of the humerus subluxated on to the edge of the glenoid, pulled there apparently by the pectoralis major. The phenomenon may ultimately become habitual or involuntary. Sometimes the patient can reproduce the condition on request, and, following the audible snap, the shoulder is immediately painful. Bristow has reported a case in which he found abnormal muscular fibres arising from the lateral side of the short head of the biceps, and passing downwards and laterally towards the long head. He was able to demonstrate at operation that abduction and rotation of the arm caused

There also exists a group of cases in which a previous toxi-infectious malady has been followed by serratus paresis; in this group are cases following typhoid, measles, influenza, and an injection of anti-tetanic serum. It is interesting that practically all instances of this type have affected the right scapula.

The earliest symptom is pain along the base of the neck and downward over the scapula and deltoid. It may be that the severity of the pain is of value in making a differential diagnosis as trauma to the muscle produces a more severe type of pain than that seen with involvement of the nerve alone. The second most common symptom is the patient's fatigue on elevating the arm or the inability fully to do this The weakness may pass unnoticed by the patient himself. The third symptom is the abnormal prominence of the scapula, a sign more frequently noticed by others than by the patient himself The time of onset of the pain is usually immediately after acute trauma, but is variable in the toxic and repeated minor trauma cases. Weakness of abduction only begins at once when the cause is acute trauma

On examination of the patient the principal clinical observations are weakness of the pushing power of the affected shoulder and weakness of abducting power of the arm above the horizontal plane. Winging of the scapula is always present when the arm is fully abducted or is elevated anteriorly. Some winging also occurs in many instances in which the arm is pendant Tenderness may be present over the course of the long thoracic nerve, the maximal point being the mid-axillary line in the fourth intercostal space. The affected scapula is nearer the mid-line and may overlap the vertebral column when the arm is abducted. In trapezius paralysis the scapula is further from the mid-line.

Treatment may be conservative or operative. Various types of conservative measures are tried first, such as constant immobilization with the arm held by a plaster shoulder spica case so as to relax the muscles, and physiotherapy, such as heat, massage and galvanic stimulation. This form of treatment may be continued for three months but is unlikely to be successful after that period The best position for the arm to be fixed in plaster is abduction and external rotation, with backward displacement of the shoulder girdle, so holding the scapula close to the thoracic wall No mechanical appliances, however, are adequate to take the place of the serratus muscle Heavy muscular effort should at this time be avoided

Operative Treatment. Some method of anchoring the scapula seems to be the best method of relieving the symptoms. Various methods have been suggested Whitman treated his cases by four strips of fascia used to sling the scapula to holes drilled in the spinous processes of the fourth to the seventh dorsal vertebræ Hass reported a good result from transplanting the teres major muscle to the digitations of the serratus, while a similar result has been got by using a portion of the pectoralis major muscle.

upper angle, situated in the depth of the serratus anterior muscle, is present in about one in every eight persons The other, somewhat rarer, is found in the connective tissue between the serratus anterior and the upper part of the lateral wall of the chest

Hendriks reported a case in which he believed the sound was caused by an inflammation in one of the sub-scapular bursæ, while Jacoby reported a case in which the X-ray picture showed two irregular shadows beneath the level of the scapular spine.

For the most part only conservative treatment need be instituted, but when there are definite bony changes, for example excessive forward bending of the scapula and exostoses, surgical removal of the offending part should be undertaken.

WINGED SCAPULA

Unusual winging of the scapula is a deformity which is fairly well recognized as secondary in some instances to paralysis of the serratus magnus muscle, though some authors favour the view that the disability is due to a traumatic rupture of the muscle at its scapular insertion.

The serratus anterior arises from the lateral surfaces of the upper eight ribs a short distance in front of the mid-axillary line Its fibres pass backwards closely applied to the chest wall and are inserted into the ventral aspect of the medial border of the scapula but mostly to the inferior angle.

The long thoracic nerve arises from the fifth, sixth and seventh cervical nerves, the upper two piercing the scalenus medius, and the seventh root passes in front of this muscle. The three roots unite at the level of the first rib to form a single trunk which descends along the inner wall of the axilla behind the brachial plexus and axillary vessels and upon the lateral aspect of the serratus to which it is distributed.

The function of the serratus anterior is mainly to aid in fixing the scapula to the thorax when the arm is elevated, particularly anteriorly, and also to rotate the scapula in abduction and during forward elevation of the arm at the shoulder

The nerve is liable to damage : (1) in the supra-scapular region from sudden or protracted trauma, e g the carrying of heavy weights on the shoulder ; (2) in the axilla from direct force , (3) at the level of the union of the three roots, from abnormalities of the first rib ; (4) from violent contractions of the scalenus medius muscle, as in swimming, a vigorous swing at a punching bag which misses, a violent pull up when hand-starting a car, or the excessive use of muscular movements of the arm, as after prolonged elevation of the arms such as from painting a ceiling or hanging from a cross bar ; and (5) possibly in the axilla from the pressure of enlarged lymphatic glands Winged scapula may also occur from a fall on the shoulder girdle. It is supposed that such a fall would force the coracoid process against the underlying first or second rib and thus injure the intervening long thoracic nerve.

is normal, there are no constitutional upsets, and sensory changes are present.

Prolapsed disc usually affects only one root. The profound weakness and atrophy of the shoulder-girdle syndrome do not occur, however.

Localized paralysis and wasting of muscles are not features of brachial neuritis.

Progressive muscular atrophy may be excluded because of the acute onset with pain, the rapid development of wasting, the absence of fasciculation, and the non-progressive course of the disease, as well as by the sensory changes that are often present.

The prognosis of cases seen in the early stages is as difficult as in anterior poliomyelitis, and similar principles apply.

Treatment. No specific treatment for the condition is known and it may be treated as poliomyelitis, with analgesics, and splints to rest the muscles. It is important to put the shoulder joint through its full range of movements at least twice a day to prevent stiffness. Where a reaction of degeneration occurs galvanism is used to maintain the muscle

Etiology. This apparently remains obscure. A virus has been suggested but the absence of constitutional symptoms seems unlike that A similar condition has been known for a long time as a result of a serum injection, and it is probable that there is a condition allied to urticaria, resulting in a perineural œdema of the affected roots and nerves comparable to the urticaria of serum sickness.

PROTRUSION OF THE CERVICAL INTERVERTEBRAL DISC

Anatomy and Pathology

The anatomy and pathology of cervical intervertebral discs is similar to that of lumbar disc herniations and to avoid repetition the reader is referred to the description of anatomo-pathology on page 742. The factors peculiar to the cervical region are outlined here.

The principal differences between the lumbar and cervical regions in relation to protrusions are those of contents and function. The cervical spine functionally is more subjected to strains of mobility than to those of weight-bearing These strains are greatest at its lower part, consequently disc herniations are commonest at C5–6 and C6–7 levels. The cervical canal, though quite capacious, contains a relatively immobile and thick cord anchored to meninges by the denticulate ligament and to some extent by the short, almost transversely running nerve roots These roots pursue their short horizontal course outside the thecal sac—though still intradural—into the intervertebral foramina, clinging quite closely to the vertebral bodies at the level of the intervertebral discs, and add to the relative fixation of the cord and its coverings The antero-posterior diameter of the intervertebral foramina in the lower cervical region is fairly small, and may be narrowed still further by any arthritic changes in the interarticular joints and also in the joints of

NEURALGIC AMYOTROPHY

(The Shoulder-Girdle Syndrome)

Parsonage and Turner have recently described a syndrome comprising pain and flaccid paralysis of the muscles round the shoulder girdle, occurring frequently during the last war, though apparently previously it had been rare They describe 136 cases, and quote in the literature several articles where cases have been described under different names. Most of the cases show some precipitating cause Many of them have been in hospital with other conditions, some of them for simple operations, others have been in hospital with infections Some have had serum injections and, in a few cases, there is a history of trauma.

Symptoms The onset is usually not accompanied by any constitutional symptoms whatever. Pain locally is almost always the presenting symptom. The pain is localized across the back of the scapula and may go down the arm or up into the neck. It is generally a constant severe ache, and lasts from a few hours to fourteen days Thereafter it appears to stop fairly suddenly and muscular paralysis then appears There appears to be no relationship between the position of the pain and the distribution of the subsequent paralysis

A striking feature of the syndrome is the rapid development of muscle weakness after the variable period of pain. The weakness is usually maximal at the outset, but in a few cases it may increase for two or three days The weakness is of the lower motor neurone type, with flaccidity of the affected muscles, and often rapid wasting Fasciculation is never seen Bilateral cases occur but there is usually an interval between the involvement of the two sides The muscles involved show that in many cases the pathological process is in one or more peripheral nerves, while in others it must have been in the nerve root In some cases, however, a lesion in the spinal cord must be assumed

The nerves frequently affected are the long thoracic, the suprascapular, and the circumflex The common nerve roots to be affected are the fifth and sixth cervical, with weakness of the spinati, deltoid, biceps, supinator longus, and at times the clavicular head of the pectoralis major; impairment of the biceps and supinator jerks; and sensory impairment over a strip on the outer side of the arm and forearm. Both anterior and posterior roots are therefore involved.

In a high proportion of cases there was patchy muscle wasting and weakness not corresponding to a nerve or nerve roots, and a spinal-cord involvement was assumed Practically every muscle in the arm may be involved, together or separately Sensory changes occur in half the cases The cerebro-spinal fluid is normal, as are the X-ray pictures.

Differential Diagnosis The differential diagnosis of this condition will exclude anterior poliomyelitis, prolapsed disc, brachial neuritis, and progressive muscular atrophy

Anterior poliomyelitis may be excluded from the fact that the C S.F

for instance, in the sudden stoppage of a vehicle or the head-on collision of motor-cars.

The syndrome of the cervical herniation producing cord compression, or the mixed syndrome of cord and nerve root, especially if the root symptoms are masked or occur secondarily, need not be fully considered here, the subject being without the scope of this book and concerning primarily the neurologist or neuro-surgeon It should be stressed, however, that one ought to be on guard against the possibility of the development of cord compression in all cases of cervical disc protrusion.

In the majority of cases the protrusion, being laterally placed, produces symptoms and signs of nerve root involvement—C6 and C7 being commonest The pain is the predominant symptom, but unlike the lumbar disc herniations, some motor loss is frequently noticed by the patient and in the great majority can be substantiated clinically.

The onset may take the form of neck stiffness with or without an ache on head movement In others, pain referred to the shoulder girdle may precede pain in the neck, and in any case sooner or later the pain in the shoulder or arm overshadows the pain in the neck Less often, paræsthesia in the fingers may be the precursor of pain The discomfort and ache of the early stages may often progress rapidly to marked stiffness of the neck, with or without a lateral tilt All movements may be voluntarily or "reflexly" restricted as they, as a rule, aggravate the referred pain and paræsthesiæ in the upper limb The referred pain is usually of a dull and gnawing character, not strictly localized, and very persistent, with superimposed lancinating pains, especially on head movements. Very often it is worse after getting up in the morning or during the night due to some unsuitable position of the head on the pillows Jolting of the body, sometimes sneezing or coughing, also aggravate the pain Although the pain is of a radicular origin it does not give a clue to the nerve root involved as it seldom radiates to the fingers, being usually referred to the scapular, acromial, clavicular, or arm regions, and apparently any of the lower cervical nerve roots may give this referred pain to the same area.

Paræsthesiæ almost invariably occur in the cervical herniations at a very early stage of the disease, indicating irritation of the nerve root They usually occur distally to the pain areas in the affected dermatome Commonly they take the form of a subjective feeling of "numbness," "tingling," or "deadness," etc, and, being usually referred to the fingers, they are of localizing significance Like pain, they are aggravated by neck movements and not infrequently by increase of intraspinal pressure

Sensory depression in the affected dermatome is a fairly frequent accompaniment of cervical herniation, though often in the more advanced stages of the syndrome Sensory deficit in a dermatome as opposed to peripheral nerve area of sensory loss greatly simplifies the differential diagnosis The depression usually takes the form of hypalgesia Proprioception as a rule is normal.

Reduction in motor power is evident in the great proportion of chronic cases, and muscular wasting is often obvious even in cases of relatively recent standing. Again, it is worth remembering in examination to be more "root conscious" than try to ascribe the findings to peripheral nerve lesions Fibrillations are relatively frequently encountered

The tendon reflexes of biceps or triceps are often depressed or occasionally absent and are of assistance in localizing the level of the lesion The other reflexes in the upper limb are less reliable in occurrence or significance The reflex changes, as well as motor weakness and sensory depression, indicate some degree of organic structural changes in some fibres of the affected nerve root due to compression. Whether, and to what extent, they are reversible, depends on the duration and severity of compression Sensory depression, as in lumbar herniations, if due to degeneration in the sensory fibres, is not recoverable since the lesion is proximal to the ganglion

The syndrome, whether mild or severe, has a distinct tendency to a relatively protracted course The intermittent pain, for months, may repeatedly be provoked by movements of the neck. Subsidence of symptoms and signs is slow and gradual.

Examination

(*a*) *Clinical* The great majority of cases show some degree of limitation of head or neck movement due to pain In severe cases this protective restriction may be in all directions, generally, however, some particular direction of bending or rotating the neck will be affected, and if the movement is performed it will produce, or increase, the radicular pain The circumduction of head and neck will show distinctly the "sector-like" distribution of pain. Extension of the neck towards the affected side is usually the most painful manœuvre. Not infrequently the diametrically opposite movement—forward and contralateral flexion—may evoke the pain In the latter position it may be increased by downward traction of the shoulder girdle on the affected side and/or by rotation of the head to the opposite side.

Neck compression test (Spurling)—steady downward pressure on the vertex of the skull or forehead from behind, with flexion and extension of the neck towards the affected side—very often may reproduce the radicular pain Suspension by the head may relieve the pain.

Localized tenderness to palpation of the spinous processes at the affected level may sometimes be found, occasionally with reproduction of the referred pain Certain areas of the muscles of the shoulder girdle may reveal tenderness, very likely due to localized muscular spasm caused by nerve root irritation, as shown by electromyographic studies

On neurological examination, the wasting, weakness, sensory loss, and reflex changes should be carefully assessed but it cannot be overemphasized that the examination should not be limited to the upper limbs only in those cases often called "brachial neuritis," "fibrositis,"

etc. Careful and, if not improving, repeated examination should be made for any evidence of latent cord compression. Severe radicular pain may overshadow symptoms or signs of pyramidal or spino-thalamic tract involvement.

(*b*) *X-ray.* Roentgenogram in the lateral view may show absence of normal cervical lordosis of the spine. Narrowing of the suspected intervertebral space is often revealed and, with clinical findings, it is a positive evidence of cervical prolapsed disc Negative X-rays, however, by no means exclude the possibility of a disc herniation Taking oblique views of the cervical spine is recommended routinely, they may show narrowing in the antero-posterior diameter of the intervertebral foramina by osteo-arthritic changes or laterally placed protrusion. Both oblique views are usually necessary for comparison. It should be remembered that the lumen of the intervertebral foramina in the cervical spine diminishes in size from above downwards

(*c*) *C.S.F. and Myelography.* Lumbar manometry often shows no abnormality in the cases with pure nerve root syndrome. Partial block sometimes—complete exceptionally—may be found in cases with a cord compression. Protein content is usually within normal limits in cases with pure nerve-root syndrome; when the cord is involved it may be raised in some cases.

In uncomplicated nerve root compression, myelography is usually unnecessary. It may, however, be useful when diagnosis is in doubt—e g. sometimes in differentiation between infrequent C7–Th1 disc protrusion and scalenus anticus syndrome In cases of cord compression, contrast myelography is usually advisable for precise determination of the nature and level of the compression.

Diagnosis

The diagnosis of cervical protrusion of the intervertebral disc is primarily clinical and relatively simple with the aid of a detailed history of the irritative stage of the syndrome—pain, and paræsthesiæ, together with objective signs of interference with a nerve root function—wasting, selective weakness, sensory deficit, and reflex changes.

Well over half of the cervical herniations occur at C6–7 level, the majority of the remainder at C5–6; C4–5 and C7–Th1 discs are only occasionally affected. It is perhaps advisable here, in order to avoid confusion, to remember the anatomical fact that there are 8 cervical nerve roots (the first one leaving the canal between the occiput and atlas where there is no disc), consequently the disc herniation on any level will compress the next numbered nerve root, e g sixth cervical disc, i e. between C6 and 7 vertebræ, will compress C7 nerve root

The lesion of C6 nerve root may be revealed by pain or paræsthesiæ referred to the radial aspect of the forearm, thumb and index finger. The sensory loss if present, usually greatest distally, will correspond to the same area (see chart) Wasting and weakness of the biceps muscle will be apparent, and biceps reflex may be reduced or even abolished.

The involvement of C7 nerve root may be shown by pain and paræsthesiæ referred to the dorsal aspect of the forearm and wrist, and to any one or all of the three middle fingers—index and middle finger most often Sensory deficit may be present, partly or fully, over the area of referred pain. Wasting and weakness of the triceps muscle with diminished or absent triceps reflex may be found.

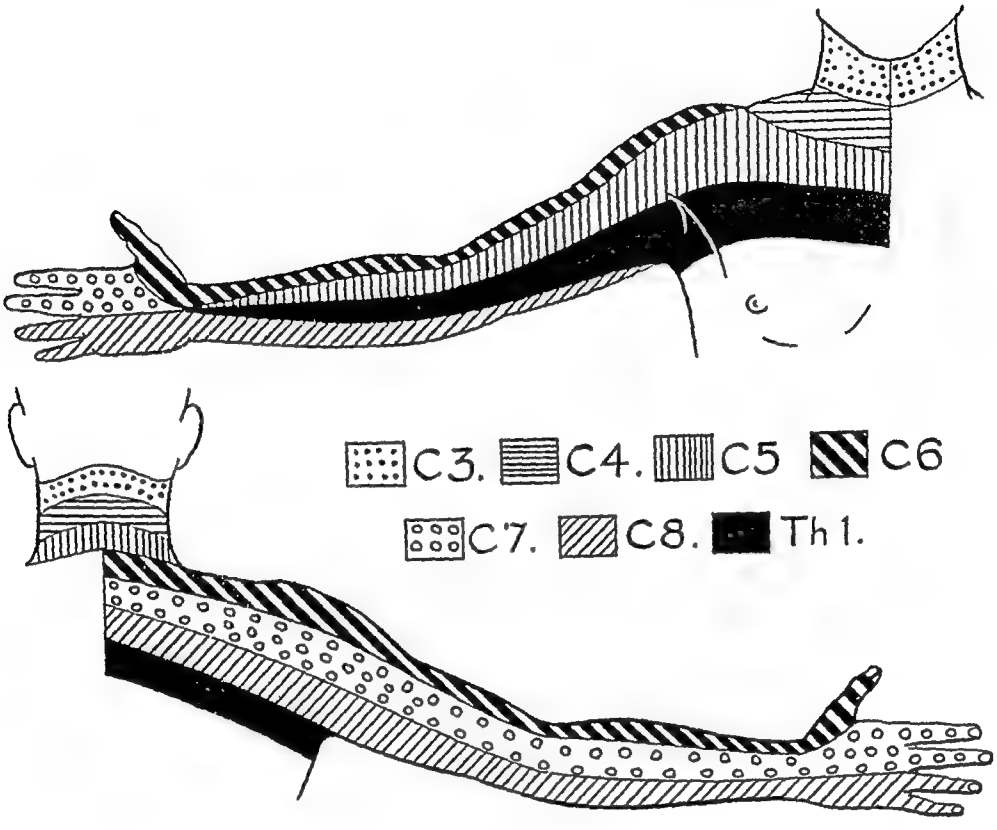

FIG 335 —Dermatomes (according to Keegan)

Due to the extensive intermingling of the segmental representation of the muscles of the upper limb, the decreased motor power in other than flexor and extensor groups of muscles has little localizing significance The lesion of C5 and C8 nerve roots can be arrived at by exclusion

DIFFERENTIAL DIAGNOSIS

Several conditions may be confused with the syndrome of cervical disc herniation and since their etiological diagnosis may sometimes be established only on exploration, the situation of the lesion is of greater importance from the differential point of view. It is, therefore, simpler to consider the diagnostic possibilities in an anatomical order—spinal cord, nerve roots, intervertebral foramina, cervico-brachial junction, etc

(1) Spinal cord tumours and syringomyelia may be considered in cases of prolapsed cervical disc with some element of cord compression In the former, absence of trauma in the history, a slow progressive

course, negative clinical tests and radiograms for protrusion, and finally myelography, will usually allow their recognition.

(2) *Radiculitis.* A history of preceding infection may be present, usually more than one root is affected, and the pain is apt to be referred to the entire limb and is not influenced by head movements Wasting and weakness is rapid, and there is pronounced tenderness of the muscles and nerves on palpation.

(3) *Osteo-arthritis of the cervical spine* occurs in an older age group and affects the spine over more than the one segment. It has a slow, chronic course, with stiffness and sometimes diffuse tenderness to palpation of the cervical spine Irritative symptoms are sometimes present but objective neurological signs from root compression are as a rule absent X-rays, apart from the well-known features of osteo-arthritis, may show spurs in the vicinity of the intervertebral foramina which are responsible for the radicular pain and paræsthesiæ. Their distribution is best seen in oblique radiograms and usually they are multiple C S F findings are always normal.

(4) *Laminar fractures* in the cervical region may simulate cervical herniation very closely, both conditions having a history of trauma and a similar course and findings At times only exploration will establish the diagnosis if the X-rays and oblique views do not show a bone fragment encroaching on the intervertebral foramen.

(5) *Cervical rib* The rudimentary rib, if not symptomless, affects the lowest trunk of the plexus composed of C8 and Th1 nerve roots The C7–Th1 disc is rarely the site of herniation capable of causing C8 nerve root compression, whereas a cervical rib is a relatively common condition The course is gradual, chronic and without remissions or exacerbations Motor signs point to median or ulnar, or involvement of both nerves, and sensory findings do not coincide with C8 dermatome pattern There are more or less marked vaso-motor symptoms which are lacking in disc syndrome X-rays show the cervical rib and further corroborative evidence against a disc herniation may be derived from lateral views showing a normal C7–Th1 disc space

(6) *Scalenus anticus syndrome.* On the whole the above remarks on the cervical rib apply here as in this condition nervous and vascular findings are similar but can not be attributed to any bony abnormality. It has been suggested that among others, root irritation by disc herniation leads to spasm of the scaleni muscles as a part of the defensive mechanism and the resulting scalenus anticus syndrome may be superimposed on disc syndrome Myelography, therefore, is recommended routinely prior to scalenotomy. Telford and Mottershead discard active function of the scaleni as an etiological factor and maintain that abnormal disposition of the insertion of the scaleni muscles is responsible for the symptoms

(7) *Acromio-clavicular arthritis,* subacromial bursitis, ulnar neuritis due to valgus deformity of the elbow, etc , if borne in mind cannot be confused with disc syndrome.

Treatment

The treatment of cervical herniated disc syndrome is essentially conservative except in cases complicated by cord compression when surgery is always advisable The most important element of treatment is rest to the neck and this can be obtained by rest in bed with suitable arrangement of pillows A slight degree of forward flexion is usually most convenient. If the patient has a habit of sleeping on his side, pillows should be adjusted accordingly to prevent lateral flexion of the neck to either side. A leather, plaster-of-Paris, or certalmide cervical collar support offers better rest by immobilization and usually relieves the pain quite rapidly. In severe cases, continuous head traction (7–12 lb.) for a few days, followed by a well-fitting collar, is said to be very effective. An adequate supply of analgesics should always supplement any mechanical form of treatment. During and after treatment it is advisable to make repeated examinations for evidence of cord compression, such as weakness of the lower limb with spastic signs, dissociated or undissociated sensory loss several segments below the level of the lesion, progressive muscular atrophy in the upper limbs, etc. Manipulation of the cervical spine is strongly contra-indicated as the result of it may be disastrous.

In the presence of cord compression surgical intervention is always indicated Occasionally it may be found that a lateral protrusion produces symptoms of cord compression due to interference with vascular supply of a segment of the cord In cases with a more centrally situated lesion, laminectomy is necessary and, to facilitate the safe retraction of the cord in its coverings, mobilization of the cord by division of several slips of denticulate ligament is advisable prior to removal of the herniation

Where conservative treatment is strictly adhered to and fails, and persistent and incapacitating symptoms and signs of root compression seriously interfere with the patient's work, surgical treatment may be considered. Hemilaminectomy as a rule is sufficient for excision of the herniation and no curettage of the disc space is attempted. At times the protrusion can not be adequately exposed due to the impossibility of safe upward retraction of the overlying stretched nerve root and one will have to be satisfied with simple decompression, with or without partial " de-roofing " of the intervertebral foramen The final results, even with these more limited procedures like decompression, are very satisfactory Operative treatment, however, should not be undertaken too lightly.

OSTEO-ARTHRITIS OF THE CERVICAL SPINE

Disc degeneration, with or without accompanying osteophytic formation, subluxation of one cervical vertebra on another, or disc protrusion, is the pathological change usually associated with neck, suprascapular, interscapular, occipital, arm, hand and chest pain

stemming from the cervical spine. Of the above causes the common change is disc degeneration with osteo-arthritis The position and size of the osteophytes are important. Those arising from the postero-lateral vertebral-body joints (joints of Luschka) may impinge on the cervical nerve roots or the vertebral artery or both, but symptoms may not be present even when an X-ray shows protrusion of the osteophytes into the intervertebral foramen.

The cervical spine may be affected by any of the three forms of osteo-arthritis described on page 688. It is often a late sequel to an injury in early life and is specially prone to occur in those who have been subject to the trauma of sport, as in horse-riding, cycling, and other forms where a fall on the head may occur

Stiffness is complained of particularly in rotation. The local pain is usually not so troublesome as the radiating one. This goes over the point of the shoulder to about the level of the insertion of the deltoid and it usually stops here If it goes further it is usually down the front of the forearm to the middle fingers. It may radiate up into the occipital region and is the cause often of persistent headaches, especially where the atlanto-axial joint is the seat of the arthritis. The headaches go up the back of the head, sometimes as far as the vertex They may be associated with areas of paræsthesia and patients may say that they notice a different feeling in this part of the head when they brush their hair.

On examination lateral bending is usually limited, as is rotation, which seems to suggest that the atlanto-axial joint is frequently affected though often not the main site Sometimes there is limitation of the whole cervical spine but it may be that the stiffness is only in the fourth to sixth cervical region Horner's syndrome has been described as occurring in cases of osteo-arthritis of the lower cervical and upper thoracic vertebræ

Diagnosis rests principally on the X-ray picture which confirms the suggestion of the symptoms and the results of the examination. It is necessary to exclude angina pectoris, which may be suggested but this site of the pain is unusual in the cardiac condition A local meningitis sometimes occurs over the root area of the fourth and fifth cervical vertebræ and may give rise to such radiation as may a spinal cord lesion Apical pleurisy and Pancoast's tumour of the pulmonary apex have also to be excluded

Non-operative treatment is often effective in relieving the pain in the majority of patients This may require a reduction of activity and the frequent use of traction or of a stabilizing collar The most useful collar is made of a broad strip of felt covered by stockinette and wrapped round the neck like a bandage. This not only produces some immobilization but it is helpful, too, from the warmth of the felt Pain-killing drugs such as veganin are most useful Many cases are relieved by 4–5 lb traction on an occipito-chin strap Osteopaths often cure headaches caused by adhesions in cervical osteo-arthritis though they

may not be able to distinguish headaches caused by intra-cranial disturbance.

If conservative treatment fails to relieve the pain, or if the pain is too extreme to be borne, then surgery is indicated This is usually done by fusing the spinous processes of the affected segment through a posterior approach Recently an antero-lateral approach has been suggested and carried out.

Laminectomy is not so satisfactory when posterior osteophytes compress nerve roots in an intervertebral foramen. Enlargement posteriorly of the foramen by removing the articular facet, as well as laminectomy, may be necessary to relieve the nerve root pressure in the foramen Unilateral excision of a posterior articulation may not cause instability, but if done on both sides may do so In the neck, removal of a degenerated but non-prolapsed disc is not feasible or desirable; by posterior laminectomy, so that disc removal and fusion of the cervical spine by an anterior route is indicated

It is necessary, of course, to be certain of the exact localization. This is done by (1) physical examination (2) by simple radiography and (3) special diagnostic methods This third method is by making discograms Contrast material is injected by means of a needle inserted antero-laterally approximating the anterior surgical approach to the cervical intervertebral discs Apart from the X-ray appearance the injection may reduplicate or exaggerate the typical pain pattern.

Operation. The patient is under general anæsthesia and should be intubated. The supine position is used with a sandbag under his neck and with the latter in slight hyperextension, and usually with slight traction on the head by means of a halter.

A vertical incision is made in front of the sterno-mastoid on the left side as there is less likelihood of traction on the recurrent nerve on this side The large vessels are retracted laterally and the middle thyroid vein ligatured This appears under cover of the anterior belly of the omohyoid and enters the internal jugular vein after piercing the anterior aspect of the carotid sheath This allows the cervical spine to be rendered visible when the sterno-hyoid, sterno-thyroid, and omohyoid muscles, the œsophagus, traches and thyroid gland are retracted medially

When osteophytic spurs are present they can be palpated through the anterior common ligament A needle may now be placed in the suspected disc space and a confirmatory lateral X-ray taken.

The space is then approached by turning back a flap of the anterior common ligament Through this aperture the disc is removed with pituitary rougeurs and curettes The osteophytes may have to be pared to allow a good access but the cortical edges of the adjacent vertebræ should be retained to hold a bone block in place when the neck is brought to the normal neutral position The bone of the vertebræ is then exposed by removal of the cartilage plates and sub-chondrial bone The space is then measured and a piece of iliac bone

removed with a sharp osteotome. The space is widened by extend the neck. The graft is tapped into position and counter-sunk. Wh seated it should be very stable. The flap is stitched into position, t soft tissues allowed to fall together, and the skin sutured. No in mobilization is necessary unless more than one space is fused when is wiser to immobilize the neck for three months.

Frykholm suggests facetectomy in cases of cervical root pres from osteophytic pressure situated within the intervertebral fo where it is inaccessible to approach by hemi-laminectomy. The neur central joint cavities on C 3–7, first described by Luschka, consist small articulations with synovial linings which are developed betw the curved upper and lower surfaces of the postero-lateral aspects the bodies of these vertebræ

The operative steps have been amply illustrated in Frykholm monograph (1951) The stages of operation consist first, of cutt well into the upper vertebra to expose the ligamentum flavum and curved line at the junction of the facets. Further bone is removed the burr to deepen the cut in the lower vertebra below the junction this lower portion of bone becomes thin enough to crack away, expo the periradicular tissue and margin of the ligamentum flavum over t intervertebral foramen. These tissues are separated from the pedicl and excised. Hæmostasis is secured with diathermy and thus the nerv root is exposed, and usually exhibits well-marked angulation from di placement by the osteophyte.

Spontaneous Axillary Thrombosis.

This is a condition that may suddenly arise in an otherwise perfec healthy individual and often a young man, where the upper arm sudden becomes diffusely swollen and discoloured. Eighty per cent. of the ca are males and in 70 per cent. the right arm is involved.

The condition is often ascribed to trauma, as in a man vigorou scrubbing his back while in a bath, or in another case where the pat strained his arm jumping from a tractor. The initial injury is usuall accompanied by acute pain, rendering them unable to work The becomes limp and useless The whole limb swells rapidly and there difficulty in moving the shoulder and to a lesser degree the elbo Superficial veins of the arm become very distended and obvious and t is often a curious tingling sensation in the fingers. At first the pain stabbing in type and later it changes to a dull intermittent ache aggra vated by use of the arm. The hand and arm assume a faintly dusk hue.

On examination the veins of the hand and arm and pectoral regi are prominent and engorged in appearance, particularly at the acromi thoracic anastomosis. There is marked tenderness of the axillary v No motor or sensory changes occur. X-rays are normal

Venography is carried out using Pyelectan, an organic iodine co

pound. 5 c.c is injected into the median cubital vein and the site of the obstruction may be shown

TREATMENT. The patient is treated in bed with the arm elevated and exercises are instituted, graduated by the limits of comfort. Anti-coagulant therapy by Heparin is started at once and controlled by the blood-clotting time

ÆTIOLOGY Hughes suggests that the condition is related to an anatomical abnormality where the phrenic nerve passes in front of the subclavian vein and so may obstruct the vessel by pressure against the tendon of the scalenus anterior almost as effectively as a ligature That such an abnormality occurs has been shown by Hovelacque who discovered it in 10 out of 138 anatomical dissections, and Schroeder in 4 per cent. of cases This theory of a pre-venous phrenic nerve obstruction offers an adequate explanation of an apparently permanent obstruction. Recovery depends on the collateral circulation and this depends on whether the nerve passes medial or lateral to the external jugular vein and the thrombus formation It may be that after the anti-coagulant treatment is instituted the simple operation of section of the phrenic nerve might be a wise procedure.

SAWAI MAN S
Date...
Price .....
JAIPUR.

CHAPTER XV

AFFECTIONS OF THE KNEE JOINT

No other joint in the body so frequently suffers derangement of its function and its stability as the knee joint, and its complicated mechanism and intricate structure make accurate diagnosis of its many disabilities difficult and uncertain

The manifestations of acute trauma and infection do not materially differ from those in other joints When these are excluded there remains a series of conditions, chiefly mechanical, which interfere with the efficient action of the joint.

The term "Internal derangement" was originally applied to these lesions in 1803 by William Hey. In his *Practical Observations on Surgery*, he thus defines them: "The complaint I have described may be brought on by any such alteration in the state of the joint as will prevent the os femoris from moving truly in the hollows formed by the semilunar cartilages and the articular depressions on the tibia."

It was originally presumed that the lesions were all intra-articular; hence, indeed, the form of Hey's description. An increasing knowledge of the pathology of the joint now indicates that certain of these mechanical derangements may in fact be extra-articular. With the realization of this fact, the number of conditions now alleged to give rise to this type of disability has grown to almost terrifying proportions.

Many of the lesions fall into the group of occupational injuries—e.g. the cartilage displacements so common in miners;—while others are common in those who indulge in certain forms of athletics. Their importance to the orthopædic surgeon is great, since disturbances in the function of the knee are increasingly common, and since treatment, at least in the early stages, is often associated with complete relief.

A CONSIDERATION OF THE ANATOMY OF THE KNEE JOINT

The knee is the largest joint in the body and its security depends not on the intrinsic shape of its articular surfaces, as in the hip, but on the series of powerful ligaments which bind the component bones together, and on the muscles which surround it.

The Quadriceps Muscle. The quadriceps extensor is formed by the rectus femoris, and the three vasti. It extends the leg or thigh and is one of the most powerful in the body, so much so that it is able to

produce a fracture of the patella by its own contraction. Its action, however, is a late acquisition in man's evolution and it is hence unstable. Any injury to the knee joint reacts on this muscle and it quickly shows a loss of volume, tone, and control and this in itself is a real disability.

Perhaps the most important component of this muscle is the vastus medialis since it is the first to waste following injury or disease and the last to recover When functionally inactive it is unlikely that the knee can be fully extended and in such a condition the joint is particularly vulnerable to stress and strain

The Medial and Lateral Ligaments. The *medial ligament* is a flattened band attached proximally to the femur, and inserted below into the antero-medial aspect of the tibia. It strengthens the capsule on the medial side, and has a close and important relationship to the medial semilunar cartilage. Fisher has shown that the ligament is composed of two parts.

(i) An anterior portion, consisting of long fibres running between the tibia and the femur, which are only loosely attached to, and readily separated from, the semilunar cartilage

(ii) A posterior part, with short fibres, which is closely bound to the semilunar cartilage a little behind the mid-point of its periphery.

It is obvious that in this peculiarity in the anatomical disposition of the ligament there is a state of affairs which can readily give rise to trouble, since, as Fisher has so ably pointed out, "A mechanical weak spot exists where the movable anterior portion joins the comparatively fixed posterior portion of the cartilage."

The *lateral ligament*, a somewhat rounded band, stretches between the femur and the head of the fibula, but has not the same close association with the lateral semilunar cartilage, the tendon of the popliteus intervening between the two.

These two ligaments resist undue lateral movements of the joint when extended, and since exaggerated lateral movements are of frequent occurrence in many types of injuries, the ligaments are often torn or damaged

Behind, the joint capsule is reinforced by a thickening known as the *posterior ligament*, it consists of an expansion of the semi-membranosus tendon, and forms the floor of the popliteal space.

The Semilunar Cartilages (Menisci). The semilunar cartilages are crescentic portions of fibro-cartilage arranged round the periphery of the upper articular surface of the tibia, on cross-section, the cartilages are wedge-shaped, the thin apical portions of the wedge being directed towards the centre of the joint. Along with the tibial spine the cartilages form two hollows or depressions, for the more accurate reception of the rounded femoral condyles than could be provided by the flattened articular facets of the upper end of the tibia.

1. Medial Semilunar Cartilage. The medial semilunar cartilage is larger and more oval than its fellow; it is attached by two horns

particularly—so that the capsular ligament is largely under muscular control.

The Tibial Spine. The articular surfaces of the tibial condyles are separated from each other by the tibial spine, in position, therefore, the spine corresponds to the intercondylar fossa of the femur.

The spine consists of two tubercles, separated by an antero-posterior groove The lateral tubercle is slightly smaller, and some fibres from the anterior extremity of the lateral semilunar cartilage are inserted into it The larger medial tubercle receives some fibres from the anterior cruciate ligament, and occasionally the posterior horn of the lateral semilunar cartilage is attached to it. The size of the tubercles is liable to great individual variation.

The Infra-patellar Pad. An intracapsular but extra-synovial pad of fat is situated behind the ligamentum patellæ; from the main mass an extension passes backwards between the layers of a triangular fold which passes posteriorly from the anterior part of the synovial membrane at the distal part of the joint. The synovial prolongation is known as the ligamentum mucosum, or patellar synovial fold, and its delicate edges as the alar folds or ligaments. The fatty extension is known as the alar pad, or as the semilunar extension of the infra-patellar pad.

The importance of these anatomical features lies in the fact that hypertrophy of the alar pad is often difficult to distinguish from lesions of the cartilage, while hypertrophy of the main infra-patellar pad is a common form of internal derangement.

The recent work of Brantigan and Voshel, which greatly impressed the author on a recent visit to Baltimore, is of great interest and worth reading in the original They point out that "the integrity of the knee joint depends upon the muscles and tendons about the knee, the articular capsule, the intrinsic ligaments of the joint, and the bone architecture of the tibia and femur

"Lateral motion of the knee joint in extension is controlled by the capsule, collateral ligaments, and cruciate ligaments, in flexion, by the same structures minus the fibular collateral ligament.

"Rotary motion of the knee joint in extension is controlled by capsule, collateral ligaments, and cruciate ligaments, in flexion, by the same structures minus the fibular collateral ligament.

"Forward gliding of the tibia on the femur is controlled by the anterior cruciate ligament

"Backward gliding of the tibia on the femur is controlled by the posterior cruciate ligament.

"Lateral gliding of the tibia on the femur is controlled by the tibial intercondyloid eminence and the femoral condyles with the aid of all the ligaments

"Hyperextension is controlled by both collateral ligaments, both cruciate ligaments, both menisci, the posterior aspect of the articular

is possible at the knee. This takes place between the medial condyle of the femur and the medial semilunar cartilage, but only when the knee is flexed. When the joint has been subjected to long-standing distensions, and the capsule has become relaxed, some degree of lateral movement may be acquired

When the knee is in motion the femur may move on a fixed tibia, or the tibia on a fixed femur In all cases, however, the cartilages remain in contact with, and move with, the tibial head, although they possess in addition a small range of antero-posterior "gliding" movement.

A most important feature of knee movements is the "screw-home" or locking action, which depends on the greater size of the articular facet on the medial condyle Fisher gives the following excellent account of the mechanism

"It will be seen that the posterior two-thirds of the medial condyle are equal in extent and parallel to the lateral, the anterior third, however, curves outwards towards the trochlear surface, and has no corresponding part upon the external condyle

"Let us imagine that extension is occurring, the tibia acting as the fixed point. The femoral condyles glide and roll upon the upper surface of the tibia and semilunar cartilages, until the lateral condyle and the corresponding part of the medial condyle are used up. The remainder of the movement must occur at the expense of the curved anterior portion of the medial condyle, and the femur accordingly rotates inwards round the tibial spine until the oblique portion is used up, and at this point, which corresponds to the termination of extension, the joint is locked, and the femur has been 'screwed home' into the 'socket' on the head of the tibia."

The Cruciate Ligaments. The articular surfaces are also bound together by the two powerful cruciate ligaments. The anterior ligament is attached to the tibia immediately behind the anterior horn of the medial semilunar cartilage and passes upwards, backwards and laterally to be attached to the posterior part of the lateral condyle. The posterior ligament is attached to the tibia behind the posterior horn of the medial semilunar cartilage, and passes upwards, forwards and medially to the anterior part of the medial condyle. The anterior cruciate ligament is tense when the knee is extended, and also when the femur is rotated medially on the fixed tibia The posterior cruciate ligament is most tight in flexion

It is often said that the cruciate ligaments normally prevent antero-posterior displacement of the knee joint This is only partially true, for in the extended position of the joint antero-posterior displacement is prevented by the normal screw-home or locking mechanism, and at other times the knee depends—as other joints do—on the protective influence of the surrounding muscles. It is significant in this connection that the knee is enfolded by an adventitious capsule provided by the muscles in the vicinity—the quadriceps and the semimembranosus

Displacements or splits of the posterior end are caused by forcible lateral rotation of the femur on the fixed tibia, combined with flexion.

(*b*) **The Lateral Semilunar Cartilage.** The lateral semilunar cartilage is less frequently injured than the medial, since it normally enjoys a greater range of movement, and is not attached to the lateral ligament. Nevertheless severe degrees of violence may result in tears or displacements.

The anterior horn may be torn if the femur is forcibly rotated outwards on the fixed tibia when the knee is flexed; medial rotation of the femur on the fixed tibia, combined with or followed by violent flexion, is liable to cause a lesion of the posterior horn.

Injuries to either of the cartilages occur only when the knee joint is in a position of flexion. The reason for this is obvious—the cartilages are so firmly fixed to the head of the tibia that they follow that bone in all its movements If, however, the knee joint is bent at the time of receiving the strain then a lateral or rotatory strain on the joint may easily displace the cartilage from its attachment to the tibia.

Pathology of Semilunar Cartilage Injuries

The commonest injury of a medial meniscus is the so-called "bucket handle tear." This injury consists of a longitudinal fracture through the substance of the cartilage, the fractured portion being displaced into the centre of the joint while the anterior and posterior attachments remain intact (see Fig. 336 C) Almost all the remaining lesions of the menisci consist of some form of bucket handle tear with or without modifications caused by subsequent trauma.

For example, a longitudinal fracture may also occur through the substance of the anterior third in which event one limb usually retains its attachment but the other is frequently mobile and slips into the joint cavity (Figs 336 B and D). A similar type of injury is found in association with posterior horn injuries (Fig 336 E). Further examples occur when the centrally displaced portion of a complete bucket handle tear is subjected to a further longitudinal split or is torn transversely leaving tags of cartilage projecting into the centre of the joint from the anterior and posterior horns.

In a proportion of cases no organic lesion is present, but the posterior half or the anterior half (Fig. 336 A), or even the whole cartilage loses its peripheral attachment and slips into the cavity of the joint with each movement. Such injuries are merely examples of bucket handle tears—the tears taking place immediately external to the periphery of the cartilage.

The operative findings in the case of the lateral semilunar cartilages are essentially similar, but in addition the cartilage may undergo cystic degeneration (see Semilunar Cysts). Degenerative cystic change is rare in the medial meniscus.

capsule, the oblique popliteal ligament, and the architecture of the femoral condyles

"Hyperflexion is controlled by both cruciate ligaments, both menisci, the femoral attachment of the posterior aspect of the capsule, the femoral attachment of both heads of the gastrocnemius muscle, and the bone structure of the condyles of the femur and the tibia.

"The menisci cushion hyperextension and hyperflexion. The tibial collateral ligament is closely related to the medial meniscus, but there is no strong fibrous-tissue attachment between them The tibial collateral ligament glides forward and backward in extension and flexion."

INJURIES AND DISPLACEMENTS OF THE SEMILUNAR CARTILAGES

Smillie in his series of meniscal injuries found that in 64 per cent the medial meniscus was involved, and that in about 5 per cent. of the cases both menisci were removed

The Mechanism of the Derangement

(*a*) **The Medial Semilunar Cartilage.** Normally, the medial semilunar cartilage—or at least its anterior movable portion—glides slightly backwards towards the interior of the joint as the knee is flexed If the joint is at the same time abducted, and the medial compartment of the knee thus opened up, the mobility of the cartilage is still further increased Sudden medial rotation of the femur on the fixed tibia forces the medial meniscus towards the back of the joint The medial rotation causes the ligament to become taut, and the ligament at first steadies the posterior part of the cartilage If the ligament withstands the strain, therefore, the anterior movable part of the cartilage bears the brunt of the injury It may either be detached at its junction with the fixed part, or it may undergo any variety of transverse or oblique tear The fragment slips into the interior of the joint, and when extension is attempted, and an endeavour made to "screw the condyle home," the fragment is nipped or impacted between the condyles and the joint "locks."

When the rotatory strain is very severe the medial ligament may be so stretched that the connection between it and the cartilage is destroyed. Indeed, the ligament may be detached both from its tibial attachment and from the cartilage. In either event the whole cartilage slips into the interior of the joint, and as extension occurs the free border is caught between the condyles, a longitudinal slit occurring in the substance of the cartilage To this latter type of lesion the apt description "bucket handle tear" is applied Smillie points out that if the tear involves the posterior third of the meniscus it springs back into place and locking does not occur.

Clinical Features of Displaced or Torn Medial Semilunar Cartilage

Predisposing Factors. The anatomical factors which appear to favour the occurrence of cartilage lesions were freely discussed in the section dealing with the anatomy of the joint. Reference may now be made to certain *occupational factors.*

Lesions of the cartilages are most common in miners, and particularly in those who have to work a low seam of coal These men have to stoop or squat at the low coal face, when hewing, so that their knee joints are constantly flexed; when they wish to clear away the

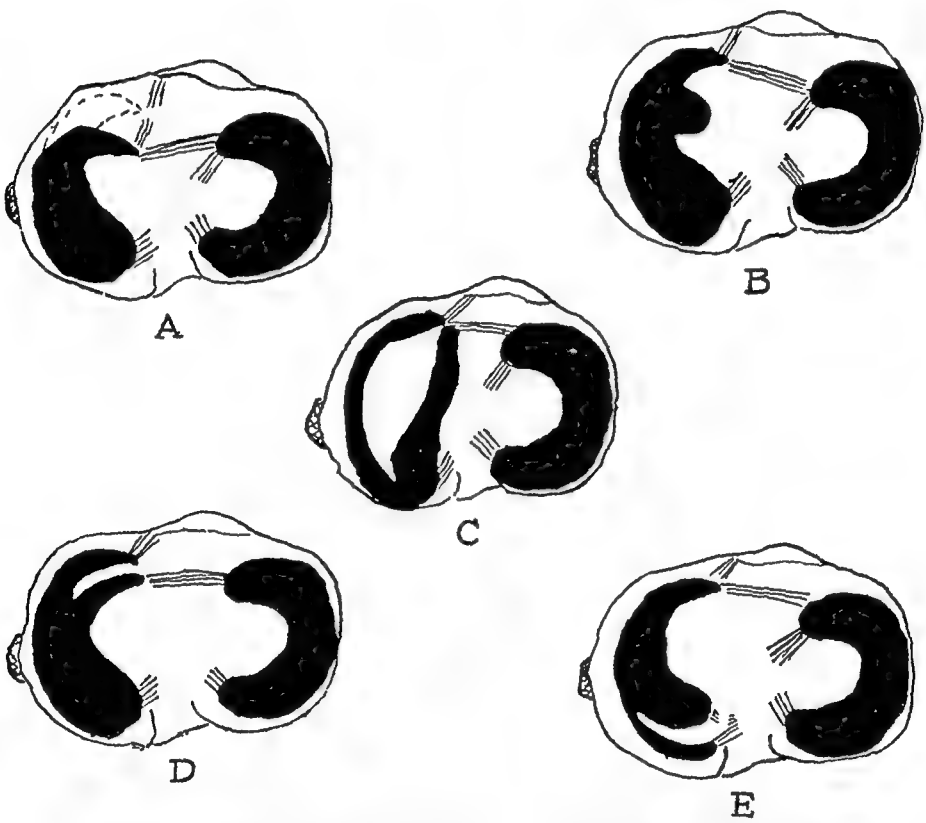

Fig 336 —Derangement of the Medial Semilunar Cartilage (A) Avulsion of the anterior horn (B) Local hypertrophy after a crushing injury (C) Bucket handle type of injury (D) Split anterior horn (E) Avulsion of the posterior horn

coal, they must, while still in the squatting position, empty the shovel over the shoulder To perform this acrobatic feat the body must be rotated, the knee joint slightly abducted, and the femur medially rotated. The medial cartilage accordingly slips in between the articular surfaces and if the miner suddenly extends the knee the cartilage may be unable to escape in time and so becomes crushed or torn

Certain forms of sport are commonly associated with cartilage injuries. Footballers are liable to them, especially when the ball is

Diagnosis

When there is a definite history of a twisting injury causing the knee to give way, followed by locking and synovitis, the diagnosis presents no difficulty. These classical signs and symptoms usually



Fig. 338.—Air Arthrograms showing apparently Normal Medial and Lateral Meniscii. The views are taken at various angles.

the lateral cartilage there is an additional sign of clicking felt and sometimes heard as the joint is straightened McMurray points out that there are two important points to be noted in regard to this diagnostic click · (1) it always occurs at the same angle of flexion of the joint, and (2) this angle is usually the last ten degrees of full active extension.

The Examination

The patient is examined with the lower limbs bare, and the knees are inspected anteriorly and posteriorly in both the upright and recumbent positions The joint is often swollen from chronic synovitis, and the swollen appearance accentuated by atrophy of the quadriceps. There may be a depression over the anterior end of the cartilage, or an external prominence at this point

In addition to the above, palpation usually reveals definite tenderness over the anterior attachment of the cartilage. This is well brought out by the following test · The thumb is placed on the medial side of the ligamentum patellæ, with the knee in flexion ; as the joint is slowly extended the anterior end of the cartilage comes into contact with the thumb and the patient experiences pain There may also be tenderness over the tibial attachment of the medial ligament. The integrity of the cruciate ligaments—especially the anterior and the medial collateral ligaments—is tested.

Fig 337.—Calcification of the Lateral Semilunar Cartilage

Movements. In unreduced cases the joint can neither be fully flexed nor extended; in old-standing cases there is often a certain amount of lateral mobility, due to laxity of the medial ligament In lesions of the posterior horn, there is sometimes a well-marked "click" or "snap" accompanying rotation when the knee is extended.

X-ray Examination. This should be a routine part of the clinical examination , it is essential for accurate diagnosis, and operation should never be undertaken without it.

Differential Diagnosis

When accurate diagnosis is difficult the following possibilities have to be excluded.

1. Injury to the Alar Pad of Fat. True locking is absent, although full extension is painful Tenderness can be elicited by pressing on the pad, and a sensation may be experienced of something slipping between the fingers.

2. Rupture of the Medial Ligament. The trauma in this case is abduction in extension rather than rotation in flexion There is no history of locking

Tenderness is present over the femoral or tibial attachments or in the line of the ligament. Undue lateral mobility is found.

It must be remembered, however, that from their anatomical relationship injury to the medial collateral ligament must predispose to injury of the medial meniscus. It is not until the acute symptoms of a medial ligament injury have subsided that the injury to the cartilage becomes evident.

3. Rupture of the Cruciate Ligaments. When the anterior cruciate ligament is ruptured, the tibia can be displaced forwards on the femur when the knee is fully extended. In the case of rupture of the posterior cruciate, the tibia can be displaced backwards on the femur with the knee flexed to a right angle If these findings are obtained, a careful comparison should be made with the sound side, as many individuals possess an unduly mobile knee.

4. Fracture of the Tibial Spine. This injury is the result of more severe violence and does not follow a simple rotatory strain. There is no tenderness over the attachments of either cartilage. Locking, if present, takes the form of a bony block to complete extension. The fracture is usually obvious on radiographic examination.

5. Loose Bodies. The locking which is produced by a loose body is usually momentary, and is not inaugurated by any special movement. The situation of the pain may vary with each attack, unless the body is pedunculated. In most cases a radiograph reveals the condition.

6. Exostosis. An exostosis in the region of the knee joint may so interfere with the free action of the tendons that "locking" may be simulated Pain is usually felt over the exostosis which can usually be palpated, and can always be seen in radiographs.

7. Osteo-arthritis. The onset is usually gradual Pain and stiffness are marked in the morning but disappear in the course of the day. Both the pain and tenderness are diffuse and not confined to any particular part of the knee. The lipping of the articular margin can usually be recognized on palpation, and demonstrated by X-rays.

8. Recurrent Dislocation of the Patella. It is not always easy from the history alone to exclude the possibility of this lesion. The

indicate a lesion of the anterior end of the medial semilunar cartilage. The signs of a lesion of the middle or posterior end of the medial cartilage, or a tear of the lateral, are less obvious but equally typical There is no locking but a sensation of something catching momentarily in the joint It can rarely be localized by the patient and after a time is not followed by effusion. McMurray has pointed out that the site of a lesion depends to some extent upon the angle of flexion of the joint at the time of the occurrence of the original injury : thus, if the joint is slightly flexed the lesion is usually towards the anterior end, while the more the joint is flexed the further back is the lesion. At mid-flexion and beyond it the damage to the cartilage is not usually gross enough to cause locking, but when it is nipped between the femur and tibia it causes pain and discomfort, and a transitory weakness frequently followed by synovitis.

McMurray has pointed out that if it is possible to manipulate the joint so that the injured part of the cartilage is nipped between the bones, pain similar to that usually experienced is felt. This most valuable method of examination is particularly useful when locking is absent and diagnosis obscure. McMurray has described the details of the manipulation The knee joint is first fully flexed so that the heel is placed almost on the buttock Abduction of the leg and lateral rotation of the foot will bring to bear on the medial semilunar cartilage a strain similar to that which produces the ordinary lesion. With the foot and leg held in this relation to the thigh the knee is slowly extended. If there is a lesion of the cartilage at any point from the level of the attachment of the tibial collateral ligament to the posterior horn, a distinct click will be produced when the femur passes over the site of injury, as the cartilage is usually thickened or loose. The same procedure is carried out with the foot now medially rotated. The patient also complains of a stab of pain as the click takes place The important result is the pain, for a mild click may be obtained with a normal but lax meniscus.

Some of the results of meniscectomy are vitiated by overlooking a tear of the cruciate or medial collateral ligament Osteochondritis dissecans may often simulate a cartilage injury and the radiological changes are sometimes late in appearing Tears of the cartilage may be masked by an associated osteo-arthritis and in these cases meniscectomy often produces diamatic relief Smillie advises that internal derangement of the knee in a woman should be regarded as a recurrent dislocation of the patella till proved otherwise

The X-ray film should eliminate such bony conditions as fracture of the tibial spine, loose body, exostosis, osteo-arthritis, myositis ossificans, and intra-articular fracture. The use of air injections into the knee before the X-ray is taken is occasionally of some use, but unfortunately it shows most accurately only the extreme lesions which are usually easily diagnosed by clinical examination. Enough air—usually about 100 c c —is injected until the suprapatellar pouch is tense and the knee then tightly bandaged from above downwards.

Prognosis

It has been stated previously that only the peripheral zone of a meniscus is vascularized. It therefore follows that healing may be expected in bucket handle tears at the extreme periphery of the cartilage, in tears entering the synovial attachments and in injuries where the anterior or more often the posterior horn is detached from the capsule of the joint. The major portion of cartilage injuries, however, do not fall into this group, and in those cases of torn meniscus it is wiser to operate and remove it in from four to six weeks.

Without operation it may be stated that the prognosis is fair in patients who pursue a sedentary occupation Recurrence of symptoms may be expected however in the majority of cases engaged in manual occupations or who continue active participation in sport.

2. The Treatment of Recurrent Cases.

In the majority of cases of recurrent displacement, where there is a history of true locking and synovitis, operation is the treatment of choice and should be undertaken at an early date to prevent the development of arthritic changes.

Opinion differs as to the necessity for the removal of the complete cartilage, and some observers content themselves with resection of the damaged or loosened portion. Such a practice is to be condemned. In the first place those with a large experience of this operation find that if the posterior part of the cartilage is left it frequently gives rise to synovitis and a feeling of weakness and insecurity in the knee which may "give way" at unexpected moments. It would appear obvious that once a cartilage has been mobilized to a point posterior to the lateral ligaments it must be entirely removed, for interference with the peripheral attachments of the posterior half of the cartilage must increase its liability to slip towards the centre of the joint. The practice of removing the displaced portion of a bucket handle tear is also unreasonable because of the frequency with which multiple bucket handle tears are encountered and the inability of the operator to test the mobility or inspect the posterior half of the remaining peripheral portion of the cartilage.

It is interesting to note that following resection of a cartilage a new "cartilage" of fibrous tissue regenerates from the synovial membrane. When the posterior horn of the original cartilage is left in the joint the anterior horn regenerates and an insecure junction is noted between the regenerated anterior and original posterior horns.

Technique of Operation

Pre-operative Treatment. During the usual two days' preparation of the skin the patient is taught the quadriceps exercises mentioned above, i.e , straight leg raising and rhythmical contracture of the extensor apparatus The rapid return of function following the removal of a cartilage depends on the volume, tone and control of the quadriceps, and as the exercises are begun on the day following operation

joint, however, is not usually tender, the quadriceps is lax, and when the knee is extended it is usually possible to displace the patella over the outer femoral condyle

TREATMENT

1. Treatment of the Original Lesion.

Certain rules are applicable to all cases.

(*a*) Reduction must be accurate.

(*b*) It must be maintained until the torn cartilage has healed.

(*c*) The damaged structures must be guarded from strain or further injury for some months

(*d*) During this period the nutrition of the joint structures and tone of the related muscles must be preserved.

The Methods in Detail

(*a*) **The Reduction.** Reduction should be performed at the earliest possible moment · in many cases an anæsthetic is an advantage, but it can often be dispensed with.

In the case of the right knee, the surgeon stands on the right side and grasps the patient's right foot firmly with his right hand, steadying the knee with his left hand The knee is first fully flexed, the leg is then abducted, and, at the same time, rotated first laterally and then medially When full rotation has been obtained it is suddenly extended, an audible snap may be heard, indicating that the displacement has been reduced. A good test of reduction is the ability of the patient to extend the knee fully and painlessly by his own effort, and maintain it in that position. If a second attempt is necessary it should be carried out under an anæsthetic.

(*b*) **The Retention.** No splint is necessary The joint is immobilized and firm compression applied by means of a Jones' bandage —several layers of wool between turns of a broad domette bandage. This both prevents the occurrence and facilitates the absorption of an effusion. The patient is kept in bed.

On the second day the patient begins quadriceps drill—straight leg raising and rhythmical contraction of the extensor apparatus This is practised five minutes per hour throughout the waking day.

On the tenth day active flexion may be permitted and on the fourteenth day the patient becomes ambulatory.

(*c*) **Prevention of Strain.** Abduction and lateral rotation of the leg on the thigh should be avoided The simplest method of ensuring this is to raise the inner side of the heel and sole of the boot by a wedge of leather. The patient should also be taught to walk with the feet parallel, or even with the toes turned inwards.

(*d*) **After Treatment.** Quadriceps volume, tone and control must be maintained and improved by the continuous practice of quadriceps exercises Massage and faradic stimulation are in common use but are no substitute for active quadriceps exercises.

condition of the posterior end of the cartilage cannot be determined on inspection from the front.

When there is difficulty in removing the posterior horn, which may occur in freeing the posterior third, it is of considerable value to divide the terminal attachment of the posterior horn to the bare area of the tibia as a preliminary step at this stage. One changes the locus of one's operative work from the medial part of the posterior third to the lateral part lying below the intercondylar fossa. The cartilage immediately becomes more mobile and with the tibia levered forwards over the sandbag it can be removed by dissecting and cutting again at its medial end.

Should it still be difficult or should the anterior horn be cut away alone, leaving the posterior horn, a second small vertical incision is made in the skin behind the medial collateral ligament. After incising the capsule in the same line the posterior horn can be seen and its attachment divided under vision. The whole cartilage can be withdrawn through this posterior capsular wound.

In closing any of these incisions the capsule and the aponeurosis are approximated together with linen thread and not catgut and finally the skin edges closed. A firm pressure bandage of Jones' type with much wool should be applied before the patient leaves the operating table, and before the tourniquet is removed. This is very necessary, as it prevents post-operative effusion of blood into the joint. A splint is not required.

Post-operative Treatment. On the day following operation the patient begins the quadriceps exercises he has learnt during the pre-operative period The bandage is not removed until the eighth day when the stitches are removed. On the same day the patient becomes ambulatory with the knee supported by a Jones' bandage if there is any marked effusion. Thereafter a progressive increase of active exercises is permitted.

Prognosis

The majority of writers are agreed that perfect results are obtained in fully three-quarters of the cases of removal of an abnormal or damaged semilunar cartilage, but when the cartilage that has been removed is apparently free from abnormality there may be persistent symptoms due, of course, to a wrong diagnosis—as, for example, ligamentous damage. Not infrequently osteo-arthritis may produce symptoms. This is particularly so when slight arthritis is present before operation in long standing cases, for it seems that the trauma of operation may aggravate it. Symptoms also persist when there is a co-existing derangement such as a loose body, hypertrophied synovial fringe, or alar pad. A neuroma of the infra-patellar branch of the saphenous nerve may occur after the operation but is relatively uncommon. This may require removal but most cases related to the nerve clear up in a few weeks.

less difficulty is encountered if the patient learns the routine during the pre-operative period.

The Operation. Rigid asepsis is essential. The leg is elevated to drain off the venous blood and a tourniquet applied high up on the thigh. This permits a clear view of the joint.

A straight incision is made from the inferio-medial aspect of the patella downwards and inwards to just below the joint line. Should it be necessary to expose the posterior horn from the back, a separate vertical incision is made behind rather than extending the anterior one in the U-shaped manner of Timbrell-Fisher.

The knee is flexed over the end of the operating table and the surgeon sits facing it The part is completely covered by a square of muslin wrung out in biniodide-in-spirit solution. After the skin is divided, a straight incision is made in the capsule, some way in front of the medial ligament. The actual entrance to the joint cavity should first be made over the femoral condyle, since if it is made over the intercondylar fossa negative pressure on the joint pulls the synovial

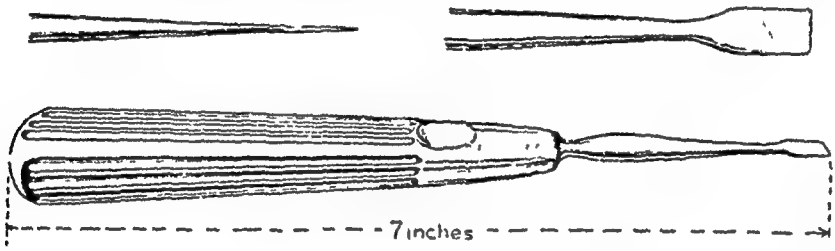

Fig. 339.—Special cartilage knife.

membrane inwards away from the knife. The extra-synovial fat and the synovial membrane are divided together. The cartilage is then carefully inspected, and any abnormality such as a tear or undue mobility noted. The retropatellar pad of fat is next examined, and loose bodies, injuries such as fracture of the tibial spine, or pathological processes like osteochondritis dissecans, excluded. If the anterior end of the cartilage is loose it is grasped with forceps. If not, the anterior attachment is divided. Usually when there is a tear of the posterior part the whole cartilage can be pulled gently towards the interior of the joint when this is done. If the cartilage does not readily displace, its attachment to the medial ligament must be divided and the cartilage then dislocated. The division of the cartilage from the medial collateral ligament and of capsular attachments immediately posterior to the ligament are greatly facilitated by the use of the author's chisel type of knife. If the head of the tibia is then forced forwards by a sandbag behind its upper end and rotated by the operator's knees, the posterior horn can be divided by means of the chisel knife.

It cannot be too strongly emphasized that when operation is undertaken for torn or displaced semilunar cartilage the cartilage should be removed, even though on first inspection it appears normal. The

Clinical Features

The most characteristic sign of a discoid cartilage is undoubtedly the loud click which is felt and heard when the knee joint is flexed or extended. It is often louder and duller than a click—rather a thud indeed. This may be appreciated at any point in the arc of movement of the joint, but is most common at the extremes of flexion and extension It is actually an exaggeration of the clicking so commonly found in traumatic lesions of the normal lateral semilunar cartilage. In association with the click there is often an aching pain on the outer side of the joint and a feeling of weakness often described as a "giving way" of the joint. As in other varieties of lateral cartilage derangement, locking is most uncommon.

There is sometimes a history of preceding trauma The syndrome occurs in the young, the majority of cases in the literature having occurred before the age of 18 In many the click or snap has been noticed previously but on account of the absence of symptoms has not been considered of serious import. It is often the occurrence of an injury, followed by aching pain, that sends the individual to the surgeon, though in many cases pain and weakness come on insidiously without trauma

Pathology

The cartilage is usually thicker than normal and is roughly quadrilateral with rounded corners. Not infrequently the peripheral margin curves upwards to be attached to the capsule in the vicinity of the lateral femoral condyle There is sometimes a hypertrophied pad of fat in the anterior part of the lateral compartment of the joint, probably derived from the alar fold.

Diagnosis

Pain and tenderness over the lateral cartilage with an audible and palpable "snap," in the absence of trauma and in a young person, should suggest the presence of a congenital discoid cartilage. If the "click" is bilateral the suspicion is strengthened, but a radiological examination is essential to exclude the presence of an exostosis which might impede the free movement of a tendon or capsular band. Finder has drawn attention to a feature in the radiographs which he considers important—the widening of the joint space between the lateral condyles of the tibia and the femur, as a result of the added thickness of the cartilage

Treatment of Lateral Semilunar Cartilage Injuries

The management of injuries and displacements of the lateral semilunar cartilage follows the lines already laid down for derangements of the medial cartilage. Reduction is effected by a similar manipulation, and retention and preservation of muscular tone are obtained in the same manner

Incomplete removal — the leaving behind of the posterior horn—is often associated with recurrent synovitis and a feeling of weakness in the joint, which may also tend to give way. This is probably the case only when the back part of the cartilage has been loosened by the original injury, or is dragged upon and partially detached by the surgeon during the operation. In either case the fault can often be diagnosed from the click on rotating the knee in full flexion.

The removal of a posterior horn may be easily accomplished through a short vertical incision behind the medial collateral ligament made with the knee in the flexed position. The saphenous vein is retracted backwards and the capsule incised. As the capsule is relaxed with the knee in flexion excellent access to the posterior horn is obtained.

Clinical Features of Lateral Semilunar Cartilage Injuries

On account of its greater natural mobility the lateral semilunar cartilage is less frequently injured than the medial. The history, signs and symptoms of displacement and tears are less clearly defined than those occurring on the medial side of the joint. Locking and effusion are less common.

The patient may complain of pain on the lateral side of the knee, particularly on the lateral side of the ligamentum patellæ; he may experience a sensation of something slipping inside the knee, usually on the outer side; or he may volunteer the information that when he straightens the knee, there is a loud crack or snap and the knee "jerks" into place—the so-called "trigger knee."

The examination is conducted on lines similar to that for the medial cartilage. There is, if anything, less wasting of the quadriceps; the tenderness is situated on the lateral side of the patellar ligament, and in the same situation there may be a definite hollow caused by the recession of the anterior horn of the cartilage.

Smillie has pointed out the occurrence of symptoms on the medial side in lesions of the lateral meniscus, and also that where there is doubt about the localization in an undoubted meniscus lesion it is probable that the lateral one is at fault.

Discoid Lateral Cartilage

The more accurate diagnosis of lateral cartilage lesions has brought to light the frequency of an interesting congenital anomaly. Smillie records one congenital disc of the medial cartilage and thirty-seven of the lateral cartilage in 1,500 cases.

A similar condition is normal in reptiles and in certain of the anthropoid apes, and Jones points out that normally in the human knee the cartilages possess a discoid or circular shape before absorption of tissue causes them to assume their semilunar shape. The condition is thus an atavism.

Pathology

The cyst is of varying size, sometimes multiloculated, and is usually situated on the lateral aspect of the cartilage. In addition to the obvious marginal cysts the cartilage is often studded with many small cysts. The larger possess a fibrous tissue wall which may or may not be lined by flattened cells. The origin and nature of these cells is obscure. Ollerenshaw originally thought them endothelial in nature and still affirms this view, but other workers, notably King, believe that they are compressed synovial cells. The smaller cysts are similar in structure, and all contain a thick mucoid material resembling that found in ganglia

Etiology

There are still two opposing views concerning the genesis of cysts of the menisci:

(1) That they are of the nature of congenital abnormalities, of the nature of endothelial inclusions which become cystic as a result of irritation and distension from trauma.

Fig 341 —Semilunar Cyst in connection with the lateral cartilage.

(2) That they are cystic or mucoid degenerations in fibro-cartilage and fibrous tissue resulting from trauma, but without any previous abnormality in the meniscus.

Davis and Edwards point out that as the menisci grow without any increase in the vascularity of the menisci, the nutrition of the middle of the disc becomes increasingly precarious, the avascular portion tending as it were to outstrip its source of nourishment. The maximal incidence of cysts is between 20 and 30 years of age, when the menisci are attaining their greatest dimensions and when the discrepancy between the dimension and blood supply is greatest. Trauma puts an added strain on the nutritive demands which at this age may exceed any reaction on the part of the peripheral vessels and result in mucoid degeneration. The factor which renders the lateral meniscus more susceptible to cyst formation is the presence of an almost avascular area where the popliteus

Removal of the lateral cartilage is essentially similar to removal of the medial cartilage. The incisions are similar though, of course, on the opposite side of the joint. The access to the anterior horn is less free than on the medial side, but owing to the greater mobility of the lateral cartilage the further mobilization to the attachment of the posterior horn is more simple and little difficulty should be encountered in removing the entire cartilage through the anterior incision. It has to be remembered that the popliteus tendon lies between this meniscus and the capsule

Recurrence of Symptoms

Symptoms may return or persist for reasons exactly similar to those for the medial cartilage, save that there is no fear of an infrapatellar neuritis following removal of the lateral cartilage.

A posterior horn remnant may require to be removed; if so, a short vertical incision is made over the joint line posterior to the lateral ligament with the joint in flexion. As the capsule is relaxed in flexion access to the posterior horn is good, but care must be taken not to injure the tendon of the popliteus, which is seen in the upper part of the incision, though, indeed, division of this tendon produces no disability.

CYSTS OF THE SEMILUNAR CARTILAGES

Cystic swellings in relation to the semilunar cartilages may be regarded as fairly common.

Fig. 340 —Semilunar Cyst of the Knee The cyst is protruding in front of the lateral ligament.

Little is known regarding their etiology beyond the fact that they frequently appear to follow an injury and are most common in association with the lateral cartilage, though the medial meniscus is also commonly affected.

the tibial spine has been avulsed, there is, in addition to the unnatural mobility, a definite obstruction which prevents full extension, and which feels definitely bony, in contradistinction to the locking following cartilage injuries.

The Posterior Cruciate Ligament. The functions of this ligament are precisely the same as the anterior with the exception of the first. In place of controlling forward movement of the tibia on the femur it controls backward movement The posterior cruciate is taut in flexion; violence which forcibly displaces the tibia backwards on the femur when the knee is flexed is therefore liable to cause rupture of the ligament. The most common cause of this injury is a fall on the flexed knee, the impact being taken on the upper end of the tibia instead of on the patella. The author saw such a case in a youth who slipped while crossing a railway line He fell with the knee flexed, the head of the tibia striking the edge of the rail.

A rupture of the posterior cruciate ligament is diagnosed by the ability to displace the tibia backwards when the knee is flexed, the posterior drawer sign There is a posterior sagging of the tibia with the knees drawn up to a right angle on a couch—the so-called passive posterior sign. The patient can usually displace his tibia backwards on the flexed knee by contraction of the ham-strings. In the more severe and complicated lesions hyper-extension of the knee is possible. An isolated rupture of this ligament is rare. It usually occurs in a severe dislocation in association with other ligamentous damage and, of course, with hæmarthrosis. In the recent injury, but more easily made out in the old injury, there is a characteristic excessive backward mobility of the tibia on the femur when the knee is flexed. *Rupture of both cruciate ligaments* may accompany dislocation of the knee joint; in this event, the joint is quite flail, and the tibia can be moved both backwards and forwards.

It should be emphasized that rupture of a cruciate ligament cannot occur without damage to other joint structures, particularly the capsule of the joint, and the disability often attributed to the ruptured cruciate ligament is actually the sum total of the effects of the injury on all the damaged structures It is for this reason that attempts to repair the cruciate ligaments are so often doomed to failure and have largely been given up

Treatment

When the hæmarthrosis has been reduced by aspiration the knee joint is immobilized in extension in a skin-tight plaster case As it is desirable the patient should remain ambulatory and exercise the limb there is no reason why the foot should be included in the plaster. An Unna's paste or elastoplast bandage is applied to the limb from toes to the knee and then a skin-tight plaster applied from the adductor region to a short distance above the malleoli over the elastoplast bandage. This allows the patient almost full use of the limb.

As soon as the joint has been immobilized the patient begins quadriceps exercises—under these circumstances consisting mainly of straight leg raising. Good development and control of the quadriceps can compensate to a considerable extent for laxity of the ligaments of the knee joint These exercises must therefore be carried out conscientiously 5 minutes per hour throughout the waking day during the three months in which immobilization is maintained. Following removal of the plaster case active flexion is commenced and quadriceps exercises continued for at least six months

The Treatment of Old Injuries of the Cruciate Ligaments

When the ligament has been ruptured for some time the ends become smoothed and covered over by scar tissue, and no amount of immobilization will produce healing. The treatment of such a case depends on the amount and nature of the resulting disability. Some individuals will be able to get about wonderfully well without apparatus, while others will be helped by wearing a knee cage which limits to some extent the strain on the collateral ligaments and which has a good moral effect. Some patients are so little affected that they can take an active part in games, or carry out a strenuous occupation. Nevertheless, in all cases, the permanent abnormal mobility predisposes the joint to the later development of arthritis.

Certain operations have accordingly been devised to reconstruct or replace the injured ligaments Technically such operations are difficult and require a high degree of skill, and the results even in the most expert hands have proved unsatisfactory and the author cannot advocate their adoption.

The recovery of stability in a joint after rupture of the cruciate ligament depends chiefly on the volume and control of the extensor apparatus and upon the continuity of the medial and lateral collateral ligaments.

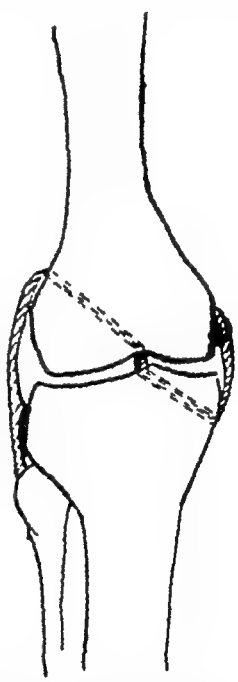

Fig 342 —Reconstruction of the anterior cruciate ligament by Fascia Lata

The fascial insertion below is retained and a strip cut and threaded through the joint Its free end is secured to the femur to strengthen the medial ligament

(a) The Operation for Reconstruction of the Anterior Cruciate Ligament. As the medial ligament is usually ruptured as well it also must be reconstructed. A large U-shaped incision is made in front of the knee, starting about the adductor tubercle, and crossing in front of the tubercle of the tibia, to end on the outer side at a corresponding point to the inner limb. The tubercle of the tibia is detached with the patellar tendon, and these along with the patella are reflected upwards, and the joint cavity opened. If suture of the ligament is impossible, the outer limb of the incision is continued upwards for

about 10 inches, and a strip, 8 inches long and 1½ inches wide, is separated from the ilio-tibial band and reflected downwards, its lower attachment to the tibia being preserved. A tunnel is now drilled in the lateral condyle of the femur, passing downwards and inwards to the area where the cruciate ligament was attached. The inner end of the hole should be made far back so as to make the new ligament as oblique as possible in the sagittal plane. A similar tunnel is now made through the tibia, commencing at the attachment of the medial ligament, and passing upwards, forwards, and laterally to finish at the site of the tibial attachment of the cruciate ligament in front of the tibial spine. Bone debris should be cleared away by a strip of gauze passed through the hole. Great care should be taken to prevent the access of the bone dust to the joint, as it may form the nucleus of a loose body or give rise to pain at a later date The fascia lata is now threaded through the femoral tunnel, from the outer side, and then through the tibial tunnel, until it protrudes at the external opening in the tibia There should be a free end left, about 3 inches in length. This is drawn tight and sutured to the most prominent point on the medial condyle, or alternatively a piece of bone is elevated from the medial condyle, the free end of the fascial ligament is laid under it, and the two secured by a staple. By attaching the fascia to the femur the medial ligament is strengthened. All the suturing should be done with the knee extended and the fascia lata fairly taut; this position should be maintained for about eight weeks, until the fascia has become firmly anchored A compression bandage and a straight gutter splint are applied. The wound is usually healed in about two weeks, and during this time it may be necessary to aspirate the joint After two weeks an unpadded plaster case is applied from the groin to above the ankle Quadriceps exercises are insisted on during this period When the plaster is removed flexion is encouraged. A knee cage is of no value —rather the reverse

(*b*) **Reconstruction of the Posterior Cruciate Ligament.** The operation is similar to that for the anterior cruciate ligament up to the exposure of the joint cavity. Thereafter the inner limb of the U-shaped incision is continued up the postero-medial aspect of the thigh exposing the hamstring tendons Corresponding lengths of the semitendinosus and gracilis are now cut, the distal ends being isolated and brought down and the proximal ends sutured to the semimembranosus A pair of artery forceps are pushed through the posterior ligament of the knee between the posterior horn of the medial semilunar cartilage and the tibia, and the two tendons pulled through the posterior ligament until their free ends hang out from the front of the joint. A hole is now bored through the medial condyle of the femur, the internal opening being as far forwards as possible on the intercondylar notch, and the outer above the middle of the medial aspect of the condyle immediately above the joint The tendons are now pulled through this hole and, with the knee extended, tightened up

and attached by their free ends to the medial condyle of the tibia. By attaching the tendons to the tibia any weakness of the medial ligament is compensated for. The joint is immobilized in the extended position for six weeks and thereafter a light plaster is fitted and the patient allowed to walk. A moulded knee cage is used for about six months.

RUPTURE OF THE LATERAL LIGAMENTS

Trauma to the medial and lateral collateral ligaments of the knee joint takes place as the result of abducting and adducting injuries with the knee joint in extension while the extensor apparatus is caught "off guard." The medial ligament is the more important of the two and is the more frequently injured. The lateral ligament rupture is often associated with damage to the lateral popliteal nerve—either a stretching damage or a complete rupture of the nerve The diagnosis is made on the history of the injury, the position of the tenderness which is in the line of the ligaments, the ability to "open up" the knee joint on the side injured and on the absence of signs suggestive of meniscus damage. An X-ray shows no abnormality.

Treatment

In the acute lesion, whether complicated by a nerve lesion or not, an exploration of the area is indicated. The ligament is stitched and the lesion of the nerve dealt with according to the findings. The sutured ligament does well but the results of treatment of the nerve lesion are disappointing In a recent rupture of the medial collateral ligament, when there is no doubt that a complete break is present, operative repair is the treatment of choice. Conservative treatment is indicated if there is an incomplete lesion. In such cases, after an aspiration of the joint, the joint is immobilized in the extended position with a compression bandage and reinforced with a posterior plaster-of-Paris slab. In fourteen days' time a skin-tight walking plaster case, permitting of ankle and foot movement, is applied

It has been stated previously that rupture of the medial collateral ligament may be accompanied by injury to the adjacent meniscus. It is often impossible to diagnose injury to the cartilage during the acute phase, but it may become clear during the period of rehabilitation that some additional internal derangement is present. This possibility should be kept in mind when late symptoms arise.

OLD INJURIES OF THE MEDIAL COLLATERAL LIGAMENT

Unrecognized or untreated cases of injury to the medial collateral ligament frequently result in symptoms due to instability of the joint. The possibility of a co-existing tear of the medial meniscus should be considered.

These cases always exhibit a gross degree of quadriceps insufficiency and before operative treatment is considered a course of vigorous quadriceps exercises should be prescribed and the case re-assessed at the end of three months. Many operative procedures have been recommended for old injuries of the medial ligament Most operations aim at the strengthening or reinforcing of a weak ligament by plication, strips of fascia lata or by means of tendons. In spite of the ingenuity of some of these procedures the results in most cases have proved unsatisfactory.

Operative Treatment. Mauck has pointed out that instability of the knee in these cases is due to laxity of the medial ligament rather than to weakness of the structure He considers that in most cases the weakness exists in that part of the ligament adjacent to the tibial head—the portion which has healed by fibrous tissue. He concluded that if the integrity of these structures could be restored the instability would be relieved and good function obtained The aim of the operation which he suggests is to shorten the relaxed ligament and to eliminate the weakened part which is made up of scar tissue

The knee joint and upper end of the tibia are exposed by an incision from the adductor tubercle to a point 4 inches below the articular surface of the tibia. The area of bone including the attachment of the medial collateral ligament is removed from the head of the tibia and the ligament shortened by mortising the bone flap into the tibia at a lower level The medial meniscus is removed. The ligament is thus shortened and that part of the ligament formed by scar tissue brought against the denuded bone of the tibial head.

GENU VALGUM

Although this deformity is commonly believed to be a result of rickets and the effect of the superimposed body weight through the medially deflected femur on soft bones, Brittain has shown the important etiological factor of the collateral ligaments of the knee. He believes the condition to be due to · (1) Laxity of ligaments, or "loose knee", (2) Quadriceps insufficiency; and (3) the child being over-weight. The inward deflection is due to the fact that the femur slopes inwards towards the knee, and to the further fact that the lateral ligament of the knee is a thick and strong structure as compared with its medial counterpart. The medial ligament has the vastus medialis inserted into it. Any insufficiency of this muscle, which functions only in the last 10 to 15 degrees of extension, leaves the medial ligament badly supported. If such children are not supported at an early stage the femora produce a fixed valgus deformity from over-growth of the medial condyle The usual method of assessing the deformity is by measuring the distance between the two internal malleoli with the extended knees just touching each other. A more certain method is to have a radiogram of a considerable length of femur and tibia on one plate.

Treatment

In the early case it is sufficient to fit them with $\frac{3}{16}$ inch inner wedge to the sole and heel of their shoes. The mother must be impressed with the necessity of allowing no weight-bearing whatever unless the wedged shoe is worn

Brittain advises a special Lloyd night splint in order to produce a quicker result, but does not fit them for small amounts of deformity or for fretful children. The splint is a modification of the Jones knock-knee brace It consists of two parts which fit together—one ensures extension of the knee, while the longer piece permits lateral pressure on the leg with an elastic bandage. In children with considerable deformity —about 4 inches of intermalleolar separation—an osteotomy is advised. The osteotomy is carried out as described in the rickety type of deformity.

FRACTURES OF THE TIBIAL SPINE

Lesions of the tibial spine are not uncommon, and are often associated with injury to one or other of the cruciate ligaments, particularly the anterior. Smith and Jones recognize three groups of injuries ·

1. Avulsion of the Spine or of its Medial Tubercle. This is produced by a similar mechanism to rupture of the anterior cruciate. Usually the ligament has remained intact, leaving the bony process to bear the brunt of the strain The fragment is usually displaced in the direction of the course of the anterior cruciate ligament which is attached to it

2. Fracture of the Lateral Tubercle. The fracture in this case is usually due to direct contact with the inner margin of the lateral femoral condyle, and the fragment is pushed a little to the medial side The mechanism of the injury, therefore, is like that which results in lesions of the medial semilunar cartilage—extreme rotatory violence.

3. Fracture of the Spine in Association with Fractures of the Tibial Condyles. Here the fracture is a crush fracture, the result of severe trauma, and in addition to the violent contact between the opposing articular surfaces there is usually some forcible abduction or adduction strain leading to fracture of the medial or lateral condyles respectively. It may thus result from falls from a height, or from a heavy weight striking the thigh or knee when the joint is flexed.

Clinical Features

The clinical evidences of spinal fractures are often masked by those of coincident lesions of the semilunar cartilage, the collateral ligaments, or the cruciates. In the first two types there is a definite bony block which prohibits full extension. In neglected cases this persists and is associated with recurrent synovitis. In the crush fracture type the co-existing condylar fracture usually causes marked and obvious lateral deformity.

Treatment

When the effusion or hæmarthrosis has been reduced by aspiration or by the elastic pressure of a Jones bandage, a skin-tight plaster of the same type as that described under Treatment of Ruptures of the Cruciate Ligament is applied and worn for a period of three months during which time the patient concentrates on exercises designed to increase the volume and tone of the extensor apparatus

In some cases, however, the bony block to extension persists giving rise to functional disability, and under these circumstances the fragment should be replaced by operation

In cases where the tubercle is avulsed by the cruciate ligament replacement by operation is usually necessary. A straight vertical incision is made along the medial aspect of the patellar tendon. It can be extended to be of the patellar displacing type if it is found necessary to have a wide exposure. The avulsed fragment of bone is easily found, but if it is more than a few days old replacement is not so easy. The bed may have to be cleared of callus and organized blood clot to receive the fragment. It is fixed by drilling two holes from the anterior aspect of the tibia just below the joint line up to and through the fragment Chinese twist silk is pushed up and through with a straight needle, hole first, and then brought down over the fragment and the silk tied in front of the tibia. Compression bandage and splints are applied for two weeks and a long plaster case for eight to ten weeks Quadriceps exercises are carried out regularly and frequently each day.

AFFECTIONS OF THE INFRA-PATELLAR PAD

From the synovial membrane which covers the deep surface of the infra-patellar pad of fat a triangular fold passes upwards and backwards to be attached by its apex to the anterior extremity of the inter-condyloid fossa This fold is called the infra-patellar synovial fold (ligamentum mucosum) and its free margins are known as the alar folds (ligamenta alaria) The pad of fat lies behind the patellar ligament and the part of it which is carried in between the synovial folds is frequently the site of hypertrophy (lipoma arborescens) In this condition grape-like pieces may be detached and form loose bodies.

When the knee joint is extended the patella is drawn up by the contracting quadriceps, and the infra-patellar pad of fat is similarly pulled up to avoid its being caught between the tibia and the femur. When an excess of fat has been deposited in the pad, however, or when the quadriceps has lost its tone, the pad may not be sufficiently drawn up, and is then liable to be nipped between the opposing articular surfaces Repeated trauma of this nature is associated with hæmorrhage into the pad, and further thickening, it becomes hard, and may project beyond the margins of the patellar ligament, in the form of two small swellings about the size of a walnut. This traumatic form of enlargement is most common in young athletes.

In older subjects, the infra-patellar pad may be hypertrophied in association with intra-articular arthritic changes, as, for example, villous hypertrophy of the synovial membrane.

Symptomatology

The condition was first described by Hoffa and is often known as Hoffa's disease The condition occurs in young people and often after rather mild injuries. It is said that people who seek advice on this condition are usually of an introspective frame of mind.

The clinical features of an affection of the infra-patellar pad, while not so distinctive as those of a lesion of a meniscus, are yet in some respects characteristic. The knee is painful, but the pain, which is constantly situated immediately behind the infra-patellar ligament, occurs only when the knee is used The joint tends also to be stiff, and the patient may complain that it is weak and liable to recurrent attacks of swelling (effusion). From the interposition of the hypertrophied fat between the articular surfaces there results a progressive limitation of extension which makes the patient walk with his knee partly flexed, bearing his weight on the metatarso-phalangeal joints with the foot in the equinus position.

True locking does not occur, but at intervals the joint may appear to "give way," or a sharp stabbing pain may occur which temporarily arrests the patient's activity.

The pad, on examination, is usually enlarged, and the swellings on either side of the ligamentum patellæ are tender. This tenderness persists, or rather is more pronounced when the joint is fully extended, and this provides a characteristic sign The quadriceps constantly shows a degree of atrophy

Radiological examination is usually negative; occasionally, however, calcium salts are deposited in the hypertrophied fat and may give a shadow in the situation of the pad.

Treatment

(*a*) **Conservative.** The symptoms are produced mainly when the knee is extended, so that conservative measures should seek to limit this movement. Jones recommends the simple but effective device of raising the heel of the boot on the affected side; this prevents full extension, and may be followed by subsidence of the swelling and disappearance of the symptoms. In severer cases, further measures may be required, in this connection, a hinged knee cage, so arranged that extension is arrested some 20°–30° short of full extension, may prove of great service

Conservative measures should always be supplemented by exercises, massage, and faradism, to strengthen the wasted quadriceps.

(*b*) **Operative.** If conservative methods prove ineffective, the pad should be removed.

An incision is made to the medial side of the lower part of the

patella; the pad is found to be loosely attached to the posterior surface of the patellar tendon, about the upper end of the tibia, but firmly fixed to the articular capsule The three prolongations at its upper end are severed by a pair of curved scissors as near its insertion into the meniscus as possible This procedure may open the knee joint, but no attempt is made to close it. After closure of the aponeurosis and skin the knee joint is immobilized for eight days, and at the end of that time active movements are begun. Complete recovery usually results in from two to three months. In many cases more adequate exposure is needed and Timbrell Fisher's patella displacing method should be employed.

BIPARTITE PATELLA

The patella, like other sesamoid bones, is subject to many anomalies of development which, though they have little or no clinical significance, are of great diagnostic importance.

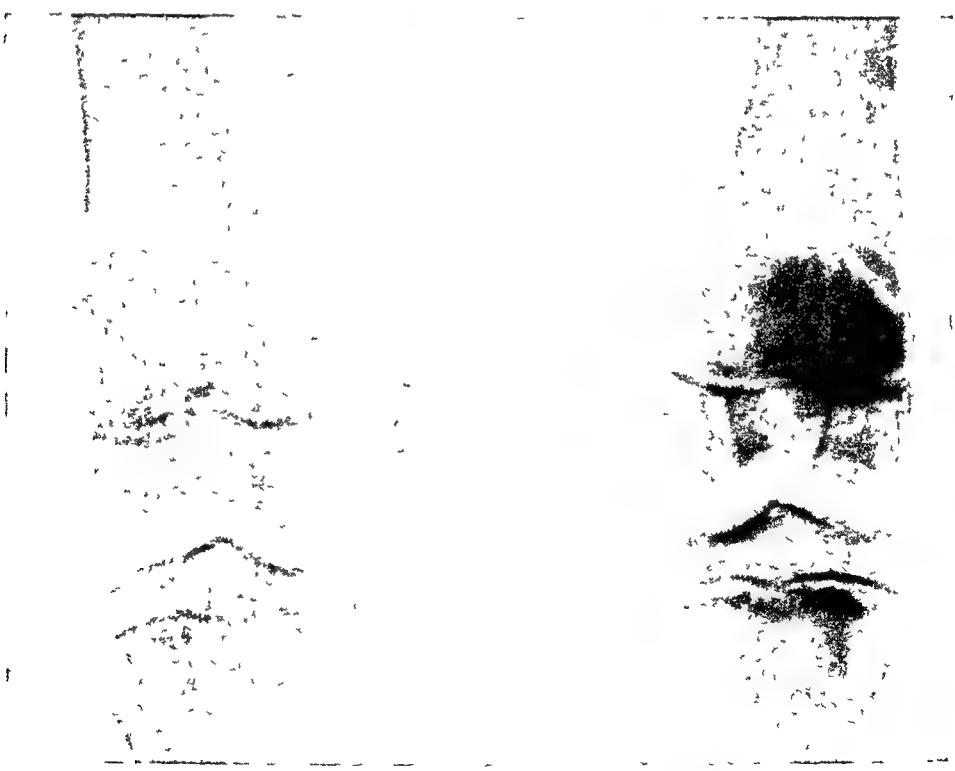

Fig 343 —Congenital Bilateral Bipartite Patellæ

The patella arises usually from a single centre of ossification, though occasionally two or even more centres are present. These several centres almost invariably fuse to form a single bone, but occasionally they remain discrete, giving the condition of bipartite or even multipartite patella. The importance of the condition lies in the fact that the unwary may confuse its radiographic appearance with that of

fracture, particularly since it is usually first observed when the knee is X-rayed following an injury.

Radiological Appearance. The general contour of the patella is not grossly altered, but the bone is seen to consist of a larger and one or two smaller fragments, the latter situated usually at the upper and outer quadrant The structure of the smaller fragments is similar to that of the main part of the bone, consisting of a shell of cortical bone, surrounding normal cancellous tissue. The fragment has a semi-lunar outer margin, but the border adjacent to the larger fragment is linear and appears in the antero-posterior view as a straight line. There is usually a definite radiological interval between the two fragments, but in the dissected specimen this apparent gap is occupied by cartilage.

In five out of six cases the condition is bilateral, while a similar condition is not uncommonly observed in the sesamoid bone beneath the head of the first metatarsal.

Diagnosis

The condition has to be distinguished from fractures of the patella. These, however, are accompanied by a definite history of injury, and the usual clinical manifestations of trauma are present. The important points in the differential radiological diagnosis are:

1. The margins of the fragments of bipartite patella are smooth and consist of cortical bone . fractured fragments show more or less serrated edges, and involve cancellous bone
2. The position of the intervening gap is also significant. Fractures rarely occur in the upper and outer quadrant, but this is almost invariably the site of the congenital anomaly
3. The congenital error is frequently bilateral.

CHONDROMALACIA OF THE PATELLA

Fissuring and flaking of the articular cartilage of the patella, or chondromalacia, is one of the commonest forms of degenerative change seen in joints Osteo-arthritis is a disease of middle aged or older people, but chondromalacia occurs much earlier It is a commencing senescence of the joint even though it begins at so young an age It begins as a nodular swelling of the articular cartilage, most commonly in the lower part of the medial facet. The lesion is localized and is associated with a decrease in the chondrostin-sulphate content and the cartilage becomes opaque Fissuring and flaking occur later and may involve the whole articular surface The flaking often produces scales which may result in cartilaginous loose bodies Marginal osteophytes may develop later and the femoral condyles occasionally show " mirror " lesions.

Clinical Features

The patient is commonly a young adult, or in early middle age and the onset is insidious, or may be precipitated by a minor injury such

as a twist or a strain. Discomfort rather than pain is experienced, and is not well localized. Later there may be pain and effusion The symptoms are intermittent, with intervals of freedom. Apparently chondromalacia does not necessarily progress and osteo-arthritis seems to be a relatively uncommon development At the more advanced stage, which is reached by comparatively few, the pain and swelling become constant, with exacerbations caused by stress, and most games and heavy work are impossible. A "catching" of the knee during flexion and extension, but not locking, is complained of There is pain on rubbing the patella on the femur, and tenderness on pressure over the articular surface of the patella; this can be elicited by displacing the patella laterally Radiographs are useful in excluding other joint diseases but the tangential view may show irregularity of the articular surface

Treatment

This may be no easy matter. When symptoms are slight the condition tends to improve spontaneously, but rest and short-wave diathermy may help. When disability is severe the patella may be exposed and small areas of affected cartilage shaved off When there is extensive disease either the whole articular surface of the patella may be removed, or the patella itself may be excised. Excision is usually indicated when the femur is involved Cave *et al* say that if operation becomes necessary a conservative procedure is indicated They deprecate removal. Through a long parapatellar incision the patella is turned and examined. Unless the menisci are well preserved, which is unusual, both are removed The posterior part of the patella is removed with a saw and thinned to approximately one-quarter of its original size. The remaining surface can be completely covered by a flap of infrapatellar fat pad and synovial membrane turned up from below.

HABITUAL OR RECURRENT DISLOCATION OF THE PATELLA

The patella may be displaced as a result of injury, or congenital abnormality, the dislocation may be upward, lateral, or medial, though clinically all others save the lateral displacement are exceedingly rare

Medial dislocation usually results from injury, but may occur in severe cases of genu varum. Occasionally as a result of injury the bone may rotate on its long axis, so that one of its borders engages between the condyles of the femur. This is a rare form of dislocation. The upward dislocation is also traumatic in origin, for there has usually been a neglected rupture of the ligamentum patellæ.

The commoner lateral dislocation is the most important and also the type most liable to become habitual or recurrent, indeed, it is the lesion usually implied by the term recurrent dislocation or "slipping patella"

The condition may occur from—

(i) *Congenital causes*, as in cases of poor development of the lateral femoral condyle, congenital anomalies of the patella, mal-attachment of the ileo-tibial tract, and in external rotation of the tibia

(ii) *Rachitic causes.* Lateral displacement of the patella may be associated with rachitic genu valgum As the knock-knee is flexed, the bone slips over the condyle, but at first complete restitution occurs when the leg is extended again. Later secondary changes may render the dislocation permanent.

(iii) *Traumatic causes* This type usually occurs in females, often in adolescence, and it is often associated with a varying degree of genu valgum, or with an extra long ligamentum patellæ. Occasionally, too, the whole joint is of the loose relaxed type, and sometimes the lateral condyle is small. These conditions predispose to the occurrence of the dislocation, since they all favour the outward pull of the quadriceps (Goldthwaite)

The usual injury is a blow or kick, but not uncommonly the displacement is the result of muscular action.

Clinical Features of Recurrent Dislocation

In mild cases the patella just slips momentarily over the condyle and the patient complains of the knee giving way and of the synovitis that follows the incident. Diagnosis in such cases is difficult

Each recurrence is usually precipitated by a sudden contraction of the quadriceps when the knee is extended or semi-flexed and the foot and leg everted, so that the insertion of the ligamentum patellæ comes to lie more laterally, and the quadriceps is allowed to drag with increased force on the already unstable bone.

At the time of the attack, the patient usually falls to the ground

When the displacement is of frequent occurrence, little or no pain is experienced, but when long intervals elapse between the attacks, the accident is associated with considerable pain, disability, and swelling of the joint.

Fig 344 —Recurrent Lateral Dislocation of the Patella

The lateral deviation of the patellar tendon is evident

The quadriceps and the vastus internus are usually wasted and the patellar tendon unduly lax Lateral movement of the patella is more than on the other side or more than

normal. A radiogram may show the patella to be situated more laterally and higher than it usually is.

Reduction is generally easy The knee is first fully extended, and then the thigh flexed to relax the quadriceps. The knee-cap is then

FIG. 345 —Congenital Dislocation of the Patella
Radiograph showing in this case a degree of genu valgum and a small lateral femoral condyle

manipulated into position by pushing it medially, at the same time correcting any rotation. The more frequent the displacement, the easier the reduction becomes, ultimately, indeed, the patient may learn to correct the dislocation himself In time, however, the repeated recurrences result in a relaxed, weakened, and unstable joint.

TREATMENT

Occasionally, recurrence may be prevented by the use of a firm bandage, or knee-cap, though as the condition is extremely disabling and annoying more radical measures are usually demanded. In addition to mechanical measures, a number of operations have been suggested and performed

Conservative Treatment.

This is of value only when the displacement is minimal. The inner side of the heel is raised. The patient is also instructed to walk with the

toes inturned, and the quadriceps, and in particular the fibres of the vastus medialis, are developed to their fullest extent.

Operative Treatment.

There is a wide choice of operations, and the final decision between them depends on the cause of the error

(1) **Osteotomy.** If knock-knee is the cause of the habitual dislocation, the obvious line of treatment is to correct the deformity and so alter the direction of the pull of the quadriceps. Genu valgum should be treated by supracondylar osteotomy, carried out through a small incision on the medial side of the knee immediately above the adductor tubercle. After the bone has been fractured, the lower fragment should be slightly rotated medially, to bring the lateral condyle further forward, while a certain degree of bow-leg can with advantage be aimed at since it increases the probability of improvement. The after-care is simply that of an osteotomy or fracture—plaster for six or seven weeks, and thereafter a walking caliper for four or five months.

(2) **Albee's Operation.** A semi-lunar skin incision reaching from above the lateral condyle to below the tibial tubercle is made round the lateral margin of the patella. The condyle is exposed, and a longitudinal incision 2 inches long made about ½ inch behind the anterior articular surface with a broad osteotome The fragment of bone thus marked out is elevated or eased up slightly out of its bed, i e a green-stick fracture is produced through the intercondylar groove. A wedge-

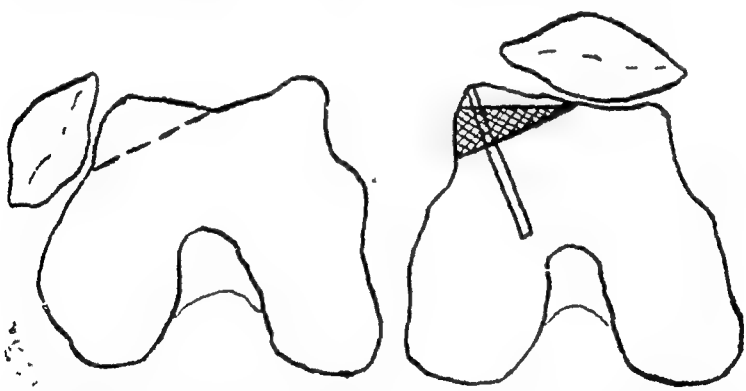

Fig 346 —Recurrent Lateral Dislocation of the Patella.
Albee's method of treatment by insertion of bone graft under the raised lateral condyle of the femur.

shaped piece of bone removed from the crest of the tibia is then inserted into the gap between the separated fragment and the remainder of the condyle. If necessary, the graft and the slip of bone it supports may be secured in place by a bone pin driven through them and into the condyle, but usually the soft tissues hold them as firmly as is necessary The skin wound is closed by continuous sutures of plain catgut, and a plaster-of-Paris case applied and kept on for three weeks At the end of this time, massage and passive movements may be begun.

(3) Transplantation of the Tubercle of the Tibia. An incision is made vertically downwards from the lateral border of the patella to the outer side of the tubercle of the tibia, from which point it deviates medially to end over the inner aspect of the tibia. The ligamentum patellæ is then defined, and, along with the small block of bone to which it is attached, it is separated from the tibia. The shortened structures on the lateral aspect of the patella are divided to allow it to move freely over to the medial side of the joint. A gap or bed is now made on the antero-medial aspect of the upper end of the tibia, its shape corresponding to that of the bony block at the end of the ligament The block is now inserted into its new bed and secured in place by a vitallium screw nail

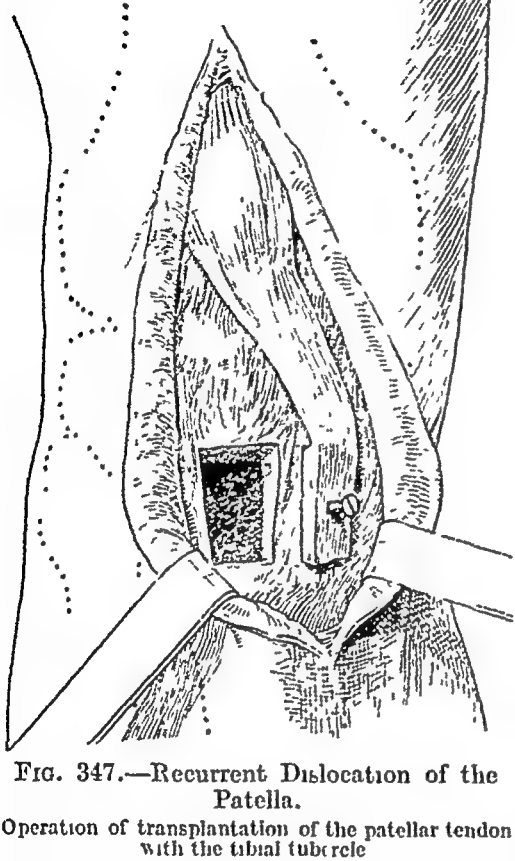

Fig. 347.—Recurrent Dislocation of the Patella.
Operation of transplantation of the patellar tendon with the tibial tubercle

A compression bandage is applied for two weeks and then the stitches are removed The leg is encased in a long groin-to-ankle plaster case. It is wise to wait a few weeks before starting quadriceps exercises in case vigorous contractions dislodge the screw.

Choice of Operation. The author practises the complete transplantation of the infra-patellar ligament and its attached segment of bone to the medial side of the tibia He has found this operation entirely satisfactory. If the contracture of the tissues on the lateral side of the patella is marked he performs in addition a capsulotomy. If there is marked genu valgum a corrective osteotomy is carried out.

LOOSE BODIES

The occurrence in joints of a variety of types of loose body has long been recognized. Practically every joint in the body has been reported on as containing such bodies, but they are most frequently found in the knee-joint An opportunity is taken here, therefore, of reviewing the whole subject.

Timbrell Fisher has done much to clarify our understanding of the pathology and the etiology of loose bodies, and his classification has

found almost universal acceptance. In some respects it is confusing, however, and the author has now adopted the following grouping:

A Classification of Loose Bodies

A. Fibrinous Loose Bodies (structureless bodies, composed of fibrinous material, or of necrotic synovial membrane).

Traumatic . . 1. After hæmorrhage.

Pathological . . In association with—
1. Tuberculosis.
2. Chronic synovitis.

B. Fibrous Loose Bodies (composed of fibrous tissue)

Traumatic . . 1. Organization of hæmorrhage into villus.

Pathological In association with—
1. Tuberculosis (nodular tuberculosis)
2. Syphilis (gummata).
3. Osteo-arthritis.

C. Cartilaginous Loose Bodies (composed entirely of cartilage cells).

Traumatic . Separation of whole or part of an intra-articular fibro-cartilage, e g. meniscus.

D. Osteo-Cartilaginous Loose Bodies.

Traumatic . 1 Displacement of non-articulating epiphysis.

Pathological . 1 Detachment of portion of articular surface (osteochondritis dissecans).
2. Detachment of osteophytes, in—
Tabes dorsalis,
Osteo-arthritis.
3 Separation of sequestra in—
Tuberculosis,
Acute arthritis.
4. Synovial chondromata.

E. Miscellaneous Loose Bodies.
1 Introduced Foreign Bodies.
2. Lipoma.
3. Angioma.
4. Secondary Carcinoma, etc., etc.

The above table includes the whole range of loose bodies, but it should be understood that the majority of these are of very rare occurrence, and, for practical purposes, the pathological diagnosis rests between osteo-arthritic loose bodies, synovial chondromata, osteochondritis dissecans, and displaced epiphyses. Some of the above conditions may now be considered in greater detail.

A. Fibrinous Loose Bodies, or Necrotic Synovium

The typical fibrinous loose bodies arise usually after a traumatic intra-articular hæmorrhage, and are often laminated. Large numbers are present

The pathological type—composed of necrotic synovial tissue—are usually associated with chronic synovitis or arthritis, especially of tuberculous origin They are multiple, and constitute the melon-seed bodies so distinctive of certain of the more chronic forms of tuberculous arthritis.

B. Fibrous Loose Bodies

These may be attached to the synovial membrane, or free in the joint cavity.

The traumatic type arises at the site of an injury to the synovial membrane. There is usually a breach of surface; and as a result of the irritation caused by the constant movement of the joint, a condition of chronic inflammation is set up. In consequence, a pedunculated tag is formed which sooner or later separates into the joint.

The pathological type occurs in association principally with tuberculosis and osteo-arthritis—both diseases in which villous overgrowth of the synovial membrane is common. The hypertrophied villi project more and more into the joint; in some cases, the base becomes attenuated to form a pedicle and ultimately the villus may drop off actually into the joint cavity All stages of "detachment" may be observed in the same joint.

Gummata of joints are not common.

C. Cartilaginous Loose Bodies

Loose bodies composed entirely of cartilage are rare, and are derived from one or other of the semilunars, usually the medial; they originate from the central part of a longitudinal tear subject to secondary trauma Jones and Lovett report a case where a rounded mass, the size of a large bean, was the only trace of a vanished medial semilunar. The connection between the mass and the missing cartilage was assumed, since the body had retained a fibrous attachment corresponding to that of the semilunar.

D. Osteo-Cartilaginous Loose Bodies

Traumatic Type

(*a*) **Displaced Non-articulating Epiphyses.** This type is found in its most classical form in the elbow joint, where, as a result of certain forms of trauma, the medial epicondyle is forcibly displaced into the joint cavity. The displaced fragment frequently goes unrecognized, and attention may be drawn to it only by the persistent limita-

tion of joint movement, and by the occurrence of signs and symptoms indicating a lesion of the ulnar nerve. Platt has drawn attention to the frequent occurrence of nerve phenomena in association with the injury, and the importance of its early recognition is thus increased.

At the time of injury, the joint is usually so swollen that deformity is not apparent, but a point of extreme tenderness is found over the situation of the epicondyle

In late cases, when the radiographic examination may suggest the presence of a loose body, the possibility of this lesion may be suggested by the increase of the "carrying angle" (cubitus valgus) which almost inevitably results.

TREATMENT

In immediate cases, after the swelling has subsided a little, the joint is opened, the detached fragment replaced in position and secured there by a small peg or nail.

In late cases, when the fragment constitutes a free joint body, it should be removed

Some observers consider that the frequency of late ulnar neuritis as a sequel of this injury justifies the performance of anterior transposition of the ulnar nerve at the same time as the fragment is replaced or excised.

(*b*) Detached Portions of Articular Surface—Osteochondritis Dissecans. Osteochondritis dissecans is a condition in which a fragment of articular cartilage, with or without subchondral bone, becomes either partially or completely separated, at characteristic sites on the articular surfaces of certain joints.

The joint most commonly affected is the knee, but similar lesions have been found in the elbow, ankle, and hip, and even in the head of a metatarsal. In some cases the condition is bilateral.

The typical sites in the various joints are as follows: in the knee, the medial condyle, close to the intercondylar notch; in the elbow, the capitellum; in the ankle, the trochlear surface of the astragalus, and in the hip, the superior aspect of the head of the femur

ETIOLOGY

The actual mechanism of the detachment of portions of the articular surface is a much debated problem. Originally it was believed that following trauma there developed a pathological process—"quiet necrosis"—which led to the gradual extrusion of a part of the traumatized surface This was the view of Paget and of König, but both these observers agreed that by the time the body separated all signs of the underlying pathological process had disappeared It was this conception of the process that led Konig to name it "osteochondritis dissecans," a name that has remained firmly entrenched in the literature although its aptitude is by no means certain.

Since the original observations, many alternative explanations have been proposed. In the main, they may be grouped into those that attribute it to trauma and those which postulate some primary disturbance of the articular surface.

The traumatic theory has been especially championed by Timbrell Fisher, and by Fairbank. Among the possible sequelæ of trauma are included subchondral fracture with gradual separation of a fragment, damage to the vessels supplying a portion of the articular surface, and a post-traumatic inflammatory condition.

FIG 348 —Displaced Non-articulating Epiphysis

The medial epicondyle of the humerus has been fractured and is displaced into the joint It still has attachments to the ulna by its ligaments

The view that the fragment is detached after a localized fracture is at first sight supported by the fact that trauma in many cases is a feature of the history It seems likely that the trauma to the usual site in the medial condyle is caused by the medial tibial spine The medial spine is always longer than the lateral and it has been pointed out that in osteochondritis dissecans it appears hypertrophied It is suggested that forced rotation of the tibia on the femur or the femur on the tibia or forcible medial displacement of the tibia on the femur, will cause the spine to impinge on the articular surface of the medial condyle. In the case of the hip, the lesion occurs on the superior surface of the head where it might conceivably be produced by forcible contact with the acetabular roof.

Fairbank supports the view that the lesion is a fracture. He bases this conclusion on the following facts:

1. It occurs most frequently in adolescents and young adults indulging in vigorous pastimes.

2. Typical lesions are seen in radiographs and revealed by operation after definite and sometimes recent trauma.

3. A lesion at the typical site may involve the cartilage only, the detached fragment consisting of normal articular cartilage. In such cases there is a definite history of trauma.

Fig 349.—Osteochondritis Dissecans
The loose body is seen in the joint space and its source on the articular aspect of the medial condyle

4. There is entire absence of inflammatory changes in and about the lesions.

5. The gross appearances when operation is performed early suggest nothing but a simple recent fracture When sufficient time has elapsed for changes to occur, the only ones that do take place are those which would be expected from an effort on the part of the tissues to repair the damage Exactly similar changes are occasionally found on the more exposed parts of the femoral articular surface, where the traumatic origin of the lesions is never disputed.

6 When the detached fragment is suspended by a vascular pedicle the bone in it is not dead and is not a sequestrum.

bodies in the joint, the body lying quietly in its bed on the medial femoral condyle. In other cases, even though the fragment is not displaced, the symptoms may be those of a mild chronic joint disturbance, such as vague discomfort with persistent or recurrent effusion (both aggravated by violent exercise), weakness, and loss of confidence in the joint. The largest number of cases fall into the *third group* in which there is a definite history of trauma, and of a chronically troublesome knee joint for two or three years. The complaint is of a feeling of soreness, or definite pain on weight-bearing, associated with swelling. The joint tends to give way and stiffness is common. These symptoms are sometimes continuous, but more often intermittent, and are often associated with locKings of the joint arising from the sitting or squatting position. Some patients occasionally feel a loose body in the joint. The quadriceps is usually wasted in these cases and in some there is uniformity on the palpation of the affected area of the articular cartilage. Occasionally the depressed tibial or femoral loose body may be palpated.

Fig. [illegible] Loose Bodies in the Knee Joint.

[illegible]

[illegible] the symptoms of a meniscus the knee should always be examined [illegible] the patient sitting [illegible] the knee is closely indicated by a [illegible] the [illegible] of the meniscus [illegible] the [illegible] bone [illegible] the [illegible] and [illegible] should be [illegible] beneath [illegible] only [illegible] ment of the [illegible] and [illegible]

The appearance of the body varies greatly; it is generally oval in shape, and with a plane and convex surface. The convex surface is often rough, and may consist of cancellous bone, but when the body has existed in the joint for a long time it changes its character, the rough surface becomes smoothed out, and rounded, and the cartilage may proliferate until the body acquires considerable proportions. The over-exuberant production of new cartilage cells may lead to the formation of a veritable cartilaginous tumour.

Fig 351.—Osteochondritis Dissecans of the Talus following an Adduction Fracture of the Ankle

Symptoms

From the standpoint of the clinical history cases may be placed in three fairly well-defined groups In *one group* are those cases where the knee is painful, swollen and tender, and locked in from 15 to 45 degrees of flexion The appearance is suggestive of injury and the condition has often begun suddenly, subsequent to a twist or other minor injury There is usually no history of previous disability. X-ray examination reveals an osteochondritic focus on the medial femoral condyle, with one or it may be two loose bodies in the joint The *second group* includes cases which are almost asymptomatic. It occasionally happens that an X-ray of a supposedly normal knee, taken for comparison, reveals a definite osteochondritic focus without free

bodies in the joint, the body lying quietly in its bed on the medial femoral condyle In other cases, even though the fragment is not displaced, the symptoms may be those of a mild chronic joint disturbance, such as vague discomfort with persistent or recurrent effusion (both aggravated by violent exercise), weakness, and loss of confidence in the joint. The largest number of cases fall into the *third group* in which there is a definite history of trauma, and of a chronically troublesome knee joint for two or three years The complaint is of a feeling of soreness, or definite pain on weight-bearing, associated with swelling The joint tends to give way and stiffness is common. These symptoms are sometimes continuous, but more often intermittent, and are often associated with lockings of the joint on rising from the sitting or squatting position. Some patients occasionally feel a loose body in the joint. The quadriceps is usually wasted in these cases and in some of them there is tenderness on firm palpation of the affected area of the condyle with the knee flexed. Occasionally the depression left by the migratory loose body may be palpated



Fig 352 —Multiple Loose Bodies in the Knee Joint

Treatment

In the presence of symptoms the joint should always be explored. If, when the joint is opened, the articular surface is found to be unbroken, but the site of the lesion is clearly indicated by a change in the colour or texture or tension on palpation of the overlying cartilage, or the extent of the lesion is indicated by a groove, an attempt should be made to determine whether the circumscribed area of cartilage is movable or not. If it is movable, it should be excised, together with any loose bone beneath it, but if it is not movable, the problem is more difficult, and the condition of the cartilage within the circumference of the lesion should be the determining factor; if the cartilage is definitely soft, sodden, and rough, it should be excised even if it is unbroken, all loose bone should be removed, and the edges of the hole should be carefully bevelled; if the cartilage is almost normal in appearance, and the lesion only just discernible, and if there is nothing to suggest that a fragment of the bone is loose the lesion may safely be left alone Green and Banks protect the knee in such cases by a walking caliper or a plaster cylinder and get excellent results.

When the lesion presents the more usual appearance of the cartilage fractured, but with an unbroken portion holding the fragment more or less in position, the separation should be completed and the fragment removed The cartilaginous margins of the crater should be carefully bevelled when necessary, and any undermined portions removed. If the fragment is free in the joint and the radiographs show the site from which it came, the incision should be planned to allow inspection of the crater as well as removal of the loose body. In all cases the condition of the semilunar cartilage should be determined

Smithe has suggested that the loose fragment, or about-to-be-loose fragment, should be fixed to its bed. He does this after, in certain cases, freshening the bed by means of metal pins These are removed later when he finds the fragment reunited He reports good results.

The immediate prognosis and the prognosis for some years to come are undoubtedly good, but the remote prognosis is less favourable as there is reason to believe that osteo-arthritic changes are likely to occur sooner or later

Pathological Osteo-Cartilaginous Bodies

1. Detached Osteophytes in: (*a*) *Osteo-arthritis.* In osteo-arthritis, three forms of loose body may occur—synovial chondroma (see p 848), detached marginal osteophyte, and detached "epi-articular ecchondrosis" or central osteophyte

The marginal osteophytes are, in certain situations, prone to injury, and may be completely broken off, or fractured, though if the fracture is incomplete, the osteophyte may remain attached by a narrow pedicle Immediately after the injury the raw bony surface can be easily recognized, but it is soon covered over by proliferating cartilage

Such bodies are usually pear-shaped On section, the peripheral area is found to consist of well-developed fibro-cartilage, and the central portion of dead bone with a well-defined cancellous arrangement

Rarely, there may be more than one detached osteophyte, and frequently in the same joint there are other forms of osteo-arthritic loose body, e g. synovial chondromata

The occurrence, in osteo-arthritic joints, of localized areas of hyperplasia of the articular cartilage was first demonstrated by Shattock. These "epi-articular ecchondroses" are essentially similar in nature to the osteophytic outgrowths at the articular margin, and the central portion is likewise often ossified Like the marginal outgrowth, these central osteophytes may become broken off, and form loose bodies

(*b*) *Tabes Dorsalis* In the hypertrophic form of Charcot's disease, osteophytic formation may also give rise to loose bodies, similar to the osteophytes of osteo-arthritis, but, owing to the more extreme nature of the pathological process in tabes, commonly bigger

2. For the sake of completeness, two types of loose body may be included—the tuberculous and the acute inflammatory

When the lesion presents the more usual appearance of the cartilage fractured, but with an unbroken portion holding the fragment more or less in position, the separation should be completed and the fragment removed The cartilaginous margins of the crater should be carefully bevelled when necessary, and any undermined portions removed. If the fragment is free in the joint and the radiographs show the site from which it came, the incision should be planned to allow inspection of the crater as well as removal of the loose body. In all cases the condition of the semilunar cartilage should be determined

Smillie has suggested that the loose fragment, or about-to-be-loose fragment, should be fixed to its bed He does this after, in certain cases, freshening the bed by means of metal pins These are removed later when he finds the fragment reunited. He reports good results.

The immediate prognosis and the prognosis for some years to come are undoubtedly good, but the remote prognosis is less favourable as there is reason to believe that osteo-arthritic changes are likely to occur sooner or later

Pathological Osteo-Cartilaginous Bodies

1. Detached Osteophytes in: (*a*) *Osteo-arthritis* In osteo-arthritis, three forms of loose body may occur—synovial chondroma (see p 848), detached marginal osteophyte, and detached "epi-articular ecchondrosis" or central osteophyte

The marginal osteophytes are, in certain situations, prone to injury, and may be completely broken off, or fractured, though if the fracture is incomplete, the osteophyte may remain attached by a narrow pedicle. Immediately after the injury the raw bony surface can be easily recognized, but it is soon covered over by proliferating cartilage.

Such bodies are usually pear-shaped On section, the peripheral area is found to consist of well-developed fibro-cartilage, and the central portion of dead bone with a well-defined cancellous arrangement.

Rarely, there may be more than one detached osteophyte, and frequently in the same joint there are other forms of osteo-arthritic loose body, e g. synovial chondromata

The occurrence, in osteo-arthritic joints, of localized areas of hyperplasia of the articular cartilage was first demonstrated by Shattock These "epi-articular ecchondroses" are essentially similar in nature to the osteophytic outgrowths at the articular margin, and the central portion is likewise often ossified Like the marginal outgrowth, these central osteophytes may become broken off, and form loose bodies

(*b*) *Tabes Dorsalis* In the hypertrophic form of Charcot's disease, osteophytic formation may also give rise to loose bodies, similar to the osteophytes of osteo-arthritis, but, owing to the more extreme nature of the pathological process in tabes, commonly bigger.

2. For the sake of completeness, two types of loose body may be included—the tuberculous and the acute inflammatory.

surfaces While carrying out some movement, the patient experiences a sudden intense pain in the joint; if it is the knee joint he usually falls, and finds that the limb is apparently powerless The joint is usually locked in a position of semi-flexion and neither extension nor further flexion are possible

There may be an obvious swelling at one part of the joint, pressure on which will release the joint and terminate the attack, or the body may become dislodged by some particular movement accidentally carried out by the patient himself Occasionally, however, an anæsthetic must be administered before the joint can be "unlocked."



Fig 354 —Loose Body in the Elbow Joint

After the attack, there may be an effusion into the joint; such recurrent synovitis is apt in time to lead to relaxation of the ligaments and instability of the joint

A characteristic point in the history is the variable site of the pain, in successive attacks, it may occur at widely differing parts of the joint, in contradistinction to cartilage lesions where the situation of the pain is constant.

Atypical Symptoms. In many cases, the usual history may not be forthcoming and the reason for this becomes apparent when the pathological nature of the loose body is considered.

In the *pathological types of loose body*, the symptoms are usually masked by those of the major disease, and the body may be overlooked in consequence Multiple bodies, e g multiple synovial chondromata, are usually small, and apt, therefore, to become impacted more frequently The accident is not usually attended with the classical symptoms, indeed, it may give rise to remarkably little pain or inconvenience

The *classical traumatic type of loose body*—derived from the articular surface—may be associated with puzzling symptoms at the beginning The explanation of these is found in the degree of attachment that exists between the body and its bed, for only where it has been completely cast off can the typical phenomena occur.

Diagnosis

X-ray examination is invaluable in the diagnosis of loose bodies, which are osseous or osteo-cartilaginous, and the film will also reveal coexisting pathological changes In connection with the knee joint, reference may be made in passing to an occasional source of error in the

suggested that this is due to the deposition, in layers, of calcium salts, derived from the synovial fluid which has permeated the body. Certain of the tumours, too, are definite osteo-chondromata, containing a nucleus of bone

The *multiple chondromata* are smaller than the single variety, and may be present in enormous numbers Berry has recorded a case in which no fewer than 1,047 such cartilaginous bodies were found in the knee joint of a woman 22 years of age.



Fig 353 —Loose Body in the Knee Joint.

The size and shape of the individual tumours vary. Groups of them may occupy pouches and recesses of the synovial membrane, and they may be flattened from mutual compression Usually there is a combination of pedunculated and free tumours, and their general character is similar to that of the single variety save for the points discussed above.

Diffuse chondromata (synovial chondromatosis) is a remarkable condition in which the whole synovial membrane is studded with discrete nodules of cartilage, which undergo ossification, and nearly all of which have a nucleus of true bone The process is thus more commonly an osteo-chondromatosis than a pure chondromatosis The tumours may become detached, and lie free in the joint cavity.

Clinical Features attending Loose Bodies in Joints

Typically, the presence of a loose body in a joint is associated, sooner or later, with what may be termed a series of classical symptoms, due to the impaction of the body between the opposing articular

the joint, they may be removed by a median exposure through the popliteal space, as advocated by Brackett.

After the vertical skin incision of 6 inches is made, the dissection is carried down between the two heads of the gastrocnemius, and, since the branches of the tibial nerve run laterally, it is recommended that the nerves and the vessels should be retracted to the lateral side. The capsule is carefully cleared by blunt dissection, to enable the loose body to be palpated before the capsular incision is made.

For loose bodies in the postero-lateral compartment, an incision parallel to the anterior border of the biceps may be used The common peroneal nerve lies posterior to the biceps and should not be in danger. The biceps is retracted backwards, the ilio-tibial band divided longitudinally, and the capsule opened, either above or below the tendon of the popliteus. The posterior horn of the lateral semilunar may be explored through a similar incision

When loose bodies are located in the postero-medial compartment, an incision may be made along the anterior border of the sartorius The muscle is retracted backwards and the capsule is opened behind the posterior margin of the medial ligament. There is a small pocket behind and rather distal to the posterior horn of the medial meniscus in which a loose body is often trapped. This should be explored Although the body is loose X-rays at intervals show it always in the same place as it cannot escape from the pocket.

PELLEGRINI-STIEDA'S DISEASE

(Post-traumatic para-articular osteoma)

This disease was first described by Kohler in 1903, although it is usually known by the names of two authors who wrote about it two years later The characteristic feature is the presence of a nodule of new bone or calcium in the region of the medial condyle of the femur. The exact site is now believed to be the medial ligament of the knee. A similar condition has been seen in the ankle and elbow joints It occurs usually in adult males and follows trauma which may be slight or severe, and of either the direct or indirect type. Following injury the earliest symptoms are those of a traumatic synovitis of the knee, followed by a period of improvement, though the knee never completely recovers, indeed, after weeks or months pain and disability may increase until a point is reached at which they are stationary Movement is then considerably limited and there is tenderness over the medial condyle, and often the condyle appears hypertrophied on palpation

The symptoms are due to the interference with the function of the medial ligament resulting in at least limitation of flexion from either adhesions or loss of elasticity

The condition is most commonly unilateral: bilateral involvement is rare. An X-ray examination is essential for diagnosis and shows a bony shadow alongside the medial condyle which may be uniform

interpretation of X-ray films. An appearance simulating a loose body is often given by a sesamoid bone in the lateral head of the gastrocnemius, which is present in about 15 per cent. of individuals, and frequently bilateral It is recognized by its regular sharply-contoured oval or circular form, and its constant position.

Treatment

A loose body which is giving rise to symptoms should be removed. When the body is free in the joint cavity, it is often a matter of considerable difficulty to locate it at the time of operation; it is often advantageous, therefore, to have the patient under observation for a day or two before operation. Should he at any time feel the loose body in a superficial position, the surgeon is informed, and, under aseptic precautions, the body is transfixed by a needle; the whole part is then carefully sterilized, and the body removed through a small incision under local anæsthesia.

If the history suggests a pedunculated loose body, which always makes its appearance at a definite spot, there is no occasion for any delay in undertaking operation. When loose bodies are multiple in the knee joint, and when a single loose body refuses to become palpable, the joint should be laid open by Timbrell Fisher's method.

Timbrell Fisher's Exposure. A slightly curved incision is made, commencing in the mid-line 1 inch above the uppermost limit of the supra-patellar pouch, and skirting the medial border of the patella and the medial border of the ligamentum patellæ, to end a little to the inner side of the tibial tubercle The flaps are reflected, and a mid-line incision made through the layer of fascia covering the quadriceps tendon, the patella, and the ligamentum patellæ The medial fascial flap is now reflected well beyond the medial border of the patella and its ligament Thereafter, it is strongly retracted, and the capsule divided ¼ inch from, and parallel with, the medial border of the patella The incision is carried obliquely upwards through the inner fibres of the quadriceps tendon, care being taken to avoid incising any muscular fibres of the vastus internus Below the incision is carried through the capsule at the medial border of the ligamentum patellæ The synovial membrane is divided along the same line, and the patella dislocated to the lateral side of the joint. In this way, an excellent exposure of the whole anterior compartment of the joint is obtained Occasionally, the lateral part of the joint is obscured by the ligamentum mucosum, which may have to be divided, and subsequently resutured

This exposure may also be used for operations on the tibial spine, and sometimes for operations on the cruciate ligament.

Loose Bodies in the Posterior Compartments

When loose bodies are situated in the posterior compartment of

CHAPTER XVI

AFFECTIONS OF THE FOOT

STATIC DISTURBANCES OF THE FOOT

At all ages, foot disabilities contribute largely to the work of orthopædic clinics. A proper conception of the mechanism of the foot in health and disease is therefore of paramount importance.

The human foot has become greatly specialized for the performance of two divergent functions.

1. In standing, it must provide a stable support for the body-weight—its passive function—cf. balance.

2 In walking, it must, in addition to supporting the body-weight, provide a resilient spring or lever by which the body can be propelled forwards—its active function—cf. propulsion.

These objects are fulfilled by the architectural arrangement of a number of small, spongy, elastic bones grouped together in the form of a series of arches and for each of the functions muscular contractions are essential, their importance being greater in propulsion than in balancing.

In addition to conferring resiliency to the foot, the arches serve for the dispersal of force applied to the plantar aspect of the foot, and they provide necessary space for the passage of nerves and vessels forwards towards the soles

A. The Longitudinal Arch extends from the calcaneus to the head of the first metatarsal, its summit being placed at the mid-tarsal joint The posterior pillar of the arch is short—from the calcaneus to the joint—whereas the anterior is long and its slope more gradual

Variations in the height of the arch are achieved by alteration in the position of the talo-navicular joint, induced by the contraction or relaxation of the tibial muscles; despite this, the arch is to some extent permanent, and gross alterations in its composition are to be regarded as pathological

B. The Transverse Arch becomes apparent when the feet are placed together It extends from the lateral border of one foot to the lateral border of the other, and has no true summit as the medial malleoli prevent the absolute apposition of the medial borders of the feet

C. The Anterior Metatarsal Arch disappears with weight-bearing It extends from the first to the fifth metatarsal heads, and

or composed of a series of separate small deposits. In the early stages the abnormal bone shadow is hazy and ill-defined but when activity has ceased the edges are clear-cut. They are usually first seen about the level of the knee joint and while in early cases they are quite separate from the condyle, in late cases the shadow may appear to be continuous with the condyle

The histological structure of the nodule varies. It may consist of a deposit of lime salts amongst the fibres of the medial ligament, or may be composed of formed bone.

Etiology

On analogy with similar disturbances—traumatic myositis ossificans—it may be presumed that as a result of trauma there is hyperæmic decalcification of the medial condyle at the site of attachment of the medial ligament. The abstracted calcium is redeposited in the traumatized or œdematous ligament and may provide the local excess of calcium demanded for the formation of bone. Occasionally the nodule disappears completely in the course of time, but more often it enlarges till it attains a certain size, at which it persists. Very rarely it may grow to a mass of considerable size and give rise to mechanical disability.

The development of the ossification may be prevented by early recognition of the possibilities of the ligamentous strain that precedes the affection, and the injection of the area with hydro-cortisone, hyaluronidase and local anæsthetic. A compression bandage over a felt pad is then applied

Passive movements should be prohibited as they so easily produce more bone and more stiffness.

In established cases with a well-marked area of calcification an early restoration of full function must not be expected. The disease is self-limiting and provided the case is not over-treated a full recovery may be expected in two to six months The slow return of flexion in such a case may provide the temptation to use passive movements or even manipulation. These forms of treatment are definitely detrimental The patient's own active flexion to a point short of producing pain, together with quadriceps exercises, will eventually produce complete recovery

Surgical removal is seldom indicated, but might be necessary if the deposit attained a size of such dimensions as to cause definite mechanical interference with the function of the joint, but only when it has reached its maximum size and is in an entirely quiescent state.

[illegible] is abduction, and these movements also originate at the talo-navicular joint.

When the foot is in a position of abduction and eversion, it is sometimes said to be pronated; supination similarly consists of a combination of adduction and inversion. These terms are confusing and should be avoided.

[illegible] Specimen of a Congenital Fusion between the Talus and the Navicular—a rare cause of flat foot.

THE UNSTABLE FOOT

(Flat foot; pes planus; pes valgus; etc.)

The factors which in combination preserve the long arch of the foot are the shape of the bony segments composing it, the plantar ligaments, and the postural activity of the tibial group of muscles.

It follows, therefore, that flat foot may arise either as a congenital or acquired deformity as a sequel to interference with one or other of these factors.

Congenital Flat Foot.

This is a comparatively rare condition. The deformity, however, is obvious. The foot is boat shaped, being [illegible] in front and behind [illegible] the abnormal direction of the talus which point [illegible] and gives rise to the prominent convexity of [illegible]. The [illegible] [illegible] [illegible]

its summit is placed opposite the heads of the second and third metatarsals. Normally the anterior arch has no great weight to sustain, and it derives adequate support from the transverse inter-metatarsal ligament, connecting the plantar aspects of the heads of the bones.

D. The Internal Arch is formed by the medial border of the foot, and its concavity is directed medially.

Despite occasional assertions to the contrary, it is reasonably certain that the arches of the foot are present at birth, in that the cartilaginous skeleton of the foot has already assumed an arched formation When the child begins to support the body-weight, however, it will be seen that the foot becomes flat, and does not develop for some years an arch which persists during weight-bearing. This is due to the fact that though it possesses its arch as an inherent right, the factor most potent in the preservation of that arch has not yet been

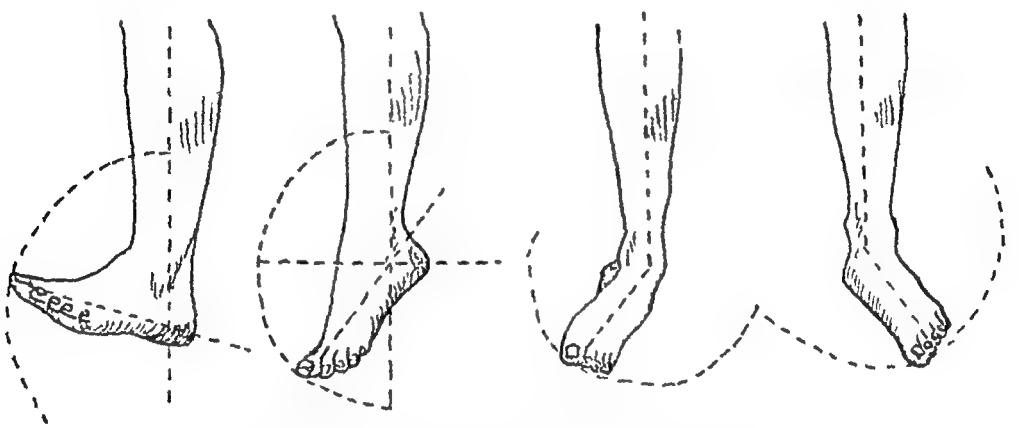

Fig 355 —The Movements of the Normal Foot

acquired; that factor is the postural tone of the long tibial muscles, which is a late human development In the foot of the orthograde primate the tibial muscles are concerned with the active movement of the metatarsus on the tarsus, and have no postural activity. Should they fail to develop it in the human child, the original arches of the foot are flattened out by weight-bearing, and the arches are never restored—as in the so-called congenital forms of flat foot

The Movements of the Foot.

It is usual to include the ankle in any consideration of movements of the foot The movements at the ankle joint consist of plantar flexion and dorsal flexion.

When the whole foot is rotated on an antero-posterior axis so that the sole faces medially, it is said to be inverted, the opposite movement is eversion, these actions occur mainly at the subtaloid joint.

The anterior part of the foot is able to move on the posterior part on a vertical axis, when the forefoot is thus brought in towards the midline of the body, it is said to be adducted The counterpart of

on a foot whose position has been altered by the muscular error. They are considered separately in Chapter X

The *static type of acquired flat foot* is one of the most common and important of orthopædic complaints

The Etiology of Static Flat Foot

Flat foot arises when the postural muscles of the longitudinal arch become unable to fulfil their function. This arch transmits the body-weight to the ground through a wide base of support The talus is the keystone, the calcaneus is the posterior pillar, and the navicular, cuneiforms and metatarsals form the anterior pillar. If the weight is passed through the subtaloid midtarsal region the stress passes through the bones, but if a little further forward then the ligaments take the strain. This stretching of the ligaments calls into play the muscles which shift the strain back to the normal area This is the balancing action of the foot, brought into play by the postural activity of the muscles This reflex is not present at birth but is gradually acquired in the first year or two after. In the first efforts of walking a child usually walks with his feet flat and abducted A good deal of this is apparent because of large deposits of fat in the sole, though it is in part real from inability to use the calf muscles to lift the inner side of the tarsus. Balancing is gradually acquired and the deformity disappears. Balancing may be late in appearing and may, indeed, never appear, and the arch in such cases remains unstable and collapsed throughout life. Perkins points out that once this postural activity has been acquired there can be only one reason for pes planus or instability of the long arch—that the foot when at right-angles to the leg is not plantargrade, meaning that the three bearing points are not all equally on the ground. There are two common ways in which this may be so · (*a*) the calcaneus may be at fault and the heel is drawn up in an equinus deformity, and (*b*) the medial anterior pillar may be at fault and the big toe is off the ground as a result of a varus deformity.

The equinus deformity is compensated for by dorsiflexion at the mid-tarsal joint and this is followed by eversion with a consequent malalignment of body-weight Varus deformity is compensated for by eversion at the subtaloid joint and similar malalignment of body-weight. In the equinus foot the calf muscles do not grow as quickly as the tibia, and in the varus foot the bones outgrow the tibialis anterior. It appears, then, that the three main causes of foot strain are—faulty postural activity of muscles, an equinus deformity of the foot, and a varus deformity of the forefoot.

There are certain predisposing factors .

(*1*) *There is a general muscular hypotonus.* Convalescence after illness or after childbirth, for example, is apt to be associated with loss of muscular tone Also when growth is rapid, the muscular develop-

Treatment is never very satisfactory and offers little chance of improvement unless begun in the first few months of life. The deformity is corrected as far as possible under anæsthesia, the fore-foot being lined up with the hind foot In many cases it consists of reducing the talo-navicular dislocation by bringing the navicular into line with the head of the talus. This has usually to be done in stages, and often the tendo-calcaneus requires lengthening. In adolescence conservative treatment usually does not prevent the development of degenerative changes which necessitate a triple arthrodesis. However, Osmond Clark has described a new operation in which, after the division of the capsular ligaments and the interosseous talo-calcaneal ligament, the subluxation at the talo-navicular joint is corrected with the head of the talus being forced upwards. The foot is then manipulated medially until the talo-navicular and talo-calcaneal joints are articulated. This new position is held by transferring the peroneus brevis tendon into a vertical tunnel in the neck of the talus and sutured back on to itself to form a sling Immobilization in plaster of Paris is necessary for six to eight weeks In some cases after the subluxation is corrected the reduction may be retained by an extra-articular arthrodesis of the subtalar joint after the manner of Grice

Another type of congenital flat foot occurs in the presence of a structural anomaly of the tarsus, known as a talo-calcanean bridge. This has been described by Harris of Toronto as a bridge of bone joining the posterior aspect of the sustentaculum tali to the outer surface of the talus. It may be complete or incomplete and can be demonstrated by oblique X-rays It prevents movement between the bones and though deformity is slight in childhood when the bones are soft, with growth the calcaneus is forced into eversion. In adult life there is an extreme valgoid deformity. The symptoms resemble spastic flat foot in that spasm is present with the valgus deformity. Any treatment short of operation is useless, so when the condition is diagnosed by X-ray operation is indicated. In very young children it may be that of resection of the bridge, although more usually an arthrodesis of the subtaloid and mid-tarsal joints is carried out.

Acquired flat foot may be—

Osseous.
Ligamentous.
Muscular—paralytic, spastic, postural or static

The *osseous* variety may result from trauma to the bones (e.g. in run-over fractures, fractures of the navicular or calcaneus), or from disease of the bones.

The *ligamentous variety* may follow rupture or avulsion from their attachment of the plantar ligaments.

In the *paralytic* and *spastic* muscular types the flattening of the arch is a secondary and late effect, due to the effect of weight-bearing

the head of the talus is pressed forwards, downwards and medially, and the body of the talus may glide forwards on the upper surface of the calcaneus. The calcaneus itself is deviated to the medial side, and its anterior end depressed with the result that the sustentaculum tali, the head of the talus, and the tuberosity of the navicular come to form prominences on the medial aspect of the foot. The long and short plantar ligaments also yield gradually and eventually the deltoid ligament of the ankle as well. When the foot is viewed from behind, the tendo-calcaneus appears to be deviated laterally, the tibial tendons are seen to be overstretched, and the peroneal tendons adaptively shortened. During weight-bearing, a lateral radiograph of the foot shows a straight line or axis joining the talus, navicular, medial cuneiform, and first metatarsal bones. Jack has described how an unstable, everted foot may be produced by a "break" in either the talo-navicular or the naviculo-cuneiform joints.

In neglected cases two further changes ensue: the displaced bones are gradually altered in shape, the navicular and medial cuneiform bones for instance becoming shaped like wedges with the apices situated dorso-laterally, and there is a permanent alteration in the set of the tarsal bones, which amounts to a subluxation at the tarsal joints; secondly, portions of the joint surface now unused eventually show fibrillation of the articular cartilage, and osteo-arthritic outgrowths appear at the margins.

Symptoms

In the first stages, the patient notices that the feet are hot and uncomfortable — they "burn" after use, and perspire more freely than normally; later comes stiffness and lameness, and the feet become stiff after sitting or resting, and are most uncomfortable when the patient rises in the morning The gait becomes inelastic and clumsy, and there is a tendency to walk with the feet everted and not to rise on the toes.

Fig 358 —Weak Abducted Feet.

Pain. Pain is more severe when standing than when walking, since walking involves chiefly the use of muscles, whereas in standing the weak muscles relax and the whole body-weight is borne by the weakened ligaments The pain is experienced in several situations—under the tubercle of the navicular (from stretching of the inferior calcaneo-navicular liga-

ment may lag behind the growth of the other tissues. Severe trauma to the leg which is complicated by muscular atrophy is also a cause.

(2) *When normal muscles are excessively fatigued.* This may happen in occupations in the course of which the individual has to stand or walk for hours at a time, and is common, for example, amongst nurses, policemen and soldiers; or it may follow excessive exercise after a period of relative disuse, as in the typical case of the clerk who sits at his desk all week and indulges in long country walks during the week-end.

Relative muscular insufficiency may be caused by a rapid increase in the body-weight, and is commonly associated with obesity; the type of flat foot for which it is responsible is often found in conjunction with the rapid increase in the body-weight of women at the menopause and is the explanation of the foot symptoms so often complained of at that time.

Excessive fatigue may also result if the muscles of one limb have to bear a disproportionate share of the body-weight, as for example when the two limbs are of unequal length through lesions of the bones or joints, or when one limb has been amputated.

In addition to these predisposing causes, there are certain *precipitating factors*, viz.

(*i*) *Faulty Footwear.* The modern shoe has several bad features, two of which deserve mention: the pointed shape displaces the great toe laterally and crushes and distorts the other toes; and the more or less unyielding leather that is used, particularly for the sole of the shoe, tends to cause atrophy of the muscles of the foot.

(*ii*) *Bad walking.* The method of walking once taught in military schools is particularly bad; for the recruit is taught to walk with the toes pointing laterally, in which position he throws an undue strain upon the long arch of the foot and on its supporting muscles

(*iii*) *Loose Methods of Standing.* When much standing has to be done, it is an advantage to the feet to attempt to invert them at frequent intervals Standing with the feet everted puts an undue strain on the ligaments of the inner side and tends in time to produce a condition of weak foot in those who have to be on their feet for long periods Under these circumstances it is important to invert and adduct the feet at frequent intervals

(*iv*) *Varicose Veins* Varicose veins are frequently found in association with flat foot in the adult, and it is supposed that the chronic congestion leads to œdema of the tarsal ligaments, and the chronic oxygen deficiency interferes with the efficiency of the muscles on which the arches depend The observation has an important practical bearing, for in most cases attempts to improve the foot condition are unsuccessful until the varicose veins have been either cured or controlled.

Pathology

In the earliest stages of flat foot there may be few or no appreciable changes; as the calcaneo-navicular ligament yields, however,

Pressure Symptoms. The medial part of the sole of the boot wears more quickly than the lateral. The skin along the medial border of the heel and foot is thickened and painful, and a callous ridge may form in this situation; painful corns may form, too, in the weight-bearing areas, under the heads of the metatarsals.

The lateral displacement of the foot often forces the little toe against the leather of the boot, and induces the formation of a callosity or corn on its most prominent part The toes are compressed laterally even when the boot is not too narrow

The effects and symptoms of flat foot are not always limited to the feet, as additional lesions may result from the disturbance of the static equilibrium of the body. Thus synovitis may occur in the knee; backache is often present, with pain in the buttocks and in the sacral region, the hip joints may also be painful and irritable

Types of Weak Foot

From the point of view of treatment it is useful to divide acquired flat foot into four classes as is done to some extent by Perkins.

1. Foot Strain, or **Incipient Flat Foot.** This is the earliest stage and corresponds to the period when pressure is first being exerted upon the ligaments There is no evident deformity, but tenderness and pain may be so severe that the patient is confined to bed

Fig 360 —Flat Foot with dropped Longitudinal Arch and Prominence of the Navicular. The rigid type

2. Mobile Flat Foot.

(*a*) *Due to faulty postural activity of muscle* There is often a general postural defect and the foot one is the most obvious element. It is also the obvious reason for examining every foot case completely undressed When the child stands there is deflection of body-weight but this disappears when he stands on his toes When the foot is correctly aligned there is no varus deformity of the forefoot and the foot is quite mobile. From the general loss of muscular tone the pelvis tends to

ment); below the medial malleolus; along the talo-calcaneau joint; on the medial surface of the calcaneus, and in some cases the tip of the lateral malleolus and the lateral surface of the calcaneus may be painful, as well as the dorsum of the foot. The pain is due to the stretching of the ligaments, and the compression of the tissues below the lateral malleolus

Tenderness. The commonest areas of tenderness are over the navicular, the inferior calcaneo-navicular ligament, the sole of the foot, and, frequently, below the head of the first metatarsal.

Swelling of the Feet. Localized puffiness is common, and in chronic cases œdema of the feet may occur.

Gait. In flat foot, raising of the heel is avoided, to prevent strain being put upon the tarsal and the metatarsal ligaments, and the patient carefully lifts the ball and the heel of the foot together. The toes are usually turned outwards—"splay foot"—and the gait is thus awkward and stiff, and without any spring.

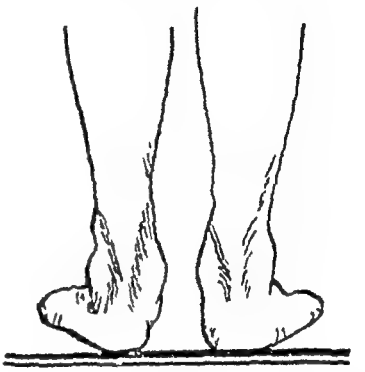

FIG 359.—Valgus Deformity of the Feet as seen from behind

The Deformity. In the early stages no deformity is visible and the arch is well formed; but it must be borne in mind that this is the period when the other symptoms—pain, tenderness, and œdema, are most severe, because the supporting tarsal ligaments, which react to severe and chronic strain in the same way as the ligaments of other joints, are just beginning to yield.

It is sometimes difficult to determine the extent of any deformity that has arisen, for the height of the longitudinal arch is very variable; indeed, it has been pointed out by Lovett that it is the high arch which is most prone to break down, and it follows that in this event symptoms may be severe with only slight depression of the arch.

The first deformity consists usually of eversion of the foot without flattening of the arch The flattening becomes apparent at a later stage, and then when the foot is inspected, the head of the talus is found to stand out prominently in the medial border of the foot.

Stiffness and Muscle Spasm. Where muscle spasm is marked, the foot resists passive correction into an inverted position, and in time becomes rigidly fixed by the formation of adhesions in the joints which are subjected to irritation. In severe cases the peroneal muscles are tightly contracted, and can be seen standing out under the skin. Attempted correction induces pain along the course of these muscles

The spasm may implicate the gastrocnemius and the soleus, and thus lead to progressive deformation of the foot.

If the stability of the long arch can be restored it can be demonstrated by asking the patient to stand on his toes. The vertical line from the middle of his patella is again inspected and if it still passes medial to the first toe the pes planus is of the rigid type. But if it passes through the second toe now the deformity is of the mobile type

To determine whether or not the foot is transmitting weight through its three points of support—i.e. is plantar grade—the foot is placed so that the vertical line drops through the second toe. In pes planus due to faulty postural activity of muscle the foot is plantar grade but if not plantar grade there may be an equinus deformity or a varus deformity which will need correction.

It is important to test the mobility of the subtaloid joint. The heel is placed in a central or neutral position, i.e. neither varus nor valgus, and the forefoot placed so that the vertical line of body-weight passes through the second toe. If this cannot be done the subtaloid and mid tarsal joints have lost their mobility and the deformity is of the rigid type

Palpation. The foot is now carefully palpated for evidence of abnormal tenderness This is usually present on both the medial and lateral aspects of the ankle; in the first case because of ligamentous strain, and in the second from the crushing of the soft tissues between the lateral malleolus and the everted foot. Pain is present on the sole, especially over the spring ligament.

Diagnosis

The diagnosis of weak, or flat, foot should not be difficult Certain conditions may sometimes have to be differentiated, and these are injury, toxic arthritis, synovitis, bursitis, tendinitis, infantile paralysis, Köhler's disease, osteochondritis of the calcaneus, and tuberculosis.

Prognosis

The prognosis in flat foot depends upon the stage at which treatment is instituted, and upon the perseverance with such treatment. Without treatment, no cure is possible, and the patient is usually forced to seek relief because of steadily increasing pain and disability The pain may completely disappear after some years, when the long arch has been completely broken down, but by that time the foot is irreparably damaged, and useless as a lever in the production of normal gait.

In the rigid type, the course is protracted, and the prognosis is guarded

Treatment

General Considerations.

No condition in the practice of orthopædic surgery has been subjected to so many varieties of treatment as flat foot Its cure is attempted by numerous methods, from alterations in the footwear

rotate forwards and the legs to rotate in twisting the feet into a valgus position.

(*b*) *Due to short tendo-calcaneus* The malalignment of the body-weight disappears on tip-toeing but when the foot is correctly aligned the foot is in equinus. This limited dorsiflexion is common in women and a frequent cause of the valgoid mobile foot. It may be due to failure of the calf muscles to lengthen as quickly as necessary with growth.

(*c*) *Due to varus deformity of the forefoot.* The faulty alignment of body-weight disappears on tip-toeing but the patient finds it difficult to balance because he is taking all his weight on a small bearing area. If the foot is correctly aligned it will be seen that the first metatarsal head is off the ground, from the outward torsion of the forefoot.

3. Voluntary flat foot corresponds to the stage at which flattening of the arch has occurred, but secondary adaptive changes have not yet ensued The tibial muscles, in particular, though they have lost their postural tone, have not been sufficiently over-stretched to interfere with their power of voluntary contraction.

4. Rigid flat foot with degenerative changes in the subtaloid-mid-tarsal joints.

Examination of the Foot

The examination of the foot should be conducted according to a definite plan, for with a constant procedure, minor degrees of derangement are more easily recognized

Inspection. The examination should commence by observing the manner of standing and walking Any limp is noted, and the elasticity of the gait and the posture of the feet in walking observed. Deformity of the shoes—excessive wearing away of the sole on the medial side, bulging of the medial side of the golosh, or the presence of localized prominences—is noted as the patient removes them.

The patient now stands barefooted before the surgeon, and the attitude, the shape, and the weight distribution of the foot is investigated. The long narrow foot is prone to foot strain The line from the centre of the patella down the tibial crest, should pass through the space between the second and third toes: in foot strain it constantly passes to the inner side of the great toe, and it also does so when the foot is externally rotated on the leg

In slight cases the persistent eversion of the foot may not be pronounced from the front In such a case, examination from behind frequently prevents error in diagnosis, as the medial malleolus is seen to be unduly prominent and the angle between the leg bones and the talus and calcaneus is extreme in an outward direction in the case of postural foot defect

In addition, the medial border of the foot may be convex instead of concave, and the head of the talus or the navicular may stand out as a distinct bony prominence on the medial side of the foot.

The absolute indications for treatment are pain and the impaired function. The existence of flat foot does not necessarily mean that treatment is required, as many people with perfectly rigid feet are able to go about their ordinary occupations without the slightest discomfort. Treatment will be discussed in conformity with the type of case to be treated.

1. Treatment of the Incipient Flat Foot (Acute Foot Strain).

In severe cases of foot strain, where the foot is œdematous and movement exquisitely painful, it is often advisable to recommend a period of rest in bed. This can be supplemented by various physiotherapeutic procedures to promote the disappearance of the œdema and improve the nutrition of the small muscles of the foot. Among such procedures may be noted:

(*1*) *Contrast Foot-baths.* Contrasted foot-baths are prescribed for older children and adults. Two buckets are used, each big enough to contain both feet. One bucket contains warm water, and the other cold water, and the patient sits in front of them and places the feet in the warm water for a minute, and then in the cold water for a similar period. This treatment is carried out for ten minutes.

(*2*) *Electrical Treatment.* Faradic stimulation of the small muscles of the foot is most effective in increasing their tone, and may be done either by the surging method or by stimulating each muscle individually

It will be found that even in the most acute types, such treatment affords speedy relief, but the after-care is equally important An endeavour should be made to eliminate any predisposing factor which appears to operate in the particular case; thus adjustment of the diet in the obese, the injection of varicose veins, the correction of faulty attitudes, and attention to the footwear are of vital importance. When first allowed up, it may be wise to reinforce the lately relaxed ligaments by *adhesive strapping* which forms a valuable method of support

Correction of Footwear The last of a shoe is the wooden model, approximately the shape of the foot, over which the shoe is built. Its bottom should be comparable to the human foot, with first and fifth toe convexities, second, third and fourth metatarsal head concavities, and with concavities for the longitudinal arch. The proper shoe has a slightly concave inner border, to favour adduction, the toe-cap is deeper over the great toe than elsewhere; and the width of the shoe is equal to or a little greater than that of the weight-bearing portion of the foot when standing It is firm behind, but flexible in front of the mid-tarsal joints, tight over the instep, with a low broad heel and with a firm counter or leather support which must grasp the heel of the foot. Due allowance must be made for rapidly growing feet.

In the fitting of shoes, the waist of the shoe, that part of the circum-

to transplantation into the outer side of the tarsus of large wedges of bone resected from the medial side.

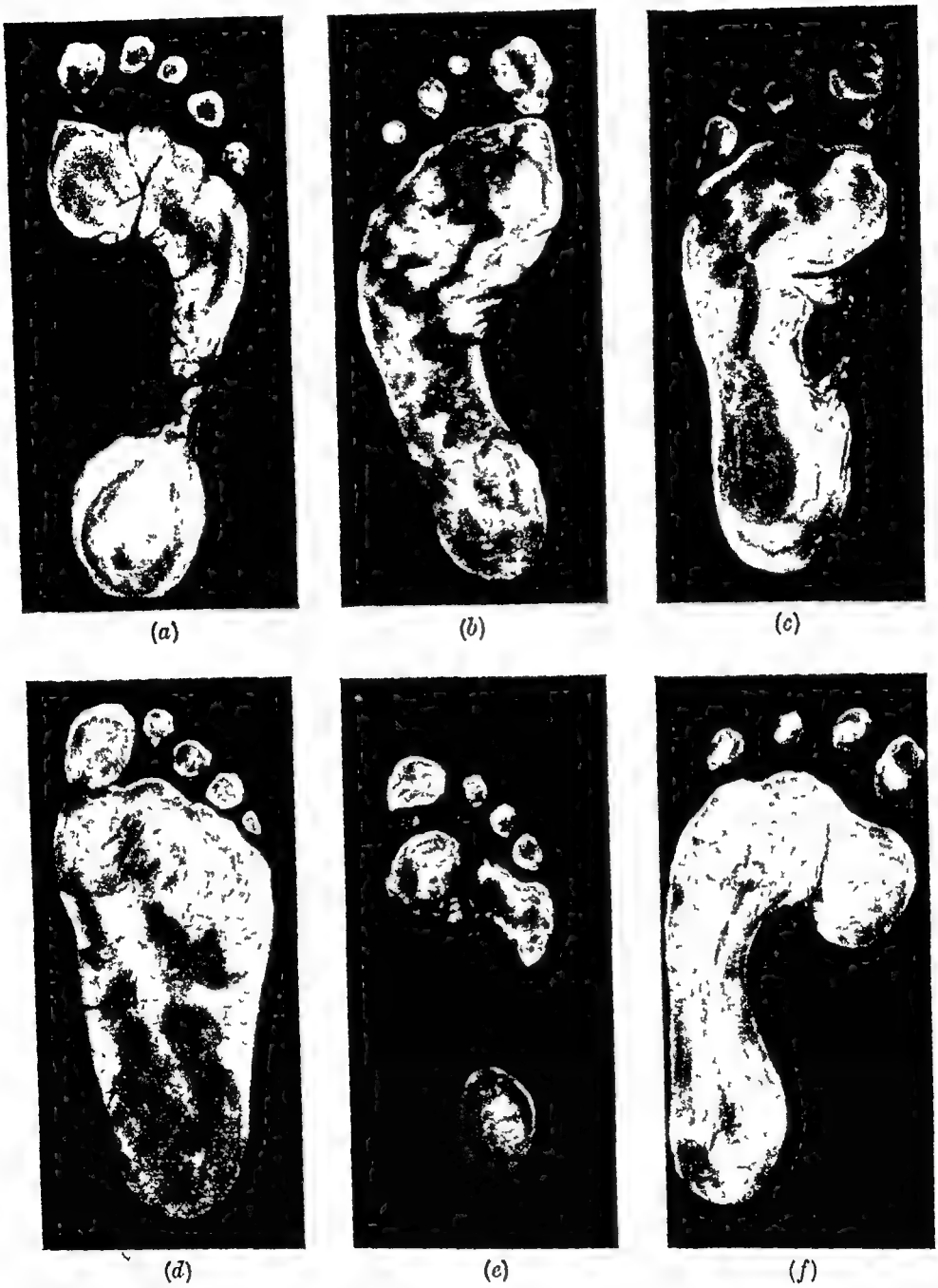

Fig 361 —Deformities of the Foot The various appearances of sole impressions (a) Normal foot (b) Commencing flat foot (c) Moderate flat foot (d) Severe flat foot (e) Pes calcaneus (f) Pes excavatus (cavus) (After De Quervain.)

The objects of treatment may be formulated thus

1 To correct the abnormal centre of gravity in the foot, so that the body-weight is transferred to the outer side of the foot.

2. To remove pressure symptoms

arch and keep it free from deformity and its ligaments from strain. Essentially they all consist of rising on the toes and on the lateral side of the foot. They are done slowly and the feet should not be allowed to come down too rapidly.

The patient is instructed to perform his exercises in bare or stockinged feet.

(*a*) *Non-weight-bearing Exercises.* These exercises may be begun during recumbency, or when the patient is allowed up, in which case the patient sits on a chair with his legs crossed.

The exercises for the toes, without weight-bearing, are flexion and extension of the toes; for the foot, strong plantar flexion, adduction and inversion of the forefoot, and finally dorsiflexion. The patient should be taught to rotate his foot, drawing the letter O with the point of his great toe. The exercises should be performed actively, and thereafter the patient should carry them out by forcing the foot into various positions with the opposite hand, while the affected foot is supported on the opposite knee.

(*b*) *Weight-bearing Exercises.* Weight-bearing exercises should be begun as soon as the pain and muscle spasm have subsided Of these, the best is walking, in which the leverage power of the foot is properly employed, and in which the two feet are nearly parallel. The following list of additional exercises will be found useful:

(*i*) *Tip-toe Exercises.* The patient places the feet side by side in an attitude of slight adduction, raises the body on the toes to the extreme limit, the limbs being fully extended at the knees, then sinking slowly rests the weight on the lateral border of the feet in the attitude of marked varus.

(*ii*) *Rising on the Lateral Borders of the Feet.* The patient stands with the feet parallel and rises on the lateral borders of his feet without twisting the legs or bending the knees. This movement takes place at the sub-taloid joint and calls only the adductors of the foot into play.

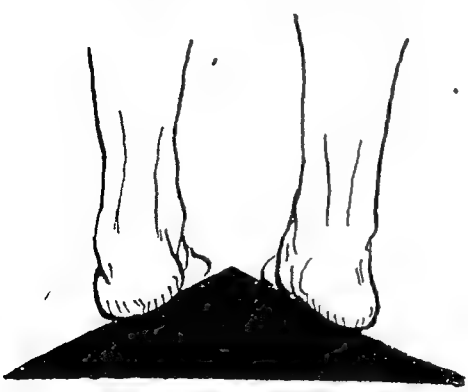

Fig 362 —Exercise for Weak Feet
Walking on an angled board to correct the valgus deformity

(*iii*) *Walking on the Lateral Borders of the Feet.* With the feet parallel, the patient rises on the lateral borders and walks in this position. If he walks with the toes turned in, the rotators are brought into play also. The big toe should be curled downwards

(*iv*) A similar exercise may be carried out, where the patient lifts the foot so that it is opposite the other knee. He walks across the room several times with this "ostrich step," always bearing his weight on the lateral border of the foot.

ference extending from in front of the heel up round the lacing part, should be accurately moulded; if it is loosely fitting, the weight of the body when walking downhill is taken on the points of the toes, whereas a tight waist will prevent this.

Flexible shoes are indicated only when the patient needs exercise, but most of the patients seen by the orthopædic surgeon, e g. patients with flat foot, need both exercise and support, and the latter need is supplied only by a rigid, or semi-rigid, shank. It should be remembered that it is useless advising women to wear a low broad heel, when they have been used to a high one all their lives. The low heel merely increases their misery, since it strains the calf muscles. In such cases, the patient is advised to wear a correct shoe for walking and when at home, when they go to dances and have to dress accordingly, they are allowed to wear any type of shoe that will fit the foot, even though by this they are undoing some of the good derived from wearing proper shoes at other times.

Following acute foot strain it is important to thicken the medial part of the sole by about a quarter of an inch, a device that deflects the body-weight to the lateral part of the tarsus and spares the longitudinal arch to some extent

It is important that children should be properly fitted with correct shoes, and this is often difficult as many children outgrow rather than outwear their shoes They should be fitted with a Thomas's heel, that is, with the medial border extending ½ inch further forward than the lateral and whose function is to transfer the body-weight to the lateral border of the foot, and which when properly made, thus compels the foot to assume a proper walking angle

It is also essential to insist on a course of exercises at this stage, before actual collapse of the foot has ensued. These are directed towards:

1. Instruction in walking,
2 Improvement of the muscular support of the arch.

(1) *Instruction in Walking.* The patient should be taught to walk with the feet parallel, as the muscles supporting the arch are then made active and therefore produce adduction and inversion of the foot. The heel-and-toe walk also brings strong muscles into play and should be cultivated When standing the patient should ensure that the weight is borne on the lateral side of the foot; the foot should never be held pronated or relaxed

(2) *Exercises* Exercises, active and against resistance, should be carried out twice daily. This treatment is tedious for adults, but they should be encouraged to persevere in its performance In children the exercises can be so modified, or carried out to music, that they are considered part of an amusement The rationale of the exercises is to stretch shortened structures, such as the tendo-calcaneus and the soft parts on the lateral side of the foot, and to strengthen the relaxed muscles so that they are in a better condition to support the

This position is retained in plaster of Paris for six weeks The difficulty of retaining inversion of the heel and eversion of the forefoot is solved by applying the plaster in two pieces, leg and hind foot in one and forefoot in another, adjusting the position of the two, and fixing them with a further roller bandage. The child is allowed to walk, preferably with the aid of a rockered over-shoe.

3. Treatment of Voluntary Flat Foot.

In this type, where the deformity can be corrected by the patient at will, the treatment proceeds along the lines already laid down When pain is prominent, rest in bed and strapping are again employed till the acute phase has subsided The after-care is similar, but in addition to the other measures, an arch support may be employed The best types of arch supports are of felt or sponge-rubber.

(*a*) *Felt Supports* Bevelled felt pads by affording a resilient support thereby increase the spring of the gait; they are very efficient, and preferable to rigid supports of celluloid, metal, or leather. The pads are actually inserted into the shoe and held in place by means of special glue and tacks They fit into the natural hollows so that no extra space is required.

(*b*) *Sponge Rubber Supports.* Supports made of sponge rubber have the same advantages as bevelled felt, and are even more resilient, in addition, they are more easily cleaned, and retain their resiliency for a longer time.

4. Treatment of the Rigid and Permanent Types.

In these cases it is important to understand why symptoms arise as the ligaments have already been stretched to their full extent they are unlikely to be the cause of pain, and any symptoms are most probably due to the formation of adhesions or the occurrence of osteo-arthritic changes in those tarsal joints which still retain some mobility; in both cases, symptoms are relieved by manipulation under anæsthesia. Following the manipulation, the patient should have a course of vigorous exercises to preserve the mobility gained by the manipulation

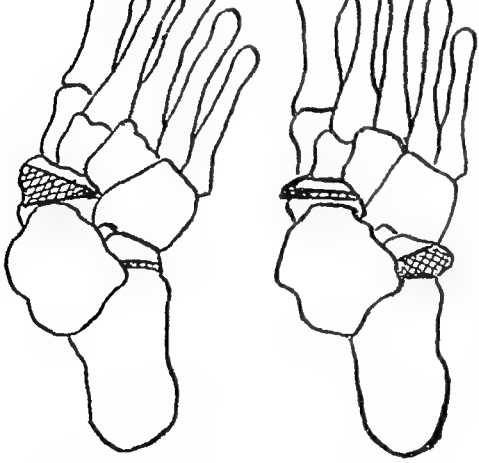

Fig. 363 —Operation for Rigid Flat Foot

A wedge of bone is excised from the navicular and inserted into a prepared bed in the cuboid

Manipulation. When the patient is anæsthetized, some of the rigidity will be found to have been due to muscle spasm, and to have disappeared If any restriction of movement remains, the foot is forcibly manipulated by a Thomas's wrench, until it is absolutely

(*v*) Walking backwards and forwards on a supination board, which consists of boards joined at their longitudinal edges at an angle of 165 degrees. The patient walks the length of this board (8 feet) three or four times, as one would walk on the eaves of a house.

(*vi*) The feet are held parallel and the knees extended. The knees are then rolled laterally so that the long arch automatically rises.

(*vii*) Bicycling on a machine in which the medial parts of the pedals are thickened.

(*viii*) The ball of the foot is placed on the sharp edge of a thick board table or some other support, with the toes projecting over the edge, and the toes are deliberately bent downwards as far as possible. If the toes do not bend readily they become more flexible on manipulation by the hands.

In children, *games* may be utilized as exercises. Ballet dancing is an excellent exercise, and may be started at the age of 4 or 5, but toe dancing should not be carried out by children with any tendency to weak feet, nor is it good for all children. Swimming and roller skating are very good.

2. (*a*) **Treatment of Mobile Flat Foot due to faulty postural activity of the muscles.** Remedial exercises are instituted to correct the faulty posture. At an early age—before two—no treatment is really required for the feet other than regular supervision to ensure that the muscles develop. Wedging of children's shoes is not of great value owing to their loose fitting Where treatment is necessary good firmly-fitting boots are wedged on the inner side of the heel to the extent of ¼ inch. Perkins advises as the only useful exercise at this stage that of making the child rotate out the legs while keeping the feet flat on the ground This is equivalent to internal rotation of the foot on the leg. Making the child stand and walk pigeon-toed is also useful.

(*b*) **Treatment of Pes Planus due to equinus deformity.** Stretching of the tendo-calcaneus and calf muscles acts also on the tarsal joints and may produce eversion and abduction with unstable tarsal joints as well as the desired dorsiflexion The equinus deformity is therefore better treated by subcutaneous tenotomy of the tendon. The foot is then put in a plaster-of-Paris case for six weeks with the three bearing points in the same plane, the body-weight correctly aligned, and the foot dorsiflexed 10 degrees beyond a right angle. In girls the short tendon may be compensated for by a high heel and the defect accepted

(*c*) **Treatment of Pes Planus due to varus forefoot.** In this form the third point of the tripod—the head of the first metatarsal—is non-weight-bearing and has to be brought down. This is done by forcible manipulation under anæsthesia when the medial border of the foot is forced down In resistant cases a Thomas's wrench holds the heel—bar below and rubber-covered blades on either side—while another wrench is used to grip the forefoot horizontally and rotate it into valgus.

severe pronated flat feet in children with eversion of the heels. In this operation two rectangular shaped pieces of cortical bone are inserted into a prepared bed in the sinus tarsi of this joint, from the lateral side These grafts aid the placing of the calcaneus under the talus which is corrected out of its equinus deformity and helps in restoring the height of the tarsi. Growth of the foot is not disturbed. Immobilization in plaster of Paris is necessary for ten weeks.

PERONEAL OR SPASMODIC FLAT FOOT

In this acute condition which is commonly seen in young adolescents there is pain, tightness or spasm of the peroneal muscles and an eversion deformity of the foot. The onset is usually after starting work or changing to an occupation involving much standing, so that the complaint is known sometimes as "apprentice's foot."

Although its etiology is obscure the lesion results from some irritative focus in the talo-calcaneal, talo-navicular, or calcaneo-cuboid joints Harris and Beath have described a common anomaly in such feet, of abnormal bony or cartilaginous bars between the calcaneus and navicular or between the talar and the navicular bones. Recently Jack has reviewed the bone anomalies of the tarsus in this condition. The calcaneo-navicular bar is a congenital anomaly in which the calcaneus and navicular bones are joined together by a complete or partial bridge of bone. It is probably due to an unusual degree of development of an accessory bone, the os calcaneus secondarius. Apart from this developmental anomaly, the irritation may result from injury or infection, and Trethowen has pointed out how the strain of prolonged standing or unduly heavy work in adolescents who have recently left school may be a factor.

In the absence of treatment, secondary organic shortening of soft tissues and alteration in the shape of the bones takes place so that the final stage is a rigid or permanent flat foot.

Treatment

The general health and the possibility of the presence of an active infective focus is looked for and treated Special oblique and axial views on radiography are necessary to demonstrate the presence of bony anomalies

An injection of proctocaine into the talo-calcaneal ligament is sometimes of value in reducing the spasm The most satisfactory results are obtained from prolonged immobilization in plaster. Treatment must be begun early to get the best results Under anæsthesia, which relaxes the peroneal spasm, a plaster case is applied in the mid position. The grossly over-corrected inverted position is inadvisable. Following a period of rest of about four weeks duration the plaster is converted into a walking plaster and immobilization continued for a further six weeks. When the plaster is finally removed the patient

flexible and flaccid; it is forced first downwards, then medially and upwards into extreme varus, and an attempt is made to get the lateral border of the inverted foot up to a right angle with the leg.

In this type it is usually impossible to restore the arch and attempts to do so, followed by encasing the limb in plaster of Paris for a period of many weeks are doomed to failure—indeed the immobilization in plaster adds to the muscular weakness already present the atrophy of disuse, and when the plaster is discarded the thin and wasted limb is in an even worse plight than before.

Where symptoms persist despite manipulation, recourse may be had to operation. the tarsal joints being arthrodesed. Ankylosis may be secured by a triple arthrodesis after the method of Naughton Dunn, or a less extensive talo-navicular arthrodesis, or some modification of it. Naughton Dunn's procedure is described elsewhere (page 557)

(*a*) *Talo-Navicular Arthrodesis.* The foot is thoroughly manipulated until it is flaccid and mobile. A 2-inch incision is then made, beginning in front of the medial malleolus and extending along the course of the anterior tibial tendon. The tendon is retracted and the dorsal aspect of the talo-navicular joint exposed by freeing the overlying ligaments and strongly flexing the foot. The joint is denuded of ligaments and the capsule opened. A curved gouge is used to excise the articular surfaces of the talus and the navicular, but care is taken to preserve the ovoid shape of the head of the talus and the convexity of the navicular, so that when the forefoot is again adducted into its proper corrected position, the navicular will rotate and remain in contact with the denuded head of the talus.

(*b*) *Talo-Navicular Arthrodesis, plus wedge insertion to outer side of the foot* In this operation, the steps of the talo-navicular arthrodesis are similar to the above, but in addition, a wedge of bone is removed from the navicular and inserted, through an incision on the lateral side of the foot, into a bed prepared for it in the antero-lateral part of the calcaneus. In most cases the foot is put up in plaster of Paris in the corrected position for twelve weeks, thereafter the ordinary treatment of flat foot is carried out

(*c*) *Naviculo-Cuneiform Arthrodesis* This operation was first described by Hoke in 1931 and reintroduced by Jack for a localized "break" in the naviculo-cuneiform joint. It is indicated in adolescent patients who have symptoms which have persisted in spite of conservative treatment A horizontal incision is made over the medial surface of this joint and after releasing the capsular ligaments the subluxation is corrected by manipulation. A trench is cut, by osteotome, in the bones and across the realigned joint and into this a rectangular shaped piece of cortical bone from the tibia is inserted. The foot is then immobilized in a moulded plaster cast for three months

(*d*) *Talo-Calcaneal Extra-articular Arthrodesis* Grice has described this operation for a paralytic foot-drop but also recommends it for

head of the second and commonly the third. The metatarsal is often abducted (primus varus).

(3) *Metatarsus Hypermobilis*, where the first metatarsal is unduly mobile. This is the result of ineffectual fixation at its base, and can be demonstrated easily by taking the metatarsal head between the finger and thumb and plantar and dorsiflexing it at its base while the tarsus is supported by the opposite hand.

FIG 364.—Hallux Valgus with Metatarsus Primus Varus

The Clinical Effects of Developmental Anomalies. In many people the possible ill effects attending developmental errors are masked by efficient muscular support and by hypertrophy of the neighbouring bones, but it is obvious that certain effects may arise in them In *metatarsus primus varus*, the first metatarsal is lying away from the long axis of the foot and fails to act as an effective fulcrum; its function, therefore, must in part be assumed by the second metatarsal, and possibly the third, and these—unless hypertrophied—are ill adapted to fulfil its purpose In *metatarsus atavicus*, a similar effect obtains, while in *metatarsus hypermobilis* the first metatarsal, though it may act as a fulcrum quite effectively if fixed by the adductor muscle,

practises graduated active foot exercises in the manner already described and Thomas's heels are fitted to the shoes In resistant cases the use of a lateral iron and inside T-strap is advisable for some considerable time.

In young patients where an obvious bony bar is present, without arthritic changes, this may be resected. This is carried out from the inner side of the foot and care should be taken in removing the whole bar not to do damage to the adjacent joints. In the older case a localized fusion of the talo-calcaneal, or the talo-navicular, joint is necessary and if a rigid flat foot is present a triple arthrodesis is carried out.

AFFECTIONS OF THE BONES AND JOINTS OF THE METATARSUS

The Normal Form of the Forefoot.

The metatarsal bones are usually arranged as a parallel series, and the first metatarsal is thicker and stronger than the others, as it provides the weight-bearing foot with one of its three chief points of support; further, because it forms the fulcrum on which the body-weight is swung forwards in walking, its head lies on a more anterior plane than the others The other important weight-bearing points of the foot are the fifth metatarsal and the calcaneus and these, with the first metatarsal head, are usually regarded as forming the points of a tripod

The intermediate metatarsal heads are sometimes said to form an arch—the *anterior metatarsal arch*, but the accuracy of this observation is doubtful. It is more than likely that all the metatarsal heads are in contact with the ground in walking, but that as a result of muscular and ligamentous support, they take relatively no part in weight-bearing under normal conditions

Developmental Anomalies of the Metatarsus.

Alterations in the normal form of the forefoot are common, and consist of atavistic anomalies of the first metatarsal. In the course of development the first metatarsal is gradually drawn laterally from an abducted position into parallelism with its neighbours, it loses the mobility it possesses in the primitive foot of the ape; and it grows in strength till it outstrips its fellows.

The common developmental errors which may occur are.

(1) *Metatarsus Primus Varus* Here the first metatarsal is distinctly abducted from the midline of the second and there is a palpable and radiologically demonstrable interval between the first and second heads Occasionally this wedge-shaped interval is occupied by an accessory ossicle—the *os inter-metatarseum*

(2) *Metatarsus Atavicus or Brevis* In this anomaly the first metatarsal bone is shorter than normal, and its head is situated behind the

with, giving rise to anterior metatarsalgia The bursa is liable to inflammatory changes, and in its late stages the joint is osteo-arthritic. A constant secondary feature is the development of an adjacent hammer toe with dorsiflexion of the proximal phalanx and even complete subluxation at the second metatarso-phalangeal joint. This results from the body weight and "take off" being displaced from the first metatarsal on to the head of the second metatarsal, causing arthritis and overlying callosity formation, with pain.

Clinical Features

Many people with hallux valgus suffer relatively little trouble till osteo-arthritis supervenes in later years In others pain may arise in association with the corn or callosity, or the bursa may become repeatedly or chronically enlarged, or even suppurate In these individuals, pain is the result of pressure on the affected structures, and relief is often obtained by cutting away the portion of the boot or shoe overlying the bunion When the symptoms are due to arthritis the range of movement of the joint is both limited and painful The condition is often accompanied by symptoms of metatarsalgia or of foot strain or established flat foot

The pain from hallux valgus, to summarize, is due to four causes:

(1) friction and pressure over the prominent head with production of a bursitis,
(2) osteoarthritis of the joint,
(3) involvement of the sesamoid bones in the arthritic process,
(4) callosities under the second and third metatarsal heads due to splaying of the transverse arch.

Treatment

(*a*) Conservative Treatment.

In mild cases the symptoms may be relieved by the provision of shoes of rational design with a straight inner side and an upper of soft leather which can be stretched in the region overlying the sensitive joint The fitting of a bar to the sole of the shoe behind the metatarsal heads is a useful addition which decreases the trauma of weight bearing. In addition the corn may be protected by zinc oxide felt plaster.

None of the devices for holding the toe in an improved position have any curative value nor do they relieve the symptoms.

If the symptoms are severe operation should be advised

(*b*) Operative Treatment.

Operation is indicated for the relief of symptoms alone and should not be undertaken merely for the æsthetic effect. It should not be undertaken in the presence of active bursitis.

Various types of operation are worthy of consideration.

without such fixation fails to form a stable weight-bearing point of the tripod, and becomes splayed out on long standing.

There is one further—and important—effect of *metatarsus primus varus;* the use of even ordinary footwear will cause the toe to become displaced, an effect that will be enhanced by the use of boots or shoes with abnormally pointed toes. The increased load thrown on the intermediate metatarsal heads is the factor underlying a series of interesting and important disturbances.

The following clinical conditions may arise therefrom, in association with developmental anomalies:

1 Hallux Valgus.
2 Metatarsalgia.
3. March Foot or March Fracture.
4. Kohler's Disease of the Metatarsal Head (Freiberg's infraction).

HALLUX VALGUS

The deformity of hallux valgus consists of extreme adduction of the proximal phalanx of the great toe towards the mid line of the foot and is associated, especially in the most extreme forms, with varying degrees of varus of the first metatarsal Lake considered that the varus deviation of the first metatarsal, the cause of which is unknown, is the most important factor in the development of this lesion Kaplan has described a strong connecting band extending from the tendon of tibialis posterior muscle into the flexor hallucis brevis and adductor hallucis and regards this as a contributory factor in producing this deformity Lesser degrees of lateral deviation are not uncommon as a result of the prevalent use of badly designed and ill-fitting shoes even when the position of the metatarsal is normal.

The phalangeal deviation is progressively increased by the contracture and shortening of the adductor hallucis and extensor hallucis longus, so that ultimately the base of the phalanx is displaced so far laterally that it articulates solely with the lateral condyle of the metatarsal head. The medial condyle of the metatarsal head remains as a prominence on the medial side of the foot and is subjected to friction and pressure from the shoe An adventitious bursa is accordingly formed and a corn or callosity develops in the overlying skin The projecting bone, together with the bursa and corn or callosity are collectively known as a bunion.

Pathology

The tissues on the lateral side of the deformity—capsule, muscle tendons and ligaments—are adaptively shortened, while the capsule and ligaments on the medial side of the joint are stretched. The cartilage on the exposed part of the metatarsal head undergoes fibrillation and degeneration, and marginal osteophytes are thrown out, as in osteoarthritis. The function of the intrinsic muscles of the foot is interfered

between the phalanx and the metatarsal head and stitched over th raw surface of the phalanx. If the tendon of the extensor hallucı longus ıs contracted ıt ıs lengthened ın the operative field or tenotomized at some dıstance above the sıte of operatıon

At the termınatıon of the operatıon pulp traction ıs put on the great toe and maıntaıned by a plaster-of-Parıs boot wıth a plaster loop over the toes (see Fıg. 366). The tensıon is applıed wıth rubber tubıng Walkıng ıs permıtted after an ınterval of about three weeks A more simple but equally efficient method of post-operatıve ımmobılızatıon ıs by compressıve bandagıng for three weeks and then actıve exercises to mobılize the new joınt.

(3) Arthrodesis of the First Metatarso-Phalangeal Joint. This operatıon is recommended by Ross Smith to preserve the strength and the functıon of the great toe. However, because of the duratıon and dıfficultıes of thıs treatment, ıt should be lımıted to the young workıng ındıvıdual who is particularly troubled wıth metatarsalgıa and callosıty forımatıon under the head of the second metatarsal bone. In thıs operatıon the base of the phalanx and the head of the metatarsal are cleared of soft tıssues and after removıng any osteophytes the articular surfaces are removed by an osteotome. A posıtıon of a few degrees of dorsıflexıon and slıght abductıon of the toes ıs obtaıned and fixed by a screw passıng oblıquely from the ınner sıde of the metatarsal to the outer sıde of the phalanx, or by staples or by two transfixıon wıres and a compressıon clamp Complete ımmobılızatıon is necessary, by plaster of Parıs, untıl fusıon occurs ın sıx weeks or more.

(4) McBride Operation. In this, the lateral deformıng forces of the conjoıned tendons of adductor hallucıs and the lateral head of the flexor hallucıs brevıs are transferred from the proxımal phalanx into the lateral sıde of the head of the first metatarsal The lateral sesamoıd and the exostoses are also removed to obtaın normal alıgnment of the hallux This operatıon may produce an abnormal posıtıon of varus of the hallux

(5) Radical Type of Operation. Such an operatıon entaıls (1) correctıon of deformıty of the first metatarsal, (2) maıntenance of correctıon; and (3) restoratıon of muscle balance The proxımal thırd of the proxımal phalanx ıs removed, as is also the exostosıs The metatarsal adductıon ıs corrected by an osteotomy just dıstal to ıts base and thıs ıs maıntaıned by ınsertıng a graft—usually from the exostosıs removed from the head of the metatarsal The attachment of the adductor hallucıs ıs transferred to the metatarsal head thus gıvıng ıt a stable orıgın, whıle ıts actıon also helps to maıntaın the correctıon of the metatarsal Any relapse of the correctıon of the metatarsal ıs due to ınsufficıent correctıon, or correctıon under tensıon Lastly the capsule on the medıal sıde of the joınt ıs rasped and thıs helps the alıgnment of the abductor hallucıs

(1) The Conservative Operation : Removal of Exostoses and Bursa. This operation is indicated when the symptoms are due to pressure on the exostoses situated on the prominent metatarsal head and overlying bursa. It will not produce relief of symptoms in the presence of gross arthritic change or deformity. This operation gives relief when the symptoms are those from the bunion but often it is followed by an increase in the deformity since the function of the medial ligament is lost and a radical operation may become necessary later

A straight incision 2 to 3 inches long is made centred over the metatarso-phalangeal joint on the medial aspect A similar incision is used for all hallux valgus operations The U-shaped incision is undesirable as the poor blood supply at the apex of the flap frequently causes delay in healing with the resulting broad tender scar. The bursa is dissected out and the medial half of the metatarsal head and any remaining exostoses removed with a sharp osteotome

(2) Excision of the Proximal Part of the Phalanx (Keller). This operation is recommended as the most satisfactory procedure in the large majority of cases and is especially useful in the presence of symptoms of arthritis A straight incision is used on the medial aspect of the joint. The proximal two-thirds of the phalanx is denuded of soft tissue and the phalanx divided about half-way between

(a) (b)

FIG 365 —Hallux Valgus (a) Severe degree (b) After arthroplasty and correction

FIG 366 —Traction applied by means of a Plaster-of-Paris Case

the head and the base and the proximal half or rather less removed, care being taken throughout the procedure to prevent injury to the underlying flexor tendon which is very easily damaged as it sticks so closely to the phalanx The head of the metatarsal is re-shaped by removal of the exostoses A flap of soft tissue may be turned into the space

foot. The joint is sometimes swollen from peri-arthritis, while a characteristic feature is the occurrence of a small marginal exostosis on the dorsal edge of the articular surface of the metatarsal head—i.e at the degenerate area of the cartilage. The gait is shuffling and ungainly.

In the early cases, before the rigidity is absolute, attempts to move the joint cause great pain, but later, when the stiffness is permanent, ordinary passive attempts at motion are painless, and the condition may be masked by an abnormal degree of dorsiflexion acquired by the inter-phalangeal joint.

Treatment

Conservative. In the acute cases rest is indicated by means of a plaster In moderate degrees of the chronic type relief may be obtained from restricting the movement of the joint (*a*) by thickening the sole of the shoe, (*b*) by the insertion of a thin plate of tempered steel between the two layers of the sole, or (*c*) by the fitting of a metatarsal bar to the sole of the shoe.

In cases with a short history and in young people a cure may sometimes be effected by over correction of the deformity under anæsthesia and the application of a walking plaster case to maintain the toe in dorsiflexion The plaster case should be retained for four to six weeks.

Operative. The large majority of cases eventually require operative interference. The condition is treated in the same way as a hallux valgus, either by a Keller's operation (p 877) or by an arthrodesis of the metatarso-phalangeal joint (p 878) The latter operation has many advocates now and seems to be very successful in the young manual worker. It should not be carried out in the acute phase and care should be taken not to dorsiflex the joint too much even in women who wear high heels.

METATARSALGIA

Pain beneath the metatarsal shafts or heads is commonly known as metatarsalgia, but it is important to discriminate between the different lesions which may give rise to it.

It has already been suggested that the anterior metatarsal arch, at least in the weight-bearing foot, does not exist, but under certain circumstances the intermediate metatarsal heads may be overloaded, and give rise to pain Pain may also arise as a result of inflammatory affections—e g. rheumatism in the metatarso-phalangeal joints, or as a sequel to falls from a height on to the fore-part of the foot

Metatarsalgia, therefore, may be—

Traumatic.
Inflammatory
Static

After Treatment.

When the patient becomes ambulatory he uses a soft shoe and is instructed in the correct "heel-and-toe" method of gait.

If the joint becomes hot and swollen the patient rests with the foot elevated until the condition becomes quiescent. Throughout ambulatory treatment he practises active toe and foot exercises Passive movements are contra-indicated, especially in a hot and swollen joint. It is essential following any of these operative procedures that the patient be provided with suitable shoes with a straight inner side which cannot cause recurrence of the deformity as a result of pressure The frequently accompanying metatarsalgia and pes planus should be treated by foot exercises designed to improve mobility and develop the muscles of the foot

HALLUX RIGIDUS

Hallux rigidus is a condition of stiffness of the metatarso-phalangeal joint of the great toe, especially characterized by absence of dorsiflexion In early cases, the power of plantar flexion is present, but in extreme examples all movement of the joint is abolished, and a flexed position is gradually assumed—*hallux flexus*

Rigidity of the joint may either be associated with inflammatory changes such as rheumatism, or else be a symptom of a traumatic lesion, in which case the causal lesion is a stroke or blow in the long axis of the toe, such as may be got from kicking a hard object, giving rise to contusion of the opposing cartilaginous surfaces of the joint and an intra-articular effusion The limitation of movement in the first instance is the result of muscular spasm designed to prevent movement at the painful joint, but secondary accommodative changes in the capsule and anterior ligaments render the stiffness permanent.

In the *static* variety of hallux rigidus there is a concomitant flat foot In the normal foot, the long axis of the first metatarsal is directed downwards and forwards from the summit of the arch, but when the arch is depressed, the base of the metatarsal sinks, its long axis becomes horizontally disposed and, in consequence, the head of the bone is rotated upwards and the dorsal portion of the articular surface ceases to be articular. The exposed area undergoes the usual changes of disuse—fibrillation and osteophytic outgrowth—so that any attempt to move the base of the phalanx over this degenerate surface is painful Reflex spasm of the muscles ensues to prevent this, and the metatarso-phalangeal joint is kept rigid.

In both varieties, the rigid joint in its later stages becomes the site of characteristic osteo-arthritic changes

Clinical Features

In hallux rigidus, pain is particularly experienced on walking, and especially when attempts are made to dorsiflex the joint for the "take-off", the pain is less severe on standing, unless there is severe flat

common in relation to the second metatarsal space. The paroxysms may be so severe that the sufferer has to stop while walking and remove the shoe. In these cases the pain can sometimes be brought on, or accentuated, by side to side compression of the metatarsal heads, and is occasionally induced by removing the shoe. Pain is also produced by dorso-plantar compression of the inter-metatarsal space at the level of the metatarsal heads. If the thumb exerts firm pressure on the site of the suspected neuroma pain may coincide with a palpable click caused by the tumour escaping into the sole of the foot.

Treatment

The object of the treatment must be to strengthen the muscles which support the forefoot, and to keep the forefoot in a corrected position while this is being accomplished. It is essential that the intrinsic muscles be strengthened by exercises and re-education The patient should be taught to contract these muscles every time the forefoot touches the ground Any co-existing defects in the mechanics of the foot should be treated, especially longitudinal arch strain and shortened tendo-calcaneus.

The following measures may be employed:

Support. (*a*) In all types the fitting of a shoe of rational design is essential It should have a straight inner side, a broad thick sole, a low heel, and a metatarsal bar or crescent should be placed across the sole, well behind the heads of the metatarsals. Occasionally this simple method will effect a cure.

(*b*) In more severe cases the support must be applied directly to the foot and this may be most simply effected by means of a felt pad and adhesive strapping changed at intervals of one week.

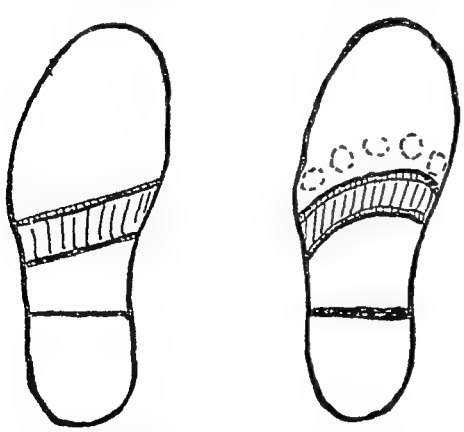

Fig 367 —Types of metatarsal bars used in cases of metatarsalgia (After Lewin)

An oval pad of piano-makers' felt with bevelled edges is placed under the metatarsal arch and secured immediately behind the metatarsal heads by adhesive strapping. In the splay foot, or ligamentous type, the strapping may be carried round the forefoot so that it produces slight compression, but when the pain is of the compression type any further compression should be avoided and the strapping carried round the medial and lateral margins only The first felt pad is about $\frac{3}{8}$ inch thick, but it is thickened each time the foot is re-strapped until the symptoms disappear Some experiment may be required in order to determine the height of pad which produces complete relief of pain.

The *static variety* demands most consideration. It is frequently found in association with developmental anomalies, particularly metatarsus primus varus and metatarsus hypermobilis, and commonly arises in those conditions where there is a rapid increase in the body-weight, or a debilitating illness which renders the foot muscles atonic.

When the interosseous muscles contract they flex the metatarso-phalangeal joints, extend the toe joints, and draw the metatarsal heads together Failure in these muscles allows splaying of the foot and curling up of the toes The extra weight borne by the metatarsal heads throws a strain on the transverse ligaments of the metatarsal heads, and pain results, just as it does in longitudinal arch strain. This type of metatarsalgia is sometimes known as *relaxation metatarsalgia*

When the metatarsal heads become crowded together as a result, for example, of the wearing of narrow shoes, the digital nerves passing forward to the toes between the heads of the metatarsals are liable to compression or irritation This in time produces an interstitial neuritis which may be productive of agonizing pain and is known as compression metatarsalgia.

There are thus two main varieties of *static metatarsalgia,* viz. (*a*) *Relaxation metatarsalgia,* due to overstretching of the plantar ligaments ; (*b*) *Compression metatarsalgia, or Morton's metatarsalgia,* due to a neuroma of the digital nerves In addition, metatarsal pain is also a prominent feature of Köhler's disease and march foot.

Clinical Features

In the first of the static types—the ligamentous—the pain is situated beneath the metatarsal heads and is of constant burning character and often described by the sufferer as like toothache. It may be relieved by lateral compression of the metatarsal heads which relaxes the strain on the stretched ligaments As it is so often a sign of overloading of the foot it may be associated with signs of foot strain related to the longitudinal arch When the condition is acute there is not infrequently some œdema of the dorsum of the foot.

The foot is broader than normal—splay foot—and there are often obvious deficiencies between the metatarsal heads caused by atrophy of the interossei muscles The clawing of the toes which occurs is further proof of the occurrence of muscular atrophy affecting the lumbricals and interossei, the proximal phalanges becoming dorsiflexed as a result of the poorly opposed contraction of the extensor muscles of the digits. Often there are calluses under the metatarsal heads

In the neuritic type the foot usually presents a different form, it is narrow, and the forefoot appears compressed The pain in this type is usually paroxysmal in nature, commencing beneath the metatarsal head and shooting forwards towards the contiguous sides of two toes. It may affect any or all of the digital nerves, but is most

œdema of the forefoot when the foot is subjected to abnormal use—as in long marching or "*hiking*." Sometimes the condition is associated with pain from the beginning. X-ray examination in the early stages shows no change in the bone, but in the course of time, if repeated examinations are made, there will become apparent a fusiform deposit of new sub-periosteal bone around the neck or adjacent part of the shaft of one or more of the metatarsals. If the exercise to which the foot is subjected is extreme, and if there occurs in addition a minor trauma—e g stepping on a pebble—the metatarsal may fracture at the site of the osteoma, the fracture in this event being a pathological one, following the abstraction of calcium from the bone and its deposit in the osteoma, and associated with extreme pain and gross œdema.

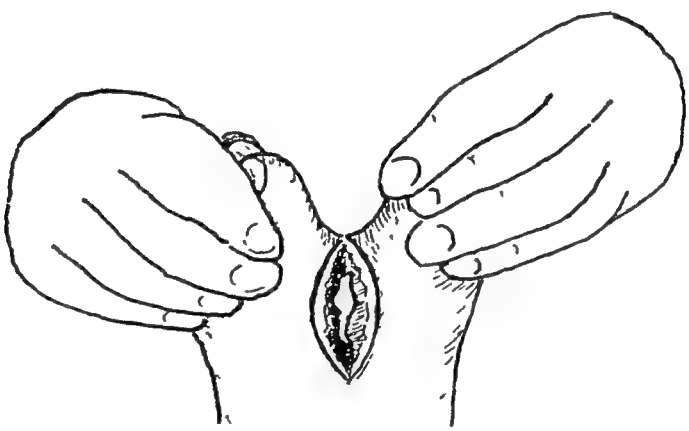

Fig 368 —Exposure of a digital neuroma

This condition is encountered most frequently in the second metatarsal, but may occur in the third or fourth metatarsal and is not infrequently bilateral.

Etiology

It is probably analogous to "stress fractures" which occur in the tibia and other weight-bearing bones

Jansen suggested that the condition was caused by the spasm of the interossei muscles, through which the vessels entering and leaving the metatarsal bone penetrate, which led to vascular obstruction, and consequent œdema of the soft tissues and periosteum, the periosteum became thick and spongy and the œdema resulted in rarefaction of the bone which was then rendered brittle.

Kirschner believes that the fracture is the primary disturbance. It is now generally accepted, however, that the primary factor is a developmental anomaly leading to a mechanical insufficiency of the first metatarsal and that the most important anomaly in this respect is metatarsus atavicus In this condition the longer second metatarsal must assume the rôle of the first in providing a fulcrum for the take-off in walking which it may do quite efficiently in ordinary circumstances.

When the acute symptoms have been relieved regular exercises, especially those designed to develop the lumbricals and interosseous muscles, should be practised.

(*c*) Certain patients require some permanent means of supporting the anterior arch

A thin leather insole is cut so that it fits the shoe exactly. A resilient rubber pad of special shape is then securely fixed to the insole immediately behind the metatarsal heads. This method is of great value in chronic cases, but its success depends entirely on the time and trouble taken to secure the correct position of the pad.

Operation. In cases resisting all other forms of treatment the question of resection of the head and neck of the affected metatarsal bone may arise. The decision to resect the head and neck of a metatarsal should not however be made lightly, in view of the permanent residual disability in the form of weakness of the foot which may result.

When operation is considered to be essential it is performed through a straight dorsal incision over the affected metatarsal, care being taken to see that no spicule of bone remains. The extensor tendon is transplanted into an adjacent one to prevent an undue pull on the unsupported toe At the termination of the operation the foot is put up in a light plaster case moulded to the transverse arch but permitting plantar flexion at the metatarso-phalangeal joints.

Walking is permitted after an interval of three weeks with the type of support described under (*b*) or (*c*) above and shoes of sound design fitted.

In those cases where the clinical diagnosis suggests a neuroma of the digital nerve excision of the neuroma is the treatment of choice. It is a common cause of forefoot pain and the operation gives a gratifying result A web-splitting incision is made on the dorsal aspect of the affected digital nerve Dissection is carried down between the heads and necks of the metatarsal bone. The heads of the bones are retracted and the transverse ligament incised, so producing adequate access to the floor of the incision. The neuroma usually then bulges into the wound. The neuroma is completely excised The neuroma may also be approached by a plantar incision.

MARCH FOOT OR MARCH FRACTURE

This error is also a sequel to a developmental anomaly of the forefoot Deutschlander in 1925 reported a series of 6 cases of localized sub-periosteal deposits of osteoid tissue on the shaft of one or other of the second, third or fourth metatarsal bones He failed to recognize its relationship to the marching fracture of soldiers described about seventy years previously by Breithaupt.

Clinical Features

The condition may begin insidiously, being obvious first as a puffy

the condition is chronic there may be an actual deposit of fibrous tissue in and around the tendon, giving it an irregular form on palpation. When these fibrous deposits project backwards, the wearing of a boot is likely to entail discomfort This condition was first described by Haglund and is often known as Haglund's disease, or winter heel

Bursal enlargements may affect the bursa normally situated between the tendon and the calcaneus, or a subcutaneous adventitious bursa which occasionally develops over the most prominent part of the posterior surface of the bone. Roth, however, drew attention to the fact that this surface is often not flat but irregular, being more prominent on its lateral side at the lowest margin of the insertion of the tendon This means that normally the part of the calcaneus projecting furthest back is not in the mid-line but is lateral to that He found that in 39 per cent. of cases of pain in the heel, this prominence is marked and palpable as a tender hard lump, though as a general rule an X-ray examination does not reveal it It is in this situation that the adventitious bursa forms, as a result of the rubbing of the shoe against the back of the heel.

The bursa at the insertion of the tendo-calcaneus is liable to inflammation from friction produced by an ill-fitting boot, and as a result of that there is a localized tenderness at the site of the bursa, and occasionally a small area of fluctuation can be detected by lateral palpation anterior to the tendo-calcaneus.

When the adventitious bursa is enlarged, the swelling is situated lower down, and is usually larger, fluctuation is easily elicited, and the skin overlying the swelling is often red and œdematous.

Partial Tears of the Tendon result from forcible contraction of the tendon, or from overstretching, and the lesion so produced may consist of avulsion of a few of the tendinous fibres from the bone, or of actual rupture of some of the fibres immediately above their insertion. In the first case, the disturbance of the periosteum results in periostitis, with relatively little or no swelling, but tenderness at the insertion of the tendon, and exquisitely painful movements. Partial rupture of the tendon fibres may be associated, in the acute phase, with slight swelling from effusion of blood, and later with the formation of irregular masses of fibrous tissue in the tendon.

Treatment

In all these cases, rest is essential In partial ruptures, when the pain is not severe, it may be sufficient to raise the height of the heel of the shoe from half to three-quarters of an inch, to prevent any overstretching of the tendon. If there is a history of a definite traumatic episode inspection by operation of any suspected tear or rupture is essential so that early suture can be carried out.

In the case of a persistent periostitis, it may be necessary to erase the affected periosteum,

Clinical Features

The condition may arise at any age, and as it is not confined to the period before the epiphysis is fused, Kohler's original conception is wrong.

In its acute phase, while the articular surface is collapsing, there is extreme pain in the foot, movements are painful, and there may be considerable œdema of the forefoot, especially marked on the dorsum. Later, when the collapse is complete, the pain may subside, leaving a deformed joint which is also less capable of free mobility than before

The *X-ray changes* are characteristic:

1. There is broadening of the metatarsal head
2. The head is irregular in contour and flat.
3. The joint space is increased
4. The shaft of the metatarsal is thick
5. Detached portions of the articular surface may lie free in the joint.

Treatment

In the acute stages the application of a walking plaster cast will afford relief. In mild cases the use of a metatarsal bar or pad may be all that is necessary.

If stiffness or pain persist when the cycle of pathology is complete, relief may be obtained by re-shaping the head of the affected metatarsal to its normal shape, and this operation is preferred to excision of the head, which although it is more certain of relieving the immediate symptoms may have the disadvantage of weakening the transverse arch.

PAINFUL CONDITIONS OF THE HEEL

Pain in the heel frequently occurs in persons who stand or walk a great deal—hence the term "policeman's heel"—but may also arise from other causes. Whatever the origin, the pain is usually aggravated by use, and may be entirely absent during rest The painful area can always be found by digital pressure

The causes of this painful condition may be classified as follows

1 Traumatic disturbances.
2 Pathological disturbances

1. Traumatic Disturbances

The Effect of Trauma. Pain resulting from trauma may be situated at the back of the heel, around the insertion of the tendo-calcaneus, or on the plantar aspect.

When situated in the region of the tendo-calcaneus, the underlying conditions are—tenosynovitis of the tendon sheath, the formation and irritation of enlarged bursæ, and partial tears of the tendon In all cases the pain is rendered worse by movement and may even be completely relieved by rest In *teno-synovitis* of the tendo-calcaneus there is swelling from effusion, often accompanied by fine crepitus, and when

aspect of the heel, and most marked at the attachment of the plantar fascia to the medial tubercle of the calcaneus, and occasionally slight swelling at the attachment of the fascia.

X-ray examination may or may not reveal the presence of a spur.

TREATMENT

Non-Operative Treatment. Any obvious cause, such as gonococcal infection or infected tonsils or teeth, must be dealt with. If the pain is acute, the patient should be kept in bed and fomentations applied. After the pain and tenderness have disappeared, proper shoes should be ordered and felt or sponge-rubber pads inserted to relieve weight-bearing on painful areas. A rubber heel should be substituted for the heel of the shoe, with an area cut out below the tender area. Rose regards the strain as being a longitudinal one along the plantar fascia and therefore recommends a complete insole with a convex wedge of sorbo rubber to support the entire length of the fascia.

In some cases, considerable relief may be afforded by the use of radiant heat or diathermy or by the injection of solutions of hydrocortisone acetate, or novocaine, or even saline into the tender area.

Operative treatment may be undertaken in resistant cases, and the spur, when present, removed; some observers think this unwise since they hold that the spur is never the cause of the symptoms *per se.* It is certain that if it is to be undertaken, the operation should be postponed till the infective or toxic agent producing the fascial disturbance is quieted; for if operation is undertaken in the actively painful stage of the disease, the hyperæmia following the operation may lead to further spur formation.

The operation is performed through an incision along the medial border of the foot, the spur being removed by means of an osteotome.

(c) Traumatic Sub-taloid Arthritis.

Fractures of the heel bone are usually caused by a fall on the feet from a height, and as they may not produce any gross deformity at the time, are liable to be overlooked unless the most careful X-ray examination is carried out. These undetected fractures may ultimately give rise to a very troublesome painfulness and weakness of the foot which may constitute a grave and lasting disability for a working man The pain and weakness are due to a chronic sub-taloid arthritis for which the only treatment that is likely to be of any benefit is a fusion of the joint. the operation for this is described on page 935.

2. Painful Heel due to Pathological Disturbances

Apart from trauma, pain in the heel may have its origin in organic disease of the bone or epiphysis, and the infection may be tuberculous, syphilitic, or pyogenic, or may follow a general gonococcal or rheumatic toxæmia.

Roth deprecates operation in cases of prominent heel bone, believing that the symptoms produced by it may be obviated by beating out the lateral half of the counter of the shoe at the back of the heel to accommodate the enlargement. However, in some cases this conservative treatment fails and it is necessary in adult cases to remove the prominent postero-superior angle of the calcaneus and any exostoses. In the younger adolescent patient this may not be sufficient, and, in a few, excision of a wedge-shaped piece of bone, the base uppermost, and a pushing forward of the posterior remainder as described by Zadeck and Thomson, is necessary.

In *acute bursitis*, relief may be obtained by rest from movement, and by fomenting. In subacute and chronic cases, the bursa may be raised above the level of the shoe by the use of a sponge-rubber heel inside. In cases where relief of friction does not lead to resolution, the bursa may be excised and also the prominent bone

Pain on the *plantar aspect of the heel* is due to the formation of *calcanean* spurs, or to traumatic or inflammatory *fibrositis* at the insertion of the plantar fascia without spur formation

(*a*) Plantar Fibrositis.

Pain may arise at the insertion of the plantar fascia in association with focal sepsis, metabolic disturbances such as gout, or rheumatism.

(*b*) Calcanean Spurs.

The occurrence of a spike of bone at the anterior edge of the calcanean tuberosities—usually the medial—is known as a calcanean spur.

It may be a sequel to repeated attacks of plantar fasciitis, or result from trauma In the former case, the repeated hyperæmia leads to the abstraction of calcium from the calcaneus, and, the granulation tissue produced by the inflammatory reaction constituting an ossifiable medium as the hyperæmia resolves, the available calcium is deposited in it to produce the spur. It is possible that the constant pull of a shortened plantar fascia—or traumatic separation of slips of the fascia, or the constant trauma of ill-fitting footwear—may also produce the spur in a similar way, i e. by inducing hyperæmia, but it is also suggested that these factors operate by causing tiny detachments of the periosteum at the insertion of the fascia, and, in consequence, small sub-periosteal deposits of new bone.

Clinical Features

It is generally believed that since the formation of a calcanean spur is secondary to fibrositis or traumatic detachments of the plantar fascia, it does not give rise to symptoms *per se*, and that pain, when present, is due to the causative condition and not to the spur.

The characteristic features are pain in the ball of the heel, especially marked on long standing or walking, tenderness on the plantar

of Paris and, after three weeks, graduated exercises. In the complete rupture operation is often worth while to evacuate the effusion, to evaluate the degree of articular cartilage damage, and to reconstitute the ruptured ligament. Immobilization in plaster of Paris is essential for six to ten weeks with graduated exercises and weight-bearing during the last three to six weeks.

Failure to treat the acute strains properly may result in the syndrome of the chronic strain of the external collateral ligament, which is commonly seen in middle-aged women. They complain that they are continually "falling over" their ankle, with pain and swelling. On examination during an acute episode there is local tenderness and pain over the ligament on forced inversion of the foot. Radiographs for "talar tilt" are taken to exclude a complete rupture.

Treatment is aimed at preventing the twisting episodes by lowering the heel of the shoe and flaring out the lateral edge of the heel by $\frac{1}{4}$ inch. The acute episode is treated by injecting procaine or hydrocortisone solutions and by bandaging.

(2) Traumatic Arthritis of the Ankle. McMurray called this "Footballer's Ankle," but it is commonly seen in most athletes. McDougall has recently reviewed this subject and considers it to have resulted from repeated minor traumata to the capsular attachments and repeated compression injuries of the bones which are in contact during extreme dorsi- and plantar-flexion. Bony exostoses are produced in the tibial margin, on the malleoli, and on the neck of the dorsum of the talus.

After a definite history of a twisting injury there is a generalized aching pain around the ankle with tenderness in the above areas. An effusion may form and radiographically the picture is obvious.

Treatment consists of resting from the sport, a supporting bandage, and graduated physiotherapy before being allowed to return to the sport. If there is a severe effusion, immobilization for two to three weeks may be necessary If conservative treatment fails and the patient is keen to continue the sport, operation is recommended to remove the bony outgrowths and immobilization in plaster for four weeks is necessary.

CLAW FOOT

The term claw foot, or pes cavus, is applied to a deformity in which clawing of the toes is combined with a raising of the long arch of the foot, and which may arise either as a congenital or as an acquired deformity.

If congenital, it does not usually become apparent until the child is six or seven years old About half the cases of congenital claw foot are associated with a spina bifida occulta, while Beykirch believes that the majority of the remainder occur as the result of developmental aberration involving the spinal cord—a myelo-dysplasia.

(*a*) Epiphysitis of the Calcaneus.

This condition is described in the chapter on Diseases of the Epiphyses It usually occurs in boys between the ages of 9 and 13, and in the differential diagnosis various conditions have to be borne in mind :

(*1*) *Calcanean bursitis.* In this condition the inflammation is more superficial and localized. The X-ray bone picture is negative.

(*2*) *Teno-synovitis* of the tendo-calcaneus is characterized by pain referred to the tendon. and by palpable silky crepitus on movement. X-ray examination is again negative

(*3*) *Bursitis* between the calcanean tendon and the skin is a superficial inflammation, usually the result of pressure from the shoe, and is readily recognized

(*4*) *Calcanean Spurs* These are rare in early adolescence and are usually found on the infero-medial aspect of the calcaneus. The area of sensitiveness suggests the diagnosis, which should be confirmed by X-ray examination.

(*b*) Tuberculosis of the Calcaneus.

This is usually situated in the anterior rather than the posterior region of the bone An X-ray photograph materially aids differential diagnosis, and shows a degree of bone atrophy that is not found in epiphysitis.

(*c*) Pyogenic Infection.

This produces marked inflammatory reaction, with destruction of bone.

PAINFUL CONDITIONS OF THE ANKLE

Pain around this joint is a frequent complaint which may become chronic in nature, causing definite disability Commonly it arises from (1) sprains of the ankle joint, or (2) traumatic arthritis

(1) Sprains of the Ankle Joint. These result from a twisting injury in which there are abduction, adduction, and rotatory strains, and produce damage to the deltoid and external collateral ligaments of the ankle Tucker has graded them mild, moderate, and severe, depending upon the amount of fibres torn, from a few fibres to a complete rupture with an unstable joint On examination there is swelling, bruising, and local tenderness over the ligaments But radiography is essential to distinguish ligamentous injury from that of a fracture of the lateral malleolus, as well as to show the presence of "talar tilt" on strongly inverting the foot, even under anæsthesia, which indicates complete rupture of the ligament

TREATMENT in the mild cases is to support the damaged ligament by a pad and bandaging, to inject procaine or hydrocortisone solutions, and then graduated active exercises The moderate case requires aspiration of the effusion or the hæmatoma, immobilization in plaster

First Degree Claw Foot. At this stage the complaint is that the child is clumsy, and that when running about he frequently falls without apparent cause, or catches his toes against low objects such as the edge of a carpet. Formerly attributed to contracture of the tendo-calcaneus, it has been shown by Todd that the only evidence at this stage is a slight extensor weakness which may be evidenced by inability to pull up the toes, or by slight difference in the diameter of the two limbs. The tendo-calcaneus is not shortened, and if the forefoot is covered, the posterior part of the foot looks normal, i e. there is no equinus

Second Degree Claw Foot. At this stage, in addition to the slight flexion of the forefoot there is dorsiflexion of the great toe at the metatarso-phalangeal, and flexion at the interphalangeal joint. The plantar fascia is felt to be tense and contracted, and there is visible deformity. A characteristic of the deformity at this stage is that the clawing can be made to disappear by upward pressure on the ball of the great toe, showing that it is caused by a downward dropping of the metatarsal head. While a child may not complain of any pain, an older patient is apt to suffer some discomfort after prolonged walking.

Third Degree Claw Foot. In the third stage, the arch of the foot is markedly raised, and all the toes are fixed in flexion, while the tendo-calcaneus may begin to appear contracted. The plantar structures are further shortened and all the toes now dorsiflexed at the metatarso-phalangeal joints and flexed at the interphalangeal joints These deformities are becoming rigid and it is no longer possible to correct the deformity by finger pressure under the first metatarsal head. The chief complaint may be of painful corns which form on the dorsum of the flexed interphalangeal joints or on the points of the toes, but in addition, such a foot is one which tires easily after much standing or walking, and a marked degree of claw foot is a greater handicap than a corresponding degree of flatness, should the patient wish to join a Service.

Fourth Degree Claw Foot. In the fourth stage, in addition to the cavus and the hammered toes, there is adduction at the tarso-metatarsal joints, resulting in a kind of varus deformity. The foot is now rigid and painful, tender callosities are present on the outer side and under the metatarsal heads, and walking is becoming increasingly painful and difficult

Fifth Degree Claw Foot. The fifth stage is seen only in cases following some paralytic condition The toes are blue and cold, the whole foot is contracted into a rigid equino-varus, with a high arch and hammered toes The patient is in a most disabled condition and exquisitely tender callosities are present.

Jones and Lovett divide the acquired type into four groups.

1. Claw Foot in Infantile Paralysis. Claw foot frequently occurs after a preceding attack of poliomyelitis, more especially where the paresis is almost negligible, and it is, in fact, frequently a characteristic deformity of the so-called "sound leg." Duchenne suggested that it was due to paralysis of the interossei and the lumbricals, thus bringing it into line with the "main en griffe" of ulnar paralysis.

2. Claw Foot in Progressive Lesions of the Central Nervous System. Claw foot, usually bilateral, is a well-known clinical accompaniment of Friedreich's ataxia, of the peroneal type of muscular atrophy, and of other rare affections of the central nervous system.

3. Claw Foot following Inflammatory Infections. The deformity may be a sequel to inflammatory contracture of the soft tissues of the sole of the foot.

Fig 371 —Claw Foot of Third Degree with marked Deformity of Toes

4. Idiopathic Claw Foot. This is the most common and most important type. It is probably due to some dysfunction or absence of the lumbrical muscles. These normally flex the metatarso-phalangeal joints and extend the inter-phalangeal ones. When the long flexor contracts on this straight digit it slings up the head of the metatarsals and prevents a drop of the forefoot on the hind foot. In the absence of the lumbricals the long flexor pulls the toes into flexion and no longer supports the metatarsal heads. The forefoot drops and the lax structures in the sole contract or "take up the slack," with the formation of the typical claw foot The hind foot in this deformity is normal—the condition being a dropping of the forefoot on the hind foot followed by a contracture of the plantar fascia and a clawing of the toes.

There is, in addition to the pes cavus, some adduction of the forefoot from the beginning An element of adduction and inversion appears in the late stage of the process, as well as some secondary contracture of the tendo-calcaneus.

Fig 372 —The plantar aspect of a Claw Foot

Clinical Features

Great stress was formerly laid on the conventional division of the clinical features of claw foot into a series of stages, but it is important to recall that the deformity is a progressive one. There is seldom pain in childhood but complaint may be made of the rapidity with which shoes are worn out.

the sole of the foot which arise from, or are attached to, the under surface of the calcaneus be separated from that bone through an incision on the medial or lateral side of the heel He made a horseshoe flap right round the heel through which he dissected off the plantar fascia and muscles from the calcaneus, but the majority of surgeons use a single medial incision. The structures are erased right forward to the calcaneo-cuboid joint on the lateral side, and to the talo-navicular on the medial side where they take up a new attachment, the procedure is thus a "muscle-slide" operation. The extensor tendons of the toes, which may lead to a relapse, may now be divided.

A horizontal osteotomy of the calcaneus with a slide forward of the lower half is a useful method used by the author. It ensures a permanent forward displacement of the short structures which so often re-attach themselves in the Steindler operation.

Lambrinudi's Operation. Lambrinudi found that correction of the clawing of the toes not only causes considerable improvement of the deformity and therefore reduction of symptoms from corns and callosities, but a marked improvement of the general function of the foot. The principle underlying the operation he has devised is that by arthrodesis of the inter-phalangeal joints the long flexor muscles take up the function of the lumbricals and flex the toes at the metatarso-phalangeal joints and themselves sling up the metatarsal heads, tending to straighten out the foot.

Through lateral incisions along the dorsum of the toes or simple transverse incisions over the dorsal aspect of each joint the interphalangeal joints are exposed and their opposing surfaces excised. Arthrodesis may be achieved either by relying on simple apposition of the apposed cut surfaces or by a long pin through the joints or, in some cases, the union may be got by carrying out the "spike" operation (*vide* p. 899). The extensor tendons of the second, third, fourth and fifth toes are tenotomized and also the dorsal part of the capsule of the metatarso-phalangeal joint. In some cases Lambrinudi advises that the extensor tendons be transplanted into their own metatarsal necks, though this is usually unnecessary since the flexor tendon in the presence of a single finger of bone to the toe acts as a sling to the metatarsal heads and holds them up Interference with the fifth toe may be unnecessary, but if the deformity is gross the toe is amputated Before closing the dorsal incisions a strong silkworm gut suture is passed from the flexor aspect of the toe round the proximal phalanx and out on to the plantar aspect close to the point of insertion. Lambrinudi uses a special sole plate to which these sutures are tied, thus maintaining the corrected position at the metatarso-phalangeal joints. The sutures, however, may be tied to a section of Cramer wire attached to a light plaster case enclosing the foot and leg The advantage of the silkworm gut sutures round the phalanges is maintenance of the correction without pressure on the skin or interference with the circulation of the toes. The sole plate or plaster case and anchoring sutures are retained for eight to ten

Treatment

First Degree.

Progress may be arrested by re-educating the small muscle function and by exercises to strengthen the foot muscles in general

The treatment consists of the use of a shoe with a ½-inch thick metatarsal bar placed across the sole immediately behind the heads of the metatarsal bones. Shoes without heels are helpful.

Second Degree.

A shoe fitted with a metatarsal bar may give temporary relief, but adequate treatment of this stage is by operation.

The plantar fascia is divided subcutaneously and the tendon of the extensor proprius hallucis divided at its insertion and passed through the neck of the first metatarsal. Arthrodesis of the interphalangeal

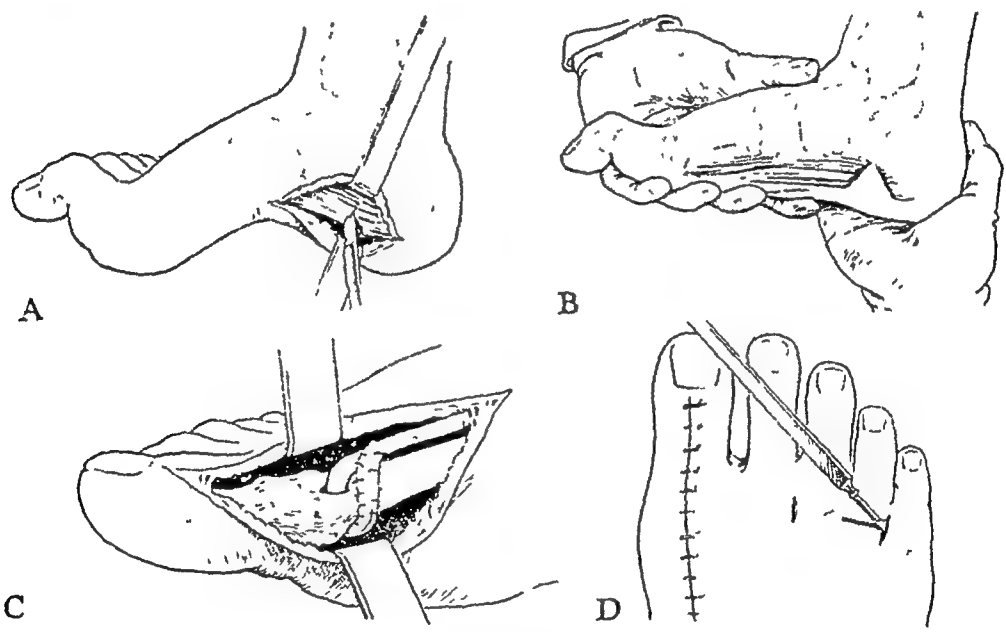

Fig 373 —The Treatment of a moderate degree of Claw Foot by Tenotomy and Tendon Transplantation

joint in a straight plane is then carried out to improve the function of "take off" in walking. After the fasciotomy the foot is wrenched. A plaster-of-Paris case is then applied to the foot to maintain the corrected position for a period of three or four weeks Afterwards a metatarsal bar is affixed to the shoe.

Third Degree.

Treatment of third degree claw foot is on the same lines as in second degree, but it is, of necessity, more thorough, more extensive, and more drastic.

Steindler recommends that in the first place, all the structures on

INGROWING TOE-NAIL

(Onycho-Cryptosis)

Ingrowing toe-nail is an extremely painful and distressing complaint which is caused essentially by the pressure of the shoe against the toe; the soft parts are forced against the nail, and if it has been carelessly trimmed and has a sharp edge, considerable pain results Nature normally protects the skin from the sharp nail edge by laying down in the nail fold skin of a more horny texture than that in the immediate vicinity. The pain is caused by a splinter of nail growing forward along the lateral groove into the soft tissues. This is the lateral edge of the nail which, owing to its hidden position, has not been adequately cut. It grows forward and penetrates the subcutaneous tissues, often carrying infection with it.

Treatment

Prophylaxis. The nail should be cut at right angles to its long axis and not convexly which destroys to some extent the protective infolding of its edge

The actual treatment of the established condition depends upon the severity of the case, and the control one expects to have over the patient. In hospital patients, for example, radical measures are the most satisfactory, but where time is not important, as in private practice, operation is seldom necessary.

Conservative Treatment. This consists in removing all possible sources of pressure, such as that of narrow shoes or narrow stockings, and in removing the irritation caused by the pressure of the nail edge. Many a slightly ingrowing nail is best left alone, the only precaution necessary being to warn the patient that he should cut the nail to its extreme edge thus avoiding the development of splinters.

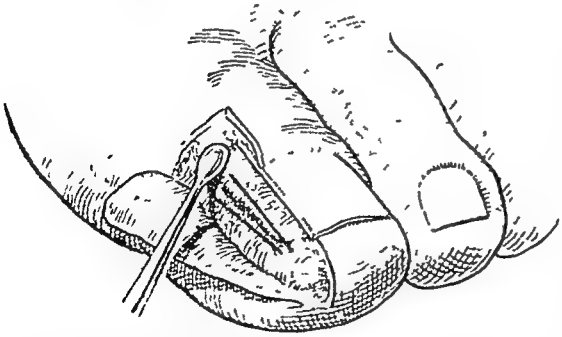

Fig. 376.—Ingrowing toe-nail The operation removes the whole of the abnormal and painful area.

Operative Treatment. The radical treatment consists of the removal of the sharp edge of the nail and its underlying matrix. A V-wedge, including about a third of the breadth of the nail, along with the nail fold, is excised from the lateral surface of the toe. The edges cannot be completely brought together, but they are approximated as far as possible with silk-worm gut sutures, as small a surface as possible being left to granulate

This operation is not always successful as often spicules of nail grow at the edges irregularly and give pain. An amputation of the

weeks by which time the ankylosis is firm and graduated exercises may be commenced. The procedure is tedious and time consuming, but the author has been impressed by the results of the cases treated by this operation.

Fourth Degree.

In the fourth stage, the high crooked arch can usually be corrected only by dividing the bones across at the level of the mid-tarsal joint A simple transverse division of the tarsus is seldom sufficient, and a wedge of bone has to be removed with its base at the dorsum of the foot, and including a considerable portion of the head and neck of the talus. If the deformity is very rigid, with marked bony deformation, a reconstruction operation, such as that devised by Naughton Dunn, may be advisable.

Fifth Degree.

Amputation of the foot is often considered to be the treatment of choice, but by means of a conservative operation a very useful foot can often be obtained, and one which will serve the patient better than an amputation stump which, at this stage, is invariably ill-adapted for wearing an artificial foot

The talus is first removed by the usual curved incision underneath the lateral malleolus. The toes, with the heads of all the metatarsal bones, are then removed through dorsal and plantar rectangular flaps, and the stumps covered over by the flaps.

SHORTENING OF THE TENDO-CALCANEUS

Slight degrees of contracture of the tendo-calcaneus are normal in many people, women, for example, who wear high heels often show it. In most cases it is not a source of discomfort, but where there are other evidences of foot strain the shortening of this tendon should not be overlooked. Shortening may also be due to reflex spasm, when the mechanics of the foot have been disturbed, and is in this case similar to the peroneal spasm which occurs in other cases

When it is due to reflex irritation, the mechanical errors which cause it should be corrected; if there is actual structural shortening, some form of stretching must be undertaken

Where the contracture is slight this may be carried out simply by removing the heel of the boot, or by adding a metatarsal bar across the front of the sole, both of which increase the pull on the tendon. The shortening may also be abolished by manipulation, repeated several times, although this is accompanied by some pain and discomfort in the calf muscles.

Where the shortening is considerable, it may be necessary to apply a plaster case to the foot and leg, with the knee in acute flexion, and thereafter to extend the knee, the tension thus placed on the gastrocnemius stretching the tendon

bed is the best treatment since removal of the nail itself is followed by further deformity in the new growth. This may be done by an amputation of the terminal phalanx, or by accurate dissection of the nail bed followed by a skin graft.

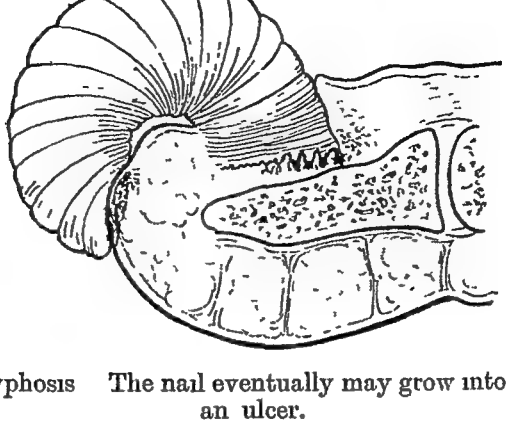

FIG 377.—Onycho-gryphosis The nail eventually may grow into the pulp and produce an ulcer.

SUBUNGUAL EXOSTOSIS

Subungual exostoses are usually due to old injuries, a mild periostitis, or a recent injury. They arise from a cartilaginous outgrowth under the nail and become osseous. They are three times as common in women and arise most frequently between the ages of twelve and thirty years.

The patient complains of acute and fairly continuous pain which is worse with the compression of the shoe. X-ray examination is diagnostic

The accepted method of treatment is by surgical removal The nail is removed and the growth peeled away from the phalanx The site may be painted with phenol followed by alcohol, and a tulle gras dressing is applied with pressure.

HYPERIDROSIS

Excessive perspiration of the feet may prove a most disagreeable and troublesome affection; the stockings and the shoe leather become damp, and bacterial growth induces a pungent and penetrating odour.

The condition is really a functional disease of the sweat glands of the feet and is probably nervous in origin. It is commonest in young males, and is frequently associated with the weak type of foot.

TREATMENT

In the mild cases, nothing further is required than a frequent change of stockings which should be of wool, and before being worn they should be well powdered with equal parts of boric and salicylic acids.

When the soles of the feet are particularly affected, cork insoles should be worn in the shoes, a fresh pair being inserted whenever the

tip of the toe with removal of the nail bed and terminal phalanx gives a good result and does not affect function. Excision of the whole nail bed, together with a thin slice from the dorsal aspect of the phalanx to which the nail bed is so intimately connected, followed immediately by a whole thickness skin-graft, is done with success.

In the presence of chronic sepsis suture must not be carried out. A small vaseline dressing is applied to the raw area which is allowed to heal by granulation tissue.

Reduction of excessive granulation tissue can be obtained by repeated applications of copper sulphate crystal, silver nitrate, or a strong solution of iron chloride

Operation should not be carried out in the presence of acute inflammation.

SUBUNGUAL HÆMATOMA

This occurs when a toe is tramped upon—often by a horse—and is the beginning of what is known as an ostler's toe There may be only minute reddish-black specks visible beneath the nail but in extreme cases the entire matrix becomes black from effused blood and in such a case the nail may be shed if untreated. There is not much space in the tip of a finger or toe so the tension of the hæmorrhage and œdema causes considerable pain. The initial pain can be relieved and complications averted. This is, of course, by evacuation of the blood and this may be achieved by drilling the nail over the blood by rotating a large sewing or skin needle. The blood is then expressed by gentle pressure. Recurrence is prevented by applying a pressure bandage for twenty-four hours. For the operation a digital nerve block anæsthesia may be used.

ONYCHO-GRYPHOSIS

This condition, sometimes called Ram's Horn Nail, or Ostler's Toe (because of frequent injury from the tread of a horse's foot), affects usually the great toe-nail and is an irregular hypertrophy of the nail whereby it grows to a considerable size, is irregular, hard, cross-ridged, and is curved with its convexity upwards instead of the normal flatness. The proximal aspect grows more rapidly than the distal and so the nail curves forwards and downwards and may ultimately erode into the pulp of the toe, become infected, and, it is said, may develop into a malignant epithelial growth Injury and infection are alleged to be the cause

Treatment

In the aged and bedridden in whom the condition is common, due, it is said, to the constant trauma of the bedclothes, palliative treatment is obviously proper This is best carried out by a chiropodist who keeps the growth in check by frequent paring and softening if necessary, by Liquor Potasii or Salicylic Acid. Complete excision of the nail

lesions may become nodular, ulcerate, and heal with pigmented scar formation

Lewis considered that pathologically it consists of arterial spasm, dilatation of other blood vessels, leading to an endarteritis obliterans, fat necrosis, and changes of chronic inflammation.

Prevention can be achieved by wearing woollen stockings Treatment is aimed at relieving the arterial spasm by heavy doses of vasodilators, i.e , nicotinic acid or tolazoline, but in very severe cases with ulceration sympathectomy may be required. Cases of marked improvement after treatment by phenoxybensamine have been reported

THE SESAMOID BONES OF THE GREAT TOE

The cartilaginous precursors of the sesamoid bones appear in early fœtal life, but do not ossify until between the ages of 8 and 11. Ossification may occur from a single centre, or from several centres, which are extremely variable in position In 10 per cent. of individuals these centres do not unite, constituting the condition of multipartite sesamoid.

Fracture of the Sesamoid Bones

The sesamoid bones of the great toe, particularly the medial, are occasionally fractured The violence may be either direct or indirect, but usually results from sudden falls upon the feet, or the dropping of heavy weights on the toe.

The symptoms are those of a sudden sharp pain, at the time of the injury, or at a later date, pain following the appearance of secondary changes The pain is situated over the affected sesamoid, and is aggravated by movement of the metatarso-phalangeal joint of the great toe It tends to diminish with rest, but returns on exercise, so that the patient is often forced to walk on the lateral side of the foot. Tenderness can be elicited by direct pressure on the plantar surface of the damaged sesamoid Osteo-arthritis of the joint between the sesamoids and the under surface of the metatarsal head may also be a cause of pain.

The diagnosis of a fractured sesamoid should be made with reservation owing to the frequency of the multipartite condition. In the multipartite condition, the gap between the separate portions is even, the long margins smooth, rounded, and well calcified, whereas fractured edges are indented and irregular and porotic Congenital subdivisions are also said to be usually transverse, and rarely oblique or longitudinal, although both of these have been described The degree of separation is further said to be wider in fractures than in congenital separations.

Inge and Ferguson believe that a diagnosis should not be made unless a previous X-ray shows the affected bone to be complete, or unless subsequent X-rays or pathological section demonstrates callus.

stockings are changed, and the feet should be bathed daily in hot and cold water alternately, dried, rubbed with alcohol, and powdered. A foot-bath of 1 · 1,000 solution of potassium permanganate is also of value. Sympathectomy has been advocated as a helpful method.

When the smell is disagreeable, a solution of chromic acid, 40 grs. to the oz., may be employed about once a week as a foot wash.

ATHLETE'S FOOT

There are many different kinds of fungus infection of the skin of the feet The group name for these infections is mycosis. One of the most common is tinea, commonly known as ringworm or athlete's foot although it is not confined to athletes or to feet. It is also known as epidermophytosis and is caused by a parasite.

There is itching, softening and peeling of the skin between the toes and on the sole of the foot. Often there are numerous tiny blisters. Itching may be intense and pus may develop under crusts from a mixed infection. The condition is highly infectious and is found particularly in habitués of gymnasia and baths.

The diagnosis is confirmed by laboratory methods; the organisms are readily seen under the microscope.

Prophylaxis. The condition is contracted by direct implantation of the parasite, and especially where warmth and dampness are present. Common sources are locker rooms, swimming pools, bathing beaches and gymnasia. Prophylactic measures include strict foot hygiene and the avoidance of bare foot walking Footbaths containing 15 per cent. sodium thiosulphate should be available in baths, etc. As a substitute the application of a 20 per cent powder of sodium thiosulphate between the toes, around the nails, and inside the socks and shoes is effective.

Curative Treatment. Dryness and cleanliness of the feet, hosiery and shoes is essential.

(1) Most cases of chronic ringworm will respond to 3 per cent. salicylic acid and 5 per cent. sulphur precipitate in petroleum applied every night, and a drying astringent powder during the day. Footwear should be dusted with this powder.

(2) After washing and drying the feet they may be painted with a 20 per cent. solution of formalin. Dry the feet in the air and apply an emulsion of castor oil, liquid paraffin, and lanolin in equal proportions.

CHRONIC CHILBLAINS

(Erythema Pernio)

This is a common complaint of young or middle-aged women during the winter months associated with a climate of damp cold. The only other predisposing factor is that it is seen in a limb affected by poliomyelitis

This painful condition of reddish mottled swollen areas is symmetrical in the legs as well as on the toes and dorsum of the feet. These

CHAPTER XVII

SOME COMPLICATIONS OF TRAUMA

VOLKMANN'S ISCHÆMIC CONTRACTURE

In 1875 Volkmann described a contracture of the muscles of the wrist and fingers which followed tight bandaging of the arm in the treatment of fractures about the elbow. He believed that it was essentially due to ischæmia of the muscles, and that, as a result of deprivation of arterial blood, the muscles suffered from want of oxygen; the condition, he thought, was thus akin to rigor mortis He also showed that paralysis occurred simultaneously with the contracture, differing in this respect from the contracture which follows a primary nerve lesion.

Incidence and Etiology

The condition occurs most commonly in children in the first ten years of life, and follows injuries, particularly to the elbow, and especially those associated with pressure, either internal or external.

At one time it was accepted that the condition was caused by the effect of improper application of splints or by acute flexion of the elbow in turn producing a venous obstruction. Many surgeons have been condemned to pay heavy damages to patients when this assumption has been quite unwarranted. If a surgeon be at fault, it is much less likely to be due to any active action on his part than it is to failure to recognize the development of ischæmia at an early stage and to take the appropriate measures to counteract it. An artery, when subjected to quite minor injury, will often go into spasm and this spasm may persist indefinitely. Volkmann's contracture is the result of ischæmic infarction produced by a segmental arterial spasm of the main artery to an extremity with reflex spasm of the collateral circulation A sub-total ischæmia is produced and the muscle bellies, demanding the greatest amount of blood and therefore the most vulnerable tissue to its loss, are first affected. Possibly gangrene of the finger-tips would occur if the spasm continued in sufficiently severe degree, but the usual result of ischæmic contracture implies that some improvement in the collateral circulation intervenes. This vasomotor activity is under control of the sympathetic nervous system.

The injury is usually a fracture or injury of the upper arm, and in the cases where the injured site was explored a profound segmental arterial spasm was discovered Usually at a point about 2 centimetres above its bifurcation the brachial artery was pulsating normally or even a little dilated, but below that it suddenly became narrowed to a string-

These authors have operated on 41 cases of pain in the sesamoid bone following trauma, and were unable to demonstrate any specific pathology in the bones themselves. The pathological conditions present, to which they ascribe the pain, were inflammatory changes in the bursæ in relation to the sesamoid, and arthritis. In several cases, the outstanding error was a subluxation of the whole or part of the bone.

Treatment

The injured foot should be immobilized in a plaster-of-Paris case which includes the great toe until the fracture has healed—usually in from three to six weeks. If this treatment fails and the symptoms persist, the affected sesamoid bone, or bones, should be removed; but great care must be exercised in removing the bones from their tendons lest the tendons be severed. Both sesamoids need not and should not be removed unless there is a clear indication to do so since the excision of both increases the risk of dividing the tendon and may make weight-bearing difficult or impossible. The operation should be supplemented by adequate post-operative massage and early movement of the toe, and when the patient is allowed to go about, the incision should be suitably protected from friction against the shoe

OVERLAPPING OF THE FIFTH TOE

This is a frequent congenital lesion in which there is constriction of the tissues on the dorsum of the toe which is drawn into a varus position with subluxation It is mainly a cosmetic deformity and produces disability in less than 50 per cent. of all cases

Treatment consists of attempting to realign the small toe by various plastic operations Wilson uses an inverted V incision over the tight dorsal fold of skin and divides the underlying constricted soft tissues The V incision is then sutured as a Y. McFarland advises the excision of the base of the proximal phalanx and then produces an artificial syndactylism by excising a fillet of soft tissue and skin between the fifth and fourth toes. The skin is then sutured above and below the cleft. This is probably the better method

change and it is often striking; pressure on a nail will readily show whether the circulation is impaired. The pulse distal to the obstruction is invariably absent and therefore it is wise whenever possible to leave an accessible pulse uncovered by bandages for regular examination. Often there is intense pain, especially on attempted movement, and numbness in the fingers; ultimately voluntary movement is totally abolished. It is to be noted, however, that pain may be absent in some cases The complete process is over in the first two days, so that the necessity for prompt initial treatment is very urgent. After this period the swelling gradually disappears and the muscles become hard, fibrosed, and resistant. As the fibrosis increases, deformity becomes obvious—especially flexion of the fingers. The fully developed picture is very characteristic: the wrist is flexed; the fingers extended at the metacarpo-phalangeal joints, and flexed at the inter-phalangeal joints, while the forearm is often pronated and the elbow flexed

There are various degrees of the deformity.

1. *Mild degrees* are often first brought to the consultant several years after an injury to the elbow The patient may be unable to extend the fingers completely but yet may possess a considerable range of movement when the wrist is flexed, indeed, it is usually possible to straighten the fingers completely with the wrist fully flexed.

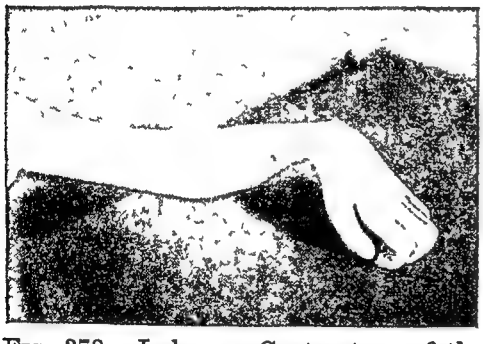

Fig 378.—Ischæmic Contracture of the Forearm Muscles

2. The *severe type*, with the fully developed and characteristic attitude described above

3. *A severe type complicated by nerve involvement* Either the median or ulnar nerve may be coincidently involved, but it must be remembered that, where the primary lesion is a supra-condylar fracture, these nerves may be injured, not by the Volkmann's contracture, but by the projecting fragments of bone In the absence of direct damage, however, either nerve may be implicated in the actual ischæmic contracture. The median nerve is frequently compressed where it passes between the two heads of the pronator teres, and the ulnar nerve may suffer from the contraction of the fibrous tissue which surrounds it; and in each case, the signs are those of an incomplete nerve lesion—usually partial anæsthesia, and paralysis of the small muscles of the hand. In addition the nutrition of the limb is impaired, the hand is cold and blue, and trophic ulceration occurs.

When the damage is reversible a limited number of muscle fibres die and they are gradually replaced by new ones growing longitudinally along the surviving sarcolemmal tubes Seddon points out that this takes a considerable time and in one of his cases the intrinsic muscles of the hand showed no improvement until after the 200th day. When

like size extending down into the radial and ulnar branches. The injury need not directly affect the vessel to produce the spasm. Although there may be a minor injury to the vessel wall that is not sufficient to occlude the vessel by the damage itself but causes the artery to occlude itself, probably through the sympathetic nerves. A similar spasm is seen following the lodgment of an embolus, and in fact may result from any disturbance of the peripheral circulation. The operation of arteriectomy in cases of embolic lodgment in a peripheral artery is based on this fact It is evident that a good collateral circulation is capable of supplying all the needs of the peripheral circulation and that the chief danger in cases of main-artery occlusion lies in the degree of constriction or dilatation of the collaterals that are under sympathetic vasomotor control.

Pathology

The gross picture, which is one of central degeneration of the muscle bundle, is duplicated histologically by only one other condition, infarction Seddon points out that the infarct takes the form of an ellipsoid with its axis in the line of the anterior interosseous artery and with its central point a little above the middle of the forearm. The greatest damage is at the centre and usually falls most heavily on flexor digitorum profundus and flexor pollicis longus which are often necrotic. Those muscles most superficially placed and sometimes the deep extensors are more likely to exhibit fibrosis. The median nerve runs near the centre of the ellipsoid and may exhibit profound ischæmia The ulnar nerve tends to be less severely affected The most extensive degeneration occurs in the centre of the muscle sequestrum, and cellular activity and fibrosis take place only at the periphery, which is surrounded by a sheath of dense fibrous tissue. In the centre of the mass, the muscle fibres lose their nuclei and cross striations, and fuse into a homogeneous mass, with little more than a defining membrane separating them As the periphery is approached, some signs of function are preserved, and there is an area of intense cellular activity, both fibroblastic and phagocytic. This picture is in contrast to muscle degeneration from all other causes, such as denervation and sepsis, in which the appearance is one of diffuse interfibrillar fibrosis.

The succeeding phases are those of replacement: fibroblasts appear, and deposit fibrous tissue, at first in thin threads and later more densely. The whole process thus seems to be one of absorption and replacement by fibrosis of dead muscular tissue A similar condition has recently been described affecting the anterior leg muscles caused by œdema in a patient taking much unaccustomed exercise.

Symptoms

The symptoms usually begin within a few hours to twenty-four hours of the injury. Griffiths says that pain, pallor, paralysis and pulselessness are all present in greater or lesser degree. Pallor is usually the first

circulation before irreparable damage is done and thus to avert contracture deformities. In treatment time is a major factor. The condition is a progressive one in which more and more damage is done All measures favouring circulation generally are of the greatest value. These include elevation of the part, removal of any splint or circular bandage, and the application of mild external warmth. The other limb, or other limbs, may be warmed as is done in immersion foot.

The next logical step is the interruption of the sympathetic reflex arc by ganglion injection or arteriectomy. The former is tried first, and if successful its results are at once apparent and an open operation is avoided. The appearance of a Horner syndrome is evidence of a successful cervical sympathetic block. The local arterial spasm may, however, be the result of a local reflex that does not include the paravertebral ganglions and so the injection cannot be expected to be universally successful, and if circulatory improvement is not immediately apparent or maintained the artery should be exposed. This at once affords an opportunity of determining any local trauma to the artery. When the spasmodically contracted artery is exposed the effect of papaverine is tried, especially if the vessel does not appear to be too badly damaged. The whole length of the affected part of the artery is flooded in a 2 per cent. solution of papaverine and in very many cases the spasm disappears within two or three minutes and the pulse returns at the wrist. If this is unsuccessful, complete interruption of the sympathetic arc is achieved by doing an arteriectomy, resecting a section of the artery at the level of the fracture Arteriectomy, in addition to the complete interruption of the reflex, has the advantage of the removal of a segment of the vessel which possibly contains a small break or tear not grossly visible, yet sufficient to maintain continued abnormal sensory stimuli. Its removal effectively produces vaso-dilatation of the collateral.

If the X-ray examination, which should have been completed by this time, does not show perfect reduction, the question of improving the alignment must be considered. It will be better in most cases to complete the reduction by open operation, since additional manipulation will further traumatize the tissues, and so increase the pain, and probably the deformity also.

2. Treatment of the Fully Developed Stage.

(*a*) **Mechanical Treatment.** The first step in treatment is to prevent contractures and maintain a supple joint with a full range of movements and so a splint is applied which makes use of elastic traction to prevent the muscles contracting while at the same time permitting the joints of the fingers and wrist to be moved, if necessary passively, to prevent them from becoming stiff

With the help of a good masseuse, the function of the hand should improve greatly, the circulation increase, and the fingers acquire greater voluntary power.

(*b*) **Operative Treatment.** A great variety of operations have

irreversible changes are present all grades of fibrosis are present up to almost complete fibrous replacement



Fig 379 —Ischæmic Contracture Extension of the fingers is possible only while the wrist is flexed.

Prognosis

The prognosis will depend upon the stage at which treatment is instituted · the earlier it is undertaken, the better the prognosis is likely to be. The outlook is grave in the severe types, and in cases with accompanying nerve involvement, but in the slighter degrees of contracture, without nerve involvement, treatment usually gives a comparatively good result.

Prophylaxis

Many limbs have been lost by adopting an attitude of wishful thinking after some or all of the signs of interference with the arterial circulation have been recognized. Action must be immediate.

The condition of the forearm and hand must be carefully watched in the early stages of treatment of all injuries of the elbow joint; and in this connection supra-condylar fracture of the humerus is particularly dangerous. The position of the elbow joint after reduction of these fractures will depend upon the extent of any swelling present, and it is only in a very few cases that it has to be acutely flexed; in every case, however, the forearm and hand should be carefully supervised for some time.

It is inadvisable to treat fractures about the elbow with plaster-of-Paris splints or bandages, particularly if they are applied in a circular fashion In all cases of elbow injury a look-out should be kept for pain, stiffness, swelling, cyanosis or lividity of the fingers, or obliteration of the radial pulse The first step, if the event has followed a fracture, is to see if the bones have moved. If they have, a further reduction should be carried out at once, and even if they have not, it is wise to extend the limb slightly because this is followed occasionally by relief of the spasm. Failure of the pulse to return within a few minutes is an indication for immediate operation.

Treatment

The treatment may be divided conveniently into various stages.

1. The Acute Stage. The goal of treatment is to restore adequate

up after a reasonable period of two or three months' physiotherapeutic treatment, the nerves should be explored at the sites where they are most likely to be compressed The median nerve should be freed from the callus of the fracture, and also released from compression as it passes under the superficial head of the pronator teres. The ulnar nerve is freed throughout the length of the flexor muscle bellies If the nerves have suffered irreversible damage they should be dealt with by one of the several types of graft according to Seddon. General physiotherapeutic treatment should afterwards be carefully carried out, the muscles at the same time being protected from over-stretching by adequate splints

MYOSITIS OSSIFICANS CIRCUMSCRIPTA

Intramuscular ossification may occur under many conditions, Gruta suggests the following classification

1. Myositis ossificans traumatica—
   (*a*) Following a severe single injury, or the application of blunt force.
   (*b*) Following dislocation
   (*c*) Following clean incised wounds
2. Myositis ossificans chronica—
   (*a*) Occurring after repeated slight injuries
   (*b*) From occupational strain of certain muscle groups.
3. Myositis ossificans of infectious origin
4. Myositis ossificans para-arthritica
5. Myositis ossificans neurotica.

The traumatic type, following a single injury, is by far the most frequent, accounting for about 75 per cent of his cases, and it occurs most commonly in the anterior and lateral aspects of the thigh, and in the upper arm It is liable to follow a backward dislocation of the elbow

It is not uncommon for bone to appear in the scar of a clean incised wound of the abdominal wall

The chronic type of myositis, occurring after repeated slight injuries, is most often seen in the "rider's bone" of the adductor muscles, where it arises because of the steady irritation of horse-back exercise Joiners and shoemakers not infrequently show some bone formation in certain muscles, either from over-straining, or from repeated slight injury.

An infectious type is said to follow spinal abscesses, or compound fractures of the forearm

Gruta described the para-arthritic form for the first time, and he stated that it arises in muscles and tendons, in relation to joints the site of chronic inflammatory processes such as arthritis deformans or tuberculosis.

Ossification has been reported in muscles and tendons in association with tabes, syringomyelia and myelitis.

been recommended for this condition, from tenoplasty, bone section, and excision of the elbow joint, to the muscle-sliding operation described by Max Page. In every case, operation should be preceded by a course of thorough stretching as described above.

Littlewood recommended lengthening of all the shortened tendons, but this is a serious operation in a young child, and requires great care and neatness if even a moderate result is to be secured. It should be attempted only if the contraction is limited to one or two of the forearm muscles

Shortening of the bones of the forearm by resection of ¾ to 1 inch from each is also a severe operation, and, according to Sir Robert Jones, it is liable to be followed by non-union due to the trophic changes in the arm The operation is recommended by Garré, but the results are not encouraging.

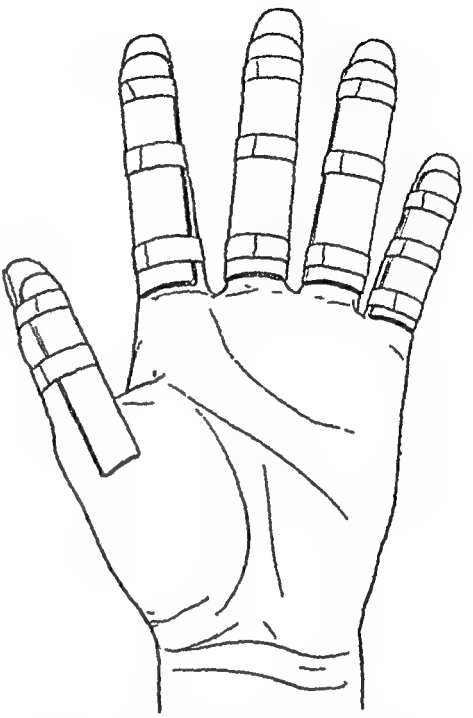

Fig 380 —Ischæmic Contracture Method of splinting the fingers

The operation which meets with most general approval nowadays is that of Max Page.

A straight incision is made from just above the medial epicondyle downwards for about 4 inches on the medial aspect of the forearm, and the flexor muscles, arising from the medial epicondyle of the humerus and the upper ends of the radius and ulna, are erased from their origins by a periosteal elevator. The hand and fingers are then hyperextended, and in this way the muscle origin is dragged downwards. The muscles obtain, in time, a new origin lower down the forearm. In performing the operation great care must be taken to avoid the ulnar nerve; if the nerve is involved, it should be freed from the surrounding fibrous tissue, and at the same time, the median nerve may be similarly dissected out and freed. The after-treatment consists of careful splinting of the hand and fingers, and reasoned physiotherapeutic treatment.

Seddon has achieved good results in severe cases by excising completely the muscle belly, or the scar representing it, of every muscle that has been completely destroyed and this immediately frees the contracture. Reconstructive procedures are carried out either at the same time or later by transplanting living muscles to replace the dead ones.

Treatment of the Nerve Complications. When there is clinical evidence of nerve involvement, which does not show any sign of clearing

2. That the new bone arises by metaplasia of the local fibrous tissue.

If the periosteum is injured, as, for example, by a severe blow, the osteoblastic layer may proliferate and osteoblasts escape into attached muscle, in which they deposit bone The periosteum at the site of muscular insertions may be torn by traction on the muscle, and the osteoblasts be liberated in this way.

The metaplastic theory is based on the clinical observations of Orth, who states that, in most cases, no connection even of fibrous tissue can be found between the skeletal bone and the adjacent mass in myositis ossificans. The radiological examination also shows that the ossifying process is unlike the orderly formation of new bone from the periosteum, since it shows scattered centres of ossification in the midst of clear areas or spaces. The existence of metaplasia is well known to pathologists, and can be seen in almost every part of the human body, so that there seems no reason to doubt the ability of the fibrous tissue to become converted into bone. Some authors have reported an increase in the amount of calcium salt in the blood serum during the occurrence of metaplasia, while Zanoli believes that the main factors in metaplasia are intoxication and infection, the toxins acting as irritants to tissues in a state of lowered resistance. Experiments, however, have failed to substantiate either of these two theories, and most investigators are of the opinion that there must be in addition a congenital factor. Virchow and others believe that there is a constitutional tendency—a Diathesis Ossificans—for fibrous tissue to react to injury by metaplasia into bone.

Pathology

The new bone differs both in form and in size from normal bone, and there may be large irregular masses of it occupying almost the whole of the muscle. The mass may be entirely separate from the shaft, or joined to it by a fibrous band, or even by a bony pedicle. Cysts are liable to form in the swelling, and microscopically an irregular mixture of bone, cartilage, muscle and connective tissue can be seen. Occasionally ossification occurs in the tendons both above and below the joint, in which case an extra-articular but complete ankylosis of the joint results.

The Course of the Disease. The course of the traumatic form is typical and may be divided into three stages:

1. In the first stage the traumatic symptoms predominate, lasting for a few days, during which time there is usually some swelling and limitation of movement which improves, but does not entirely disappear, as the acute symptoms subside.

2 At the end of the second week, or even later, pain reappears, movement becomes further limited, and the original swelling slowly increases. At the end of four weeks the X-ray film may show an irregular and distinct shadow parallel to the bone, but separated by a light zone.

Incidence

Myositis occurs usually in early adult life, between 17 and 25 years: it may arise at a much later age, however, and cases of the disease in patients of 70 years of age have been reported. The muscles most commonly affected are the quadriceps and the adductors in the lower limb, and the flexors of the elbow in the upper limb.

Etiology

Many theories have been advanced to explain the occurrence of myositis ossificans, and they fall naturally into two groups:

1. That the new bone arises from the periosteum of the adjacent bone

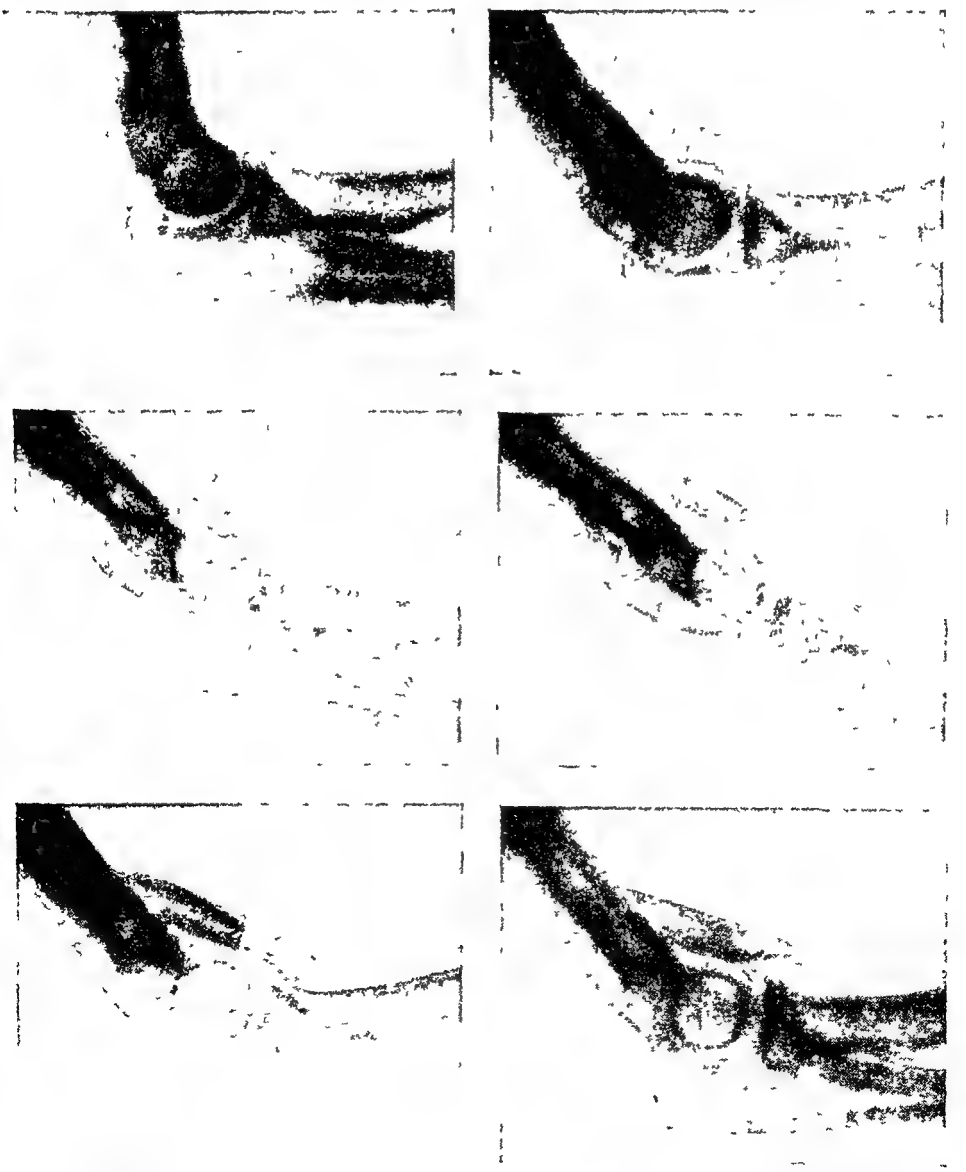

Fig 381 —From a case of Intra-muscular Osteoma following on dislocation of the elbow. The first picture was taken three weeks after reduction, the others at intervals of two months, seven weeks, seven weeks, nine weeks, and five months respectively

stages a sarcoma shows little change in the bone, and somewhat later —about the second month—the myositis shows some local decalcification of the underlying cortex which may suggest a sarcomatous origin, but in the sarcoma the erosion is associated with absorption of the spicular periosteal accretions immediately over it The bone in myositis gradually increases in density and the symptoms almost as gradually subside. A biopsy is not usually indicated because expert pathologists may mistake the two and because in the acute stage of a myositis surgical interference increases the ossification.

Treatment

Even without interference, myositis displays a marked tendency to retrogress, and eventually to disappear completely, and early operation is frequently followed by recurrence the consensus of opinion, therefore, is that conservative measures should be adopted, particularly in the early stages of the process. Any form of treatment which stimulates or irritates the affected part may favour or increase the intramuscular ossification . hence massage, forced passive movements, and even active movement should be prohibited at first Jones and Lovett point out in this connection that the modern practice in elbow injuries of enforcing rest, with the forearm supported by a sling and the elbow acutely flexed, is rarely followed by this complication. The part should therefore be rested, and all physiotherapeutic treatment discontinued. X-rays should be taken at regular intervals, in order to observe the growth or otherwise of the mass

Excision of the mass should not be contemplated until it has become stationary, and should be undertaken then only if the lump is unusually large, or is causing great limitation of movement

FRACTURES

A detailed review of the treatment of fractures is outwith the scope of this book , but some of the disabilities which result from them will be discussed briefly A certain number of fractures result in deformity, and in impairment of function , the objects of treatment, therefore, are to abolish the deformity and to restore complete function. Thus in the primary treatment of fractures the first essential is to secure *good alignment* of the fragments, so that the joint components may retain their correct relationship. In this connection it may be said that while correct apposition of the two ends is the ideal to be striven for, slight overlapping, with the fragments parallel, is compatible with good function, and is better than angling; angling of the fragments results in deflection of body-weight, as a result of which the joints above and below the fracture are subjected to abnormal strains and stresses. The second essential is to obtain *good union* , and the third is to preserve the *joint function*, which means the preservation of full joint mobility.

3. In the third stage the growth of the swelling may stop, or the lump may slowly increase by continued deposition The pain disappears and the X-ray film shows a sharply limited mass which is smaller, denser, and more homogeneous than before.

The period of active growth varies from ten weeks to six months, and inflammatory symptoms are practically never associated with the swelling.

Fig 382 —Myositis Ossificans in the Quadriceps Muscle of the Thigh.
The mass entirely disappeared after rest

Diagnosis

The diagnosis is not usually difficult, except in the early stage when many confusing conditions such as hæmatoma, callus, muscle tumours, osteomyelitis, syphilitic conditions, periostitis, and neoplasms have to be excluded The most important and sometimes the most difficult lesion to differentiate is sarcoma: both have many points in common—they develop in young persons, usually after trauma; they grow quickly and are hard in consistence, and the time which elapses after the original injury is usually the same. The features that assist the diagnosis are:

1. Sarcoma is usually situated near the epiphysis, whereas myositis is over the shaft. 2. Sarcoma grows more lavishly, and eventually invades the soft parts. 3 Late spontaneous and severe pain, which tends always to increase, indicates a neoplasm. A tendency for the swelling to diminish in size, and its uniformly hard consistence, together with pain which occurs early and gradually loses its intensity, are the peculiar features of myositis ossificans. On X-ray examination, the cortex and the periosteum are normal in myositis, and the newly formed mass lies parallel to the surface and separated from it by a distinct area; in sarcoma, on the other hand, there are early medullary changes, and early destruction of the cortex, while the bony mass contains trabeculæ which are obliquely or transversely disposed in relation to the shaft, with which they are visibly connected.

Yet there are cases which are extremely difficult to differentiate Often the patient is unable to remember any trauma. In the early

Treatment of Delayed Union

In general, it may be said that measures directed towards the improvement of the patient's condition will facilitate union between the bone-ends in fracture.

As the principal cause of non-union of a fracture is inadequate immobilization every effort must be made to immobilize the fracture and to protect it from all stresses and strains. Repeated movement of the fragments with reactionary hyperæmia causes resorption of the bone ends and the fracture line widens to a cavity and its line becomes woolly and ill-defined This fracture is only slow in uniting. If movement continues, the margins become well defined, and there is sclerosis present, then it is an example of non-union. The slowly uniting fracture is treated by complete immobilization, particularly avoiding excessive traction and shearing and rotational strains until union occurs. In certain situations the healing is delayed by a poor blood supply as in the scaphoid bone but even here if the fracture is in apposition adequate immobilization will ensure union. Almost the only indications for operation are the presence of a sequestrum in an infected fracture or the interposition of soft parts.

Non-Union

In un-united fractures the two fragments remain separate, and the bone-ends are eburnated and sclerosed; a gap usually exists between the fragments, and there may or may not be an actual pseud-arthrosis. The condition is permanent, and has to be distinguished from delayed union, in which the organization of the callus into solid bone is merely abnormally retarded. It is impossible to fix a time-limit within which union should have occurred, but if mobility is still present at the end of six months, the fracture may be considered un-united Cases have been reported, however, in which solid union has occurred at an even later period.

Etiology of Non-Union

The process of healing may be arrested at any stage in the repair of the fracture, and may be the result of local or constitutional errors, or both.

Local Causes.

1. The primary granulation tissue may fail to bridge the gap—
   (*a*) because of the interposition of soft parts,
   (*b*) because of mal-alignment of the fragments,
   (*c*) because of the actual loss of bony tissue.

2. The granulation tissue may become converted into fibrous or scar tissue before lime salts have become deposited, and the contraction of the fibrous tissue strangles the osteoblasts and deprives them of much of their nourishment

The late complications of fracture for which the services of the orthopædic surgeon may be sought are:

Delayed Union.
Non-Union.
Mal-Union, or Union in faulty position.

Each of these presents an individual problem.

Delayed Union

A fracture is said to be healed or united when there is more or less complete continuity between the fragments. The process of healing or union is accomplished in four stages:

1. A stage of preliminary fibrous union, or union by granulation tissue.
2. The formation of soft callus
3. The formation of hard callus, or bone.
4. Adaptive reconstruction of the callus to restore the original architecture of the bone

It is not always easy to decide when union is delayed, since the time of healing of fractures varies considerably, but the sites where delay most commonly occurs are the lower third of the tibia, the middle third of the humerus, and the middle third of the femur If the tibia is not completely united in eight weeks, the humerus in six weeks, and the femur in ten weeks, i e where there is still considerable mobility between the two ends after these periods, delayed union is present, though at this stage it does not require any other treatment than continuing immobilization

There is little information of a positive nature about supposed causes of non-union Delayed union is probably 90 per cent. preventable and there seems little doubt that too active treatment is to be avoided: once the fragments are in position they should be left alone Indeed, Watson-Jones says that non-union of fractures is due to the failure of the surgeon much more than to the failure of the osteoblasts and that with few exceptions it is an avoidable complication.

As the delay may be due to inefficient reduction, it becomes very necessary to obtain good alignment, to maintain it, and at the same time to see that the circulation of the limb is maintained. Union is frequently delayed in compound fractures. Loss of bone, removal of bone by operation, separation of the fragments by too strong traction, incomplete immobilization—especially when rotation of the fragments is permitted—are all obvious causes of non-union

Amongst the constitutional causes of delay are advanced age, and the presence of some acute or chronic disease, and it has been suggested also that the calcium- and phosphorus-content of the blood may be diminished in some cases.

constituents, plays a definite rôle in bone regeneration, despite the fact that Leriche has emphatically stated that the periosteum has no true osteogenic function. Cowan believes that in fractures the injured periosteum produces granulation tissue, which quickly becomes transformed into dense avascular fibrous tissue; that granulation tissue is also thrown out by the bone itself, chiefly from its marrow tissue, and that this is pro-callus in which the fibres are delicate and scanty, and the blood-vessels numerous, and in which deposition of calcium salts occurs early.

Clinical Features

The signs of non-union vary from slight movement between the fragments associated with pain, to pseudarthrosis and complete impairment of function. Where the union is almost complete the mobility may be very slight, but pain is usually experienced on active use, and is followed by swelling. Great care is necessary to distinguish non-union from delayed union; the distinction is best made by repeated clinical examinations and successive radiographs.

Treatment

1. Mechanical Treatment.

Treatment of non-union by mechanical means is merely palliative, and is applicable only when the general condition of the patient or local condition of the limb makes operation inadvisable.

When the humerus has failed to unite, a sheath of leather may be used which should extend as high as possible and reach down to the elbow joint, and should be attached to a sheath on the forearm by means of a joint at the elbow. The addition of a forearm piece makes the arm more useful and more stable

In un-united fracture of the femur some form of walking caliper splint such as Thomas's, in which the weight is taken on the tuber ischii, is the best form of apparatus. Again, a sheath of leather should be incorporated in the splint to encircle the thigh.

When the tibia is un-united, a short caliper from the heel of the boot to below the knee, along with a leather cage, is sometimes all that is required, in many cases, however, a walking caliper such as is used for the hip is necessary.

2. The Operative Treatment.

The effective treatment of non-union is essentially surgical, but in old compound fractures there is ever present a fear that operative interference will light up a previous pyogenic infection, as organisms may lie dormant either in the bone-ends or in the scar tissue between them

It is wise, therefore, to institute antibiotic treatment before operation. There may be a guide to the type of the drug from previous bacteriological reports; if not, then penicillin or streptomycin is used over a period of 10 to 14 days prior to the operation In cases of non-union

3 Injudicious manipulations and imperfect immobilization may interfere with the formation of the granulation tissue, destroy the fine capillary buds, and so lead to faulty local nutrition.

4. The blood supply to the fracture and its vicinity may be jeopardized by swelling or laceration of the soft parts, and the addition of any of the other factors may then be sufficient to defeat the efforts at union.

Phemister described an aseptic necrosis in fractures of the shaft and believed it to be a common cause of delayed union and non-union. This condition is really due to a deficiency of blood in one or both fragments and is a sequel to the trauma that produced the fracture; it has also been called traumatic arterial ischæmia by Girdlestone. Bone cells require for their work an adequate supply of blood and any diminution of the blood supply tends to subdue their activities and, according to the degree of ischæmia, the cells pass from quiescence to suspended animation or even death. The condition may be diagnosed from the X-ray examination after some weeks when it is noticed that one or other fragment does not share in the general decalcification normal at this period. Girdlestone recommends continuous accurate immobilization and at the same time active function of the limb.

5. Infection has in most cases a destructive effect on the developing callus and even on the fully-formed bone, which is seen especially in the non-union which sometimes follows the plating of fractures, where a low-grade infection is present

In spite of this long list of causes predisposing the failure of union of a fracture it is probable that the really important factor is some error in the treatment, and the usual one is the permission of undue strain or movement at the fracture site.

Constitutional Causes.

Among the more important general causes which predispose to non-union may be mentioned—

Endocrine deficiencies,

Acute or chronic illnesses,

Deficiency in the calcium and phosphorus content of the blood.

When the un-united fracture is exposed at operation, the cortex is found to be rough and usually devoid of periosteum for some distance on either side of the fracture The bone-ends may be either porous and atrophic, or sclerosed, and the callus over the proximal fragment is usually greater than that on the distal one. There may be a fibrous union between the fragments, or a definite joint cavity may exist with bursal sac, synovial fluid, and joint capsule, the so-called pseudarthrosis or "false joint." In some cases the fragments are atrophic, and terminate in cone-shaped ends which are covered with dense fibro-cartilage.

When delayed union follows a severe trauma, the periosteum is usually thin and difficult to raise from the bone without tearing and shredding. Mott believes that the periosteum, alone of all the bone

(*c*) **Bone-grafting Operation.** This is the ideal method of dealing with un-united fractures of the leg. In the first place the graft acts as an internal prop which helps to keep the fragments in alignment; it serves further as a conductive bridge along which new developing bone may cross from one fragment to the other; and it provides a source of new bone-reparative tissue. An autogenous graft is best, but homologous human bone stored in a bone bank may be used Now healthy bone from amputated limbs or removed in the course of other operations is kept in the refrigerating bone bank and transplanted as

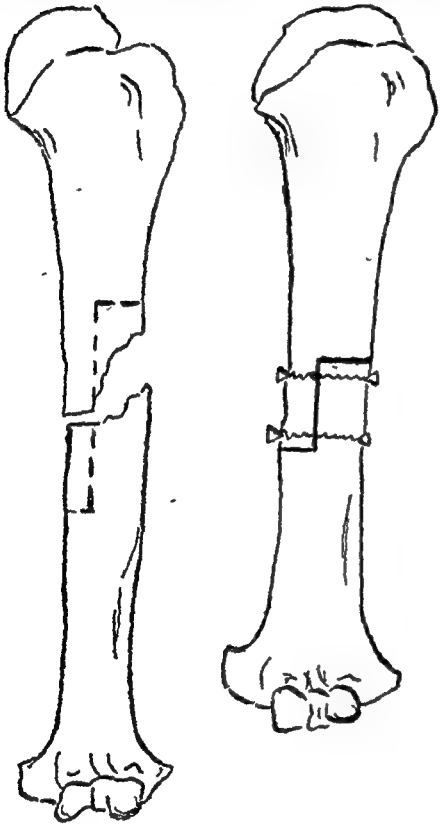

Fig. 383 —Non-union of Diaphysial Fractures

The stepping operation frequently carried out in the humerus

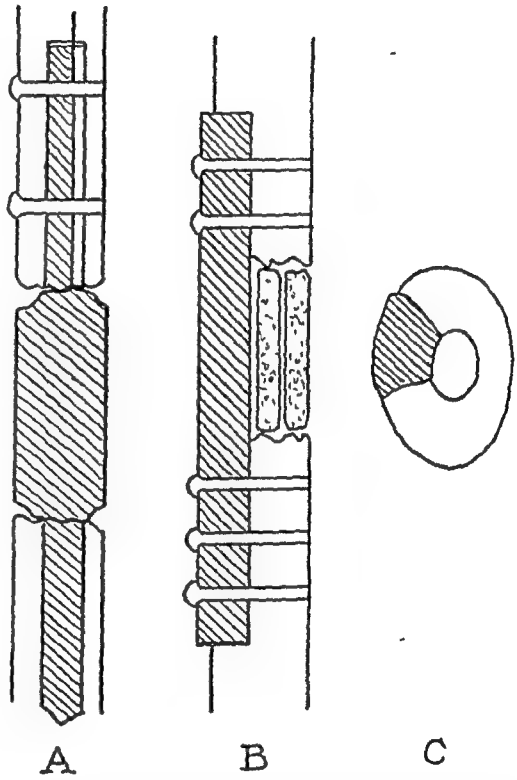

Fig. 384 —Non-union of Diaphysial Fractures.

Bone-grafting operation carried out where it is necessary to preserve length in a bone (after Hey Groves)

a substitute for fresh autogenous bone. Such banks provide a reserve which makes it unnecessary to cut grafts from normal bone, particularly in cases requiring a lot of bone graft material.

The Fate of the Autogenous Graft. When an autogenous graft is implanted between the ends of an un-united fracture, it does not survive: all bone spaces are empty and the trabecula of bone, whether compact or cancellous, must be replaced. Cells on the surface may survive; the subperiosteal cells, endosteal cells, and the cells of the marrow cavity proliferate: within a few days of transplantation osteoclastic activity is observed on one side of every dead trabeculum, while at the same time new bone is laid down by osteoblasts on the

following a compound fracture it is a wise procedure to perform the operation in two stages.

During the first stage, the wound scar is excised down to the bone in order to eradicate tissue which is possibly infective and to ensure that the bone-ends will be ensheathed by healthy vascular tissue. At the same time, also, the bone-ends may be prepared for the second operation by excising the fibrous tissue which covers them. If satisfactory closure of the wound cannot be obtained after excision of the scar, an ample pedicle graft may be taken from the opposite leg to make good the deficiency.

The major procedure—the fixation of the fragments—may be undertaken by any of the methods enumerated below, but it should not be contemplated until at least one month has elapsed since the preliminary operation

The methods of uniting the fragments vary in character and complexity according to the circumstances of the case. The following procedures are available.

(*a*) **Drilling the Fragments.** There is a type of non-union in which the fragments are apparently in good apposition and in which there is no interposition of soft tissue, but where the radiograph shows that there is marked sclerosis and avascularity of the bone-ends. In such a case, union may be obtained by the very simple procedure of Beck which tends to promote natural callus formation. One or two small incisions are made at varying points round each bone-end, through each of these openings a fine drill, $\frac{1}{8}$ inch in diameter, is introduced, and twenty or thirty holes drilled in the fragments The ends of the bones in consequence become vascularized, and a fresh osteoblastic reaction occurs. After the operation the fracture is immobilized on a splint and treated as a case of delayed union. This operation is a simple one and unattended with risk, while, if unsuccessful, it has at least done no harm, and has not prevented the performance of one of the major operations later.

(*b*) **The Step-up Operation of Sen.** This is regarded as the operation of choice in un-united fracture of the humerus, where shortening of the limb is of less consequence than in the leg. After the scar tissue has been removed, and normal vascular soft tissue exposed in the vicinity of the fracture, each fragment is brought out into the wound and divided longitudinally by a saw for about $\frac{1}{2}$ inch. The saw-cut is brought out on the medial side of one fragment and on the lateral side of the other, so that about $\frac{1}{2}$ inch of bone, consisting of half the diameter, is removed from the opposite sides of each fragment. The fragments are then fitted together, clamped in position and united by two transfixing screws After the operation the arm is put up in a plaster-of-Paris shoulder spica down to and including the wrist. Union may be slow, but is usually complete in from six to eight weeks.

This is the most successful method of treating an un-united fracture, but it has the great disadvantage that it cannot be applied to fractures of the leg, since it is followed by a considerable degree of shortening.

The treatment of an un-united fracture, unlike that of a recent one, is not a mechanical problem. When union fails, the problem passes from the realm of mechanics into those of physiology and biology The success of a bone-grafting operation, therefore, depends not so much upon securing by mechanical means a perfect apposition, as upon producing suitable local circumstances to aid the formation of granulation tissue, and later of callus

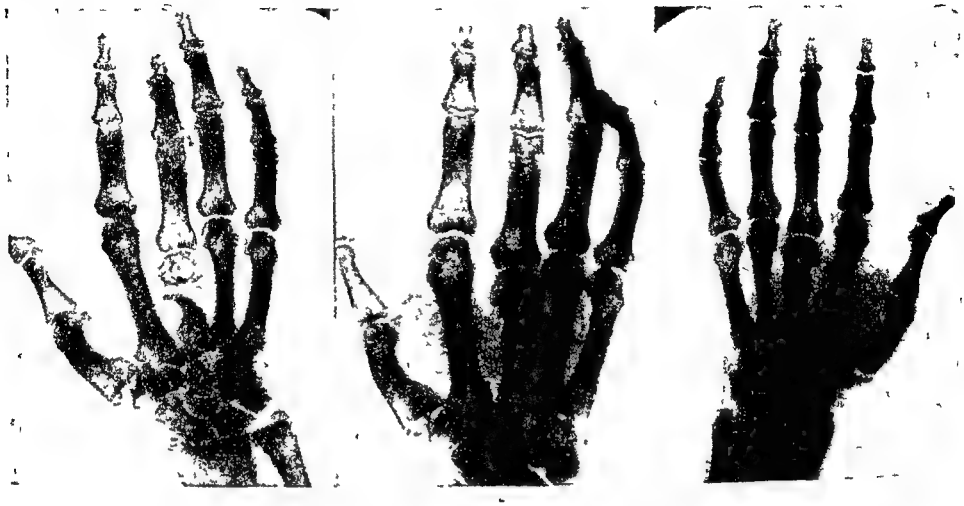

FIG 386 —Gap Fracture of a Metacarpal with Palmar Spur.
Treated by bone graft from the tibia

The Massive Inlay Graft. This is the usual method of the author. The area of fracture is exposed by a generous skin incision, made, whenever possible, through healthy tissue, and access to the fracture should be obtained as far as possible without undue traction on the soft tissues The bone-ends are exposed and freshened with an osteotome, and any anæmic scar tissue is carefully dissected away so that only tissue with a good blood supply will lie in contact with the graft The periosteum is then divided longitudinally on each side of the gap, in order that a gutter may be made for the graft; the periosteal flaps are reflected on either side, and the cortex exposed. Two parallel longitudinal saw-cuts which go through the entire thickness of the cortex and extend for two or three inches from the line of fracture well into non-sclerosed bone, are now made in each fragment, and the rectangular strips of bone so marked out are removed, leaving a gutter. The cuts extend well into non-sclerosed healthy bone. The length of graft required is now obtained by measuring the gutter, and removing a similar length from the anterior surface of the tibia The wound and gutter are packed with hot saline compresses while the graft is cut from the tibia. The graft is made of sufficient length to extend to the end of the gutter and of similar breadth, and has generous contact with the vascular marrow substance and normal bone cortex well on each side of the point of non-union. In this way the

other. When the graft is more trabecular it is quickly replaced by living bone, but where it is more compact replacement is slower.

Some years ago the inlay or onlay grafts were commonly used, serving a double purpose—fixation when it was screwed on to the fragments and osteogenesis by its vitality. It is more usual now to use bone grafts in the form of cancellous chips as with their greater surface area and their trabecular structure their osteogenetic power is greater than the more compact bone of the graft from the tibia. To secure fixation at the same time either an intramedullary nail or a plate with screws may be employed. Watson-Jones says the modern tendency of bone-grafting for un-united fracture is to rely less on accurate

(a) (b) (c)

FIG 385 —Non-union of the Tibia, following a Gun-shot Wound. (a) The gap fracture. (b) A sliding graft has been used to bridge the gap and union has taken place. (c) Three years after the operation.

carpentry with an inlay graft and with screws, and more on the practice of freshening the bone-ends, filling the gap with cancellous chips cut from the ilium and providing fixation by medullary nailing.

It is of the utmost importance that the approximation of the surfaces of the graft and of the host should be as accurate and as wide as possible If the surfaces are poorly apposed, more granulation tissue is required to bridge the gap, and healing is accordingly slow, but if the tissues are brought into close contact the layer of granulation tissue is of microscopical thickness, and healing by first intention results It is equally important to ensure firm fixation of the graft to the host, since slight movements may, in such rigid tissue as bone, tear the delicate granulation tissues or blood-vessels, or even fracture the soft callus.

marrow substance of the graft gets the best chance of being penetrated by the blood-vessels of the host and so of acting as a vessel-conducting agent. The graft is laid in the gutter and retained in accurate apposition and immobilized by four vitallium screws. The site of fracture is covered by the periosteal flaps which were reflected to expose the cortex, obtaining in this way two layers of periosteum to cover the transplanted fragment, and the overlying tissues and skin are closed without drainage. Where no soft tissue can conveniently be used to cover over the graft, e g on the superficial aspect of the tibia, a broad pedicled flap of fascia may be taken from over the adjacent calf muscles, and folded back over the graft.

In some cases it is possible by means of twin saws, which can be varied in their proximity to each other, to cut grafts so accurately that they can be wedged into the gutter and hammered home and so hold the bone fragments firmly while a plaster is applied This accurate wedgement of the graft obviates the necessity of any other fixing material.

If the fracture is towards the end of a long bone it may be possible to obtain a graft from the longer fragment by the sliding method A rectangular graft is then cut from the shaft and slid along into a gutter prepared as above in the smaller fragment.

A useful addition to cases where osteogenesis is doubtful is to apply thin cancellous chips of bone alongside the fracture. The chips are applied round the bone and appear to activate bone growth to a considerable extent. The best site from which to take such chips is the crest of the ilium.

Cancellous Bone-grafting. As ultimately the graft has to be absorbed and replaced, the more quickly this happens the more quickly will fracture union occur. It is obvious that cancellous chips would fulfil this requirement more satisfactorily than compact bone But if they are used immobilization must be achieved by other means—medullary nail or plate—whereas both fixation and osteogenesis are achieved by the inlay graft alone There are fractures, however, where cancellous grafting is the better method, particularly a fracture that was compound and where a flare-up is a possibility. The tendency now is to use cancellous bone wherever it is possible, principally because of the speed of replacement and regeneration.

Usually the sclerosed ends of the two fragments are freshened and all the hard sclerosed bone is removed, until the ends are seen to be bleeding. A medullary nail or a plate is then used and the space of the fracture site packed with cancellous bone from the crest of the ilium The chips are impacted and punched into each other as tightly as possible

The best source of cancellous bone is the ilium and from the crest a thin margin is cut with an osteotome and reflected with the muscles still attached. The outer cortex of the ilium is then removed and a good supply of cancellous bone is available. It is removed with a gouge

Operative Treatment

The operations advocated for un-united fractures of the femoral neck have greatly improved the end results. The surgeon should be thoroughly familiar with all the operative procedures that have been found useful in this condition and should be able to weigh the advantages and the disadvantages of each method and to select that one which will give to his patient the best chance of a reasonably satisfactory functional result

Operation offers a chance of a painless and reasonably stable hip with a fair range of movement. The selection of the proper method is often difficult, but apart from the obvious considerations of the age and physical condition of the patient, the choice will be from one of two groups according to the state of the femoral head. All cases are divided into either.

(1) those with a viable head, or

(2) those where the head has undergone aseptic necrosis or where there is a secondary arthritis

In the first group there is always a possibility of reproducing a more or less normal anatomical state of affairs, either by a graft or nail or both, or by some form of osteotomy, but in the second group the choice is restricted to an arthrodesis, some reconstructive form of surgery, or some form of arthroplasty.

It is not always possible before operation to be sure of the condition of the head, and so the actual decision on the type of operation may have to be deferred until the head is seen at the operation Where viable, the head, after its fractured surface is removed, shows a uniform bleeding area, but the one which is necrotic presents a dense, hard, yellowish-white area of sclerotic bone

A head which is small and atrophic, or one fixed by adhesions, does not give a good result.

The state of the femoral neck is important and the best results are obtained where there has been little absorption of the neck and where there has been little displacement of the fragments.

A summary of the possibilities would therefore be.

(A) Cases with a viable head.

(i) Bone graft,
(ii) Bone graft, plus a Smith-Petersen nail,
(iii) McMurray osteotomy,
(iv) Blade-plate fixation abduction osteotomy,

(B) Cases with aseptic necrosis and/or arthritis.

(i) Modification of a cup arthroplasty;
(ii) Arthrodesis,
(iii) Girdlestone pseudarthrosis,
(iv) Reconstruction of Colonna.
(v) Brittain's arthrodesis.

by the sectional method so as to disturb the area as little as possible. The plaster should not be disturbed until at the end of twelve weeks it is bivalved and removed to enable an X-ray examination to be made. No attempt should be made to test the consolidation clinically until the X-ray is available If union is still not complete, immobilization is continued in the bivalved plaster casing, but the case is removed daily to allow massage, not only over the area of operation, but uniformly over the limb, to stimulate the circulation and callus formation. Free and full use should be forbidden until union is complete Active physiotherapy has to be continued for a long period after the operation since joint stiffness and tendon adhesions are overcome only with difficulty. Radiant heat or diathermy are followed by manual massage, which is of the greatest importance. In most cases in which the graft fractures, or breaks away from its attachment to its host, the fault lies in the careless supervision of the convalescent treatment.

UN-UNITED FRACTURE OF THE NECK OF THE FEMUR

The subcapital fracture of the neck of the femur is, without doubt, one of the most disabling of all fractures when, as is not uncommon, non-union occurs

The Smith-Petersen nailing method appeared likely to solve the problem of this fracture, but apparently the difficulties of accurate closed reduction and accurate insertion of the nail have not been overcome and there is still quite a number of cases that do not unite.

The failure of union may be said to be due to two factors: (1) an insufficient blood supply to the proximal fragment, and (2) incomplete coaptation, or faulty alignment, of the fragments Faulty apposition is undoubtedly the main cause. If a large series of cases showing non-union is studied, in 75 per cent it will be apparent that at no time during treatment was end-to-end apposition of the two fragments obtained If, however, the displacement is accurately reduced, the deficient blood supply will not have any appreciably bad effect upon the union A number of them, however, will develop avascular necrosis of the proximal fragment followed by non-union, or at best delayed union, which may or may not be followed by arthritis; and yet another group will unite without immediate complication but will later develop arthritis. Even if union takes place, however, it is reckoned that 30 per cent. of such cases exhibit the changes of aseptic necrosis of the head of the femur, or arthritis When non-union results the patient is usually unable to bear weight on the limb, and must either wear for life a supporting splint, such as a caliper, or undergo some form of operation. In the old and feeble, conservative treatment may be advisable, in younger cases operative methods are advocated.

A (iii) The McMurray Osteotomy. This operation, which has been described in its use in the treatment of osteo-arthritis of the hip joint, is equally useful in the treatment of non-union of the femoral neck. It is particularly suitable for elderly and debilitated people who are unable to stand extensive procedures. A modification has been described to prevent the displacement of the distal fragment. This may be displaced by the ilio-psoas muscle or its lateral angulation may be lost even in a plaster spica. To prevent these displacements the osteotomy may be fixed by a Blount or Neufeld plate. The operation is carried out under X-ray control and a preliminary guide pin inserted to verify the site of insertion and its angle. The plate, which is bent to produce an angle of 150 degrees on its outer side, is hammered up through the proximal fragment, and screwed to the distal one as shown in the figure.

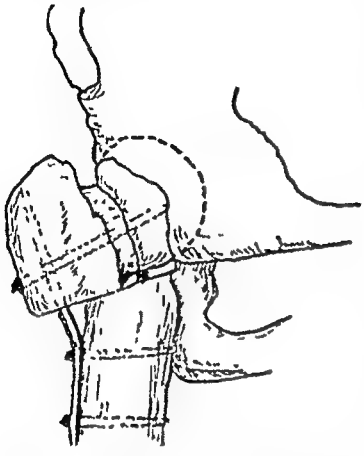

Fig. 389.—McMurray Osteotomy fixed by a modified Blount Plate.

A (iv) Blade-plate Fixation Abduction Osteotomy. The operation of osteotomy for an un-united fracture of the neck of the femur necessitates the application of a plaster case for some months with all its attendant difficulties, particularly the possible stiffness of joints and the direct hardship to the patient Blount, to obviate these disadvantages, recommends fixation of the osteotomized fragments by means of a "Blade-plate." This has the further obvious advantage that it prevents slipping, which is stated to occur even in a properly applied hip spica. The more commonly used type of appliance is a combination of a Smith-Petersen nail with a vitallium plate down along the upper end of the shaft of the femur These are fixed together by means of a large screw. The nail is inserted over a guide-pin up into the neck of the femur in the first place and the osteotomy carried out at the requisite place, usually more or less in the same level and direction as a McMurray osteotomy. The shaft is then displaced medially under the fracture and a plate angled to the proper degree is fixed on the shaft and screwed on to the nail Blount states that the principal advantages of this method of internal fixation of femoral osteotomies are that there is no necessity for a plaster case,

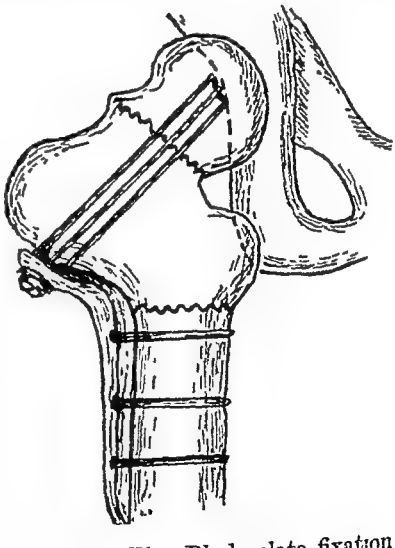

Fig 390.—The Blade-plate fixation Osteotomy of Blount.

A (i) The Bone Graft Operation. The hip joint is exposed by a Smith-Petersen incision. The neck of the femur is inspected. The fractured surfaces may be exposed by lateral rotation of the limb and freshened by removal of the sclerosed bone and fibrous tissue. The position of the limb is then corrected, and sufficient abduction and traction applied to bring the freshened ends into close apposition. A hole is drilled from the trochanter, through the neck, into the capital fragment. A graft is then taken from the fibula and roughly filed into a circular shape, inserted through the tunnel in the neck, and driven home with a bone mallet With the handle held against the great trochanter close to the peg graft, the head of a wooden mallet is now struck with the palm of the hand or with a sandbag In this way close approximation of the fragments is secured. Osteogenesis is improved by laying alongside the fracture some slivers of bone from the iliac crest.

A (ii) Combined Graft and Nail Method. This combination was described in 1939 by Dickson and later a convincing paper was published by James Patrick on a series of cases—mostly recent fractures but some non-union cases up to six months old. Where there is much displacement it is necessary to reduce the fracture after exposing it by the original Smith-Petersen exposure, but it is preferable where possible to do the operation by the so-called "blind" method.

The nail is inserted by the usual method, over a preliminary guide pin, with X-ray control. Great accuracy is required and this can be achieved by the use of a Patrick director. The nail is placed low down in the neck to allow for the placement of the graft above it After the nail is inserted satisfactorily a graft is cut from the lower half of the fibula. The muscular ridges are removed with a bone file until the whole graft can be passed through one of the holes in a gauge which contains three perforations—$\frac{1}{2}$ inch, $\frac{7}{16}$ inch, and $\frac{3}{8}$ inch respectively. The graft is then cut to slightly less than the length of the nail A tunnel is drilled above and parallel to the nail and this direction is more easily achieved by inserting a guide pin through the nail temporarily so that the tunnel may be made parallel to it The graft is then tapped into place and should not be inserted quite as far as the nail. A plaster-of-Paris spica is usually unnecessary but no weight-bearing is allowed for four months Early joint movement and motion on crutches is allowed after the end of a week

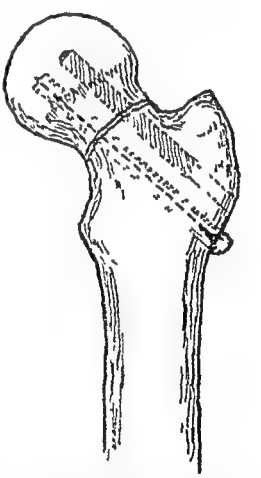

Fig 388.—The Combined Graft and Nail Method.

Patrick points out that early weight-bearing may force the graft into the joint. The living graft fuses more rapidly to the vascular basal fragment than to the head and so tends to pass into the joint. The inert nail, remaining more firmly embedded in the relatively avascular head, tends usually to be extruded.

5–7 lb. are suspended on the leg for some four to six weeks. Exercises are carried out during this period, particularly quadriceps drill but also exercises for the ankle and toe. Sitting in comfortable flexion and lying in maximum comfortable extension for alternating periods every day are ordered. The patient is allowed to sit up out of bed after about five weeks and thereafter starts weight-bearing, first with a "walker," then with crutches and ultimately with a stick.

B (ii) Arthrodesis. Gill pointed out the inadvisability of attempting to secure union of fragments when there has been rapid absorption of the neck after the initial injury, indicating severe injury to the blood supply, where there is gross necrosis of the head, where the neck has been completely absorbed, and where there is evidence of chronic arthritis. In such cases an arthrodesis is performed.

The advantages of this operation lie in the freedom from pain, a stable weight-bearing structure, and a useful extremity. There is no doubt it is not an easy matter to achieve fusion and many would prefer an excision of the head and neck after the manner of Girdlestone. However, by modern methods a high percentage of good results can be achieved.

METHOD Through a Smith-Petersen incision the joint is opened and the articular cartilages removed. In the case of the head, if completely un-united or soft from necrosis it is removed. Chips of cancellous bone are placed in the joint cavity and good co-aptation of the surfaces secured before a long Smith-Petersen nail is driven up the neck and head and into the iliac bone. A small vertical skin incision is made over the trochanter to facilitate the insertion of guide wire and nail An important addition to the operation now is to do a high osteotomy of the femur. This allows the optimum position of the head to remain and the shaft to be placed in the optimum position. The method, too, eliminates stress at the fusion site and promotes more rapid consolidation without causing undue complications. If the osteotomy is made high the broad bone surfaces show little tendency to displace and one is sure of good knee movement eventually The leg is put up in traction either in a Thomas's caliper or by a Russell traction. Consolidation is reasonably quick and in seven to eight weeks the retentive apparatus is removed and knee movement and quadriceps drill already in use are increased in time and extent.

B (iii) Girdlestone Pseudarthrosis. This is a method that may be used in cases of non-union of a fractured neck where the head is dead. It is also of use in cases of arthroplasty—either by cup or acrylic head—that have failed and have resulted in much pain. A false joint is created by excising the head and neck of the femur. This can be done through the usual postero-lateral incision. It is useful in elderly patients whose functional requirements are relatively small and who, in any case, are unsuitable for extensive reconstructive surgery. It gives a comfortable false joint with fair movement but with poor stability and some shortening. The stability can be improved and the shortening mini-

the patient may walk with crutches in less than two weeks, accurate maintenance of any desired angulation is ensured, and untoward angulation prevented, while rotation is accurately controlled. Weight-bearing is permitted when there is radiological evidence of union.

B (i) Modified Cup Arthroplasty. A Smith-Petersen incision is used The incision is from the junction of the middle and anterior thirds of the iliac crest to the anterior superior spine. It then continues downwards and slightly laterally along the medial border of the tensor fasciæ latæ, terminating about 5 inches below the anterior superior spine. The dissection is carried down between the sartorius and the tensor and then between the iliacus muscle medially and the rectus femoris laterally, avoiding at the distal end motor fibres of the femoral nerve. The superior part of the incision is now dissected by clearing the iliac crest of the abdominal muscles, sartorius and Poupart's ligament medially, and the gluteus medius, tensor fasciæ latæ and gluteus minimus laterally, so exposing the anterior third of the iliac crest. The capsule is exposed by dividing the iliac fascia and dividing the rectus femoris muscle and the acetabular origin of the iliacus muscle close to the inferior spine. These are reflected laterally with the Y ligament and the fibrous portion of the capsule The head and neck are exposed to view by removal of the capsule in front of the joint. The view is improved by strong retraction of the iliacus and sartorius medially.

The great trochanter is now osteotomized off the shaft along with its attached muscles The head of the bone is removed from the acetabulum. The upper part of the femur is shaped to fit into the acetabulum and to fit the cup. The acetabulum itself is deepened by special gouges until there is ample room to accommodate a fairly large cup. In some cases a vertical osteotomy of the upper acetabular buttress may be carried out in order to produce by outward displacement of the lateral piece of bone an upper buttress, so preventing a possible dislocation of the cup. The acetabular floor and the end of the femur are now reamed with special reamers and the whole area cleared of bone debris and fragments by syringing and swabbing. The cup is put into the acetabulum and the top of the femur fitted into it. The trochanter is now displaced down the shaft as far as the muscles will allow and fixed there by means of screws. Closure of the wound is aided by removing the projecting anterior part of the iliac crest.

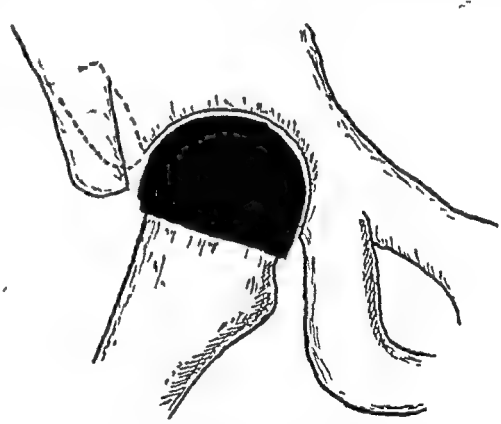

Fig 391 —Modified Cup Arthroplasty of Smith-Petersen.

When the operation wound has been stitched a Thomas's splint is put on the leg, and skin traction applied in a position of abduction.

the two fragments. This is only likely to be successful in fairly recent cases and where there is little sclerosis or necrosis of bone, but in such cases this is the method of choice. When the surgeon has to be content with less severe and less exacting procedures, the displacement osteotomy of McMurray is the best method, where the objective is healing of the non-union together with the osteotomy surfaces and painless adequate joint motion, with a minimum of shortening. This gives a really wonderfully good functional result in that the leg is stable and shortening is avoided. There is, however, some limitation of hip movement. When the head is the seat of an avascular necrosis, with or without a secondary arthritis, it is obvious that neither of the above methods is suitable since a painful joint would be inevitable. In such cases, if the patient is reasonably fit and, especially, not too old, an arthrodesis gives a good result, but where the condition of the patient is doubtful probably a Girdlestone type of operation is the one of choice since it is one of no great magnitude.

MAL-UNION OF FRACTURES OF THE CALCANEUS

Fractures of the calcaneus are amongst the most disabling of all injuries, and the victim never seems to recover completely the movements of inversion and eversion that occur at the talo-calcanean (subtaloid) joint. He does, however, manage to rise on his toes remarkably well, and may walk without a limp, although there is a very noticeable loss of spring when running is attempted. Frequently traumatic flat foot results when the lateral and upward displacement of the posterior part of the calcaneus remains uncorrected. The heel is also often displaced laterally, so that the line of transmission of the body-weight falls over the medial side of the posterior pillar of the arch. The foot is thus forced over into an abducted position and muscular strain is then inevitable. Spurs may form on the under surface of the bone from the extrusion of small fragments from the main body of the bone As in joint injuries elsewhere, improvement is slow, and it may be three or four years before recovery reaches its maximum. Too gloomy a view, therefore, should not be taken of bad immediate functional results.

The ordinary fracture is a compression one and there are usually multiple cracks in the bone It may even be severely comminuted. The bone is broadened laterally, the heel is swollen and tender, and there is a prominence beneath both malleoli In late fractures the patient complains of a considerable amount of pain from secondary arthritis of the talo-calcanean joint.

Treatment

Treatment may be palliative or operative. Conservative treatment which aims at correcting the faulty mechanics of the foot by means of arch supports, wedged heels, etc., is not usually attended with any great degree of success More can be done to improve the condition of these

mized by doing at the same time or subsequently a low osteotomy with a backward angulation at the site (the Batchelor operation). After-treatment in such cases is important and they should be put in traction for some six weeks and thereafter fitted with a tuber-bearing thigh corset and walking caliper. This treatment tends to minimize upward displacement of the trochanter and render the results more stable.

B (iv) The Colonna Reconstruction Method. This is a very similar operation to that of Whitman, differing only in that the abductor muscles are freed from the great trochanter without division of bone. No portion of the underlying bone is removed Indeed, great care is taken to leave the upper extremity of the femur covered by a thin layer of muscle and fibrous tissue The head and attached neck are now removed from the acetabulum. After the trochanter is freed of all its muscle attachments it can be easily pulled down and placed deeply within the acetabulum. The abductor muscles are then pulled down. A bony trough is made on the lateral aspect of the femur as far down as the abductor muscles will reach when the limb is in about 30 degrees of abduction. Two small drill holes are made through the shaft in an antero-posterior plane, the muscles drawn down to this position and held in place by kangaroo tendon, and the cortical covering of the trough sutured over the mass. The vastus lateralis is then carefully sutured over the new insertion of the gluteus medius and the gluteus minimus.

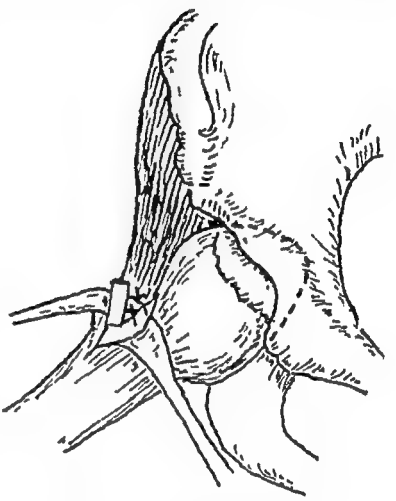

Fig 392.—The Colonna Reconstruction Method.

This operation is said to be advantageous in that a greater degree of motion is got after the operation and that there is practically no loss in length. The only criticism, however, is that the trochanter may subluxate after the extremity is adducted to be parallel to the opposite one.

B (v) Brittain's Arthrodesis. This is a reasonable and successful way of producing an arthrodesis without interfering with the actual joint It is particularly useful where there is much sclerosis of the joint from previous procedures. The author has used it successfully in cases of attempted arthrodesis by other methods that have failed (*vide* p 361).

Summary. The choice of method in the treatment of an un-united fracture of the neck of the femur must depend to a great extent upon the age and well-being of the patient, as well as on the local condition of the fracture area The ideal to be striven for is the restoration of the normal relations in and about the joint In cases where the head is viable the best means of achieving this is by an autogenous peg graft inserted into

including the peroneal tendons, the periosteum and acortical layer of bone be now stripped up and laid forward and upwards. All the excess bone and callus found here is now cleared away leaving a saucer-like crater of bone The talo-calcanean joint is identified slightly above the tip of the malleolus and the remainder of the cartilaginous surface of the joint is removed. If there is outward deviation of the calcaneus the removal of bone is done so that when the apposing surfaces of the talus and calcaneus are fitted together the deviation will be corrected. Where badly comminuted it is better to do a modified Naughton Dunn arthrodesis. If the comminution affects only the subtaloid joint, this should be arthrodesed much in the same way that the author advises for arthrodesis of the ankle joint (p 938). Gallie arthrodeses the subtaloid joint by a bone block, believing that the slight valgus deformity may be disregarded. With the patient on his face the joint is approached by a longitudinal incision along the lateral border of the tendo-Achillis for 3 inches. The joint is located by sideways movement of the calcaneus and a mortise is cut in the two bones, $\frac{1}{2}$ inch wide and $\frac{1}{4}$ inch deep and going as far forward as the transverse sinus. A graft is cut from the tibia and divided into two, and with the cortical surfaces together they are driven into the mortise If the grafts are of the proper dimensions their cancellous surfaces will press snugly against the lateral walls of the mortise Pridie has recently reported good results in cases of considerable comminution by complete excision of the bone as a primary procedure. The hæmatoma that produces plantar ischæmia is removed at the same time with great benefit.

MAL-UNION OF A POTT'S FRACTURE

The term "Pott's Fracture" is employed to describe most of the fracture-dislocations of the ankle. These injuries are particularly liable to lead later to disturbances of the joint mechanics.

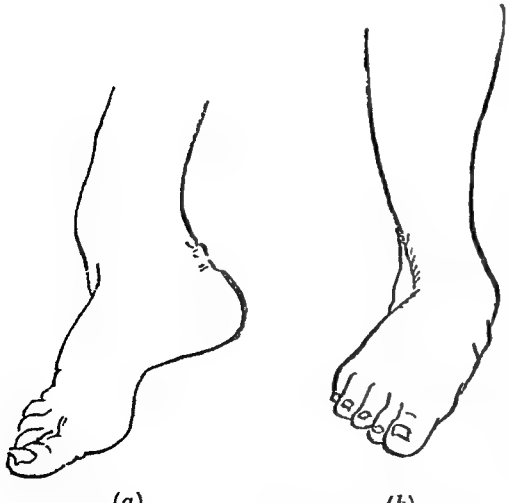

Fig 394.—Mal-union of a Pott's Fracture.
(a) Backward displacement
(b) Lateral displacement

Unreduced fractures at the ankle are commonly accompanied by severe disability of the joint The foot is fixed in a marked valgus attitude and there is often a backward dislocation of the ankle joint. The medial malleolus is prominent and the tendo-calcaneus contracted. Pain is severe and continuous, and eventually the foot may be rendered quite useless.

Radiological investigation will demonstrate that the line of

patients by producing a sub-taloid arthrodesis. Indeed this operation is used by some surgeons as a primary method of treatment. In late cases there are certain procedures additional to an ordinary talo-calcanean arthrodesis that make for a better result.

Fig 393 —Old Un-reduced Fracture of the Calcaneus.

The Operation. The technique of the procedure is as follows · After a tourniquet has been applied to the limb a curved incision is made along the medial surface of the calcaneus beginning immediately posterior to the medial malleolus and extending round the tip anteriorly and slightly upwards to the navicular bone. Care must be taken not to injure the important structures running under the malleolus into the foot. Dissection is carried on through the soft tissues and the sub-taloid joint is exposed. The cartilage of the posterior articulation of the talus and calcaneus is removed with a thin osteotome. In order that a complete arthrodesis may result another incision is made on the lateral side extending from a point immediately posterior to the tip of the lateral malleolus then under the tip and slightly upwards to a point immediately dorsal to the calcaneo-cuboid joint. As on the inner side the dissection is carried on to the bone, carefully avoiding injury to the peroneal tendons. Cotton advises that a flap

(i) Reproduction of Fracture and Reduction. In the typical Pott's fracture with eversion of the foot and a fracture of both malleoli, an osteotomy of both malleoli allows full correction to be made with considerable hope of good function.

Where the lower end of the tibia has been broken and displaced outwards, as well as the lower end of the fibula, a double osteotomy in the line of the fracture may solve the problem.

The difficult type of tri-malleolar fracture where the posterior surface of the tibia is broken off and the astragalus, fibula and posterior tibial fragment displaced upward, may in recent cases be treated by lengthening the tendo-Achillis, pulling the foot downwards and forwards and nailing the tibial fragment in position But in old cases it is better to fuse the ankle joint.

(ii) Osteotomy and Correction of the Malalignment.

This may be carried out where the talo-tibial relationship is normal The deformity is usually an eversion one. An oblique osteotomy of the fibula is carried out and the bone elongated. A small wedge is removed when the tibial side is divided and this wedge used to fill up the gap in the fibula. Good correction may be achieved by a wrench and the position is maintained in plaster. A similar operation is depicted in Fig. 395 for an inversion fracture.

(iii) Arthrodesis of the Ankle Joint. The author uses a bone-block method. A vertical incision is made over the lower end of the

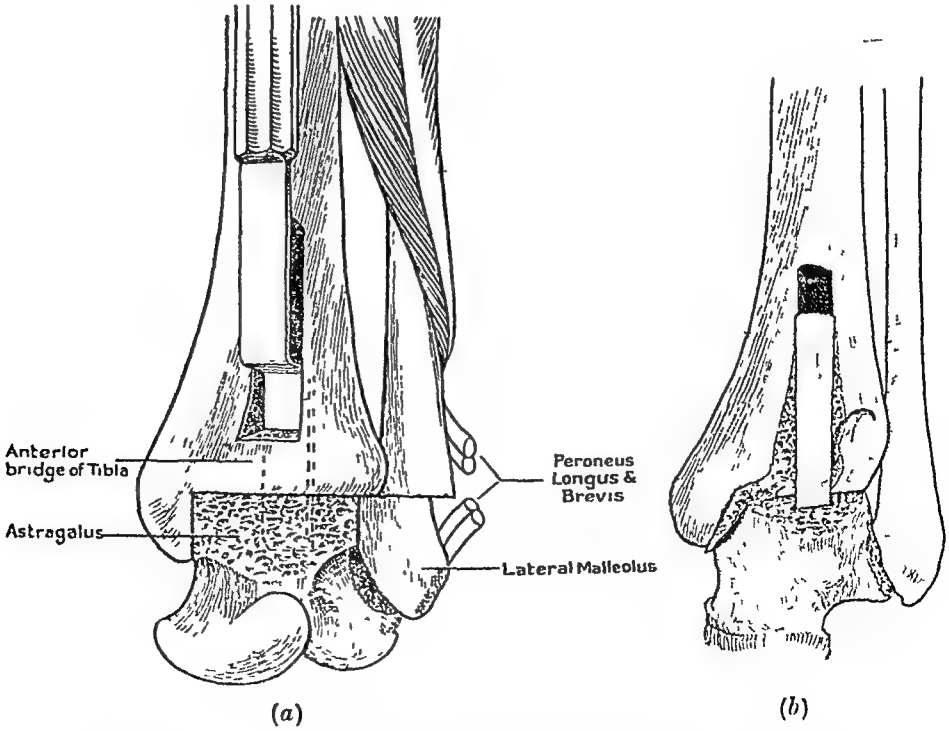

FIG. 396 —Arthrodesis of the Ankle.

(a) Brittain's method (b) Watson-Jones's method.

articulation between the tibia and the talus slopes obliquely downwards and medially, instead of being horizontal

If a backward displacement of the talus has been present for three months, changes have occurred in the joint to such an extent that a painless functioning joint is out of the question. If arthritis has occurred, simple replacement is not sufficient since pain, swelling and limitation of movement would persist. A strong, stable, painless ankle, without motion, is preferable to such a joint. The usual procedure is therefore a fusion rather than a reconstruction, but the choice of treatment will be from—

(1) Conservative supporting treatment;
(2) Reproduction of the original fracture and reduction;
(3) Osteotomy and correction of malalignment;
(4) Arthrodesis of the ankle.

1. Conservative Treatment.

If the displacement is slight, and particularly in older people, a simple leather arch support with an ankle corset may relieve the pain and provide enough support to enable them to walk.

2. Operative Treatment.

The disability from mal-united fractures of the ankle is usually so extreme that only surgical measures will afford relief.

Trethowen believes that the decision rests on the age of the fracture; the age, occupation, and general condition of the patient; and the extent to which weight has been transmitted through the deformed ankle If, for example, there is a considerable amount of traumatic arthritis, a reconstruction is less likely to succeed than an arthrodesis Again, reconstruction is usually not undertaken after an interval of six months from the date of the fracture

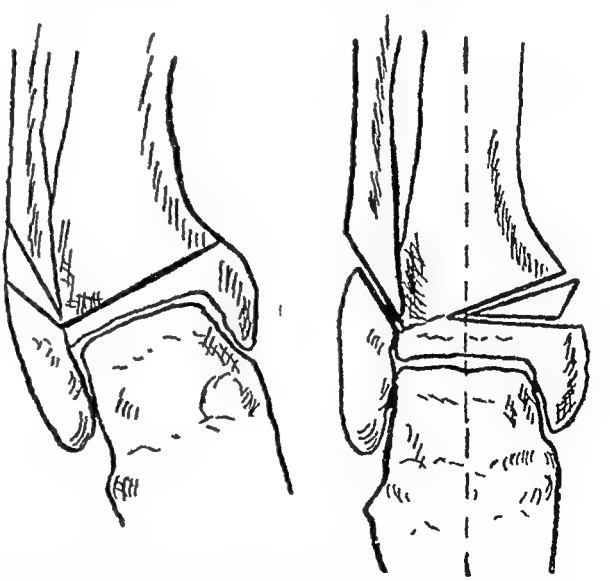

Fig 395.—Mal-union after Pott's Fracture.—Osteotomy and correction.

The aim in performing a reconstruction is to secure freedom from pain and a fair degree of ankle movement. If this cannot be guaranteed, it is better to arthrodese the joint and ensure a painless ankylosis. A final decision as to the choice of operation may be possible only after the joint is exposed at operation.

The different ways of dealing with unequal leg lengths are classified by Wilson and Thomson as:

I. Changing the rate of growth.
  (i) Stimulating the growth of the short leg:
    (a) Local stimulation of bone growth.
    (b) Lumbar sympathectomy.
  (ii) Retardation of growth in the longer leg:
    (a) Epiphyseal arrest—(i) temporary.
      (ii) permanent.

II. Surgical reconstruction.
  (i) Bone lengthening of the short leg.
  (ii) Bone shortening of the longer leg

Local stimulation of the epiphyses has been found to occur in many pathological conditions—congenital hemi-hypertrophy, arteriovenous aneurism, some infective conditions, notably tuberculosis of the knee, some tumours, as neurofibromatosis, and following trauma.

Extensive periosteal stripping has been carried out experimentally to produce extra length, with an increase in the growth rate of 5–15 per cent No local method, however, has been found to be useful in extent or practical owing to the great difficulty in producing an increased blood supply over a long period.

Lumbar sympathectomy produces an increased blood supply better than any local procedure yet devised, but even with this method the increase in length is rarely over an inch. The operation produces a prolonged hyperæmia and is well worth while for the relief of chilblains and pain associated with the poor circulation in poliomyelitis, but the increase in growth is too little and too inconstant for it to be recommended as a method of increasing leg length, though it may be of use in the young in preventing a further increase in discrepancy.

Retardation of growth in the longer extremity.

Phemister was the first to suggest the limitation of longitudinal bone growth by surgical means. He described a simple procedure which consists of removing small bone grafts, about 1 to 2 cm in breadth and 4 cm. in length, from each side of the lower end of the femur or the upper end of the tibia. These are taken largely from the diaphysis, but extend just across the epiphyseal line The epiphyseal cartilage plate is exposed by this removal and a large area of it curetted The curetted area is cauterized sometimes with a diathermic cautery The grafts are turned end for end and re-inserted across the epiphyseal line Several grafts are used from the lateral and medial aspects of the distal end of the femur and the proximal end of the tibia and fibula

More difficult than the actual technical procedure is the decision as to when the operation should be performed and which epiphysis should be fused. A simple method of calculation, sufficiently accurate in the face of the many variable factors associated with bone growth, is suggested by White and Stubbin, and recently by Anderson and Green

fibula extending from below the malleolus upwards for 5 to 6 inches The fibula is divided in an oblique direction upwards and inwards about 3 inches above the malleolus and the lower fragment levered outwards and downward, so exposing the joint. If there is any displacement of the internal malleolus, it is divided at the level of the ankle joint and any lateral displacement of the talus corrected A block of bone about 1 to 1½ inches in all directions is now cut with an osteotome on the fibular side from the lower margin of the tibia and the upper margin of the talus This may be used entire or divided into small pieces. If the former, it is turned round 90°, replaced in the gap after the position of the ankle joint is corrected, and punched home. When small chips are used they likewise are punched well home. The fibula is replaced and the obliquity of the osteotomy retains it in position. A stable ankle joint is easily achieved after three months immobilization in plaster of Paris.

Since torsional movement of the foot may occur in the plaster, Watson-Jones fixes the joint with a bone-graft He cuts a graft from the lower end of the anterior aspect of the tibia, turns it upside down and drives it into a socket in the astragalus The graft is firmly wedged to the tibia by crushing bone in on either side of it. Brittain suggested a similar operation but removed his graft from the tibia at a higher level leaving an anterior bridge of bone so that the graft as it traverses the ankle joint is totally enclosed He used a special angled osteotome to cut the bed into the astragalus

THE PROBLEM OF THE SHORT LEG

Several operative measures have been instituted to equalize the length of the lower limbs when these are unequal Such a procedure is of value where deformity or disease of the pelvis or limb bones has led to unilateral shortening. In addition, it is of great value in cases of infantile paralysis associated with shortening, where the patient has recovered a degree of muscular power which should enable him to walk were the leg not overtaxed by the heavy appliance necessary to compensate for the defect in the length.

Inequality of leg length is always a crippling affection The disability is directly proportional to the amount of difference in the two limbs A discrepancy of 1 inch can generally be compensated for by tilting the pelvis, but when the difference is greater a raising in the shoe is necessary to prevent undue curvature of the spine and its consequent symptoms of strain and fatigue. A raising under the shoe is satisfactory up to 3 inches but over this a metal patten must be used and in extreme cases a modification of a light metal artificial limb may be necessary.

Many methods have been devised for equalizing the lengths of the lower extremities, but many have been discarded as of little more than theoretical value, or because of the frequency of complications

2. Deformities of the knee—flexion contracture, etc
3. Malunion and non-union of the fragments.
4. Stiff joints.
5. Weakening of leg muscles.
6 Nerve complications.
7. Disturbance of circulation—chronic swelling.
8. Infection.
9. Aseptic necrosis of bone.

It is not surprising that the risks as well as the magnitude of this operation have been emphasized and, as a consequence, that it must never be undertaken lightly. Abbott has stressed the importance of the application of certain fundamental principles in order to lengthen the bone which are:

1. Traction must be made directly on the bone itself;
2. In order to overcome the elastic resistance of the soft parts the traction must be slow and continuous in type;
3. To avoid harmful pressure on these soft parts the alignment and contact of the fragments must be maintained during the lengthening process.

An important cause of malalignment is the resistance of the fibrous structures, particularly those attached to the fibula. At present, therefore, increasingly radical divisions of the deep fascia, the intermuscular septa, the periosteum, and the interosseous membrane are carried out. The operation is, therefore, one of undoubted magnitude, requiring extensive dissection of the leg, with freeing of the blood vessels and nerves at points of fixation and preservation of the nutrient vessels of the tibia and fibula

Leg lengthening is preferable in those of short stature in whom it is obviously desirable to preserve what height they have It has to be borne in mind, too, that leg shortening is carried out on the normal limb and on this ground may be objected to—and reasonably so—by the patient The indications for and the objections to leg lengthening make it desirable to restrict the procedure to a limited group.

The leg-lengthening operation is carried out below the knee as it is safer here from some of the complications and especially is non-union less likely to occur. Femoral lengthening is more of a problem owing to its deeper situation and stronger muscle attachments, so that control of alignment is more difficult. Because of its magnitude it is carried out in two stages with an interval of five to six days between them Abbott and Saunders describe an operation which, though complicated, is an improvement on former methods.

The Operation. A detailed description is beyond the scope of this text-book, and the reader is referred to the literature for full operative details (See Bibliography.)

First stage The incision follows the biceps tendon to the neck of the fibula, continues to the crest of the tibia, and down to the junction of the middle and lower thirds.

(1956). Regardless of the age and size of the child, these authors calculate that a growth-arrest procedure at the distal femoral epiphysis will retard growth at the rate of $\frac{3}{8}$ inch a year, while at the proximal end of the tibia and fibula it will retard growth $\frac{1}{4}$ inch They assume that growth ceases in boys at 17 and in girls one year earlier. These figures have proved sufficiently accurate in a large number of cases.

Methods have been suggested for arresting epiphyseal growth temporarily by means of the insertion of metal staples across the epiphyseal cartilage. Blount uses staples $\frac{3}{4}$ inch long, and with the cross member $\frac{5}{8}$ inch for the tibia and $\frac{7}{8}$ inch for the femur. These are made of stainless steel of a calibre $\frac{3}{32}$ inch Three staples are inserted on each

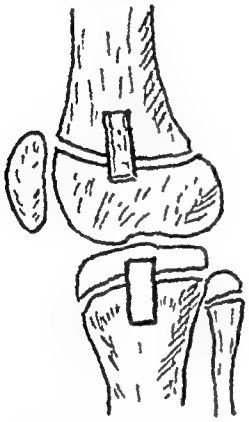

Fig 397 —Retardation of Growth by Phemister's Epiphyseal Graft Method.

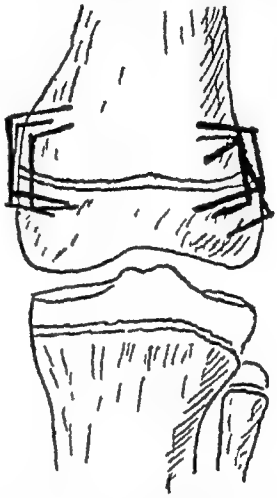

Fig. 398 —Retardation of Growth by Stapling Line drawing from an X-ray.

side of the epiphysis and growth is found to be stopped immediately and almost completely Three staples are applied into the lateral and three on the medial aspect of the selected epiphysis and when sufficient retardation has taken place the staples are removed so that the epiphyseal growth may then continue Location of the staples for removal may require some removal of bone This should not be replaced unless a grafting effect across the epiphysis is produced. Such a procedure may be repeated should the discrepancy persist or be still too much at a later date

Knock-knee can be corrected by this method by the insertion of three to four staples on the medial side.

Neither of the operations to arrest epiphyseal growth is applicable, obviously, when the patient has reached maturity.

The leg-lengthening operation.

Lengthening of the short leg was the first procedure to be attempted, but Abbott and Saunders have noted this formidable list of complications occurring in this method :

1 Deformities of the foot—valgus, etc

extremity by epiphyseal arrest or resection is preferable to lengthening of the leg when:

(1) the discrepancy is less than 3 cm.;

(2) the patient is less than 15 or 16 years of age;

(3) the muscles of the hip or knee are paralysed;

(4) shortening is so marked that maximum lengthening will not equalize the extremities sufficiently to enable the patient to discard lengthening appliances;

(5) there is a history or evidence of bone disease; or

(6) when the abnormality is congenital, as in the absence of part of the bone to be lengthened.

While leg shortening is not always free from complications it is a much simpler undertaking than leg lengthening. At the present stage of development of operations for discrepancy in length of the legs the operation of leg shortening, or epiphyseal arrest, is preferable to leg lengthening.

The Operation. This operation is best carried out at the upper end of the femur in the subtrochanteric area as there is a big area of bone here which tends to ensure union, whereas in the mid-shaft union may not be so absolutely certain The fixation of the two fragments after the removal of the required segment of bone for shortening is carried out by means of a Smith-Petersen pin and a plate joined together, a type of appliance which is now to be obtained in many different forms The technique is essentially that used in the treatment of trochanteric fractures. The upper part of the femur is exposed by a lateral incision, the Smith-Petersen nail is driven through the great trochanter into the neck at the proper angle to make the plate fit along the lateral surface of the shaft, thus maintaining the normal angle between the shaft and the neck. A guide wire is usually used to ensure this. The section of bone to be excised is measured with calipers. A vertical saw cut along the cortex of the bone constitutes a marker to be used in setting the fragments without rotational displacement. A straight acting motor saw is used for cutting the bone. Before the fragments are aligned the plate is attached to the nail. The fragments, having been exposed subperiosteally, are brought into apposition and the saw cuts are matched. Driving the nail is then completed and the plate is attached to the femoral shaft by screws which penetrate both cortices. The last and most important detail is that the connecting screw is tightened forcibly, a large screw-driver being used. Pieces of bone from the resected fragment may be used alongside and around the osteotomy to help in the formation of callus. No external fixation is necessary, the leg being kept comfortable on a pillow between sandbags Some three months are required in bed, followed by walking on crutches and gradually increasing weight-bearing.

THE PROBLEM OF THE STIFF KNEE

Free movement of the knee joint depends on the integrity of the various tissues surrounding it as well as of the joint itself. The com-

The common peroneal nerve and its branches are freed. The deep fascia is incised transversely and the lateral head of gastrocnemius retracted.

The posterior tibial vessels and nerve are freed and the origin of soleus reflected from the fibula The anterior and posterior intermuscular septa are incised. The attachments of peroneus longus, extensor digitorum longus, and tibialis anterior are reflected from the head of the fibula and lateral condyle of the tibia The interosseous membrane and tibialis posterior are also freed from the upper end of the fibula. A long oblique osteotomy is now made through the fibula, downwards and laterally, and a similar one through the antero-lateral cortex of the tibia downwards and medially.

Second stage—(five to six days later) A lengthening apparatus with transfixion pins is applied, and an incision made over the postero-medial aspect of the calf. The deep fascia is incised in the length of the wound and also transversely.

The tendon of gastrocnemius is freed from the tendon of soleus, sectioned obliquely, and then implanted into soleus at a higher level. The origin of soleus is then detached. The insertion of popliteus is reflected upwards and the origin of tibialis posterior and the attachment of the interosseous membrane freed for a distance of $1\frac{1}{2}$ inches.

An oblique osteotomy is then made through the posterior cortex of the tibia, completing the osteotomy begun in the first stage.

The extension apparatus is then adjusted to secure separation of the fragments. The wound is closed.

Abbott and Saunders have shown that $\frac{1}{16}$ inch of length per day can be gained with little discomfort to the patient This has been increased up to $\frac{1}{8}$ inch and they have gained as much as $1\frac{1}{2}$ inches in twenty days, but such rapidity is not generally advised. When the required amount of lengthening is obtained a plaster case is applied until union of the fragments is firm.

Bost and Larsen have reported good results in operating on the femur using an intramedullary nail to maintain alignment They found an undesirable frequency of delayed union and in one case an arterial spasm. The maximum correction achieved in their patients with limb-length inequality was $8\frac{1}{4}$ inches This was achieved by three operations At the first they removed $1\frac{1}{2}$ inches from the long leg and inserted this segment in the osteotomized short leg and then inserted the medullary nail. They did their osteotomies transversely, obliquely, or by a step cut, and primary union occurred as readily after a transverse osteotomy as in the other two methods The more the bone is lengthened the longer is the time for union No doubt this complication would be avoided if the fractured area was surrounded by cancellous bone chips.

Shortening of the longer leg.

Compere and many others believe that shortening of the normal

Treatment

(1) *Manipulation.*

Adhesions may be broken down and an increased movement achieved in certain well-chosen cases. Smillie has stated that manipulation is contra-indicated in the presence of any pathological process indicated by a "hot joint," in the early stages of recovery, in the presence of any decalcification of the adjacent bones and in the presence of unsound union at the fracture site. If the patella is relatively mobile, there is no fibrosis in the supra-patellar region and the resistance is elastic, manipulation may be successful. Apart from reaction and failure, a fracture of the patella is to be feared. It should be protected by an assistant while the forced manipulation is being carried out Following the manipulation supervised active exercises are carried out persistently and with vigour and determination from the earliest possible moment Many cases fail to improve with manipulation for apart from the local difficulties the patient may not have the will to get better or may lack the moral and physical courage to bear the discomfort and sometimes pain of the after-treatment. An alternative in such cases and in cases where manipulation is contra-indicated is some form of operation—two have been used fairly extensively.

(2) *Quadricepsplasty* (Thomson).

This is particularly useful following fractures of the femur or extensive wounds with much scarring of the quadriceps mechanism. Thomson advises excision of all the scar tissue.

The area is usually exposed by a lateral incision, though this may vary with the site of the scarring. It extends from below the patella to the upper third of the thigh The rectus is isolated and separated from the vasti lateralis and medialis. The anterior knee capsule is then divided transversely on both sides of the patella for a distance sufficient to overcome the capsular shortening The vastus intermedius, which is usually a scarred band fixing the patella and rectus to the femur and obliterating the supra-patellar pouch, is excised completely, leaving a fibrous and periosteal covering on the anterior surface of the femur. The knee is now slowly flexed to 70 degrees, releasing the remaining intra-articular adhesions. If the vasti are badly scarred they are isolated from the rectus by suture of the subcutaneous tissue and fat to the anterior surface of the femur, thus creating an artificial intermuscular septum and eliminating all scarred muscle from the remaining quadriceps mechanism If the vasti are relatively normal they are re-united to the rectus as far distally as the lower third of the thigh. After operation the leg is placed in a Thomas's splint with skin traction to a flexed knee for three to four weeks Active exercises are begun immediately.

(3) *Bennett's operation*

Bennett has described an operation which aims at freeing and elongating the tendon He believes that it is better to operate on a patient

monest factor interfering with this integrity is the presence of adhesions. Smillie has pointed out that these may occur within the synovial cavity, especially in the supra-patellar pouch, in the capsular and peri-articular tissue, in the quadriceps, and in the fascia lata. Limitation of knee flexion is most commonly found after fractures in the vicinity of the knee and particularly of the shaft of the femur, after infections in or about the knee joint, and following certain operations where the knee is kept extended for long periods and in operations which have been badly planned

Most of these produce stiffness for obvious reasons When a fracture is slow in uniting, possibly because of the treatment, the knee is very likely to be stiff afterwards. The prevention is to secure union as quickly as possible In cases necessitating exposure of the shaft of the femur an anatomical approach without doing much division of muscles or dividing many vessels is important If possible it should go between muscles as for example that used in the postero-lateral approach

The complication following a fracture of the femur may result from the fragments entering the knee joint but also from injudicious treatment. Prolonged skeletal traction, especially if the traction pin is through the lower end of the femur, and especially if the knee is fixed for too long, that is over seven to eight weeks, almost certainly results in difficulty in knee movements.

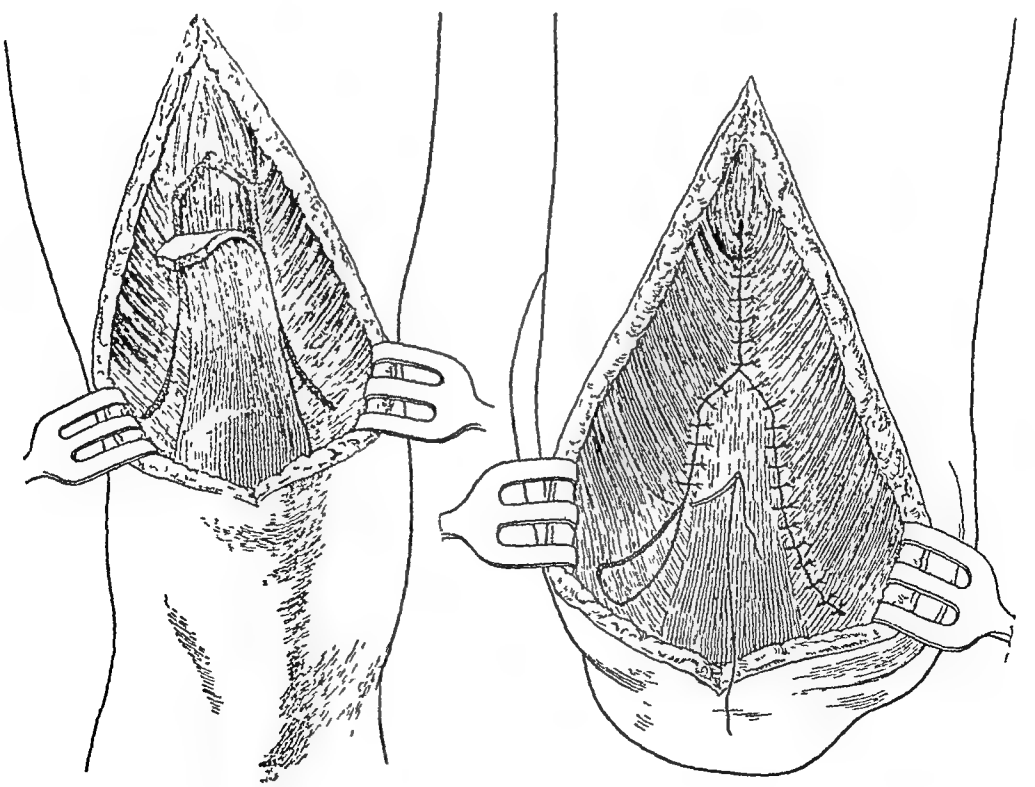

Fig 309.—Bennett's Operation of Lengthening of the Quadriceps Tendon for Stiff Knee.

cases resulting from trauma and from neglect are more amenable to treatment.

In some cases correction may be obtained by conservative measures either by continuous traction or by a wedge plaster case. In both cases the danger of a traction paralysis of the external popliteal nerve must be kept in mind

Where conservative measures fail certain operations have been used with success.

1. Posterior Capsulotomy. A straight incision down the popliteal fossa is likely to produce a keloid scar with contraction, and so it is better to approach the area through two lateral incisions These are about 5 inches in length from just above the condyles to 2–3 inches below the joint line On the outer side the ilio-tibial band is divided transversely and the peroneal nerve isolated. The biceps tendon is lengthened in a Z-manner. The lateral condyle is now identified and capsule incised and stripped upward from the posterior aspect of the femur, and separating the outer head of the gastrocnemius. This stripping is carried up to about 3 inches above the joint and inwards to the middle of the femur.

A medial incision is now made above the adductor tubercle to 2 inches below the joint line A similar stripping is carried out on this side. It is helpful to pass a copper retractor from side to side and so get a good view of the posterior aspect of the joint With the knee in acute flexion and the posterior structures retracted, the light capsular structures in the region of the intercondylar notch, and the attachment of the inner head of the gastrocnemius are freed, divided, or lengthened, according to requirements.

Manipulation should now produce a fairly straight knee. If the peroneal nerve appears stretched now it is dissected freely above and below. This reduces the tautness considerably.

After-treatment. A most careful watch is kept on the circulation of the toes throughout the post-operative period. If, on straightening out the knee, the circulation appears adequate, a plaster-of-Paris case is applied with the knee in the fully extended position. This remains on for two to three weeks and then a posterior gutter splint is used and physiotherapy started A jointed walking caliper is fitted and used from the end of the second month and retained until the patient has muscular control of flexion and extension, but for six months a posterior gutter splint is used at night

2. Osteotomy. Where there is free movement of the knee from say a position of 30 degrees of flexion up to 100 degrees a wedge osteotomy at the supracondylar level may be carried out A wedge of bone with its base anteriorly is removed so that the 70 degrees of movement is now from the straight position to 70 degrees flexion This is only done in the absence of any activity of disease in the knee joint An internal fixation by a plate allows post-operative movement of the knee.

who has walked for five years with 10 degrees of flexion, than on one who has walked for only five months, although there may be 30 degrees of flexion. In the former, the joint and muscle tissues are in good tone and therefore lend themselves better to operation, and begin to function more rapidly. It is inadvisable to operate in cases where the joint is sensitive to pressure.

Technique of the Operation. The patient lies with the knee flexed as much as possible over the end of the operating-table, in order to allow of free manipulation after the tendon has been released. A straight incision is made over the tendon, and the skin flaps reflected to expose the attachment of the rectus and the capsule of the knee joint The tendinous portion of the muscle is freed from the muscular part by linear incisions along each side, extending from the attachment of the belly of the rectus femoris to the patella. The incisions follow closely the margin of the tendon and diverge at the upper border of the patella, to leave the strong attachment of the tendon at this point undisturbed. These incisions must be sufficiently deep to include the tendinous portion of the vastus intermedius as well. The upper ends are then connected by a short transverse incision and the entire tendon is dissected downwards to the patella off the underlying structures. The knee is then carefully flexed, to at least 90 degrees, any adherent parts of the capsule or about the lateral margin of the knee being severed. The leg is then brought back to 80 degrees of flexion, and the tendon sutured on either side to its muscles by means of kangaroo tendon or strong chromic catgut. If adhesions are present between the vasti and the lower part of the femur, the muscles should be dissected off the femur, to permit of their being drawn in towards the middle line for suture to the tendon. When the tendon has been thus anchored to vasti at each side, a space is still left above at the lower end of the rectus. This is closed by a catgut suture, still further approximating the vasti The knee is then put up in a position of 80 degrees flexion in plaster of Paris for a period of three weeks At the end of this period, passive extension of the knee is begun during the day, and the knee replaced in its flexed position on a splint at night. At the end of the fourth week active contraction of the muscles is encouraged. The leg should not be completely flexed at too early a date, as the tendon may then rupture from its muscular attachment The power of extending the leg is slow to return, especially in its last few degrees . in some cases it may not return for a year. Weight-bearing on the leg without suitable protection is not allowed for at least three months from the date of operation.

Flexion Contracture of the Knee

This is a common sequel of long continued over-action of the hamstring tendon It is seen at its worst in a neglected tuberculous knee joint or in rheumatoid arthritis where, in addition to the contracture, a posterior and rotatory dislocation often takes place The non-infective

Watson-Jones points out that the following factors, several of which may occur in the same case, are considered responsible for continued or recurrent exudation: (1) disuse with continued venous stasis; (2) recurrent œdema; (3) the recurrent trauma of daily passive stretching or repeated manipulation, (4) the constant trauma of immobilization in a position of strain; (5) continued infection near a joint, and (6) the continued irritation of foreign bodies near a joint

Immobilization in itself is not a major factor in the development of adhesions when uncomplicated by other factors. Any adhesions formed are the result of venous stasis Once a patient resumes active use of the part, recovery of normal function occurs

Watson-Jones emphasizes the serious disability that follows the presence of continued œdema in a limb which is immobilized. "There is no more potent factor in adhesion formation, for œdema is the glue of which adhesions are made." Swelling is controlled by external pressure and active muscle exercise. He particularly denounces passive stretching and exercise, since such therapy results in a continual recurrent traumatic exudation, with the formation of fresh adhesions.

Extra-articular adhesions which may be connected with the capsule, the ligaments, or the muscles, are the result of old organized blood-clots or effusions following trauma; they are just as liable to produce limitation of movement as are intra-articular adhesions, and in time are followed by adaptive shortening of the muscles and other soft structures.

Intra-articular adhesions may be caused by synovitis, or arthritis, but those usually treated by manipulative surgery are the result of trauma which produces a sprain of a joint This sprain occurs when the muscles are taken unawares and the joint is forced to the extreme limit of its normal movement, or a little beyond, so that the force, continuing, stretches the ligaments, it is actually a rupture of ligaments, usually in a minor degree, a few fibres being separated or torn, with, as a result, slight hæmorrhage and exudation of fluid. This is followed either by complete resolution and return to normal, or by the formation of new fibrous tissue and scarring at the site of the injury When the acute process has subsided it may be found that part of the ligament has become thickened and contracted, so that a movement which puts it on the stretch is restricted; such a condition is commonly spoken of as "adhesions"

Diagnosis of Adhesions

The diagnosis of traumatic adhesions is of considerable importance, and in particular they have to be differentiated from the presence of arthritis The differences between the two conditions can be set out most suitably in a tabular form (see next page)

The difference in the limitation of movement is one of the most important points in the differential diagnosis, and provides a safe and practical rule for treatment by manipulative surgery, but it must be

CHAPTER XVIII

MANIPULATIVE SURGERY

This is a branch of surgery which has been undeservedly neglected by our profession, and it has in consequence fallen largely into the hands of unqualified practitioners; that it should have done so is a real misfortune, as manipulation, properly carried out on suitable cases, can be a most valuable therapeutic agent. Manipulative surgery aims at restoring movement to a joint whose range of movement is limited, and at abolishing the pain which is so frequently present in a stiff joint. In order to restore normal movement, or even merely to increase the range of movement of a damaged joint, some abnormal resistance to movement must be overcome by the use of a certain amount of force during the manipulation; and the degree of force necessary will be reduced to a minimum if the muscles are first relaxed by an anæsthetic.

Manipulation can be effective in relieving pain caused by replaceable displacements and by fibrous adhesions in and around a joint, or attached to a normally mobile structure. Richardson says that unless one of those conditions exists and can be diagnosed, and unless it can be ensured that manipulation will have the desired effect without producing harmful results, it is not indicated.

The impaired function which is so obvious in most cases requiring manipulation may be caused not only by a lesion in the joint itself, but also by some condition either of the soft tissues in the vicinity of the joint, or of the muscles which activate it; all these lesions can often be effectively treated by putting the joint through its normal range of movement, and it is seldom necessary to exceed the normal range.

ADHESIONS

The common cause of stiffness of a joint is the presence of adhesions which may be both in the joint itself and in the soft tissues around it. An adhesion is a pathological band, the result of an exudate produced by trauma or inflammation, in the early stage it is weak and easily stretched, but as fibrosis sets in it loses its elasticity and impedes the movement of the joint.

Joint stiffness after injury is due to adhesion of the capsular plications, which, in turn, is the result of organization of any exudate in the periarterial tissues. In fact, it is the recurrence and persistence of serofibrinous exudation which provides the key to the problem of adhesion formation.

conditions associated with limitation of movement in which it would be useless or dangerous to carry out manipulation, the outstanding example of this being tuberculosis of a joint; obstructions which result from mal-united fractures and exostoses are also definite contra-indications to forcible movement. With the possible exception of certain straightforward cases of foot-strain, no joint should be manipulated without previous X-ray examination which will eliminate unsuitable cases of joint disease, gross bony obstructions, loose bodies, fixed joints, advanced osteo-arthritis, and myositis ossificans.

The following points are necessary in the forcible manipulation of any joint:

1. Preliminary treatment, massage and gentle manipulation should be continued till no further functional improvement can be obtained.

2 If the restricted movement is excessive, manipulation should be performed in stages, only one restricted motion or a part of it being restored at each manipulation.

3. Heat, active exercises, and massage of the treated muscle group must be continued after the manipulation until resulting tenderness has disappeared before the next group is stretched.

Contra-Indications.

Manipulation should not be performed in the presence of active disease of a joint, and, even where an acute arthritis appears to have settled down, it may have harmful effects, for the resisting power of the joint may be lowered, and the slightest injury may be sufficient to light up a sub-acute infection. Where the original arthritis was secondary to some focal infection, the focus should first be removed, and manipulative treatment carried out afterwards. Whether an infective process is active or not can be determined by the pain elicited on moving the joint: if the condition is purely traumatic pain will occur only on movement, and will be of the nature of a sharp stab which is soon over; if, however, an infective process is at work there is liable to be a continuous indefinite aching without any apparent cause, or a dull throbbing pain almost unknown in purely traumatic conditions, and any pain definitely caused on movement is at first sharp in character and then slowly subsides. Some cases of adhesions are unsuitable for manipulation, either because the adhesions are themselves too strong to be broken down by manipulation, or because of the risk of producing a fracture, or in some cases a combination of these two factors In fractures of the lower end of the femur with a stiff knee the adhesions may be extremely dense, and if the quadriceps muscle or the patella is fixed to the front of the femur it is very easy to fracture the patella during the manipulation. Similarly in an old fracture of the upper end of the humerus the adhesions may be so strong that under manipulation the neck of the humerus itself gives way before the adhesions It is well to remember that when a limb has been fixed in a plaster-of-Paris case for any length of time there

remembered that this distinction does not apply in cases of septic infection involving the tissues, nor to fractures within the joint.

Signs and Symptoms.	Adhesions	Arthritis
1. Limitation of movement.	Only those movements which put affected ligaments on stretch All others free.	All movements limited to some extent
2. Pain	(*a*) Localised and occurring when adhesions are stretched. (*b*) Maximal when joint is moved. (*c*) Less severe when joint surfaces forced together.	(*a*) Diffuse. (*b*) Maximal when bony surfaces are forced together.
3 Tenderness . .	Can be localized by pressure	Diffuse
4 Stiffness . . .	Stationary or retrogressive	Progressive
5. Muscular wasting .	From disuse only.	Greater than can be explained by disuse alone
6. Temperature of joint	Unaltered	Usually raised

The differential diagnosis is completed by means of an X-ray examination, and indeed the joint should always be X-rayed in any case either of disease or injury.

The Choice of Cases for Manipulation

The main conditions which call for manipulative surgery are: (1) dislocation, (2) adhesions which require to be ruptured, (3) certain conditions of the soft tissues, (4) joints which are not absolutely dislocated but which are the seat of some defect difficult to describe and to which Mennell gives the name "seized"

In all these conditions manipulation is directed towards a joint whose range of movement is limited by some abnormal resistance; the manipulation overcomes that resistance and either completely or partially restores the normal mobility of the damaged joint.

The difficulty in manipulative surgery lies not so much in carrying out the manipulative procedure as in deciding upon the indications for carrying it out It is obvious that there are many pathological

of joint surfaces without an active dislocation; most people have experienced sudden pain in a joint on extreme or unexpected exertion; they check the movement at once, and, if possible, shake the part and get instantaneous relief. In some joints, however, this relief cannot be obtained voluntarily, as the joint may not be accessible, or amenable, and then manipulation becomes necessary. It is suggested that the only possible explanation of such an occurrence is that the joint surfaces have "seized up," to use an engineering expression, and are freed by their subsequent manipulation. Some joints are more subject to this than others, as for example those between the proximal and distal rows of metacarpal bones in the common form of "tennis wrist," a condition easily remedied by manipulation.

The cases most suitable for manipulation are those with limitation of joint movement produced by fibrous tissue adhesions following injury; they are undoubtedly benefited by manipulation, and, it must be added, by nothing else. Manipulation is valuable in the later stages in the treatment of fractures of the limbs where the joints have become stiff as a result of immobilization. In this connection one would point out that prolonged rest of a healthy joint rarely gives rise to more than a temporary stiffness, which, though sometimes more intractable in older people, is easily overcome by passive movement in adolescents and young adults, but that where the prolonged rest is part of the treatment of a fracture in the neighbourhood of a joint, quite considerable stiffness may follow, probably a reaction to stretching or tearing of the joint capsule and ligaments. Some rheumatic joints, whether they be the site of osteo-arthritis or rheumatoid arthritis, are also improved by manipulation, but when to institute this treatment in such cases is a most difficult decision to make. It is not possible to say whether ionization, diathermy, or other form of radiation will be most beneficial in any given case, but they should all be tried in turn, and if none prove successful then manipulation should be considered. Forced manipulation should never be undertaken whilst the joint is acutely inflamed, but only when the joint has recovered from the disease. Broadly speaking, recovery can be said to have occurred when the range of movement of the joint is not diminished by use: if the movement of the joint is restricted to a certain range by fibrous ankylosis, and this range is further reduced when the joint is used, we know that recovery has not taken place, and that manipulation would be disastrous; but if the joint shows an increasing range of movement following function then in all probability it is free from active disease.

Prevention of Adhesions

In order to prevent the formation of adhesions any inflammation that may be present is allayed; local effusions are prevented by pressure; injured structures are massaged early; and movements that place no strain on the injured soft tissues, especially active movements,

is often a considerable degree of disuse-atrophy of the bones which are consequently easily fractured: one has seen a fracture of the upper end of the femur produced by attempting to reduce a congenital dislocation of the hip where a previous attempt had failed, and the patient had spent the intervening period in a plaster case.

As a rule the rigid arthritic joints that are met with in elderly people are better left alone: as Bankart has pointed out, grey hair and stiff joints are an unfavourable combination.

Manipulation is not called for in children, partly because of the risk of epiphyseal injury, but more especially because of the marked tendency to spontaneous cure.

The chief of the contra-indications to the manipulation of a joint is the presence of tuberculous disease. The other main contra-indications are active infective processes, bone over-growth from any cause (such as after fractures), advanced osteo-arthritis, myositis ossificans, bone cysts and bone tumours Great caution is required in cases where bones show considerable radiographic translucency from disuse and where the patella is adherent after fractures of the femur, and in the case of the shoulder after fractures extending into the joint Any erosion of cartilage or the presence of a loose body should as a rule be a contra-indication to manipulation

The following is a summary of the specific contra-indications to manipulation:

1. Any radiological or clinical suspicion of tuberculosis
2. Syphilitic articular or peri-articular lesions
3 In the back, any suspicion of spondylitis or arthritis of the spinal joints or radiological evidence or suspicion of destruction or progressive joint pathology.
4. Gonorrhœal arthritis.
5 Excessive osteoporosis, especially in the aged.
6 Any radiological evidence of malignancy in the bones or soft tissues.
7 Any evidence of compression of the cord or cauda equina.
8. Any case presenting recent leucocytosis, or increased sedimentation rate

Watson-Jones deprecates the use of manipulation in seriously stiff joints with massive adhesion formation, in osteo-arthritic joints, and in low back pain

Conditions in which Manipulation is of Value

Manipulative procedures may be successful if active pathological processes have ceased, or are quiescent, if the limitation of movement is due to adhesions, if the limitation is due to the locking of two joint surfaces upon one another, and if the manipulation is performed with a skill that will lay no undue strain upon a normal structure, whether an intrinsic part of the joint or not. There may be a slight displacement

are free and apparently full. Pain may be complained of on the inner side of the joint line on rotation of the tibia, and tenderness is frequently elicited over the inner side of the joint line, a little in front of the internal lateral ligament or over it.

The treatment of this chronic knee sprain is manipulation under an anæsthetic, followed by massage, exercises, and faradic stimulation to the muscles. A general anæsthetic is given and complete relaxation produced. To break down the adhesions the knee is fully flexed and in that position the leg is rotated out and in.

1. The knee is fully flexed until the back of the calf touches the thigh. This is completed by a short, sharp jerk of the leg towards further flexion and in many cases an audible click or crack will be produced.

2. An attempt is made to pull or push the head of the tibia forwards on the femur. This is best done by putting the forearm into the angle behind the knee, and, using the forearm as a fulcrum, trying to lever the head of the tibia forwards by flexing the knee over the forearm Alternatively the knee is again flexed over the surgeon's forearm which is placed in the popliteal space, and the tibia is then pulled slightly forwards by means of the forearm.

3. With the knee flexed to a right angle, the surgeon grasps the foot with one hand, and the head of the tibia directly with his other hand, while an assistant steadies the thigh, and the tibia is then forcibly rotated, first in one direction and then in the other, using both the grip of the hand and the swing of the body for the movement

4. Standing at the foot of the operating table, the surgeon puts the patient's heel on his shoulder, and after clasping his hands over the front of the knee he pulls down the joint into full extension with one or two short, sharp jerks. This grip gives the most powerful pull and the most complete control of the movements.

5. If the adhesions are in front of the joint, the knee should be flexed while the hip joint is hyper-extended in order that extra tension may be put upon the structures in front of the joint In these cases flexion is carried out with the patient in the prone position.

If, after an injury, a patient is unable to extend his knee fully, we may suspect either an unreduced semilunar cartilage, or, more rarely, a fracture or evulsion of the tibial spine which may be clearly seen on an X-ray film A displaced semilunar cartilage may be reduced by manipulation even if some months have elapsed since the injury. The chief obstacle to reduction is muscular spasm which holds the bones tightly together, gripping the cartilage between them. In the case of the internal cartilage, the knee should be flexed and the tibia rotated inwards under an anæsthetic, then abducted during extension. In dealing with the external cartilage, the tibia should be rotated outwards and adducted. It is sometimes possible without an anæsthetic to "trick" the muscles, since the extensors and flexors are not in spasm together and there is a short period during the change from

are practised, and the early active function of the joint encouraged. Injured joints should be immobilized in the semi-flexed position, as stiffness develops more readily in the extended than in the flexed position, and also because when the joint is eventually mobilized a start may be made in both directions, whereas if the joint has been immobilized in extension all the increase in movement must be made in one direction.

Treatment of Adhesions by Manipulation.

Adhesions should be prevented from forming by early active movement, but once present they should be broken down little by little, or more forcibly under an anæsthetic. The force that may be used in particular cases can be gauged only by experience; one may put all one's force into the manipulation of an adult foot, and the manipulation of a spine also requires a considerable amount of strength; the strength of the adhesions, the size and build of the patient, the age and sex of the patient in relation to the probable strength or brittleness of the bones, and the effect of previous immobilization and probable atrophy of the bones, must all be taken into consideration.

Manipulation fails most often through faulty technique, that is, failure to manipulate with sufficient force and in the right direction, inexperience, fear of accidents, and imperfect muscular relaxation, are responsible for many of the failures and inadequate after-treatment accounts for not a few others.

In attempting to break down non-arthritic adhesions muscular resistance must be eliminated before the passive resistance of fibrous adhesions can be estimated accurately, and this is the most important indication for an anæsthetic, although it is desirable also to avoid unnecessary pain. Full anæsthesia is essential when dealing with old and strong adhesions, as manipulation can only be performed thoroughly when the muscles are completely relaxed; gas and oxygen, therefore, is as a rule only possible for recent adhesions, though the quick recovery of consciousness after it means that the patient can be made to move his joints all the sooner after the manipulation, and this has an excellent moral effect.

As manipulation in most cases consists in forcibly moving a joint so as to stretch and tear the adhesions, we must know what the normal range of movement in the joint should be; this can be ascertained by putting the joint on the normal side through its full range. A different amount of force is required in different joints, and even in the same joint in different cases, and the amount of force which may be employed with safety in the movement, and the extent and direction in which to move the joint, are learned by experience; it cannot be measured or described, but it is the least possible consistent with obtaining the desired movement, and must be of a carefully guarded nature After the joint has been carried to the extreme limit of movement, an attempt is made to carry it a shade farther, and

(*a*) *Cervical Pain.* Pain in this region may be benefited by manipulation if the contra-indications stated are borne in mind.

Method · The patient lies on an operating table with the head projecting The head is grasped by the surgeon with one hand under the occipital region and the other under the patient's chin. Very gently and carefully avoiding undue force, and simultaneously applying traction, the movements of extension, lateral bending, and rotation are performed. Where rotation is limited a sudden and sharp jerk may be carried out at the point of limitation. Immediate re-educational exercises are carried out afterwards. Manipulation of the neck performed this way is valuable in cases of occipital neuralgia and headache.

(*b*) *Dorsal Region.* The patient sits on a low stool for the application of rotation and side-bending. His hands are clasped behind his neck The surgeon stands behind and a little to one side and, stretching across the front of the patient, grasps the patient's arm with one hand and with the other applies pressure to the posterior aspect of the affected region of the back in the region of the angles of the ribs. A powerful leverage is thus obtained and movements of flexion, extension, lateral bending and rotation carried out.

A useful addition to above and a more important one is the movement of hyper-extension. The patient sits well back across an operating table with his hands clasped behind his head and his elbows well forward The surgeon, standing behind the patient, places his hands round the front of the patient's arms back on to the patient's neck. A good leverage is obtained and a sudden movement of extension of the surgeon's spine and a shove forward of his chest produces hyper-extension of the patient's spine. This is usually accompanied by the crack of adhesions giving way.

(*c*) *Low Back Pain* The condition in this region which is most amenable to treatment by manipulation is a strain of the sacro-iliac joint The symptoms and diagnosis of this condition have already been described, and treatment by manipulation is usually very satisfactory, though a proportion of cases are not cured by this method and require operative means

THE TECHNIQUE. The patient lies upon a firm, low operating table and is fully anæsthetized. As in other joint manipulations, the spine is put through its normal range of movements.

It is not usually considered wise to introduce flexion into the manipulative procedures since this movement, in its extreme, may very easily produce prolapse of a disc.

(*1*) *Rotation.* The assistant holds down the shoulders while the surgeon, standing on the right-hand side of the table, rolls the pelvis over towards him. The left leg is brought down over the right side of the table, and the left iliac crest forced, by sudden sharp movements, down on to the table. With the surgeon standing on the left side of the table, the movement is repeated in the opposite direction, and by these means considerable rotation of the spine is effected.

extension to flexion when each group of muscles is passing from contraction to relaxation, or vice versa; at this moment they may be caught off guard or comparatively relaxed. The trick consists in performing rapidly alternating movements of flexion and extension, and in rotating the tibia simultaneously, at the very moment of change from one to the other.

After-treatment. Since the cartilage rarely heals, immobilization serves no rational purpose. All knees after manipulation should have a pressure bandage applied for twenty-four hours to prevent or diminish swelling, and thereafter massage, active movements, and electrical stimulation of the muscles are begun.

3. The Hip Joint.

The chief conditions in the hip joint for which manipulation is used are osteo-arthritis, and un-united fractures of the neck of the femur with a painful adducted limb, and in such cases, manipulation often gives the patient freer movement and relief of pain In manipulating, the joint is moved in all directions, but, where there is any osteo-arthritis, not through its full range but merely until adhesions are felt to give way. Under a general anæsthetic, while an assistant holds the other hip in the neutral position the limb is grasped at the mid-thigh level with one hand and below the knee with the other and the thigh moved until the movement is felt to be checked. An endeavour is then made to estimate the degree and nature of the resistance; if solid, it should be strained but not forced, but if it yields, movement is continued until the limit of safe movement appears to have been reached. In this way all the movements of the hip are dealt with in turn, ending with circumduction. It is dangerous to use the leg as a long handle at a right angle with the thigh, since this long leverage may easily produce a fracture. Great care should be taken in manipulative abduction, adduction and rotation, indeed, in most cases traction of the straight hip, then of the flexed hip, followed by flexion and extension only are carried out.

4. Spinal Pain.

There are cases of spinal pain with no specific signs, expecially those with cord or root pressure and no abnormality in X-rays other than degenerative changes if the patient is in the older age-group, which may be subjected to manipulation The impression is that such cases are associated with some mechanical abnormality of the inter-vertebral joints Such cases have occasional occurrence of pain of fulminating onset and equally sudden remission which, of course, suggests a mechanical derangement and not an inflammatory state In these cases manipulation would seem the only form of direct attack and should be harmless. If, on the other hand, there are signs of disc degeneration, manipulation, in spite of some protagonists, is debatable and dangerous.

anæsthetic where there is some definite indication. "Pump-handling" an elbow is the worst possible treatment and can only result in further limitation of movement It is better to instruct the patient to exercise the joint actively to the maximum capacity of the muscles of the afflicted arm for about 3-4 minutes every hour of the day. It is dangerous to get someone to work on the joint. They cannot resist the temptation to push or force the joint. In cases of stiff elbow it is wise to exclude myositis ossificans by X-ray films before attempting any manipulation, as movement of any kind is contra-indicated in these cases, the correct treatment being prolonged immobilization of the elbow until the new bone has become absorbed or dense and well defined.

A special manipulation is used in cases of tennis elbow. The procedure recommended by Bankart is first to pronate the forearm and flex the wrist; then, keeping the wrist fully flexed, to extend the elbow fully with a short, sharp jerk. This effect may also be obtained by reversing the order of these movements as follows: first fully extend the elbow joint with the forearm in a position midway between supination and pronation; then, keeping the elbow extended, simultaneously complete the pronation and fully flex the wrist with a quick forcible movement. This manœuvre is more likely than the first to stretch the extensor muscles at their origin from the humerus. It is also useful to adduct the extended elbow forcibly in an ulnar direction and in this way further stretch the extensors.

7. The Wrist Joint.

Manipulation is not often called for in the wrist joint, but immobilization of the joint following a sprain may lead to much stiffness from adhesions about the strained ligaments Often after the stiffness appears to have gone the patient still complains of pain and weakness of the hand, and it is found that the extremes of flexion and extension are limited and painful. In these cases, manipulation under an anæsthetic is indicated since full movement may be restored by putting the wrist joint through its normal range of movements. Strong "jerky" traction is a useful addition to the above. The wrist is a joint which is not infrequently affected by what is called seizing.

It is unwise to manipulate the metacarpo-phalangeal and interphalangeal joints which are stiff after injuries of the hand or wrist. They should be treated only by active exercises.

In rheumatoid arthritis, where the patient has a wrist that is becoming fixed in a position of palmar flexion, manipulation is indicated. With the wrist in this position not only is a satisfactory grip impossible but the likelihood of ulnar deviation of the fingers is greatly increased. Even if the wrist is warm and swollen it is wise to put it in dorsiflexion and in a plaster-of-Paris case afterwards This is the only case where this treatment is justified in a "warm" joint but, of course, only one movement is required

(2) *Extension.* The patient is turned on his face, and the surgeon and his assistant place their forearms under the thighs and lift the thighs up; their other hands are then put over the lower lumbar spine and, keeping the elbows straight, they give a sudden jerk in this position, which produces a degree of hyper-extension of the spine.

After-treatment. There is rarely much reaction, and so massage and exercises are begun the following day and are continued for a month or longer; in this way the lumbar spine and sacro-iliac joints are mobilized It may be necessary, in older cases, to manipulate them more than once before they are cured Cases which resist this treatment may be cured by arthrodesis after the manner of Smith-Petersen already described.

5. The Shoulder Joint.

In manipulating the shoulder, especially in the aged, great care is needed, since it is not difficult to produce a fracture or a dislocation, either when rotating the humerus laterally, or when abducting it. The patient lies on his back with the injured shoulder projecting over the edge of the table, and he should be fully anæsthetized, as complete muscular relaxation is a necessity A short leverage is preferable to a long one, so the arm should be gripped at the mid-shaft of the humerus and not at the elbow. In manipulating a right shoulder, the left hand of the operator steadies the shoulder girdle, while the right hand grips the middle of the humerus, with the elbow of the patient flexed over the operator's forearm. The arm is rotated inwards and outwards, and then completely adducted and abducted. In the fully abducted position it is again rotated inwards and outwards. The scapula is next released and allowed to move with the arm while it is fully elevated, in which position full rotation should be carried out, so that the forearm can easily be placed behind the back and behind the neck The arm is then circumducted while being brought down to the side Finally the arms are elevated and the hands placed behind the head, and from this position the arm is pushed backwards, the head of the humerus stretching the front part of the capsule. If adhesions are very firm, these movements may have to be done in stages, but if possible they should be completed at the one time.

Mennell has pointed out the importance of putting traction on the adducted arm, so pulling the humerus downwards, and thereafter pressing the head of the humerus into the glenoid cavity, and again carrying out the various manipulative manœuvres with the head in that position Here, too, the movements of rotation should be carried out with the greatest care lest a spiral fracture be produced Usually traction and abduction are the movements carried out

6. The Elbow Joint.

It is doubtful if an elbow joint should ever be manipulated and certainly, if it is done, it should be only once and probably under an

childhood arthrodesis is apt to lead to interference with the subsequent growth of the bone, and therefore of the limb.

Regarding the stage at which arthrodesis should be undertaken, it is well to bear in mind that during the active phase of the disease an ordinary intra-articular arthrodesis may not be followed by bony ankylosis, the operation should be postponed, therefore, until the disease has been rendered inactive by a period of conservative and anti-biotic treatment, and the final decision as to its suitability must rest on the radiographic and the clinical appearances of the affected joint.

In many cases of joint tuberculosis the operation is carried out by the extra-articular method. This has as its aim the fixation of the joint without opening the joint cavity, and without interfering with the joint surfaces, and, though these aims may not be fulfilled since the capsule has often to be opened, there is nevertheless considerably less disturbance of the diseased area than in the frankly intra-articular type of operation.

The spinal osteo-synthetizing procedures are, in actual fact, extra-articular arthrodeses in the truest sense of the term, and in the hip also a completely extra-articular fusion can be carried out.

Arthrodesis can also be usefully employed in the type of tuberculous joint that heals by fibrous ankylosis in bad position.

(*b*) *Infective Arthritis.* Joints which, as a result of infective arthritis, have been left crippled and painful, with limited movement and bad function, are best treated by arthrodesis, but before the operation is undertaken, the surgeon must be certain that the active infective process has been completely eradicated.

The operation is also applicable in cases of rheumatoid arthritis of the hip or of the knee, though these often fuse without any interference

(*c*) *Neuropathic Arthritis.* Fusion is a beneficial procedure in a Charcot's joint, as it stabilizes the limb, and obviates the necessity for controlling apparatus.

2. Arthrodesis for the Sequelæ of Trauma.

The value of arthrodesis in the treatment of arthritic pain following fractures which involve the articular surfaces cannot be overemphasized. Such pain is especially common in the ankle region, where mal-union is frequent, and where the mal-union has been followed by the development of arthritis, the value of the operation is enhanced. The severe disability which results from fractures of the calcaneus can be diminished by the operation of sub-taloid arthrodesis, and indeed, many surgeons advocate its employment as an immediate measure in all cases of fractured calcaneus where the displacement is gross

Crush fractures of the vertebral bodies may be followed by severe and persistent pain, despite treatment by prolonged recumbency and the application of a well-designed brace, and in those cases a fusion operation will probably alleviate the disabling symptoms.

CHAPTER XIX

ARTHRODESIS AND ARTHROPLASTY

ARTHRODESIS

Arthrodesis is the term applied to the artificial, or operative, production of ankylosis in a joint. In performing the operation usually the whole joint cavity is obliterated, and the bony components brought into apposition; eventually they unite, and with the establishment of bony continuity all trace of the original joint is lost.

Arthrodesis may result in the complete eradication of certain diseases, or may be employed as a method of stabilizing unstable joints.

Its curative function is exercised in virtue of the fact that the diseased tissues are more or less completely ablated. In tuberculosis, for example, the removal of as much diseased tissue as possible, and the approximation of the bone-ends renders the tuberculous focus entirely intra-osseous, and a decided step is thus made towards the natural elimination of the disease. In other types of inflammatory affections, e g rheumatoid arthritis and post-traumatic arthritis, the fixation of the joint may also result in the cessation of the inflammatory process.

Its stabilizing function is of most importance in the treatment of those affections which terminate in flail joints; not only does arthrodesis restore stability, but at the time of operation any deformity can be corrected, or potential distortion prevented

The symptomatic indications for arthrodesis are, in brief.

1 Persistent pain, and

2. Loss of function, with or without deformity.

The principal conditions which produce these are:

1 Arthrites of various types, including tuberculosis.

2 Trauma, particularly fractures involving joint surfaces, or fracture-dislocations

3 Paralysis · usually anterior poliomyelitis, but sometimes a peripheral nerve injury

These will now be considered in more detail.

1. Arthrodesis in the Various Types of Arthritis.

(*a*) *Tuberculosis* In tuberculosis, operations designed to ankylose the joint are restricted usually but not always to adult cases, since in

destructive arthritis (*q.v.*). Key advises the insertion of transverse stainless steel pins and turn buckles to maintain firm contact of the ends of the bones, and which are tightened to produce a positive pressure, the degree being determined by the bending of the pins. Charnley has recently produced a compression clamp to obtain an early and sound arthrodesis.

The Ankle Joint.

The principal indication for arthrodesis of the ankle is following mal-union of a fracture involving the joint and producing pain In paralytic cases a triple arthrodesis after the manner of Dunn, with or without bone block, is often preferable. It may, however, be done in severe paralytic deformities, as equino-varus, where the major deforming factor is in the ankle joint (supination of the body of the talus). The patient should be past the growth period and it is presumed that active muscles suitable for transplantation are not available

FIG. 401 —Arthrodesis of the Shoulder The acromion has been fractured and flexed down on the humerus

3. Arthrodesis in Paralysis.

When a joint has been rendered completely flail after an attack of anterior poliomyelitis, the function of the limb can often be considerably improved by arthrodesis. The method is of great value in flail shoulder, for example, but the operation must be followed by careful after-treatment, in particular, the arm should be kept abducted at a right angle until there is sound union

Arthrodesis may occasionally be of value in certain cases of spastic paralysis In spastic drop wrist, for example, an arthrodesis will substantially improve the usefulness of the hand.

Arthrodesis in the Various Joints

The Hip Joint.

Arthrodesis of the hip may be employed, either for stabilizing a weak joint or obliterating a diseased one; it is applicable, therefore, to tuberculosis, to the flail joint which follows anterior poliomyelitis, to old-standing cases of congenital dislocation, to unreduced traumatic dislocations, and to painful osteo-arthritis

There are two well-recognized methods of carrying out the operation—the intra-articular and the extra-articular, though in many cases a McMurray osteotomy gives better and more certain results. The intra-articular method is carried out by an excision of the cartilages and insertion of a pin (p. 457), while the best extra-articular method is that suggested by Brittain (p. 361).

The Knee Joint.

The indications for stabilizing the knee are essentially the same as for the hip joint, although the knee can often be controlled very efficiently by mechanical apparatus of the walking-caliper, or the knee-cage, type Arthrodesis of the knee is more difficult in children than in adults, and it should be further borne in mind that while a knee joint ankylosed in extension is serviceable for walking, it is a considerable handicap when the patient desires to sit. Most surgeons, indeed, refuse to arthrodese a knee joint until after the age of 14 years, and even then the possibilities are first explained and the final decision left entirely to the patient Usually relatively few prefer arthrodesis to mechanical appliances.

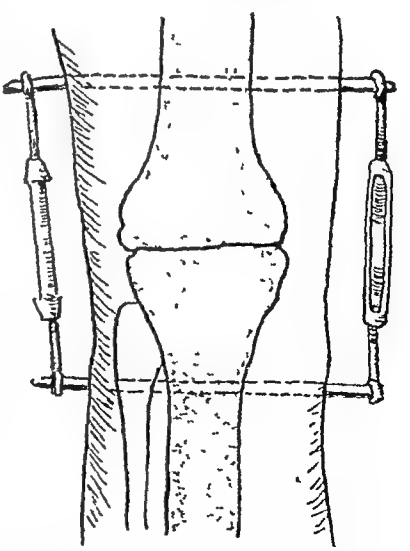

Fig. 400 —Key's Method of Maintaining Bone Contact.

For all practical purposes arthrodesis of the knee finds its greatest sphere of usefulness in tuberculosis and in

To facilitate this manœuvre it is necessary to divide the clavicle and the spine of the scapula.

The wound is closed in layers and a plaster case applied which encases the arm and forearm and reaches from the shoulder to the pelvis. The shoulder is placed in the position of maximum functional utility, i.e. abduction of 75 degrees, with the elbow joint on the same

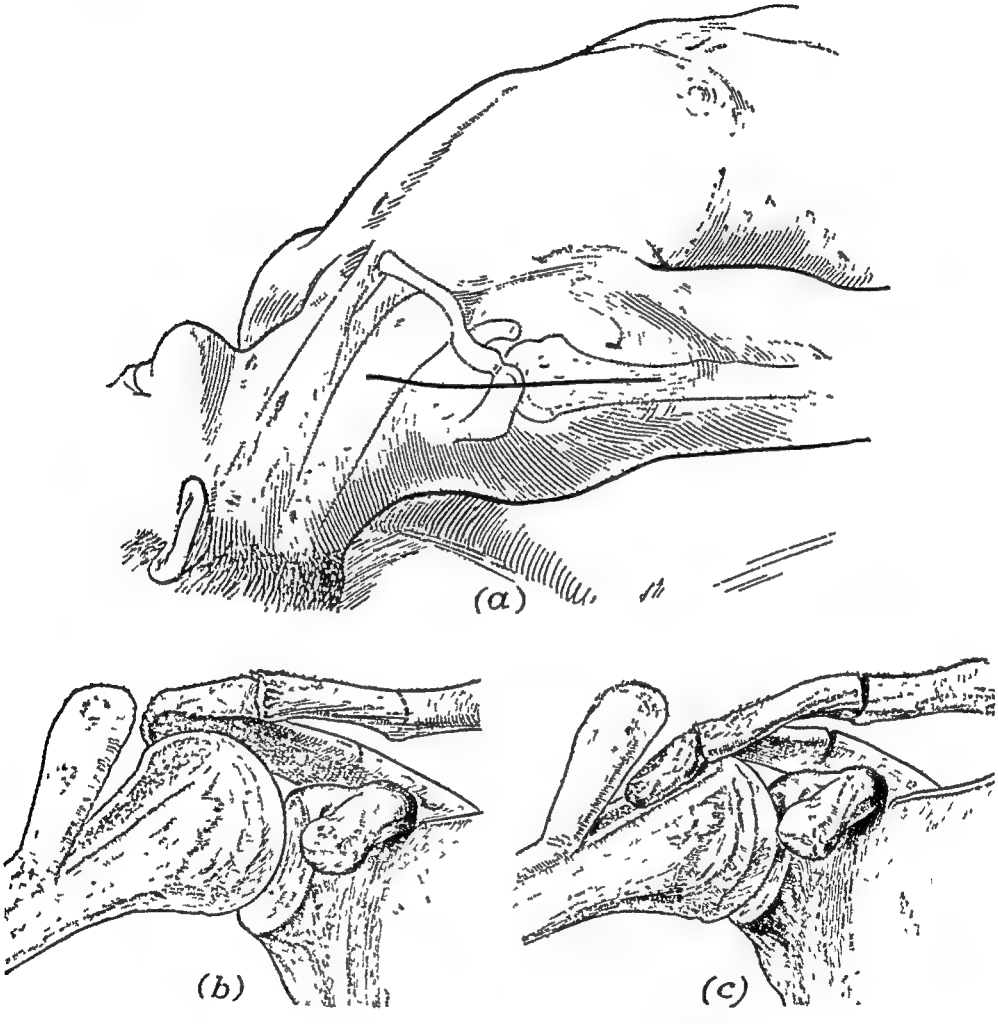

FIG. 402.—Arthrodesis of the Shoulder

(a) The incision from the humerus (b) The acromion and the clavicle are fractured and a wedge of bone raised (c) The fractured parts are bent down and covered by the humeral segment

plane as the anterior surface of the body, and with the forearm slightly above the horizontal, corresponding to slight lateral rotation of the humerus. The stitches are removed in a fortnight's time and a new, more or less skin-tight spica applied; this is a more closely fitting one since, as the wound is healed, fewer dressings are necessary. If X-ray shows a satisfactory position the plaster case is worn for four to six months and thereafter an abduction splint is applied for a further three to six months. When the plaster is removed, massage and muscle

Before the ankle joint is arthrodesed, the condition of the other weight-bearing joints of the limb should be investigated. It is essential that these be in a position to co-operate, and many cases of ankle deformity, otherwise suitable for arthrodesis, will be best left alone if the hip and the knee joints are in any way abnormal.

The various methods of fixing the foot and ankle are discussed in detail in the chapters on Poliomyelitis and Tuberculosis. Formal arthrodesis of the ankle joint alone is often employed in cases of malunion following fracture about the ankle, and is described on page 938.

The Shoulder Joint.

At the shoulder, arthrodesis is employed principally in correcting the flail joint of anterior poliomyelitis. As alternatives to the operation various types of tendon transplantations have been devised to restore mobility to the paralysed shoulder, but these are often unsuccessful as it is often impossible to transpose the muscles to a new humeral attachment without endangering their blood and nerve supply. Fortunately, however, the scapula is endowed with strong and active muscles and when the scapulo-humeral joint is arthrodesed the limb retains a considerable range of movement in virtue to those muscles, the movement now occurring between the scapula and the chest-wall The muscles of greatest importance in this connection are the trapezius and the serratus anterior, and unless they are acting normally the operation is doomed to failure.

Arthrodesis of the shoulder should not be carried out under the age of 10, but thereafter it should be performed as soon as possible, in order to preserve to as great a degree as possible the development of the scapular, the arm, and the forearm muscles, and so conserve the function of the arm.

The operation is also employed in tuberculosis, but co-existing pulmonary infection may be a contra-indication The extra-articular method of Brittain is now most commonly used after the acute phase has subsided (see p. 385).

The Intra-articular Operation. A "sabre-blade" incision is used and the deltoid muscle divided close to its origin and turned down A good exposure is now obtained of the upper end of the humerus, acromion, clavicle and spine of the scapula The capsule is opened and the joint exposed and the head of the humerus dislocated. With a gouge the joint surfaces are thoroughly rawed, all the remains of the cartilage and if necessary sclerosed bone being removed to expose bleeding cancellous bone on both the glenoid and humeral head The joint is now placed in the optimum functional position and a guide wire inserted from the outer aspect of the humerus into the glenoid The position of the wire is checked by an X-ray and when correct a Smith-Petersen pin is driven over the wire and the wire removed The arthrodesis may be reinforced by cancellous chips from the iliac crest or by bending down the rawed acromion into a notch cut in the humerus.

exercises are commenced, special attention being paid to the trapezius and the serratus anterior.

The Elbow Joint.

Arthrodesis of the elbow has a limited application; it is practically impossible in children below the age of puberty, and even in adults it is extremely difficult to obtain sound fixation It may be employed, however, in conditions which have resulted in flail elbow, such conditions include anterior poliomyelitis, gunshot wounds with extensive destruction of bone, and some cases of tuberculosis in which the joint has been rendered flail as a result of a previous excision.

Before arthrodesis is undertaken, the case should be reviewed carefully, and any possibility of muscle transplantation fully explored. Further, in traumatic and arthritic conditions the excellent results which follow arthroplasty should be borne in mind before an arthrodesis is finally decided upon.

In this, therefore, as in most other orthopædic manœuvres, the requirements of the patient will be responsible for the ultimate decision as to the choice of method. In the case of arthrodesis, the choice depends on whether the patient requires a strong, stable joint, or a movable joint; this, in turn, depends partly on his occupation, and partly on his other pursuits. When the left elbow is flail, and the patient right-handed, the joint should be ankylosed.

The Author's Method. A posterior mid-line incision is made and the skin flaps reflected. The triceps is detached from the olecranon and reflected upwards, care being taken to preserve the ulnar nerve. The forearm muscles are stripped from the proximal end of the radius and ulna, if possible without damaging the underlying periosteum, and the lower end of the humerus, which is usually sclerosed, is then completely resected. A cuff of periosteum is then reflected upwards from the end of the bone and the portion of the shaft now exposed squared off by filing. The position of the ankylosis is now decided upon, and, while it is usually impossible to obtain the desired position absolutely, yet with a certain amount of trouble a satisfactory arthrodesis, either in supination or in pronation, can usually be secured.

The position having been decided, attention is turned to the upper ends of the forearm bones. These are usually found to be fused together by a ridge of bone, or connected by strong fibrous tissue. These connections between the radius and ulna should, as far as possible, be preserved Using a small, fine, frame saw, with a detachable blade, a square aperture is now cut between the radius and ulna as near their proximal ends as possible The lower end of the humerus is then inserted into the gap and secured in place by a piece of silver wire. The wire should be knotted in front of the joint as in this situation it is less likely to cause pressure and consequent irritation or necrosis of the skin. The cuff of periosteum is turned downwards, and sutured over the line of union to the periosteum of the

To facilitate this manœuvre it is necessary to divide the clavicle and the spine of the scapula.

The wound is closed in layers and a plaster case applied which encases the arm and forearm and reaches from the shoulder to the pelvis. The shoulder is placed in the position of maximum functional utility, i.e. abduction of 75 degrees, with the elbow joint on the same

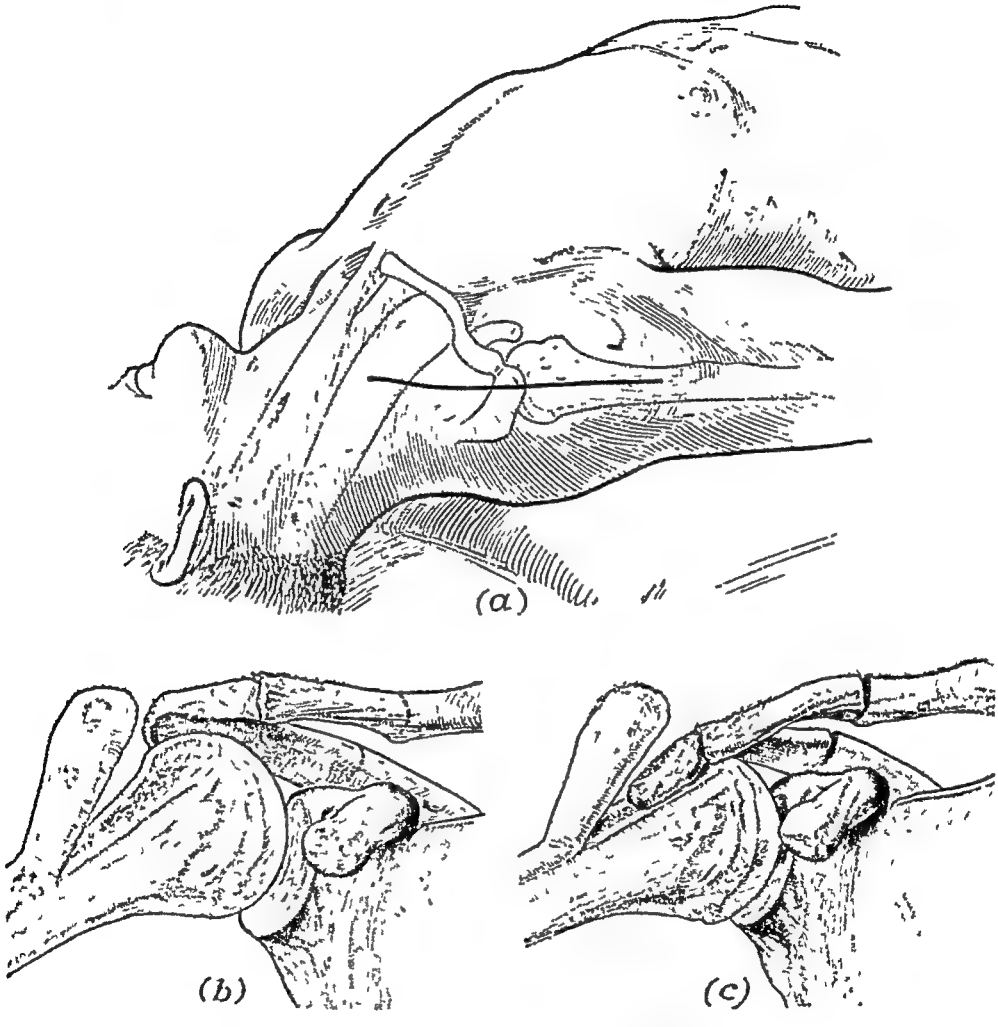

FIG 402.—Arthrodesis of the Shoulder

(a) The incision from the humerus (b) The acromion and the clavicle are fractured and a wedge of bone raised (c) The fractured parts are bent down and covered by the humeral segment

plane as the anterior surface of the body, and with the forearm slightly above the horizontal, corresponding to slight lateral rotation of the humerus. The stitches are removed in a fortnight's time and a new, more or less skin-tight spica applied; this is a more closely fitting one since, as the wound is healed, fewer dressings are necessary. If X-ray shows a satisfactory position the plaster case is worn for four to six months and thereafter an abduction splint is applied for a further three to six months. When the plaster is removed, massage and muscle

ments of the spine the operation of Albee is to be specially commended. The technique of these operations is described in their appropriate place.

Other Joints.

Methods of operative fixation are not necessarily restricted to the larger joints. Indeed, the efficient fixation of certain of the small joints may be a matter of supreme importance in preserving the function of the hand or foot. Naughton Dunn's tarsal arthrodesis, for example, is one of the most notable contributions to the surgery of the foot.

The Wrist.

Arthrodesis of the wrist is indicated when the joint is flail, when it is ankylosed in faulty position, and in painful arthritis, a sequel of such conditions as un-united fracture of the scaphoid, Kienbock's disease, and also following tuberculous, rheumatoid or infective lesions.

In a paralytic flail wrist with good finger function tendon transplantation is a preferable procedure, and arthrodesis should be undertaken only when transplantation fails.

The grasping power of the fingers is considerably greater when the wrist is in a position of dorsiflexion, so that in spastic drop wrist the

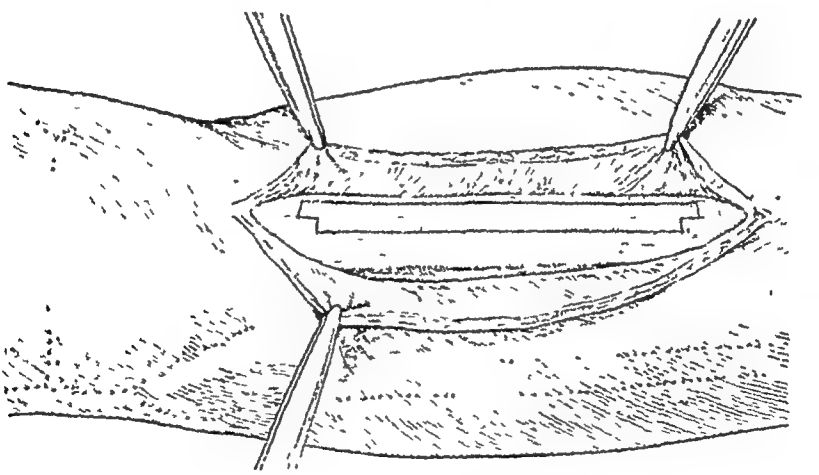

(a)



(b)

FIG. 404.—Brittain's Arthrodesis of the wrist.

(a) The method of cutting the graft
(b) The slotting of the graft into the wrist bed.

forearm bones The triceps muscle is turned back, and provides an adequate muscle covering.

The arm is immobilized in a plaster case, which extends from the wrist to the shoulder and chest. In about three to six weeks the plaster is removed, the stitches cut, and a smaller case applied to include the arm and forearm. This remains on for three months and thereafter a sling is worn and daily physiotherapeutic treatment employed. The author has used recently an angled vitallium plate to secure adequate fixation. Good co-aptation and immobilization are achieved with the plate and to assist union chips of cancellous bone are implanted between and around the bone ends.

Brittain's method. A longitudinal incision 5 inches long is made over the posterior aspect of the joint. The ulnar nerve is exposed but not disturbed. Two holes, each $\frac{1}{8}$ inch in diameter, are drilled in the olecranon process $\frac{1}{2}$ inch apart, the first $\frac{1}{4}$ inch from the tip and the second $\frac{1}{2}$ inch distal thereto and all joined by an osteotomy These drill holes are necessary to prevent splitting the bone. The osteotome is carried up through the elbow joint in the line of the shaft of the humerus, inclining slightly forwards for about 3 inches. Two similar holes are now drilled in the outer aspect of the humerus just above the olecranon fossa While the first osteotome is in position a second is introduced in the long axis of the shaft of the ulna and at right-angles to the humerus, but inclining slightly backwards. By leaving the first osteotome in position the second will avoid it and the grafts will not encounter each other in their passage through the bone. The elbow will be completely locked by the two osteotomes The first osteotome is now withdrawn and replaced by a slightly thicker chisel. This is rocked to and fro, creating a space for the graft. A graft cut from the tibia is introduced and driven into place. A second graft is introduced in the same way.

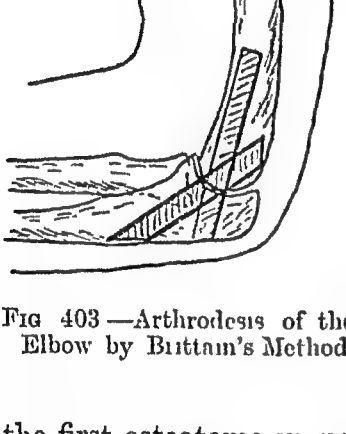

Fig 403 —Arthrodesis of the Elbow by Brittain's Method.

The arm is supported by a plaster case from axilla to the palm and in two weeks the stitches are removed and a new skin-tight shoulder spica applied. This remains on for three to four months

The Spine.

Spinal fusion is commonly carried out in tuberculous disease, and in America is also widely practised in the immediate treatment of crush fractures of the vertebræ. Lumbo-sacral and sacro-iliac arthrodeses are also becoming increasingly popular as remedies for low back affections. For sacro-iliac arthrodesis, the most satisfactory technique would appear to be that of Smith-Petersen, while for the other seg-

exercises are commenced, special attention being paid to the trapezius and the serratus anterior.

The Elbow Joint.

Arthrodesis of the elbow has a limited application; it is practically impossible in children below the age of puberty, and even in adults it is extremely difficult to obtain sound fixation. It may be employed, however, in conditions which have resulted in flail elbow; such conditions include anterior poliomyelitis, gunshot wounds with extensive destruction of bone, and some cases of tuberculosis in which the joint has been rendered flail as a result of a previous excision.

Before arthrodesis is undertaken, the case should be reviewed carefully, and any possibility of muscle transplantation fully explored. Further, in traumatic and arthritic conditions the excellent results which follow arthroplasty should be borne in mind before an arthrodesis is finally decided upon

In this, therefore, as in most other orthopædic manœuvres, the requirements of the patient will be responsible for the ultimate decision as to the choice of method. In the case of arthrodesis, the choice depends on whether the patient requires a strong, stable joint, or a movable joint; this, in turn, depends partly on his occupation, and partly on his other pursuits. When the left elbow is flail, and the patient right-handed, the joint should be ankylosed.

The Author's Method. A posterior mid-line incision is made and the skin flaps reflected. The triceps is detached from the olecranon and reflected upwards, care being taken to preserve the ulnar nerve. The forearm muscles are stripped from the proximal end of the radius and ulna, if possible without damaging the underlying periosteum, and the lower end of the humerus, which is usually sclerosed, is then completely resected A cuff of periosteum is then reflected upwards from the end of the bone and the portion of the shaft now exposed squared off by filing. The position of the ankylosis is now decided upon, and, while it is usually impossible to obtain the desired position absolutely, yet with a certain amount of trouble a satisfactory arthrodesis, either in supination or in pronation, can usually be secured.

The position having been decided, attention is turned to the upper ends of the forearm bones. These are usually found to be fused together by a ridge of bone, or connected by strong fibrous tissue. These connections between the radius and ulna should, as far as possible, be preserved. Using a small, fine, frame saw, with a detachable blade, a square aperture is now cut between the radius and ulna as near their proximal ends as possible. The lower end of the humerus is then inserted into the gap and secured in place by a piece of silver wire The wire should be knotted in front of the joint as in this situation it is less likely to cause pressure and consequent irritation or necrosis of the skin. The cuff of periosteum is turned downwards, and sutured over the line of union to the periosteum of the

function of the fingers is improved by ankylosis of the wrist in dorsiflexion. Probably the best operation is Brittain's modification of the Albee operation, in which the joint is arthrodesed in dorsiflexion. This operation does not interfere with the power of pronation and supination.

The Brittain Operation. A straight incision is made on the dorsal aspect of the wrist extending from 4 inches above the joint to 1 inch from the proximal end of the third metacarpal. The bones are exposed and a gutter made for a graft. This is about half an inch broad and is cut from 2 inches in the radius and extends into the proximal half of the third metacarpal. It is conveniently cut with a very sharp osteotome which is also used to excavate into the marrow cavity of both bones under the cut ends of the bed. The graft is cut with a step at each end so as to fit into the medullary cavity of both radius and metacarpal, a little traction being put on the fingers to allow the graft to be levered and fitted into its bed. When the traction is released the metacarpal overlaps the graft and holds it securely, the step in the graft fitting snugly into the two medullary cavities and locking the joint The arm is immobilized for four months. An alternative method is to make a similar but rather wider gutter and fill it with cancellous chip grafts from the ilium These are punched tightly home. This method is very effective and there is no likelihood of the skin being damaged by pressure as sometimes happens with a cortical graft.

ARTHROPLASTY

Arthroplasty, which has come to occupy an increasingly important place in the work of the orthopædic surgeon, may be defined as a reconstructive procedure which seeks to restore mobility to an ankylosed joint Although joint mobility may occasionally follow as a result of osteotomy, the mere division of bone can scarcely be considered a true arthroplasty since the restoration of movement is not the main objective There is often confusion, too, between excision and arthroplasty, especially in the elbow joint Excision is merely the removal of sufficient bone to induce a pseudarthrosis, whereas arthroplasty is the reconstruction of the component parts necessary to function It should be borne in mind that in reconstructing joints, stability is of equal importance to free movement, and, if arthroplasty is to be successful, both these requirements must be fulfilled

The first attempts at mobilizing joints consisted in performing a simple osteotomy and preventing subsequent union by traction. In this way a patient sometimes obtained a stable, weight-bearing, and movable joint, but the result was always uncertain. In the modern form of arthroplasty, joint surfaces are formed, and a piece of soft tissue interposed between them, in the expectation that its presence will interfere with the subsequent fusion of the surfaces and result in the formation of a permanent joint. The method has been attended by a large degree of success, and is now generally accepted

ments of the spine the operation of Albee is to be specially commended. The technique of these operations is described in their appropriate place.

Other Joints.

Methods of operative fixation are not necessarily restricted to the larger joints. Indeed, the efficient fixation of certain of the small joints may be a matter of supreme importance in preserving the function of the hand or foot. Naughton Dunn's tarsal arthrodesis, for example, is one of the most notable contributions to the surgery of the foot.

The Wrist.

Arthrodesis of the wrist is indicated when the joint is flail, when it is ankylosed in faulty position, and in painful arthritis, a sequel of such conditions as un-united fracture of the scaphoid, Kienbock's disease, and also following tuberculous, rheumatoid or infective lesions.

In a paralytic flail wrist with good finger function tendon transplantation is a preferable procedure, and arthrodesis should be undertaken only when transplantation fails.

The grasping power of the fingers is considerably greater when the wrist is in a position of dorsiflexion, so that in spastic drop wrist the

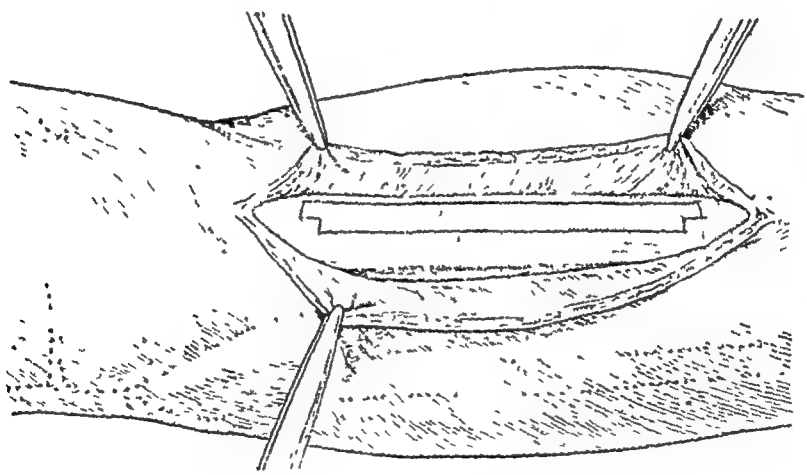

(a)

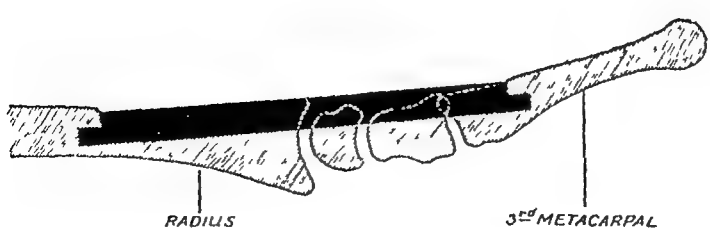

(b)

Fig 404.—Brittain's Arthrodesis of the wrist.

(a) The method of cutting the graft.
(b) The slotting of the graft into the wrist bed

inflammation has subsided. One to two years is usually considered a safe limit in the case of ankylosis from pyogenic infection.

The results of arthroplasty in rheumatoid arthritis are, on the whole, poorer than in the other types of ankylosis, because there is an ever-present danger of recrudescence, and it is extremely difficult to control the tissue reaction of such a joint.

Where a joint has become ankylosed following the reception of some severe trauma, arthroplasty is the procedure of choice, and, similarly, where a joint has been long obliterated by a bony ankylosis as the end-result of a violent inflammatory reaction, the operation may be undertaken with complete confidence

The result of the operation is to some extent influenced by the condition of the chief muscles controlling the joint If the flexor and extensor muscles are well developed, and free from toxic atrophy or scarring, then there is an excellent prospect of a movable joint resulting In the knee, for example, the condition of the quadriceps is all-important, and arthroplasty should never be undertaken when this muscle is grossly atrophied, or where extensive adhesions exist between the muscle and the front of the femur.

In addition to the state of the musculature, the condition of the remaining soft parts must also be considered, particularly when the ankylosis has followed severe war injuries. If there has been extensive destruction of skin, or gross interference with the vessels or nerves in the region of the joint, the technical difficulties of the operation may be so great as to render it inadvisable, unless preceded by some such preliminary operation as a pedicle flap graft or tendon lengthening or stretching.

When the joint has become fixed in bad position, the deformity should be corrected at a previous operation In such cases it might be possible to correct the alignment while the arthroplasty was being performed, but in the majority of cases the deformed attitude would make the operation technically too difficult. The presence of osteoporosis or bone atrophy is unfavourable since they interfere with the remodelling of the bone for the new articulation. Alteration of the internal architecture such as the presence of a medullary cavity through the area of operation does not favour the formation of a new joint

Arthroplasty may be said to enter its sphere of greatest usefulness in those cases in which more than one joint is ankylosed Accordingly where both hip joints are fixed, arthroplasty should be carried out, certainly on one side and possibly on both. Where both elbows are ankylosed, the operation again should be performed on each side, and, when the knees are fixed, arthroplasty should be attempted on one side. When both hips and knees are affected—a condition not infrequently seen in multiple arthritis—an attempt should also be made to mobilize one or more joints

2. The Nature of the Functional Impairment. Ankylosis in good position is quite compatible with efficient function of the limb,

as the standard form of operation. The justification for the procedure is based on the subsequent changes which the interposed flap undergoes. The portion between the bone-ends becomes liquefied, and a sac or cavity, lined with adventitious tissue, forms which is not unlike that of a physiological joint or bursa.

Various materials may be employed as flaps, including pedicled muscle flaps, free fascia lata, and artificial materials such as nylon, etc The interposed tissue is laid over the new joint surfaces and serves in some measure to prevent any gross inflammatory reaction in the joint —an important point, since the formation of granulation tissue would almost certainly lead to fresh ankylosis. Certain additional steps are necessary, however, to prevent further the formation of this granulation tissue, since even the most minor surgical procedures are followed by some degree of inflammatory reaction. The most important points in the technique of arthroplasty in this connection are: strict asepsis and careful hæmostasis. After operation complete immobilization of the joint should be insisted upon until the tissue reaction has settled down

Indications for Arthroplasty. Arthroplasty may be employed for ankylosis resulting from a variety of conditions, but careful consideration must be given to each individual case before it is decided upon. The operation is indicated only when the mobilization of a stiff joint will materially improve the function of a limb, and arthroplasty is likely to fall into disfavour, both amongst orthopædic surgeons and amongst patients, if the latter requirement is not fulfilled.

Certain other factors must be taken into account, however. They are:

1. The nature of the causative disease.
2. The nature and extent of the disability.
3. The circumstances of the patient

1. The Importance of the Nature of the Causative Disease. Arthroplasty should be undertaken only in joints which are [illegible] cally sound, i.e. joints which contain no traces of either [illegible] latent inflammation. The operation, therefore, has [illegible] place in the treatment of tuberculous joints, as these [illegible] considered soundly healed and free from risk of [illegible] exceptional case in which the disease has been almost [illegible] synovial membrane and in which the bony constituents [illegible] are sound and healthy, a good result may sometimes [illegible] In bilateral disease of both hips or knees arthroplasty [illegible] considered if the disease is healed. It is concei[illegible] be considered in old tuberculous [illegible]

When joint ankylosis has [illegible] infection, a considerable time [illegible] taken, in order that there [illegible]

of the granulation tissue, and ultimately, therefore, of the fibrous tissue.

In modern arthroplasties, the preference is for pedicled flaps, as these form a satisfactory covering and at the same time retain their blood supply and vitality. When for any reason they cannot be obtained, then a free graft of fascia lata should be employed. This also retains its vitality, and is associated with little or no tissue reaction. The bone-ends are each generously covered by a flap, which is then firmly secured in position.

(*iv*) *The Prevention of Adhesions, and the Production of a Synovial Cavity* These objects are best fulfilled when the wound heals smoothly and rapidly, and when the limb has been subject to sufficient traction to keep the bone-ends some distance apart. At the time of operation, it is essential to secure complete hæmostasis, otherwise blood-clot forms between the bone-ends and later organizes into fibrous tissue, as a consequence of which the new joint rapidly becomes the site of a fibrous ankylosis The after-care is also important in this connection. Active movement should be begun early after the operative reaction has settled down.

(*v*) *The Provision of New Ligaments, and the Prevention of Undue Mobility* This factor becomes important only in the reconstruction of joints whose stability depends mainly on the peri-articular ligaments In the case of the hip joint, for example, where there is little or no lateral strain, the soft parts round the joint are generally sufficiently strong to compensate for the loss of ligamentous control. In the knee joint, on the other hand, stability is essential, and must be obtained at all costs. To this end, Albee cuts the bones in a V-shaped manner, so that they fit accurately into each other and prevent lateral mobility. Some form of plastic material, such as nylon, is used frequently, while new bone-ends of acrylic are employed in the hip with some success (see p 458 *et seq.*).

(*vi*) *The Restoration of Function.* To obtain the fullest possible return of function, careful and prolonged after-treatment is essential. Traction is applied and the joint surfaces kept apart until a new synovial cavity has formed. In addition, the application of traction ensures that the part is kept at rest. In eight to ten days, when healing is presumed to have occurred, graduated movements should be begun, but weight-bearing should not be permitted for a considerable time.

Arthroplasty of Individual Joints

For all practical orthopædic purposes only four joints lend themselves satisfactorily to arthroplasty The tempero-mandibular joint is sometimes the site of ankylosis and results are good, though it is outwith the province of the orthopædic surgeon In the shoulder, arthrodesis in good position gives such good results, especially when the muscles which rotate the scapula are strong, that it is preferred to

and unless a movable joint is going to confer some extra advantage to the patient, arthroplasty should be avoided. Where the position of the ankylosis is bad, or where the ankylosed joint is painful or becoming progressively deformed, then the operation is definitely indicated, if the other circumstances of the case are appropriate, but it must not be rashly undertaken. In each case the surgeon must decide whether the patient's requirements will not be served best by excising the offending joint and arthrodesing it in a proper position. In this connection, a sharp distinction must be drawn between the upper and the lower limb In the arm, mobility is all-important; whereas in the leg, strength and stability are essentials which must not be sacrificed for the sake of movement.

3. The Patient's Circumstances. Due consideration must be paid to the temperament and social position of each individual patient, while the age is also of importance. The success of the operation depends upon complete and willing co-operation between the patient and the surgeon; and the individual must be willing to suffer a considerable amount of pain during the early days of convalescence, and to submit himself to painstaking after-treatment It is futile, therefore, to attempt an arthroplasty unless the patient possesses the time and the means to undergo this necessary after-care. Arthroplasty is attended with most success when undertaken in young people, provided the period of active bone growth has passed. The age period during which it may be confidently and appropriately performed is usually placed between the time active growth stops and the age of 40. The prognosis is not favourable in children as the epiphysis may be traumatized at operation and growth arrested or distorted.

Technical Considerations in Performing any Arthroplasty.

In the making of a new joint there are certain essential and constant procedures to be performed These are:

(*i*) *The formation of the Gap.* Sufficient bone must be removed to permit free movement in the desired direction At the same time care must be taken not to excise too much, lest a flail joint result.

(*ii*) *The Shaping of the Bone-ends.* The bone-ends are usually roughly shaped by a saw, and then smoothed out by filing. The new joint is constructed either on the principle of a hinge or of a ball-and-socket joint In making a hinged joint, the articular surface must be made as wide as possible, and the two joint surfaces should be made respectively convex and concave, in order to increase the stability.

(*iii*) *The Covering of the Bone-ends.* Many methods have, from time to time, been resorted to in order to ensure a covering over the bone-ends. In the original types of the operation, the bones were distracted and allowed to become coated with granulation tissue. Hard wax has also been employed, and, in a sense, it has been satisfactory, for it checks the bleeding, and to some extent controls the exuberance

the humerus and the forearm bones. The fascia is folded in half lengthwise with the rough surface on the outside and the folded edge is anchored to the anterior capsule or its remains by three catgut stitches. The proximal fold of the transplant is then reflected over the condyles of the humerus. The lateral edges are sutured to the adjacent soft tissue well over the margin of the humerus by interrupted stitches, the new sigmoid cavity is next covered by the distal half of the transplant forming a closed sac which simulates that of the normal joint. Where a radio-ulnar synostosis is present sufficient bone is excised to permit free rotation of the radius and the head of the radius invested with fascia. The articulation is reduced and the soft tissues stitched in place.

The elbow is immobilized in a right-angled plaster-of-Paris case and the arm slung to an overhead frame. By this method the weight of the arm is taken on the hand and this usually supplies a sufficient degree of traction. When healing is complete—10 to 14 days—the case is bivalved and removed every two hours and active exercises practised for a few minutes

2. Carpo-metacarpal Arthroplasty.

Ankylosis of the thumb in a bad position is particularly disabling. It may result from a comminuted Bennett's fracture. Successful cases have been reported by the following method:

A straight incision is made from the dorsal surface of the metcarpo-phalangeal joint of the thumb proximally and passing over the anatomical snuff-box between the extensor tendons. The area of the carpo-metacarpal joint is exposed and the old joint line cut into and through with an osteotome. The base of the metacarpal is freed and may be brought out of the wound to be prepared and filed smooth after sufficient of the bone has been removed to permit free motion. A strip of fascia lata is wrapped round the head and held in place with a purse-string suture After suture of the wound a plaster case is applied with the thumb abducted and opposed Active motion is begun in fourteen days

3. Arthroplasty of the Hip Joint.

This is one of the most important weight-bearing joints in the body and the question of arthroplasty, therefore, constitutes a difficult problem. It is, however, a ball-and-socket joint and so does not depend so much on ligamentous support as do other joints. It would appear, therefore, that the hip joint is ideal for arthroplasty. Nevertheless McMurray, referring to fascial or formal methods of arthroplasty, said the best result of an arthroplasty was a good arthrodesis! Clinically certainly by these methods the results were not satisfactory. Since these days great advances in technique have been made, encouraged no doubt by the epoch-making work of Smith Petersen with his vitallium cup arthroplasty Later the brothers Judet described a new and

arthroplasty. In foot conditions, arthroplasty is not associated with much improvement, save in hallux valgus and hallux rigidus, where mobilization of the metatarso-phalangeal joint effectively relieves the pain. Attempts at reconstruction of ankylosed fingers have been less successful, but better results may accrue from the method in which the whole phalanx is excised instead of merely a small part. In any case, the extensor tendons are so intimately related to the joint capsule that when a small part of the head or the base is removed adhesions ultimately occur between the tendons and the reconstituted joint, and fresh ankylosis occurs comparatively soon

1. Arthroplasty of the Elbow Joint.

Ankylosis of the elbow joint is common, but fortunately the joint is not a weight-bearing one and arthroplasty is usually successful. The following are the indications.

1. Ankylosis following trauma.

2 Rheumatoid Arthritis. Good results are achieved when the activity of the disease has abated and the basal sedimentation rate is low.

3 Ankylosis following pyogenic infection.

Arthroplasty of the elbow is contra-indicated in men of the labouring classes, if the ankylosis is in good position, and if they are able to carry on their work In such cases, a fixed joint is stronger, and therefore more useful for hard manual work, than a joint whose stability has been reduced by mobilization.

The Method. Arthroplasty of the elbow in its simplest form consists of a simple excision of the joint; usually a flap of fascia lata is interposed in addition Successful mobilization after simple excision depends upon the amount of bone removed, and, since there is only a narrow margin between a movable. stable joint and a flail joint the operation must always give rise to considerable anxiety. It is usually impossible to secure an adequate pedicled flap from the neighbourhood of the elbow, and a flap of fascia lata is the more usual covering selected for the bone-ends.

The Operation. A straight posterior vertical incision 6 to 8 inches in length is made through the skin and the flaps reflected The deep fascia is reflected laterally, exposing the broad aponeurosis of the triceps muscle This muscle is divided about 1 inch above its insertion and reflected upwards The joint is exposed and the periosteum stripped from the lower inch of the humerus Fusion between the humerus and the forearm bones is severed with an osteotome, the ulnar nerve being carefully protected. The joint is dislocated. The lower extremity of the humerus is fashioned with a file after the last $\frac{3}{4}$ inch has been removed With a curved osteotome the superficial bone is removed from the sigmoid cavity and smoothed with a file The head of the radius is removed to the level of the inferior portion of this cavity. Fascia lata is now cut, of sufficient length to cover in one piece both

Most surgeons would hesitate with our present knowledge to attempt the operation as recorded results are disappointing. The following points are for consideration before a decision is made

The most favourable age to undertake the operation is from adolescence to 40 years. It is contra-indicated in children, in whom the epiphysis is liable to be traumatized, and in whom it is usually impossible to secure proper co-operation in the after-treatment It should also be avoided in the presence of much scar tissue, when the skin is adherent to the bone or in the presence of flexion contracture of over 100 degrees. When the limb is shortened by more than 3 inches the operation should be avoided, since it causes further shortening The results are also uncertain in large, obese individuals

Arthroplasty should be carefully considered in ankylosis following pyogenic arthritis and following trauma. It is of value in gonococcal ankylosis and osteo-arthritic and rheumatoid arthritic fixation.

Arthroplasty can also be undertaken when tuberculous disease has been cured by a previously performed arthrodesis, if the bone shows sufficient recalcification on radiological examination. In the above circumstances, it should be carried out only at the patient's express desire

The Technique of Arthroplasty of the Knee. The operation should be preceded by the application of a tourniquet, which is applied as high up the thigh as possible, so that it does not interfere with the application of a plaster The joint is approached through a U-shaped incision round the patella, with its concavity upwards The ligamentum patellæ is detached from the tibia, along with a generous portion of the tuberosity. The soft tissue and the remains of the capsule are now dissected off from the ankylosed joint, and, along with the patella and the patellar tendon, are turned upwards to expose completely the anterior and lateral surfaces of the ankylosis.

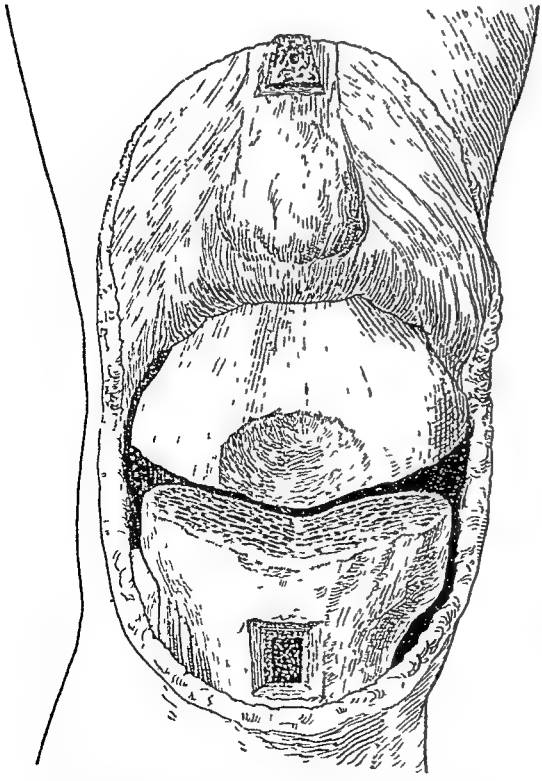

Fig. 405.—Arthroplasty of the knee
Albee's method of sectioning the bones to aid stability

The collateral ligaments are spared to preserve lateral stability but the intra-articular ligaments and the menisci are removed

The bone is divided in a V-shaped fashion, with the apex of the V pointing down-

unique method where the head of the femur was replaced by an acrylic prosthesis. This was followed by many variations of the prosthesis—e.g., Thomson, Moore and others None of these methods has met with universal satisfaction Mrs. Shepherd, in an analysis of 650 cases, found that with regard to durability cup arthroplasties went on improving for up to four years when 45 per cent. had good or excellent results; after five years 51 per cent. had poor results. The Judet arthroplasty was characterized by quicker recovery but the result deteriorated sooner and progressively. She believed that arthroplasties with no inserted foreign material lasted best; then those with unfixed inserts (e g, cups), and lastly those with fixed prosthesis. With improved methods, materials, and techniques, however, it is likely that a replacement arthroplasty may ultimately be the choice.

Some of the indications are mentioned in variations of the clinical conditions found in osteo-arthritis and it is for these that the operation is principally carried out Replacement arthroplasty is also used as an immediate treatment for fracture of the neck of the femur, as a later operation in similar cases where an aseptic necrosis occurs, and where a nailing operation has been unsuccessful It is indicated, too, in bony ankylosis from old infections and in certain late arthritic cases of congenital dislocation of the hip.

The formal arthroplasty with fascia is rarely attempted and where the hip is involved in some pathological process and where an arthrodesis is contra-indicated a replacement arthroplasty or a cup is the choice.

1 Smith Petersen Cup Arthroplasty—*vide* p. 458 (Chapter VIII).
2 Judet's Replacement Arthroplasty—*vide* p. 460 (Chapter VIII).
3. Resection of Head and Neck—*vide* p. 459.

Resection of Head and Neck. This operation, popularized to some extent by Gridlestone, is useful in cases of rheumatoid arthritis which, of course, are not favourable for other types of arthroplasty because of the formation of new bone. It is also used in cases of cup arthroplasty and replacement arthroplasty that have failed. The head and neck are approached by a postero-lateral incision and the head and whole of the neck removed. The important part of this procedure is the after-treatment. Traction should be maintained for six weeks to prevent upward migration of the trochanter and thereafter a tuber-bearing corset and caliper used This minimizes the shortening and produces a certain stability. Sometimes there is added a subtrochanteric osteotomy with backward angulation. This lessens the flexion that may occur when the trochanter is displaced behind and above the acetabulum

4. Arthroplasty of the Knee.

Arthroplasty of the knee is a problem which has so far defeated all attempts to solve it. Owing to the complexity of the joint the problem is a difficult and intricate one. But a reliable arthroplasty would be most valuable when there is a bilateral ankylosis and where movement is of more importance than stability.

CHAPTER XX

AFFECTIONS OF SOFT TISSUES

GANGLION

A ganglion is a cystic swelling in the neighbourhood of a joint or tendon sheath. particularly at the wrist, at the foot, or at the knee. The cyst is unilocular or multilocular, and contains a clear jelly-like, colloid material, or a thick mucinous fluid.

Pathology

There is usually one large main cyst, either unilocular or multilocular, but an accessory cyst may be present. The wall of the cysts consists of dense fibrous tissue resembling that of the capsule of a joint. The lining layer is a smooth shining white membrane, arising as a condensation of the fibrous tissue of the wall The cysts are filled with a thick, sticky, colourless fluid, of the consistency of soft jelly and probably of the nature of mucin. They most commonly arise from a joint but on occasion from a tendon sheath, especially the small one situated in the palm over the metacarpo-phalangeal joint They have usually no direct communication with the joint or the tendon sheath

The microscopic findings show that the development of ganglia may be divided into three fairly definite stages The first stage is characterized by a large number of spheroidal cells which are closely packed together and merged by insensible gradations into spindle cells of the periphery. The second stage may possess features of the first stage and present a central area which is beginning to take on the characteristics of a cavity filled partly with a secretion from those cells Sometimes all of the spheroidal cells undergo the mucoid change at the same time, so that the mucoid material abuts on the spindle cell tissue. It is in the third stage that one finds the changes seen in the well-developed ganglion In this stage the wall is smooth and of variable thickness, and the lining membrane bears an astonishing resemblance to the synovial membrane of joints. The walls of the larger cysts are poorly supplied with blood-vessels, and in many cases the vessels show a marked fibrosis of their wall and narrowing of their lumen Indeed, it has been suggested that the vascular lesion is the real cause of the degeneration, the impoverished blood supply being supposed to induce a local impairment of nutrition.

wards, and the angle between its limbs equal to 120 degrees (Fig. 405). The femur is thus left with a projecting apex. The posterior edge should be rounded off to ensure good flexion. The upper surface of the tibia is so shaped that it presents a corresponding V-shaped depression to accommodate the lower end of the femur. Adaptation of the joint surfaces in this way minimizes to a remarkable extent any lateral instability, since the wedge at the lower end of the femur is forced into the corresponding tibial notch each time weight is borne on the limb.

After their preliminary preparation, the raw bone surfaces are smoothed and filed down in order to facilitate motion A rectangular flap of fat and fascia lata should then be cut from the lateral aspect of the thigh. This graft is laid over the raw bone surfaces, and sutured in position with chromicized catgut. If the patella has been ankylosed to the front of the femur, it may be necessary to interpose a second flap of fascia in this situation.

Instead of fascia a nylon membrane may be stretched over the lower end of the femur and fastened into position with small stainless steel staples driven into the bone Using this method Kuhns emphasized the importance of stretching the membrane smoothly and tightly.

At the completion of the operation, adhesive strapping is applied on either side of the leg, and, before the tourniquet is removed, a plaster-of-Paris case is fitted. The plaster bandages should be applied from below upwards and should be fairly tight. If these requirements are fulfilled, the plaster exerts both a compressing and immobilizing effect, and, therefore, has a marked hæmostatic influence.

A weight of 15 lb. is now fixed by means of tape to the adhesive strapping bands along the medial and lateral sides of the limb. This traction is usually continued for about four weeks, after which the plaster is removed and massage commenced. The case, however, may be bivalved at the end of two to three weeks, and the patient encouraged to begin active movement then. Weight-bearing, on crutches, may be allowed three months after the operation, and thereafter a knee cage should be fitted, with the lateral irons extended down and fitted to a box in the heel of the shoe. This obviates downward slipping of the cage Kuhns *et al* report 58 good results out of 70 operations by the nylon method. In 26 knees the range of flexion was 90 degrees or more and in 40 it was between 60 degrees and 90 degrees.

communis and extensor indicis on the medial side. On the volar aspect of the wrist they usually lie between the tendons of flexor carpi radialis and brachio-radialis, in close relation to the radial artery. They are often intimately attached to the flexor tendon, and in some instances may be adherent to the skin. A particularly troublesome one is found lateral to the pisiform bone. It may press on the ulnar nerve and cause paresis.

(*ii*) *Hand Ganglia* are found attached to tendons about the level of the metacarpal head. They are tender and often disabling

(*iii*) *Tarsal Ganglia.* In the foot, ganglia are situated on the dorsum, in relation to one or other of the intertarsal joints. They are usually smaller and flatter than the wrist ganglia, and are often mistaken for a solid or even a bony tumour.

(*iv*) *Ganglia in the Region of the Knee.* At the knee, ganglia occur in the interval between the femur and the leg bones, usually on the lateral aspect of the joint in front of the tendon of the biceps They are distinct from semi-lunar cysts, but since the two conditions are analogous the differential diagnosis is of little moment. They may arise also on one or other side of the patellar ligament; in this situation they may grow to a considerable size and project beyond the ligament on each side Ganglia in connection with the knee joint may give rise to discomfort and stiffness, and so interfere with the use of the limb to a large extent.

Fig 406 —Ganglion of the Knee Joint

Treatment

Many authorities recommend a preliminary trial of non-operative treatment before radical surgical interference is undertaken.

The simplest mode of treatment is the aseptic modification of the old-fashioned Seton method. The overlying skin is carefully sterilized, and a needle carrying a double thread of thick silkworm gut is passed through the cyst The suture is left protruding from both needle punctures, its ends cut short, and a dressing applied A week later the silkworm gut is removed and the punctures sealed with collodion An aseptic reaction is thus induced and the cyst is obliterated by granulation tissue.

Bundles of nerve fibres are frequently observed passing through the degenerated areas. These may account for the pain and tenderness which are so often associated with ganglion formation.

Etiology

The observations of Carp and Stout suggest that a mucinous degeneration occurs in the dense connective tissue adjacent to joints and tendon sheaths. This affects the collagen in a number of isolated but closely approximated areas, and a series of small cysts arise which later coalesce to form the larger cysts containing mucin

The occasional occurrence of mitosis, and the great thickness of the walls of most of these ganglia, indicate that a tissue reaction must have been called forth by the degeneration. That this cellular proliferation is directly due to the accumulation of the mucinous fluid is borne out by the frequency with which the entire process is arrested by the dispersal and absorption, or the withdrawal by aspiration, of the fluid. King believes that the process may be regarded as a proliferation of cellular structure, a disintegration of cells, and an accumulation of cellular secretion with the formation of a cavity. He concludes that the process is not primarily a degeneration of cellular tissue, but a secretion of the synovial cells. He believes that the chief causes are trauma and a constitutional factor.

Clinical Features

A ganglion gives rise to swelling, impairment of function, and pain. The swelling may be gradual or sudden in its onset, and, once established, is often found to vary from time to time. The size varies with the situation, the largest occurring on the dorsal aspect of the wrist and in the popliteal region. It may be visibly multilocular, but more frequently it is smooth and rounded It can be rendered more apparent by stretching any tendons to which it is attached. The ganglion is usually tense, but a few are fluctuant.

Pain, when present, radiates from the site of the swelling, and is pronounced when the neighbouring joint is moved. If the ganglion is connected with a tendon sheath a feeling of weakness may be experienced in the digits in which the tendons are inserted.

They are met with during the second, third and fourth decades, usually in women; thereafter they become progressively more rare and are uncommon in old age.

Ganglia are to be recognized from their situation and their physical characters There should, however, be no difficulty in diagnosis.

Sites.

(*i*) *The Wrist* On the dorsal surface of the wrist ganglia may occur on the radial, ulnar, or medial aspect. They are usually found over the articulations between the navicular and the lunate, and between the multangulum minor and the capitate. They are situated in the interval between the extensor pollicis longus laterally and the extensor digitorum

(4) *Bunions*, from pressure of faulty shoes over the medial part of the head of the first metatarsal bone.

(5) *Calcanean*, between the insertion of the tendo-calcaneus and the overlying skin.

(6) *Kyphotic*, over the prominent part of the vertebral spinous processes and the skin in some cases of kyphotic curvature of the spine.

(7) Large subaponeurotic bursæ develop under the scalp of Billingsgate porters and those who habitually carry weights on their heads.

Since bursæ are similar in most respects to the synovial membrane of the joints, they are subject to similar types of disease which may be classified as follows:

1. Traumatic
2. Infectious.
3. Syphilitic.
4. Gouty.

1. Traumatic Bursitis

A blow over a bursa is followed by an effusion, usually serous, which appears rapidly and subsides gradually Repeated injuries of a minor nature, such as those that occur in certain occupations, may also produce acute bursitis. This traumatic, or occupational, bursitis, is by far the most common lesion of the bursæ. The wall becomes so thick, and the lining cells so degenerate, that the secreting fluid is no longer absorbed and the sac becomes greatly distended, as for example in "housemaid's knee" It is usually thought that there is some toxic factor at work in addition to the trauma, since only a small proportion of those who require to kneel for long periods ever suffer from pre-patellar bursitis.

Symptoms

If the inflammation is acute, the part is hot, swollen, and tender, fluctuation can usually be elicited and the patient is unable to use the limb

The majority of cases are chronic in type, and there is a gradual accumulation of fluid within the sac, constituting the bursal hygroma In time the wall of the bursa becomes enormously thickened and fibrosed, and there may even be septa running across the cavity. When the thickening is extreme, a fibrous tumour may be formed, which is distinguishable from a neoplasm only by reason of a small cavity which persists in the centre of the "tumour" Loose bodies are often present, and may be recognized on palpation. It is not unusual for hæmorrhage to take place in a bursa and deposits of fibrin and old blood clot adhere to its walls and cause obliteration of the cavity. In these circumstances the bursa becomes more solid to the touch and fluctuation and transillumination will not be obtained.

In deep-seated cases, where the diagnosis is in doubt, a large bore needle should be inserted and the typical fluid aspirated.

The ganglion may be ruptured by gradual pressure of the thumb or by a sudden blow Those attached to the capsule of a joint have a thicker connective tissue wall, however, and are in addition better protected by soft parts, so that they are difficult to burst. If it is not possible to burst the sac it may be punctured with a tenotome followed by firm pressure to disperse the contents

Conservative methods may not be at once successful and may have to be repeated.

When non-operative means have been unsuccessful, surgical treatment should be instituted. The whole of the cyst-wall must be removed, otherwise recurrence takes place. An extremely careful technique is therefore essential; general anæsthesia, strict asepsis, and the control of hæmorrhage by a tourniquet. The ganglia arising from the capsule of joints are intimately adherent to them, and usually have a broad base, so that they can be excised only by sharp dissection. If in the process the joint is entered, the capsule need not be closed, but it is important to secure complete hæmostasis, and a firm bandage, applied after the operation, tends to minimize the risk of a hæmatoma. For some reason a keloid scar is apt to result from the incision and because of this it may be advisable to prevent irritation after the operation by the application of a wrist splint till healing takes place.

AFFECTIONS OF BURSÆ

A bursa is a closed sac lined by endothelium, and containing synovial fluid. It is usually situated over a bony prominence, in the vicinity of a joint, or at a point where a tendon or a muscle moves over a projecting portion of bone. Bursæ may or may not communicate with the joint cavity. Their primary function is to permit of free movement and lessen friction between the hard and the soft tissues of the body, especially where such movement is subject to pressure. Some, such as the pre-patellar and olecranon bursæ, are constantly present, while others such as the bursæ which develop over exostoses, and over a kyphus in a tuberculous spine, are adventitious and develop as a result of continual irritation. Structurally these bursæ are similar to a normal bursa, except that their walls become thick and fibrous from prolonged irritation and the lining becomes shaggy and polypoid, especially from deposits of fibrin and unabsorbed blood clot. Amongst the adventitious bursæ are the following:

(1) "*Tailor's ankle.*" Over the subcutaneous area above the lateral malleolus a large bursa often appears in tailors who sit in the cross-legged position, thus bringing this area in contact with the table.

(2) "*Porter's shoulder,*" between the upper surface of the clavicle and the skin in those who carry loads on the shoulder.

(3) "*Weaver's bottom,*" between the gluteus maximus and the ischial tuberosity.

A retro-calcanean bursa is commonly present between the tendo-calcaneus and the tuberosity of the calcaneus, and, when distended, forms a painful, fluctuating swelling over the back of the heel Similarly there may be a bursa between the insertion of the tendo-calcaneus and the overlying skin, and infection of this bursa is known as calcanean bursitis. The symptoms of bursitis in the region of the heel are pain and tenderness on pressure, which are aggravated by standing and walking It is usually sufficient in the milder cases to remove the counter (stiffening) from the shoe when walking. In obstinate cases, the bursa may require to be excised and any exostosis shaved off. (See also p. 890.)

A bursa is also met with occasionally on the under aspect of the calcaneus, often associated with a spur—the sub-calcanean bursa When inflamed there is pain and tenderness on the under aspect of the heel. In excising the sub-calcanean bursa, a flap is turned downwards and forwards from the heel, the bursa dissected out, and the spur, if present, removed. The bursa most frequently seen in the foot is that which develops over the exostosis of a hallux valgus.

Bursitis of the Knee

Numerous bursæ occur in the vicinity of the knee joint, in relation to the attachments of the various muscles and ligaments. *Anteriorly* there are four bursæ; these are the supra-patellar and the pre-patellar bursæ, a small subcutaneous bursa sometimes present in front of the tibial tuberosity, and the infra-patellar bursa between the proximal extremity of the tibia and the deep surface of the ligamentum patellæ.



Fig. 407.—Pre-patellar Bursitis.

Posteriorly there are two bursæ, one between each head of origin of the gastrocnemius and the capsule of the joint. They often communicate with the joint The bursa between the medial head of the gastrocnemius and the capsule sends a prolongation between the gastrocnemius and the semimembranosus. This bursa is often enlarged, forming a swelling at the inner side of the popliteal space which is spoken of as enlargement of the semimembranosus bursa.

On the *medial* side there are three bursæ One separates the tendons of the sartorius, gracilis, and semi-tendinosus from the tibial collateral ligament as they cross it The other two separate the tendon of the semimembranosus from

TREATMENT

In acute cases, the condition may subside with rest and hot fomentations, but when the bursal wall is thickened the complete sac should be excised.

2. Infectious Bursitis

Infection of a bursa may be due to the introduction of virulent pyogenic bacteria, or to a more attenuated low-grade type of organism. The acute form may be suppurative or non-suppurative, depending upon the type and virulence of the organism. The source of the infection is probably one of the common distant foci of infection, such as the tonsils, the air sinuses, or the teeth. Chronic gonococcal infection is also a common cause, while typical tuberculous bursitis, with caseation and sinus formation, is occasionally seen. The tuberculous type occurs chiefly in the pre-patellar and sub-deltoid bursæ, or in one of the bursæ over the great trochanter.

TREATMENT

An acute infectious bursitis is treated on similar lines to other inflammatory processes. The chronic form, which is usually tuberculous, should be excised.

3. Syphilitic Bursitis

The pre-patellar, the sub-acromial, and the olecranon bursæ may be implicated during the tertiary stage of syphilis.

Syphilitic bursitis is characterized by a primary effusion into the bursa, which later breaks down to form sinuses or ulcers. In all forms of chronic bursitis the blood should be examined, and when the Wassermann test is positive, anti-luetic treatment employed before surgical methods are advised.

4. Gouty Bursitis

In association with gout, degenerative changes sometimes occur in the bursæ, usually the olecranon and the pre-patellar. The bursal wall is the site of a chronic inflammatory change, and the lumen is distended by chalky deposits.

DISEASES OF INDIVIDUAL BURSÆ

Bursitis of the Foot and Ankle

Adventitious bursæ may develop over any of the bony prominences of the foot and ankle under the stimulus of constant irritation Thus an industrial, or trade bursa, popularly known as the "tailor's ankle," may form over the lateral malleolus.

upper part of the tuberosity of the tibia and the ligamentum patellæ is small, and separated from the synovial membrane of the knee joint by a pad of adipose tissue. When infected, there is pain and tenderness over the ligament, and the patient is unable to flex or extend the limb completely. The tibial tuberosity appears enlarged, and there is a fluctuating swelling on either side of the patellar ligament, most marked when the knee is actively extended.

3. Sub-crural Bursitis. This bursa beneath the quadriceps tendon usually communicates with the joint and shares in its diseases When cut off from the joint it may be affected independently, and when distended with fluid forms a horse-shoe swelling around the patella

4. Semi-membranosus Bursitis. The bursa between the medial head of the gastrocnemius and the semi-membranosus tendon is liable to become inflamed, especially in gamekeepers and shepherds Its apparent predilection for the latter is said to be due to the increased amount of knee flexion necessitated by walking through heather and gorse.

The lesion is accompanied by pain and limitation of movement at the knee joint The swelling usually enlarges distally in an intermuscular interval, and presents as an oval fluctuating swelling, limited on its outer aspect, but more free and less defined towards the inner aspect of the popliteal space. As in the majority of these periarticular swellings, it becomes tense on extension and flaccid on flexion of the knee Such swellings are usually much larger than they appear, since they lie under the deep fascia, they have been mistaken for varicose veins

The treatment is excision.

5. The Popliteal Bursa. This arises from the synovial membrane of the knee joint surrounding the intra-articular portion of the popliteal tendon. It gives rise to a rounded swelling behind the external condyle of the femur deep to the biceps tendon and the ilio-tibial band. It has to be differentiated from a bicipital bursa which lies lower down between the biceps tendon and the external lateral ligament. Both may be mistaken for a cyst of the lateral cartilage.

Bursitis in the Hip Region

Numerous bursæ have been described in the neighbourhood of the hip joint, but only three are of any practical significance—the bursa overlying the great trochanter, the ischio-gluteal, and the psoas bursæ.

1. Trochanteric Bursitis. (Sub-gluteal Bursa.)

The trochanteric bursa is one of some size which lies between the tendons of the gluteus maximus and the lateral surface of the great trochanter In inflammatory conditions, pain and tenderness, usually not

the tibial collateral ligament medially and the head of the tibia laterally, and serve to protect the tendon which is sandwiched between the ligament medially and the condyle of the tibia laterally.

On the *lateral* aspect of the knee joint there are three bursæ—one between the biceps tendon and the fibular collateral ligament, one between the fibular collateral ligament and the popliteus tendon, and a third between the popliteus tendon and the lateral condyle of the femur. This last bursa is really a tube of synovial membrane round the popliteus tendon, like that around the long head of the biceps at the shoulder joint, and therefore communicates with the joint.

Symptoms arise most frequently in relation to the pre-patellar and the infra-patellar sacs, in the bursa deep to the medial head of the gastrocnemius, and in those deep to the tendon of the semimembranosus

1. Pre-patellar Bursitis. The pre-patellar bursa is subcutaneous, and is present in about 90 per cent. of people It usually covers the lower half of the patella, and the upper half of the patellar ligament. It is most commonly affected in women of the servant class, or in those whose occupation demands prolonged kneeling. Indeed, effusions into the bursal sac are popularly known as "housemaid's knee" because in scrubbing the hands rest on the floor bringing the bursa into contact with the ground. Priests do not get pre-patellar bursitis because when they kneel in the upright position the bursa is not brought into contact with the ground.

In addition to traumatic effusions, it is perhaps the most usual site for the syphilitic form of bursitis

Pre-patellar bursitis has to be carefully distinguished from osteomyelitis and tuberculosis of the patella; occasionally, in the suppurative type, where there is also necrosis of the superficial aspect of the patella, it may be difficult to determine whether the bone or the bursal infection was the original lesion. The knee joint is practically never involved, owing to the dense ligamentous and fibrous structures which are interposed between it and the bursa. The pre-patellar bursa is said to be liable to gummatous infiltration so that a Wassermann test should be done if there is any doubt.

TREATMENT

The treatment of acute bursitis is that of any ordinary infection—rest and hot fomentations. The fluid may, in addition, be aspirated repeatedly, but the relief so obtained is not permanent. If the effusion suppurates, the bursa should be drained by two lateral incisions.

In chronic infections complete excision of the sac is the most successful method of treatment The dissection is performed through a longitudinal incision to either side of the middle line, and the knee should be immobilized for ten days following the operation, until the wound has healed, thereafter, active function may be resumed.

2. Infra-patellar Bursitis. The infra-patellar bursa between the

origin of the extensor muscles. Compere has frequently found a buttonhole slit of the ligament at operation and he usually also resects it

Treatment

It is commonly agreed that in the acute cases rest, or at any rate abstention from tennis or whatever is the causative factor, will bring immediate relief and ultimate cure. This is, however, slow. In addition to abstention from games the hand should be placed in a cock-up splint to relieve the extensor tendon from tension. Various types of physical treatment—short wave therapy, radiant heat, etc.—may be combined with the rest but the effect of this is probably psychical.

Mills pointed out that many patients with tennis elbow had been relieved by osteopaths and bone-setters. He also observed that in patients with tennis elbow, when the forearm was fully pronated and the wrist and fingers flexed, there was considerable limitation in extension at the elbow. By manipulating the elbow into complete extension, and keeping up pressure over the medial epicondyle with the hand and forearm in the above position, so producing a certain amount of adduction, he was able to relieve the symptoms in every case. Where the symptoms were of long standing, he advocated the use of an anæsthetic. In the typical successful case the manipulation is accompanied by an audible click Cyriax uses deep massage before the manipulation and repeats the treatment four times at daily intervals.

Good results are got from an injection consisting of 50 mg of hydrocortisone in a 2-ml suspension with the addition of 1,000 units of hyaluronidase to ensure maximum dispersion and contact. This may be used along with a 2 per cent. novocaine solution.

Operative Treatment

When the condition is thought to be due to bursitis, or to periostitis, operation may benefit the condition. It may be wise to give a preliminary injection of procaine right down to the bone over the tender spot and to observe how far this relieves the condition. Often this may succeed in curing the condition. The actual operative procedure consists in cutting down to the bone and raising the origin of the common extensor tendon together with the periosteum. In exceptional cases an adventitious bursa or a hypertrophied synovial fringe is found and this should be removed.

The author believes that the condition is due to tearing of the insertion of the extensor tendons After a reasonable period of conservative treatment by injection, the condition is operated on if symptoms still persist. The affected area is exposed after the area of tenderness has been carefully delineated. The muscular insertion is erased from the epicondyle and sometimes even a small portion is excised. The treatment has been uniformly successful, and the author believes this to be due to the subsequent deposit of scar tissue in the affected region securely refixing the muscular origin.

very severe, are situated just behind the great trochanter; the tenderness can be elicited by direct palpation over the area, or by rotating the limb. When the bursa is distended the hollow behind the great trochanter is obliterated, and the limb usually rotated laterally to relax the gluteus maximus. Passive movement of the hip joint is not painful, and there is no flexion contracture. Bursitis has to be distinguished from an acute epiphysitis, osteomyelitis of the great trochanter, and from the inflammatory diseases of the hip joint. The bursa is not infrequently the seat of a tuberculous infection.

Treatment

In the presence of pus the bursa should be incised and drainage established. The incision is made immediately behind the great trochanter, and care must be taken not to go too far from the trochanter lest the sciatic nerve, which lies close to it when the hip is laterally rotated, be jeopardized.

In non-suppurative lesions, rest and physiotherapy are usually sufficient. Tuberculosis of the bursa is most satisfactorily treated by complete ablation.

2. Psoas Bursitis.

The large psoas bursa lies between the ilio-psoas muscle and the pelvis. Posteriorly and above, it is in relation to the ilio-pectineal eminence, and below to the capsule of the hip joint. It accompanies the femoral nerve and frequently communicates with the hip joint. When inflamed, pain and tenderness are present in the medial part of Scarpa's triangle. In the late stage it may suppurate, and fluctuation may then be demonstrated in the same region. The swelling in the triangle may be sufficient, indeed, to obliterate the normal inguinal groove. The bursa is liable to compress the femoral nerve, and pain referred down the limb and to the knee is common, as in hip-joint disease. Flexion of the thigh is painful, and the pain increases when the leg is extended. The diagnosis of this condition from hip-joint disease, and from psoas abscess, may be extremely difficult Before any question of aspiration is entertained, it must be remembered that an obturator hernia produces a swelling in this region.

Treatment

The treatment, in acute suppurative conditions, consists of incision and drainage, and in chronic infections of complete excision. The bursa is best reached by a vertical incision lateral to the line of the femoral artery, the fibres of the ilio-psoas muscle are retracted medially to expose the distended sac. It should be borne in mind that the bursa often communicates with the joint cavity, and it may be necessary, therefore, to drain the hip joint also in purulent infections of the bursal sac.

chiefly the skin, subcutaneous tissue and interstitial connective tissue. The palmar fascia is remarkable, however, for the fact that within its fibres there is evidence of an active proliferation of fibroblasts without other signs of inflammation. The process progresses through the cycle of fibroblastic proliferation and then deposition of collagen fibres which contract and compress the fibroblasts and the final picture of avascular scar tissue results.

Incidence.

Dupuytren's contraction is most common in the later decades—a fact borne out by statistics from various workhouses, where it is present in about 18 to 20 per cent. of the male, and in from 2 to 4 per cent. of the female inmates One or both hands may be affected; when bilateral the condition usually starts on one side some time before the second becomes implicated. Any of the fingers may be involved, but the ring finger suffers most, with contraction of the little finger only slightly less frequent.

ETIOLOGY

The cause of the palmar contracture is still unknown. Dupuytren believed that *trauma* was the essential etiological factor.

The traumatic theory of origin is, however, not very adequately supported by statistics. The error is not by any means confined to workers · indeed, it is more prevalent in those who do little or no manual labour at all, in the proportion of 55 to 45 per cent Furthermore, it commonly affects the left hand, even in right-handed workmen, or both hands. In view of these incontrovertible facts, it is difficult to believe that trauma is an essential factor

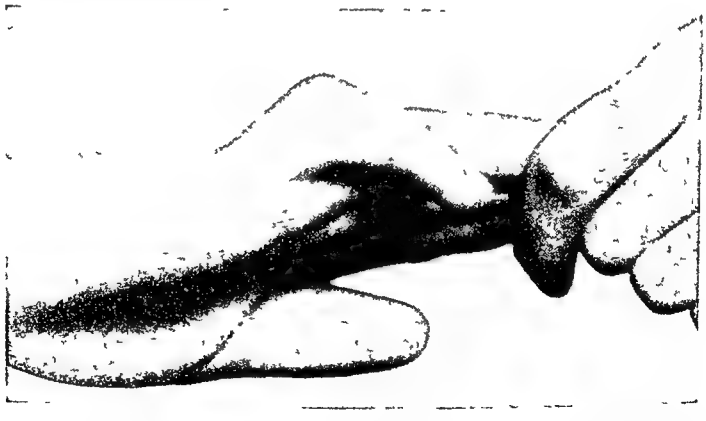

FIG. 410 —Congenital Contraction of the little finger
The metacarpo-phalangeal joint is extended, whereas in the Dupuytren's type this joint is flexed.

Guérin believed it to be due to some "*constitutional vice*," such as gout or rheumatism, and his theory had many adherents despite the lack of convincing proof. It is also seen in epileptics receiving barbiturates for long periods.

DUPUYTREN'S CONTRACTION

Although first referred to by Platter in 1610, the pathology was described for the first time by Dupuytren in 1831 and it has since been given his name, and so this characteristic and common affection of the palmar fascia is now known as Dupuytren's Contraction. The disease begins insidiously and without apparent cause. It results in the shortening or contraction of the fascia, and has a special predilection for the ulnar side of the hand. The male members of successive generations are often the victims

Pathology

At first only the fascia shows any pathological change; ultimately, however, the overlying skin becomes involved. As the finger in consequence becomes more and more acutely flexed, the conformation of the joint surfaces is altered. The earliest manifestation is an isolated nodular thickening, seen usually in the line of the flexor tendon of either the ring or little finger, or both. Later fresh nodules may appear in the fascia over the other flexor tendons, but the middle and index fingers are rarely affected. The skin on the distal side of the primary nodule is drawn up into a fold, and after an interval the finger or fingers become progressively flexed at the metacarpo-phalangeal and the proximal inter-phalangeal joints: the distal joint is held in extension. Eventually the finger becomes so bent that the tip is permanently in contact with the palm, and the power of extension is completely lost. The palmar fascia at this stage can be seen and felt to stand out as a prominent taut cord, closely adherent to the overlying skin The flexor tendons and their sheaths are unchanged, but the joint surfaces of the affected finger may show pressure changes in advanced cases, and the joint capsule is usually contracted to a considerable extent on its flexor aspect. The contracted capsule, indeed, may prove a serious obstacle to full extension, even after the fascial contracture has been adequately relieved The condition has also been described in the plantar fascia.

Fig. 409.—Dupuytren's Contraction.

Histology.

Meyerding points out that signs of inflammation, proliferation of capillaries and fibroblasts with marked perivascular infiltration, affect

When the lesion is fully established, such conservative measures are likely to prove unavailing, and recourse must be had to operative measures.

Operative Treatment.

Only two methods need be considered—

1. Subcutaneous fasciotomy.
2. Excision of the palmar fascia.

The ultimate choice of procedure will depend on the nature and the severity of the contracture, and on the patient's general condition. The minor operation is useful in mild cases, or in those where the main distribution of the contracture is limited to a single finger and the fascial thickening takes the form of a prominent localized band. It is also of value when the age or circumstances of the patient prohibit the more complete procedure.

After the subcutaneous division of the fascial bands, prolonged and assiduous after-care is essential if the first improvement is to be maintained. Despite this, the contracture is liable to recur, since the offending structures have not actually been removed.

The radical operation has the virtue of completely disposing of the affected tissue, and it must still be considered the method of choice in severe cases, when the patient's other circumstances permit of it.

1. Subcutaneous Fasciotomy. The procedure is carried out under a local anæsthetic. A small, sharp tenotomy knife is inserted through healthy skin, and directed towards the tightened bands, which are then divided The operator's finger should rest on the surface at the site of the division, to prevent accidental buttonholing of the skin. A sufficient number of fasciotomies is performed to permit the complete correction of the deformity, and a splint is thereafter applied.

2. Excision of the Affected Fascia. This operation is the radical one and the one of choice in cases that permit of it

Koch has laid stress on certain factors: the correct choice of incision, the use of a bloodless field in operation, complete removal of hopelessly involved skin and wide removal of palmar fascia well beyond the obviously involved area; care in the dissection to protect the digital nerve and blood-vessels; the use of a free full thickness graft, careful hæmostasis and careful asepsis. He uses an angled incision down the hypothenar eminence to the head of the fifth metacarpal and then transversely across the palm at the level of the metacarpal heads. Where the finger is affected a straight incision is used on the ulnar side of the digit

This should be done at an early stage if possible to obviate the contractures of joints and the loss of vitality of the skin Preliminary tenotomies ten days before are advisable where much contracture exists The tenotomy incisions are made at the site of the future operative incisions. This is followed by splintage to lengthen the structures.

There is a striking histological resemblance of the fibroblastic processes in Dupuytren's contraction to other localized fibroblasias such as keloid and fascial desmoid-fibroma of the abdominal wall. The concomitant occurrence in some cases of Dupuytren's contracture of thickening and contracture of the plantar fascias and of induration of the penis seem to suggest that there may be something in the theory of a constitutional predisposition or diathesis.

The question of *heredity*, on the other hand, admits of no dispute; the deformity has been constantly noted to affect several generations of a family The importance of hereditary influences in causing the contracture have not been elaborated

Symptoms

The first sign of the contracture is the appearance of a small hard nodule in the palmar fascia overlying the head of one of the metacarpals. Thereafter the patient notices a progressively increasing flexion contracture, most commonly of the ring finger. Eventually the nodule disappears, and is replaced by a narrow cord-like band of contracted fascia. Gradually other fingers may show some degree of flexion, and the overlying skin becomes puckered and bound down to the contracted fascia. The flexion of the fingers is due to the contraction of the slips or prolongations which pass from the main palmar fascia to the digits; these digital bands do not reach as far as the terminal phalanx, so that the terminal interphalangeal joint remains extended.

Pain is uncommon Occasionally a dull, aching sensation may be felt in the palm, and at times the nodules are distinctly tender.

Diagnosis

Dupuytren's contraction must be distinguished from—

(*a*) Contractions due to injury or infection.
(*b*) Congenital contractions
(*c*) Spastic contractions.
(*d*) Ulnar paralysis.

The first group can be readily recognized from the history, while in the spastic type the long flexor tendons are the structures principally involved, so that when the wrist is fully flexed, to relax the shortened tendons, the finger can be extended. The congenital type is usually bilateral. In both congenital and spastic contractions, too, the metacarpo-phalangeal joint may be fully or even hyperextended.

Treatment

In the early stages, exercises involving hyperextension of the fingers should be prescribed, and the patient should be taught to straighten the contracting finger himself at regular intervals. One of the best methods of so doing is to place the fingers, as fully extended as possible and with their palmar surface down, under the buttocks while sitting down on a hard chair. The patient thus sits on the hand.

of the contracting fascia and incomplete removal of the palmar fascia, while the final result is also vitiated by delayed healing, necrosis of skin, or, of course, division of nerves.

Post-Operative Treatment.

Much depends on the care with which the post-operative treatment is carried out, particularly in the case of the subcutaneous fasciotomy method.

A splint is worn for seven or eight days. Thereafter, in the case of the smaller operation, it is discarded during the day, but worn during the night for a further period of several weeks The patient should be instructed to extend the affected fingers repeatedly during the daytime, to avoid recontraction. After a month or so the hand should be carefully re-examined to ensure that all the contracted tissue has been severed. Frequently tiny slips will be found to have escaped notice, and will ultimately, if left, spoil the efficacy of the whole operation.

If the excision has been complete, it is unnecessary to retain the splint for longer than a week. The stitches, however, should not be removed for a further week or ten days as the palmar skin is thick and heals slowly. Active movements of the hands and fingers should be begun as soon as the skin is soundly healed.

INJURIES OF MUSCLES

Rupture of Muscle

A muscle may be ruptured as a result of a violent contraction, or by sudden relaxation or elongation when it is in a state of contraction, or by a direct blow sustained when it is actually functioning It may occur when the muscle is in strong contraction and the group of antagonistic muscles are suddenly and unexpectedly brought into action. The muscles most commonly affected are the short extensors of the toes, the gastrocnemius, the plantaris, the tibialis posterior, the rectus femoris, the biceps humeri, the deltoid, the trapezius, the sterno-mastoid, and the abdominal muscles.

The site of the rupture may be either in the muscle belly itself or at the musculo-tendinous junction. It may be complete, partial, or only a few fibres may be torn A hæmatoma forms between the divided ends, and is gradually absorbed, and replaced by scar tissue since the muscle fibres themselves do not regenerate. Afterwards, when the muscle belly is brought into action, there may be a visible prominence above and below the level of the rupture. The contractile function of the muscle is slightly diminished, and, if severe, the motion at the associated joints may be limited, and deformity may arise as the fibrous tissue contracts.

At the moment of rupture there is a sudden sharp and stabbing pain, as if from a direct blow, a sensation of something giving way,

In bad cases it is sometimes advisable to do the first stage of a tubular pedicle and attach it to the ulnar border of the hand some weeks previously so that it will be ready for application at the completion of the operation.

The operation is carried out under general anæsthesia and with a tourniquet applied.

The incision advocated by Bunnell is parallel to the distal crease in the palm and at the ulnar end turns proximally along the course of the flexor tendons of the little finger. Through the L-shaped incision a broad flap of skin is dissected up from the palmar fascia but taking with it where possible the superficial fat. The thickened fascia is now removed *en bloc*. Starting at the ulnar side and proximally, a clean dissection is carried out removing every part of the palmar fascia. It is first divided proximally where it joins with the palmaris longus tendon, and grasped with strong Kocher's forceps. The dissection then proceeds to the other side of the palm and to the fingers until it is held only by the bands running down into the fingers As each volar digital nerve and vessel is reached the fascial septum running between these and the flexor tendon is cut off very deep where it runs to the metacarpal The nerves are always located before any free cutting is done. By the dissection the fascial bands are traced down from the palm into the fingers. Each finger is then opened through a mid-lateral incision on one or both sides and the thickened bands dissected out completely and resected, after the volar digital nerves and vessels are located.

It will now be seen how much improvement has resulted. The fingers are not extended further than the stretched nerves and vessels will tolerate. It may be necessary to divide the anterior and antero-lateral parts of the joint capsule.

Primary union is important and if the skin is obviously avascular it should be excised and a full thickness graft from the abdomen applied. If the little finger is too contracted to be useful it is amputated but first the bone is removed and all possible of its skin saved to cover any area in the palm that needs it. Where grafts are used the part is splinted by a dorsal splint and a pressure dressing is applied.

When the dissection is completed the tourniquet is removed and the area pressed by swabs for five minutes to allow clotting. Any vessels still bleeding are ligatured with the finest catgut. The incision is closed leaving in place small capillary tubing to drain the area. A rubber sponge pressure dressing is applied. No attempt is made to extend the fingers fully. The dorsal digitated splint is applied by strapping to the wrist and strips of adhesive are placed round the proximal segment of each finger and one of the digitations of the splint.

The drains are removed the next day, but steady pressure is kept up for two weeks. The only movement allowed at this time is that of the middle and distal finger joints, which is encouraged from the beginning

Poor results follow straight longitudinal incisions made in the line

lesion, i e. at the musculo-tendinous junction, in the tendon itself, or at its point of insertion.

The symptoms and treatment of such lesions are identical with those of rupture of a muscle. When the tendon is essential for the preservation of function, immediate operation should be undertaken. The ends are identified and approximated, the suture being carried out with linen thread. It is to be remembered that, in cases of complete division, the proximal end quickly retracts and a considerable gap may be present from the moment of injury, especially in the flexor tendons of the fingers.

In the case of old injuries, much can be done by a carefully planned reconstructive operation. The tendon is carefully dissected out and the scar tissue removed. Adjacent tendons should also be freed from the fibrous tissue, and gaps, when present, should be remedied by the insertion of a free graft of tendon or fascia lata In spite of the most careful operative technique, however, the results of operation in old tendon injuries are frankly disappointing.

A CONSIDERATION OF THE COMMON TENDON RUPTURES

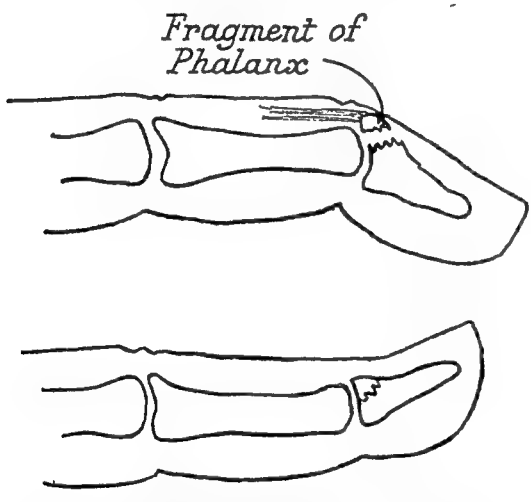

FIG 411 —Avulsion of the Extensor Tendon of the Finger.

Dis - insertion of the Extensor Tendons of the Fingers (Mallet finger).

The tendon to the extensor digitorum communis is sometimes avulsed by sudden forced flexion of the terminal phalanx such as is caused by a blow on top of the finger at cricket or baseball. It seems that it may also happen with very slight violence, as in the case of a housewife making a bed.

The rupture takes place across the posterior capsule of the joint and across the insertion of the extensor tendon. Less frequently a small piece of bone is avulsed from the terminal phalanx In a child the epiphysis may be avulsed Considerable swelling develops within the first few hours and tends to obscure the fact that the terminal phalanx is unable to move, so that not infrequently the case is seen only at a late stage, when the patient is unable to extend the terminal phalanx. Then the persistent flexion of the phalanx produces the typical mallet finger. Rarely an osteophyte grows, blocking extension.

The swelling disappears slowly and the finger is painful for some time Frequently, in addition to the flexion at the distal interphalangeal joint, the proximal one is fully extended, so that the finger is unsightly,

and immediate disability. Sometimes an audible snap may be heard. The part is swollen and painful on movement, while ecchymosis appears in the skin at the point of rupture. A gap in the muscular continuity may actually be palpable.

Treatment

In the incomplete variety, where the line of rupture cannot be palpated, the part should be immobilized in a position which relaxes the affected muscle, the swelling being controlled by strapping, or by a firm bandage. After a few days graduated movements may be allowed, and massage instituted. Faradic stimulation is also useful.

In minor injuries, if treatment is begun promptly, full recovery of function is the rule, except in the case of the posterior spinal muscles where symptoms may persist for a long period. In these cases the delayed recovery may be due to painful adhesions in the scar, and judicious manipulation may therefore prove beneficial

When the rupture is complete, immediate suture is essential, assuming that the patient is of suitable age and physique. This is especially necessary where the rupture has been at the musculo-tendinous junction, as in the gastrocnemius. The post-operative treatment entails immobilization until union is firm, followed by physiotherapy of an appropriate type

INJURIES OF TENDONS

Tendon Rupture

A single tendon may be ruptured by violent muscular contractions, or severed in penetrating wounds Lacerating wounds and severe contusions may also result in the division of one or more tendons, especially where the wounds are situated on the volar and dorsal surfaces of the wrist

Subcutaneous rupture may result from the sudden over-stretching of a muscle, the muscle belly itself remaining intact. The tendon may also be torn away from its point of insertion, with or without an accompanying fragment. The term "dis-insertion" is given to this type of injury.

Platt has divided tendon ruptures into two main groups:

1 The common type, produced by a sudden powerful over-stretching of the muscle while in a state of contraction.

2. The less common and more insidious form, where the tendon apparently ruptures spontaneously This occurs in certain tendons which occupy a bony groove. Here the rupture is determined by friction of the tendon, which gradually leads to attenuation until the tendon ultimately snaps across in response to a comparatively trivial violence. It occurs principally in the extensor pollicis longus and in the long head of the biceps brachii.

Tendon ruptures may also be classified according to the site of the

(3) **Incomplete tear in the middle-aged.** In this type there is 20–30 degrees flexion deformity with an ability to flex the joint fully and extend it to within 20–30 degrees of full range. If such a tear is unassociated with a fracture it may be left alone and it will be found that within a few weeks the patient will have accommodated himself to his disability. Indeed, many aver that such "treatment" is all that is necessary for all cases.

(4) **Arthrodesis.** Where treatment has been unsuccessful or there has been none and the patient complains of loss of function, deformity, or a painful arthritis, the choice lies between amputation and arthrodesis of the terminal joint The latter is the better choice and a very good function will result. The joint is approached through an L-shaped incision or a T-shaped one, and the cartilage is removed from the apposing surfaces. Fixation in 15 degrees flexion is obtained with a bayonet-shaped skin needle and supported after by a plaster-of-Paris case.

Injuries of the Biceps.

Most commonly, when the biceps ruptures, the lesion is situated at the attachment of the long head, either in the bicipital groove—an extra-articular rupture—or at its origin from the upper margin of the glenoid cavity—an intra-articular rupture. Rupture of the biceps insertion at the elbow is exceedingly rare, but Platt records a case in which it was avulsed from the tuberosity of the radius

The tendon of the long head may be ruptured by a sudden over-stretching as in lifting a heavy weight, or it may appear to give way gradually and spontaneously after adhesions between the tendon and the shoulder joint have led to its progressive attenuation. Rupture may be preceded by an actual dislocation of the tendon from its groove.

Symptoms

The patient usually feels a sharp pain on the top of his shoulder extending down the anterior portion of the arm to the elbow Some hear and feel a sharp snap like the crack of a whip, but where a rupture occurs in a tendon already altered by disease the final rupture may occur without the knowledge of the patient His only complaint may be that of weakness of the arm and a vague feeling of discomfort in the shoulder, attributed to rheumatism If the rupture occurs in the tendon of the long head and is complete the belly of the muscle will be drawn towards the elbow and will bulge in the lower third of the arm If it occurs in the lower tendon, the bulging will be seen in the upper third of the arm, and the whole muscle will be drawn up towards the shoulder When the arm is extended passively the tumour becomes smaller but does not disappear. There may be an extensive ecchymosis in the region of the biceps, especially in lesions of the muscular belly, but this discoloration may be absent in lesions of the tendons With the arm at rest, the tumour is felt to be soft and mobile and not adherent

and awkward in use. It gets in the way and stubs in failing to clear objects in grasping

TREATMENT.

The open mallet finger caused by a cutting or crushing violence is treated on the usual lines for a compound joint injury followed by splinting, but it is unlikely for a good functioning joint to result.

The simple closed type is X-rayed to discover if bone has been avulsed as with this type there is often extensive articular cartilage involvement and symptoms of traumatic arthritis can be very prolonged. If this is to be avoided early and accurate reduction of the fracture is essential

(1) Immediate Treatment. This is by immobilization with the distal joint hyperextended and the proximal inter-phalangeal joint held in 60 degrees of flexion to allow the two lateral bands of the extensor aponeurosis to shift volarwards and so gain 3 mm. of slack. The patient is instructed to oppose the thumb and the involved finger and pinch them together to maintain the above position. While he is holding this position narrow wet strips of plaster are laid on the volar aspect of the finger and other strips laid across the dorsum of the finger at its base, and another just proximal to the distal joint. The finger is held in position until the plaster is set. If the finger is fat the hand should be included. The plaster remains on for five weeks, and is replaced then for a week or two by a dorsal splint of Collodion made by painting three coats with intervening gauze on the distal two segments in the position of hyper-extension. It has been suggested that the position of hyper-extension may best be retained by a wire through the distal phalanx into the middle one.

If the X-ray showed an avulsion of bone a further plate should be taken to make sure of its position. If it is displaced within the joint either another attempt should be made to reduce it or it should be exposed as below.

(2) Late Treatment. Repair is indicated by suture if complete recovery is essential. Bunnell points out the necessity of exact technique and delicate handling of the skin and tendon The incision is an L-shaped one crossing just proximal to the distal joint and prolonged if necessary up the side of the middle phalanx. No 35 removable stainless steel wire is used to minimize the reaction. The wire is spliced into the tendon, placing a pull-out wire for its removal, and is made to emerge through the skin close to the finger nail through a drill hole. The finger is put in the position just described for five weeks but the wire is removed in three.

If a bone fragment has been avulsed it is secured firmly in place by a loop of wire about the piece passed through a drill hole in the phalanx and on out through the pulp, where it is tied over a piece of gauze A pull-out wire is placed for its removal

end, the ruptured tendon may be sutured to the tendon of the short head or to the coracoid process. Where the tendon is too short for this, it may be possible to insert it to the floor of the sulcus intertubercularis, after roughening the floor of the latter. This is done by splitting the tendon and fixing it firmly through holes made in the back of the sulcus. Where there is some loss of tendon at the lower part it may be necessary to resort to a transplant of fascia lata. If the rupture occurs in the muscle proper, in addition to suturing the muscle one should overlap a large fascial transplant for reinforcement. For the repair of a rupture of the lower end two methods have been employed—fixation of the tendon on the radius with a nail, or, if this is not possible, suture of the tendon to the neighbouring soft tissues. In old standing cases, especially in old people, operation is rarely worth while.

Rupture of the Extensor Pollicis Longus.

Division of this tendon results in partial inability to extend the proximal joint of the thumb and complete inability to extend the distal joint The injury occurs either as an isolated lesion, or in association with a fracture of the lower end of the radius. The isolated type is seen in kettle-drum players, and is said to be preceded by a mild tenosynovitis. It was known to German military surgeons by the name of "Kettle Drummers' Palsy." When associated with fracture, the tendon rupture usually takes place some weeks after the bone is injured. The fracture, apparently, leads to some distortion or unevenness of the tendon groove so that the tendon becomes weakened through gradual attrition. Finally it ruptures.

The rupture is recognized through the inability to extend the terminal phalanx of the thumb against resistance, and by the absence of the subcutaneous "bow-string" normally formed by the tendon when the thumb is fully extended The loss of function may also be demonstrated by stimulating the muscle belly by the faradic current. There is little or no dropping of the terminal phalanx, as the distal end of the tendon is usually adherent to the lower end of the radial groove.

Treatment

Repair of the tendon usually gives a good functional result. If the division is clean cut the repair is done by direct suture by Bunnell's pull-out wire method No 35 stainless steel wire is used as the least irritating suture and is smooth and strong. The wire suture is spliced into the proximal end and is passed through the distal end and brought out through the skin there to be fastened firmly to a button or the thumb nail. The proximal end of the tendon is thus held distally against the distal end. The ends may be further attached by very fine blood vessel silk or No 40 wire The ends are held together until physiologic union takes place, which is in about three weeks After that the

to either skin or the deep tissues. On flexion of the forearm, especially against resistance, the tumour enlarges and hardens. There may be some tenderness on pressure and sometimes pain. The abnormal perceptibility of the tendon of the long biceps, felt under the anterior border of the deltoid, is of prime diagnostic importance, for ordinarily the tendon ceases at this junction and loses itself in increasing spindle belly mass.

Diagnosis

The symptoms which accompany the disability as well as the type of onset and the findings on examination are valuable. These are detected easily by inspection of the shoulder and arm (shape, deformity, abnormal tumour, hollow, and ecchymosis), by palpation which confirms the site, shape, volume, elasticity and hardness of the tumour, by



Fig. 412 —Bilateral rupture of the biceps

abnormal perceptibility of the tendon, and by examination of the function which is more or less impaired The classical signs of this rupture are Heuter's sign (pain in the shoulder when the supinated forearm is flexed); Pagenstecher's sign (subluxation of the humeral head upwards and medially), and Cruveilhiers's sign (elevation of the humeral head). Although noted the author believes these signs to be more of theoretical interest than of practical value.

Treatment

Occasionally good functional results are obtained by conservative measures, but often, even in the case of partial rupture, loss of function is very marked Operation is therefore advisable. An incision is made in the arm where one expects to find the lesion. If the long head is ruptured at its attachment to the lip of the glenoid or near its upper

Diagnosis

Where the rupture has occurred only twenty-four to forty-eight hours before it is seen, the examination may be rendered difficult by the marked œdema, which tends to disguise the gap between the separated ends The following points may be said to establish the diagnosis ·

1. The presence of a gap into which the finger can be introduced, and which is increased by dorsiflexing the foot.

2. Unduly high level of the prominence caused by the bellies of the calf muscles.

3. An abnormal range of passive dorsiflexion compared with that on the uninjured side. This sign, naturally, is absent in cases of partial separation.

4. Inability to perform, or marked limitation of, plantar flexion. A certain degree of plantar flexion may be obtained by the action of the peroneus longus, the tibialis posterior, and the long flexors of the toes, but this feeble effort cannot be compared with the normal movement which follows active contraction of the calf muscles.

Treatment

A recent complete rupture should be repaired as soon as possible by operation With the ankle plantar flexed and the knee flexed to relax the calf to its utmost, the ends can usually be approximated without undue tension The suture should be carried out with silk unless the tear has been a ragged one, when the sutures may cut out. Under these circumstances a living suture of fascia lata should be employed. Wherever practicable the sheath should also be carefully restored

A modification of the pull-out wire suture of Bunnell may be used. The primary wire pulls down the proximal tendon and makes its exit on the sole of the foot on either side of the heel. Traction is maintained on the wire to relieve the tension on the proximal fragment The rupture is also repaired with multiple small interrupted sutures of silk

After operation the leg should be immobilized in plaster of Paris, with the foot in full plantar flexion and the knee flexed. Three weeks later the foot is gently brought to the right-angled position, the plaster re-applied, and the patient allowed to walk. In six weeks the plaster is removed entirely, and the patient allowed to get about in a shoe with an elevated heel Massage, faradism, and exercises in walking may all be usefully employed in the convalescent period.

Operative treatment should also be recommended in the old neglected ruptures associated with instability of the leg Several methods may then be employed to repair the defect. The suture line may be reinforced, for example, by a strong fascial strip, or by the plantaris tendon which can be left attached to the calcaneus and divided high in the calf. It may even be necessary to turn down a flap from the proximal end, in order to obtain apposition A free tendon graft may also be employed to bridge the defect. In these cases Platt recommends the trans-

suture material is superfluous. The long stitch is removed by a pull-out wire under the proximal loop of the stitch. Both ends of this pull-out wire are brought out through the skin proximally to the tendon junction and there left. If there is any roughening of the radius in the groove this should be smoothed out. In three weeks the stitch attached to the button is cut near the skin after sterilization with iodine and a gentle pull on the pull-out wire. This withdraws the wire suture. If there is any resistance it is done gradually by fixing a small rubber band to it and fixing this to the skin. In twenty-four hours the wire will be out.

In old-standing cases, where there is a considerable gap between the ends, direct suture may be attempted first, but if it prove impracticable, either a free tendon graft from the palmaris longus should be employed to bridge the defect, or the tendon be transplanted into the tendon of the extensor carpi radialis longior.

After-Treatment

The thumb should be supported in a plaster case in full extension for three weeks. Thereafter gradual mobilization is begun, due precautions being taken to prevent over-stretching.

Rupture of the Tendo-Calcaneus.

This is an accident of middle life, and may result from various types of trauma It is commonly found in tennis or badminton players, and in many cases it occurs when the individual is taking a step backwards.

The rupture is usually complete, the tendon giving way through its narrowest part, about 1½ inches above its insertion. The line of separation is transverse and may be clean, like an incised wound, or ragged, from the projecting bundles of tendon fibres The sheath may, or may not, remain intact, and the proximal end of the tendon rapidly retracts. The interior of the sheath rapidly fills with blood, and its walls become œdematous. The plantaris usually escapes damage.

Incomplete ruptures are rare, except at the musculo-tendinous junction. French writers have, however, described a rupture " en deux temps " where an incomplete division is converted into a complete one by a second injury some weeks later.

Clinical Picture

At the moment of rupture the patient experiences a sharp pain, as if he had sustained a blow on the heel There is immediate and considerable disability, and in a short time swelling and tenderness appear. The patient is unable to walk without experiencing severe pain.

In untreated cases the sheath may become adherent to the retracted ends of the tendon and so act as a feeble bond of union enabling a certain amount of muscular contraction to occur. The calf muscles remain shortened and plantar flexion is permanently diminished.

of union should be strong enough in three weeks to allow cautious and graduated movement of the knee joint.

When operation is contra-indicated, the knee should be kept fully extended, preferably on a posterior splint

Rupture of the Ligamentum Patellæ.

This is the least common of the various injuries of the extensor mechanism of the knee. In nature and etiology it is similar to rupture of the quadriceps and fracture of the patella. The upward recession of the patella, the absence of the ligament on palpation, and the loss of power of extension are the obvious diagnostic signs

In an early case repair by suture is usually practicable. In long-standing and neglected ruptures, where the ligament has been gradually replaced by an attenuated band of fibrous tissue, a new ligament should be constructed. A long strip of fascia lata is passed through a drill hole in the tibial tubercle. The two free ends are sutured, under tension, to each other and also to the remains of the ligamentous tissue at the apex of the patella. The knee is then immobilized in extension for three weeks, at the end of which time active movements of the quadriceps muscle and cautious mobilization of the knee joint may be carefully undertaken.

Dislocations of Tendons

The Peroneal Tendons.

Dislocation of the peroneal tendons, upwards and forwards from their normal position behind the lateral malleolus, is by no means rare, and, unless efficiently treated at the beginning, is apt to recur. The dislocation may affect one or both tendons.

The condition occurs usually in older children, and may escape notice for some time , frequently a definite snap is felt at the time of dislocation and this may attract attention to the lesion.

The dislocation may be either traumatic or the result of a congenital malformation of the groove in which the tendons lie In paralytic talipes calcaneo-valgus a similar displacement is occasionally seen. The displacement usually occurs when the foot is dorsiflexed and abducted.

The signs include local swelling and ecchymosis. The function of the foot is not seriously impaired, though the lateral ligament of the ankle joint is usually torn. The patient feels as if something had given way in the foot, and the tendon or tendons are then found to lie over the malleolus or in front of the malleolus

A recurrent dislocation, though often causing no disability, is not infrequently evidenced by a slight limp.

Treatment

In recent cases the tendons should be reduced, and kept in place by adhesive plaster applied over a felt pad laid over and behind the mal-

plantation of the peroneus longus and the tibialis posterior into the calcaneus at the site of the tendon insertion, in order to strengthen the bond of union

The best method is by turning down superficial strips of tendon from the broad upper part. The superficial surface of both parts of the tendon is exposed and the gap and broken surfaces cleared of fibrous tissue The outline of two long strips of tendon ¼ inch wide is made by shallow incisions following the grain of the fibres. Each strip, ⅛ inch deep, is divided above and freed down to within ½ inch of the end of the tendon. These strips are then threaded through the upper tendon ½ inch above its rupture and from back to front. This prevents the strip from being pulled off its parent tendon A transverse channel in the distal stump of the tendon is cut near the calcaneus with a narrow tenotome. The strips are drawn through in opposite directions and with the foot in equinus they are drawn taut and fixed with silk The tendons are reinforced with silk A below-knee plaster-of-Paris splint is applied with still a little equinus deformity to relax tension. This is retained for four to six weeks.

Rupture of the Plantaris Tendon.

A diagnosis of a ruptured plantaris is frequently made, but universal doubt is cast on its occurrence as an actual entity It is more than likely that the condition which goes by this name is rather an incomplete rupture of the tendo-calcaneus, or of some muscular fibres in the calf The disability is slight, and responds well to conservative treatment. The patient sits on a table and allows his foot to drop Several pieces of adhesive plaster are made to encircle the thickest part of the calf Then an elastoplast bandage is applied from the foot to below the knee The patient is then encouraged to walk. By this means a full contraction of the calf muscles is not possible and so the pain is relieved and healing encouraged. In some cases a slight elevation of the heel of the boot will assist in the disappearance of symptoms.

Rupture of the Rectus Femoris.

The tendon of the rectus femoris may be torn across during a powerful contraction of the quadriceps The lesion is therefore similar in nature, and occurs as an alternative, to fracture of the patella from muscular violence. The fibres are usually avulsed from the upper border and the anterior surface of the patella, but a slender strip of the deeper part of the tendon may remain intact. If the quadriceps pouch is torn at the same time, a hemarthrosis accompanies the rupture.

The patient is usually past middle age, and the clinical features are typical of tendon ruptures in general. In spite of the integrity of the vastus medialis and lateralis, extension of the knee is quite impossible, and there is an obvious gap between the two ends of the divided tendon.

Repair of the rupture by operation should be carried out, except in aged patients or those of a bad physique. After suture the bond

Stenosing Tendo-vaginitis at the Radial Styloid

This is an affection of the tendon sheaths of the long abductor and the short extensor of the thumb, characterized by fibrosis of the sheath and narrowing of the intra-thecal lumen.

It occurs at the point where this tendon runs through a ligamentous synovial lined sheath for 1¼ inches over the prominence of the radial styloid. It runs in a shallow bony groove where it is subject to direct trauma. At the styloid process this tendon is subject to an unusual degree of sharp angulation in the various motions of the wrist. The joint between metacarpal and radius angulates more sharply in women and is more liable therefore to friction trauma

Keon Cowen has pointed out that anatomical variations of the tendon are common. In 79 per cent. of cases the abductor pollicis longus was represented by two tendons and in 94 per cent the tendon of the extensor pollicis brevis was very small and in some only a small wisp of a tendon. In 33 per cent he found that the pollicis longus occupied a separate compartment though a single fibro-osseous canal was usual

Etiology and Pathology

The friction between the tendon, tendon sheaths and bony prominence incurred in holding the tendon in its bed through its greatest range of angulation results in tenosynovitis which eventually becomes stenosing. It appears that the excessive use of the involved tendon is the most likely explanation, since it occurs almost exclusively amongst workers who use their thumb a great deal. In some instances, however, it apparently follows a single direct blow. In both cases the effect is to induce an increased friction between the two tendons and the rounded distal end of the radius An œdema of the tendon sheath is thus produced and this results in a vicious circle, since it further increases the friction. Ultimately fibrosis leads to an actual stenosis of the sheath at this point

De Quervain in 1895 first described the condition in the abductor longus pollicis tendon but it is known to occur in other tendons now, especially the extensor carpi radialis, extensor carpi ulnaris, and the peroneus longus.

The X-ray examination frequently fails to show any change in the underlying bone, although occasionally, especially in old-standing cases, there may be an irregularity at a point on the radius which corresponds to the site of the stenosis of the sheath

Clinical Features

The patient invariably complains of severe pain at the wrist, usually localized in the region of the radial styloid, the pain may radiate into the hand and up the forearm. There is weakness of the thumb and weakness of the grip The onset has been gradual, usually without

leolus. If the ankle is then kept at rest with the foot inverted for four weeks a return of the displacement is unlikely.

In recurrent cases of dislocation there appears to be a choice of two methods of treatment. In that commonly used by the author the peroneal groove behind and below the malleolus is deepened by means of a sliding graft of bone from the malleolus slid downwards. By means of an osteotome the lateral aspect of the malleolus is separated from the main bone in a vertical direction, and then slid downwards about ¼ inch, or more if necessary, and fixed by means of a screw nail. Excellent functional results follow this operation.

Watson-Jones suggested an operation in which he used a strip of the tendo-calcaneus to thread through the fibula. The tendo-calcaneus is exposed and a tendon strip 2½ inches in length and about ¼ inch in width on the lateral aspect of the tendon is freed from above downwards and left attached at its calcanean insertion. The peroneal tendons are firmly retracted. A hole is drilled transversely through the fibula ½ inch above the tip of the malleolus and the tendon slip is passed from behind forwards through the drill hole, looped and sutured on itself. This operation prevents the re-dislocation of the peroneal tendon, therefore making a capable substitute for a retinaculum.

Trigger Finger

Trigger finger is a condition in which some obstacle to full voluntary flexion or extension of the finger is present, and the movement can be completed only by assistance. When thus passively moved past the position in which it is arrested, the finger jerks into the desired position with a faint audible snap.

The phenomenon is due to a stenosing tendo-vaginitis of the flexor tendons of the finger. When the hand is opened and shut the affected finger shows a slight range of movement, but remains in a position of flexion. When the digit is passively extended, slight resistance is encountered until a certain point is reached, after which the movement is free.

It usually affects the middle finger of the right hand, particularly in women; the ring finger and thumb are also occasionally affected.

A small thickening or enlargement is found on the flexor tendon where it passes beneath the pulley opposite the metacarpo-phalangeal joint. The opening in the pulley may be constricted or a portion of the sheath itself may be thickened and constricted and pressing upon the tendon itself to such a degree as to cause an enlargement of the tendon on each side of the band.

If rest in a splint in the semiflexed position for some weeks proves ineffective in relieving the condition, the tendon sheath may be explored. If a nodule is present it is excised A fusiform enlargement of the tendon requires splitting of the annular band. This should be split on its lateral side and never on its gliding surface. Care should be taken to avoid the digital nerve.

ACUTE INFECTIONS OF THE HAND

Acute infections of the hand are due to the introduction of pyogenic organisms. When pus is present the term "whitlow" is used to describe them. They may take many forms, and accurate diagnosis of the various types is essential to good and proper treatment. The various types of whitlow gradually merge into one another and sometimes more than one form is present. Organisms may be introduced through a trivial wound, such as a pin-prick, a puncture by a splinter of wood, or through a fissure. The onset is usually abrupt, and the local manifestations of inflammation—heat, redness, swelling and pain—are quickly apparent round the site of entry of the organisms. The pain may attain great severity, and is worse if the arm is dependent, or if the part is squeezed or knocked against anything. The patient is usually unable to sleep, and the general condition deteriorates rapidly.

Iselin, to whom tribute is due for an excellent monography on the subject, emphasizes that the pathological anatomy is the foundation of the whole problem of acute infections of the hand and classifies them in a way that is easy to understand, for each has its own clinical features and its own particular incision.

Classification (Iselin-modified).

1 *Whitlows*

(A) Superficial Whitlows—in one of the layers of the skin

i. Subcuticular whitlows.
ii. Peri-ungual whitlow (paronychia)
iii. Sub-ungual whitlow.
iv. Carbuncle (furuncle of the finger).
v. Acute spreading infections.
vi. Gangrenous whitlow.
vii. Erysipeloid.

(B) Deep Whitlows—subcutaneous.

(*a*) Infections of the subcutaneous cellular tissue—cellulitis.

i Whitlow of the pulp
ii. Whitlow of the second phalanx.
iii Whitlow of the first phalanx-basal segment

(*b*) Infections of the tendon sheaths—tenosynovitis—of the second, third, and fourth fingers Infection in the sheaths of the thumb and little fingers cause abscesses of the hand rather than whitlows of the fingers.

2 *Complications of Whitlows.*

i Osteomyelitis of a phalanx
ii Arthritis

any precipitating trauma. The pain becomes so severe in the course of weeks or months that the wrist is completely disabled. It may be neuralgic in character and is very severe at night. It is also aggravated by abduction and extension of the thumb or by pressure over the radial styloid, or by ulnar deviation of the hand.

Examination occasionally demonstrates a visible swelling in the region of the styloid, which is extremely tender to pressure. Occasionally a cartilaginous-like thickening can be felt under the skin, while at times the periosteum of the underlying radius is also thickened. There is never any redness, infiltration, or rise in local temperature, while crepitus on movement is never elicited.

Treatment

Two methods only are likely to be of any avail—prolonged immobilization or operative intervention

Conservative treatment is by immobilizing the tendon by means of a non-padded plaster case including the forearm, hand and thumb to its distal crease. The wrist is put in dorsiflexion and the thumb in its position of function—opposition. This is said to give, with six weeks treatment, relief in about 70 per cent. of cases If a cure is not obtained in this period, operation is indicated.

Bunnell recommends a short transverse scar to make it less conspicuous and lessen the likelihood of a keloid formation. The deep fascia is divided longitudinally and twigs of the radial nerve carefully avoided. A small incision is made into the sheath and a probe passed up and down to locate exactly the constriction The sheath is then slit open and left so A considerable longitudinal section of the tendon sheath should be removed as this is more certain to cure than simply a long slit

Bunnell has pointed out the presence of a third or aberrant tendon in the sheath and has suggested that its presence may be the cause of incomplete cure in some cases. This extra tendon has a separate muscle slip which fuses higher into the muscle of the abductor pollicis longus. Bunnell found the tendon 1½ inches long and lying along the volar aspect of the abductor tendon. None of his cases was inserted into the metacarpal nor did any of them move the thumb when pulled; instead they radial- and palmar-flexed the wrist. They were inserted into the scaphoid, trapezius, transverse ligament, or thenar fascia The tendon, when giving symptoms, produced some limitation of the thumb and wrist and weakness in the thumb, cramp in the forearm when moving the thumb, and in one case pain and tenderness over the tuberosity of the scaphoid

Wherever found, this tendon should be excised since it has a shorter lever arm than the abductor although both arise from the same muscle. This upsets the mechanism and is the cause of the symptoms.

TREATMENT

The separated epithelium is completely removed with scissors, and the exposed dermis carefully examined for the presence of a small sinus leading to the subcutaneous space. No anæsthesia is necessary for this small operation The thorough removal of the detached epithelium

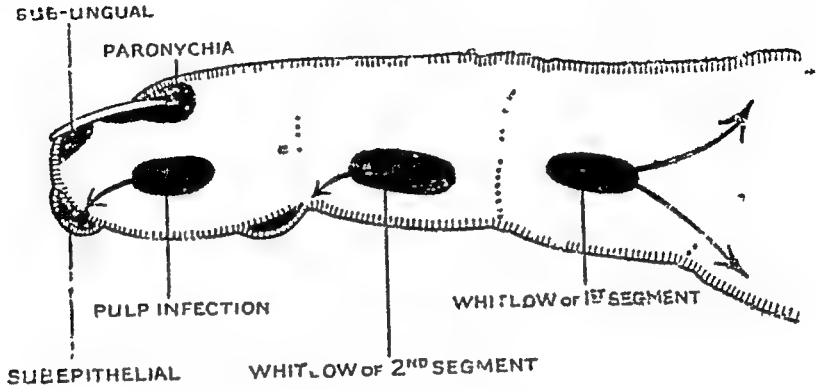

FIG 413—The Varieties of Whitlow
The arrows show direction of spread

is essential, otherwise the persistence of undermined edges favours the development of further infection. A simple absorbent dressing is applied.

When a small sinus is found leading below the dermis it may be that the removal of the raised epidermis is enough to permit drainage of the deep abscess. But if pain is still present in two days further drainage is carried out under general anæsthesia

(ii) Paronychia.

The troublesome form of subcuticular infection which affects the nail-folds is known as paronychia The infection may be introduced through a "hang nail," or by the separation and elevation of the eponychium when the nails are manicured From the anatomical point of view two varieties have to be distinguished according to whether or not there is pus under the nail The peri-ungual type is a simple septic blister, while in the sub-ungual type the nail is attacked by the underlying pus The infection starts on one side of the nail as an acute localized one but tends to spread towards the base and the opposite side and is therefore known as a "run-around"

A more frequent type is that associated with chronic infection along the edge of a "hang nail." For a few days pus may exude from the inflamed area about the nail-edge. Then a certain amount of swelling and redness may be observed, but with little or no pain In some cases the pus may burrow deeply towards the bone for the proximal edge of the nail lies in contact with the phalanx More usually the swelling extends round the base of the nail until eventually the opposite side is reached At the end of two or three weeks drops of pus may be expressed from under the various parts of the eponychium A few weeks later the entire nail may become detached along its base, but in spite of

3 *Abscesses of the Hand.*

(A) Superficial

i Superficial phlyctenoids (septic corns).

ii. Superficial carbuncles—mainly on the dorsum of the hand.

(B) Deep (subaponeurotic).

i. Infections of the radial and ulnar tendon sheaths.

ii. Infections of the cellular spaces—thenar, hypothenar, middle palmar spaces (pre-tendinous, retro-tendinous and commisural) and dorsal.

Frequency. Severe cases of hand infection are now uncommon Wilson has tabulated the frequency of the various types of infection, and states that pulp infection accounts for 24 per cent., cellulitis 30 per cent., paronychia 27 per cent, web infections 12 6 per cent., thecal infection 1·6 per cent, and "others" 2 2 per cent. His figures run closely parallel with those from University College Hospital.

Bacteriologically the infections are often due to penicillin-sensitive staphylococcus aureus, or streptococcus In consequence it is often possible to abort an early infection before suppuration occurs by antibiotic therapy; when pus has formed, or there is sloughing, although it may prevent spread or blood infection, penicillin or any other antibiotic will not affect the progress of the local lesion. The antibiotics, therefore, have not led to any amendment of surgical principles in the management of suppurative hand and finger lesions The indiscriminate use of antibiotics is to be deprecated. If a neglected lesion is not seen until after necrosis or suppuration has supervened, surgical treatment without antibiotic therapy is the first step, and is usually effective. In a growing number of cases, the infecting organism is not sensitive to penicillin, and in these too correctly planned surgical intervention is the proper course.

(A) Superficial Whitlows

(i) The Subcuticular Infection.

This condition, also known as a purulent blister, usually results from pricking the finger. An abscess forms in the skin, usually on the palm, though it also occurs on the dorsal aspect. It raises the epidermis from the dermis over a varying area which may include the greater part of the finger. Frequently a subcuticular collection of pus co-exists with an infection of the subcutaneous area, the two communicating through a small sinus in the dermis. This "hour-glass" or "collar-stud" abscess is found particularly at the webs of the fingers, and especially in men who resume arduous manual labour after a period of idleness. In the "collar-stud" type the superficial pocket is small, the finger is swollen and tender, and pain does not cease with pus formation, as it does in the ordinary superficial collection.

Palpation with a small instrument reveals an area of maximum tenderness. When the pain is thus localized operation is indicated. An incision is made parallel to the nail edge and at the point of maximum tenderness A triangular piece of nail is excised in order to expose the abscess cavity completely. Healing occurs quickly and the nail usually grows without deformity.

(iv) Carbuncular Infections.

Carbuncles may develop on the hand as elsewhere; they affect the hair-bearing portions on the dorsum, particularly the dorsum of the proximal phalanx, and the ulnar aspect of the back of the hand. The staphylococcus is the usual infecting organism.

The carbuncle may develop either in the hair follicle and its associated sebaceous gland, or in the convoluted sweat glands The infection then spreads downwards into the subjacent fat, and extends laterally until it eventually fills up the loose space under the skin. From there it ascends into other glands in the neighbourhood, and from these numerous sources the infection extends to the surface, straining, as it were, through a sieve The central part of the lesion becomes necrotic, and pus and debris are extruded on the surface. The drainage is inadequate, however, and the process still tends to extend round the periphery.

Clinically, the lesion presents a central zone of necrosis, in its immediate vicinity, the skin is perforated by a series of pus-exuding sinuses; beyond this there is a bluish zone which is undermined by pus which has not yet penetrated the skin Surrounding the entire lesion, there is an area of induration which indicates the inflammatory nature of the process

Treatment

The carbuncle should be freely laid open by cruciate incision, which extends well beyond the indurated edge into normal tissue. The four flaps thus marked out are reflected until healthy tissue is exposed all round the periphery. Any free sloughs are removed, but curetting is undesirable and harmful Hot moist gauze is now packed under each flap to ensure drainage The packing is removed at the end of twenty-four hours and the flap allowed to fall back into position

(v) Acute Spreading Infections.

This type of infection varies from a fleeting lymphangitis to an inflammation involving skin and subcutaneous tissues, it may be accompanied by abscess formation and areas of necrosis leading to loss of skin. It is very common in doctors and nurses and often a very serious, and may be fatal, condition.

Signs and Symptoms

A minute wound or pin-prick, surrounded by redness and swelling, may or may not be visible. The incubation period is very short, the

the improved drainage there is still a chronic discharge from the original nail sulcus and a fungus-like mass of granulation tissue growing from the nail-bed. Although the base of the nail may be raised entirely from its bed, the distal exposed portion remains firmly attached to the matrix.

TREATMENT

The pus is evacuated through a longitudinal incision along the lateral side of the nail; it extends back to the base as far as the sulcus, and passes well to the lateral side of the nail to avoid damaging the nail-bed or the overhanging cuticle. The eponychium is pushed back with a sponge and the point of a sharp scissors inserted under the detached edge of the nail, which is cut off along with any portion of the nail-root which has been undermined by the pus. The flap of cuticle reflected by the incision is now kept elevated by inserting under it a small strip of gauze saturated with vaseline. Hot moist dressings are then applied for two days, at the end of which time vaseline-gauze dressings are employed.

When more than half of the nail-base has become involved in the swelling and redness, a second incision is made on the other side of the nail, and, after reflecting a flap of the entire eponychium, the nail-fold is packed as before. The entire nail-root will often be undermined in such cases, and, if so, it is completely removed, the distal adherent portion of the nail being left undisturbed The end of the finger then remains protected by the adherent part of the nail. When the nail is completely removed the application of a dressing or even a light touch on the nail-bed causes a good deal of pain.

(iii) Sub-ungual Whitlow.

This type follows a perforation or a partial detachment of the nail. The pus collects as a small abscess between the nail and its bed, either



FIG 414 —The Method of removal of the detached Part of the Nail in Paronychia

at the tip of the finger or at its lateral aspect. It may spread to the pulp, or towards the bone and produce an osteomyelitis. Violent pain prevents sleep and there is a sensation of tightness and throbbing.

is a third group where the local lesions are less extensive and where the gangrenous process is localized.

The organism is usually the hæmolytic streptococcus alone or with other organisms, but the non-hæmolytic type and others are found. Such infections do not confine themselves to those of poor physique and poor general health. Rather the opposite in fact, since they often occur in those of robust health. The important factor seems to be the extraordinary virulence of the micro-organism.

TREATMENT

Acute spreading infections are now rare, and can be arrested by penicillin, aureomycin or erythromycin. The patient should be treated in bed and the part splinted. Local heat may give comfort.

As resolution occurs, local suppurative lesions may appear anywhere in the area of infection. These must be drained, in accordance with the surgical principles governing the treatment of infection in the appropriate site—tendon sheath, intermuscular space, axilla Areas of skin necrosis may require to be incised, and often a skin graft used to cover the raw area when granulation tissue has covered it.

(vi) Gangrenous Whitlow.

Iselin points out that often a finger infection apparently following a normal course suddenly becomes gangrenous over a more or less extensive area. This he says is due to an arterial thrombosis and not to local anæsthesia, tourniquet or antiseptic dressings hitherto believed to have been important The gangrene is noticed when the dressing is changed The skin is cyanotic, cold and insensitive. It may occur in a simple whitlow or in a case of acute diffuse suppuration There is no pain or general disturbance but the finger is inevitably lost. Treatment is, of course, disarticulation of the finger through healthy tissue as soon as possible.

(vii) Erysipeloid.

This curiously enough occurs in the catering trades—fishmongers, greengrocers, cooks, etc It is seen as a curious red and painful swelling, usually at the base of the finger. There is no pus. It progresses slowly and may spread from one finger to another.

It appears two to fourteen days after an injury, usually a scratch There is a sensation of tightness, itching and heat Round the wound is a dark red raised zone. The pain is often severe and is accentuated by changes in temperature There is no rise of temperature nor are there any general symptoms, but in some cases there is glandular enlargement. The condition lasts two to three weeks and local recurrences are common The cause is the bacillus of swine fever (B erysipelatis suis)

Treatment is entirely conservative and consists of warm moist dressings and later the part is painted with tincture of iodine. X-ray therapy and antibiotics are also recommended

patient usually showing signs of an infection of the gravest type after a very few hours. In other cases the infection appears to follow a mild course and then quite suddenly the infection flares up to an alarming extent. If the terminal phalanx is the primary site the whole finger may be swollen and red, and there may be red streaks along the dorsum of the hand and on the forearm These streaks represent the dilated and inflamed lymphatics, and are tender and on light palpation with the fingers easily felt as tightly stretched threads.

The lymphatics of the hand pass almost invariably by the shortest route to the dorsum, and hence dorsal œdema and redness are constantly found in palmar infections. The back of the hand is pink in colour and pits readily on pressure.

When the primary focus is situated in the little or ring fingers, or at the ulnar margin of the hand, infection spreads along the ulnar margin of the forearm to the epitrochlear glands, which become enlarged, painful and tender. Some of these lymphatics, however, pass directly to the humeral group of the axillary glands, without communicating with the epitrochlear glands.

When the primary focus is in the thumb or index finger infection travels by the lymphatics along the radial side of the forearm. Some of these vessels incline medially across the front of the forearm, to pass with the lymphatics of the ulnar side to the epitrochlear glands or to the humeral group of the axillary glands. The majority pass along with the cephalic vein on the lateral side of the arm, to the delto-pectoral interval, where they terminate in one of three ways—by draining into either the infra-clavicular group of the axillary glands, the delto-pectoral glands, or, very rarely, the supra-clavicular glands.

It will be evident, therefore, that lymphangitis from an infective focus in the thumb, index, or middle finger is potentially much more serious than that from a focus in the ring or little finger, since infection may spread directly to the infra-clavicular or even the supra-clavicular glands, rendering systemic involvement much more probable

The hand and arm are rosy red in colour, often with purplish patches. The redness is accompanied by an infiltration of the tissues most prominent on the dorsal aspect but also involving the medial side. Palpation of the whole area is almost painless. The swelling limits movement. There is no lymphadenitis in most cases though it is occasionally present and may go on to suppuration.

In the fulminating cases death occurs in a few days following on a most extraordinary impairment of the general condition. Within two days the body is wasted, the skin dry, the eyes hollow, the lips open and dry, showing the teeth and gums and producing a most impressive and unforgettable facies.

In the more fortunate patients a less rapid course is present and the symptoms are less overwhelming. Gangrenous patches may occur in the skin and late pulmonary infections are to be expected. There

means of free egress. As the pressure rises the vessels which supply the distal part of the phalanx, and which lie one on each side of the space, are obliterated, necrosis of the bone following as a direct consequence. The branches which supply the epiphysis are derived before the main arteries enter the space and hence the necrosis is limited to the diaphysis. The pus may spread to the surface under the dermis producing a "collar-stud" whitlow—usually at the tip on the palmar aspect. It may spread laterally and gain the lateral edges of the nail fold Lastly it may spread deeply and infect the bone. The pulp space infection of the thumb may in addition spread to the thenar space or along the long flexor tendon sheath.

TREATMENT

In more than 50 per cent. of pulp infections complete and early resolution follows treatment by rest and penicillin. In most of the remainder, this treatment leads to a small localized abscess which should be drained by an incision over the actual lesion. If such conservative measures fail, or if suppuration is advanced when the patient first attends, a more liberal drainage is necessary.

The incision should be situated on the lateral aspect of the phalanx, so that after healing the tactile portion of the finger will be left free from scars. The pulp space extends from the tip of the digit to the level of the epiphyseal line of the terminal phalanx—that is a quarter of an inch distal to the last interphalangeal crease. The incision therefore should not extend further proximally than this. The incision should be long enough to open the pocket freely; it is unwise to make a circular flap incision round the end of the finger, and if the single lateral incision appears to be insufficient, a second should be made on the opposite side.

If the phalanx is bare and exposed in the abscess cavity, it should be removed, if only one part of its circumference is exposed, it should not be interfered with as it frequently heals without giving rise to any trouble If the joint is found to be seriously involved, amputation is generally advisable.

(ii) Whitlow of the Second Phalangeal Space.

This is a special type described by Iselin. The pus is circumscribed to the palmar aspect of the second phalanx and is usually more fluid and contains fewer sloughs than that of whitlow of the pulp. It may spread towards the skin as a "collar-stud" abscess and only exceptionally into the adjacent spaces or into the tendon sheath The finger is red, œdematous, flexed and rigid Tenderness is present throughout the length of the second phalanx It may be difficult to differentiate this whitlow from a tendon sheath infection, but in the latter there is pain along the line of the sheath with a maximal point of tenderness at the proximal end—i e over the palmar cul-de-sac of the sheath

(B) Deep Whitlows

(a) Infections of the Subcutaneous Cellular Tissue

These infections develop in the cellular tissue of the palmar aspect of the fingers. The palmar creases on the fingers demarcate three segments each of which corresponds to a phalanx. The distal pulp space is the commonest type of whitlow and is unique because it is not a loose space since the fibrous bands tack down the skin to the periosteum and penetrate the bone The middle space is localized by fibrous partitions above and below, and separated from the bone by the deep tendons covered by a strong fibrous arch The proximal space is separated from the middle by this fibrous partition, but communicates with the palm along the lateral aspects of the base of the finger and therefore infection can easily reach the cellular planes of the web of the finger. The cellular tissue of the proximal and middle spaces is much looser and less resistent than that of the pulp.

(i) The Pulp Space Infection.

Anatomy The pulp is divided into separate compartments by non-extensile fascia running between the periosteum of the distal phalanx and the skin. The digital arteries run distally through the pulp tissue close to the antero-lateral surface of the phalanx to reach the nutrient foramina of the phalanx, which enters the diaphysis in its distal third The branch supplying the epiphyseal part of the phalanx lies proximal to the pulp. The distal part of the phalanx may therefore sequestrate while the proximal epiphyseal part remains well-nourished

The pulp space abscess, also known as a felon, is one of the commonest infections of the distal phalanx. There is usually a history of a pin-prick, but not infrequently no preceding injury can be discovered. On the second or third day after infection the tissue is œdematous and infiltrated with yellow serum around a small central area of necrosis seldom larger than a cherry stone. There is severe pain in the distal phalanx, at first pricking in character, but rapidly becoming throbbing, so that the patient is unable to sleep or even to rest. The distal portion of the finger becomes red, swollen, and tender, and the tenderness is situated for the most part over the area of involvement In the later stages pus forms, and with the tissue destruction this sensitiveness disappears. The top of the finger is at first tense from œdema, but this tenseness is soon replaced by induration and loss of its normal resilience—a cardinal sign indicative of pus. Later there is a fluctuating boggy mass, unless, as is more usual, the pus has perforated to the surface before this stage In the pulp of the distal phalanx, the connective tissue framework is so arranged as to form a terminal closed sac, while the strands which unite the skin to the periosteum form an easy pathway for infecting organisms It is not unusual, therefore, to have the periosteum and the bone secondarily infected If pus develops in this closed space it is held under considerable tension, and has no

is made towards the collection of pus far enough back on the lateral aspect not to endanger the digital vessels. A slip of rubber dam may be inserted and even pulled through a second incision on the opposite side. There is no danger of pressure ulceration of the sheath, which is well protected at this level.

(iii) Whitlow of the First Phalangeal Space.

Infection in this area is uncommon and is usually caused by direct infection of the space through a puncture or incised wound. It develops in two to three days, soon involves the lateral aspects of the finger and then spreads to the web of the finger on one side only.

The clinical signs are those of a whitlow with pain predominating at the base of the digit. An asymmetrical swelling is observed at the base with involvement of the web. The neighbouring finger is separated from the infected one. The redness and swelling is principally on the palmar aspect but spreads towards the dorsum. Lymphangitis is often present The point of maximum tenderness reveals the site of the pus and it is to be noted that this tenderness is not over the upper cul-de-sac of the tendon sheath in front of the metacarpo-phalangeal joint as in a sheath infection. Although the finger is often flexed it can be extended easily. This condition has to be distinguished from an infection of the web itself and this is done by noting that the web infection is accompanied by a symmetrical swelling and œdema that involve the bases of the neighbouring fingers.

Treatment. Iselin recommends a three-branched incision, the digital branch opening the lateral aspect of the finger along the line of union of the dorsal and palmar skin and carried up to the web, while the second and third branches split the web from before backwards from the base of the digital incision. A counter-incision on the other side of the finger is unnecessary. No drains are required in this wide exposure but the wound is lightly packed with gauze. In three to four days the packing is omitted and the fingers allowed to approximate When healed the scar is concealed in the web.

(b) Infection of the Synovial Sheath—Tenosynovitis.

The tendon sheath may be involved either by lymphatic extension or by direct continuity from a subcutaneous whitlow. Direct inoculation, unless precipitated by careless incisions, is rare, but the sheath may occasionally be infected from a subcutaneous abscess in the lumbrical canal. Infection through the lymphatics may follow a needle-prick, commonly in the distal or middle phalanx, and is usually streptococcal in origin.

Klapp has shown that at an early stage the pus is localized to one or two segments of the sheath; complete invasion is secondary and takes place in an irregular manner. The pus collects in front of the

TREATMENT

Under anæsthesia and in a bloodless field the pus cavity is located by a probe after the skin of the blister is removed. A lateral incision-

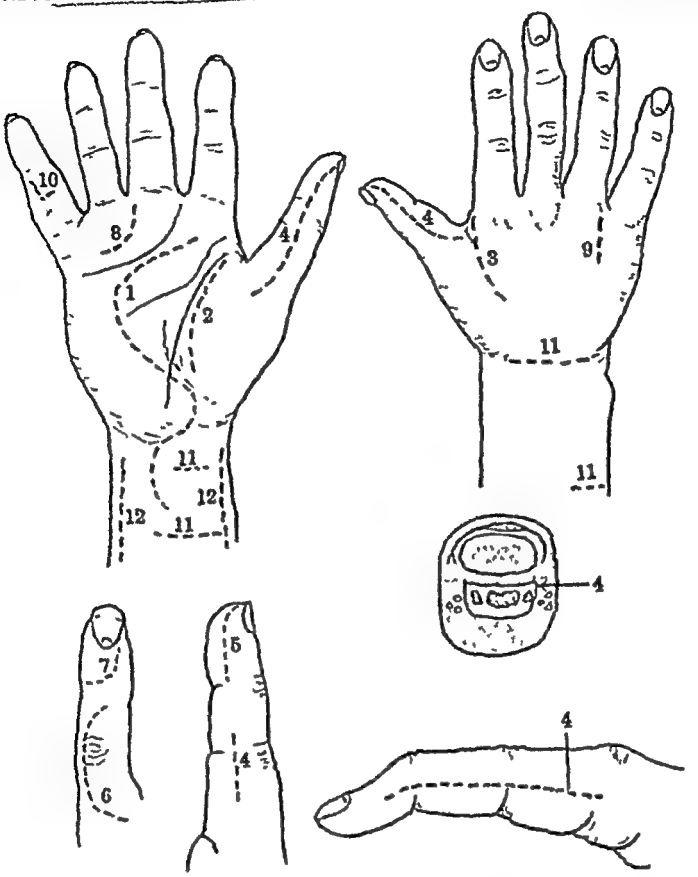

FIG 415 —Redrawn and captions quoted from Sterling Bunnell, *J Bone and Joint Surgery*, **14**, 27 (1932)

"A chart of advisable or correct incisions in the hand which will afford access and will not cause disability 1 Incision for approach into palm for drainage of middle palmar space It parallels the flexion creases, except in the immovable part or heel of the hand, allows wide opening by a triangular flap, and can be prolonged so as to separate without severing the branches of the medial nerve from those of the ulnar nerve It may then be extended up through the annular ligament at its ulnar edge and up the forearm as shown It crosses the flexion crease in the wrist in a curve so as to avoid resulting in flexion contracture 2 Incision for draining the thenar space It parallels the thenar crease, must not sever the thenar motor nerve and must leave pedicles sufficiently wide to nourish area of skin between it and incision for middle palmar space abscess 3 Incision for part of thenar space dorsal to adductor muscles to thumb It should be radial to the first interosseous muscle and stop short of cutting the radial artery as it passes through the first cleft 4 Mid-lateral incisions in fingers and thumb which avoid volar nerves and vessels and do not produce flexion contractures If made intermittently opposite the joints the annular ligaments or pulleys which are opposite the centres of the phalanges will be spared 5 Incision for drainage into pulp abscess One should cut across lateral fat columns, be posterior to the tactile surface and not cause tenosynovitis by nicking the sheath of the flexor tendon 6 Flap incision for approach to extensor tendon in finger so that the incision will be remote from the tendon 7 Incision for approach to insertion of extensor tendon 8 Palmar approach to collar-button abscess to give open drainage Avoid cutting nerve to finger 9 Dorsal approach to posterior part of collar-button abscess It does not overlie the joint or tendon 10 Flap incision for subcutaneous abscess One arm should be median to nerve The other blocks the upward spread of the infection 11 Incisions in forearm for reaching tendons should parallel the fine wrinkling of the skin to be inconspicuous eventually and to avoid keloid formation 12 Incisions for drainage of quadrilateral space in forearm Entrance should be just anterior to bones and anterior to the radial nerve and posterior to the dorsal branch of the ulnar nerve"

Two clinical types have to be distinguished:

1. Where the infection, generally staphylococcal, is a local one, such as that which commonly follows lacerated wounds. This type begins slowly, and there is time for plastic adhesions to form and limit the infection. There is little general reaction, but the local evidences are well marked.

2. Where the injury is slight, of the nature of a pin-prick or an insignificant cut. The infection is usually streptococcal and is carried to the sheath by a lymphatic vessel The pain is severe and in a few hours the finger is swollen, red, and exquisitely tender. There are early evidences of toxæmia. Plastic adhesions have not time to form, and the infection accordingly spreads rapidly through the entire system of communicating sheaths. This type is apt to be associated with early rupture of the sheath and extension into the connective tissue spaces. In neglected cases, there may be a spread into the palm or forearm, or a joint may become infected and undergo complete disorganization The infection may spread directly into the forearm in the case of the thumb and little finger, but only after a preceding invasion of the palm in the case of the other fingers In the forearm a diffuse cellulitis or a localized deep abscess forms under those circumstances.

Tenosynovitis of the Little Finger.

The flexor tendon sheath of the little finger communicates with the ulnar bursa in the majority of cases; in 80 per cent. of cases the ulnar bursa communicates with the radial bursa, so while infection may remain localized to the finger, it usually extends to other areas and particularly to the ulnar bursa, the radial bursa, and the fascial spaces of the hand and forearm

In the fulminating type infection of the ulnar bursa is rapid. This complication is marked by the development of œdema, especially on the dorsum of the hand. Although concavity is still present there is a fullness in the palm and also immediately above the annular ligament The most conspicuous sign, Kanavel's sign, however, is the spread of the exquisite tenderness to the new area involved, the point of maximal tenderness being at a point just proximal to where the distal flexion crease of the palm abuts on the hypothenar eminence.

When the infection spreads still further to involve the radial bursa, there is swelling and tenderness in the thenar eminence, and along the sheath of the flexor pollicis longus.

When the infection spreads still further to involve the radial bursa, the pus tracks along the connective tissue, or the intermuscular spaces. It first passes between the flexor digitorum profundus and the pronator quadratus to the space, known as Parona's space, between the flexor muscles and the interosseous membrane; at or about the middle of this area it passes more superficially, and towards the ulnar side, along the ulnar artery and nerve. The forearm becomes the seat of a brawny induration, but fluctuation need not be expected, since the abscess is

joint as the sheath shows a dilatation in front of each of the finger-joints separated by two narrower portions. The narrowing is produced by the constriction of the two pulleys or aponeurotic bands which enclose the tendons in front of the first and second phalanges. The tendon is restricted in this aponeurotic tunnel at these two areas and there is no room for pus. But in the inferior, the middle, and in the palmar dilatations, each opposite a joint, there is a space where the pus can and does collect. The swelling and implication of the tendon sheath produces a further narrowing and produces what Iselin calls a functional partitioning of the synovial cavity.

Extension from one sheath to another follows strictly the anatomical relationships, and occurs usually through a lumbrical space, or through a fascial space The ulnar bursa may be involved from the little finger and the infection then commonly extends to the radial bursa and to the sheath of the flexor pollicis longus. The pus may extend from the synovial sheath into the thenar space, either by rupture of the sheath directly into the space or via the lumbrical spaces on either side of the proximal phalanx. Less often, the proximal interphalangeal joint may be affected The synovial sheath of the thumb tends to rupture into the forearm, less commonly the thenar space may be implicated.

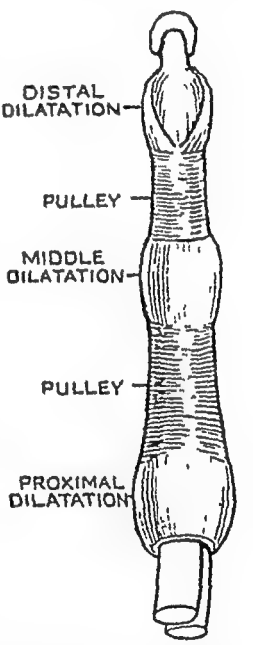

FIG 416—Diagram of the Digital Tendon Sheath showing the important Dilatations (After Iselin)

When the tendon sheath is affected, the finger becomes red, painful, and swollen, the swelling spreading rapidly to the dorsum of the hand. Sheath involvement is indicated by the absence of voluntary movement, the finger becomes rigid and contracted and attempts at passive extension induce great pain. Local tenderness is marked, and is confined to the anatomical limits of the sheath, it is usually most evident over the proximal end, at the metacarpo-phalangeal articulations.

The four cardinal symptoms and signs of tenosynovitis are

1. Excessive tenderness, limited to the disposition of the sheath.

2. Symmetrical enlargement of the whole finger.

3 Excruciating pain on extending the finger, this is most marked opposite the proximal end of the sheath.

4 A persistent attitude of flexion of the finger due to distension of the sheath It is inconstant and disappears when spontaneous rupture has taken place and when the distension has been relieved by a small incision.

Often the only sign is pain on pressure over the upper cul-de-sac of the sheath, in front of the head of the metacarpal bone

Treatment of Tenosynovitis

A bloodless field secured by tourniquet, general anæsthesia, and careful, planned dissection are essential if a suppurative tenosynovitis fails to resolve on penicillin-therapy and requires drainage

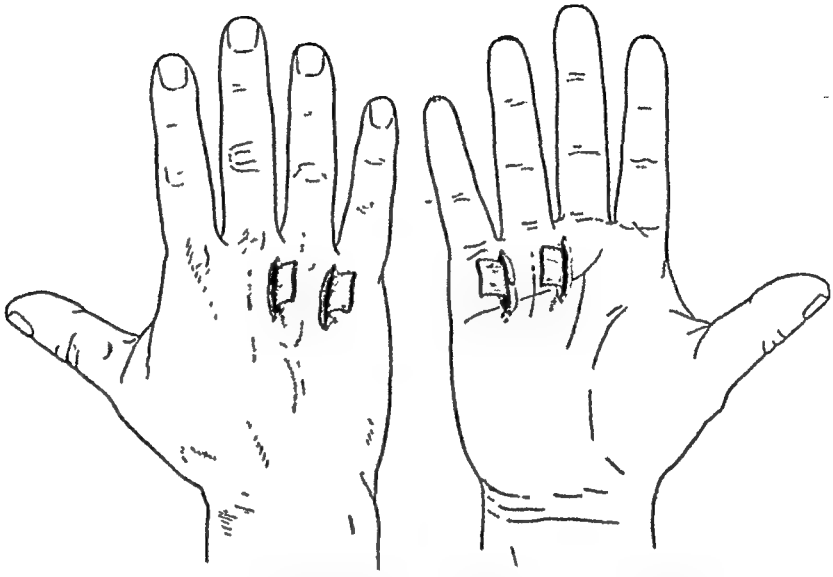

Fig 417.—Iselin's method of opening an infected Digital Sheath The Drains are inserted through the proximal dilatation

Iselin opens only the superior cul-de-sac of the sheath since that is where pus collects and where the tendon is in greatest danger. Four incisions are made, the two palmar ones just proximal to the web on

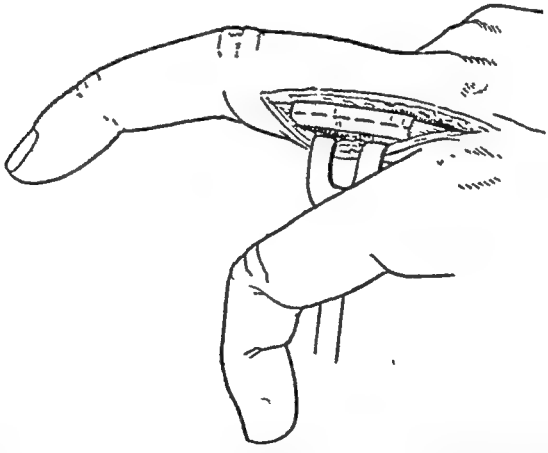

Fig 418 —If drainage of the proximal dilatation is not enough the first Pulley for the Tendon is exposed and divided along one side (After Iselin)

each side of the affected finger vertically upwards for 2 cm The cul-de-sac is opened on each side and a pair of forceps pushed back to raise the skin on the dorsum where further incisions are made over the points The forceps is pushed through, and opened to grasp strips of rubber

deeply situated When a definite ulnar or radial bursitis has lasted forty-eight hours, extension should be assumed, and appropriate incisions made.

When there is no free communication between the tendon sheath of the digital flexor and the ulnar bursa, the pus may rupture into the lumbrical or the palmar spaces. The web between the ring and little fingers is swollen and red, and the ulnar side of the adjacent ring finger is often similarly implicated. A collection of pus in the middle palmar space is accompanied by a slight bulging of the palm which replaces the normal concavity.

Tenosynovitis of the Index, Middle, and Ring Fingers.

Infection of the tendon sheaths of these fingers has the same features as that of the little finger, but the pathways of extension are somewhat more limited The most common spread is to the lumbrical space on either side of the proximal phalanx. From there it may spread to the dorsum of the hand via the web, to the tendon sheath of the adjacent finger, or to one of the palmar spaces—the middle in the case of the ring and middle fingers, and the thenar in the case of the index finger.

Tenosynovitis of the Thumb.

Tenosynovitis of the thumb usually precedes an infection of the radial bursa, and has similar features to the other types of thecal whitlow. The thumb is held in a position of semiflexion, and is uniformly enlarged. The patient may be able to flex the digit slightly, but under no circumstances can he be persuaded to extend it actively, and passive extension is attended with extreme pain. Exquisite tenderness is elicited by pressure on the volar aspect of the proximal phalanx and the metacarpo-phalangeal joint.

The spread to the radial bursa is usually rapid; occasionally, also, the radial is infected from the ulnar bursa, and, very rarely, from the thenar space. In all cases, pain, swelling and tenderness are present over the limits of the bursa. The thenar eminence looks fuller than normal, but the swelling here is mild in comparison with the ballooning that accompanies a thenar space infection.

In addition to the pain in the thumb, the index finger may also be slightly sensitive in radial bursitis.

Should the infection spread to the ulnar bursa, the symptoms and signs of ulnar bursitis supervene and actually predominate. It has to be emphasized that in such a spread there is no gross swelling of the palm.

In late and neglected cases, the radial bursa ruptures into the forearm; the rupture is preceded by the development of a swelling immediately above the transverse carpal ligament: from there the pus passes deep to the flexor tendons into the forearm.

(ii) Osteomyelitis and Bone Necrosis.

The distal phalanx is most commonly affected, usually from a subcutaneous whitlow. A radiographic examination may show the presence of a sequestrum, and a probe inserted through the sinus will encounter bare bone.

TREATMENT

The sequestrum, or the necrosed bone, should be removed Amputation should not be carried out at the same time, as in many cases the periosteum will form new bone to make good the defect In such a case an excellently functioning finger may be secured

(iii) Extension to the Fascial Spaces of the Palm.

Extension to the palm may complicate the subcutaneous or other types of whitlow, signs of infection may then arise in the thenar or middle palmar space, or in the radial or ulnar bursa.

These will be described later.

3. Abscesses of the Hand

(i) Infection of the Synovial Sheaths of the Hand.

These sheaths or bursæ enclose the flexor tendons in the carpal canal and in the palm, and are two in number—the radial and the ulnar The radial encloses the long flexors of the thumb and becomes continuous with the digital sheath at the base of the thumb The ulnar bursa forms a sheath for the two layers of the flexors of the fingers and communicates directly with the digital sheath of the little finger. The sheaths extend to about 25 millimetres above the radial styloid

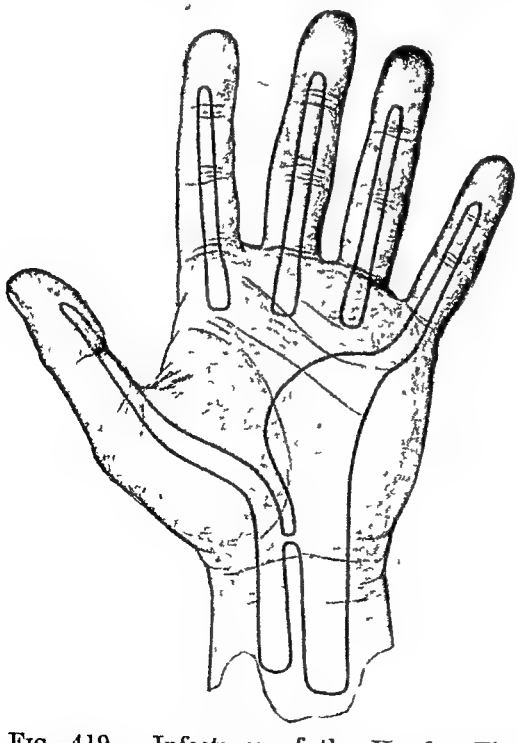

FIG 419 — Infections of the Hand The synovial compartments of the palm

Infection is generally through a punctured or incised wound in the neighbourhood of the tendon. Less often the infection may be due to an extension of a subcutaneous whitlow of the first or fifth finger, or a whitlow of the cellular spaces.

PATHOLOGY

In early cases the pus completely fills the radial bursa, but in the ulnar bursa it only occupies the deeper retro-tendinous part where the com-

dam which are pulled through to the palm. Dry dressings are applied and changed infrequently. Pain may persist for two to three days.

If in three to four days this drainage is unsatisfactory a dorsal incision is lengthened distally and the pulley divided on one side This incision leaves the vessels and nerves intact in front of the wound.

Alternatively, incisions may be made on the antero-lateral aspects of the proximal and middle phalanges just in front of the digital vessels and nerves. The resulting scar is thus removed from pressure and the tendon is prevented from starting forwards or prolapsing through the wound. The interphalangeal creases should be avoided unless they appear to act as constricting bands to the distal portions of the fingers. Once the pus has been discovered, an incision long enough to secure thorough drainage is required. The tendon sheath should therefore be carefully examined, and, if distended and full of fluid, or if pus can be seen escaping from it through a small hole, it should be split up along its entire length, the overlying tissues including the skin being divided accordingly. If the tendon is found in a sloughing condition it should be removed, but it should in all cases be given the benefit of any doubt as to its vitality

2. The Complications of Whitlows

Infection may extend from its primary site to infect neighbouring and important areas Thus it may involve the joint, giving rise to a suppurative arthritis; it may implicate the bone, and produce an osteomyelitis; or it may, and not infrequently does, extend to the fascial spaces in the palm of the hand

(i) Suppurative Arthritis.

This is most commonly due to extension from a thecal whitlow, the proximal interphalangeal joint being the most frequently affected.

The pathology is similar to that of suppurative arthritis of any other joint. The usual constitutional disturbance is present, and locally the joint is red, hot, swollen, and painful, while its function is seriously interfered with. The joint tends to assume an attitude of slight flexion. An abscess may form on the dorsal or the dorsi-lateral aspect of the joint and eventually sinuses may supervene.

TREATMENT

The best and most satisfactory treatment when the distal interphalangeal joint has become involved is immediate disarticulation through the joint.

When the proximal interphalangeal joint is infected, amputation through the metacarpo-phalangeal joint offers the best chance, although if there is no tenosynovitis and the joint is only partially involved, excision may be carried out Excision, however, is not attended with a good functional result, and it is therefore rarely indicated

results In diffuse infections, however, the condition of the hand after healing is usually very bad The wrist is ankylosed, the fingers may be stiff and rigid in the typical attitude of interosseous paralysis

TREATMENT.

Iselin points out that uncomplicated synovial whitlows and diffuse ones require different operative techniques The uncomplicated tenosynovitis requires forearm incisions over the superior cul-de-sac. For an ulnar bursa infection the ulnar incision is enough, but for a radial bursa infection or an infection of both bursæ the ulnar incision is completed and supplemented by a short radial incision to permit introduction of through and through drainage.

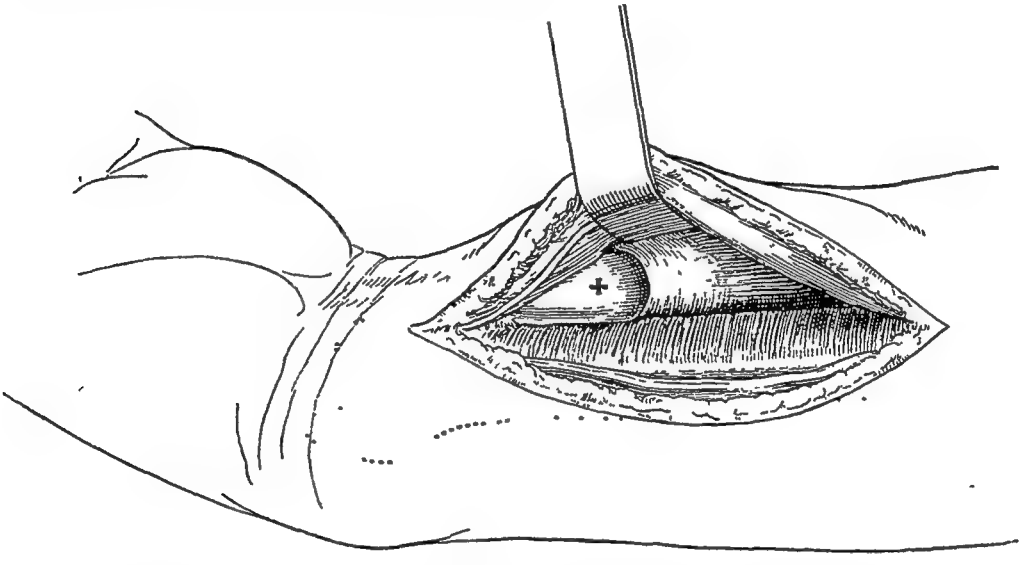

FIG 420 —The incision to expose the Tendon Sheaths in the Forearm The flexor carpi ulnaris is retracted after stripping it from the Ulna and the synovial Sheath exposed It may have burst or may require opening at + (After Iselin)

For a diffuse synovitis additional incisions in the hand are required Incisions into the finger are useless The hand incisions enable us to insert transfixion drains through the interosseous space between the fourth and fifth metacarpals when the ulnar bursa is involved, and through the web of the thumb in infection of the radial bursa If there should also be an extension into the superficial palmar space it must be evacuated by a low median incision. The lower forearm incision on the ulnar side is made over the easily palpable border of the ulna for a distance of about 3 or 4 inches. The aponeuroses are incised immediately in front of the border of the ulna, along the line of the interspace that lies between the ulna and the flexor carpi ulnaris tendon The wound is enlarged in an upward direction by detaching the lower fibres of that muscle from their insertion into the bone The flexor carpi ulnaris is then retracted and the deeper aponeurosis, which is best marked in the lower part where it forms almost an accessory covering

munication with the digital sheath of the little finger is situated. When inflamed, the external aspect of the sheath is œdematous and congested. The interior is dull, thickened, and in places shows yellow plaques The infection may pass from one bursa to the other, generally along the pre-existing anatomical communication. Extensions into the cellular spaces are frequent, as is also extension into the forearm which is a serious complication. When the latter occurs the pus escapes from either bursa into the cleavage plane that lies behind the posterior aspect of the sheath and in front of the pronator quadratus, a space known as the space of Parona. Further spread may then take place upwards into the forearm along the plane between the two groups of flexor muscles.

There are two main types of infection of the bursæ—

(1) The purely synovial form in which the diagnosis, based on classical signs, is easy, the treatment simple, and the prognosis excellent with modern technique.

(2) The diffuse form, in which diagnosis is difficult, of which the treatment calls for multiple interventions, and in which the outlook is much more uncertain.

In the first type the pus is still within the synovial sheath and the signs are definite. In the diffuse tenosynovitis pus has already spread to one or other of the spaces to be described, the signs are misleading and often incomplete.

Clinical Features.

Pain appears on the day following infection, first in the finger and then in the hand and finally in the wrist. It increases rapidly, prevents sleep and causes a high temperature. On inspection the hand is enormous, swollen on its palmar, but especially on its dorsal aspect. The swelling and redness spread to involve the front of the forearm. The fingers are semi-flexed

1. Simple Infections of the Bursæ.

The flexed finger and the shooting pain, typical of a tenosynovitis, are present. Any attempt to straighten the finger increases the pain, which is felt most severely in the infected finger, so that in an infection of the radial bursa the thumb only is completely rigid and inextensible, while the other fingers can be extended. When the ulnar bursa is infected the fifth finger is stiff and tender.

2 Diffuse Synovitis.

The classical signs of tenosynovitis are no longer present. The difficulty lies in the recognition of a synovial infection underlying the more serious collections in the cellular spaces and diagnosis cannot usually be made with certainty until the hand has been explored.

When the infection remains localized in the sheath the prognosis is good although functional impairment of the affected finger usually

retracted inwards with the radial artery. The pus has generally become diffused in the retro-tendinous space, but in some cases it may be necessary to evacuate it by an incision. A radial incision alone is never sufficient though an ulnar one may be since it furnishes dependent drainage.

When the tenosynovitis has become diffuse palmar incisions are required. The ulnar palmar incision, 2 cm. long, is made in the fourth interosseous space, reaching down to 1 cm. from the web. Forceps are passed through the space from front to back and the projection of its points cut down on to make a shorter dorsal incision A through and through drain is introduced.

The thenar incision is made into the thick of the commissure of the thumb, mid-way between the internal border of the thenar eminence and the base of the thumb. An incision is made on the dorsal surface of the first interosseous space and a through and through drain inserted to evacuate the palmar and any dorsal collection.

Post-operative Treatment.

The hand is immobilized in the position of function on a plaster slab or a wire splint. The dressings are changed infrequently unless the temperature fails to subside. Absolute immobilization of the hand in an elevated position to keep the forearm incisions dependent is essential to ensure a successful result The drains are removed about the fifth or seventh day and the dressings and splints reapplied and immobilization continued for a few days longer.

(ii) Infection of the Palmar Cellular Spaces.

Six cellular spaces of the hand are described by Iselin. In the central palmar region there are three—the superficial pre-tendinous palmar space, the deep retro-tendinous palmar space, and the commissural or web spaces There are also the thenar space in the thenar eminence, the hypo-thenar space in the hypo-thenar eminence, and the dorsal space on the back of the hand.

(1) *The central superficial pre-tendinous palmar space* lies in the palm of the hand immediately underneath the palmar aponeurosis and is limited behind by the tendons and the vessels of the superficial palmar arch The lateral boundary lies along the line of the second metacarpal, while the medial boundary lies along the fourth inter-metacarpal space. It communicates with the forearm, the first web space of the finger, and with the retro-tendinous space.

(2) *The deep central palmar space.* This lies behind the flexor tendons and in front of the deep palmar, the so-called interosseous aponeurosis It communicates with the fingers through the lumbrical canals, with the thenar space, and with the forearm behind the tendon sheaths

(3) *The commissural spaces* are three in number and lie in the webs of the fingers and are about the size of a cherry-stone

to the deeper portion of the ulnar bursa, is incised. The pronator quadratus is then exposed and recognized by the transverse direction of its fibres and the pearly lustre of the tendinous strands of its insertion into the ulna. It is absolutely necessary to get down to the pronator quadratus.

The ulnar nerve and vessels are neither seen nor in danger because they are displaced forward and protected by the retractor. The finger is thrust under the tendons, relaxed by flexion of the wrist, to ascertain the extent of upward spread, and the cutaneous incision is extended as far as may be necessary.

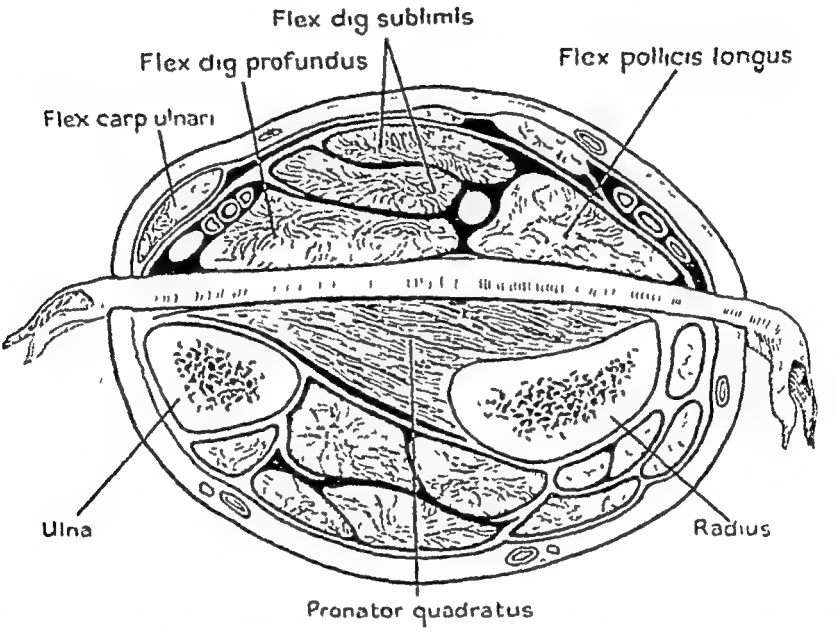

FIG 421 —A Section of the Forearm above the Wrist showing the Method of draining Parona's Space

When still within the sheath pus is not discovered when the pronator quadratus is exposed and the tendons lifted The synovial cul-de-sac must then be exposed and opened This is easily done because the cul-de-sac bulges when pressure is applied to the palmar pouch and is then easily visible Care must be taken to make the opening sufficiently large to furnish adequate drainage Drainage is best ensured by a rubber strip

The Radial Incision In making this incision care must be taken not to carry it down further than 3 cm above the radial styloid so as to avoid the radial artery and the abductor pollicis longus The superficial aponeurosis is incised along the anterior border of the brachioradialis The incision should not be made too far forward because that would endanger the radial artery In this situation we seek to expose the pronator quadratus which is still covered by the deep aponeurosis The external border of the flexor longus pollicis is exposed just below its last fibres of origin from the radius. This border is freed and

the thumb, and the remainder of the palm is flat, supple and painless. Palpation elicits intense pain on pressure over the thenar eminence and over the web which is red and so swollen that the thumb is held abducted by the swelling For the drainage of this collection Kanavel prefers an incision over the web of the thumb, the space being approached thereafter by inserting closed artery forceps in the direction of the space.

2. Infection of the Hypo-thenar Space.

The pus is localized between the hypo-thenar muscles and their aponeurosis and completely fills the space. Intense pain is experienced, while the area is red, swollen and extremely tender. The notable feature is the restriction of the symptoms to the hypo-thenar eminence. The space is incised antero-laterally and drained by a strip of rubber and usually heals quickly, in less than a week.

3. Infection of the Retro-tendinous Central Palmar Space.

This is not a common infection and usually results from a rupture of the digital tenosynovitis which has burst at the superior cul-de-sac The amount of pus is never very large, usually not more than about 1 drachm. It usually produces a paralysis of the interossei, which paralysis may remain for some time. Often there are trophic changes in the fingers as a result of involvement of the nerves and vessels in their palmar course

Clinical Features.

Following on a tenosynovitis which has been opened the temperature and swelling do not subside, or may reappear after having temporarily improved The pain becomes dull and localized in the palm The swelling is visible on inspection and is associated with redness of the median part of the palm, particularly towards the webs of the fingers and on the dorsum of the hand. Flexion deformity of the fingers is not marked but active movements are painful. The palm is painful on pressure and this may produce some exudation of pus from the drainage incision of the tenosynovitis. The hand is characteristic in appearance in that the first phalanx is extended while the second and third are flexed, but not to any marked extent.

Iselin suggests that the operative methods are two in number (1) drainage of the collection by incisions avoiding injury to the sheaths; and (2) amputation of the finger in which the infection originated The latter is suggested particularly in cases of tenosynovitis where the original operation has been by a median incision which certainly destroys the function of the finger He also resects the head of the metacarpal since it acts as a plug and blocks the infected spaces from below Where the condition has not been a sequel to a tenosynovitis Kanavel makes an incision through the inferior portion of the inter-digital space along the lumbrical muscle This incision can be prolonged upwards for

(4) *The thenar space* lies in front of the transverse head of the adductor pollicis behind the thenar, or inter-muscular aponeurosis, attached to the third metacarpal

(5) *The hypo-thenar space* is limited on all sides by the hypo-thenar aponeurosis which commences on the external border of the fifth metacarpal and terminates on the ulnar border of the same metacarpal.

(6) *The dorsal space* is limited in front by the fascia covering the back of the metacarpal bones and the interossei muscles, and behind by the superficial dorsal aponeurosis and the skin.

From the anatomical point of view, therefore, there are six varieties of cellular infection of the hand corresponding each to one of the spaces above described. The distinction between tendon sheath infections already described and those of the cellular spaces is that sheath infections are much more serious, while infections of the cellular spaces are more frequent and may spread to the sheath if the collection is not recognized early and opened up before it has had time to spread to involve these neighbouring structures.

1. Infection of the Thenar Space.

This space is anatomically well defined and therefore its infection should produce characteristic clinical effects. The pus is located in the palm, anterior to the transverse head of the adductor pollicis. It

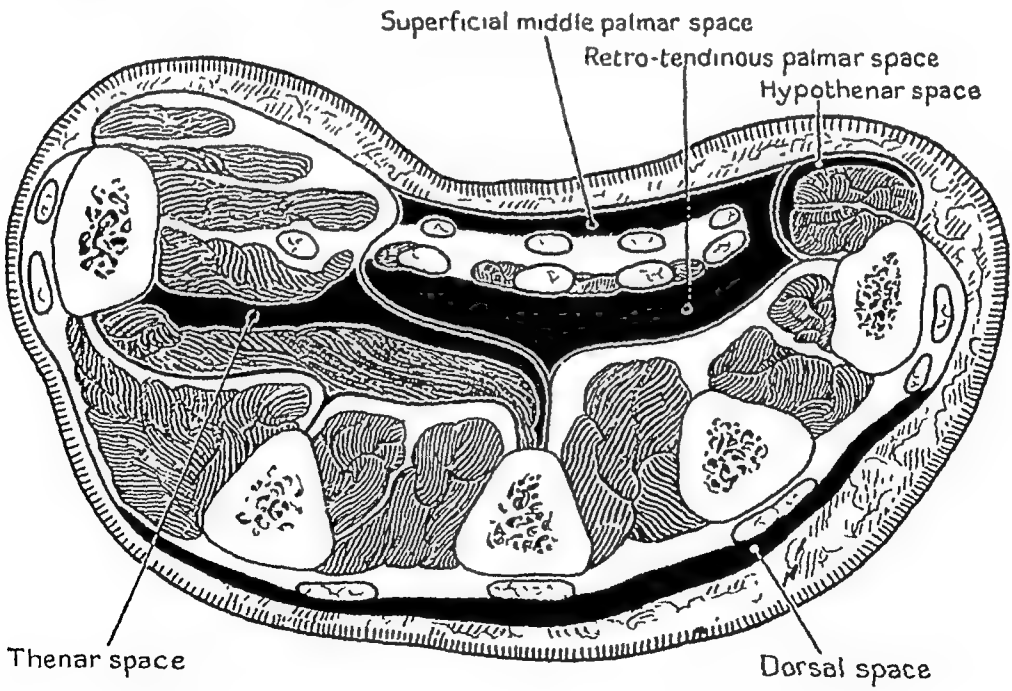

FIG 422 —The cellular Spaces of the Hand shown in a cross-section

spreads towards the web and from there may reach the dorsal aspect. The thenar region is markedly swollen both on the palmar and dorsal aspects, but this swelling ceases abruptly at the adductor crease of

but usually remains confined to the hand and does not extend to the wrist

CLINICAL FEATURES.

The pain is moderate but the temperature rises quickly. Inspection reveals considerable swelling and redness of the entire dorsum of the hand. Œdema involves the roots of the fingers and spreads up to the forearm which is streaked by lines of inflamed lymphatics

Diagnosis is not always easy because the pus may be masked by the extensive œdema of the back of the hand.

TREATMENT

Suppuration may be obvious, otherwise the base of the inter-digital space in which pus is suspected is incised. The pouch is then explored with curved forceps and counter-incisions made and drains inserted from one to the other.

Some Considerations in the General Treatment of Hand Infections

The principles of treatment laid down by Wilson for the treatment of these acute infections are three in number

(1) The provision of adequate rest.
(2) An adequate supply of an anti-bacterial drug
(3) Timely and adequate incisions where required

He emphasizes the importance of tension in such lesions and points out the profoundly destructive effect it has Tension is responsible for the infection and destruction of the phalanx in pulp infection and for the destruction of the endothelium in thecal infections with its resultant fibrosis and fixation. The results of sheath infection in the index, middle, and ring fingers are usually followed by serious disability whereas in infection in the thumb and little fingers they are often satisfactory Wilson believes this is due to the fact that pus within the sheaths of the index, middle, and ring fingers is confined within a non-tensile fibrous sheath, whereas in the case of the thumb, and little finger, the tension is relieved by the expansion of the radial and ulnar bursæ The tension, too, in these acute infections, interferes with the access to the infected area of any anti-bacterial agent which may be employed

Where practical, the patient should be confined to bed and the toxæmia treated A light nourishing diet is given and an attempt made to eliminate the toxins by way of the bowel, the kidneys and the skin. Bland fluids are given liberally Where penicillin is not immediately available, sulphonamides may be given in liberal doses

Rest is ensured by splinting the part Plaster slabs are used and the arm is put in a sling.

Penicillin in a dose of 500,000 units is given twice daily. It is given intramuscularly in all cases prior to the formation of pus, but when pus forms it may be discontinued if much sloughing is present, as it has been found to delay the separation of sloughs. Incision is carried

4 cm. into the palm. A pair of closed forceps should be passed up under the tendons into the retro-tendinous space and then opened to evacuate the pus. A strip of rubber in this incision gives good drainage.

4. Infection of the Superficial Pre-tendinous Central Palmar Space.

The term "subcutaneous" given to this space is erroneous since the collection is sub-aponeurotic and not subcutaneous. Infection may come from infected blisters, or a whitlow, or from cuts and pricks. The pus lies under the palmar aponeurosis and the tendons in their sheath are pressed backwards to form the posterior wall of the infected space. There is usually only a few cubic centimetres of pus. The collection may spread towards the skin of the palm and produce a collar-stud abscess, or it may spread to the web or to the thenar space.

CLINICAL FEATURES.

There is severe pain and high temperature The centre of the palm of the hand is markedly swollen with well-marked lateral limitations. There may be swelling in front of the wrist with redness and œdema spreading up the forearm. Active movements of the fingers and wrist are restricted, but passive movements are normal.

The treatment consists in incision of the palm in the mid-line. The vessels and nerves lie deep to the pus so are out of danger. The edges of the skin and the aponeurotic wound should be excised to prevent their tendency to close. Spread in any direction is treated by counter-incision.

Infection of the Finger Web.

This is the most common of these infections. Pain is localized to the finger web and is severe. The two fingers on either side of the affected web are separated and cannot be approximated. The web itself is swollen and red, both in front and behind. The swelling is symmetrical, differing from a whitlow of the first phalanx The hollow of the palm and its surroundings remain quite normal. Finger movements, though restricted, are still possible and painless.

TREATMENT.

An incision 2 cm in length is made on the palmar aspect of the web to evacuate the collection. A dorsal counter-incision is added and a strip of rubber pulled through Whenever the infection appears to be serious the web of the finger may be completely split. This gives little trouble later as the cut edges tend to fall together.

Dorsal Cellulitis.

In an infection of the dorsal space the pus is subcutaneous, the vessels, nerves and tendons being displaced forward against the deeper planes. The pus may spread over the whole extent of the dorsal aspect

gluteus maximus and the femur An X-ray film should be taken to exclude the presence of osteomata, or of osteochondritis. The snapping may become habitual, and a source of considerable discomfort to highly strung nervous people.

The writer recalls a case where, following an osteotomy for a flexed and adducted tuberculous hip, a snapping hip developed on the healthy side. The abductor on the normal side was apparently displaced medially to the great trochanter so that the fascial band snapped backwards and forwards over it

If operative treatment becomes necessary, division of the offending band or tendon or surgical resection of the prominence of the trochanter and a fibrous mass arising from the tensor opposite the trochanter gives an excellent result. If an osteoma or exostosis is present it is of course removed.

When the tensor fasciæ latæ is at fault the author makes three vertical incisions separated by three-eighths of an inch in the tensor fascia and divides them below so as to form two long strips attached to the muscle above. The two tails are then laced through an antero-posterior perforation in the trochanter, one entering from behind and one from the front They are sutured together and so fix the important factor in the causation of the snap.

out when pus has formed. In all cases space for drainage must be provided. If a linear incision seems to be inadequate, a narrow ellipse or circle of skin is also excised. Such drainage is preferable to the insertion of rubber-dam drains and where the latter are used they should be removed after a minimal period. In addition to incisions for drainage of pus, they may be used to relieve tension in certain cases, notably in the acute pulp infection where the examining finger can easily detect dangerous tension. Incisions are made under perfect anæsthesia and always with the aid of a tourniquet

Dry dressings are more satisfactory than wet ones since the latter lead to maceration of the skin. Redressing is carried out as infrequently as possible

Iselin points out that dressings are used only to protect the wound from external contamination and are in no way therapeutic. They absorb the secretions and help in splinting the finger.

Mobilization begins when the acute process has subsided and movements are then of an active nature. No forcible passive movements are allowed

Amputation is sometimes called for, and the following may be held to indicate the removal of the part:

1 Sloughing of the tendons
2 Suppurative arthritis.
3 Stiffness of the finger—either in the flexed or the extended position
4 Osteomyelitis—acute or chronic.
5. Gangrene
6. Painful scars.

SNAPPING HIP

An audible sound or click may be heard or felt during certain movements of the hip joint It may have a variety of explanations, some of which are intra-articular, while others are due to factors outside the joint.

The rare intra-articular type occurs in children, and is due to slight voluntary displacement of the head of the femur over the upper and posterior border of the acetabulum so that the thighs are sharply flexed and adducted. The displacement eventually becomes a habit, and is best prevented by firm bandaging to prevent hip flexion.

The more common extra-articular type is analogous to luxation of the peroneal tendon at the ankle The snap is heard, and felt, when the knee is flexed and the hip rotated medially At times a tight band may be seen to slip backwards and forwards over the great trochanter. This form occurs both in adults and children, and is apparently due to friction between the anterior border of the gluteus maximus and the trochanter, or between a fascial band and the bony prominence. It is also encountered in cases of arthritis, or in effusion into the bursa between the